

The Pelvis and Acetabulum, 2251

The Hip, 2273

The Femur, 2301

The Knee, 2321

The Tibia, 2371

The Ankle, 2391

The Foot, 2414

The Pelvis and Acetabulum

PELVIC AND ACETABULAR FRACTURES

Pelvic and acetabular fractures are much less common in children than in adults and are most often due to high-energy trauma. It is vitally important for the person evaluating a child with a pelvic fracture to investigate other organ systems for potentially life-threatening injuries, including the vascular, genitourinary, and neurologic systems. Treatment is most often nonoperative owing to the elastic nature of the child's pelvis and the surrounding soft tissue. Operative treatment usually consists of internal fixation, external fixation, or a combination of both.

Anatomy. The pelvis is formed from three primary centers of ossification—the ischium, ilium, and pubis—and also includes the sacrum. The three centers of ossification join at the triradiate cartilage, which fuses at 16 to 18 years of age (Fig. 42–1).⁴² At the inferior pubic rami, fusion of the ischium and pubis takes place at age 6 to 7 years.

The secondary centers of ossification are the iliac crests, which appear at 13 to 15 years of age and fuse at 15 to 17 years, and the ischial apophyses, which appear later, at 15 to 17 years, and fuse at 17 to 19 years.⁴² Other secondary centers of ossification include the anterior-inferior iliac spine, the pubic tubercle, the angle of the pubis, the ischial spine, and the lateral wing of the sacrum.

The stability of the sacroiliac joint is due to the strong anterior and posterior ligamentous structures. The anterior ligamentous structures are weaker than those posteriorly and are composed of a flat ligament running from the ilium to the sacrum. Posteriorly there are short and long ligaments: the short posterior ligaments travel obliquely from the posterior ridge of the sacrum to the posterosuperior and posteroinferior spines of the ilium; the long posterior ligaments are longitudinal fibers running from the lateral sacrum to the posterosuperior iliac spines. These then merge with the sacral tuberos ligament and are the major stabilizing ligaments of the sacroiliac joint.

The development and growth of the acetabulum in children has been described in a classic article by Ponseti.²⁸ The acetabulum in childhood is composed of growth plate cartilage of the ilium, ischium, and pubis, peripheral articular cartilage, and hyaline cartilage (Fig. 42–2). Growth of

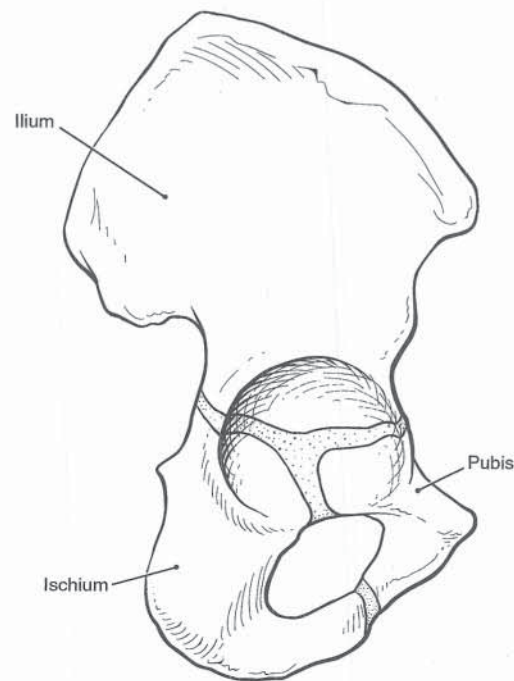


FIGURE 42–1 Lateral view of the pelvis demonstrating the relationship of the ilium, pubic bone, and ischium and their junction at the triradiate cartilage.

the acetabulum occurs from interstitial growth within the triradiate aspect of the cartilage complex, causing the hip joint to expand. The presence of the femoral head within the acetabulum promotes the development of the concavity of the acetabulum. The depth increases as a result of interstitial growth in the acetabular cartilage, appositional growth at the periphery, and periosteal new bone formation at the acetabular margin. Secondary centers of ossification appear at puberty and include the os acetabuli (epiphysis of the pubis), forming the anterior wall; the acetabular epiphysis (epiphysis of the ilium), forming the superior wall; and the seldom seen epiphysis of the ilium. These secondary centers of ossification appear at approximately 8 to 9 years of age and unite at approximately 18 years of age.

Ligamentous structures connect various portions of the pelvic ring to provide stability (Fig. 42–3). The sacrotuber-

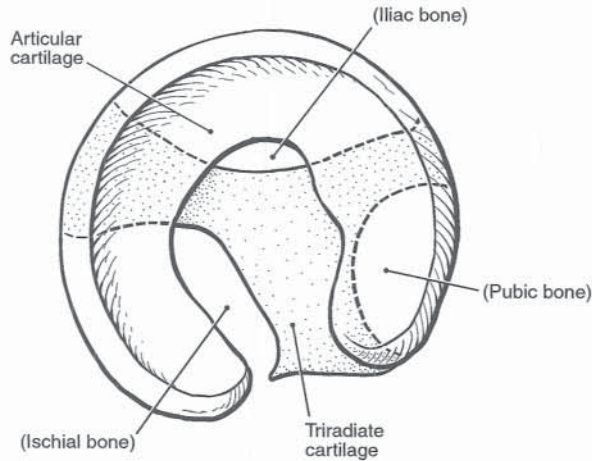


FIGURE 42-2 Diagram of the triradiate cartilage demonstrating the sites occupied by the iliac, ischial, and pubic bones. (From Ponseti IV: Growth and development of the acetabulum in the normal child. *J Bone Joint Surg* 1978;60-A:575-585.)

ous ligament connects the posterolateral aspect of the sacrum and the dorsal aspect of the posterior iliac spine to the ischial tuberosity. The sacrospinous ligament connects the lateral aspect of the sacrum and coccyx to the sacrotuberous ligament and inserts on the ischial spine. In addition to the ligamentous connections within the pelvis, there are numerous connections between the pelvis and the spine. The ilio-lumbar ligaments bridge the transverse processes of L4 and L5 to the posterior iliac crest. The lumbosacral ligaments run from the transverse process of L5 to the ala of the sacrum.

Pelvic and acetabular injuries differ from those same structures in adults in several ways. Owing to the presence of various apophyses, avulsion injuries occur in children. In addition, growth plate injuries may occur, especially in

the acetabulum, and can lead to a dysplastic acetabulum or leg length discrepancy.⁵ Also, the child's pelvis is more elastic because of the mechanical properties of children's bone and the presence of more cartilaginous structures; consequently, after a significant pelvic injury, radiographs may show only a single innocuous-appearing fracture.

Other organ systems that lie adjacent to or within the pelvis include the nervous, genitourinary, and vascular systems. The lumbosacral coccygeal plexus enters the pelvis and is composed of the anterior rami of T12 through S4. The sciatic nerve exits the pelvis from beneath the piriformis muscle and enters the greater sciatic notch (Fig. 42-4). Major vascular channels lie on the inner wall of the pelvis. The common iliac vessel divides, giving off the internal iliac artery, which lies over the pelvic brim, and the superior gluteal artery, which crosses over the anteroinferior portion of the sacroiliac joint to exit the greater sciatic notch, where it lies directly on bone. The bladder and urethra are the structures of the urinary system that are most often injured following a pelvic fracture. The bladder lies superior to the pelvic floor and the urethra passes through the prostate in males to exit the pelvic floor. The membranous urethra is the initial portion, at the upper surface (followed by the bulbous portion, below the pelvic floor), and is the portion most often injured.

Classification. Several classification systems exist for pelvic fractures in adults.^{4,14,26,38,39,44} These classifications are based on the anatomic site of the fracture,¹⁴ the mechanism of injury,⁴⁴ and the mechanism and stability of the pelvic fracture.^{38,39} The two most common classification systems utilized are those of Young and Burgess (Fig. 42-5)⁴⁴ and Tile and Pennel (Fig. 42-6).^{26,39}

The Young and Burgess classification is based on the direction of the offending force: anteroposterior compression, lateral compression, and the vertically unstable or shear-type injury. The Tile and Pennel classification is simi-

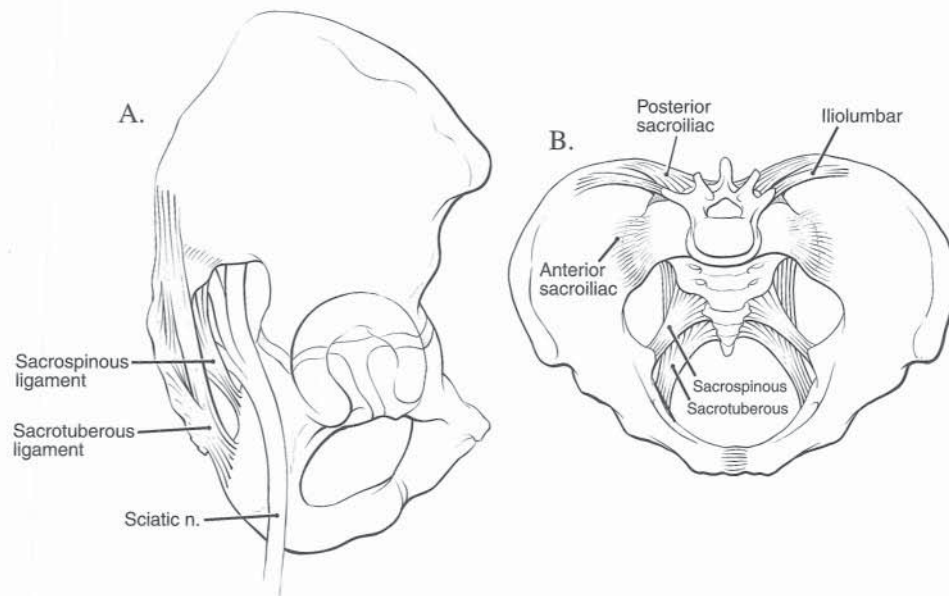


FIGURE 42-3 Ligamentous structures that provide stability to the pelvic ring. A, Lateral view of the sacrospinous and sacrotuberous ligaments. B, AP view of the sacrospinous and sacrotuberous ligaments. Posterior ligamentous structures include the strong posterior sacroiliac ligament and iliolumbar ligaments and the weaker anterior sacroiliac ligaments.

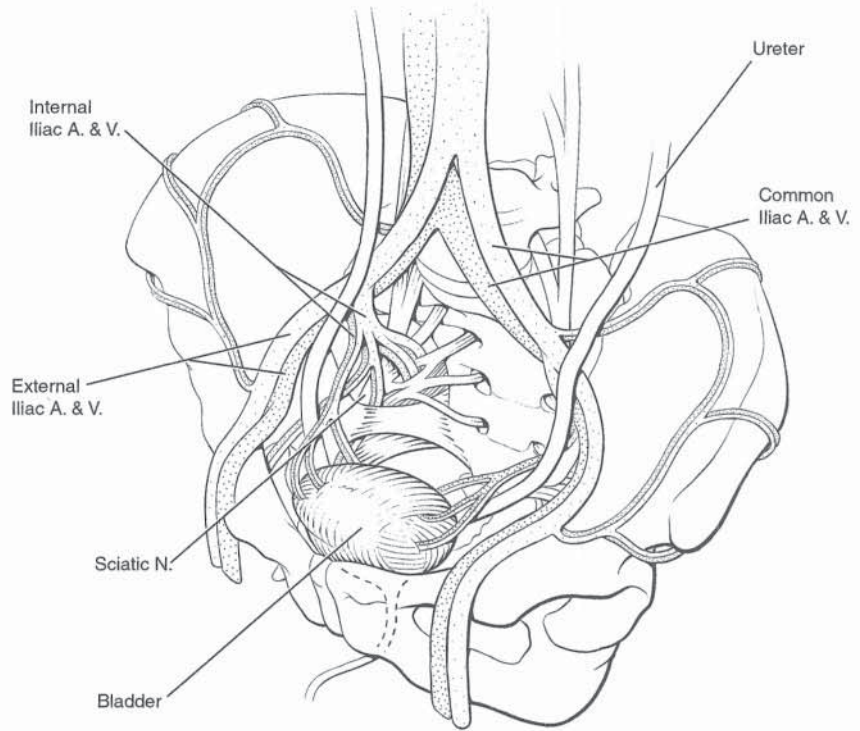


FIGURE 42-4 Internal view of the pelvis showing the relationship of the great vessels, lumbo-sacral plexus, bladder, and ureters.

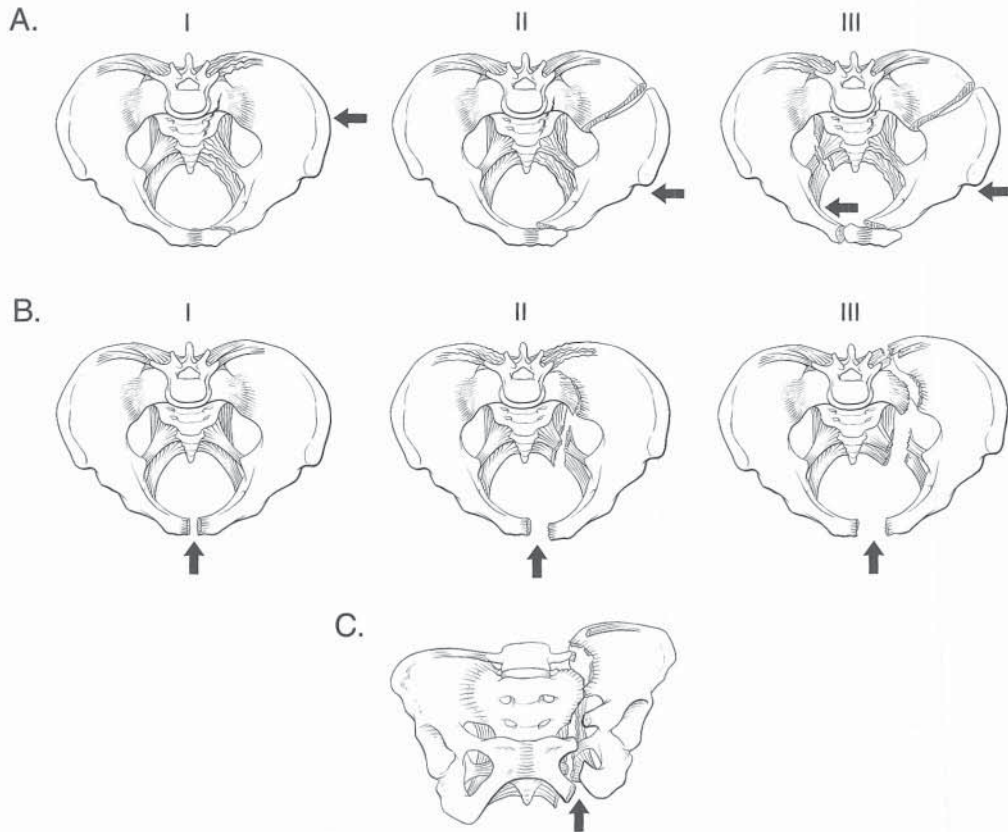


FIGURE 42-5 Young and Burgess's classification of pelvic fractures. A, Lateral compression force. *Type I*: The posterolateral force results in a sacral and pubic ramus fracture. *Type II*: The anterolateral force results in an additional iliac wing fracture. *Type III*: Further force creates an opening injury to the contralateral pelvis with disruption of the sacrospinous, sacrotuberous, and anterior sacroiliac ligaments. B, Anteroposterior compression force. *Type I*: Disruption of the symphysis pubis. *Type II*: Disruption of the anterior ligaments. *Type III*: Disruption of the posterior ligaments. C, Vertically directed force creating fractures in the rami and disruption of the sacrospinous joint.

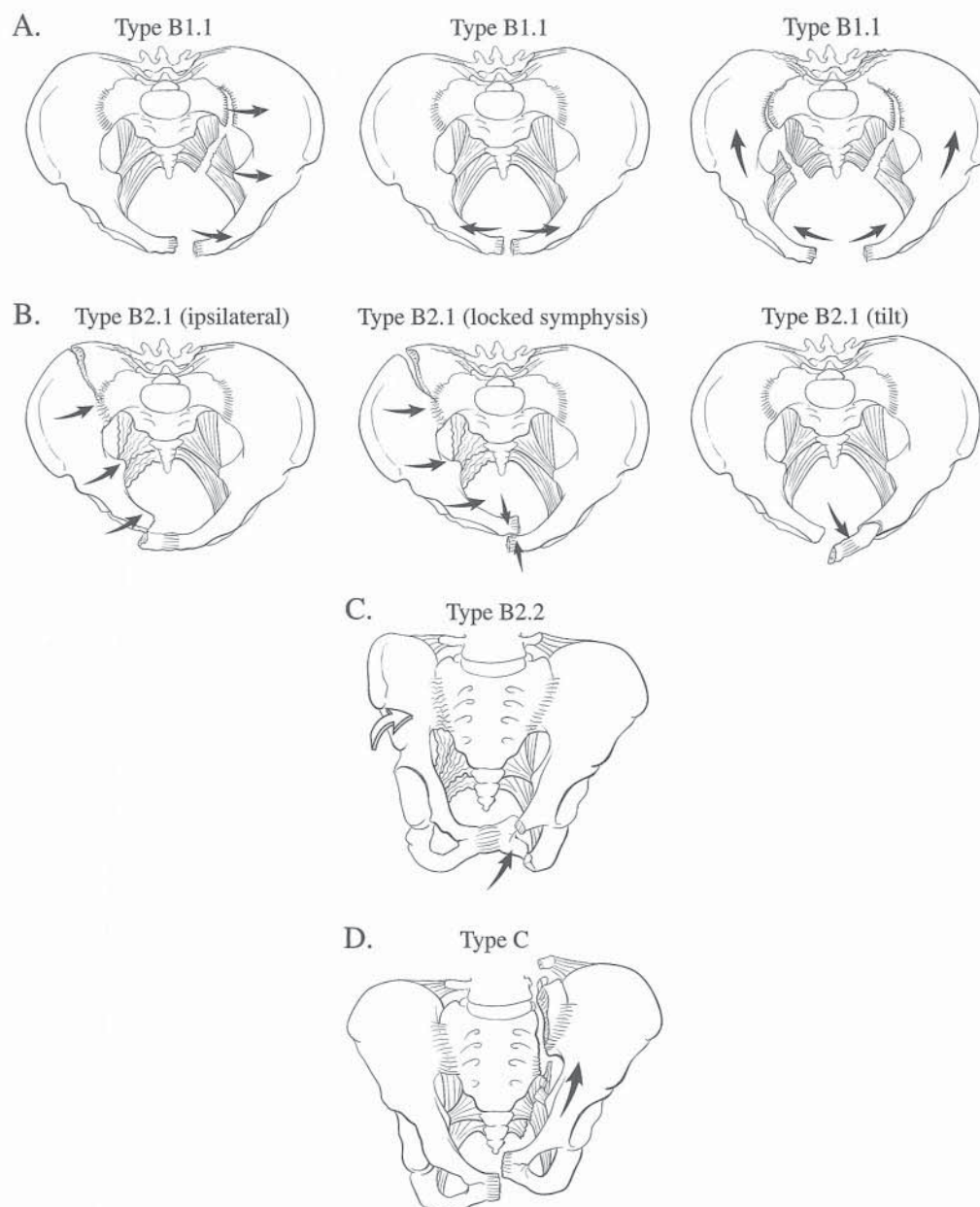


FIGURE 42-6 Tile and Pennel's classification of pelvic fractures. Stable fractures that do not involve the pelvic ring are not shown. A to C are the rotationally unstable but vertically stable fractures. A, External rotation or "open-book" fractures. B, Internal rotation or lateral compression injuries with ipsilateral injury only. C, Lateral compression injuries with contralateral fracture. D, Vertically and rotationally unstable fractures of the pelvis.

lar in determining the mechanism of injury and the stability of the pelvis, and aids in treatment planning. Three major categories of fractures exist. The type A fracture is stable and includes avulsion injuries, minimally displaced fractures, and transverse fractures of the sacrum and coccyx; type B fractures include the rotationally unstable but vertically and posteriorly stable fractures; and type C fractures are severe fractures with rotational, posterior, and vertical instability (Fig. 42-6).

Because of the differences in anatomy and fracture patterns in children and adolescents, separate classifications for pediatric pelvic fractures have been developed.^{3,30,40,42} Quinby divided patients into three categories based on associated injuries: group I, patients needing laparotomy; group II,

those not needing laparotomy; and group III, patients with an associated severe vascular injury.³⁰ This classification has little utility today because of the lower incidence of laparotomy in the pediatric population, but it does illustrate the high prevalence of visceral and vascular injuries in association with pelvic fractures in children. Watts divided pelvic fractures according to the radiographic findings: group I, avulsion injuries, usually of the anterior superior or inferior iliac spine and the ischial tuberosity; group II, fractures of the pelvic ring, both stable and unstable; group III, acetabular fractures.⁴²

We prefer the more recent classification scheme described by Torode and Zieg, which is a four-part classification based on the radiographic examination findings: type I, avulsion

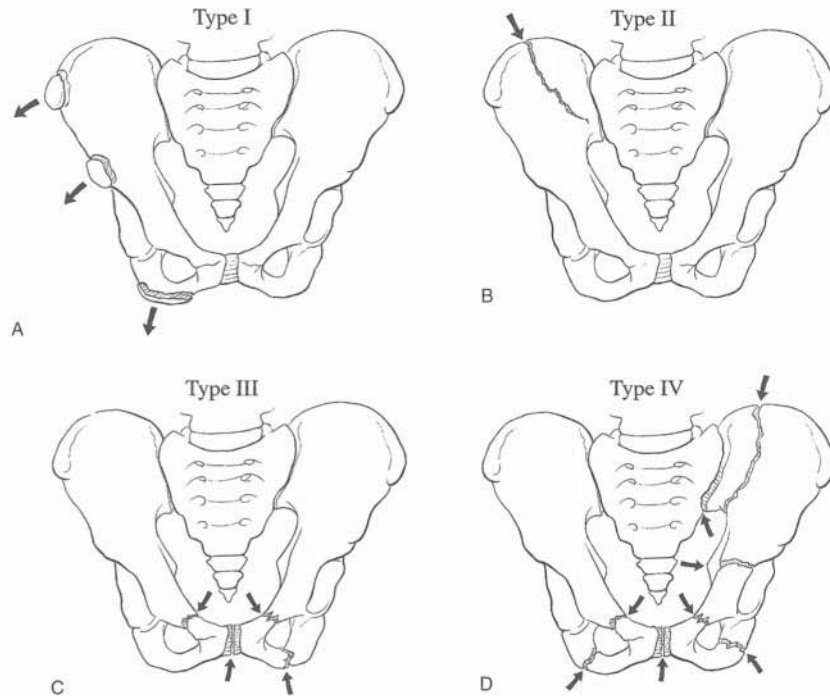


FIGURE 42-7 Torode and Zieg's classification of pelvic fractures. A, Type I: Avulsion fractures. B, Type II: Iliac wing fractures. C, Type III: Simple ring fractures. D, Type IV: Ring disruption fractures.

fractures; type II, iliac wing fractures; type III, simple pelvic ring fractures; and type IV, ring disruption fractures that are unstable (Fig. 42-7).⁴⁰ This classification scheme correlates well with fracture outcome and the type of treatment required. Type I injuries were treated symptomatically without admission to the hospital, type II and III injuries required admission to the hospital primarily for observation of associated injuries, and type IV injuries required more aggressive management, including operative intervention, and had a higher complication rate.

Acetabular fractures in adults are best classified according to the original descriptions by Letournel.¹³⁻¹⁵ This classification scheme is based on five primary simple fracture patterns and five associated fracture types, which in turn are based on the simple fracture patterns.

Acetabular fractures in children are best classified into four types:⁴²

- Type I: Small fragment fractures that occur with dislocation of the hip
- Type II: Linear fractures that result in one or more large, stable fragments
- Type III: Linear fractures that result in hip instability
- Type IV: Fractures that are secondary to central dislocations of the hip

Mechanism of Injury. Motor vehicle accidents account for 75 to 90 percent of all pelvic fractures in children.^{30,32,33,40} Differing from adults who sustain pelvic fractures, in which case the patient is typically the occupant of the vehicle, the child with a pelvic fracture is most often a pedestrian who has been struck by a motor vehicle; this mechanism of injury accounts for up to 75 percent of pelvic fractures in children.⁴⁰ Many of these children have not only been struck but also directly run over by the vehicle. Quinby described 20 children with pelvic fractures, 19 of whom were pedestrians struck by a vehicle; eight of those were also directly run

over.³⁰ Other causes of pelvic fractures in children include falls from a height (8 to 10 percent), bicycle or motorcycle injuries (5 to 8 percent), and sporting injuries (3 to 5 percent).^{33,40}

Avulsion injuries are produced from milder trauma than pelvic ring fractures. The majority are from participation in sports when an acute powerful muscle contraction results in the avulsion injury. The most common sports in which injuries occur are football, soccer, and sprinting.

Associated Injuries. The high energy that produces pelvic fractures commonly results in visceral and vascular injuries, which may be fatal. The mortality associated with pelvic fractures in children is reported to be between 2 and 11 percent.^{1,33,40} The probability of associated injuries is highest (60 percent) when multiple fractures of the pelvic ring are present, followed by iliac or sacral fractures (15 percent) and finally isolated pubic fractures (1 percent). Similarly, resuscitation requirements are greater in patients with unstable pelvic fractures than in those with stable fractures. In a study of all pelvic fractures presenting to the Hospital for Sick Children in Toronto between 1971 and 1981, in which 141 patients met the inclusion criteria, Torode and Zieg reported that 27 percent of patients required blood transfusion, with the majority of patients having the more severe type III or IV pelvic fracture.⁴⁰

The most common associated injuries involve the genitourinary system, other intra-abdominal organs, the neurologic system, and the musculoskeletal system. Genitourinary injuries are generally seen in individuals who have sustained more severe pelvic injuries, with a reported incidence of 10 to 20 percent.^{1,3,24,30,35,40} Bladder rupture or laceration and urethral injury are the most common genitourinary injuries, occurring in approximately 5 percent of pelvic fractures in children. They are followed in frequency by perineal or vaginal laceration. Between 30 and 60 percent of patients

with pelvic fractures present with macroscopic hematuria, thought to be the result of minor contusion or catheter trauma; most cases resolve with time.³¹⁻³³

Intra-abdominal injury occurs in up to 15 percent of pelvic fractures and includes contusions or laceration of the spleen, liver, or kidney, and very often mesenteric injuries or injuries to the large or small intestine.^{1,3,24,30,33,40} Modern approaches to treating intra-abdominal injuries in children have resulted in a decline in the rate of laparotomies performed for the assessment and management of these injuries.^{3,40}

Neurologic injury is the most common associated nonorthopaedic injury in children with a pelvic fracture, with a reported incidence of up to 50 percent.⁴⁰ Concussion is the most common neurologic injury (33 percent), followed by skull fracture (16 percent), nerve avulsions (5 percent), and brain death (4 percent).⁴⁰

Associated musculoskeletal injuries occur in up to 50 percent of cases, with a higher incidence in patients with unstable pelvic fractures.⁴⁰ The most common fractures involve the femur (25 percent), skull (15 percent), upper extremity (15 percent), and the tibia/fibula (15 percent).^{33,40}

Associated injuries related to the vascular system are most often due to venous bleeding leading to retroperitoneal hematoma, which occurs in up to 46 percent of patients.³³ In one series of patients with retroperitoneal hematomas 10 percent of patients were in hypovolemic shock at the time of presentation and required administration of whole blood or packed cells. Major arterial injuries, on the other hand, are relatively rare, occurring in approximately 3 percent of patients.

Diagnostic Features. A history of a child's being struck by a car while walking or running should alert the physician that pelvic trauma has occurred. Because these children often

have a head injury and are often confused or amnesic, a high suspicion for pelvic trauma and associated injury is mandatory in this setting. In addition, the initial pelvic radiograph is difficult to interpret and may not indicate the great amount of energy originally imparted to the pelvis. The details of the accident are important, including the speed of the traveling vehicle, the direction in which the child was struck, and whether the child was directly run over by the vehicle. The patient with an avulsion fracture will present with less pain and is usually an older child (12 to 16 years old) seen after an athletic event.

The physical examination by the orthopaedic surgeon should be thorough and organized, beginning with inspection of the entire body, including the perineal area, followed by palpation and assessment of pelvic stability, and finally a thorough assessment of the peripheral pulses and a neurologic examination.

The patient should be inspected for lacerations, abrasions, and evidence of tire marks on the skin, with the child "log-rolled" to allow a careful inspection of the entire body. With severe crush injuries, a significant soft tissue injury may occur in which the subcutaneous fat and skin are sheared off the underlying fascia, the so-called Morel-Lavallee lesion.^{9,23} This is most often seen in the obese child over the greater trochanteric region in acetabular fractures and in the buttock region in lateral compression-type injuries of the pelvis (Fig. 42-8). Deformity of the pelvis and the extremities should also be evaluated. The child's hips should be rotated to assess for asymmetry, especially in the setting of a lateral compression-type injury. Limb lengths are also assessed, especially in the vertically unstable pelvic fracture.

Palpation of the pelvis is done to assess bony tenderness, sacroiliac joint tenderness, and the stability of the pelvis in

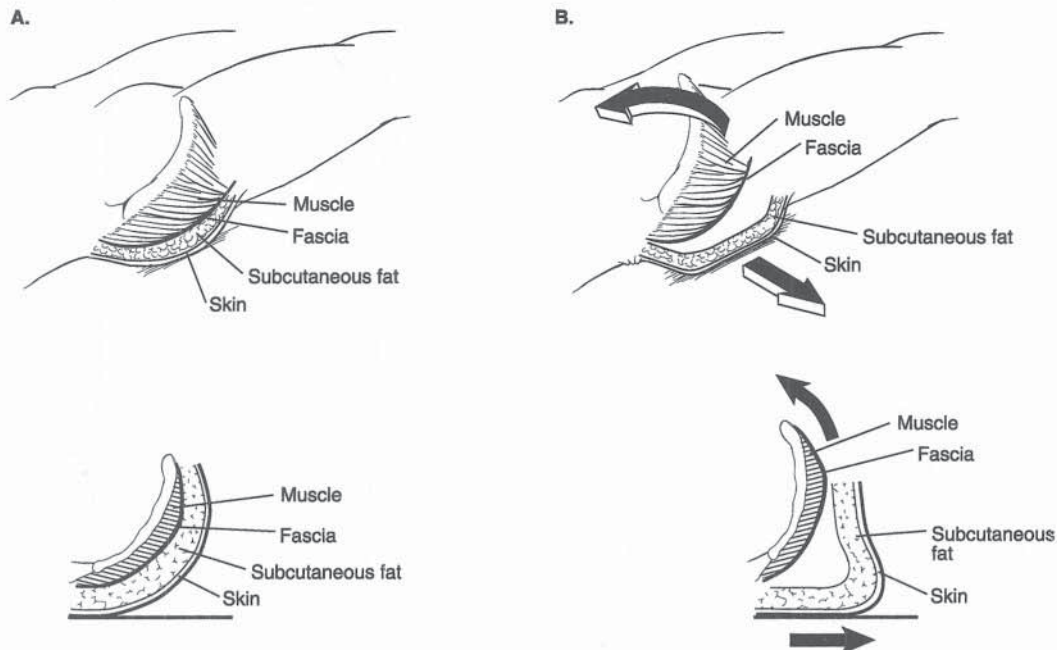


FIGURE 42-8 The Morel-Lavallee lesion, an injury in which the subcutaneous fat and skin are sheared off the deep fascia over the buttock. A, Relationship between the fascial layer and the subcutaneous fat. B, Mechanism of shearing of fat and fascial layers.

the anteroposterior, mediolateral, and vertical planes. Any pain on palpation of the bony prominences (as well as pain in the sacroiliac joints or sacrum) should lead to suspicion of a pelvic fracture. Pain with anteriorly directed pressure along the anterosuperior iliac spines or with medially directed pressure along the iliac wings should alert the clinician to an open book-type fracture or a lateral compression-type fracture, respectively.

Vertically unstable fractures are difficult to assess by palpation but may be implied by an oblique-appearing pelvis or a limb length discrepancy. Although arterial injuries are rare, the lower extremity pulses should be carefully palpated and further assessed by Doppler examination if a discrepancy between extremities is present. A careful neurologic examination is performed to assess the integrity of the lumbosacral plexus.

Careful inspection of the perineal area is essential. Blood at the urethral meatus or a scrotal hematoma may indicate a urethral injury. The vagina and rectum are inspected for tears. A rectal examination is done to assess rectal tone, to evaluate the position of the prostate in boys, to palpate rectal tears, to feel for fractures, and to attempt to elicit pain on palpation of the bony pelvis. A digital pelvic examination should be performed in girls. It is best done under sedation, if possible, especially in a young child, and is best done by a gynecologist when available.

Radiologic Examination. The initial AP pelvic radiograph should be obtained as soon as possible in the emergency room suite. A radiology technician should be available when the patient arrives in the emergency room and the pelvic radiograph should be obtained during the stabilization of the patient (unstable patients should never be transported to the radiology suite for radiographs of any type). This will allow assessment of the pelvis for severely unstable fracture

patterns which may be contributing to the patient's hemodynamic instability. Recognizing these fracture patterns will aid the trauma team in formulating treatment and further diagnostic plans, and will allow the orthopaedic team to close down the pelvic volume to tamponade persistent venous bleeding.

Other plain radiographs that should be obtained to assess pelvic fractures include inlet and outlet views.⁷ The inlet view is obtained with the patient supine and the x-ray beam aimed caudally 60 degrees, and therefore at right angles to the pelvic brim, allowing visualization of the iliopectineal line, the pubic rami, the sacroiliac joints, and the alae and body of the sacrum (Fig. 42-9). The inlet view is best used to assess the anterior and posterior displacement of the pelvic ring, especially posterior displacement of the sacroiliac joint, sacrum, or iliac wing; internal rotation deformities of the pelvis; and sacral impaction injuries. The outlet view is obtained by directing the x-ray beam 45 degrees in a cephalad direction (Fig. 42-10) and helps define superior-to-inferior displacement of the pelvic ring, superior rotation of the hemipelvis, and the sacral foramina, which are best seen in this view.

Plain radiographs used to assess acetabular fractures include the oblique views described by Judet (Fig. 42-11).¹² The iliac oblique view shows the posterior column and anterior acetabular wall and the iliac wing. The obturator oblique view shows the anterior column and posterior wall of the acetabulum and the obturator foramen (Fig. 42-12). Careful inspection of the two oblique views and the AP pelvic view should allow classification of the acetabular wall fracture according to Letournel.¹⁴ Computed tomography (CT) is used to assess acetabular fractures only after the fracture has been carefully evaluated and classified based on the plain radiographs. CT is performed to identify loose fragments

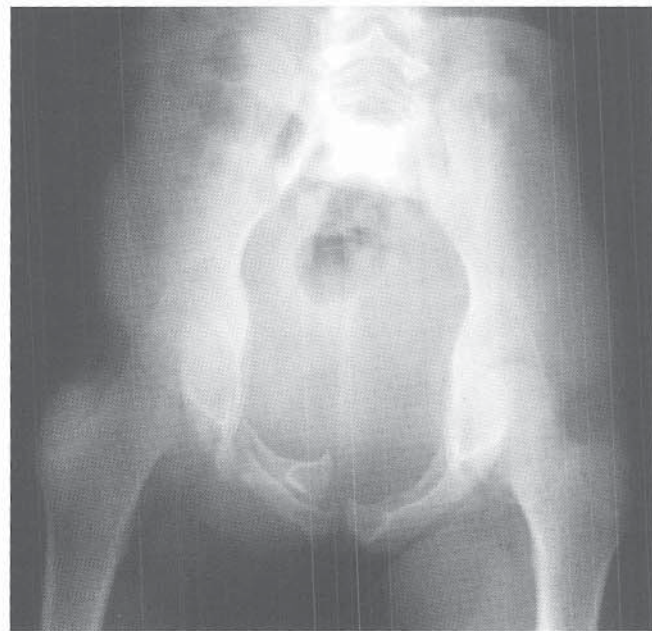
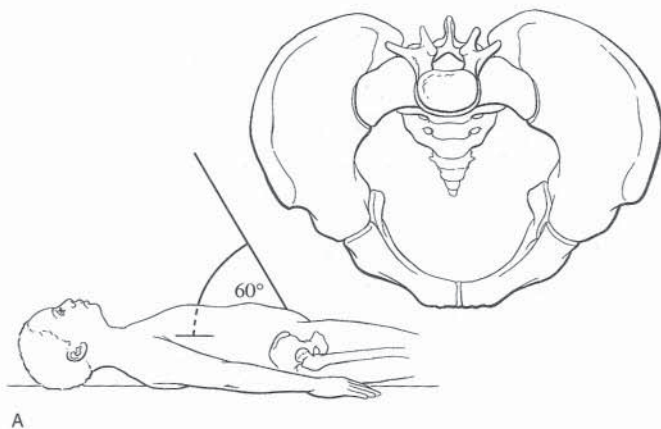


FIGURE 42-9 A, For an inlet view, the patient is supine and the x-ray beam is directed 60 degrees caudally. B, Radiographic inlet view showing disruption of the anterior ring with fracture displacement.

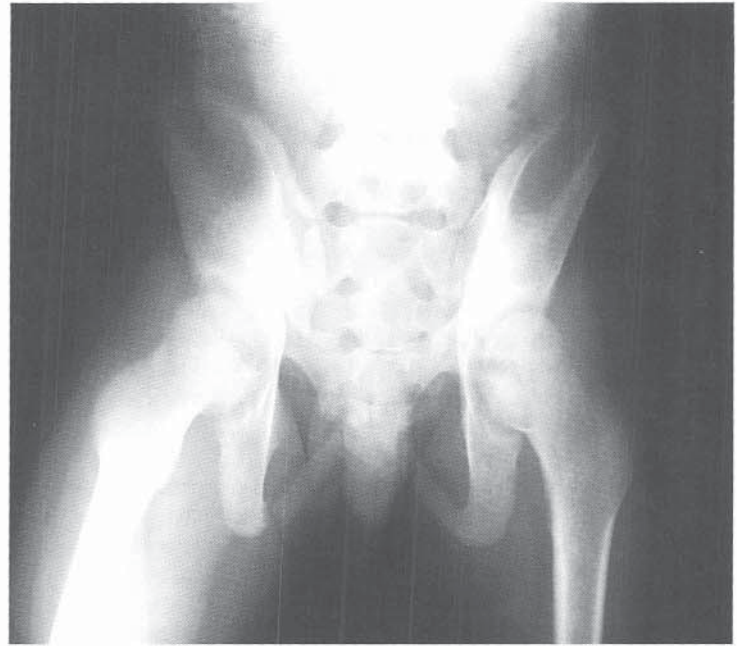
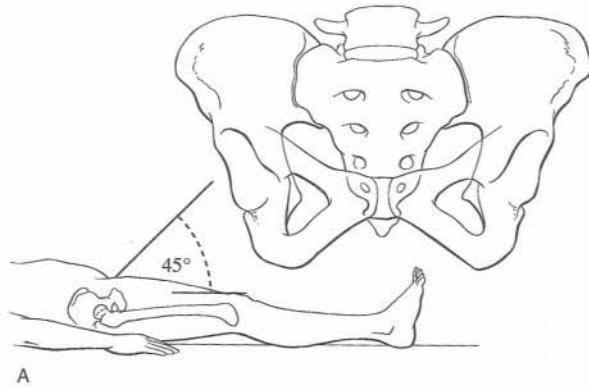


FIGURE 42-10 A, For an outlet view, the patient is supine and the x-ray beam is directed 45 degrees cranially. B, Radiographic outlet view. Note the right inferior ramus fracture.

and incongruities of the joint and to determine the size and displacement of the wall fracture.

Pelvic fractures in general, and particularly pelvic fractures in children, can be difficult to define, especially the posterior anatomy (including the sacrum and the sacroiliac joints). CT should be used in this setting to diagnose a pelvic fracture or to fully define an injury suspected on the plain radiographs. A thin-section CT study (2 or 3 mm) with three-dimensional reconstruction can be performed and has

several advantages over plain radiography: the images can be viewed in a multitude of planes, bowel gas and feces do not obscure the posterior pelvic ring, and soft tissue and fluid assessment can be performed on the same study without exposure to additional radiation.¹⁶ Magnetic resonance imaging (MRI) has no significant role to play in evaluating the pediatric pelvic or acetabular fracture.

Treatment of Pelvic Fractures. Treatment will be discussed based on the classification of Torode and Zieg:⁴⁰

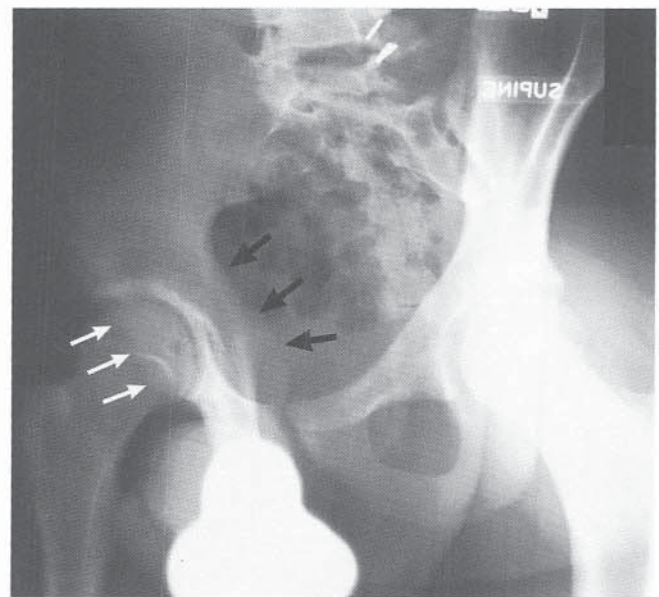
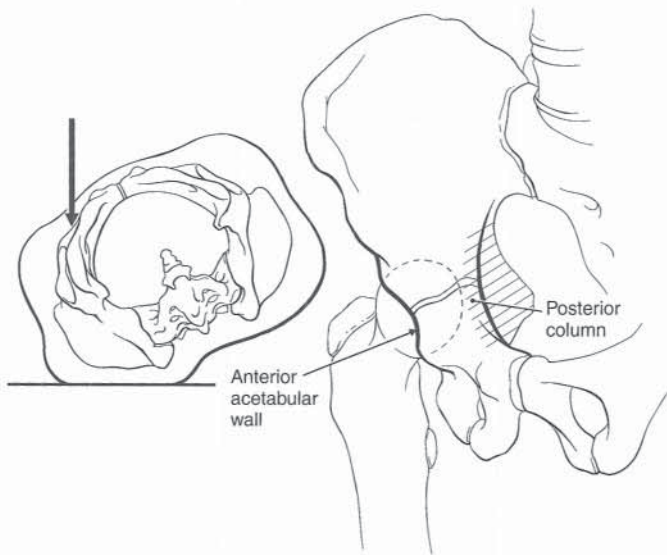


FIGURE 42-11 A, The iliac oblique view is imaged with the x-ray beam directed 45 degrees toward the side of the pelvis to be examined. B, Radiographic right iliac oblique view showing the anterior wall (white arrows) and posterior column (black arrows).

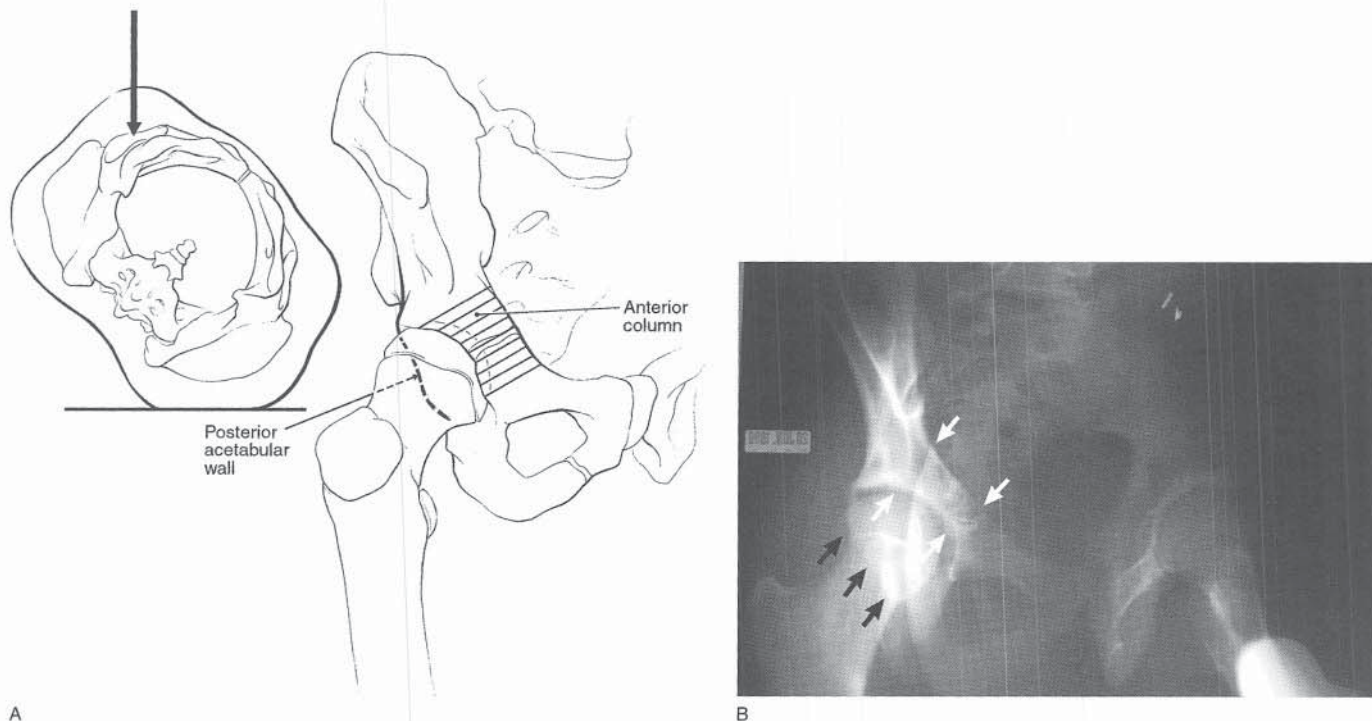


FIGURE 42-12 A, The obturator oblique view is imaged with the x-ray beam directed 45 degrees away from the side of the pelvis to be examined. B, Radiographic right obturator oblique view showing the anterior column (white arrows) and posterior wall (black arrows).

- Type I: Avulsion fractures
- Type II: Iliac wing fractures
- Type III: Simple pelvic ring fractures
- Type IV: Pelvic ring disruption fractures

TYPE I: AVULSION FRACTURES. The most common avulsion injuries occur in the pelvis at the ischial tuberosity (the attachment of the hamstrings and hip adductors), the anterosuperior iliac spine (attachment of the sartorius muscle), the anteroinferior iliac spine (attachment of the direct head of the rectus), and, less often, at the iliac crest and the lesser trochanter of the femur (attachment of the iliopsoas tendon) (Fig. 42-13).^{8,37} Athletic injuries account for the majority of these fractures, boys are more often affected than girls, and the average age at injury is between 12 and 14 years, just prior to closure of the apophyses.⁸ The powerful contraction of the attached muscle results in avulsion of bone. An acute injury is most common; however, chronic repetitive trauma can also result in avulsion injuries.^{37,43}

The typical history is that of an adolescent athlete who performs a sudden strenuous activity such as kicking a ball or making a quick turn and feels a sudden, sharp pain. The pain is localized to the area of injury and results in limitation of motion, most often of the hip joint. The pain is aggravated by passive motion of the hip that places tension on the attached muscle: flexion and abduction of the hip, in ischial tuberosity avulsion injuries; extension of the hip, in anterosuperior and anteroinferior spine injuries and lesser trochanter avulsions. Active contraction of the muscle that produced the avulsion is quite painful. Localized tenderness of the superficial structures such as the anterosuperior iliac spine and the ischial tuberosity will help establish the diagnosis. Radiographically, the avulsed fragment is displaced from its normal anatomic location (Fig. 42-14). This is most easily

seen in lesser trochanteric injuries and ischial tuberosity avulsions and is more difficult to see radiographically in anterior superior and inferior iliac spine injuries because of the mild displacement that occurs. The anteroinferior iliac spine fracture avulsion can only be seen in an oblique view.³⁷ Comparison views of the contralateral side are helpful in

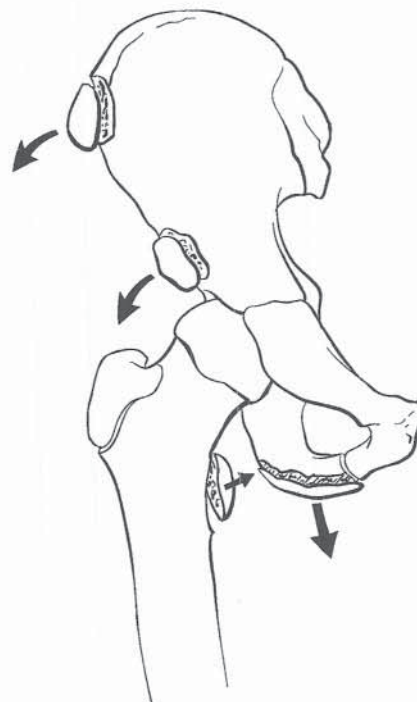


FIGURE 42-13 Torode and Zieg's type I injury—pelvic avulsion fracture.

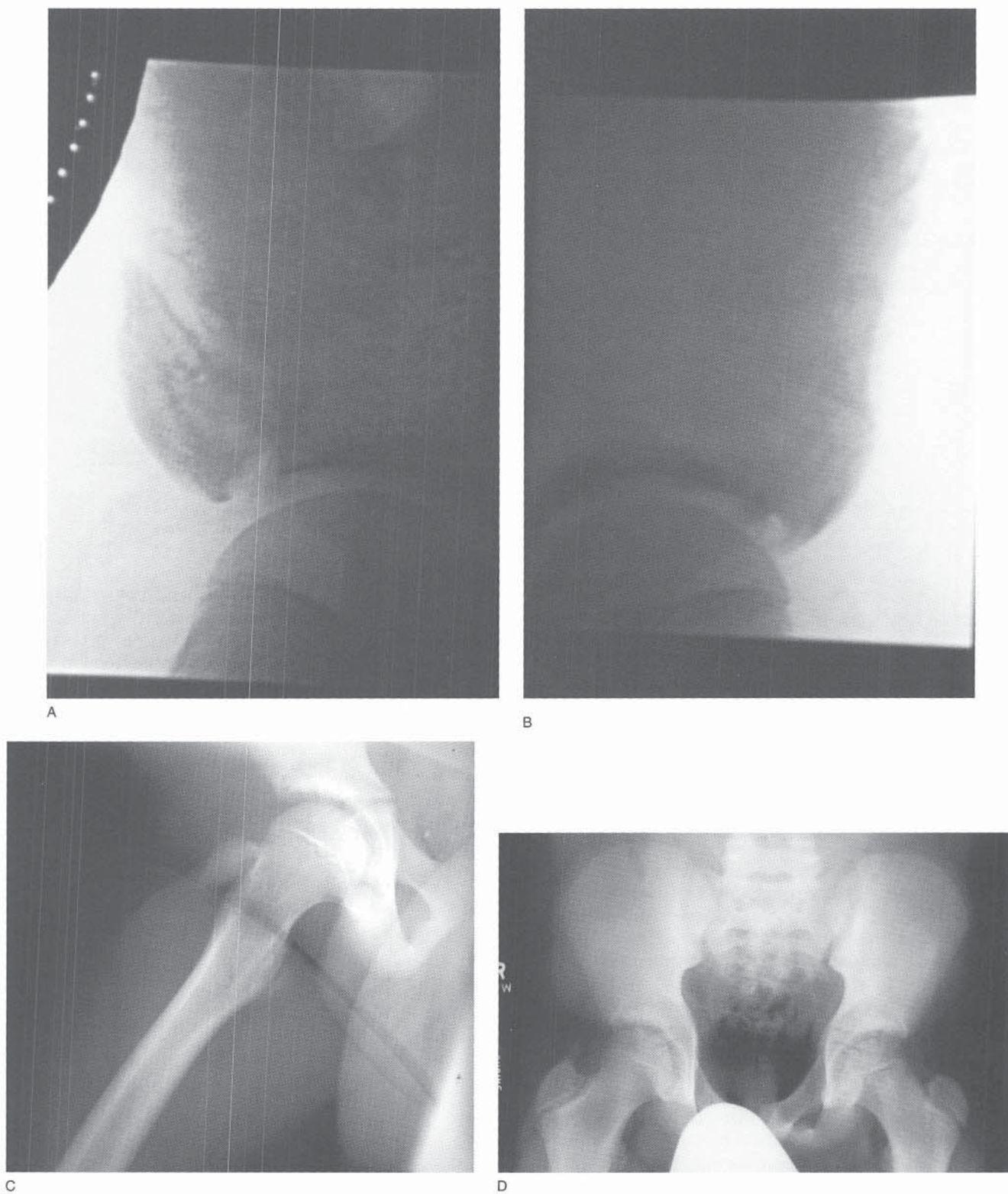


FIGURE 42-14 Avulsion fracture of the pelvis and proximal femur. A, Lateral view radiograph of an avulsion of the anteroinferior iliac spine. B, The opposite, normal side. C, A greater trochanter avulsion fracture. D, Four months after injury, the radiographs demonstrate complete healing in an anatomic position.

confirming the diagnosis and avoiding further unnecessary imaging studies.

Conservative treatment of avulsion injuries of the pelvis is usually successful and consists of symptomatic treatment in which the patient is placed on crutches to allow the involved extremity to be rested.^{20,37,43} Admission to the hospital may be necessary until the patient is able to ambulate safely on crutches, with the length of stay averaging up to 5 days.³⁷ The period of treatment is 2 to 3 weeks, until symptoms resolve and radiographic evidence of healing is present. Avulsion injuries of the ischial tuberosity are most prone to nonunion, with some groups reporting a 68 percent incidence of nonunion.⁴² These nonunions may result in pain with sitting and on excessive physical activity; however, most patients have very few symptoms despite the presence of a nonunion. We perform open reduction and internal fixation only for painful nonunions of the ischial tuberosity. Of 14 cases of nonunion of the ischial tuberosity treated by surgical intervention, ten were treated with excision and three with early reattachment, with one of the three patients having a continued nonunion.⁴²

Most studies report return to full function following avulsion injuries around the pelvis.^{6,20} The 20 patients described by Fernbach and Wilkinson returned to their previous level of athletic competition following conservative treatment of an avulsion injury of the pelvis.⁸ The worst results occur in patients with avulsion injuries of the ischial tuberosity. Sundar and Carty described three patients with acute avulsion fractures, all of whom had symptoms at follow-up and difficulty resuming sporting activities, while five of nine patients with a chronic ischial avulsion injury had reduced sporting ability at follow-up.³⁷

To avoid reinjury, the avulsion injury should heal fully before the patient returns to full activities.²⁰ A conditioning and strength program is usually necessary to restore the strength of the affected muscle to normal before the child resumes competitive athletics.

TYPE II: ILIAC WING FRACTURES. These fractures represent approximately 15 percent of all pelvic fractures in children, a slightly higher percentage than in adults.^{32,40} The mechanism is usually an external force exerted on the iliac wing that results in a disruption of the iliac apophysis or a lateral compression-type wing fracture (Fig. 42–15). Patients are most often pedestrians struck by a motor vehicle, although direct trauma from other objects may result in this injury. Associated abdominal injuries are less common than the type III and IV fractures, with the incidence of genitourinary injuries being 6 percent and the need for a laparotomy 11 percent.⁴⁰ However, these injuries can lead to significant blood loss, and blood transfusions have been necessary in up to 17 percent of patients.⁴⁰ Fracture displacement is most often lateral and is usually mild, owing to the vast muscle attachments.

Treatment usually consists of admission to the hospital for observation of the musculoskeletal injuries, hemodynamic status, and associated intra-abdominal injuries. An ileus may develop after an iliac wing fracture and must be carefully evaluated by a general surgeon, with CT of the abdomen performed if necessary. Treatment of the ileus usually consists of bowel rest and/or placement of a nasogastric tube.

Although pain initially limits the patient's activities fol-

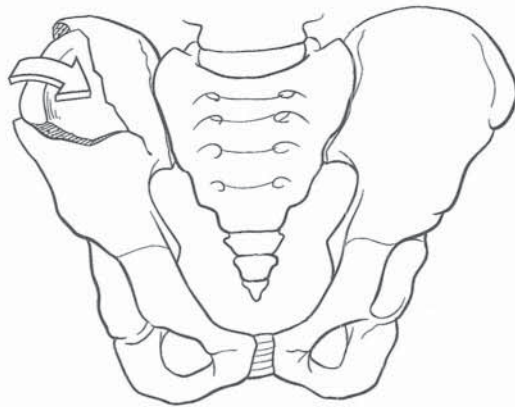
lowing the injury, most patients quickly regain their mobility. Fracture healing is usually rapid and functional limitations are quite rare with this type of injury, although some may have delayed ossification of the iliac apophysis or a prominent bump from ossification of the injured area.⁴⁰

TYPE III: SIMPLE PELVIC RING FRACTURES. This injury includes fractures of two ipsilateral pubic rami, disruptions of the pubic symphysis, fractures or separations of the sacroiliac joints, or displaced fractures in which no clinical instability can be detected (Fig. 42–16). This is the most common fracture type, accounting for up to 55 percent of all pelvic fractures in children.^{3,30,32,40} Unlike in adults, in whom a pelvic fracture in one part of the ring must be associated with a fracture in another part, children can have a fracture or fractures in a single aspect of the pelvic ring without an associated fracture. Presumably this is due to the elasticity of the sacroiliac joints and pubic symphysis, which allows some strain to occur without radiographic evidence of an injury. A single fracture with significant displacement but without posterior ring injury should be classified as a type III fracture, since the overall stability of the ring is intact.

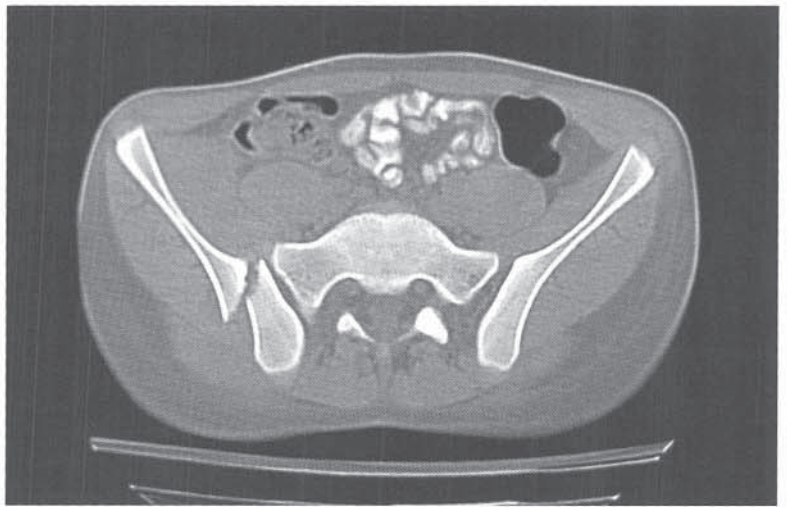
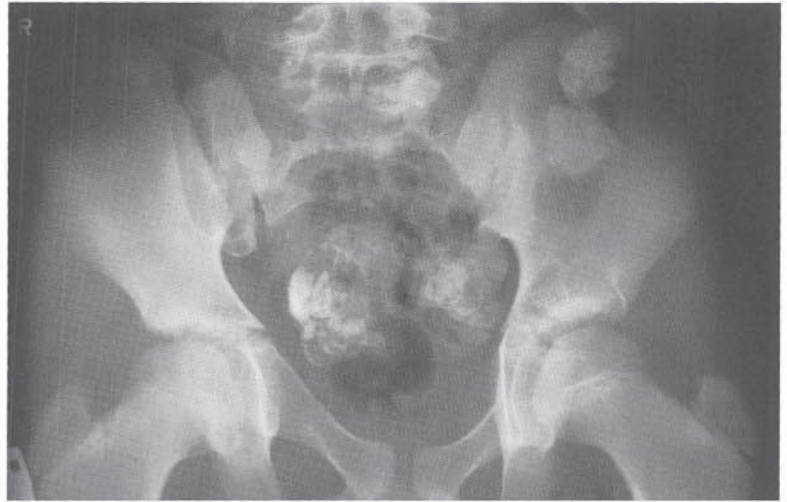Other less common fractures classified as type III fractures include fractures of the sacrum and coccyx. Fractures of the sacrum are relatively rare, with a reported incidence of 1 to 12 percent.^{6,25,32} These fractures are best viewed on the AP or outlet view of the pelvis and are important to recognize, because they can result in injury to the sacral nerves. Most sacral fractures are undisplaced, transverse fractures through a sacral foramen and rarely require operative intervention. Coccygeal fractures are difficult to diagnose from radiographs because of the considerable normal anatomic variability.²⁹ The diagnosis, therefore, is most often made clinically when tenderness is noted over the coccyx. Treatment is conservative with symptomatic pain management, including sitting on a cushioned donut until symptoms resolve.

Type III fractures are associated with a higher incidence of other musculoskeletal injuries, than type I or II injuries, including musculoskeletal (50 percent), genitourinary (26 percent), and neurologic injuries (57 percent). Careful assessment of these potential associated injuries is important.

Patients with these simple ring fractures do very well with conservative treatment consisting of a short period of bed rest followed by progressive weightbearing until the patient is comfortable and independent on crutches. Fracture healing is rapid in the undisplaced fracture; however, it may be delayed in the displaced fracture. Torode and Zieg reported that two patients (3 percent) of 70 with type III fractures had delayed union of displaced pubic rami fractures, which healed approximately 1 year after injury.⁴⁰ Pubic symphysis disruptions may occur as an isolated injury or, more often, with injury to the anterior capsule of the sacroiliac joint and/or partial separation of the adjacent ilium. However, these injuries are stable because of the posterior structures (joint capsule, periosteum, and ligamentous structures) of the sacroiliac joint. Isolated pubic symphysis disruptions without significant injuries to the posterior ring occur at the bone-cartilage level, allowing healing to be complete without residual instability.⁴⁰ Significant displacement of the pubic symphysis with posterior ring injury may require operative intervention (see subsequent discussion under Treatment Techniques).

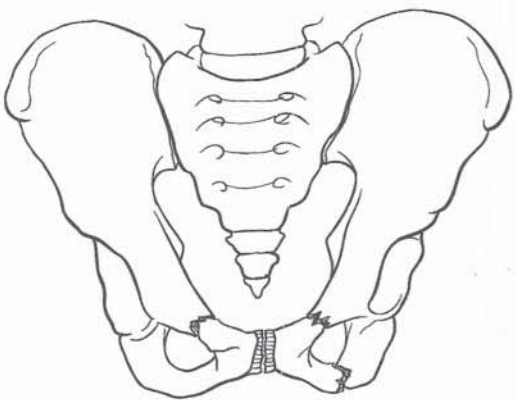


A

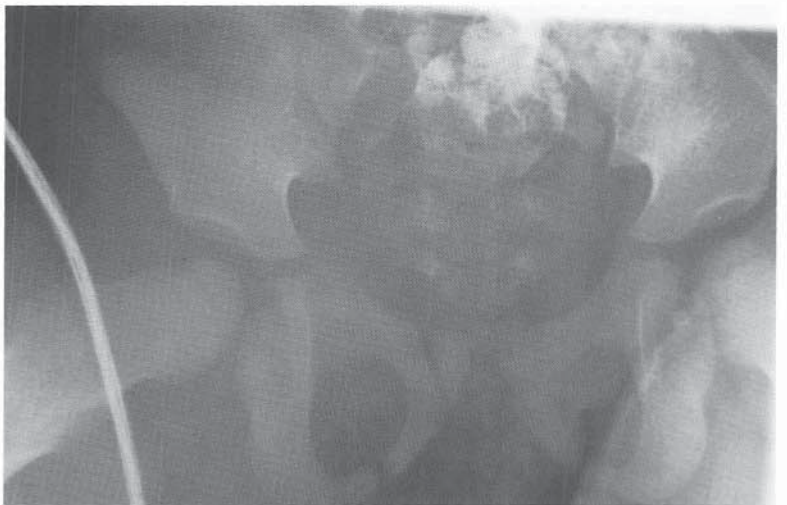


B

FIGURE 42-15 A, Type II pelvic injury in the Torode and Zieg classification. B, Radiograph and CT scan of a type II or iliac wing fracture.



A



B

FIGURE 42-16 A, Type III pelvic injury in the Torode and Zieg classification. B, Radiograph of a type III or simple pelvic ring fracture.

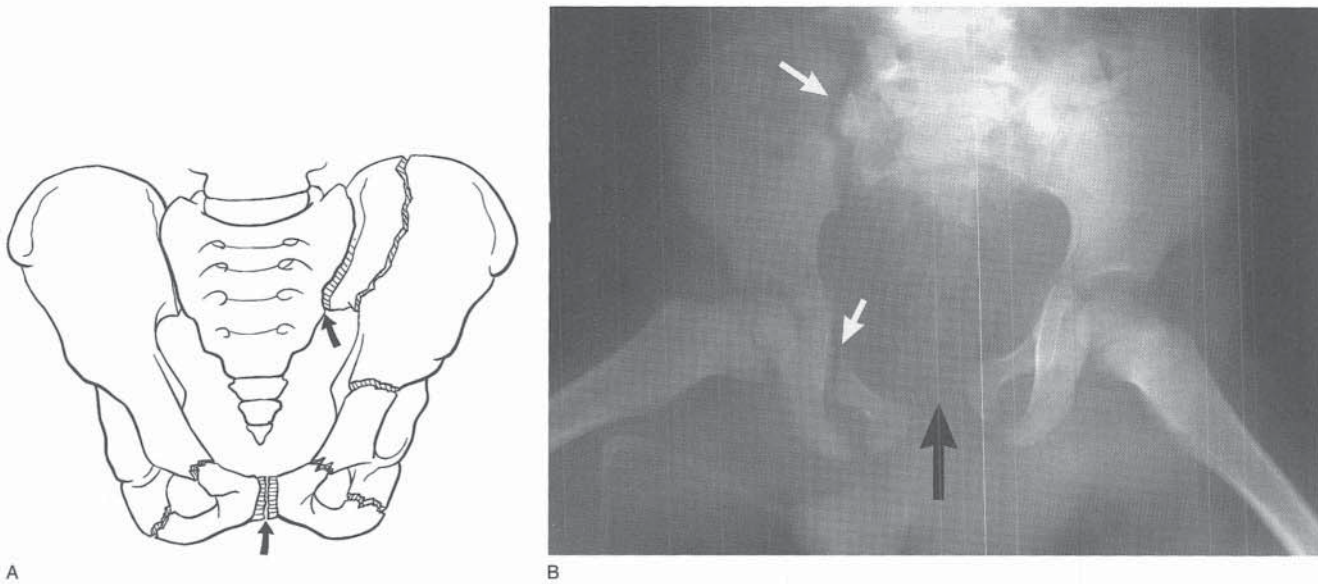


FIGURE 42-17 A, Type IV pelvic injury in the Torode and Zieg classification. B, Radiographs demonstrating pubic symphysis diastasis, right superior ramus fracture, and right sacroiliac joint widening.

TYPE IV: PELVIC RING DISRUPTION FRACTURES. Pelvic ring disruption fractures include bilateral pubic rami fractures, or so-called straddle fractures; double ring fractures or disruptions (e.g., pubic rami fracture and disruption of the sacroiliac joint); and fractures of the anterior structures and acetabular portion of the pelvic ring (acetabular fractures will be discussed in the subsequent section) (Fig. 42-17).

Type IV fractures have the highest incidence of associated genitourinary (38 percent), musculoskeletal (56 percent), and neurologic (56 percent) injuries, and also result in significant intra-abdominal injuries requiring laparotomy (40 percent). In addition, the mortality rate has been reported to be as high as 13 percent.⁴⁰

Straddle fractures consist of bilateral fractures of both the superior and inferior rami, or a symphysis pubis separation along with ipsilateral superior and inferior rami fractures (Fig. 42-18). A straddle fracture usually occurs following a

fall while straddling an object or following a lateral compression-type injury. Associated injuries to the genitourinary system are fairly common; the reported incidence is as high as 20 percent.^{6,25}

Treatment consists of bed rest with the hips slightly flexed, to relax the abdominal muscles, which tend to displace the fracture fragments. The hips should also be in mild abduction to prevent adductor muscle tension. The duration of bed rest depends on the amount of displacement and the amount of pain present, with most patients needing 2 to 3 weeks.⁴² Weightbearing is begun as tolerated by the patient. Fracture union may be delayed up to a few years if fracture displacement is present.¹⁹

The second group of type IV fractures includes the vertically and/or rotationally unstable pelvic fracture, which accounts for approximately 20 to 30 percent of all pelvic fractures in children.^{32,33} A complete description of the analogous

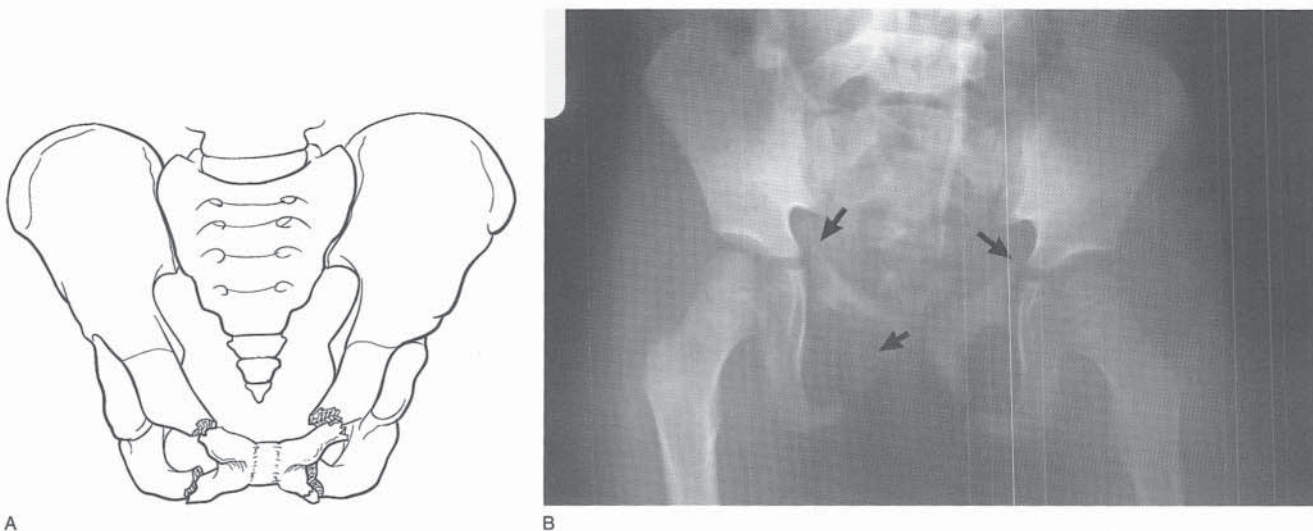


FIGURE 42-18 A, Straddle fracture. B, Bilateral superior and inferior rami fractures (arrows) in a straddle fracture.

injury in adults has been provided and the injuries classified by Young and Burgess⁴⁴ and Pennal and Tile.^{26,38} Because these injuries are rare, specific treatment protocols are not as well-defined in children. Historically, treatment has consisted of conservative management using pelvic slings and skeletal traction. However, recent developments in treating adult pelvic fractures have been applied to pediatric fractures, with promising results.

The following treatment guidelines are based on the Young and Burgess classification. In general, children less than 10 years old do well with nonoperative treatment. Lateral compression fractures in which the posterior structures and bone are intact (types A1 to A3) and anterior compression fractures without posterior sacroiliac joint disruption, or posterior ring or displaced sacral fractures (types B1 and B2), usually do not need operative intervention. The only exception occurs when significant hemodynamic instability is present, requiring emergency application of a pelvic external fixator to decrease pelvic volume and tamponade venous bleeding. Anterior compression injuries with displaced posterior pelvic fractures or sacroiliac joint disruptions (type B3), and vertically and rotationally unstable fractures (type C), require operative intervention, which usually consists of open reduction and internal fixation.

The lateral compression-type injury (Fig. 42-19) that results in an anterior pelvic ring fracture and partial sacroiliac injury in which the anterior ligaments are injured with intact posterior ligaments results in a rotationally unstable but vertically stable pelvis. Therefore, treatment is bed rest followed by advancement of crutchwalking, nonweightbearing on the affected side for 6 to 8 weeks, then weightbearing as tolerated by the patient. In the patient with a displaced lateral compression fracture of the A2 or A3 type, open reduction and internal fixation can be performed.

Anterior compression-type injuries (Fig. 42-20) in young children less than 10 years old usually heal without difficulty and respond to conservative, symptomatic treatment as outlined above, which may include immobilization in a hip spica cast. In the older child with a symphysis pubic diastasis of less than 3 cm, conservative treatment is appropriate; however, if the diastasis is greater than 3 cm, open reduction of the diastasis should be considered. In those fractures in

which there is complete disruption of the posterior structures with complete (vertical and rotational) instability, a closed reduction followed by percutaneous screw fixation of the sacroiliac joint, with or without open reduction and internal fixation of the symphysis pubis, should be performed.

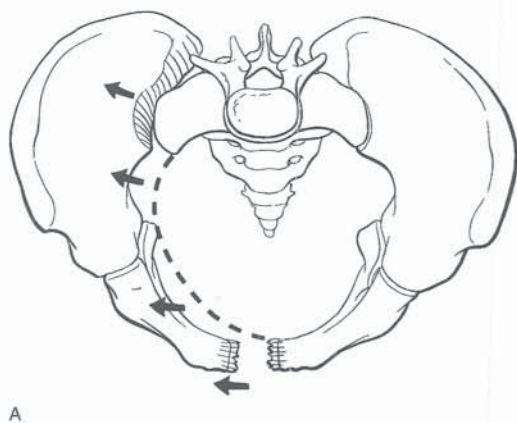
In the Malgaigne-type injury (Fig. 42-21) there is complete disruption of the entire hemipelvis with vertical shear injury and vertical displacement. The patient presents with a limb length discrepancy with a vertically and rotationally unstable fracture. In the young child this can often be treated with skin or skeletal traction to reduce the vertical displacement and to stabilize this highly unstable fracture. The traction is usually needed for 2 to 3 weeks, until the fracture has stabilized sufficiently to allow hip spica application or has fully healed.²⁴ In the child older than 10 years, traction to reduce the pelvis is followed by percutaneous fixation of the sacroiliac joint. The anterior pelvis is stabilized with either external or internal fixation.

Treatment Techniques

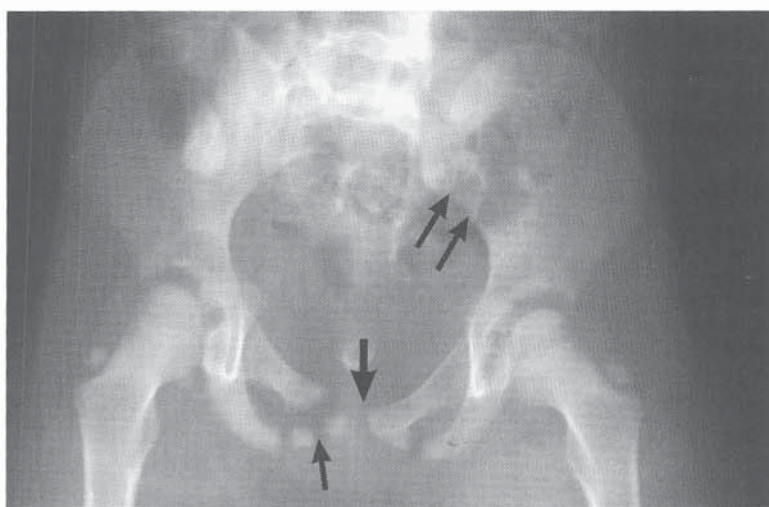
EXTERNAL FIXATION. There are two main indications for use of an external fixator. The first is the presence of significant hemodynamic instability that is refractory to blood and fluid resuscitation. In this setting the external fixator is placed to reduce the volume of the pelvis in an attempt to tamponade the venous bleeding. We recommend applying the external fixator in the operating room under sterile conditions. If the hemodynamic instability is very severe in the emergency department, as a temporary measure a bed sheet is wrapped around the patient's pelvis and tied snugly to reduce the pelvis. The sheet is removed in the operating room just before the external fixator is applied.

The second indication for use of an external fixator is an anterior pelvic ring displacement associated with posterior ring displacement in a rotationally and vertically unstable fracture pattern. In this setting, external fixation should be used in combination with internal fixation of the posterior injury.

In the emergency situation in which hemodynamic instability is present, an external fixator can usually be applied quickly to the anterior pelvis (Fig. 42-22). When emergency application is required, a single pin or screw is placed on each side of the pelvis, then the external fixator bars are

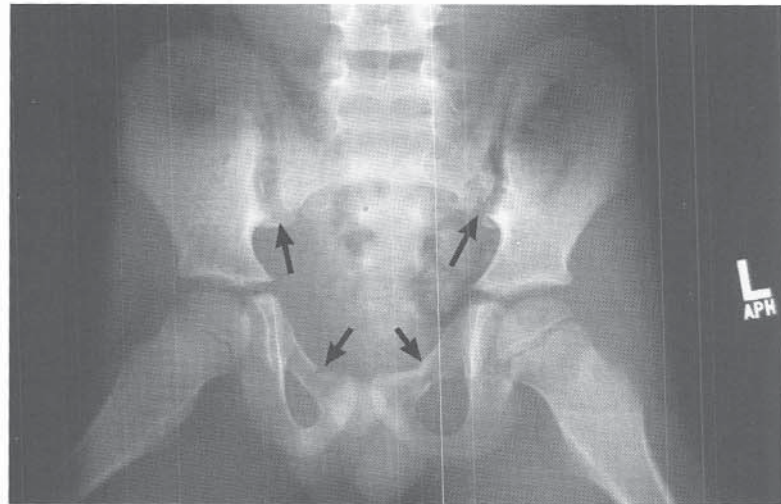


A

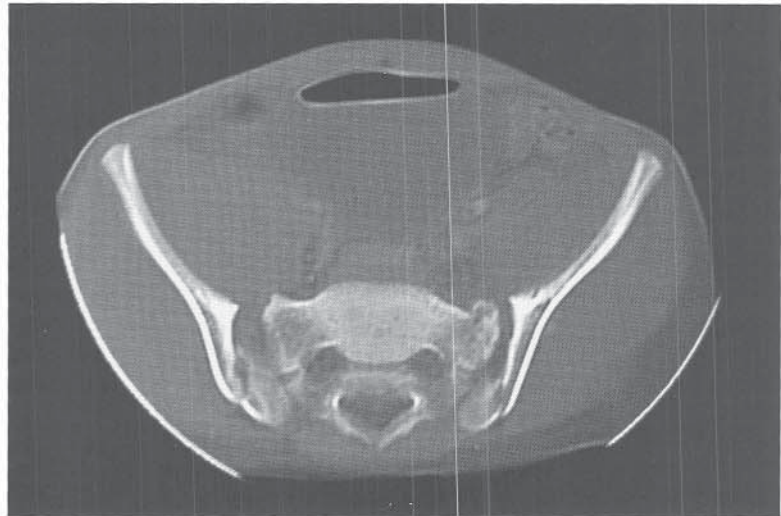


B

FIGURE 42-19 A, Lateral compression fracture. B, Radiograph of a lateral compression-type injury with an anterior pelvic ring fracture and partial sacroiliac joint injury.



A



B

FIGURE 42–20 A, Radiograph of an anterior compression injury. B, CT scan of an anterior compression-type injury with partial disruption of the posterior ring that was successfully treated conservatively.

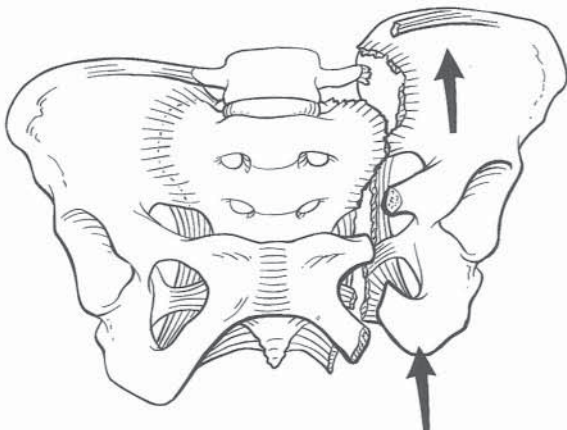


FIGURE 42–21 A Malgaigne-type fracture with vertical displacement.

assembled and the pelvic displacement is reduced. The choice of pin size depends on the age and size of the child, with standard adult-size 5.0-mm Schanz screws used in children older than 8 and the smaller external fixator pins used in younger children.

Since the iliac wing is directed obliquely from lateral to medial, it is important to direct the drill bit and pins from lateral to medial at an approximately 30-degree angle from a vertical line to avoid perforating the medial or lateral cortex. A small incision is made over the anterosuperior iliac spine in a transverse direction to allow the pins to slide along the incision during the reduction maneuver. This is followed by predrilling with a 3.2-mm drill bit (if the 5.0-mm Schanz drill bits are used). The pin is then advanced by hand, using a T-handled chuck to allow the pin to advance between the inner and outer cortical walls of the pelvis. The threaded aspect of the pin should be completely buried in the thickened anterior aspect of the iliac wing. If a second pin is used, it is placed approximately 1 to 2 cm away from the first pin to provide greater stability.

After the pins have been placed, the external fixator bars are loosely attached to the pins just prior to reduction. The surgeon must understand the pelvic displacement before

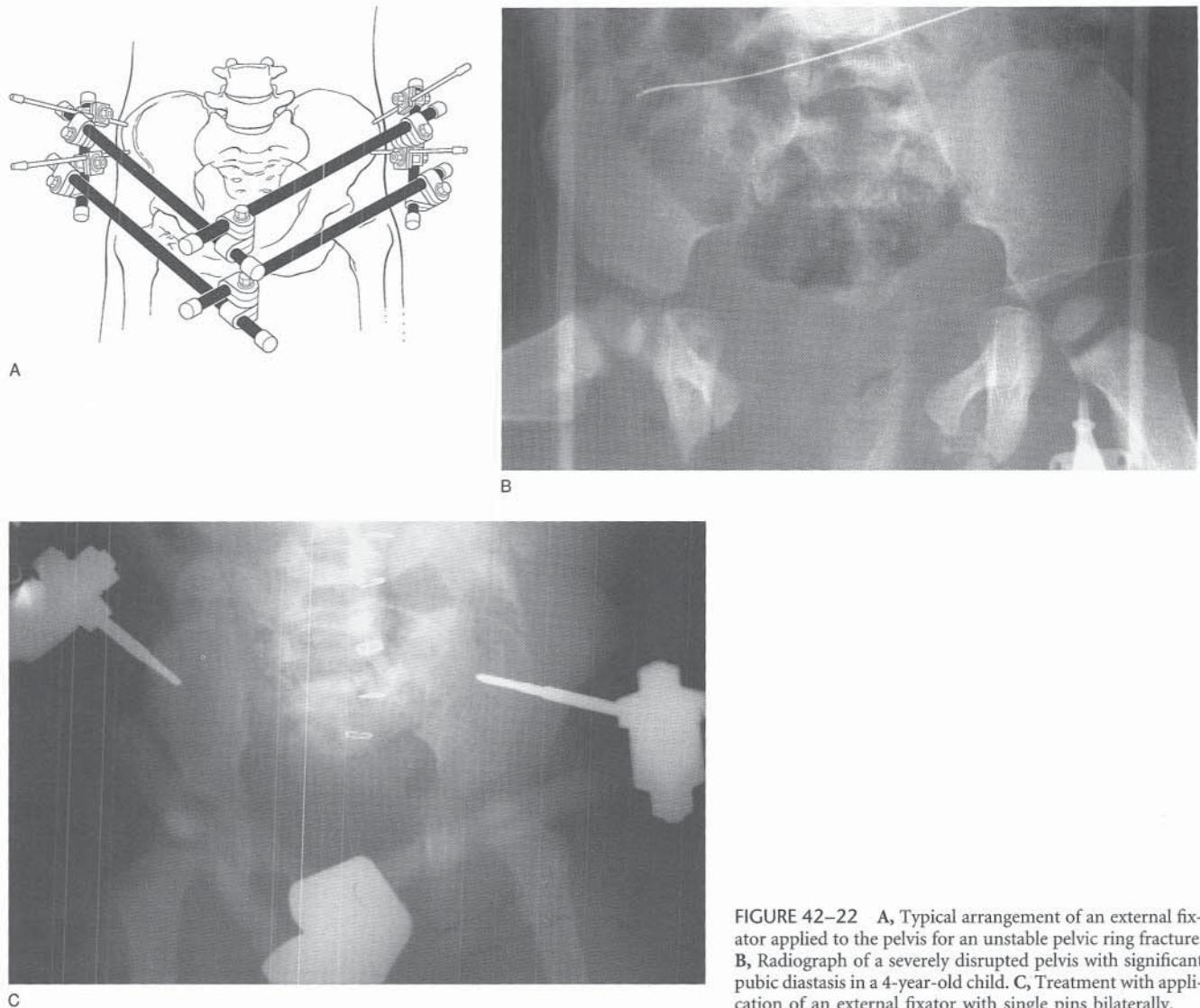


FIGURE 42-22 A, Typical arrangement of an external fixator applied to the pelvis for an unstable pelvic ring fracture. B, Radiograph of a severely disrupted pelvis with significant pubic diastasis in a 4-year-old child. C, Treatment with application of an external fixator with single pins bilaterally.

undertaking the reduction. With vertical displacement of the pelvis, axial traction on the appropriate extremity is required; with rotational deformity, the pelvis must be rotated to achieve reduction. Following reduction, the external fixator frame is tightened to stabilize the pelvis, and radiographs are obtained to confirm the reduction. The frame is adjusted to allow adequate room for the abdomen, and it should be positioned so that the patient can sit in a reclining chair.

OPEN REDUCTION AND INTERNAL FIXATION OF THE SYMPHYSIS PUBIS.

The indications for open reduction with internal fixation of the symphysis pubis are similar to those for external fixation of the pelvis: (1) fractures with more than 3 cm of symphyseal displacement, and (2) unstable, open book-type fractures with posterior ring disruption. This technique should not be used when hemodynamic instability is present, because external fixation can be done more rapidly without a soft tissue dissection, which may accentuate the blood loss and result in hemodynamic instability.

A Foley catheter should be placed to decompress the

bladder. A standard transverse Pfannenstiel incision is made approximately one fingerbreadth above the pubic tubercle (Fig. 42-23). The spermatic cord is identified and retracted out of the operative field. The rectus sheath is divided above the symphysis, and the fatty tissue anterior to the bladder is bluntly dissected off the anterior symphysis. The anterior rectus sheath has usually been avulsed from the pubis at the time of injury; however, if it remains intact, it should be incised transversely, leaving a small attachment so that the rectus sheath can be sutured back into place following fracture fixation. A sponge should be packed behind the symphysis to protect the bladder. Subperiosteal dissection is then carried out laterally until enough exposure is attained for plate fixation. We prefer dynamic compression or pelvic reconstruction plates (3.5 mm) when the child is large enough, and four-hole plates when possible, although two-hole plate fixation appears to be stable enough in children less than 12 years. In the very young child (less than 8 years old), two-hole semitubular or one-third tubular plates can be used effectively. Hohmann retractors are placed around

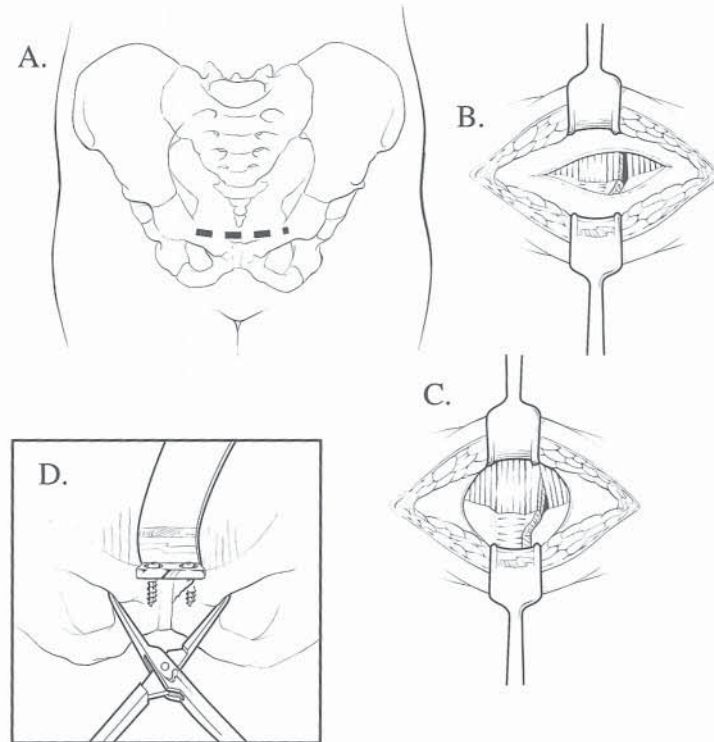


FIGURE 42-23 Surgical exposure for open reduction and internal fixation of a pubic symphysis diastasis. A, A Pfannenstiel incision is made just superior to the pubic symphysis. B and C, A transverse incision is made in the rectus sheath and subperiosteal dissection is carried out over the pubic tubercle. D, Internal fixation with a two-hole DC plate.

the symphysis, and reduction is best achieved by spanning the bone reduction forceps across the obturator foramina. Anatomic reduction should be achieved under direction visualization.

INTERNAL FIXATION OF THE SACROILIAC JOINT. Injuries of the sacroiliac joint, including dislocations and fracture-dislocations, can be approached through open exposure of the joint, either anteriorly or posteriorly,^{1a-4a} or can be treated by closed reduction followed by percutaneous fixation.³⁴⁻³⁶ The advantage of an open technique is that anatomic reduction can be better achieved when a significant fracture is associated with the sacroiliac joint disruption. This is rarely seen in children's pelvic injuries and is generally not necessary for appropriate treatment. We prefer to perform a closed reduction followed by percutaneous internal fixation under fluoroscopic guidance.^{34,35} A posterior open reduction is needed if the closed reduction is unsuccessful or there is a significantly displaced sacral fracture.

The posterior approach requires the patient to be placed prone on the operating table. A vertical incision is made 2 cm lateral to the posterosuperior iliac crest. The gluteal muscles are subperiosteally reflected off the posterior iliac wing. The origin of the gluteus maximus is reflected off the sacrum, and the greater sciatic notch is exposed to fully visualize the fracture reduction. To identify sacral fractures, the dissection is carried down to the sacral notch by reflecting the gluteus maximus fibers, the erector spinae, and the multifidus muscles. Internal fixation can usually be performed with single- or double-screw fixation, as described below, or with 3.5-mm reconstruction plates.

For percutaneous screw fixation, we prefer to place the patient supine on a radiolucent operating room table with the pelvis positioned on a flat elevated surface (one or two bed sheets). The image intensifier is then used to image the

sacroiliac joints and the sacrum in three views: a straight AP view, a 40-degree cephalad view (outlet view), and a 40-degree caudal view (inlet view). The inlet view shows the screw placement in the axial projection, and the operator examines the screw to be sure it is not too anterior or posterior. The outlet view shows the screw in the cephalocaudal orientation, and the operator ensures that the screw is between the neural foramina (Fig. 42-24). In a child more than 10 years old, we prefer to use a 6.5-mm or 7.3-mm cannulated cancellous screw, and in the younger child we use a 5.5-mm cannulated cancellous screw.

Intraoperative stimulus-evoked electromyography can be used to decrease the risk of iatrogenic nerve injury during the placement of percutaneous screws.^{21,22} Both legs are prepared and placed into the operative view to allow manipulation for reduction purposes. Reduction of the sacroiliac joint requires that traction be placed on the leg and manual compression be applied across the sacroiliac joint. More severely displaced fractures may require the use of skeletal traction, in which case we prefer to use a Schanz pin placed into the anterosuperior iliac spine to reduce the disruption. The starting position for the initial screw is approximately 2.5 cm lateral to the posterosuperior iliac spine. A small stab incision is made, and under image intensification the initial guide wire is placed superior to the first sacral foramen past the midline. We recommend that a second guide pin be placed between the first and second sacral foramina to help maintain the reduction during screw placement. The initial guide pin is then overdrilled across the sacroiliac joint and the lateral cortex is tapped, followed by placement of a partially threaded cancellous screw with a washer. The screw should travel past the midline to achieve optimal purchase and help lag the sacrum to the ilium to a reduced position. We have used single-screw fixation in children's

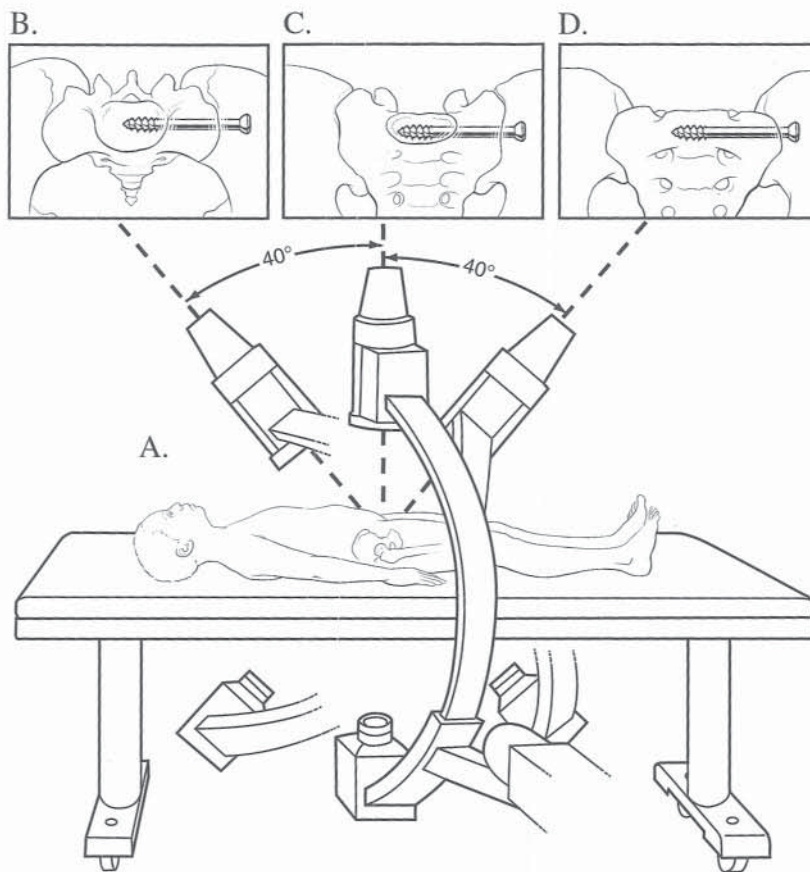


FIGURE 42-24 A, Fluoroscopic imaging for placement of sacroiliac screws. With the patient supine on the operating room table, fluoroscopy is used to image the pelvis in three views. B, The inlet view shows the anterior and posterior margins for screw placement. C, The AP view provides a general view of screw placement. D, The outlet view shows the superior and inferior margins for screw placement.

sacroiliac joint disruptions, with good success (Fig. 42-25). If good screw purchase is not achieved, the screw position should be verified, and if the screw is in the correct position, a second screw should be placed between the first and second sacral foramina. Postoperatively the patient can be partially weightbearing on the affected side, followed by full weightbearing after 6 weeks.

Treatment of Acetabular Fractures. Acetabular fractures in children are very rare, accounting for approximately 5 to 10 percent of all pelvic fractures. The majority do not require operative intervention. An isolated injury to the triradiate cartilage may not be noted at the time of the initial injury but may manifest later, when premature closure of the triradiate cartilage results in the development of a shallow acetabulum.⁴⁰

Acetabular fractures in children are usually treated nonoperatively, with approximately 25 percent requiring operative intervention.¹⁰ By contrast, the vast majority of acetabular fractures in adults require operative intervention.^{2a,14,15,17,18}

Conservative treatment is indicated in children's acetabular fractures when they are minimally displaced (less than 2 mm), and in fracture-dislocations in which a stable closed reduction of the femoral head results in minimal displacement of the fracture fragments. This includes all type I and most type II fractures in which the fracture fragments are less than 2 mm displaced following hip joint reduction, and some type IV fractures in which reduction of the central hip dislocation results in fracture reduction to within 2 mm. All patients with less than 2 mm of displacement have good or excellent functional radiographic results.¹⁰

In type I fractures, the patient is placed on bed rest for a short period (3 to 7 days) until comfortable and then begins to ambulate on crutches without bearing weight. Radiographs and/or CT scans should be obtained after the patient has been on crutches for a few days to ensure that the fracture fragments have not displaced. Progressive weightbearing is then started after 8 to 10 weeks.

Type II fractures are often associated with other pelvic ring fractures, which must be assessed and treated as discussed earlier. The acetabular fracture can generally be treated conservatively, usually with a period of bed rest and skin or skeletal traction. The period of bed rest is generally 4 weeks, followed by progressively increasing weightbearing, with the average time to full weightbearing being 10 weeks.¹⁰ Operative treatment of the acetabular fracture of this type is relatively uncommon.

Type III fractures are treated similarly to those in adults, with assessment of the fracture pattern, application of skeletal traction to restore articular congruity to within 2 mm, and operative intervention if this is not achieved. In our experience, traction is usually unable to restore or maintain joint congruity within acceptable limits, and open reduction with internal fixation is necessary. If traction is successfully utilized in these fractures, it must be continued for up to 12 weeks to avoid redisplacement of the fracture.

Type IV fractures in which there is a central fracture-dislocation should be initially treated with skeletal traction to try to reduce the dislocation and achieve an acceptable reduction. The few type IV fractures described in the literature have generally required operative intervention.^{2,10} Open

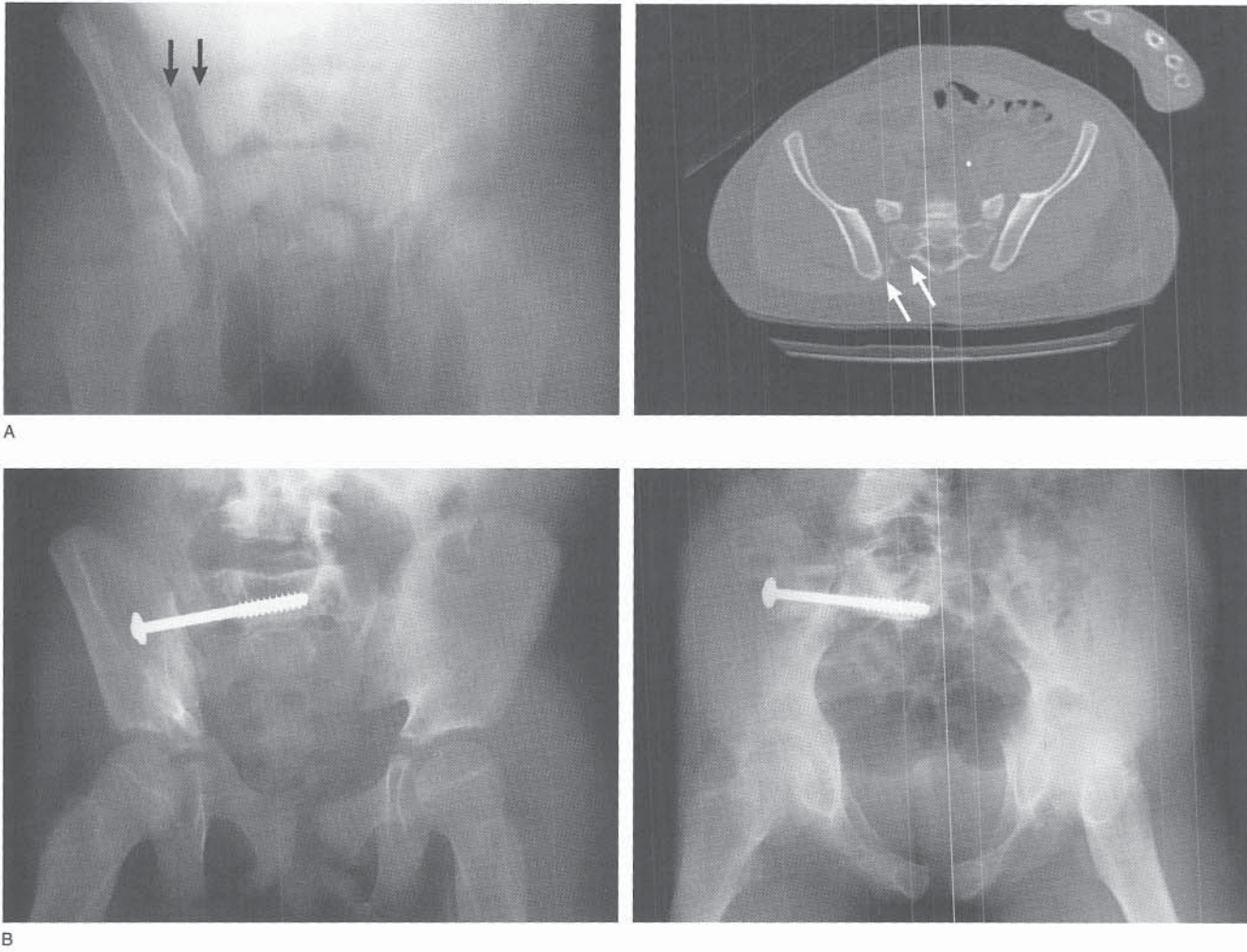


FIGURE 42-25 A, Initial outlet radiograph showing disruption of the right sacroiliac joint in a 10-year-old boy. The displacement is confirmed on CT, with disruption of the posterior ligaments. The *arrows* indicate the amount of displacement of the sacroiliac joint. B, Postoperative inlet and outlet radiographs. The sacroiliac joint disruption has been reduced and fixed with a single percutaneously placed screw. The outlet view shows the screw just superior to the first sacral foramina. The inlet view shows the screw to be well positioned in the axial plane.

reduction with stable internal fixation should be performed, although this may not improve the overall result. Heeg and colleagues described three patients with central fracture-dislocations, all of whom required operative intervention. An anatomic reduction was achieved in two patients, with a fair result in one and an excellent result in the other; the third patient had a poor outcome after anatomic reduction could not be achieved, and underwent a hip fusion 6 months following injury.¹⁰

Although isolated triradiate cartilage injuries account for a small percentage of acetabular fractures in children, they must be recognized because they can lead to significant progressive deformity (Fig. 42-26). The acetabulum grows through interstitial growth within the triradiate cartilage, so that interruption of this growth results in a shallow acetabulum, similar to developmental dysplasia of the hip.²⁸ Heeg and colleagues reported on four patients with injuries of the acetabular triradiate, all of whom had sustained an injury of the sacroiliac joint.¹¹ In three of the patients, acetabular deformity with hip subluxation developed, and the authors recommended that any patient who sustains pelvic trauma

should be followed clinically and radiographically for at least 1 year. Bucholz and colleagues reported on nine patients with triradiate cartilage injuries and classified these into two main patterns of injury based on the Salter-Harris classification.⁵ The first type, analogous to Salter-Harris type I or II injury, is a shear injury in which there is central displacement of the distal portion of the acetabulum (Fig. 42-26A); the prognosis for continued normal acetabular growth is favorable. The second type, analogous to the Salter-Harris type V injury, is often difficult to diagnose and generally has a poor prognosis, with premature closure of the triradiate cartilage. The degree of deformity depends on the age of the child at the time of injury; no patient in their study developed significant acetabular dysplasia when the injury occurred after age 11 years.⁵ The diagnosis is confirmed by thin-section (2 to 3 mm) CT through the triradiate cartilage (Fig. 42-26B).

Premature physal closures of the triradiate cartilage are treated by physal bar resection with interposition of fat or wax. There are very few reported cases in the literature, and results have been mixed. Peterson and Robertson reported

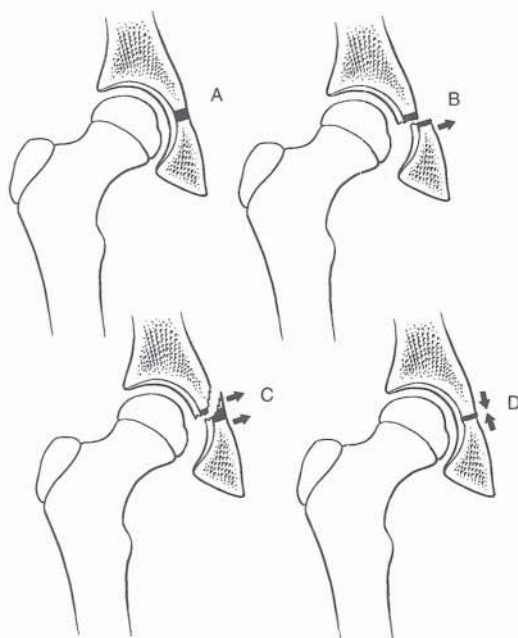
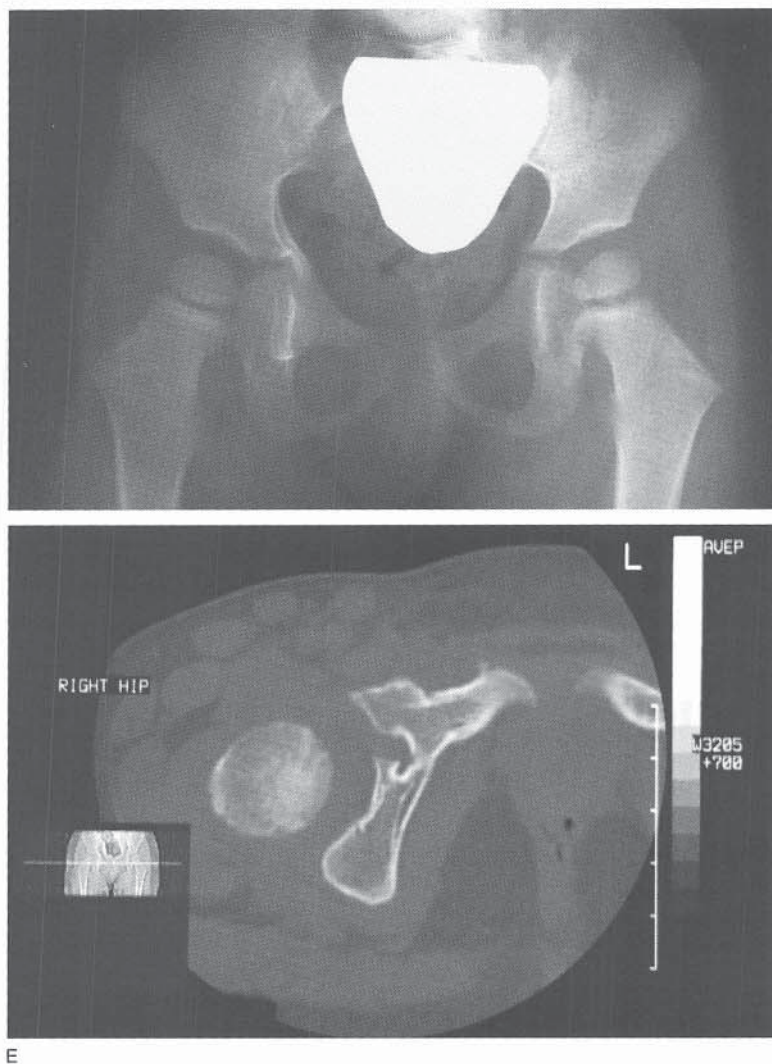


FIGURE 42-26 Triradiate cartilage injuries. **A**, Depiction of the normal triradiate cartilage. **B** and **C**, The first group of injuries described by Bucholz, in which a Salter-Harris type I or II fracture occurs; the prognosis for continued growth is good. **D**, The second type of triradiate cartilage injury, in which a Salter-Harris type V injury occurs; the prognosis for continued growth is worse. **E**, Radiograph and CT scan showing premature closure of the triradiate cartilage following injury in a 4-year-old girl who sustained a Salter-Harris type II fracture.



a successful physal bar resection in a child who had sustained the injury at 5 years of age and over the ensuing 2-year period had demonstrated development of a shallow acetabulum.²⁷ The second window of the ilioinguinal approach was used to identify the physal bar, and the exposed bony surfaces were covered with a thin layer of bone wax. Postoperative follow-up was reported to age 19 years, at which time the acetabulum had shown increased growth, which was observed by analyzing radiographic markers placed at the time of surgery. We recommend physal bar resection through an ilioinguinal approach when the patient is less than 12 years old.

The operative approach to the acetabulum depends on the type of fracture present. The posterior column and posterior acetabular wall are best fixed through the Kocher Langenbeck approach, and the anterior column and inner innominate bone are best approached through an ilioinguinal approach. Both columns can be approached through an extended iliofemoral approach; however, this approach leads to the highest incidence of heterotopic ossification and the longest postoperative recovery period and is rarely used in children's acetabular fractures.

The Kocher-Langenbeck approach requires the patient to be prone on a radiolucent operating table. The incision is begun lateral to the posterosuperior iliac spine and extends to the posterior aspect of the greater trochanter and down the lateral aspect of the femoral shaft. The fascia lata is split in line with the femur, the gluteus maximus tendon is then taken off its attachment to the femur, and the sciatic nerve is identified superficial to the quadratus femoris. The greater and lesser sciatic notch are then exposed by taking the piriformis and obturator internus tendons off the trochanter. Subperiosteal dissection is then carried out to expose the inferior aspect of the iliac wing, and a capsulotomy is made to expose the posterior aspect of the acetabulum and femoral head (Fig. 42-27).

The ilioinguinal approach was first described by Letournel, and this classic description should be studied prior to utilizing this approach.¹⁵ The patient is placed supine on the operating table. The incision begins at the midline approximately 3 to 4 cm above the pubis and continues to the anterosuperior iliac spine and follows the iliac crest. Subperiosteal dissection is then carried out along the iliac crest to expose the anterior sacroiliac joint and the internal

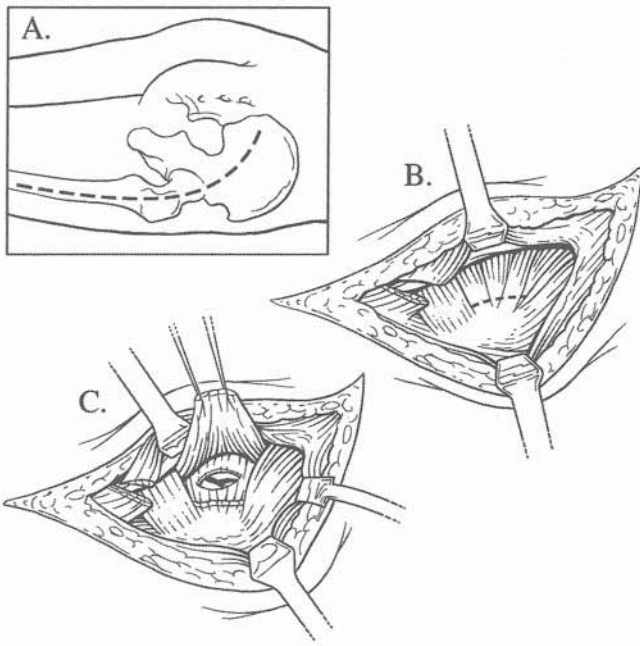


FIGURE 42-27 Kocher-Langenbeck approach to the posterior acetabulum. A, The incision is begun lateral to the posterosuperior iliac spine and continued to the greater trochanter and laterally down the proximal femur. B, The piriformis and obturator internus tendons are then dissected off the greater trochanter. C, Subperiosteal dissection followed by a capsulotomy is used to expose the posterior aspect of the acetabulum.

iliac fossa. The external oblique aponeurosis is incised to expose the inguinal canal. The spermatic cord is bluntly dissected and isolated, and a Penrose drain is placed around it. The posterior aspect of the inguinal ligament is then incised, allowing access to the psoas sheath, the retropubic space of Retzius, and the external aspect of the iliac vessels. A Penrose drain is then placed around the psoas and lateral cutaneous nerve of the thigh, and the iliopectineal fascia is divided. A second Penrose drain is placed around the external iliac vessels and lymphatics. The three windows of the ilioinguinal approach are now present (Fig. 42-28). The first window is between the iliac fossa and the psoas muscle, giving access to the internal iliac fossa, the anterior sacroiliac joint, and the upper portion of the anterior column. The second window is between the psoas muscle and the iliac vessel and provides access to the pelvic brim from the anterior sacroiliac joint to the lateral extremity of the superior pubic ramus. The third window is medial to the iliac vessels and provides access to the symphysis pubis and the retropubic space of Retzius.

The extended iliofemoral approach is rarely necessary and can be best learned by studying Letournel's original description.^{13,15}

Complications. Nonorthopaedic complications are related to the associated injuries as described in the preceding sections, especially genitourinary and neurologic system injuries, hemorrhage, lacerations of the vagina or rectum, and possibly death. Urinary infections have been reported in 10 to 20 percent of patients, and pulmonary complications, including pneumonia, have occurred in 10 to 30 percent of patients.^{33,41}

Complications related directly to the pelvis and acetabular fractures include delayed union, nonunion, malunion, and sacroiliac joint pain. Nierenberg and colleagues reported no complications in 14 patients with stable pelvic fractures, but three of six unstable fractures had malunions.²⁴ Torode and Zieg reported complications only in type IV pelvic fractures. Of 40 patients, eight (20 percent) demonstrated nonunion of the pubic rami and three (8 percent) demonstrated premature closure of the triradiate cartilage. In addition, marked displacement of the pelvic ring was noted in five (13 percent) patients, although four of these patients were classified as having an excellent result and one (3 percent) patient demonstrated fusion of the sacroiliac joint, which was partly responsible for pelvic distortion.⁴⁰

Acetabular fractures are associated with both early and late complications. Heeg and colleagues described eight (35 percent) patients with early complications: four had a urinary or respiratory tract infection, three had pin tract infections, and one patient had a superficial infection at the operative site. Late complications occurred in three (13 percent) patients, all of whom had operative treatment: two (9 percent) had premature closure of the triradiate cartilage requiring further operative treatment and one (4 percent) had a painful hip secondary to extensive heterotopic ossification and subsequently underwent fusion.

REFERENCES

The Pelvis and Acetabulum

- Bond SJ, Gotschall CS, Eichelberger MR: Predictors of abdominal injury in children with pelvic fracture. *J Trauma* 1991;31:1169.
- Brooks E, Rosman M: Central fracture-dislocation of the hip in a child. *J Trauma* 1988;28:1590.
- Bryan WJ, Tullos HS: Pediatric pelvic fractures: review of 52 patients. *J Trauma* 1979;19:799.
- Bucholz RW: The pathological anatomy of Malgaigne fracture-dislocations of the pelvis. *J Bone Joint Surg* 1981;63-A:400.
- Bucholz RW, Ezaki M, Ogden JA: Injury to the acetabular triradiate physeal cartilage. *J Bone Joint Surg* 1982;64-A:600.
- Dunn AW, Morris HD: Fractures and dislocations of the pelvis. *J Bone Joint Surg* 1968;50-A:1639.
- Edeiken-Monroe BS, Browner BD, Jackson H: The role of standard roentgenograms in the evaluation of instability of pelvic ring disruption. *Clin Orthop* 1989;240:63.
- Fernbach SK, Wilkinson RH: Avulsion injuries of the pelvis and proximal femur. *AJR Am J Roentgenol* 1981;137:581.
- Hak DJ, Olson SA, Matta JM: Diagnosis and management of closed internal degloving injuries associated with pelvic and acetabular fractures: the Morel-Lavallee lesion. *J Trauma* 1997;42:1046.
- Heeg M, Klasen HJ, Visser JD: Acetabular fractures in children and adolescents. *J Bone Joint Surg* 1989;71-B:418.
- Heeg M, Visser JD, Oostvogel HJ: Injuries of the acetabular triradiate cartilage and sacroiliac joint. *J Bone Joint Surg* 1988;70-B:34.
- Judet R, Judet J, Letournel E: Fractures of the acetabulum: classification and surgical approaches for open reduction. *J Bone Joint Surg* 1964;46-A:1615.
- Letournel E: The results of acetabular fractures treated surgically: twenty-one years' experience. In *The Hip: Proceedings of the Seventh Open Scientific Meeting of the Hip Society*, p 42. St. Louis, CV Mosby, 1979.
- Letournel E: Acetabulum fractures: classification and management. *Clin Orthop* 1980;151:81.
- Letournel E, Judet R: *Fractures of the Acetabulum*. Berlin, Springer-Verlag, 1981.
- Magid D, Fishman EK, Ney DR, et al: Acetabular and pelvic fractures in the pediatric patient: value of two- and three-dimensional imaging. *J Pediatr Orthop* 1992;12:621.

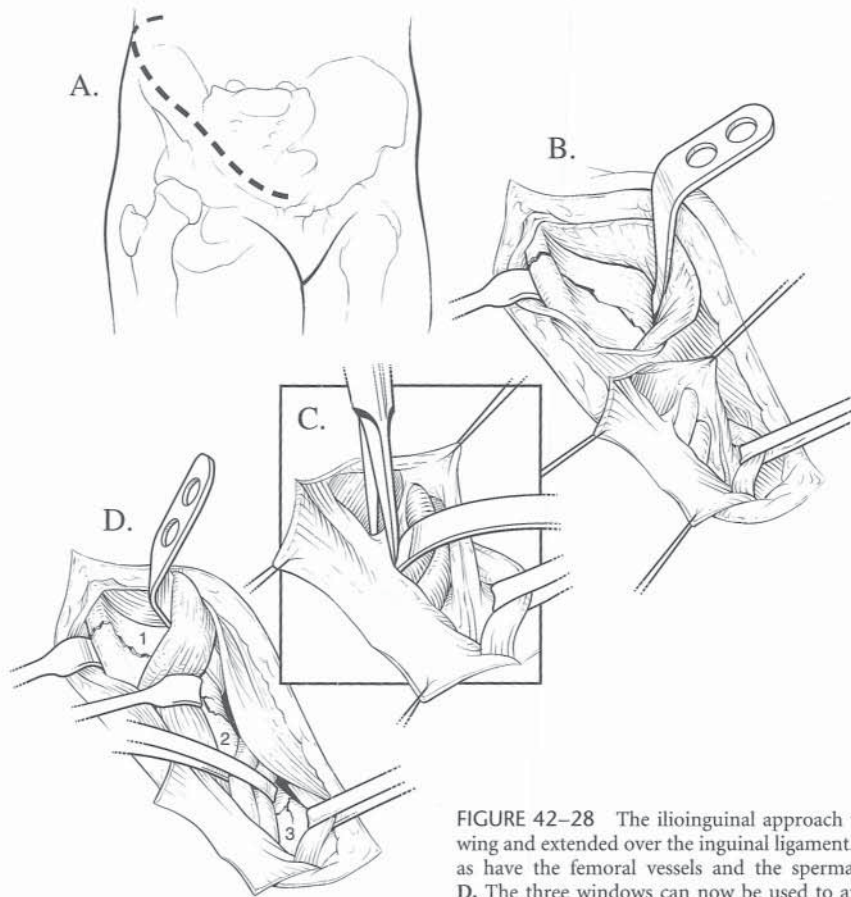


FIGURE 42-28 The ilioinguinal approach to the acetabulum. A, The incision is begun at the iliac wing and extended over the inguinal ligament. B, The medial aspect of the iliac fossa has been exposed, as have the femoral vessels and the spermatic cord. C, The iliopectineal fascia has been incised. D, The three windows can now be used to approach the acetabular fracture.

17. Matta JM, Anderson LM, Epstein HC, et al: Fractures of the acetabulum: a retrospective analysis. *Clin Orthop* 1986;205:230.
18. Matta JM, Mehne DK, Roffi R: Fractures of the acetabulum: early results of a prospective study. *Clin Orthop* 1986;205:241.
19. McDonald GA: Pelvic disruptions in children. *Clin Orthop* 1980; 151:130.
20. Metzmaker J, Pappas A: Avulsion fractures of the pelvis. *Orthop Trans* 1980;4:82.
21. Moed B, Ahmad B, Craig J, et al: Intraoperative monitoring with stimulus-evoked electromyography during placement of iliosacral screws: an initial clinical study. *J Bone Joint Surg* 1998;80-A:537.
22. Moed BR, Anders MJ, Ahmad BK, et al: Intraoperative stimulus-evoked electromyographic monitoring for placement of iliosacral implants: an animal model. *J Orthop Trauma* 1998;12:85.
23. Morel-Lavallee: Decollements traumatiques de la peau et des couches sous-jacentes. *Arch Gen Med* 1863;1:20.
24. Nierenberg G, Volpin G, Bialik V, et al: Pelvic fractures in children: a follow-up in 20 children treated conservatively. *J Pediatr Orthop B* 1993;1:140.
25. Peltier L: Complications associated with fractures of the pelvis. *J Bone Joint Surg* 1965;47-A:1060.
26. Pennal GF, Tile M, Waddell JP, et al: Pelvic disruption: assessment and classification. *Clin Orthop* 1980;151:12.
27. Peterson H, Robertson R: Premature partial closure of the triradiate cartilage treated with excision of a physal osseous bar: case report with a fourteen-year follow-up. *J Bone Joint Surg* 1997;79-A:767.
28. Ponseti IV: Growth and development of the acetabulum in the normal child: anatomical, histological, and roentgenographic studies. *J Bone Joint Surg* 1978;60-A:575.
29. Postacchini F, Massobrio M: Idiopathic coccygodynia: analysis of fifty-one operative cases and a radiographic study of the normal coccyx. *J Bone Joint Surg* 1983;65-A:1116.
30. Quinby WC Jr: Fractures of the pelvis and associated injuries in children. *J Pediatr Surg* 1966;1:353.
31. Rang M: *Children's Fractures*. Philadelphia, JB Lippincott Co, 1974.
32. Reed M: Pelvic fractures in children. *J Can Assoc Radiol* 1976;25:255.
33. Reichard SA, Helikson MA, Shorter N, et al: Pelvic fractures in children: review of 120 patients with a new look at general management. *J Pediatr Surg* 1980;15:727.
34. Routt M, Kregor P, Simonian P, et al: Early results of percutaneous iliosacral screws placed with the patient in the supine position. *J Orthop Trauma* 1995;9:209.
35. Routt M, Meir M, Kregor P, et al: Percutaneous iliosacral screws with the patient supine technique. *Operat Tech Orthop* 1993;3:35.
36. Routt ML Jr, Simonian PT: Closed reduction and percutaneous skeletal fixation of sacral fractures. *Clin Orthop* 1996;329:121.
37. Sundar M, Carty H: Avulsion fractures of the pelvis in children: a report of 32 fractures and their outcome. *Skeletal Radiol* 1994;23:85.
38. Tile M: *Fractures of the Pelvis and Acetabulum*. Baltimore, Williams & Wilkins Co, 1984.
39. Tile M: Pelvic ring fractures: should they be fixed? *J Bone Joint Surg* 1988;70-B:1.
40. Torode I, Zieg D: Pelvic fractures in children. *J Pediatr Orthop* 1985; 5:76.
41. Trunkey DD, Chapman MW, Lim RC Jr, et al: Management of pelvic fractures in blunt trauma injury. *J Trauma* 1974;14:912.
42. Watts HG: Fractures of the pelvis in children. *Orthop Clin North Am* 1976;7:615.
43. Winkler AR, Barnes JC, Ogden JA: Break dance hip: chronic avulsion of the anterior superior iliac spine. *Pediatr Radiol* 1987;17:501.
44. Young J, Burgess A: *Radiological Management of Pelvic Ring Fractures*. Baltimore, Urban & Schwarzenberg, 1987.

ADDED REFERENCES

The Pelvis and Acetabulum

- 1a. Kellam JF, McMurtry RY, Paley D, et al: The unstable pelvic fracture: operative treatment. *Orthop Clin North Am* 1987;18:25.
- 2a. Matta J, Saucedo T: Internal fixation of pelvic ring fractures. *Clin Orthop* 1989;242:83.

- 3a. Ruedi T, Hochstetter AV, Schlumpf R: *Surgical Approaches for Internal Fixation*. Berlin, Springer-Verlag, 1984.
- 4a. Simpson L, Waddell J, Leighton R: Anterior approach and stabilization of the disrupted sacro-iliac joint. *J Trauma* 1987;27:1332.

The Hip

HIP DISLOCATIONS

Traumatic hip dislocations in children are relatively rare injuries. In the younger child (less than 5 years old), minor trauma such as a slip or a fall from a low height may cause a hip dislocation, whereas a dislocation in an adolescent is generally caused by major trauma such as a motor vehicle accident. Posterior dislocations are approximately eight to nine times more common than anterior dislocations, and treatment generally consists of closed reduction under sedation or general anesthesia, followed by immobilization and a short period of nonweightbearing activity. Complications are similar to those in adults; however, recurrent hip dislocations are more common in children.

Anatomy. The iliofemoral ligament, often referred to as the Y-ligament of Bigelow, is the major ligamentous structure stabilizing the hip. It originates on the anteroinferior iliac spine, extends across the anterior aspect of the hip joint, and attaches to the femur at the anterior intertrochanteric line (Fig. 42–29). The iliofemoral ligament limits hyperextension and lateral rotation of the hip joint and is the primary obstacle to reduction in posterior hip dislocations. The ischiofemoral ligament is located posteriorly and lies deep to the short external rotators, which provide additional stability. In a posterior dislocation of the hip, the ligamentum teres is avulsed, the posterior hip capsule is torn, a fragment of the posterior acetabular rim is often fractured, and the labrum may be avulsed or torn. The capsular tear may be at its attachment to the posterior labrum^{5,23} or in its midsubstance.⁴² The short lateral rotator muscles—obturator internus, piriformis, obturator externus, and quadratus muscles—are either partially or completely torn along with the capsule. The gluteus maximus, medius, and minimus muscles are stretched and translated posteriorly by the femoral head, which lies deep to or within the fibers of these muscles.

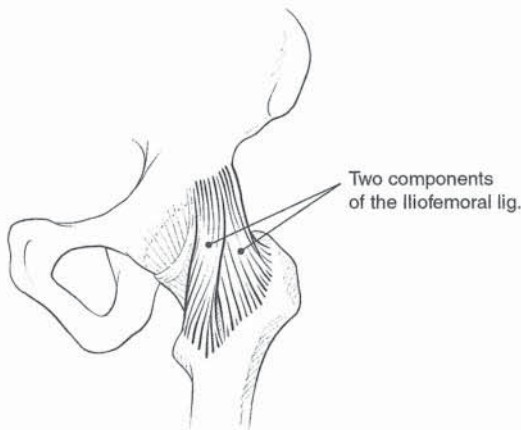


FIGURE 42–29 The iliofemoral ligament is composed of two bands originating on the anteroinferior iliac spine and attaching to the intertrochanteric line anterior to the lesser and greater trochanter.

Structures and conditions that are known to block reduction include the piriformis muscle, which may be displaced across the acetabulum; osteocartilaginous fragments; infolding of the labrum and capsule; and buttonholing of the femoral head through a small tear in the posterior capsule.^{5,29,32,40}

Anterior hip dislocations also tear the ligamentum teres and the anterior joint capsule. The muscles anterior to the hip joint may be stretched or partially torn. Rarely, the femoral nerve and artery are also injured during a high-energy injury.^{4,12}

Classification. There are several classifications for hip dislocations in adults. However, because this injury is rare in children, no classification system is widely used in the pediatric literature. The simplest classification is based on the direction in which the femoral head is dislocated relative to the acetabulum (Figs. 42–30A and B). Most (75 to 90 percent) hip dislocations are posterior.^{6,8,11,30,31} Posterior hip dislocations can be further subdivided based on the resting position of the femoral head: iliac, if the femoral head lies posteriorly and superiorly along the lateral aspect of the ilium, and ischial, if it lies adjacent to the greater sciatic notch. The remaining dislocations are anterior and are subdivided into obturator and pubic dislocations (Figs. 42–30C and D). A central hip dislocation is relatively rare in children and is associated with a fracture of the acetabulum.

Hip dislocations in children are associated with fractures of the acetabulum or proximal femur far less frequently than in adults. The incidence of associated fractures in children ranges from 4 percent in the series of Pearson and Mann³⁰ to 18 percent in the Pennsylvania Orthopaedic Society report.¹³ The Stewart-Milford classification is the most commonly used classification for hip fracture-dislocations (Fig. 42–30E):³⁷

- Grade I: No acetabular fracture or only a minor chip fracture.
- Grade II: Posterior rim fracture, but the hip is stable after reduction.
- Grade III: Posterior rim fracture with hip instability after reduction.
- Grade IV: Dislocation accompanied by fracture of the femoral head and neck.

Acetabular fractures should be classified individually to allow standard preoperative treatment planning (see previous discussion under Pelvic and Acetabular Fractures).

Mechanism of Injury. Two main mechanisms of injury result in a hip dislocation, usually based on age. In the younger age group (less than 5 years old), a trivial fall or slip may result in a hip dislocation because of the generalized joint laxity and soft cartilaginous acetabulum in this age group. In older patients (11 to 15 years) the hip dislocation is more often due to a higher-energy trauma (athletic injury or a motor vehicle accident).^{13,21} It is important to obtain a good history, since the mechanism of injury has prognostic implications, with high-energy trauma injuries resulting in a worse outcome.¹³

The typical posterior dislocation results from a posteriorly directed axial load applied to the distal femur. This is often seen in motor vehicle accidents in which the patient is in the front seat during a head-on collision and the knee strikes the dashboard, pushing the femoral head posteriorly out of the acetabulum. This mechanism of injury often

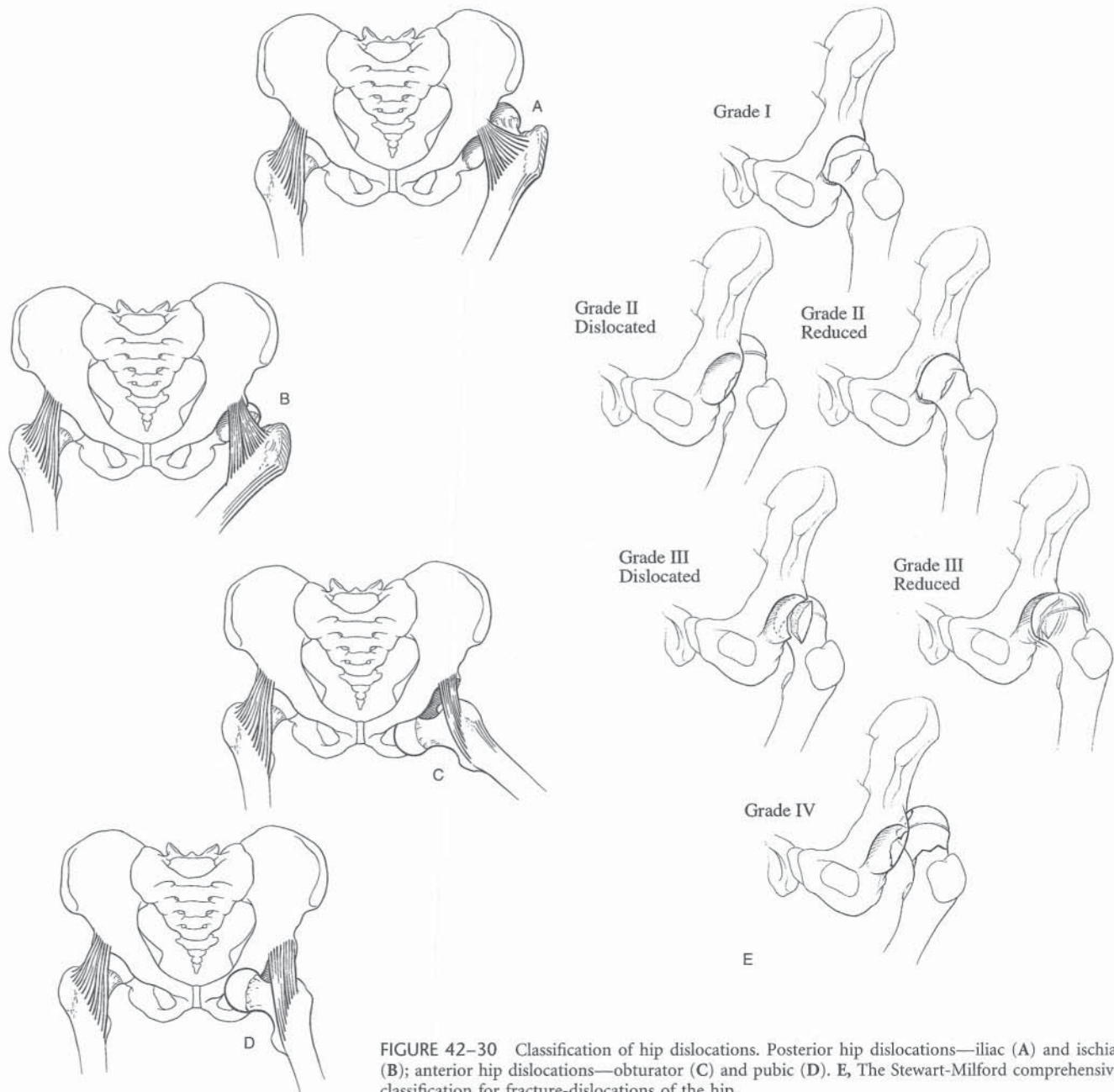


FIGURE 42-30 Classification of hip dislocations. Posterior hip dislocations—iliac (A) and ischial (B); anterior hip dislocations—obturator (C) and pubic (D). E, The Stewart-Milford comprehensive classification for fracture-dislocations of the hip.

results in associated injuries, including hip, femoral shaft, distal femoral, patellar, or proximal tibial fractures. A front-seat passenger or driver who sustains these fractures in a motor vehicle accident should always be suspected of having a hip dislocation or subluxation with an associated acetabular injury. Careful physical examination and radiographic examination, often including CT, are necessary to evaluate the hip joint even though the initial AP radiograph may appear normal.

Anterior hip dislocations result from an anteriorly directed force applied to the posterior aspect of the abducted and laterally rotated thigh. The femoral head is displaced forward, commonly lying external to the obturator foramen.

Central dislocations with fractures of the acetabulum are due to a medially directed force on the greater trochanter.

A fall from a height is the most common mechanism, followed by a motor vehicle accident in which the dashboard strikes the knee when the hip is extended and abducted.

Diagnostic Features. The child with an acute hip dislocation will be in severe pain, and any attempted motion of the affected hip will exacerbate the pain. The position of the limb is characteristic for the type of hip dislocation. In a posterior hip dislocation the involved thigh is held flexed and adducted and in a medially rotated position (Fig. 42-31A). The limb appears shorter than the contralateral limb, and the femoral head can be palpated posteriorly. In anterior dislocations the leg is held in abduction, lateral rotation, and some flexion (Fig. 42-31B). There is fullness in the region of the obturator foramen, where the femoral head can be palpated, and the extremity may appear longer

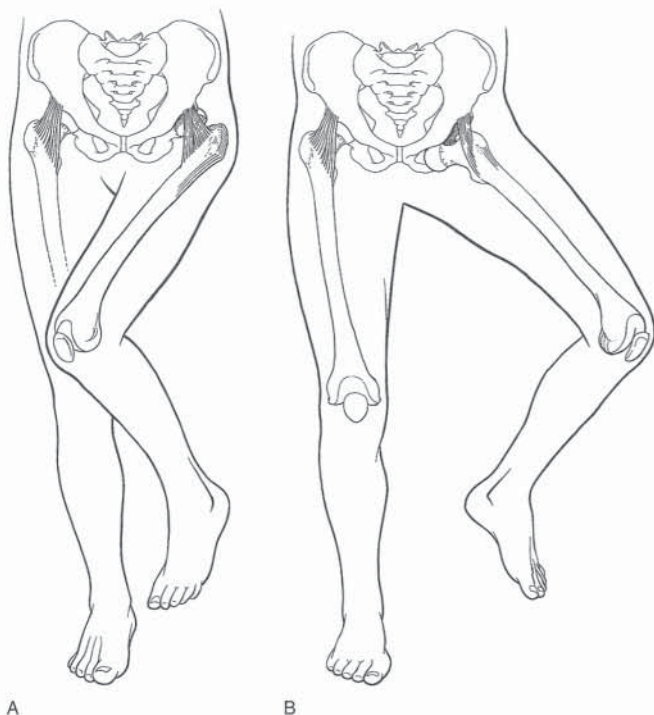


FIGURE 42-31 Clinical position of the lower extremity with posterior (A) and anterior (B) hip dislocations.

than the other side. In central hip dislocations the leg does not rest in a characteristic position and the leg length is similar to that of the opposite leg. There may be some narrowing of the pelvic width as a result of the central displacement of the affected hip. A thorough neurologic examination of the affected extremity should be performed, with careful evaluation of sciatic nerve function in posterior dislocations and femoral nerve function in anterior dislocations. The peripheral pulses, including the posterior tibial, dorsalis pedis, and popliteal pulses, should be palpated, and a thorough examination should be performed to assess for other injuries, especially ipsilateral leg, thigh, and hip fractures.^{2,7,19,20,25}

Radiologic Examination. An AP pelvic radiograph should be obtained to confirm the hip dislocation and to rule out other fractures (Fig. 42-32A). Oblique (Judet) views and CT scans should be obtained when an associated acetabular fracture is suspected (Fig. 42-32B). Isolated radiographs of the hip joint should be obtained before attempts are made to reduce the hip dislocation when a femoral head or femoral neck fracture is seen on the initial AP pelvic film. Following reduction of the hip dislocation, an AP pelvic radiograph should be carefully evaluated to confirm a concentric reduction (Fig. 42-33). A postreduction CT study can be done routinely following an apparently successful closed reduction to ensure that a concentric reduction was achieved and to image loose fragments in the joint, which cannot be seen on a plain radiograph. Because associated fractures in children are relatively rare, with a posterior or anterior hip dislocation, we prefer to perform a postreduction CT study when concerned that a concentric reduction has not been achieved or to assess an acetabular wall or femoral head fracture suspected on the postreduction radiograph. An arte-

riogram should be obtained in any child in whom the clinical findings or Doppler studies indicate a femoral arterial injury.²⁸

Treatment. Hip dislocations should be treated on an urgent basis with prompt, immediate reduction following a thorough physical examination and evaluation of the plain radiographs. A closed reduction should be attempted under general anesthesia in the operating room if it can be done without delay, or in the emergency room under conscious sedation. The method and duration of immobilization following reduction have not been agreed upon, although some form of immobilization should be used.

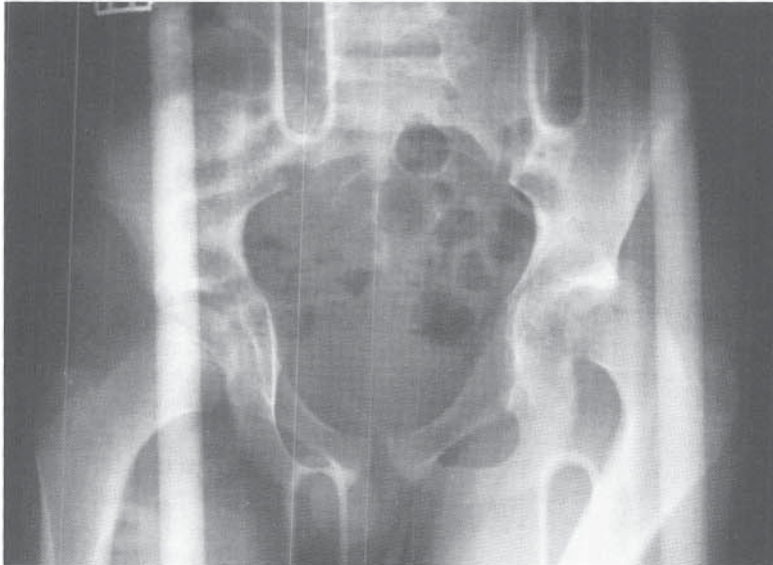
Closed reduction of a posterior dislocation can be accomplished using the Bigelow,³ Allis,¹ or Stimson³⁸ methods, which all rely on flexion of the hip joint to relax the iliofemoral ligament. The easiest, most common, and most effective treatment is that described by Allis (Fig. 42-34).¹ The patient is placed supine, and an assistant stabilizes the pelvis by applying direct pressure over the anterosuperior iliac spine. The hip and knee are then flexed 90 degrees, with the thigh in slight adduction and medial rotation. The surgeon then places a forearm behind the patient's knee and leg and applies an anteriorly directed force to release the femoral head from behind the posterior lip of the acetabulum. If soft tissue resistance is felt, further medial rotation and hip adduction are performed in an effort to relax the hip joint capsule, while the closed reduction is performed. An assistant can apply anteriorly directed pressure on the femoral head to aid in the reduction.

In the circumduction method of Bigelow, an assistant applies countertraction on the anterosuperior iliac spine while the surgeon grasps the affected limb at the ankle with one hand and places the opposite forearm behind the patient's knee (Fig. 42-35). The initial maneuver is to flex the adducted and medially rotated thigh 90 degrees while longitudinal traction is applied in line with the deformity. This will relax the Y-ligament and bring the femoral head near the posterior rim of the acetabulum. The femoral head is then freed from the rotator muscles by gently rotating the thigh back and forth. Finally, the femoral head is levered into the acetabulum by gentle abduction, lateral rotation, and extension of the hip. Manipulation should always be gentle, to prevent rupture of the Y-ligament or damage to the sciatic nerve. The prone position is required for the Stimson technique, which is difficult to do in a larger child but can be used in the younger patient (Fig. 42-36).

To reduce an anterior dislocation of the hip, a modification of the Allis technique entails initially flexing the knee to relax the hamstrings while the hip is fully abducted and flexed to 90 degrees (Fig. 42-37). Traction should be applied directly in line with the longitudinal axis of the femur while an assistant applies posterior pressure on the anteriorly dislocated femoral head. The surgeon then adducts the hip, using the patient's thigh as the lever, to reduce the femoral head into the acetabulum. The hip can be medially rotated as it is adducted to achieve reduction.

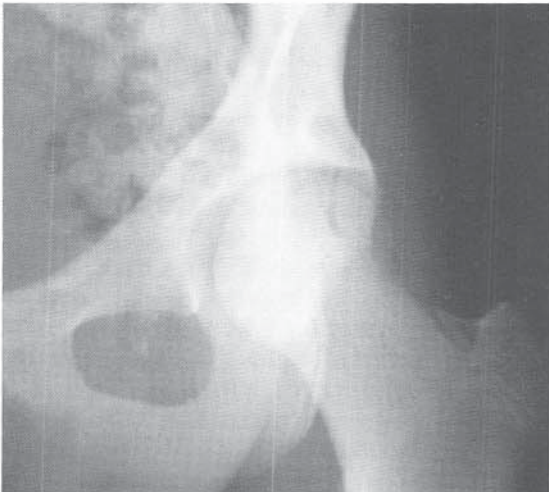
Central dislocations require skeletal traction through a distal femoral pin to reduce the femoral head to its anatomic position. Because the central dislocation is associated with an acetabular fracture, which is often comminuted, the medially

Text continued on page 2280

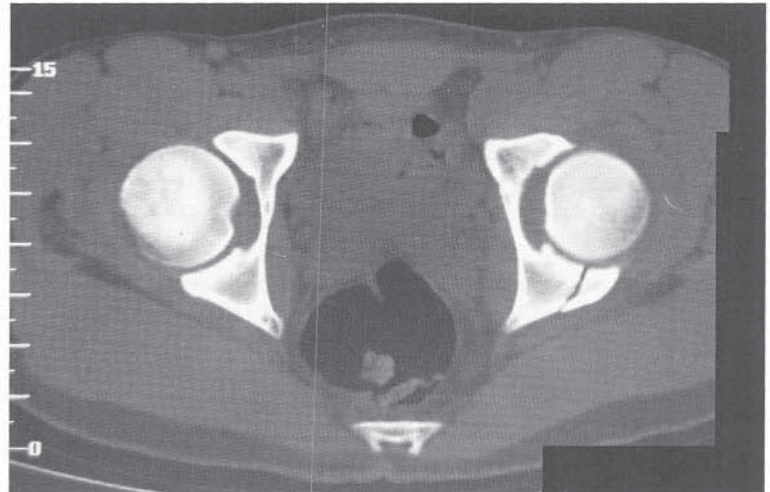


A

FIGURE 42-32 Posterior hip dislocations. **A**, AP radiograph of a posterior hip dislocation in a 10-year-old. **B**, Posterior acetabular fracture seen on a postreduction radiograph and CT scan following a posterior hip dislocation in a 13-year-old boy.



B



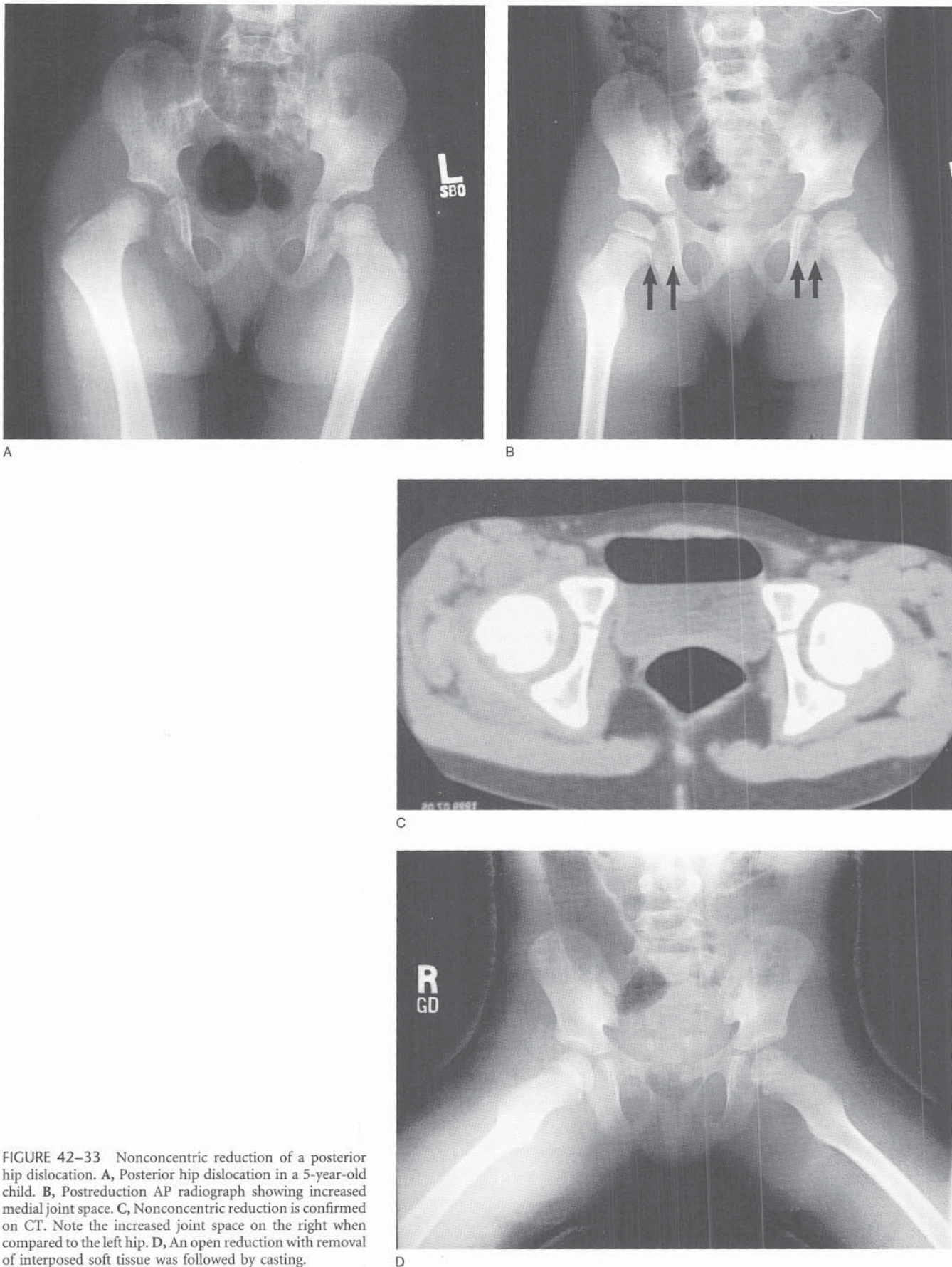


FIGURE 42-33 Nonconcentric reduction of a posterior hip dislocation. **A**, Posterior hip dislocation in a 5-year-old child. **B**, Postreduction AP radiograph showing increased medial joint space. **C**, Nonconcentric reduction is confirmed on CT. Note the increased joint space on the right when compared to the left hip. **D**, An open reduction with removal of interposed soft tissue was followed by casting.

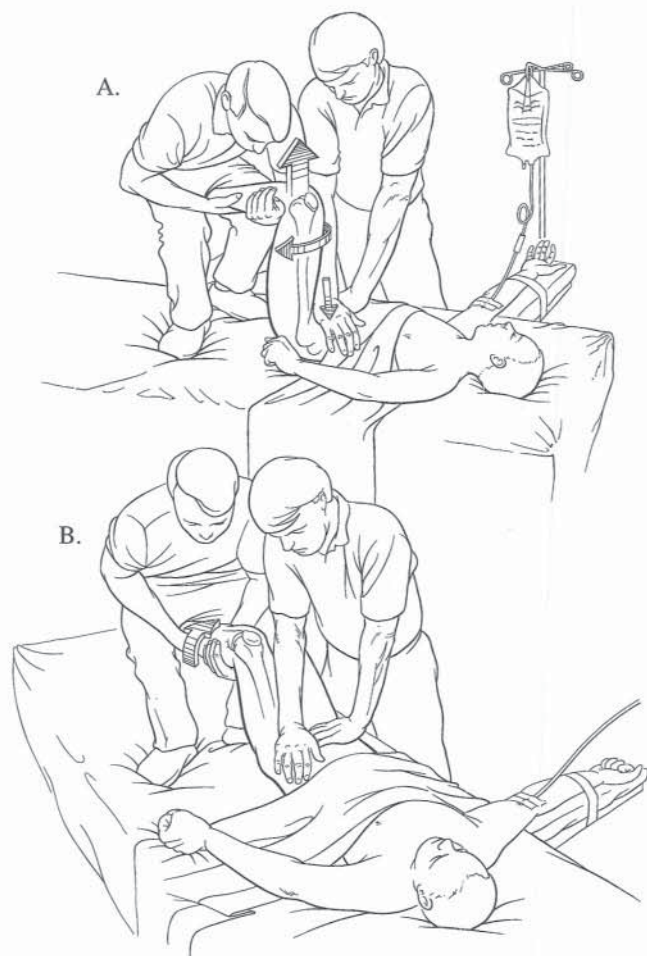


FIGURE 42-34 A and B, Allis's direct method for reducing a posterior hip dislocation.

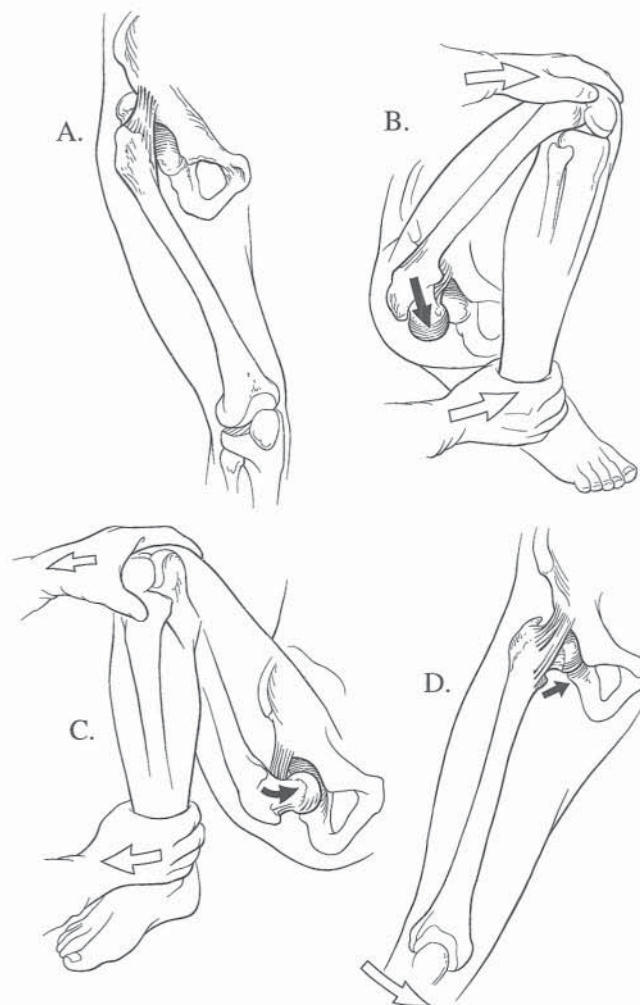


FIGURE 42-35 A to D, Bigelow's circumduction method for reducing a traumatic posterior dislocation of the hip.

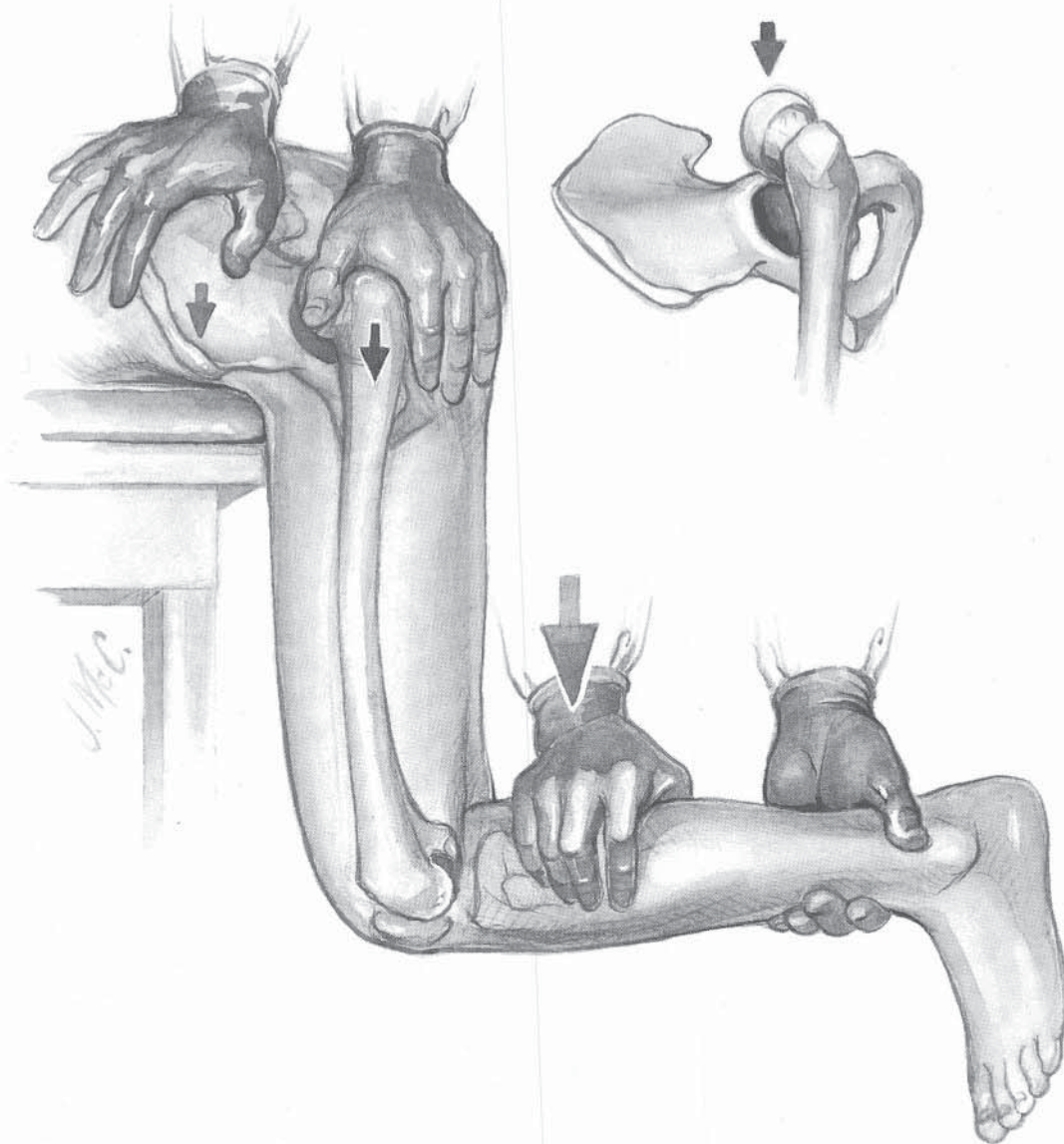


FIGURE 42-36 Stimson's gravity method for reducing a traumatic posterior dislocation of the hip.

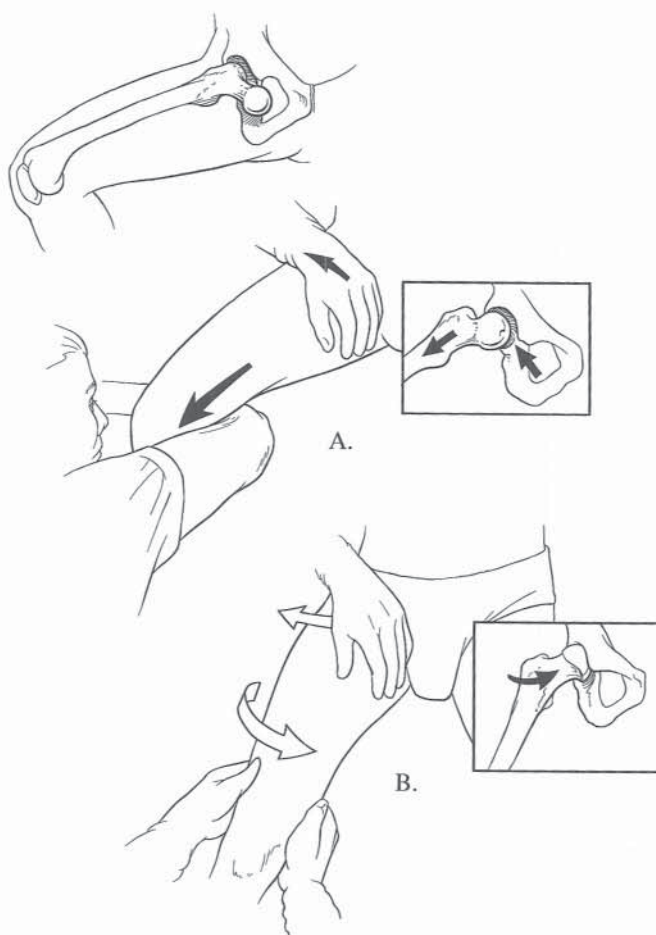


FIGURE 42-37 A and B, Allis's method for reducing a traumatic anterior dislocation of the hip.

displaced femoral head must be initially reduced into its anatomic position. This is best accomplished through a skeletal traction pin (Schanz pin placed from lateral to medial or a skeletal traction pin placed in the AP direction) into the greater trochanter. Lateral traction can be applied to initially reduce the central dislocation and then be removed if the reduction is stable, or it can remain for up to 2 to 3 weeks. The distal skeletal traction is maintained for a total of 3 to 4 weeks, with some active range of motion of the hip allowed to promote molding of the acetabulum.

The indications for open reduction of a dislocated hip are failed closed reduction, a nonconcentric closed reduction, and a dislocation associated with a displaced femoral head, neck or acetabular fracture. The surgical approach depends on the direction of the hip dislocation: a posterior approach for posterior dislocations and an anterior approach for anterior dislocations. The goals of surgical intervention are to clear the obstacles preventing reduction of the hip (piriformis tendon, hip capsule), identify objects preventing a concentric reduction (inverted limbus, osteocartilaginous loose bodies), anatomically fix any acetabular or femoral head fractures, and repair the soft tissue envelope.

A standard posterior approach (Southern or Moore) to the hip is used (Fig. 42-38).²⁶ The sciatic nerve should be identified visually and followed both proximally and distally, especially when nerve injury has been identified on the pre-

operative physical examination. The remaining soft tissue structures should then be inspected and all torn muscles tagged with suture to allow proper closure at the completion of the procedure. The short external rotators should be divided 1 cm from their insertion. The femoral head is often protruding through a tear in the posterior capsule, and care should be taken to avoid injuring the articular cartilage at that point. The capsule should be incised to allow complete inspection of the labrum, the posterior wall of the acetabulum, and the articular surfaces of the acetabulum and femoral head. Subluxation or dislocation of the femoral head should be performed to allow good visualization, and it is often achieved by means of skeletal traction applied through a Schanz screw placed into the greater trochanter. The joint is irrigated, and any osteocartilaginous debris is removed. Posterior rim fractures should be internally fixed with screws in the young child, and a 3.5-mm pelvic reconstruction plate should be used in the adolescent. Labral avulsions are repaired by fixing the labrum down to the posterior rim of the acetabulum (analogous to a Bankart-type repair in the shoulder), and the posterior capsule should be repaired (see Fig. 42-38C).

An anterior approach for an anterior hip dislocation can be either a direct anterior (Smith-Peterson) approach or an anterolateral (Watson-Jones) approach. The literature on surgical intervention for anterior dislocations is sparse, since the vast majority are concentrically reduced closed.^{7,9} However, the goals of surgical treatment remain the same and should be kept in mind when operative intervention is needed.

The postreduction treatment following a concentric reduction depends on the age of the patient and on whether or not associated fractures are present. Children less than 6 to 7 years old should be placed into a hip spica cast with the affected hip in neutral extension and some abduction. An alternative treatment in the young child is a period of skin traction. In the older child, bed rest followed by gradual mobilization on crutches can be used. The period of immobilization for a simple dislocation should be 4 weeks in the young child and 6 weeks in the older child, to allow capsular and soft tissue healing. In fracture-dislocations, 6 to 8 weeks of immobilization in the young child and up to 12 weeks in the older child should be used to allow fracture healing. Following the period of immobilization, partial weightbearing is allowed until there is pain-free full range of motion of the hip, at which time full weightbearing is allowed.²¹ Most children will resume full activities and full weightbearing as soon as the immobilization period has ended.³⁰ Although these guidelines are generally accepted, there is no consensus on the exact duration of immobilization and time to full weightbearing. In addition, there is no correlation between the final result and the period of nonweightbearing following a traumatic hip dislocation.^{8,13,14,21,30,34}

Complications. The most common complications following a traumatic hip dislocation in children are AVN of the femoral head, sciatic nerve injury, recurrence of the hip dislocation, late degenerative arthritis, and, rarely, femoral arterial injury in anterior dislocations.

The most common complication following a posterior traumatic hip dislocation in children is AVN of the femoral head, with the reported incidence between 8 and 18 percent.^{13,15,17,21,30} The most important factors predisposing to

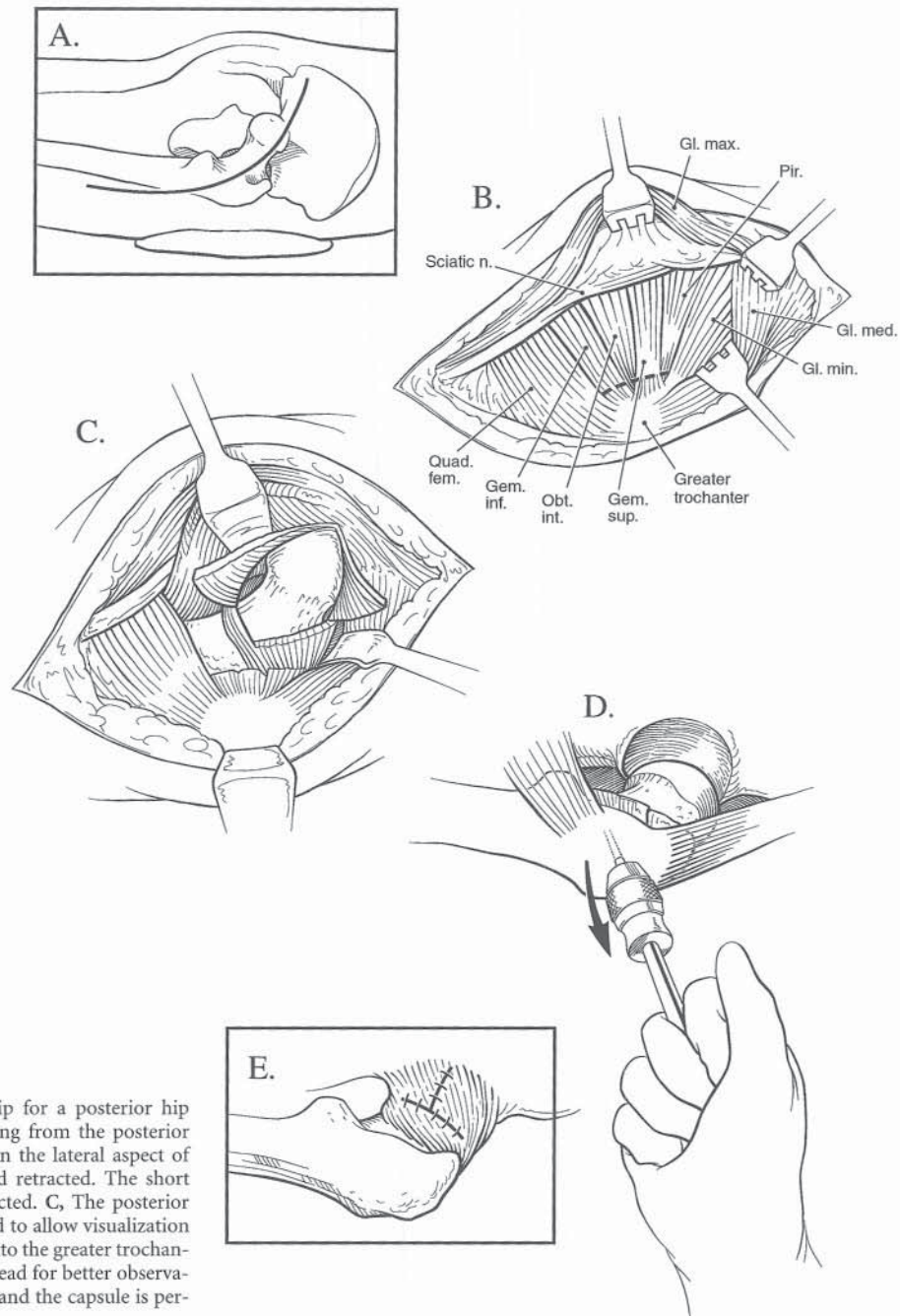


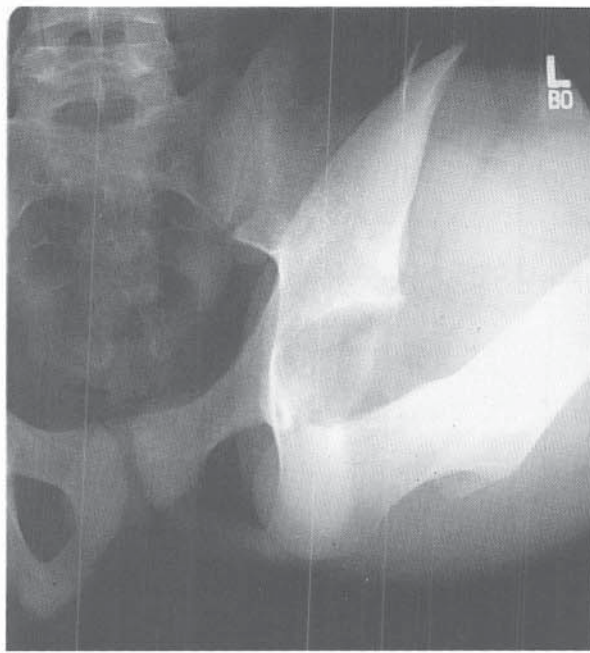
FIGURE 42-38 Posterior approach to the hip for a posterior hip dislocation. A, A skin incision is made extending from the posterior iliac spine over the greater trochanter and down the lateral aspect of the thigh. B, The sciatic nerve is identified and retracted. The short rotators are incised at their insertion and retracted. C, The posterior capsule, which is partially torn, should be incised to allow visualization of the acetabulum. D, A Schanz screw is placed into the greater trochanter to allow the surgeon to distract the femoral head for better observation of the acetabulum. E, Repair of labral tears and the capsule is performed.

the development of AVN are older age (more than 6 years), severe trauma, and a delay of more than 24 hours from the time of injury to the time of reduction (Fig. 42-39). Although radiographic changes can be seen as early as 3 months, AVN can develop up to 2 years after injury.¹³ Therefore, serial radiographs should be obtained for at least 2 years following the original dislocation. The treatment of AVN is difficult and varies with the age of the child. In adolescents, a proximal femoral osteotomy can be used to position viable femoral head in the weightbearing zone.

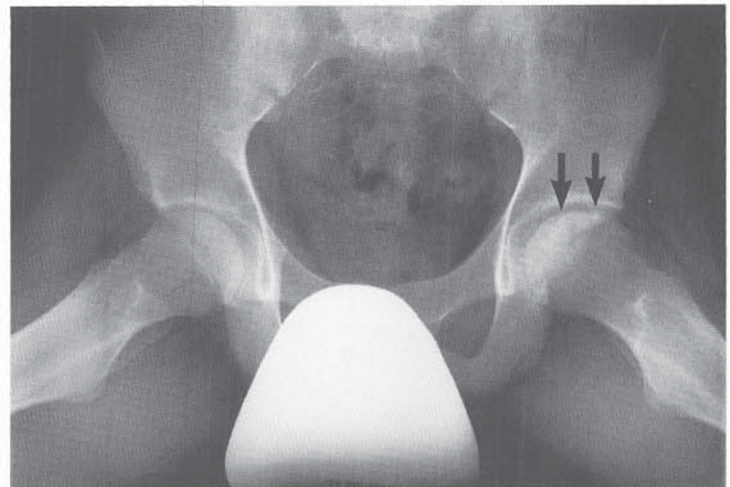
Sciatic nerve palsy is considered to be rare, but has been reported in up to 25 percent of posterior dislocations. All

instances occurred in older children and resulted from a high-energy injury, either automobile, motorcycle, or football trauma.³⁰ The sciatic nerve injuries are usually partial, and exploration of the nerve has been recommended in patients who have not demonstrated some recovery by 3 months. Pearson and Mann reported partial return of nerve function in four of five patients (one patient underwent nerve exploration at 3 months), with the fifth patient having a complete recovery.³⁰

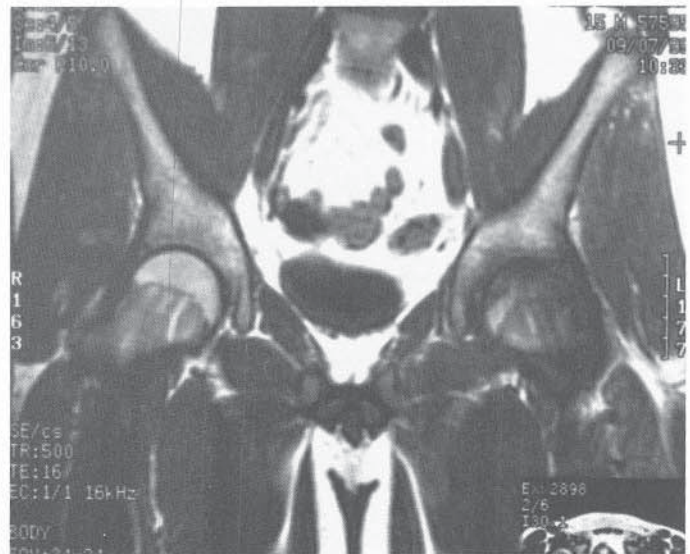
Recurrent hip dislocation is more common in children than in adults, and the reported cases in the literature are all posterior dislocations, usually in children less than 10 years old. No association has been demonstrated between



A



B



C

FIGURE 42-39 AVN following hip dislocation in a 15-year-old boy. A, Anterior hip dislocation. B, Radiographs obtained 6 months after the injury demonstrating AVN. C, MRI demonstrating partial femoral head AVN.

recurrence of a posterior dislocation and the severity of the injury or the type of immobilization used. Some have suggested that a minimum of 2 weeks of immobilization is required to allow the capsule to heal and thus lower the incidence of redislocation.^{10,18,36} Inadequate healing of the posterior capsule or attenuation of the posterior capsule accounts for the recurrent dislocation and can be treated by open surgical repair^{14,23,36,42,43} or by immobilization of the hip in 45 degrees of flexion and 20 degrees of abduction for 4 to 6 weeks.^{2,16,43} The evaluation of a recurrent hip dislocation should include CT to identify loose bodies within the joint and posterior acetabular or femoral head fractures that occurred at the time of the redislocation. CT arthrography is useful for identifying a redundant posterior capsule or residual posterior capsular defect, which is seen as dye leaks from the capsule.⁴² The lesions noted in adults at the time of reexploration of the hip are labral avulsions,^{23,27,33} a tear of the posterior capsule,^{22-24,39,41,42} or a markedly attenuated capsule.¹⁶ Operative repair of the torn capsule and a “Bankart-type” repair of the labrum should prevent further dislocation, although supplementation with a posterior bone

block has been described.^{23,24,33} If a redundant capsule is present, treatment consists of excision of the posterior pouch and repair of the capsular defect.

Degenerative arthritis after traumatic hip dislocation is infrequent in the pediatric population and is due to AVN of the femoral head. Predisposing factors may include a delay in reduction, the presence of cartilaginous loose bodies, acetabular labral tears, and a nonconcentric reduction due to trapped osteocartilaginous fracture fragments or an inverted limbus. When degenerative changes are noted it is important to look for signs of incomplete reduction. Treatment should be conservative and includes the use of anti-inflammatory medications, modification of activities, and weight control.

Vascular injury in anterior dislocations is a surgical emergency and requires prompt reduction of the hip followed by vascular repair.^{4,28,35} Examination of the peripheral pulses is extremely important in anterior dislocations and should be done at presentation, following reduction, and then serially over the next 24 to 48 hours. Another rare complication is injury to the triradiate cartilage, leading to a shallow

acetabulum and hip subluxation.⁴³ Treatment consists of physeal bar excision, if detected early, or acetabular reconstruction when identified late.

REFERENCES

Hip Dislocations

- Allis O: An Inquiry into the Difficulties Encountered in the Reduction of Dislocation of the Hip. Philadelphia, 1896.
- Barquet A: Traumatic hip dislocation with fracture of the ipsilateral femoral shaft in childhood: report of a case and review of the literature. *Arch Orthop Trauma Surg* 1981;98:69.
- Bigelow H: The Mechanics of Dislocation and Fracture of the Hip with the Reduction of the Dislocations by the Flexion Method. Philadelphia, Henry C Lea & Co, 1869.
- Bonnemaïson MF, Henderson ED: Traumatic anterior dislocation of the hip with acute common femoral occlusion in a child. *J Bone Joint Surg* 1968;50-A:753.
- Canale ST, Manugian AH: Irreducible traumatic dislocations of the hip. *J Bone Joint Surg* 1979;61-A:7.
- Choyce C: Traumatic dislocation of the hip in childhood and relation of trauma to pseudocoxalgia: analysis of 59 cases published up to Jan., 1924. *Br J Surg* 1924;12:52.
- Craig CL: Hip injuries in children and adolescents. *Orthop Clin North Am* 1980;11:743.
- Epstein HC: Traumatic dislocations of the hip. *Clin Orthop* 1973;92:116.
- Epstein HC, Wiss DA: Traumatic anterior dislocation of the hip. *Orthopedics* 1985;8:130.
- Freeman G: Traumatic dislocation of the hip children: a report of 7 cases and a review of the literature. *J Bone Joint Surg* 1961;43-A:401.
- Funk F: Traumatic dislocation of the hip in children: factors affecting prognosis and treatment. *J Bone Joint Surg* 1962;44-A:1135.
- Garcia Mata S, Hidalgo Ovejero A, Martinez Grande M: Open anterior dislocation of the hip in a child. *J Pediatr Orthop B* 1998;7:232.
- Gartland JJ, Benner JH: Traumatic dislocations in the lower extremity in children. *Orthop Clin North Am* 1976;7:687.
- Gaul RW: Recurrent traumatic dislocation of the hip in children. *Clin Orthop* 1973;90:107.
- Glass A, Powell H: Traumatic dislocation of the hip in children. *J Bone Joint Surg* 1961;43-B:29.
- Graham B, Lapp RA: Recurrent posttraumatic dislocation of the hip: a report of two cases and review of the literature. *Clin Orthop* 1990;256:115.
- Haliburton R, Breckenshire F, Barber J: Avascular necrosis of the femoral capital epiphysis after traumatic dislocation of the hip in children. *J Bone Joint Surg* 1961;43-B:43.
- Heinzelmann PR, Nelson CL: Recurrent traumatic dislocation of the hip: report of a case. *J Bone Joint Surg* 1976;58-A:895.
- Huo MH, Root L, Buly RL, et al: Traumatic fracture-dislocation of the hip in a 2-year-old child. *Orthopedics* 1992;15:1430.
- Klasen HJ, Binnendijk B: Fracture of the neck of the femur associated with posterior dislocation of the hip. *J Bone Joint Surg* 1984;66-B:45.
- Libri R, Calderon JE, Capelli A, et al: Traumatic dislocation of the hip in children and adolescents. *Ital J Orthop Traumatol* 1986;12:61.
- Liebenberg F, Dommissie GF: Recurrent post-traumatic dislocation of the hip. *J Bone Joint Surg* 1969;51-B:632.
- Lieberman JR, Altchek DW, Salvati EA: Recurrent dislocation of a hip with a labral lesion: treatment with a modified Bankart-type repair. Case report. *J Bone Joint Surg* 1993;75-A:1524.
- Lutter L: Post-traumatic hip redislocation. *J Bone Joint Surg* 1973;55-A:391.
- Mass DP, Spiegel PG, Laros GS: Dislocation of the hip with traumatic separation of the capital femoral epiphysis: report of a case with successful outcome. *Clin Orthop* 1980;146:184.
- Moore A: The Moore self-locking vitallium prosthesis in fresh femoral neck fractures: a new low posterior approach (the Southern exposure). American Academy of Orthopaedic Surgeons Instructional Course Lectures, vol 16. St. Louis, CV Mosby Co, 1959.
- Nelson C: Traumatic recurrent dislocation of the hip. *J Bone Joint Surg* 1970;55-A:128.
- Nerubay J: Traumatic anterior dislocation of the hip joint with vascular damage. *Clin Orthop* 1976;116:129.
- Patterson I: The torn acetabular labrum: a block to reduction of a dislocated hip. *J Bone Joint Surg* 1957;39-B:306.
- Pearson DE, Mann RJ: Traumatic hip dislocation in children. *Clin Orthop* 1973;92:189.
- Pennsylvania Orthopaedic Society: Traumatic dislocation of the hip joint in children: final report by the Scientific Research Society. *J Bone Joint Surg* 1968;50-A:79.
- Proctor H: Dislocations of the hip joint (excluding "central" dislocations) and their complications. *Injury* 1973;5:1.
- Rashleigh-Belcher H, Cannon S: Recurrent dislocation of the hip with a "Bankart-type" lesion. *J Bone Joint Surg* 1956;68-B:398.
- Schlonsky J, Miller PR: Traumatic hip dislocations in children. *J Bone Joint Surg* 1973;55-A:1057.
- Schwartz DL, Haller JA Jr: Open anterior hip dislocation with femoral vessel transection in a child. *J Trauma* 1974;14:1054.
- Simmons RL, Elder JD: Recurrent posttraumatic dislocation of the hip in children. *South Med J* 1972;65:1463.
- Stewart M, Milford L: Fracture dislocation of the hip. *J Bone Joint Surg* 1954;36-A:315.
- Stimson L: Treatise on Dislocation. Philadelphia, Lea Brothers & Co, 1888.
- Sullivan C, Bickel W, Lopscomb P: Recurrent dislocation of the hip. *J Bone Joint Surg* 1955;37-A:1266.
- Thompson S: Traumatic dislocation of the hip. In Proceedings of the Sheffield Regional Orthopaedic Club. *J Bone Joint Surg* 1951;42-B:858.
- Townsend R, Edwards G, Bazant F, et al: Posttraumatic recurrent dislocation of the hip without fracture. *J Bone Joint Surg* 1969;51-B:194.
- Weber M, Ganz R: Recurrent traumatic dislocation of the hip: report of a case and review of the literature. *J Orthop Trauma* 1997;11:382.
- Wilchinsky ME, Pappas AM: Unusual complications in traumatic dislocation of the hip in children. *J Pediatr Orthop* 1985;5:534.

HIP FRACTURES

Compared with hip fractures in adults, hip fractures in children are relatively rare, accounting for less than 1 percent of all pediatric fractures. The vast majority of hip fractures in children, 80 to 90 percent, are due to high-energy trauma; the rest are due to moderate trauma or pathologic conditions.

Hip fractures are classified according to their anatomic location, with femoral neck fractures (transcervical or cervicotrochanteric) being the most common. The treatment of most hip fractures in children consists of closed or open reduction and internal fixation, followed by a period of external immobilization. Despite advances in operative technique and more aggressive treatment, the rate of complications from pediatric hip fractures (AVN, coxa vara, premature physeal closure, malunion, nonunion) remains relatively high.

Anatomy. The proximal femur consists of a single physis at birth that later separates into two distinct centers of ossification—the capital epiphysis and the trochanteric apophysis. Ossification of the femoral epiphysis occurs between 4 and 6 months of age, and the ossific nucleus (Fig. 42–40) of the greater trochanter appears at 4 years. The femoral neck-shaft angle is 135 degrees at birth, increases to approximately 145 degrees by 1 to 3 years of age, and gradually matures to an angle of 130 degrees at skeletal maturity.^{18,48,58} Femoral anteversion at birth is approximately 30 degrees, decreasing to an average of 10.4 degrees at skeletal maturity.^{47,58} The trochanteric physis closes between 16 and 18 years and the proximal femoral physis closes at

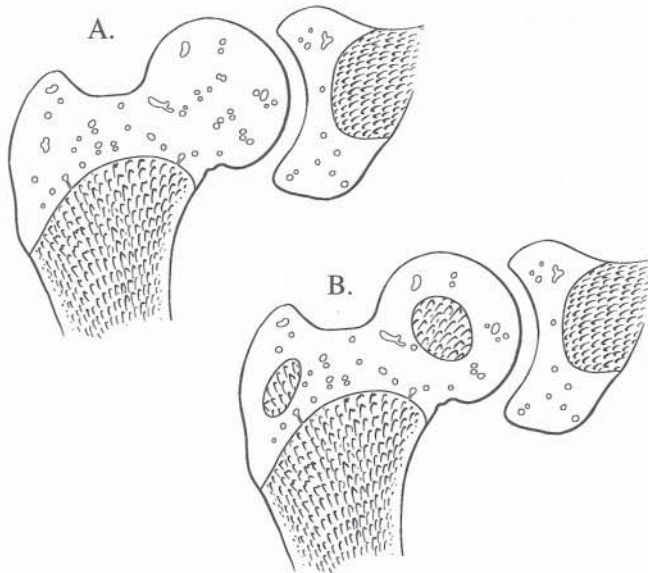


FIGURE 42-40 A, The proximal femoral epiphysis is a single physis at birth. B, At approximately age 4 years, the single growth center divides into a separate greater trochanteric and femoral head growth center. Note the two secondary centers of ossification.

approximately 18 years. Growth arrest of the proximal femoral physis prior to skeletal maturity may result in an abnormal neck-shaft angle, femoral anteversion, and a reduced articulothoracic distance (Fig. 42-41). In addition, since the proximal femoral physis contributes approximately 15 percent of the growth of the entire extremity, mild limb length discrepancy may occur.

Because of the high incidence of AVN of the femoral head, the vascular anatomy of the proximal femur is important to understand. It has been extensively studied by Chung,¹¹ Ogden,³⁸ and Trueta.⁵⁶ The blood supply of the proximal femur comes from two major branches of the profunda femoris artery—the medial and lateral circumflex arteries, which originate at the level of the tendinous portion of the

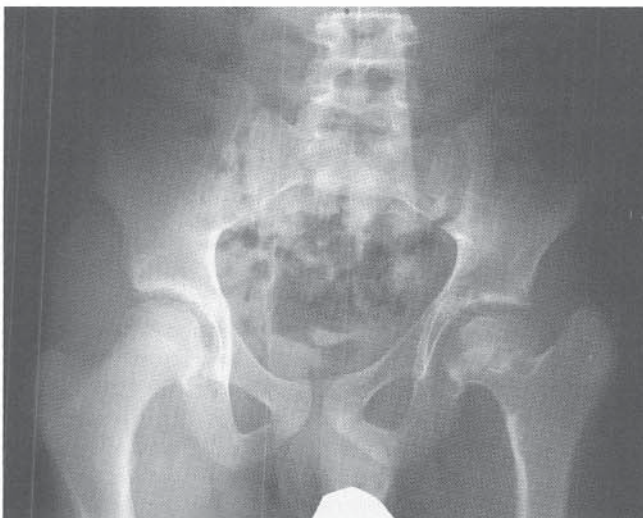


FIGURE 42-41 Proximal physeal growth arrest following a transcervical left hip fracture, with subsequent coxa breva, coxa magna, and a decreased articulothoracic distance.

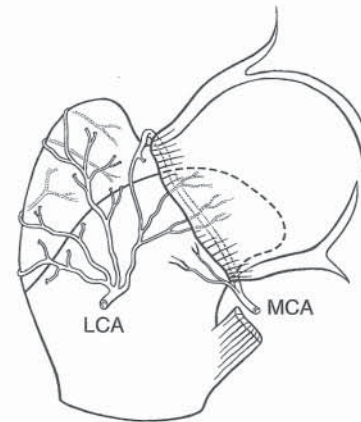


FIGURE 42-42 The femoral head blood supply from the medial and lateral circumflex arteries, branches of the deep femoral artery at the level of the tendinous portion of the iliopsoas muscle.

iliopsoas muscle (Fig. 42-42). The lateral circumflex artery travels posterior to the femoral neck and the medial circumflex artery travels anterior to it. The transverse branch of the lateral circumflex artery divides at the anterolateral border of the intertrochanteric line, giving off branches that penetrate the lateral and anterolateral portions of the greater trochanter. Until the age of 5 to 6 months this branch also supplies much of the anterior portion of the proximal femoral epiphysis and physis.

The major blood supply to the proximal femur comes from the medial circumflex artery, which travels posterior to the iliopsoas tendon, then travels to the medial side of the proximal femur between the inferomedial capsular insertion and the lesser trochanter. Two major branches of the medial circumflex artery are then given off—the posterior inferior branch, which travels along the inferior margin of the posterior neck, and the posterior superior branch, which travels along the superior margin.

At birth the lateral circumflex artery supplies the anterolateral growth plate, the major aspect of the greater trochanter, and the anteromedial aspect of the femoral head. The medial circumflex artery branches to provide blood to the posteromedial proximal epiphysis, the posterior physis, and the posterior aspect of the greater trochanter. The artery of the ligamentum teres supplies a small area of the medial femoral head. Blood vessels, which cross the physis at birth, gradually disappear by age 15 to 18 months, at which time no vessels are observed crossing the growth plate.

By the age of 3 years the contribution of the lateral circumflex vessel to the blood supply of the proximal femur diminishes and the entire blood supply of the proximal femoral epiphysis and physis comes from the lateral epiphyseal vessels, branches derived from the medial circumflex artery (Fig. 42-43). The posterosuperior and posteroinferior vessels were both thought to have prominent roles in the blood supply to the femoral head by Ogden,³⁸ although Trueta and Morgan⁵⁷ felt that the lateral cervical ascending artery (posterosuperior branch) played a more significant role. These vessels lie external to the joint capsule at the level of the intertrochanteric line and then traverse the capsule and travel proximally within retinacular folds. Very few vessels supplying the femoral head travel within the capsule,

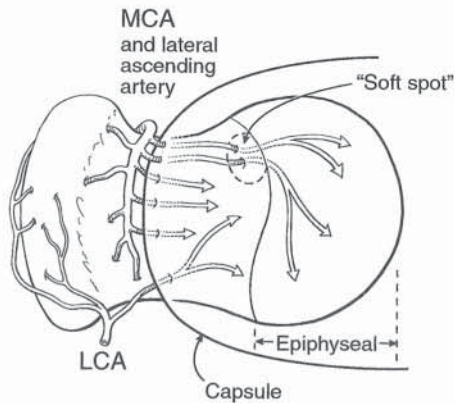


FIGURE 42-43 The medial and lateral circumflex vessels as they enter the femoral head. The major blood supply comes from the lateral cervical ascending artery, a branch of the medial circumflex artery.

and therefore a capsulotomy incision should not compromise the vascularity of the femoral head.³⁸ This arrangement of the blood supply to the femoral head persists into adulthood. The artery of the ligamentum teres, a branch of the obturator (80 percent) or the medial circumflex (20 percent), provides approximately 20 percent of the blood supply to the femoral head beginning at approximately 8 years of age and is maintained into adulthood.^{38,57}

Classification. Fractures of the hip in children are classified into four types based on the anatomic location of the fracture as described by Delbet¹⁶ and later popularized by Colonna¹³ (Fig. 42-44):

Type I: Transepiphyseal—an acute traumatic separation

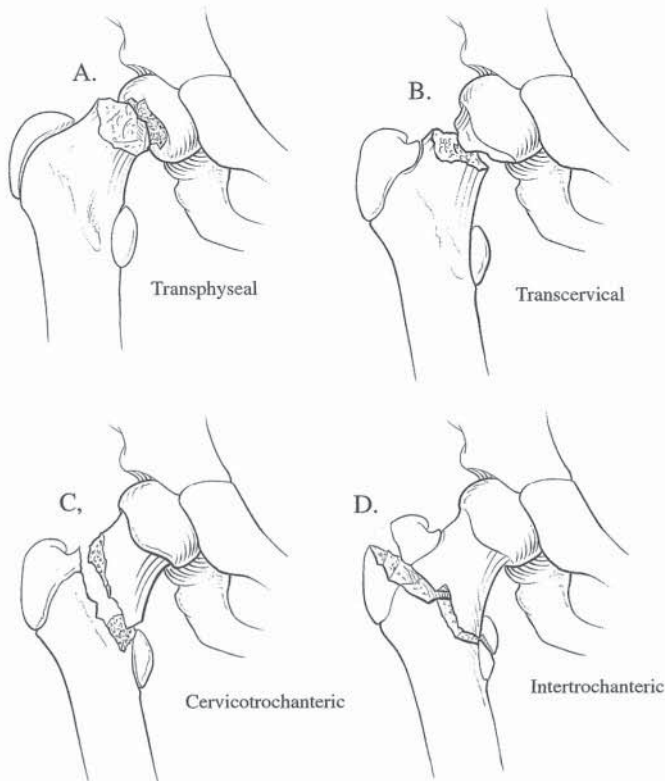


FIGURE 42-44 Delbet's classification of children's hip fractures: A, transphyseal; B, transcervical; C, cervicotrochanteric; D, intertrochanteric.

of a previously normal physis (Fig. 42-45). This type of fracture accounts for less than 10 percent of all children's hip fractures. In 13 reported series, 43 (8 percent) of 511 hip fractures in children were type I.* Anatomically, it is similar to the type I physeal injury of Salter and Harris and can be distinguished from a slipped capital femoral epiphysis (SCFE) by the younger age of the patient (8 to 9 years), the usually sudden onset of pain secondary to severe trauma, and radiographs showing a more displaced acute separation of the physis. This injury predominantly occurs in two age groups: young infants (less than 2 years old)^{20,22,30,39} and children ages 5 to 10.^{27,45} In the newborn, it is known as proximal femoral epiphysiolysis and follows breech delivery, and may be mistaken for congenital dislocation of the hip. It is usually recognized late (more than 2 weeks), following the formation of abundant callus.^{39,62} It has also been described in the adolescent patient following an attempted closed reduction of a posterior hip dislocation.^{19,26}

The mechanism of injury is usually severe trauma, often being struck by a car⁴⁴ or a falling from a height, but it has also been reported in victims of child abuse^{20,22} and during difficult labor.²⁵ It is associated with femoral head dislocation in approximately 50 percent of cases.^{8,20,21,26} Associated injuries occur in up to 60 percent of cases, with pelvic fractures, often bilateral, being the most common.⁴⁴ The results of treatment are relatively poor, with a reported incidence of AVN of the femoral head between 20 and 100 percent.^{7,27,29,45}

Type II: Transcervical—a fracture through the midportion of the femoral neck (Fig. 42-46). This is the most common fracture type, accounting for 40 to 50 percent of hip fractures. In the literature, 229 (45 percent) of 511 hip fractures in children were type II.† These fractures are the result of severe trauma, and the majority (70 to 80 percent) are displaced at the time of presentation. The most common complication is AVN, which has historically been reported to be up to 50 percent.^{8,27,29,45} However, recent studies that have relied on more aggressive treatment, including evacuation of the intracapsular hematoma, have reported a significant reduction in the incidence of AVN.^{6,9,54} The best predictor for developing AVN is displacement of the fracture at the time of injury.⁴⁵ Other complications, including loss of reduction, malunion, nonunion, varus deformity, and premature epiphyseal closure, result in relatively poor outcomes when compared with the outcomes of type III and IV fractures.

Type III: Cervicotrochanteric—a fracture through the base of the femoral neck (Fig. 42-47). The reported incidence is between 25 and 35 percent. Of 511 hip fractures, 171 (33 percent) were type III.‡ AVN occurs in approximately 20 to 25 percent of cases and is related to the amount of displacement at the time of the injury.

Type IV: Pertrochanteric or intertrochanteric—a fracture between the greater and lesser trochanter (Fig. 42-48). The reported incidence is between 6 and 15 percent. Of 511 hip fractures, 68 (13 percent) were type IV.§ AVN occurs infrequently (less than 10 percent), and these fractures have the best overall outcome.

*See references 8-10, 15, 23, 25, 27, 29, 40, 42, 45, 54, 59.

†See references 8-10, 15, 23, 25, 27, 29, 40, 42, 45, 54, 59.

‡See references 8-10, 15, 23, 25, 27, 29, 40, 42, 45, 54, 59.

§See references 8-10, 15, 23, 25, 27, 29, 40, 42, 45, 54, 59.

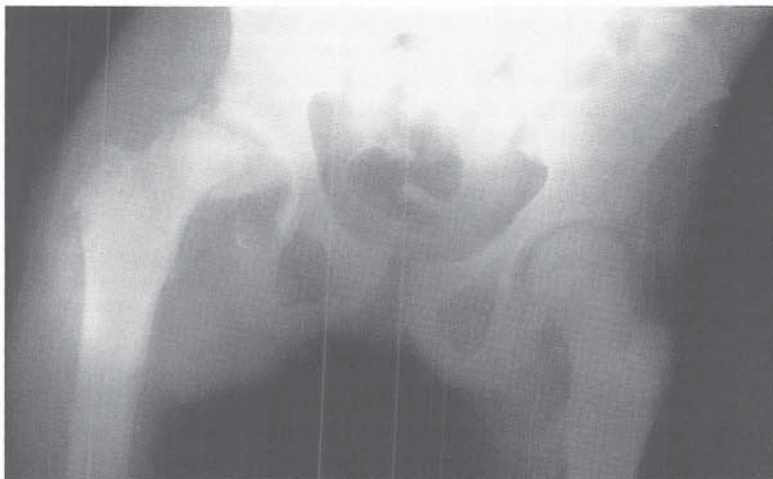


FIGURE 42–45 Transphyseal hip fracture in a 10-year-old child with posterior dislocation of the epiphysis.

Hip fractures that do not fit into the Delbet classification include fractures of the proximal metaphysis in newborns and stress fractures. Proximal metaphyseal fractures will often be confused with a dislocation of the hip since the capital femoral and greater trochanteric epiphyses are not yet ossified (Fig. 42–49). Stress fractures of the femoral neck have been reported in less than 20 cases in the literature; the child presents with a history of a minor injury and vague hip pain.^{32,51,53,63} The fracture is often missed on the initial presentation, which may lead to displacement requiring operative intervention (Fig. 42–50).^{53,63}

Mechanism of Injury. Hip fractures in children are most often the result of severe high-energy trauma (a fall from a height, a motor vehicle accident, or a fall from a bicycle). Such mechanisms account for approximately 85 to 90 percent of all fractures.* This differs significantly from the situation in the elderly adult population, in which hip fractures are common and result from minimal trauma, most commonly a fall. Because of the severe energy required to produce these fractures, associated major injuries are seen in up to 30 percent of cases.^{29,45} Intra-abdominal or intrapelvic visceral injuries and head injuries are the most common associated injuries.⁴⁵ Other musculoskeletal injuries are seen less often and include hip dislocations, and pelvic and femoral shaft fractures.^{19,26} Because of these associated injuries, any child who presents with a hip fracture must be carefully evaluated. A small fraction of patients sustain hip fractures from trivial trauma, often associated with a pathologic lesion in the area of the fracture. The most common preexisting conditions include a unicameral bone cyst, osteogenesis imperfecta, fibrous dysplasia, myelomeningocele, and osteopenia from previous polio.^{7,27,29,59} Finally, child abuse may cause hip fractures in children less than 12 months of age.^{22,59}

Diagnostic Features. The patient initially presents after a severe traumatic event with complaints of severe pain in the hip. The history should include the mechanism of injury and a description of other areas of pain. Because of the severity of the hip pain, the patient may not provide a good description of other painful areas, and therefore the examiner must take care to rule out associated injuries. On the other hand, other severe injuries can obscure the

diagnosis of a hip fracture. Lam reported 75 hip fractures in children, 15 of which were first diagnosed after a period ranging from 1 week to 8 months.²⁹ One of the principal reasons for a missed diagnosis was the presence of a more serious concomitant injury overshadowing the hip fracture. Undisplaced hip fractures and stress fractures, which occur in approximately 30 percent of cases,^{25,45} may not present with severe pain. The patient may be ambulating at the time of evaluation following a “twisting” or “sprain” of the hip from a slip or athletic mishap.^{32,51,53,63}

On physical examination, the patient with a displaced hip fracture will hold the injured limb laterally rotated and slightly adducted, and the limb will appear shortened. The patient is in severe pain and is unable to actively move the limb. If a dislocation is present, the extremity is held in flexion, adduction, and internal rotation. Local tenderness is elicited on palpation and is most severe posteriorly over the femoral neck. Passive motion of the extremity is markedly restricted, especially with flexion, abduction, and medial rotation. In a nondisplaced fracture the hip examination may not be very remarkable, with very mild discomfort elicited during passive range of motion of the extremity. In addition, the patient may be able to ambulate with very

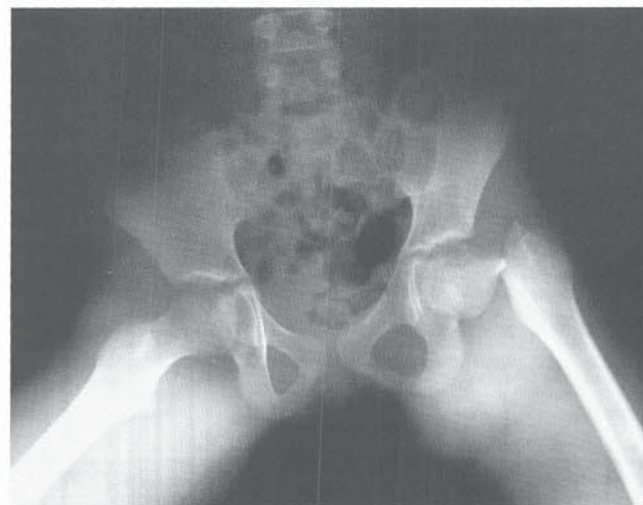


FIGURE 42–46 Transcervical or femoral neck fracture.

*See references 7, 15, 23, 25, 27, 29, 42, 45, 59.

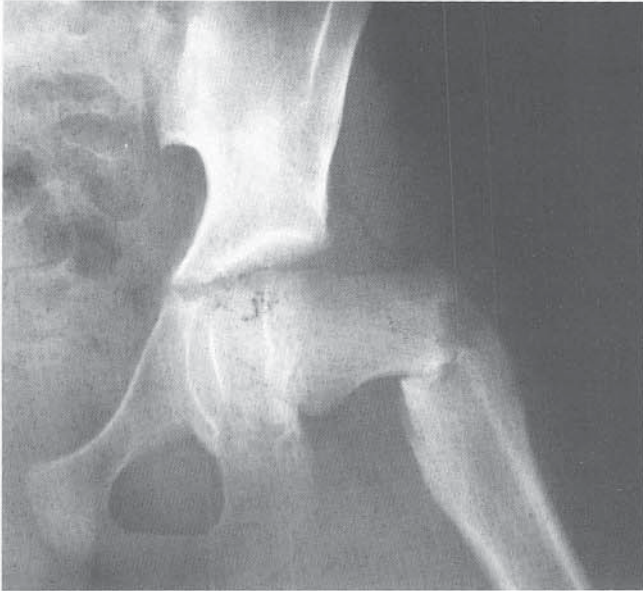


FIGURE 42–47 Left cervicotrochanteric hip fracture in a 9-year-old child.

little pain. A careful, detailed history, physical examination, and radiographic evaluation are important in these patients to avoid missing the diagnosis.

Radiologic Examination. The radiographic evaluation consists of AP and lateral images of the hip. The radiographs should be analyzed for the type of fracture (Delbet classification), the direction of the fracture line, the amount of displacement, the degree of varus, and the location of the femoral epiphysis. Comparison views of the other hip may assist the surgeon in determining whether a nondisplaced

fracture of the femoral neck is present. Such a determination is best done by inspecting the proximal femur for any disruption in the normal trabecular pattern. Nondisplaced or stress fractures can be confirmed with radioisotope bone scanning with pinhole magnification.^{14,32,53} Bone scan imaging must be delayed somewhat from the time of the initial injury to allow increased bone metabolism to occur at the fracture site to avoid false negative examinations. (In the elderly, the general recommendation is to wait 48 to 72 hours from the time of injury.) Although no data exist on the time delay required in the child or adolescent, we recommend delaying bone scan imaging for 24 to 36 hours following injury. MRI is the best imaging modality for the nondisplaced or stress fracture of the femoral neck, providing greater accuracy, earlier diagnosis, and shorter hospital stay, with no exposure to radiation.^{4,14,24,49–52} MRI will demonstrate decreased signal on a spin-echo T1 image and a correspondingly increased signal due to edema or bleeding on the T2-weighted images.⁵¹ An additional advantage of MRI over other imaging modalities is that additional information can be obtained, including femoral head viability and the presence of associated bone cysts.

Treatment. Improvements in surgical techniques and more aggressive treatment have resulted in improved outcomes in children's hip fractures.^{7,8} The most important factors to consider before initiating treatment are the age of the child, the type of hip fracture, the amount of fracture displacement, and the angle of the fracture line. Results in young children (less than 8 years old) with nondisplaced fractures or type III or IV fractures are better than those in older children with a displaced type I or II fracture.

The goals of treatment of children's hip fractures are to achieve anatomic reduction and to provide stability to the

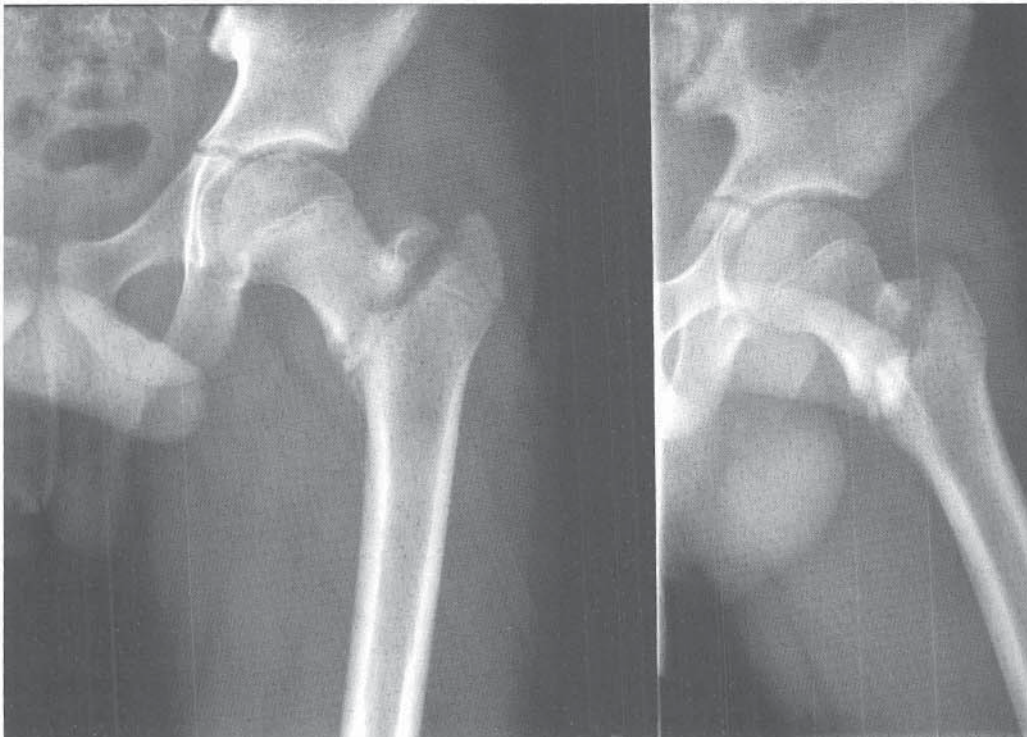


FIGURE 42–48 Left intertrochanteric hip fracture in a 10-year-old child.

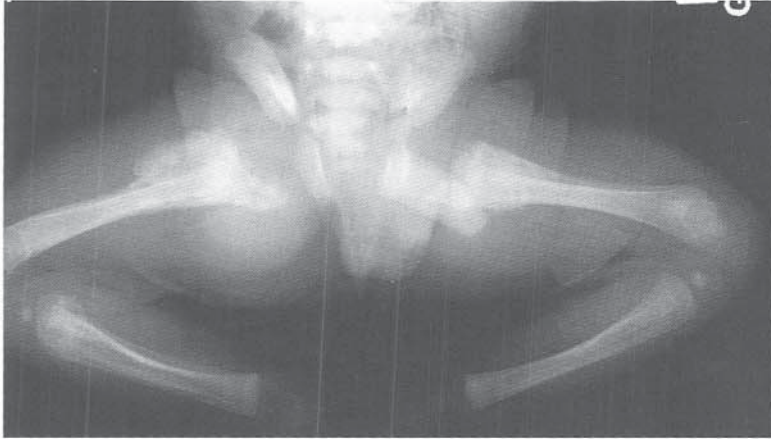


FIGURE 42-49 Proximal femoral metaphyseal fracture in a young infant, demonstrating abundant callus formation. Note the multiple fractures in this child abuse case.

fracture fragments in order to maintain the reduction and allow complete fracture healing. In general, these goals are best achieved in the operating room, with fracture reduction performed under fluoroscopic guidance and fracture stabilization achieved with rigid internal fixation. Hip spica casting should be used in most children's hip fractures (in addition to internal fixation) to immobilize the extremity and allow complete and solid fracture healing. It is occasionally used as the definitive treatment in small children, in children with minimally displaced cervicotrochanteric and intertrochanteric fractures, and in children with a stress fracture of the femoral neck.

Specific treatment plans are described below for each fracture type.

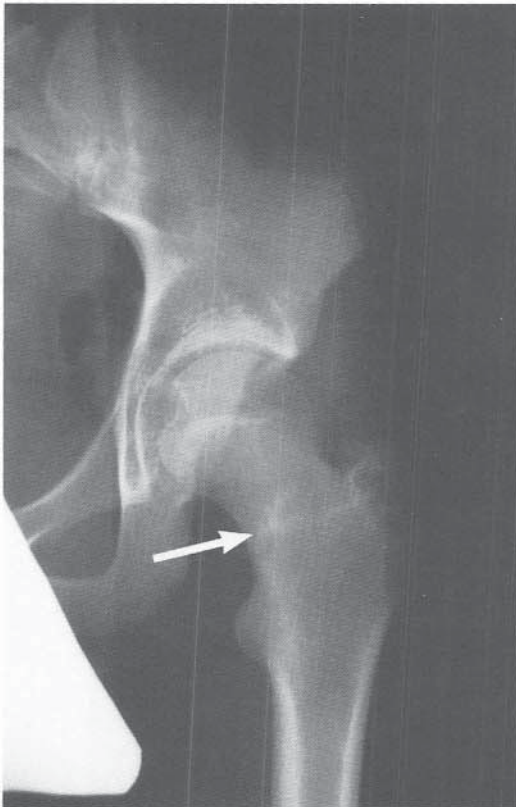


FIGURE 42-50 Stress fracture of the femoral neck.

TYPE I: TRANSEPIPHYSEAL FRACTURES. Historically, transepiphyseal fractures have been associated with a high rate of complications, including loss of reduction and subsequent varus angulation, AVN of the femoral head, and premature epiphyseal closure. The literature reports loss of reduction with resultant varus deformity in approximately 35 percent of transepiphyseal fractures when treated with cast immobilization. Although the rate of AVN is most dependent on the amount of displacement at the time of the injury, loss of reduction can be a contributing factor and should be limited by stable internal fixation (Fig. 42-51). We recommend an anatomic reduction with rigid internal fixation followed by cast immobilization. It is important to determine whether the femoral epiphysis is reduced within the acetabulum on the initial radiographs. If the epiphysis is within the acetabulum, a gentle closed reduction similar to that done for a SCFE is performed, since the neck is displaced anterior to the epiphysis. The hip is slowly flexed, slightly abducted, and internally rotated while the surgeon observes the fracture under fluoroscopy. Once an anatomic reduction is achieved, internal fixation should be performed through a small lateral incision. In a young child (less than 4 years old) we recommend smooth Kirschner wires, 4.0-mm cannulated screws in the child 4 to 7 years, and 5.0- to 6.5-mm cannulated screws in the older child. To limit the risk of premature physeal closure, threads from wires or screws should not be crossing the physis at the completion of the procedure.

If the femoral epiphysis is dislocated from the acetabulum, we recommend a single attempt at a closed reduction. However, the likelihood of achieving a closed reduction in this situation is small. Multiple attempts may predispose to AVN and are not recommended. Canale reported failure of closed reduction in four of five patients with a type I fracture in which the epiphysis was dislocated from the acetabulum; all five children eventually developed AVN.⁸ Therefore, an open reduction should be performed initially in this setting or following a single attempt at a gentle closed reduction. The majority of fracture dislocations occur posteriorly and should be approached with a modified Southern (Moore) approach, while an anterior fracture-dislocation requires an anterior (Smith-Peterson) approach. The obstacles to reduction are similar to a typical hip dislocation (see discussion in Chapter 15, Developmental Dysplasia of the Hip). A separate lateral incision is then made and the fracture is stabilized with rigid internal fixation.

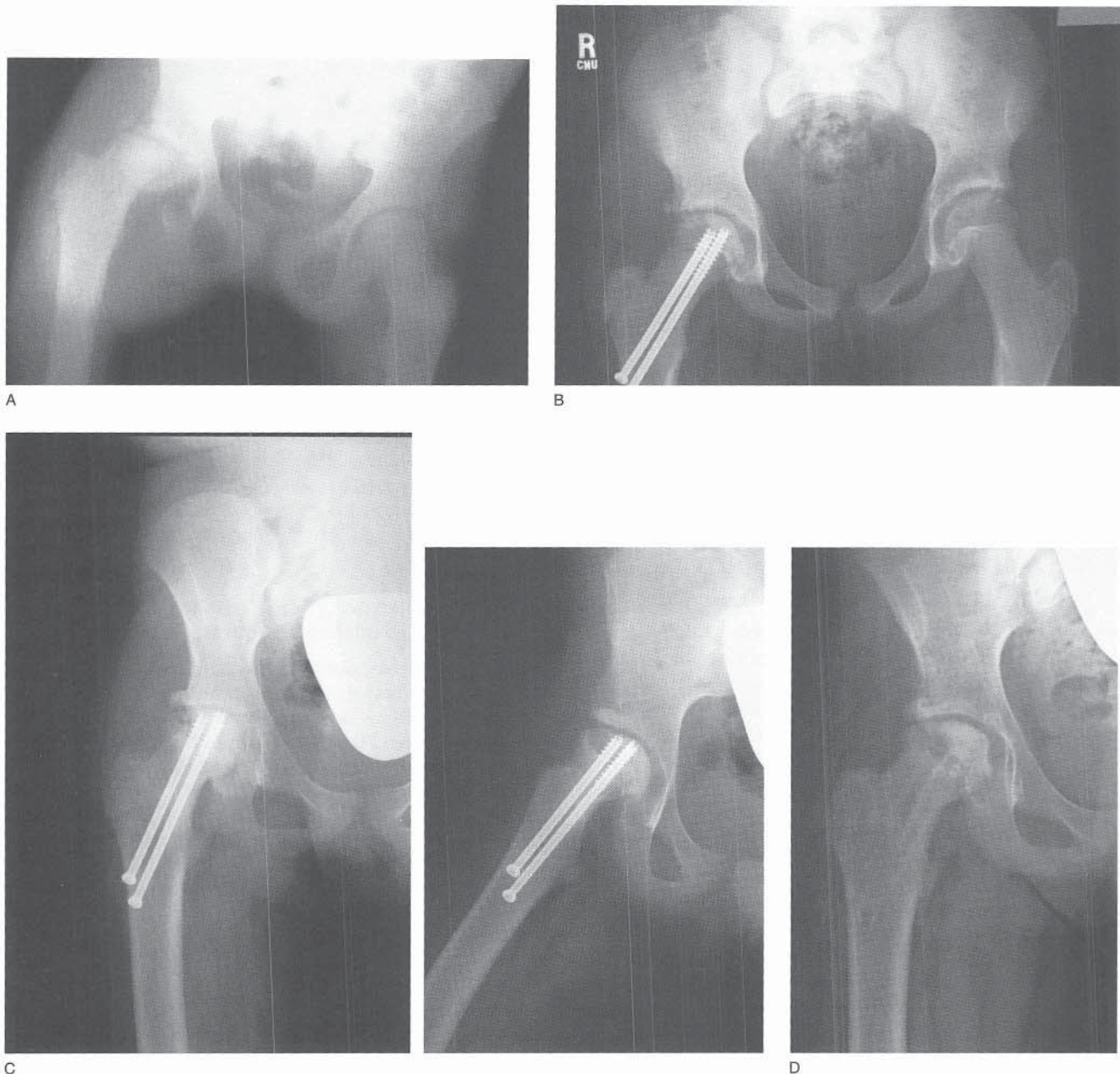
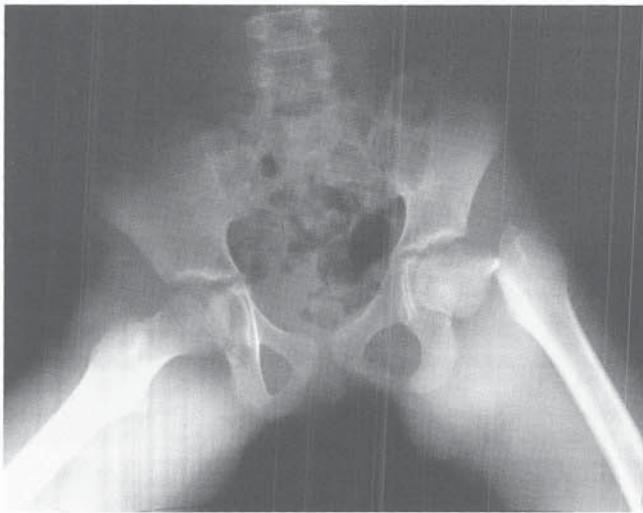


FIGURE 42-51 Transphyseal fracture in a 10-year-old that was treated with internal fixation and casting. A, Type I fracture-dislocation. B, Radiographic appearance after posterior open reduction and internal fixation. C, Four months following injury, there was evidence of AVN. D, Radiographic appearance after screw removal.

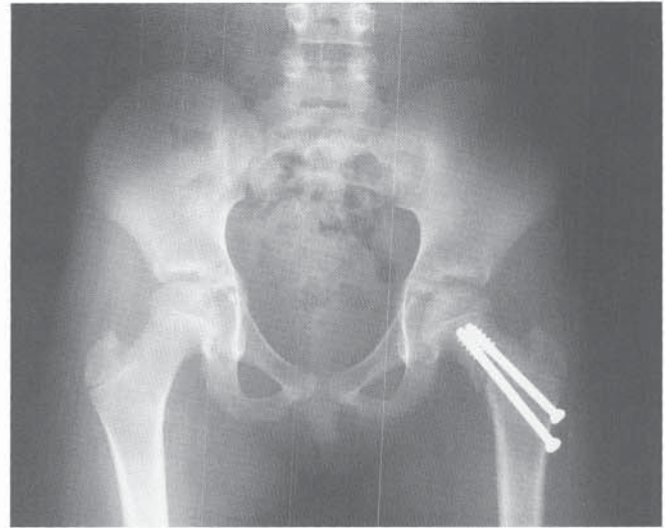
We recommend cast immobilization in a one-and-one-half hip spica cast in all patients following either a closed or open reduction and internal fixation. The hip should be positioned in approximately 30 degrees of abduction, neutral extension, and 10 degrees of internal rotation for a minimum of 6 weeks, and up to 12 weeks in the older child if fracture union is delayed. Some surgeons advocate cast immobilization as the principal mode of stabilization in the child less than 18 months old with a transepiphyseal separation, since more remodeling potential exists in this age group. However, Forlin and colleagues described five patients with an average age of 15 months with severely displaced transepiphyseal separations who were treated by closed reduction and cast im-

obilization only.²⁰ All five patients developed varus angulation; three patients required a valgus femoral osteotomy, and in the remaining two patients the varus deformity remodeled. We recommend this treatment in a patient less than 2 years old with minimal or no displacement which does not require manipulation at the time of treatment.

TYPE II: TRANSCERVICAL FRACTURES. We recommend that all transcervical fractures (including the nondisplaced fracture) in children of all ages be treated by stable internal fixation to avoid loss of reduction and subsequent malunion, and delayed union or nonunion (Fig. 42-52). These complications are much more common when fractures are stabilized by external immobilization alone.^{25,29,45} Anatomic reduction must



A



B

FIGURE 42-52 Transcervical fracture treated with internal fixation and casting. **A**, Injury radiographs of a displaced transcervical hip fracture. **B**, Radiographic appearance after open reduction and internal fixation. Note that the fixation stays distal to the physis.

be achieved to help prevent nonunion, and, although not proven, it may diminish the risk of developing AVN. A gentle closed reduction should be attempted under fluoroscopic guidance. The closed reduction maneuver was described in the 1890s by Whitman, who felt that an anatomic alignment was mandatory to prevent future deformity.^{60,61} The reduction consists of first, fully abducting the normal hip to stabilize the pelvis, followed by progressive abduction of the extended affected hip. The surgeon then places downward pressure on the greater trochanter and uses the upper border of the acetabular rim as a fulcrum to restore the normal relationship of the proximal femur while the hip is abducted (Fig. 42-53). During abduction of the hip, the extremity is internally rotated to 20 to 30 degrees to complete the reduction maneuver. Once reduction is achieved the extremity should be slowly adducted to allow placement of internal fixation through a lateral approach. If closed manipulation fails to achieve anatomic reduction, an open reduction through an anterior or anterolateral approach must be performed (Fig. 42-54). Once reduction is achieved the fracture should be stabilized with threaded Kirschner wires in the young child and cannulated screws in the older child. Internal fixation devices should be kept distal to the physis; however, fracture stability is of prime importance and should not be compromised in an attempt to avoid the growth plate (Fig. 42-55). In the older child a minimum of two screws should be placed parallel to one another and in a lag-type fashion, with screw threads in the proximal fracture fragment producing compression across the fracture site. To avoid fracture displacement, we recommend having two guide wires in place while the third guide wire is overdrilled, tapped, and then used as a guide for screw placement.

Cast immobilization in a one-and-one-half hip spica cast is recommended postoperatively for 6 to 12 weeks until good healing callus is seen. Although still controversial, there is increasing evidence that hip decompression through needle aspiration of the hip joint results in a lower incidence of AVN in type II hip fractures.^{9,35,54} Needle aspiration through a sub-

adductor approach has little risk and should be done following reduction and internal fixation (Fig. 42-56).

TYPE III: CERVICOTROCHANTERIC FRACTURES. Although type III fractures have a better overall outcome than type II fractures, the displaced fracture has equally poor results.^{8,29}

We recommend that the displaced fracture be treated by closed reduction and internal fixation in all age groups. Non-

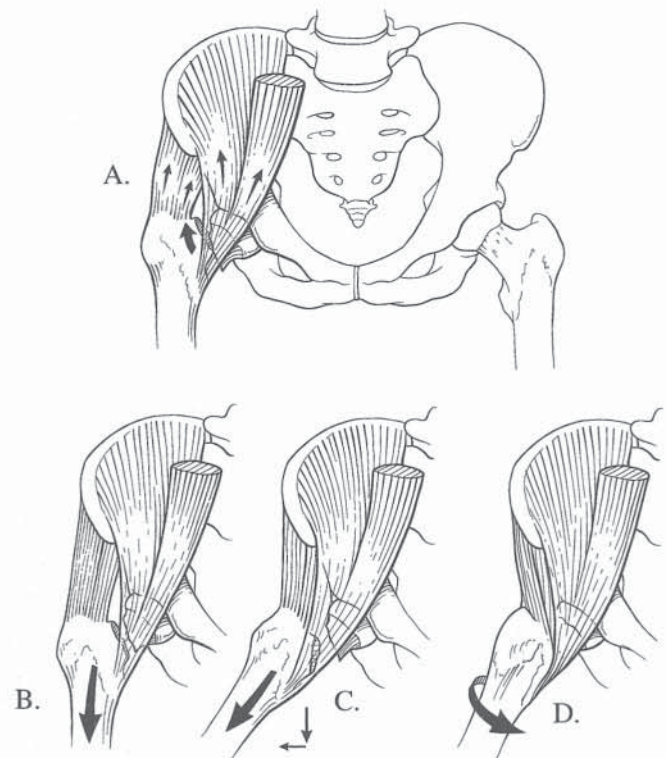


FIGURE 42-53 Closed reduction maneuver to reduce a femoral neck fracture. In-line traction (**A** and **B**) is followed by progressive abduction (**C**) and internal rotation (**D**).

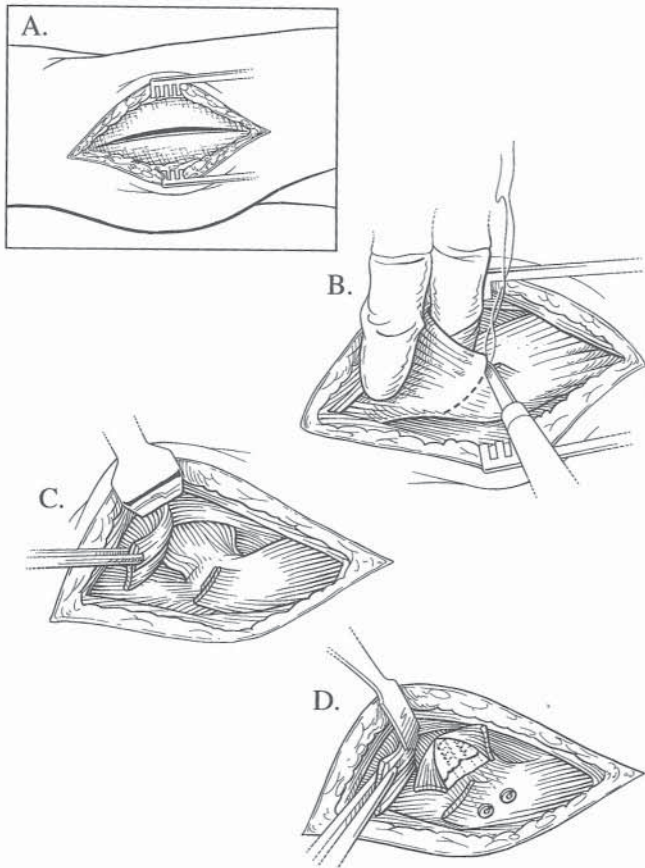


FIGURE 42-54 Open reduction and internal fixation of a femoral neck fracture using an anterolateral approach. A, The lateral incision is made and the tensor fasciae latae is incised. B and C, The gluteus medius and minimus are incised at their tendinous portions and retracted proximally as one layer to allow reapproximation. D, The capsule is opened. The fracture is reduced and fixed with two cannulated screws.

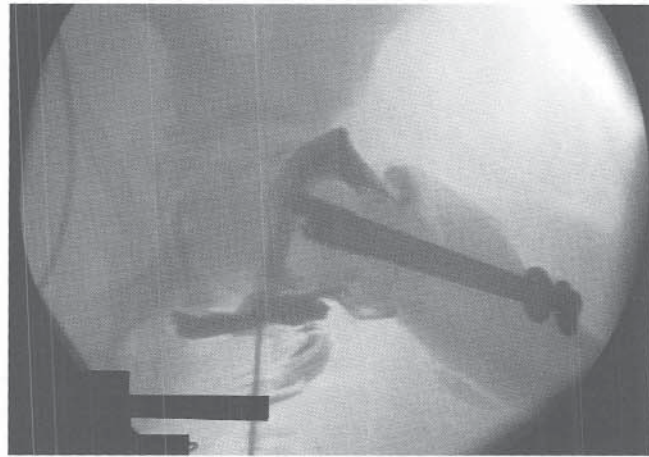


FIGURE 42-56 Arthrogram of the hip to ensure needle presence in the joint followed by aspiration following a closed reduction and screw fixation of a basicervical hip fracture in a 10-year-old child.

displaced fractures in the older child (more than 6 years old) also should have internal fixation (Fig. 42-57). Although some have recommended closed reduction and abduction spica casting without internal fixation, varus deformity develops in 65 to 85 percent of cases so treated. Undisplaced fractures in the child less than 6 years old may be treated with an abduction cast. In the child less than 6 years old, with a displaced fracture, a closed reduction and hip spica casting may stabilize the fracture, but maintenance of the reduction relies on the position of the extremity and the molding of the cast. In most cases we prefer the stability of internal fixation. In addition, because of the distal location of this fracture relative to the physis, internal fixation with cannulated screws or Kirschner wires is technically easier than in the type II fracture. However, the distal location of the fracture may not afford good purchase for cannulated screws, resulting in loss of

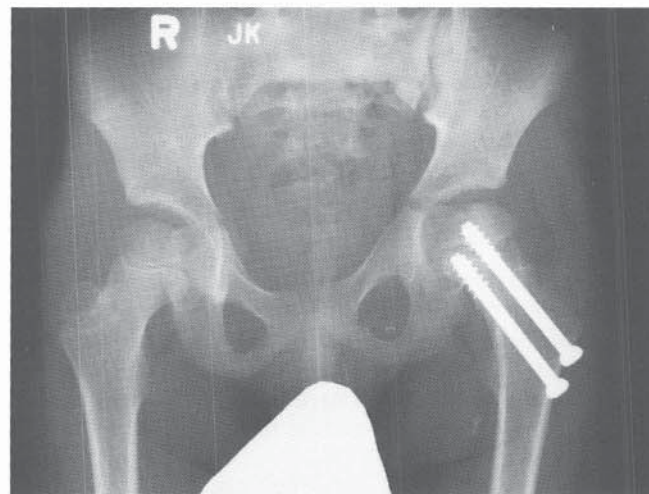
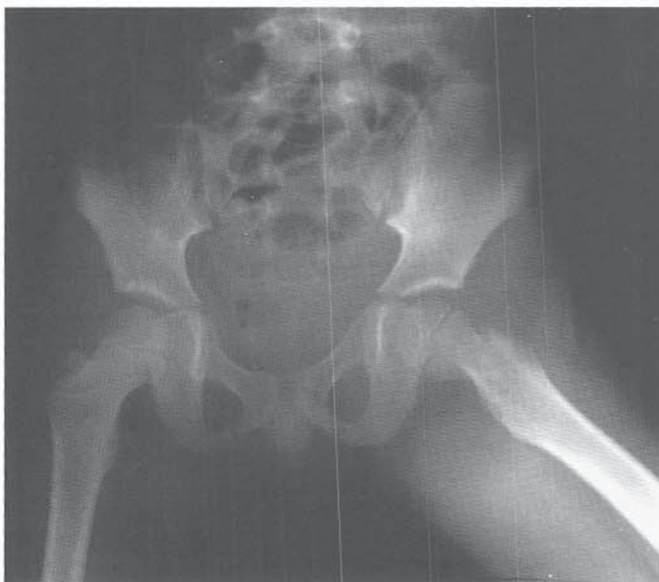

FIGURE 42-55 A and B, Transcervical hip fracture in a 12-year-old adolescent that was treated by screw fixation. To obtain stable fracture fixation, the screw threads are proximal to the fracture and provide compression across the fracture site.

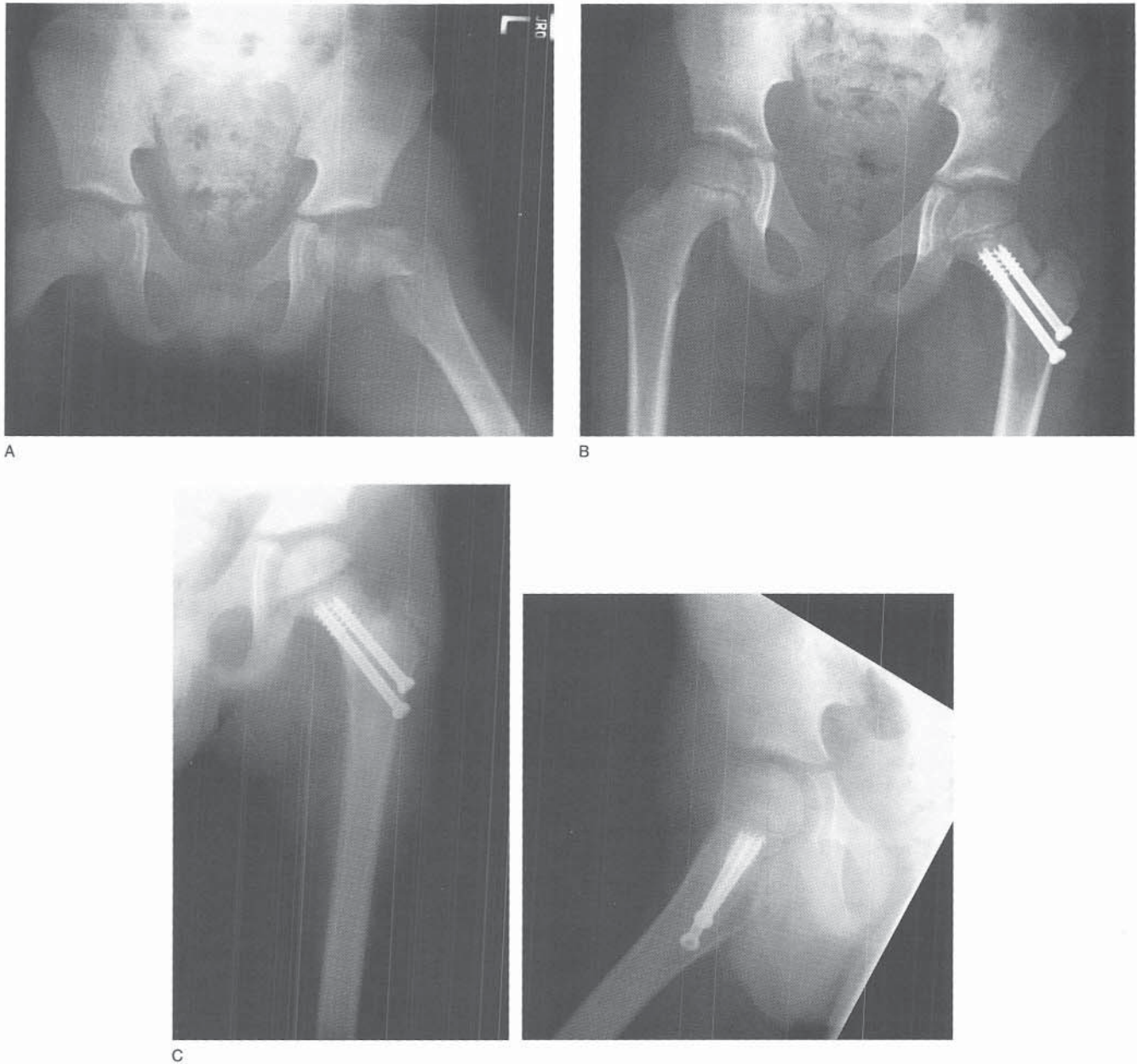


FIGURE 42-57 A, Cervicotrochanteric fracture in a 7-year-old child. B, Radiographs following a closed manipulation, anatomic reduction, and percutaneous screw fixation. A hip spica cast was used for 2 months. C, Final healing at 8 months.

reduction and subsequent varus. We recommend hip spica casting to supplement cannulated screw fixation or the use of a hip screw and side plate construct.

TYPE IV: PERTROCHANTERIC OR INTERTROCHANTERIC FRACTURES. This fracture type results in the best outcome and can often be treated nonoperatively in the child less than 6 years old. As in type II and III fractures, a closed reduction with internal fixation is the treatment of choice for the displaced fracture in any age group and for the nondisplaced fracture in the older child (Fig. 42-58).

STRESS FRACTURES. Stress fractures occur predominantly in the adult population as a result of repetitive loading of pathologic bone (rheumatoid arthritis, osteoporosis) or normal bone (military recruits).^{5,55} Stress fractures have been

subgrouped into the transverse or tension type, which appears as a small lucency in the superior part of the femoral neck and requires internal fixation to prevent displacement, and the compression type, which appears as a haze of callus on the inferior aspect of the neck and rarely displaces if treated conservatively.¹⁷

Only 13 cases have been reported in the literature in children and adolescents.^{12,17,32,51,53,63} Stress fractures in children usually occur in the 8- to 14-year-old age group and present with mild symptoms of pain which can mimic transient synovitis, a pre-SCFE, avulsion injuries of the pelvis, muscle strains, and benign lesions such as osteoid osteoma. The patient complains of mild hip pain, which often does not prevent participation in normal activities such as cross-country running.⁵³ The physical examination is essentially normal, with

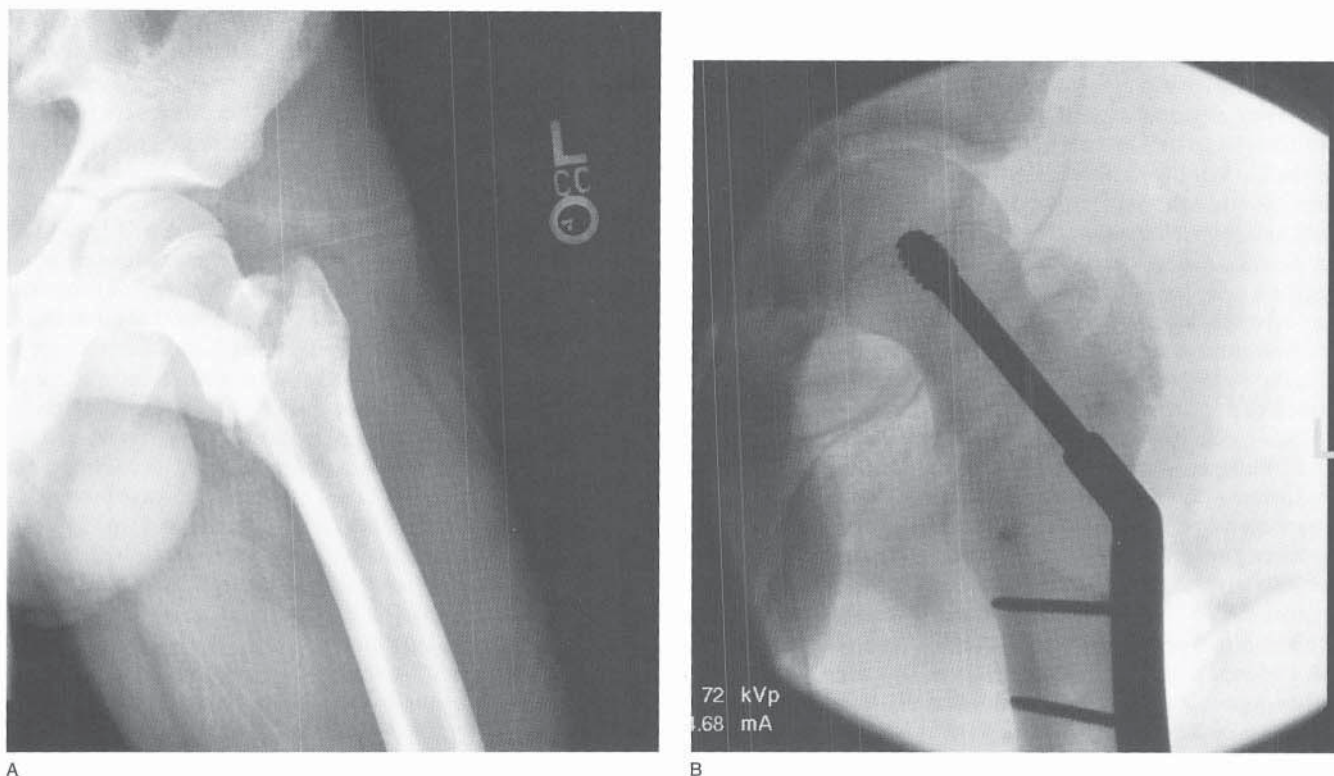


FIGURE 42-58 A, Left intertrochanteric hip fracture in a 10-year-old child. B, Treatment with a compression screw and side plate after a closed reduction.

minimal pain on hip motion. Radiographic evidence of the hip fracture often is not seen for up to 4 to 6 weeks from the time of appearance of the original symptoms or the initial presentation. Bone scans will usually show a stress fracture; however, MRI is most helpful in making a diagnosis.²⁸ Displacement of stress fractures in children has been reported when normal activities were continued, or after a fall.^{53,63}

Algorithms for the treatment of femoral neck stress fractures in children are based on the premise that only compression-type fractures occur in children.⁵³ Once the diagnosis is made, treatment should consist of nonweightbearing in the cooperative patient or hip spica casting in a patient in whom the weightbearing status cannot be controlled. When painful symptoms have resolved (usually within 4 to 6 weeks), partial weightbearing can be resumed. Full weightbearing is started only after solid radiographic union of the fracture. Internal fixation should be performed on any fracture that is displaced at the time of presentation or begins to show displacement or evidence of delayed union/nonunion.

Complications. The treatment of hip fractures in children is associated with a high incidence of complications, especially in the displaced fracture and in the older child.^{8,27,42,45} The incidence of each complication has diminished with more aggressive operative management, including prompt closed or open reduction, stable internal fixation that avoids the physis, and external immobilization. Complications in children's hip fractures include AVN, coxa vara, nonunion, premature physeal closure, and infection.

AVASCULAR NECROSIS. AVN is the most common and most devastating complication associated with hip fractures in children. Because of the high incidence of AVN and the

severity of symptoms, AVN is the principal cause of poor results in children's hip fractures. Historically, the incidence of AVN has been reported to be 100 percent, 50 percent, 25 percent, and 15 percent for types I, II, III, and IV fractures respectively, with an overall incidence of 43 percent.⁸ When 11 series are combined, the incidence of AVN is lower: 45 percent, 33 percent, 14 percent, and 3 percent for types I, II, III, and IV fractures, respectively.* AVN of the femoral head is thought to occur because of disruption or compromise of the blood supply of the femoral head at the time of the initial trauma (displacement of the fracture) and the tamponade effect of the hip hemarthrosis.

Risk factors predisposing to AVN are fracture displacement, which is the most important factor; the presence of a type I or II fracture; and a fracture in an older child (more than 12 years old). Canale reported that over 90 percent of patients who developed AVN had displaced hip fractures.^{7,8} Heiser and Oppenheim in 1980 reported 100 percent good results in nondisplaced fractures and only 50 percent good results in displaced fractures.²⁵ Pffringer and Rosemeyer reported lower rates of complications (including AVN) overall in children less than 12 years old: AVN occurred in 30 percent of adolescents but in only 19 percent in children less than 12 years old.⁴² Although early reduction (within 24 hours) with fixation improves the overall outcome of hip fractures in adults, there are few studies directly comparing early and late treatment in children. Pffringer and Rosemeyer reported improved outcome in children and adolescents with early operative treatment (within 36 hours of injury).⁴²

Although the mode of treatment has not been thought to

*See references 8, 9, 15, 23, 25, 27, 29, 40, 42, 54, 59.

have an effect on the incidence of AVN, there is growing evidence that more aggressive operative management to include decompressive hip arthrotomy reduces this risk.^{7,9,35,54} Cheng and Tang reported on ten patients (average age, 12.9 years) with displaced hip fractures; seven underwent decompression of the hip joint with needle aspiration followed by closed reduction and internal fixation; three required an open reduction and internal fixation. No patient had developed AVN at an average follow-up of 4.6 years.⁹ Ng and Cole combined their six cases of displaced hip fractures in children who underwent hip decompression with 39 similar cases reported in the literature and compared them with 48 cases reported by Canale that were treated without hip decompression.³⁵ They concluded that hip decompression lowers the incidence of AVN, especially in type II and III fractures. However, Gerber and colleagues reviewed the experience with open reduction and internal fixation of hip fractures in children at seven Swiss hospitals and could not demonstrate an improvement in the incidence of AVN.²³ Although the data are not conclusive, they do suggest that hip decompression helps lower the incidence of AVN, is relatively easy to perform, and is associated with minimal complications. Therefore, we recommend needle aspiration of the hip joint using an 18-gauge needle via a subadductor approach at the time of the initial treatment. This should be done at the completion of the reduction and fixation to minimize the reaccumulation of fracture hematoma.

Symptoms of AVN may occur early, with complaints of groin pain. Radiographic evidence of AVN can be seen as early as 2 months following injury and is generally seen within 1 year of injury (Fig. 42–59).^{8,46} Radiographs may

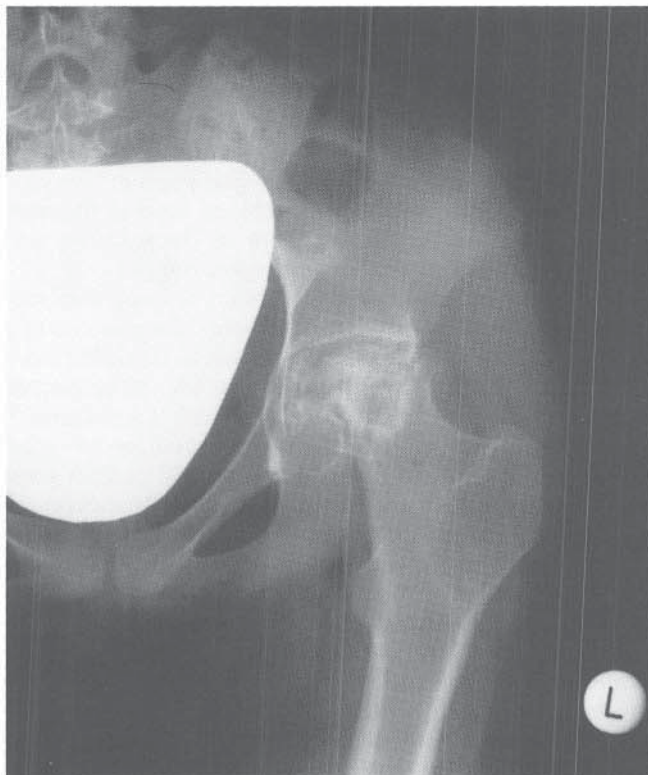

FIGURE 42–59 Severe AVN of the femoral head following a displaced femoral neck treated with closed reduction and screw fixation. The hardware was removed when there was evidence of AVN.

demonstrate osteopenia of the femoral head, later followed by sclerosis, fragmentation, and often collapse and deformity. MRI is the most sensitive test to confirm the diagnosis and also defines the extent of femoral head and neck involvement. Radioisotope scanning shows decreased uptake in the femoral head and/or neck and is useful in the hip that has stainless steel internal fixation.^{26,37}

Three patterns of AVN have been described by Ratliff (Fig. 42–60).⁴⁵ In type I AVN there is severe diffuse necrosis involving the entire femoral head and the proximal fragment of the femoral neck (Fig. 42–61). The femoral head necrosis is accompanied by various degrees of collapse, from segmental necrosis with minimal collapse to diffuse complete collapse with subluxation. Type I AVN results from interruption of the lateral epiphyseal and the metaphyseal vessels. This is the most common pattern of AVN, accounting for more than 50 percent of cases, and has the worst prognosis. In Ratliff's study, type I necrosis occurred in 33 of 55 cases (60 percent); the patients with partial collapse had fair results, whereas the patients with complete collapse had poor results.⁴⁵ Canale reported that 80 percent of patients with AVN had the type I pattern.^{7,8}

Type II AVN is characterized by sclerosis from the fracture line of the femoral neck to the physis but sparing the femoral head (Fig. 42–62). Type II accounts for 25 percent of cases of AVN and has the best results.

Type III AVN is characterized by more localized necrotic changes, often in the anterosuperior aspect of the femoral head, with little collapse (Fig. 42–63). It is usually due to interruption of the lateral epiphyseal vessels before entrance into the epiphysis. This type is seen in approximately 25 percent of cases and has a better prognosis than type AVN I.⁴⁶

In general, AVN following hip fractures in children results in poor outcomes in up to 60 percent of cases. In a long-term follow-up study, Davison and Weinstein reported that 64 percent (nine of 14) of patients with AVN had severe pain, limited range of motion, and proximal femoral deformities; and four (44 percent) required arthroplasty an average of 5.6 years following injury.¹⁵ Leung and Lam, in a long-term follow-up of hip fractures in children 13 and 23 years following injury, found that 20 percent of patients had severe collapse and deformity from AVN.¹⁴

The treatment of AVN has been relatively unsuccessful, and some have suggested that treatment does not affect the natural history.³³ Canale and Bourland reported that 60 percent of patients with AVN following hip fractures had poor results, regardless of whether treatment was specifically undertaken to treat the AVN.⁸ Little data is available on the treatment of AVN following hip fractures in children, which makes defining one treatment modality superior to others difficult.^{8,45}

The goals of treatment are to preserve the functional range of hip motion, maintain containment of the femoral head within the acetabulum, and preserve as much femoral head viability as possible. In general, the treatment of AVN should begin at the onset of symptoms and should entail partial weightbearing or nonweightbearing until painful symptoms resolve. Canale and Bourland had 22 hips with AVN; seven were treated with bedrest or nonweightbearing ambulation started at the time that AVN was first recognized and continued for an average of 8 years. One patient had a good result, three had fair results, and three had poor results.⁸ In a study

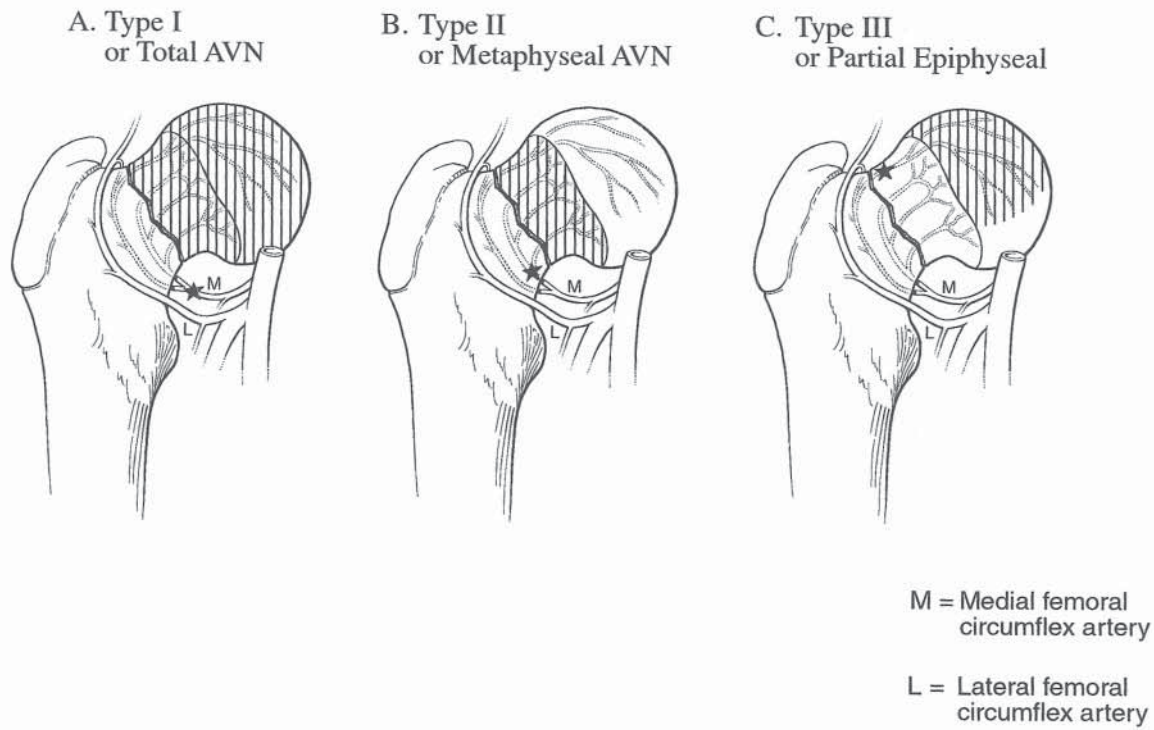


FIGURE 42-60 Patterns of AVN of the femoral head following hip fractures in children, as described by Ratliff. Note the location of the vascular compromise that leads to each pattern. A, Type I or total AVN of the entire femoral capital epiphysis and proximal fragment of the femoral neck. B, Type II or metaphyseal AVN from the level of the fracture to the physis. C, Type III or partial head AVN. The AVN is confined to the femoral head.

by Ratliff, 20 patients with type I AVN, without subluxation of the femoral head had fair results at final follow-up following treatment with a weight-relieving caliper.⁴⁵

Operative treatment has resulted in poor outcomes principally because of selection bias; the most severe cases of AVN have received operative treatment. When AVN is first recognized, the initial step is removal of internal fixation devices to prevent hardware penetration into the joint. Fur-

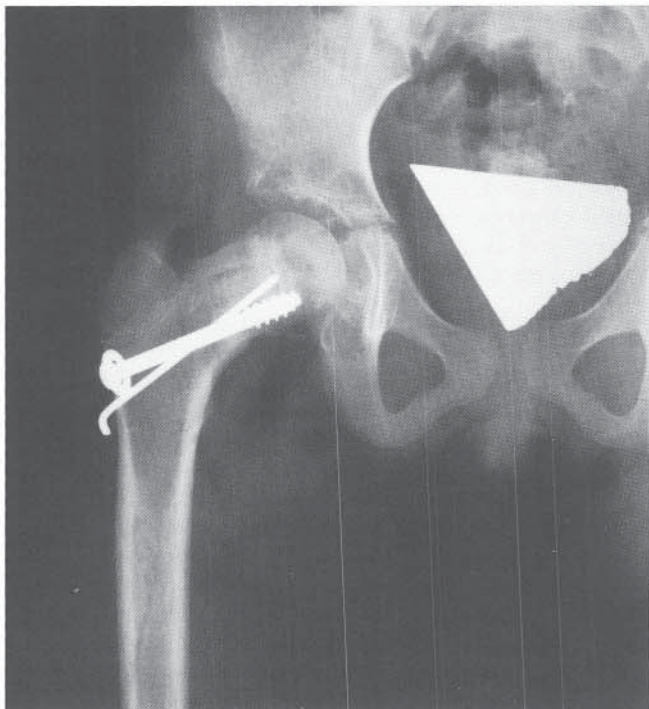


FIGURE 42-61 Type I AVN in an 8-year-old child. The avascular area is proximal to the femoral neck fracture.

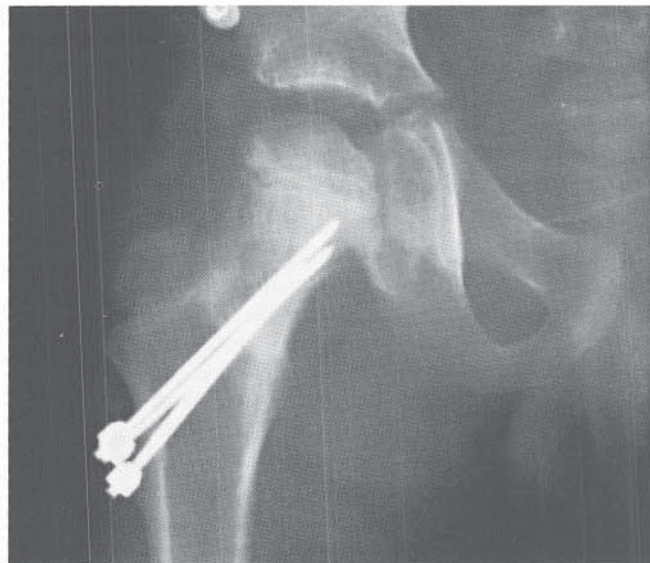


FIGURE 42-62 Type II AVN in a 6-year-old child following closed reduction and internal fixation of a cervicoprochanteric hip fracture. The AVN extends from the fracture site to the physis.

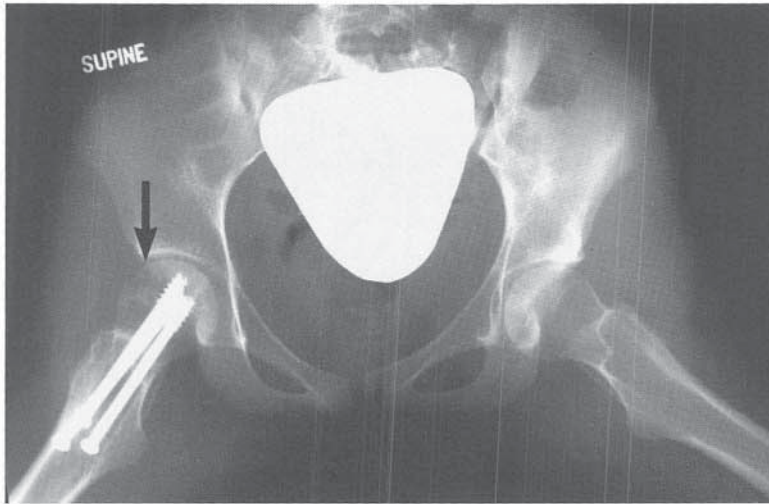


FIGURE 42–63 Type III AVN, or partial femoral head AVN (arrow), following a femoral neck fracture.

ther operative treatment options include intertrochanteric osteotomy (usually valgus) to place viable head in the weight-bearing zone, capsulotomy, and arthrodesis. Ratliff reported seven cases of type I necrosis with subluxation of the femoral head that were treated by subtrochanteric osteotomy in an attempt to allow revascularization of the femoral head. All seven patients had poor results, and this procedure was not recommended.⁴⁵ Similarly, Canale and Bourland described one patient who had a cortical bone graft inserted into the avascular area, with a poor result, and a patient who underwent a valgus osteotomy, with a fair result.⁸ Cup arthroplasty or total hip arthroplasty in this setting has also resulted in poor outcomes. Davison and Weinstein reported on four patients who underwent cup arthroplasty or total hip arthroplasty. In two the arthroplasties have been revised, and in the other two follow-up has been short.¹⁵

We recommend partial weightbearing or nonweightbearing on the involved extremity at the first signs and symptoms of AVN until revascularization is complete and painful symptoms have resolved. If femoral head necrosis is associated with severe symptoms and subluxation, intertrochanteric osteotomy to place more viable head in the weightbearing zone or arthrodesis is recommended (Fig. 42–64). In general, we do not recommend cup arthroplasty or total hip arthroplasty in the adolescent with AVN because of the relatively short life span of these prostheses in the young, active patient.

COXA VARA. Coxa vara may be due to four main causes: malreduction, in which the fracture is left in a varus position; loss of reduction due to inadequate fracture stabilization, usually when external immobilization alone is used; delayed union or nonunion, in which eventual varus develops; and premature closure of the proximal femoral physis with overgrowth of the greater trochanter. It occurs in 10 to 32 percent of cases, depending on the type of treatment used.*

Closed reduction and external immobilization with abduction casting results in the highest incidence of coxa vara, most often due to loss of reduction. Although closed reduction and internal fixation can result in coxa vara, the severity of the varus deformity tends to be mild when compared to

that in patients treated by closed reduction and casting. Canale and Bourland reported coxa vara in 13 patients (21 percent of their study group). In seven children treated by closed reduction and internal fixation, the coxa vara resulted in an average neck-shaft angle of 127 degrees, whereas in five children treated by reduction and casting, the varus deformity averaged 94 degrees.⁸ McDougall reported a 50 percent incidence of coxa vara and related this to bending of the femoral neck because of bone plasticity at the fracture site, despite radiographic union.³¹ Others feel that the obliquity of the fracture line (Pauwels' angle of more than 50 degrees) results in fracture instability and predisposes to varus deformity.¹ Some remodeling occurs with milder deformity, especially in the younger child.²⁵ However, a neck-shaft angle of less than 100 degrees is associated with a poor outcome, and such a deformity has little ability to remodel, even in the young child.

Preventing a coxa vara deformity is best accomplished with an anatomic reduction and rigid internal fixation followed by external immobilization in most cases. To lessen the risk of premature physeal closure and subsequent coxa vara, internal fixation devices should avoid the growth plate as long as good screw purchase can be achieved. We recommend valgus osteotomy with blade plate fixation in a child with a neck-shaft angle of less than 110 degrees or when loss of reduction occurs (Fig. 42–65).

NONUNION. The incidence of nonunion varies between 6.5 and 12.5 percent and appears to be related to the method of treatment.^{8,25,27,45} In various series of patients in which the majority were treated with external immobilization, higher rates of nonunion were reported^{27,45} than in more recent series in which internal fixation was used.^{8,25} Additional factors associated with nonunion include poor reduction, distraction of the fracture fragments at the time of internal fixation, and a Pauwels' angle of more than 60 degrees. Nonunion can lead to coxa vara and can predispose to other complications such as AVN and premature physeal arrest, and ultimately lead to poor results when an established nonunion occurs. Therefore, prevention by means of an anatomic reduction, rigid internal fixation, and external immobilization is important.

Nonunion should be treated when it is diagnosed, to prevent further complications. In the child less than 10 years

*See references 8, 15, 25, 27, 29, 45, 59.

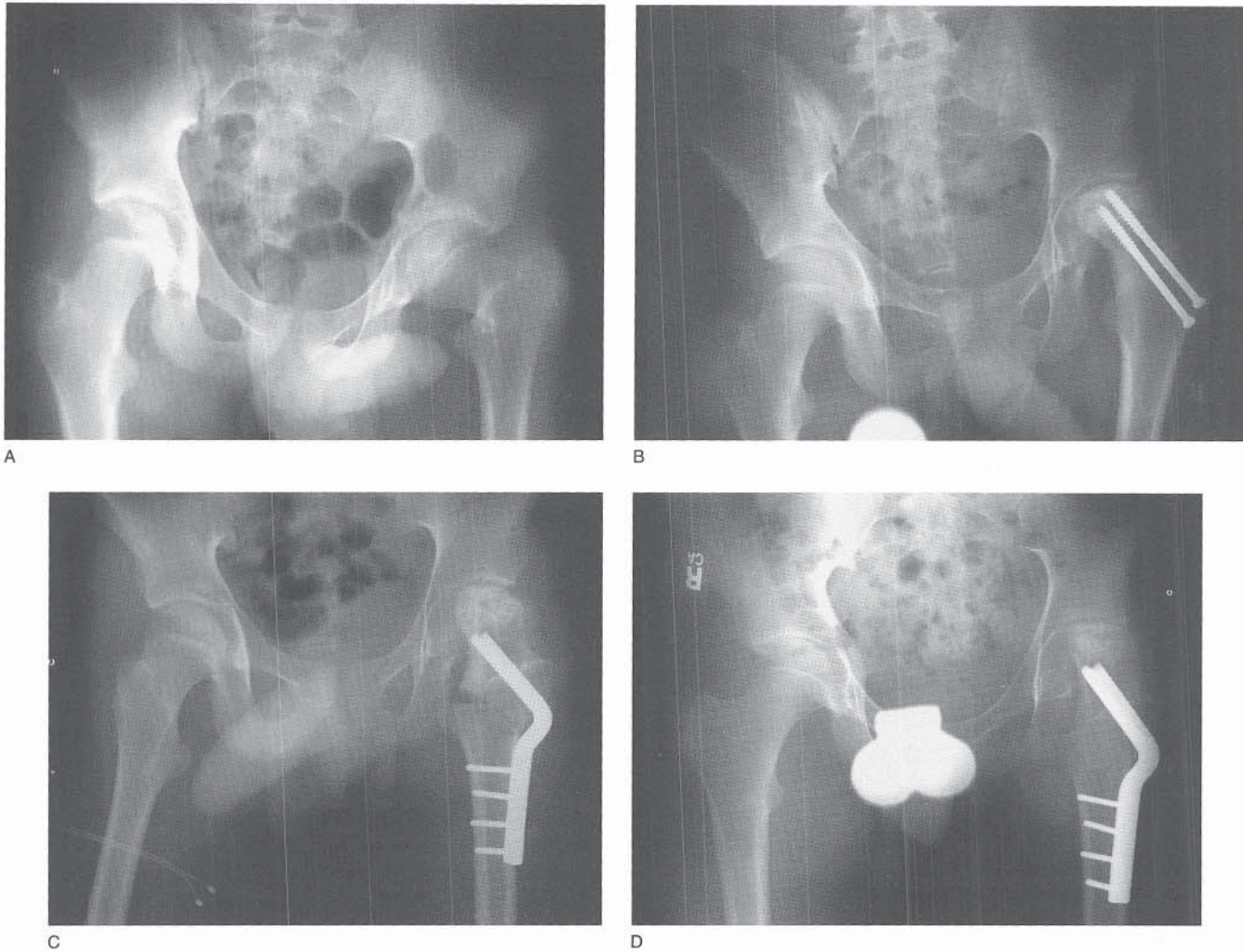


FIGURE 42-64 Intertrochanteric osteotomy to reposition viable femoral head in the weightbearing zone in a 16-year-old male adolescent with a displaced femoral neck fracture. **A**, Preoperative radiograph. **B**, Radiographs obtained months after operative fixation showing femoral head collapse. **C**, A valgus osteotomy was performed with blade plate fixation to get viable femoral head into the weightbearing zone. **D**, Appearance at final healing one year following the osteotomy. The patient has an improved gait with mild symptoms.

old, we recommend autogenous bone grafting with rigid internal fixation, with screws placed in lag-type fashion to gain compression across the fracture site. A subtrochanteric valgus osteotomy should be performed as described by Pauwel in the older child, or in any child with a Pauwels' angle greater than 60 degrees or when an unreducible coxa vara is present (Fig. 42-66).⁴¹ The goal of valgus osteotomy is to alter the plane of the fracture to produce compressive loads across the fracture site to enhance healing. Preoperative planning should be performed to restore a normal neck-shaft angle, which generally requires removing an approximately 25-degree laterally based wedge with the osteotomy placed just superior to the lesser trochanter, followed by blade plate fixation.³⁴ In adults, excellent results have been reported using this technique, with fracture union in nearly all cases.^{2,3,36} Canale and Bourland reported four nonunions treated successfully with subtrochanteric valgus osteotomy without bone grafting in children.⁸

PREMATURE PHYSEAL ARREST. The reported incidence of premature physeal arrest varies between 10 and 62 percent.^{8,25,29,42,45}

Factors that contribute to premature physeal arrest are the amount of displacement at the time of injury (requiring more manipulation and potential injury to the physis), the development of AVN, and internal fixation that crosses the physis. In most cases of premature physeal arrest there is associated AVN of the femoral head. The development of AVN with collapse may lead to premature physeal arrest; however, it is more likely that these fractures are displaced at the time of injury, leading to compromised blood supply to both the epiphysis, leading to AVN, and the physis, leading to physeal arrest. Lam reported that eight of nine patients with premature physeal arrest had associated AVN,²⁹ while Heiser and Oppenheim reported AVN in five of their nine cases.²⁵

Internal fixation, when it crosses the physis, may predispose to premature physeal arrest. Canale and Bourland reported a 62 percent incidence of premature physeal arrest in their initial series. Of the 23 cases in which Knowles pins crossed the physis, 18 (78 percent) closed prematurely and five remained open.⁸ In their later study, the incidence of premature physeal arrest dropped dramatically, to 12 per-

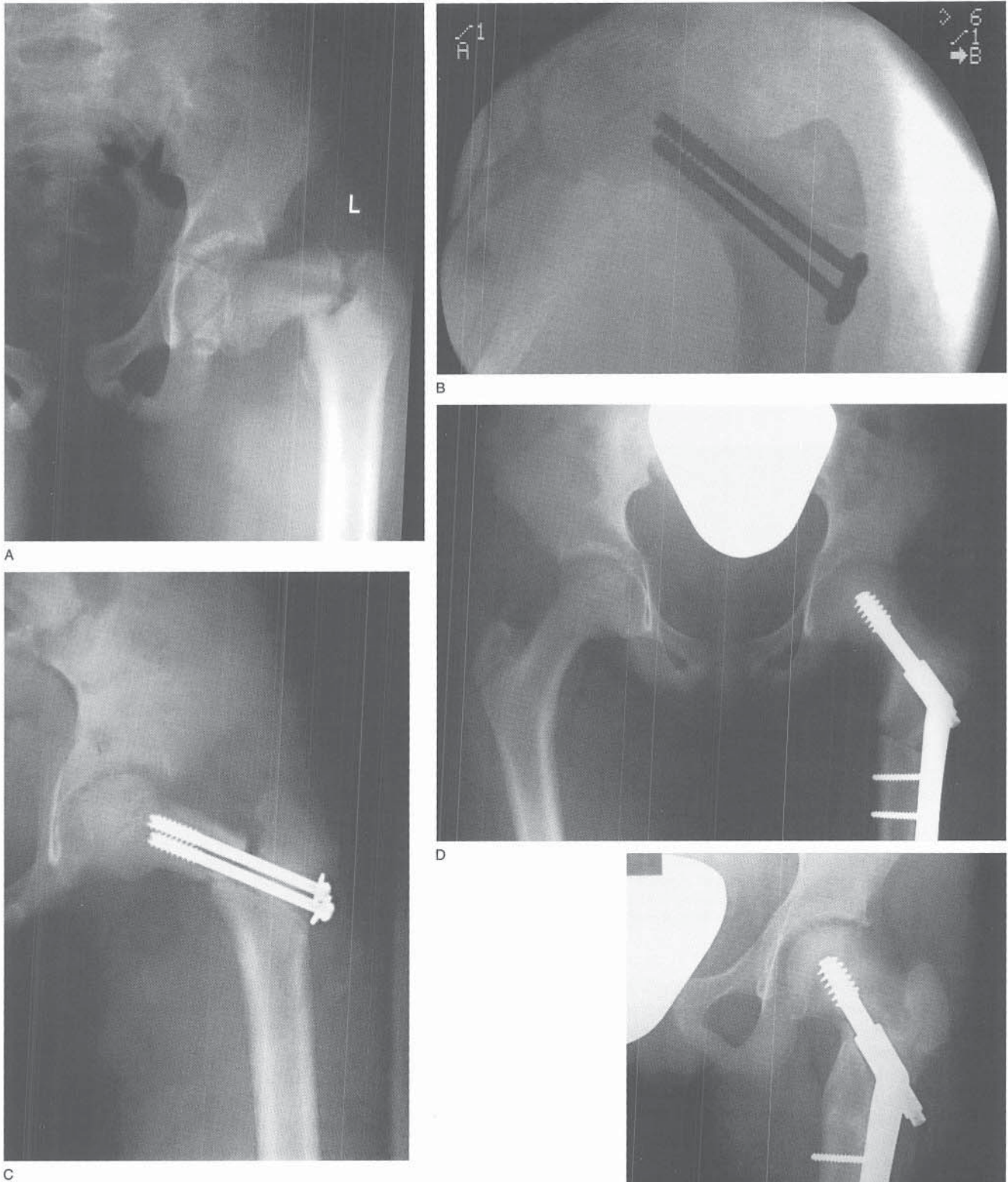
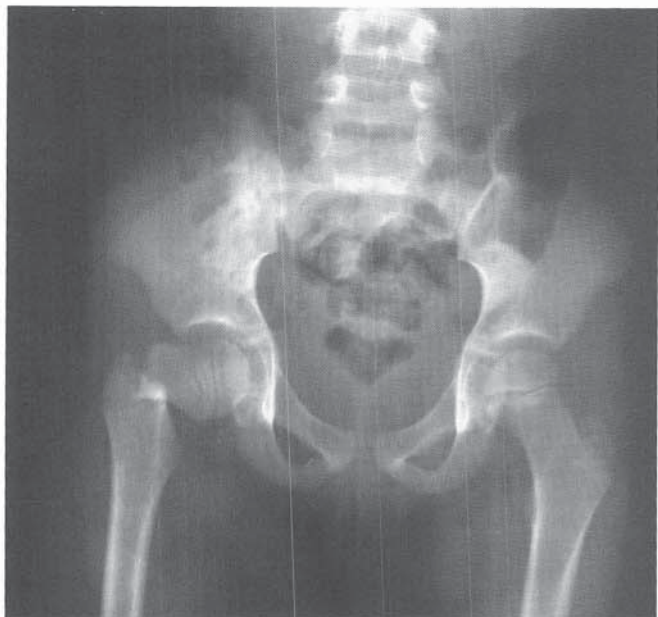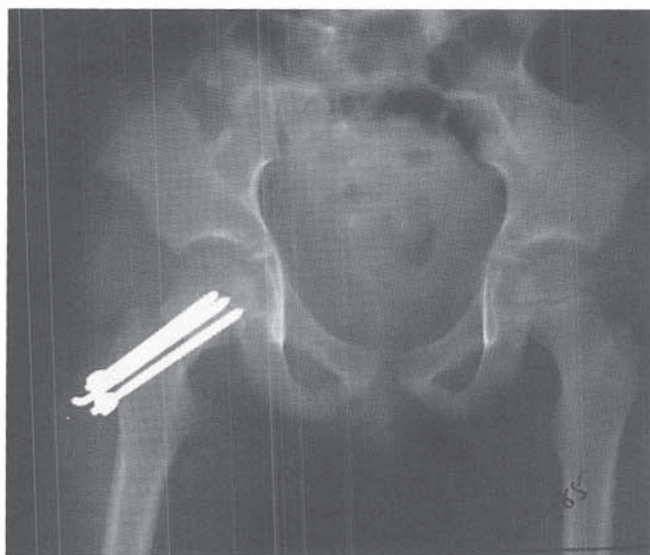


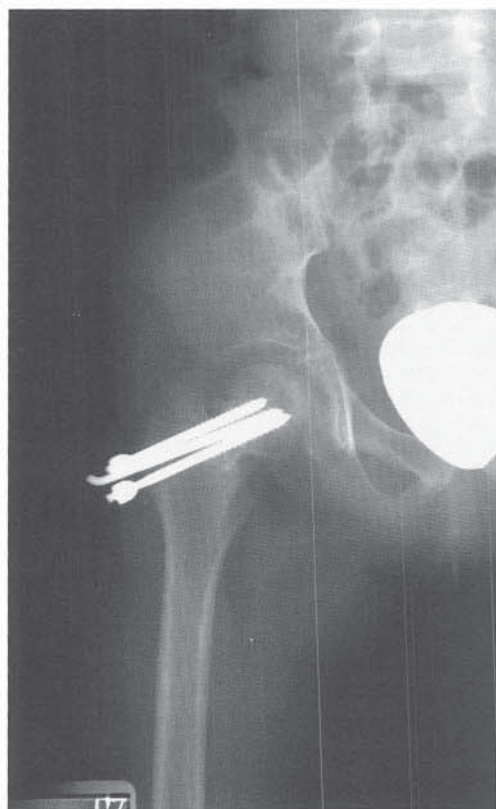
FIGURE 42-65 Cervicotrochanteric fracture in a 10-year-old girl. **A**, Initial injury films. **B**, A closed reduction and percutaneous pinning with two 6.5-mm cannulated screws was performed, followed by immobilization in a hip spica cast. **C**, The fracture line is vertical, and at the 4-week follow-up evaluation the fracture reduction has been lost owing to screw migration in the metaphysis with resultant varus deformity. **D**, Valgus intertrochanteric osteotomy was then performed. The cannulated screws were removed after the guide wires were placed. The large compression screw was placed over the inferior guide wire while the superior guide wire prevented rotation of the femoral neck. Preoperative planning resulted in using a 20-degree laterally based wedge to produce a valgus correction osteotomy and align the fracture in a more horizontal position. **E**, Final healing radiograph.



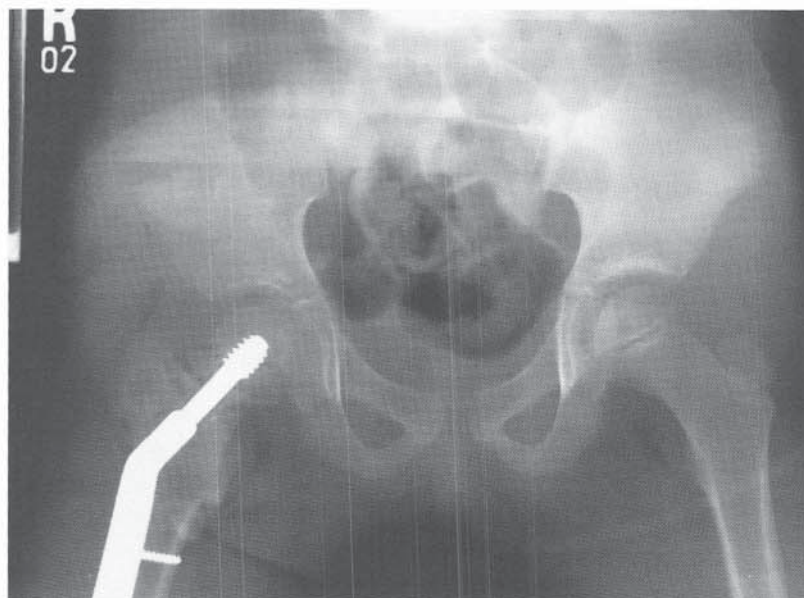
A



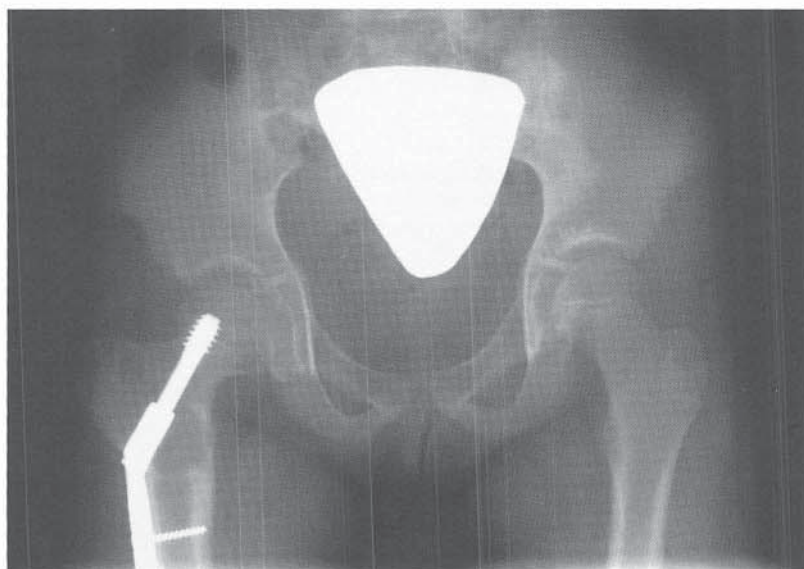
B



C



D



E

FIGURE 42-66 Radiographs of a femoral neck fracture with a relatively steep Pauwels' angle. Union was delayed, and a valgus osteotomy was performed to promote fracture healing. **A**, Initial injury radiographs of a 5-year-old girl who was struck by a car. **B**, A closed reduction followed by three-screw fixation was performed. **C**, At 4 months delayed union with some varus angulation was noted. **D**, A subtrochanteric valgus osteotomy was performed. **E**, Healing of the fracture and the osteotomy has occurred.

cent. The decreased incidence was attributed to avoiding the physal plate with internal fixation devices and to using as few pins as possible.⁷

Premature physal closure by itself does not usually result in significant deformity or limb length discrepancy since the proximal growth plate contributes only 15 percent of the growth of the entire extremity. However, when premature physal closure is combined with AVN in the young child, significant limb length discrepancies develop in virtually all cases.

To prevent premature physal arrest, treatment of the displaced hip fracture should consist of gentle closed reduction to avoid further injury to the physis in type I fractures. This is followed by smooth pin fixation in the young child or cannulated screws in the older child in which the threads do not span the physis. In all other fractures, internal fixation devices should be left short of the physis as long as fracture stability is not compromised.

Radiographs of the affected hip should be compared with radiographs of the contralateral side to determine whether premature physal arrest and AVN have occurred. Serial scanograms and bone age measurements should be performed to predict the eventual limb length discrepancy, with the Moseley straight-line graph used to accurately predict the appropriate timing of a contralateral epiphysiodesis.

INFECTION. Infection is relatively rare in the child and adolescent following a hip fracture; the reported incidence is approximately 1 percent.^{7,8,44} Infection is usually associated with subsequent AVN, and patients generally have poor outcomes because of pain and deformity. Davison and Weinstein reported that two (10.5 percent) of 19 patients who underwent total cup arthroplasty due to pain and poor hip function had septic arthritis and associated AVN.¹⁵ Treatment consists of debridement of the hip joint until gross infection is cleared, followed by intravenous administration of antibiotics. The duration of intravenous antibiotic administration depends on the virulence of the offending organism and the clinical course of the patient. In general, 2 to 3 weeks of intravenous antibiotics followed by 2 to 3 weeks of oral antibiotics will eradicate the common organisms; however, 6 to 8 weeks of vancomycin therapy is required to treat methicillin-resistant *Staphylococcus aureus*.

REFERENCES

Hip Fractures

- Allende G, Lezama L: Fractures of the neck of the femur in children. *J Bone Joint Surg* 1951;33-A:387.
- Anglen JO: Intertrochanteric osteotomy for failed internal fixation of femoral neck fracture. *Clin Orthop* 1997;341:175.
- Ballmer FT, Ballmer PM, Baumgaertel F, et al: Pauwels' osteotomy for nonunions of the femoral neck. *Orthop Clin North Am* 1990;21:759.
- Berger PE, Ofstein RA, Jackson DW, et al: MRI demonstration of radiographically occult fractures: what have we been missing? *Radiographics* 1989;9:407.
- Blickenstaff LD, Morris JM: Fatigue fracture of the femoral neck. *J Bone Joint Surg* 1966;48-A:1031.
- Boitzy A: Fractures of the proximal femur. In Weber B, Brunner C, Grueler F (eds): *Treatment of Fractures in Children and Adolescents*. Berlin, Springer-Verlag, 1980.
- Canale ST: Fractures of the hip in children and adolescents. *Orthop Clin North Am* 1990;21:341.
- Canale ST, Bourland WL: Fracture of the neck and intertrochanteric region of the femur in children. *J Bone Joint Surg* 1977;59-A:431.
- Cheng J, Tang N: Decompression and stable internal fixation of femoral neck fractures in children can affect the outcome. *J Pediatr Orthop* 1999;19:338.
- Chong KC, Chacha PB, Lee BT: Fractures of the neck of the femur in childhood and adolescence. *Injury* 1975;7:111.
- Chung SM: The arterial supply of the developing proximal end of the human femur. *J Bone Joint Surg* 1976;58-A:961.
- Coldwell D, Gross GW, Boal DK: Stress fracture of the femoral neck in a child (stress fracture). *Pediatr Radiol* 1984;14:174.
- Colonna P: Fracture of the neck of the femur in childhood: a report of six cases. *Ann Surg* 1928;828:902.
- Connolly LP, Treves ST, Connolly SA, et al: Pediatric skeletal scintigraphy: applications of pinhole magnification. *Radiographics* 1998;18:341.
- Davison BL, Weinstein SL: Hip fractures in children: a long-term follow-up study. *J Pediatr Orthop* 1992;12:355.
- Delbet P: Cited in Colonna, PC: Fracture of the neck of the femur in childhood: a report of six cases. *Ann Surg* 1928;88:902.
- Devas M: Stress fractures of the femoral neck. *J Bone Joint Surg* 1965;47-B:728.
- Fabry G, MacEwen GD, Shands AR Jr: Torsion of the femur: a follow-up study in normal and abnormal conditions. *J Bone Joint Surg* 1973;55-A:1726.
- Fiddian NJ, Grace DL: Traumatic dislocation of the hip in adolescence with separation of the capital epiphysis: two case reports. *J Bone Joint Surg* 1983;65-B:148.
- Forlin E, Guille JT, Kumar SJ, et al: Transepiphyseal fractures of the neck of the femur in very young children. *J Pediatr Orthop* 1992;12:164.
- Funk F: Traumatic dislocation of the hip in adolescence with separation of the capital epiphysis: factors affecting prognosis and treatment. *J Bone Joint Surg* 1962;44-A:1135.
- Gaudinez RF, Heinrich SD: Transphyseal fracture of the capital femoral epiphysis [Clinical Conference]. *Orthopedics* 1989;12:1599.
- Gerber C, Lehmann A, Ganz R: Femoral neck fractures in children: a multicenter follow-up study. *Z Orthop* 1985;123:767.
- Haramati N, Staron RB, Barax C, et al: Magnetic resonance imaging of occult fractures of the proximal femur. *Skeletal Radiol* 1994;23:19.
- Heiser JM, Oppenheim WL: Fractures of the hip in children: a review of forty cases. *Clin Orthop* 1980;149:177.
- Herring JA, McCarthy RE: Fracture dislocation of the capital femoral epiphysis. *J Pediatr Orthop* 1986;6:112.
- Ingram A, Bachynski B: Fractures of the hip in children: treatment and results. *J Bone Joint Surg* 1953;46-B:867.
- Keene JS, Lash EG: Negative bone scan in a femoral neck stress fracture: a case report. *Am J Sports Med* 1992;20:234.
- Lam SF: Fractures of the neck of the femur in children. *J Bone Joint Surg* 1971;53-A:1165.
- Lindseth RE, Rosene HA Jr: Traumatic separation of the upper femoral epiphysis in a new born infant. *J Bone Joint Surg* 1971;53-A:1641.
- McDougall A: Fractures of the neck of the femur in childhood. *J Bone Joint Surg* 1961;43-B:16.
- Miller F, Wenger DR: Femoral neck stress fracture in a hyperactive child: a case report. *J Bone Joint Surg* 1979;61-A:435.
- Morrissey R: Hip fractures in children. *Clin Orthop* 1980;152:202.
- Müller M: Intertrochanteric osteotomy: indication, preoperative planning, technique. In Schatzker J (ed): *The Intertrochanteric Osteotomy*, p 25. Berlin, Springer-Verlag, 1984.
- Ng GP, Cole WG: Effect of early hip decompression on the frequency of avascular necrosis in children with fractures of the neck of the femur. *Injury* 1996;27:419.
- Nierenberg G, Volpin G, Bialik V, et al: Pelvic fractures in children: a follow-up in 20 children treated conservatively. *J Pediatr Orthop B* 1993;1:140.
- Ogden J: *Skeletal Injury in the Child*. Philadelphia, WB Saunders Co, 1990.
- Ogden JA: Changing patterns of proximal femoral vascularity. *J Bone Joint Surg* 1974;56-A:941.
- Ogden JA, Lee KE, Rudicel SA, et al: Proximal femoral epiphysiolysis in the neonate. *J Pediatr Orthop* 1984;4:285.
- Oveson O, Arreskov J, Bellstrom T: Hip fractures in children: a long-term follow up of 17 cases. *Orthop* 1989;12:361.
- Pauwels F: Der Schenkelhalsbruch: Ein mechanisches Problem. Translated by Hildegard Spital. *Beilageheft zur Zeitschrift für Orthopaedische Chirurgie*, vol 63, 1963.
- Pforringer W, Rosemeyer B: Fractures of the hip in children and adolescents. *Acta Orthop Scand* 1980;51:91.

43. Ratliff A: Fractures of the neck of the femur in children. *J Bone Joint Surg* 1962;44-B:528.
44. Ratliff AH: Complications after fractures of the femoral neck in children and their treatment. *J Bone Joint Surg* 1970;57-B(2):175.
45. Ratliff AH: Traumatic separation of the upper femoral epiphysis in young children. *J Bone Joint Surg* 1968;50-B:757.
46. Ratliff AH: Fractures of the neck of the femur in children. *Orthop Clin North Am* 1974;5:903.
47. Reikeras O, Bjerkreim I, Kolbenstvedt A: Anteversion of the acetabulum in patients with idiopathic increased anteversion of the femoral neck. *Acta Orthop Scand* 1982;53:847.
48. Reikeras O, Hoiseth A, Reigstad A, et al: Femoral neck angles: a specimen study with special regard to bilateral differences. *Acta Orthop Scand* 1982;53:775.
49. Rizzo PF, Gould ES, Lyden JP, et al: Diagnosis of occult fractures about the hip: magnetic resonance imaging compared with bone-scanning. *J Bone Joint Surg* 1993;75-A:395.
50. Rubin SJ, Marquardt JD, Gottlieb RH, et al: Magnetic resonance imaging: a cost-effective alternative to bone scintigraphy in the evaluation of patients with suspected hip fractures. *Skeletal Radiol* 1998;27:199.
51. Scheerlinck T, De Boeck H: Bilateral stress fractures of the femoral neck complicated by unilateral displacement in a child. *J Pediatr Orthop B* 1998;7:246.
52. Shin AY, Morin WD, Gorman JD, et al: The superiority of magnetic resonance imaging in differentiating the cause of hip pain in endurance athletes. *Am J Sports Med* 1996;24:168.
53. St. Pierre P, Staheli LT, Smith JB, et al: Femoral neck stress fractures in children and adolescents. *J Pediatr Orthop* 1995;15:470.
54. Swiontkowski MF, Winquist RA: Displaced hip fractures in children and adolescents [published erratum appears in *J Trauma* 1986;12:1160]. *J Trauma* 1986;26:384.
55. Tountas AA, Waddell JP: Stress fractures of the femoral neck: a report of seven cases. *Clin Orthop* 1986;210:160.
56. Trueta J: The normal vascular anatomy of the human femoral head during growth. *J Bone Joint Surg* 1957;39-B:358.
57. Trueta J, Morgan J: The vascular contribution to osteogenesis. *J Bone Joint Surg* 1960;42-B:97.
58. Vonlanz T, Mayet A: Die Gelenkcorper des menschlichen hufgelenkes in der profredienten Phase ihrer umwegigen Ausformung. *Z Anat* 1953;117:317.
59. Weiner DS, O'Dell HW: Fractures of the hip in children. *J Trauma* 1969;9:62.
60. Whitman R: Fracture of the neck of the femur in a child. *Med Rec* 1891;39:165.
61. Whitman R: Observations on fractures of the neck of the femur in childhood with special reference to treatment and differential diagnosis from separation of the epiphysis. *Med Rec* 1893;43:22.
62. Wojtowycz M, Starshak RJ, Sty JR: Neonatal proximal femoral epiphysiolysis. *Radiology* 1980;136:647.
63. Wolfgang GL: Stress fracture of the femoral neck in a patient with open capital femoral epiphyses. *J Bone Joint Surg* 1977;59-A:680.

ADDED REFERENCE

Hip Fractures

- 1a. Leung PC, Lam SF: Long-term follow-up of children with femoral neck fractures. *J Bone Joint Surg* 1986;68-B:537.

The Femur

FRACTURES OF THE FEMORAL SHAFT

The management of femoral shaft fractures in children continues to be challenging and controversial. Traditional treatment has relied on nonoperative approaches, since fracture healing occurs relatively rapidly in children and good results are generally seen. However, with a better understanding of the biology of fracture healing and with advances in fixation methods and operative techniques, there has been a general

movement toward operative stabilization of femoral shaft fractures in children.

Anatomy and Development. The femur first appears during the fourth week of gestation as a condensation of mesenchymal tissue. By the eighth week enchondral ossification has begun and growth is rapid. The primary ossification center is the femoral shaft, with ossification of the secondary centers beginning in the upper epiphysis at 6 months as a single center of ossification that later becomes the femoral head and the greater trochanter. Later, during the seventh fetal month, the distal secondary center of ossification develops. After birth, ossification of the femoral head occurs at approximately 4 to 5 months of age, the greater trochanter ossifies at approximately 4 years of age, and the lesser trochanter ossifies at 10 years of age.

Growth of the femoral shaft occurs initially by enchondral ossification and production of a medullary cavity with calcification in the periphery and vascularization in the center, a process that results in a large primary ossification center. Woven bone results from this ossification and persists for the first 18 months of life, later becoming more adult-type lamellar bone. This longitudinal and peripheral growth continues until skeletal maturity.

The blood supply of the femoral shaft is from both endosteal and periosteal blood vessels. The endosteal supply typically is derived from two nutrient vessels that enter the femur from a posteromedial direction. The periosteal capillaries supply the outer 25 to 30 percent of cortical bone and are most prominent in the areas of muscular attachments to the femoral shaft (Fig. 42–67). These two circulatory systems,

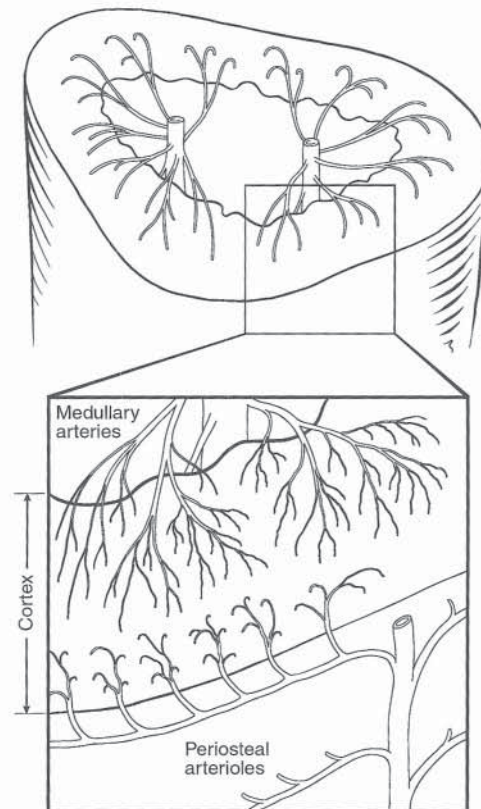


FIGURE 42–67 The blood supply to the femoral diaphysis. The medullary artery supplies the inner two-thirds and the periosteal vessels supply the outer one-third.

together with the metaphyseal complex of vessels, are interconnected to provide a strong vascular supply allowing for rapid fracture repair.

Classification. Like most diaphyseal fractures, the classification of femoral shaft fractures is based on the radiographic examination and the condition of the soft tissue envelope (closed or open fracture). Radiographs are evaluated for fracture location (proximal, middle, or distal third), configuration (transverse, oblique, or spiral), angulation, the degree of comminution, and the amount of displacement, translation, and shortening. Winquist and colleagues have classified the amount of comminution, which is especially useful when rigid intramedullary nailing is used to treat the femoral shaft fracture.⁸⁶ Shortening is best classified as more than 3 cm (unacceptable shortening) or less than 3 cm (acceptable shortening) at the time of presentation. The physical examination determines whether an open injury is present, defined as a fracture that communicates with the external environment, usually because of penetration of the fracture fragment in an inside-to-outside fashion. The three-part Gustilo system is used to classify all open fractures and helps determine the specific treatment plan, including the antibiotic regimen.³⁶

Mechanism of Injury. The mechanism of injury in femoral shaft fractures is largely correlated with age. Child abuse is the leading cause of femoral fractures before walking age, accounting for 70 to 80 percent of fractures in this age group.³⁵ Between 1 and 4 years of age, 30 percent of femoral shaft fractures are attributed to abuse. A high suspicion of abuse, therefore, must be entertained, with an appropriate history and a directed physical examination to look for other injuries. In addition to age, other factors that should raise the suspicion of child abuse include a first-born child, preexisting brain damage of the child, bilateral fractures, subtrochanteric or distal metaphyseal beak fractures, and delay by the family in seeking treatment.⁸ A careful analysis is needed, since returning a child to the home where abuse has occurred can lead to more abuse (approximately 50 percent) and death in 10 percent of cases.³³

In the adolescent age group, high-velocity motor vehicle accidents are more often the mechanism of injury, accounting for up to 90 percent of all femoral shaft fractures in this age group.^{39,52} High-energy trauma results in more significant fracture displacement, which should alert the clinician to the high probability that life-threatening intra-abdominal and/or intrathoracic injuries and head injuries are present. Rang has coined the term Waddel's triad to include a femoral fracture associated with head and thoracic injury sustained in an automobile-pedestrian accident.⁶⁶ An organized, thorough initial examination and treatment are imperative in this setting and should reflect the current treatment algorithms for the polytraumatized patient.^{13,52}

The timing of femoral shaft fracture fixation in the pediatric patient has been studied in a large series of polytraumatized patients. Unlike adults, children with multiple injuries and an associated femoral shaft fracture rarely develop pulmonary complications, and the timing of fracture stabilization does not appear to affect the prevalence of pneumonia or respiratory distress syndrome.³⁸

Minor trauma or repetitive fractures should alert the clinician to the possibility of an underlying pathologic condi-

tion, including osteogenesis imperfecta, which is largely a diagnosis based on the typical signs of the disease (dentinogenesis imperfecta, blue sclera, hearing loss, and multiple fractures). The diagnosis can be confirmed by analysis of collagen produced by cultured dermal fibroblasts. Generalized osteopenia from cerebral palsy, myelomeningocele, and other neuromuscular conditions also predispose to fracture.³⁰

Radiographs should always be carefully evaluated for localized pathologic conditions that can predispose to fracture. The most common benign conditions include aneurysmal bone cyst, unicameral bone cyst, nonossifying fibroma, and eosinophilic granuloma (Fig. 42–68). Malignant conditions are far less common and include osteogenic sarcoma, Ewing's sarcoma, and, rarely, metastatic disease.

Another rare entity is the femoral shaft stress fracture, which often presents with a long-standing complaint of pain in the thigh region in an adolescent athlete. No preceding trauma is recalled, and multiple medical opinions are usually sought without a conclusive diagnosis.¹⁷ Timely diagnosis and treatment are essential to prevent subsequent complete fracture.

Physical Examination. The examination of the injured child must be individualized according to the age of the child and the circumstances of the injury. The patient with a femoral shaft fracture has localized tenderness and swelling and usually has a deformity with associated shortening and obvious crepitus on palpation. Careful and circumferential evaluation of the soft tissue envelope, looking for areas of ecchymosis around the buttock and hip area, may suggest an ipsilateral femoral neck or intertrochanteric fracture or hip dislocation. The skin should be thoroughly inspected to identify an open injury, which should be classified according to the Gustilo classification.³⁶

A neurologic and vascular examination of the involved extremity should be performed and the findings compared with findings on the contralateral side. A repeat neurovascular examination following gentle reduction and immobilization in a splint or in boot traction should remain normal. If the neurovascular status declines following manipulation, the splint should be promptly removed and remanipulation carried out.

Because many patients with femoral shaft fractures have sustained high-energy trauma, a multidisciplinary team approach is necessary. The initial resuscitative treatment is generally carried out by a general surgeon and should follow well-established guidelines.³ The secondary definitive, injury-specific examination should not be limited to the primary complaint of the patient and should include inspection of the back and spine. Every extremity must be carefully inspected and palpated to avoid missing injuries, which can become difficult to treat if detected late. This is especially important in the head-injured patient who is unable to communicate symptoms. Repeated examinations are a necessary part of the evaluation in this clinical situation.

Radiologic Examination. Standard radiographs in both the AP and lateral projection of the entire femur, to include the hip and knee joint, are necessary. In the proximal femur, femoral neck and intertrochanteric fractures and hip dislocations can be associated with a diaphyseal fracture and are missed in up to one-third of cases.^{11,27,42,74} In the distal femur,

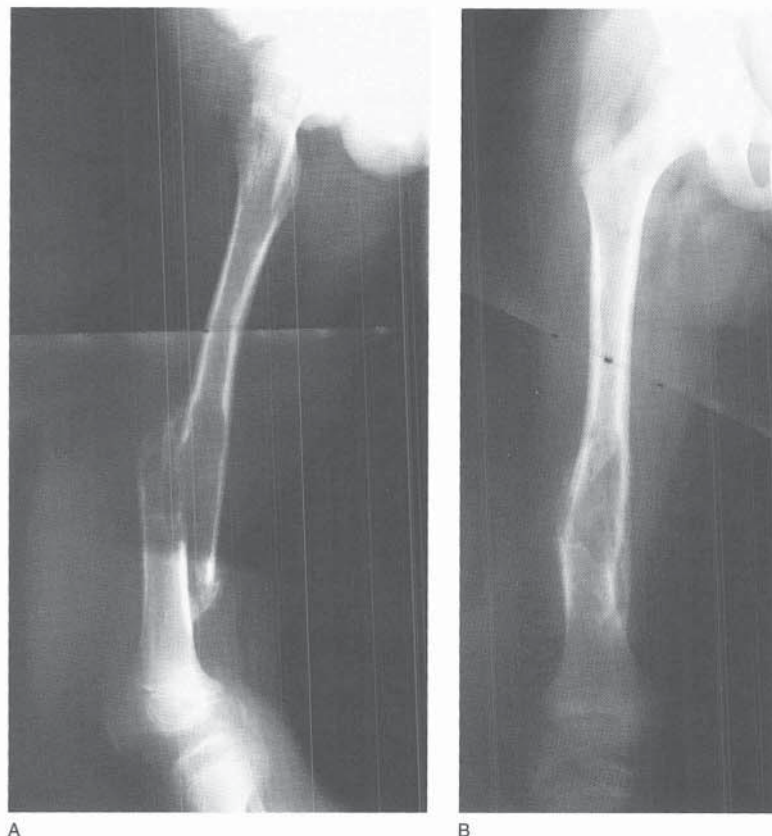

FIGURE 42-68 Pathologic femoral fracture through a unicameral bone cyst in a 10-year-old child. **A**, Preoperative radiograph. **B**, Radiograph obtained 2 months following injury after hip spica cast treatment.

associated physeal injuries and ligamentous and meniscal injuries are often seen.⁷⁹ Poor-quality radiographs are unacceptable, and the study must be repeated before the patient leaves the emergency room or radiology suite. In the older child, a Thomas traction splint that has been applied either in the field or upon arrival in the emergency room often obscures the proximal femur on the initial radiographs (Fig. 42-69). This splint should be adjusted or removed to allow complete imaging of the proximal femoral bony anatomy.

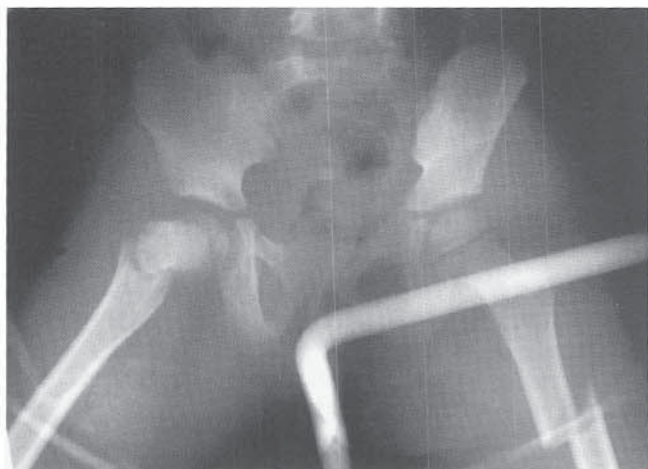

FIGURE 42-69 Femoral fracture. The initial AP radiograph, shown here, demonstrates a fracture of the diaphysis of the left femur; however, the proximal femur cannot be seen because of obstruction by the traction splint. A basicervical neck fracture is seen on the right.

The radiographs should be evaluated for fracture configuration, degree of comminution, displacement, angulation, and degree of shortening. This information is important in understanding the mechanism of injury and the force imparted to the bone and soft tissue, information ultimately used in planning treatment. The deforming forces of the surrounding musculature result in characteristic displacement patterns (Fig. 42-70). For example, a proximal one-third fracture will result in flexion (iliopsoas), abduction (abductor muscle group), and lateral rotation (external rotators) of the proximal fragment.

Plain radiographs are usually all that is needed to evaluate femoral shaft fractures. Rarely, stress fractures require CT¹⁷ or MRI to confirm the diagnosis. CT is best used to evaluate intra-articular fractures of the femoral head and distal femur, hip dislocations (to assess intra-articular loose fragments following reduction), and physeal injuries. MRI and/or CT are useful in the pathologic femur fracture. Angiography is indicated in the setting of diminished or absent pulses associated with a femoral shaft fracture, all knee dislocations,^{78,84} and when an ipsilateral tibial fracture is present (floating knee).

Treatment. Several methods are available to treat femoral shaft fractures in children. The age and size of the child are the most important factors in deciding which treatment modality is most appropriate. In general, we prefer to treat the younger child nonoperatively in a Pavlik harness or hip spica cast and the older child with some form of skeletal fixation. Additional factors to consider include the mechanism of injury, the presence of multiple injuries, the soft tissue condition, the family support environment, and the

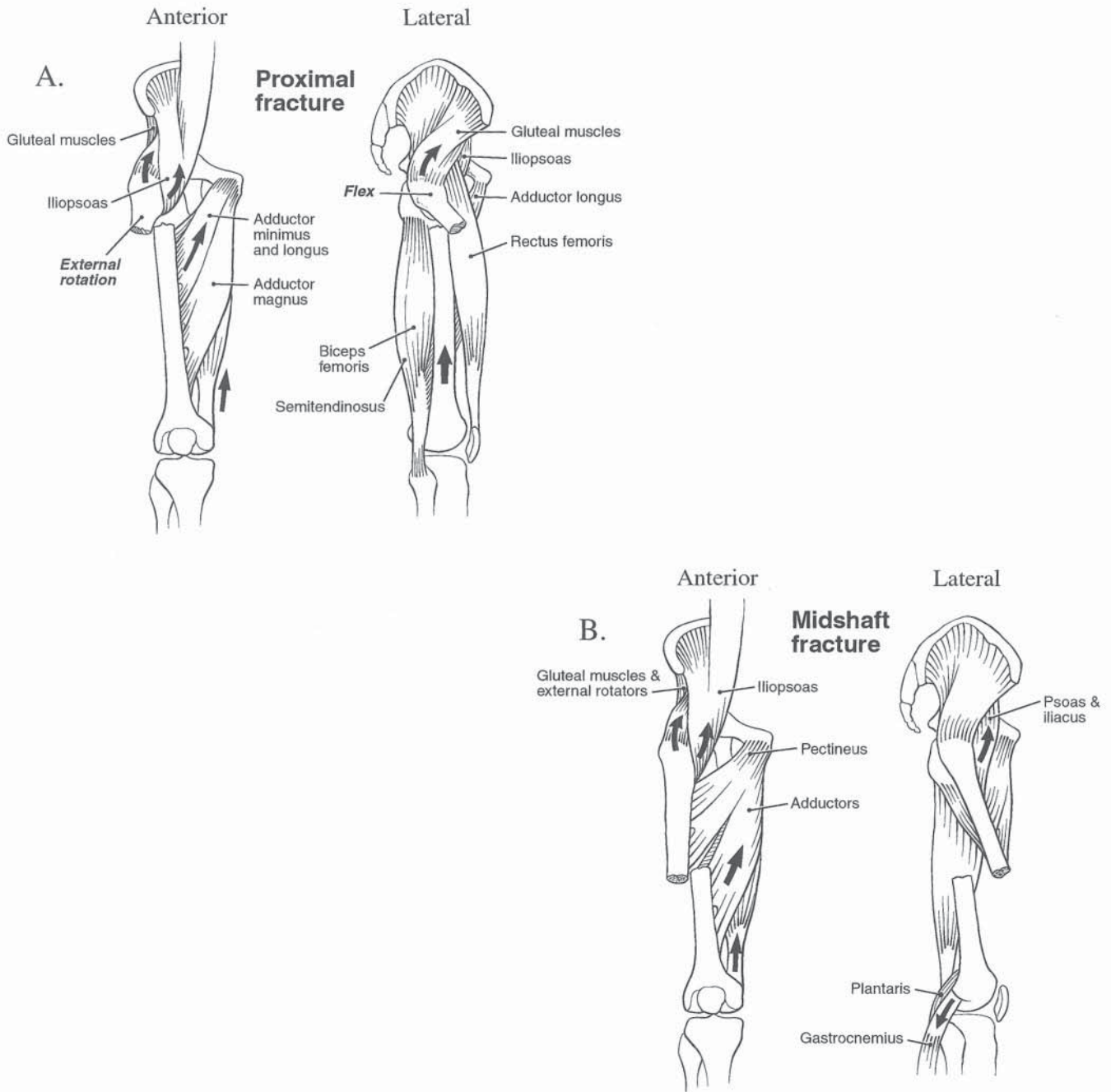


FIGURE 42-70 Characteristic displacement patterns in femoral shaft fractures. **A**, Displacement of fragments in fractures of the upper third of the femoral shaft. **B**, Displacement of fragments in fractures of the middle third of the femoral shaft.

economic resources available. Finally, as in any form of orthopaedic treatment, the experience, skill, and preference of the treating physician play a significant role in determining treatment. We use the following guidelines, based on the age of the patient, to determine treatment:

0 TO 6 MONTHS. In the young child, age 4 months or less, or in a small child up to 6 months old, immediate application of a Pavlik harness results in an excellent outcome, with time to union averaging 5 weeks.⁷² The advantages of the Pavlik harness include the ease of application without requiring a general anesthetic or sedation, minimal hospital-

ization, the ability to adjust the harness when fracture manipulation is required, and the ease of nursing and diapering. Excessive hip flexion in the presence of a swollen thigh may lead to a femoral nerve palsy, and therefore weekly evaluations of quadriceps function should be performed during treatment (Fig. 42-71).

7 MONTHS TO 5 YEARS. When shortening of the fracture is limited to less than 2 to 3 cm, with a stable simple fracture pattern, we prefer to treat the child with closed reduction and immediate spica cast application (Fig. 42-72). Skin or skeletal traction is required when excess shortening (more

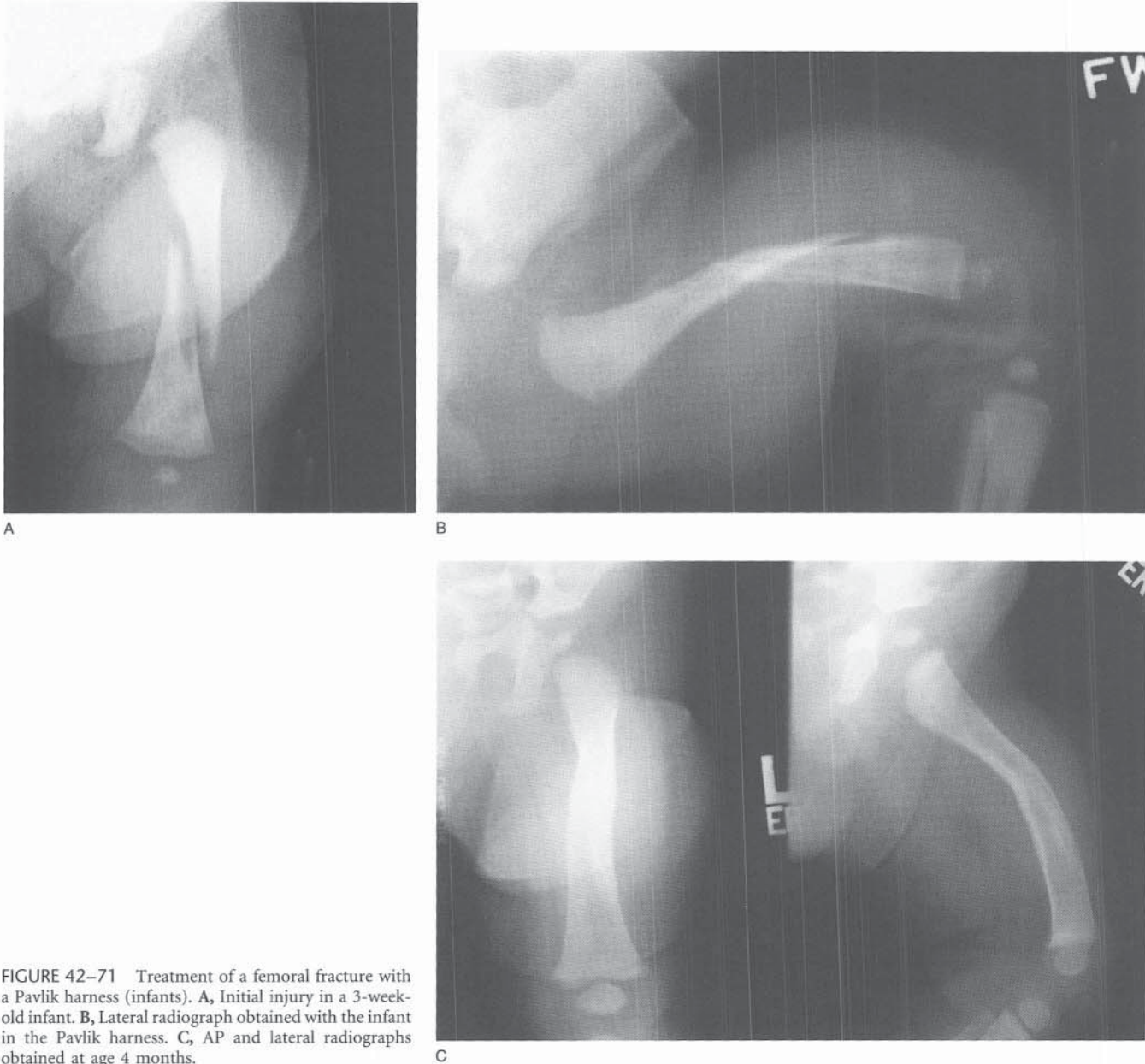


FIGURE 42-71 Treatment of a femoral fracture with a Pavlik harness (infants). **A**, Initial injury in a 3-week-old infant. **B**, Lateral radiograph obtained with the infant in the Pavlik harness. **C**, AP and lateral radiographs obtained at age 4 months.

than 3 cm) or angulation (more than 30 degrees) is present. In the multiply injured patient, immediate stable fixation is often required and is best accomplished with external fixation or plate fixation. In larger 5-year-old children we may use Enders intramedullary rods with a stable fracture pattern.

6 TO 10 YEARS. Femoral shaft fractures in children between 6 and 10 years of age are treated by closed or open reduction and stabilized with flexible rods (Enders or Nancy), especially when a stable transverse fracture pattern is present. Additional modes of treatment include initial skeletal traction followed by spica cast treatment, plate fixation, or external fixation (Fig. 42-73).

11 YEARS TO SKELETAL MATURITY. Enders intramedullary rodding is again an excellent choice in a stable fracture pattern.

In this age group the rigid locked intramedullary rod is preferred in some centers for a stable fracture pattern, but it must be placed with the proximal starting point at or just distal to the greater trochanter to minimize the risk of AVN of the femoral head.

Treatment Techniques

TRACTION. Skin traction is a noninvasive technique that is used in the following settings: (1) a small child whose fracture is too shortened (more than 3 cm) to allow the child to undergo immediate spica casting. The traction is used to align the fracture until enough callus formation has occurred to allow spica cast application. (2) Any child who is to undergo definitive skeletal fixation on a delayed basis. The skin traction will temporarily stabilize and align the leg,

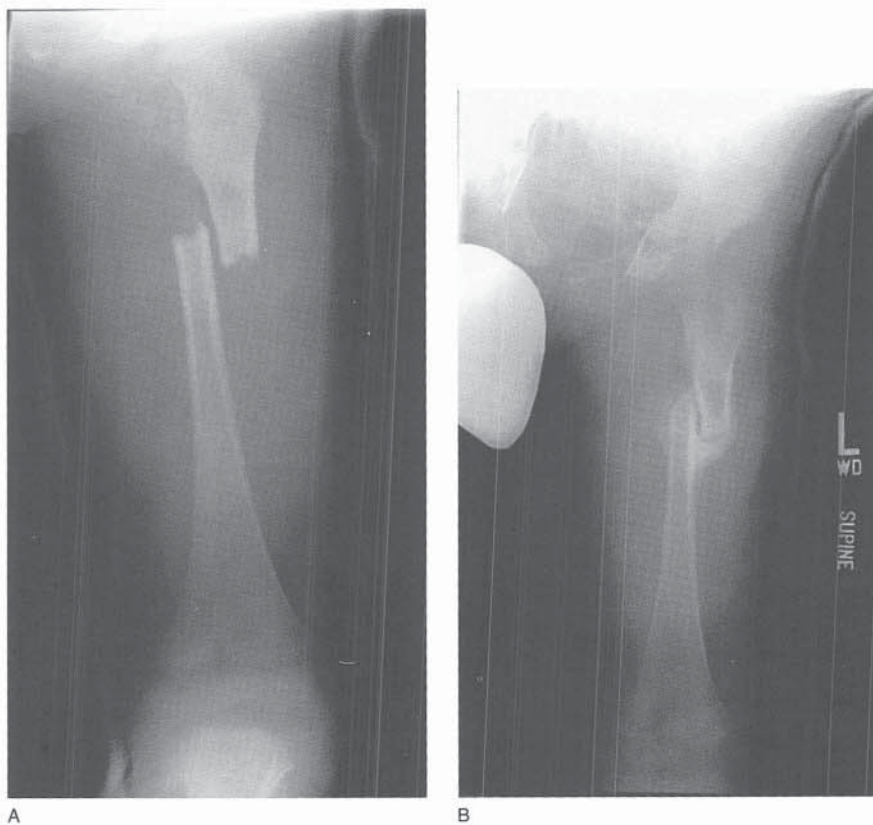


FIGURE 42-72 Treatment of a femoral fracture with immediate spica casting in the young child. A, Initial postreduction radiograph showing 2 cm of shortening in a child age 3 years 6 months who was treated with immediate closed reduction and immediate spica casting. B, Radiographic appearance after 7 weeks in the cast.

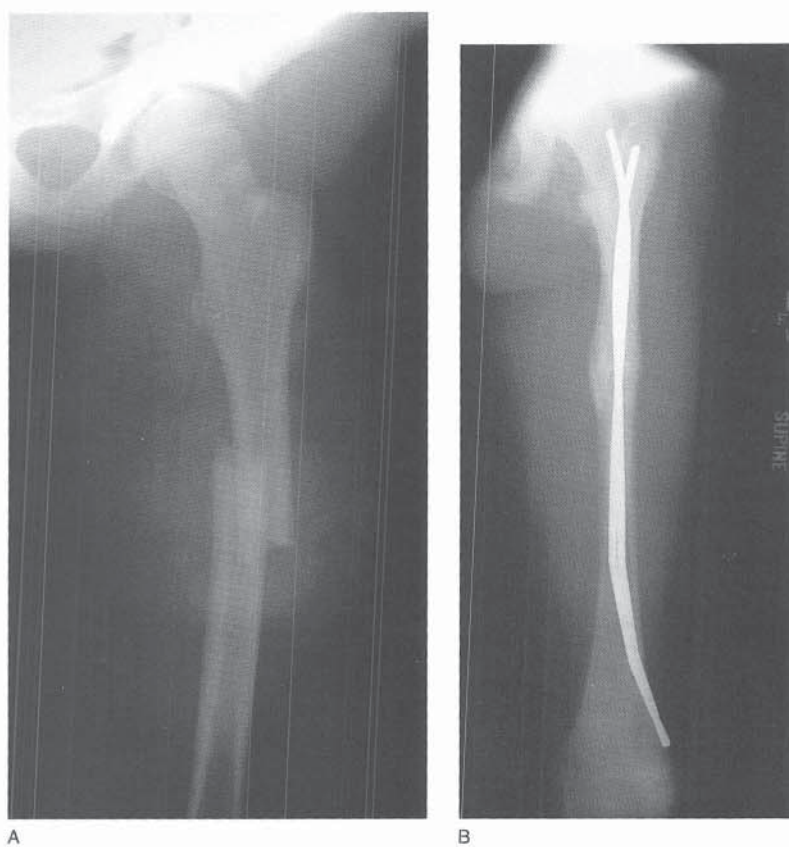


FIGURE 42-73 Stabilization of femoral shaft fractures in children ages 6 to 10 years. A and B, A 7-year-old child with a transverse fracture of the femur treated with two Enders flexible nails placed in retrograde fashion.



FIGURE 42-74 Traction for treatment of a femoral shaft fracture. **A**, Application of skin traction initially entails placing cotton cast padding onto the skin and taping followed by placement of a U-shaped strap, which is then overwrapped with an Ace or elastic bandage. **B**, Small child placed into Bryant's traction. In this overhead skin traction technique, just enough weight is placed to elevate the buttock off the surface of the bed.

providing some stability and comfort in the interim period (Fig. 42-74A).

Although skin traction is very effective in these settings, there are potential problems and complications that should be kept in mind. In the very young child, less than 2 years of age, Bryant's traction is used (Fig. 42-74B).¹⁵ This consists of overhead skin traction with the hips flexed to 90 degrees and the knees fully extended. Since the traction is applied through the skin, patients with abnormal sensation in the lower extremities should not be treated in this fashion. Vascular insufficiency is the most serious complication and results from the vertical position of the legs (increased resistance to distal leg perfusion), extension of the knees (stretching of the popliteal artery) and compression of the external wrapping on the leg.⁶⁰ The complications of overhead Bryant's traction can be avoided by applying traction in a position of 90 degrees of hip flexion and 45 degrees of knee flexion²⁹ and is what the author recommends when skin traction is to be used. Skin blistering and sloughing must be avoided with any form of skin traction; these problems

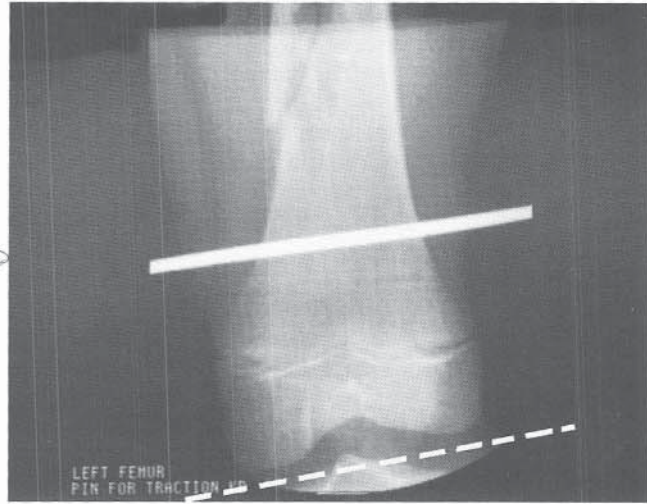


FIGURE 42-75 A distal femoral traction pin placed perpendicular to the femur and parallel to the knee joint line (dotted line).

are minimized when the amount of weight used is no more than 5 to 10 lb, depending on the size of the child. When more weight is required to control the fracture, we prefer to use skeletal traction.

Skeletal traction is a more powerful technique to apply traction to the femur. It is used in the older child with a diaphyseal fracture, when more than 5 to 10 lb of weight is required, and in any child with a proximal femur fracture in whom 90-90 traction is needed. The distal femur is the best site for placement of the traction pin, which should be placed parallel to the knee joint to prevent varus or valgus deformity (Fig. 42-75).²³ Under sedation and sterile conditions, the distal femoral traction pin should be inserted just superior to the adductor tubercle and advanced laterally (Fig. 42-76). When soft tissue injury and contamination prevent femoral traction pin placement, the traction pin can be placed in the proximal tibia, but only after a careful knee examination has been performed to exclude ligamentous injuries. The proximal tibial traction pin should be placed

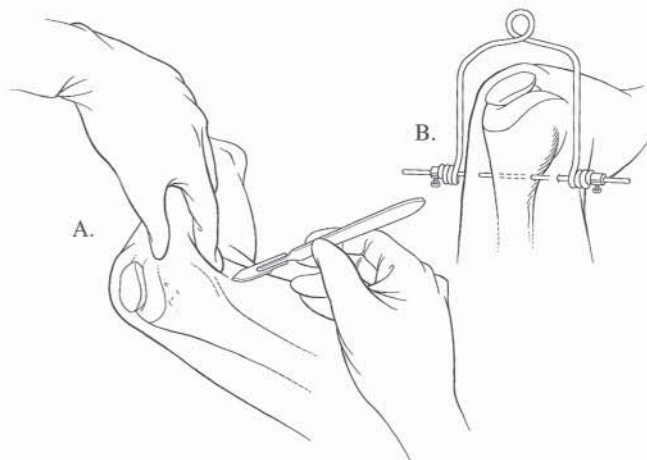


FIGURE 42-76 Placement of a femoral traction pin just superior to the adductor tubercle. **A**, The site is prepared using sterile technique. A local anesthetic is used. **B**, Traction pin in place with a traction bow.

distal to the tibial tubercle physis to avoid anterior growth arrest and the development of a recurvatum deformity.^{4,46,59}

Traction should reduce the fracture to within 2 cm in the younger child, and end-to-end apposition should be achieved in the child older than 11 years.⁴ Radiographs of the femur should be obtained in both the AP and lateral views to check alignment and callus formation. Traction can be continued for 2 to 3 weeks, until callus formation is present and the child has no or minimal tenderness on palpation at the fracture site. Traction pins can be incorporated into a hip spica cast at an early period to better control the fracture; however, this is frequently complicated by pin tract infection and pin breakage. (We do not recommend this technique.)

SPICA CASTING. Immediate spica casting has been advocated in the following instances: (1) in a child with an isolated stable femoral shaft fracture with less than 3 cm of shortening; (2) in a child less than 8 years old; and (3) for a fracture without massive swelling of the thigh.^{47,72} If these conditions are not present, a period of traction should be used. Another important factor is the social situation in which the child is living, since the most difficult problems encountered by families have to do with transportation of the child and keeping the child clean in the cast. Preschool children tolerate a spica cast much better than school-age children, since younger children can be transported more easily and heal more rapidly.⁴⁴

The cast should be placed with the child's hips flexed approximately 60 to 90 degrees (the more proximal the fracture, the more the hip should be flexed), with 30 degrees of abduction; the knees should be flexed to 90 degrees (Fig. 42-77). Some external rotation will correct the rotational deformity of the distal fragment. Several authors have recommended placing a long-leg cast initially and then transferring the patient to the hip spica table and applying the remainder of the cast.^{2,47} We and others⁷¹ recommend placing

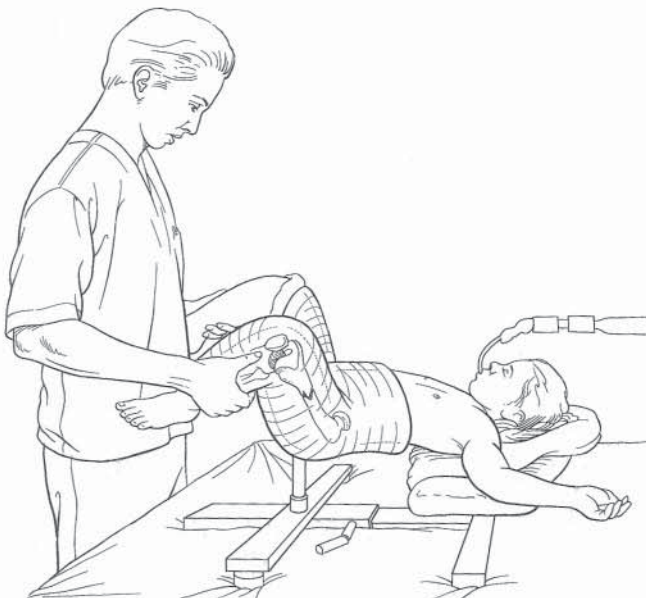

FIGURE 42-77 Hip spica casting for a left femoral shaft fracture in a young child. The hips are flexed to approximately 60 degrees and the knees to 90 degrees.

the patient on the spica table and applying the cast while an assistant holds the fracture in a reduced position. The cast material is rolled, and a good condylar and buttock mold is then placed into the cast. Radiographs in the lateral and AP planes are obtained before the cast hardens to allow mild manipulations as needed in the cast. In general, the fracture tends to drift into varus and flexion, and this should be kept in mind while applying the cast. Acceptable alignment depends on the age of the patient but in general is considered to be no more than 15 degrees of deformity in the coronal plane and 25 to 30 degrees in the sagittal plane.^{1,47} Shortening should not exceed 2.0 cm. Radiographs should be obtained weekly during the first 2 to 3 weeks to allow correction of any loss of the initial reduction. Excessive shortening within this time period is corrected only by removal of the cast and a short period of time in traction followed by recasting. Wedging of the cast will allow some correction of angular deformity (up to 15 degrees) but must be done with caution, since peroneal palsies have been reported during correction of valgus deformities (Fig. 42-78).⁸⁵ Femoral fractures that are more susceptible to losing reduction are those in which the fracture occurred from a high-energy mechanism and those fractures associated with polytrauma. Careful follow-up with weekly radiographs should be performed.

EXTERNAL FIXATION. The main indications today for external fixation are (1) an open fracture; (2) severe disruption of the soft tissue envelope, including severe burns; (3) multiple trauma; (4) an extremity with an arterial injury requiring immediate revascularization of the extremity; (5) an unstable fracture pattern; and (6) failed conservative management.* External fixation is generally indicated in children ages 5 to 11 years.

The most commonly used fixators today are the Orthofix Dynamic Axial Fixator (EBI)⁴⁵ and the AO Fixator (Synthes). These unilateral fixators are relatively easy to apply and allow angular correction during the follow-up period (Fig. 42-79). The fixators are generally left on for 10 to 16 weeks, until solid union has been achieved. Weightbearing is permitted as early as tolerated by the patient and is dependent to some degree on the stability of the fracture and the external fixator. Blasier and colleagues reported a large series of 139 femur fractures treated with an external fixator in children whose average age was 9 years. Progressive weightbearing was encouraged, and the time in the external fixator averaged 11.4 weeks, with no reported nonunions.¹²

The most common complication of treatment with an external fixator is pin tract infection (approximately 50 percent of cases), which generally responds to good pin care and antibiotics. The rates of nonunion, delayed union, and angular deformity are generally reported to be slightly higher than when more rigid fixation techniques are used. Refracture is also more common, with a reported incidence of 1.5 to 21 percent (Fig. 42-80).^{5,12,64,76,77} These complications are most common in fractures with a short oblique fracture pattern. Because refracture occurs at the previous fracture site, owing to incomplete union, the fixator should be left in place until solid union is seen radiographically. Shortening and overgrowth have not been a major issue,

*See references 1, 5, 12, 21, 24, 45, 77.

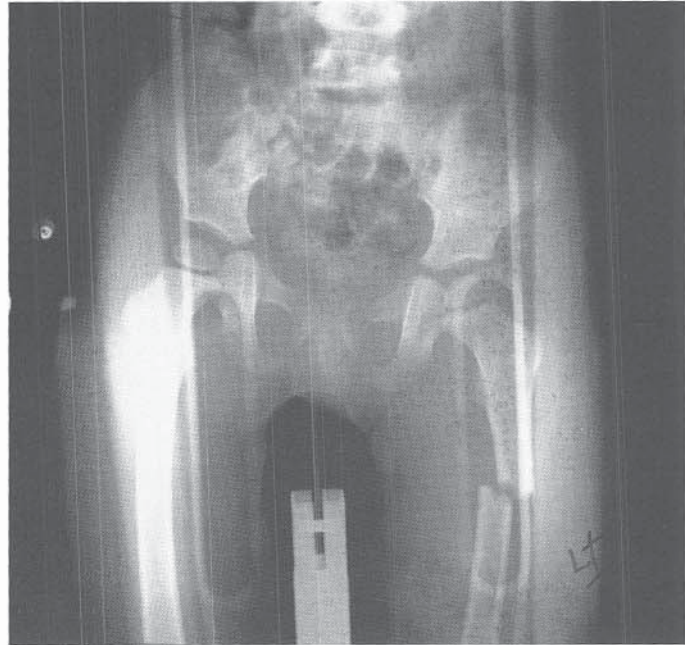
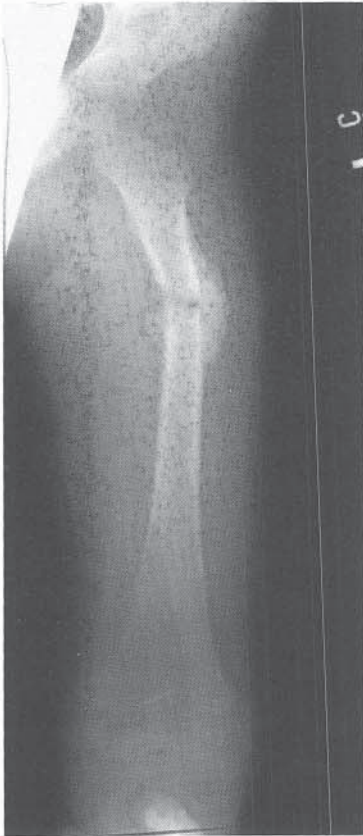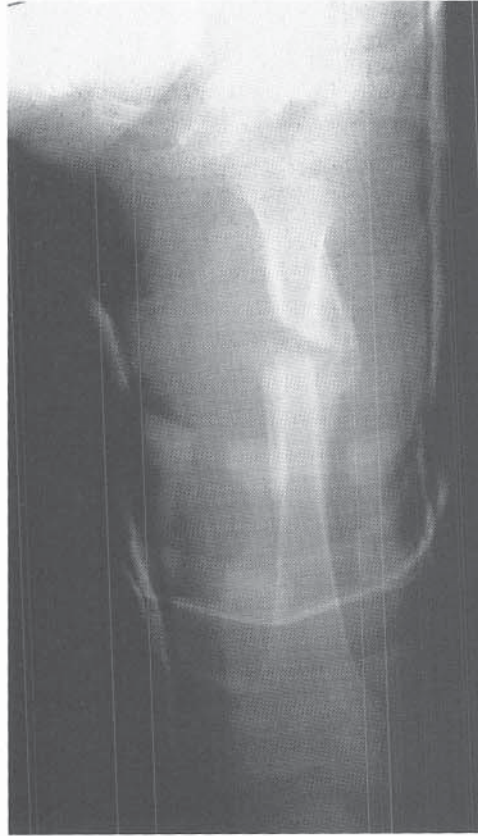


FIGURE 42-78 Manipulation and wedging of a malunited femur fracture. A, Initial radiograph of a left femoral fracture in a 3-year-old. B, At 5 weeks, there was excess varus angulation. C, A percutaneous osteoclasis was performed, followed by casting. The initial casting resulted in residual varus. Wedging of the cast with an opening medial wedge osteotomy corrected the deformity. D, Six weeks following osteoclasis and cast wedging, the fracture has healed in good alignment.

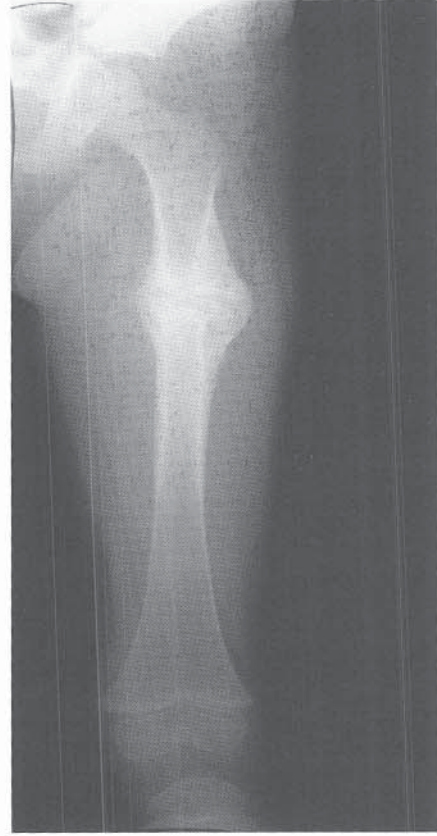A



B



C



D

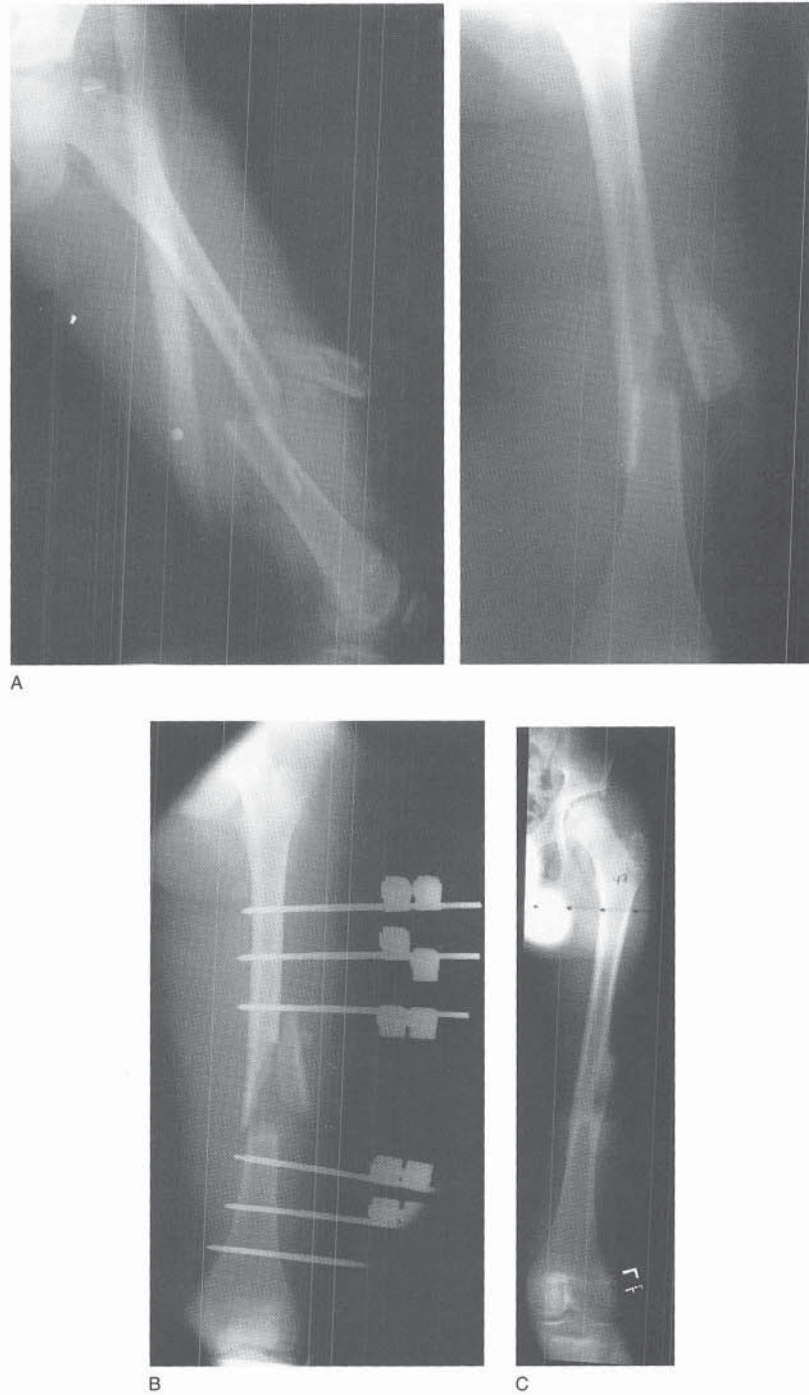


FIGURE 42-79 External fixation of a femoral shaft fracture. A, Initial radiograph in a 12-year-old child with an open femoral fracture. B, Appearance following application of an external fixator. C, Final healing at 1-year follow-up. Bone grafting had been performed at 4 months.

and complete apposition of the fracture fragments should be achieved at the time of the initial reduction.

OPEN REDUCTION AND INTERNAL FIXATION. Proponents of internal fixation with plates and screws recommend this form of treatment for children with multiple trauma or patients with closed-head injuries. The main advantages to this technique are that fracture stabilization is performed quickly, an anatomic reduction is achieved, and the fracture is rigidly

fixed, allowing early mobilization. Open reduction with plate fixation is relatively easy to perform, and this method can be used in any age group (Fig. 42-81). The disadvantages are the large incision and soft tissue stripping, the risk of plate breakage and refracture, and the need for plate removal, with a risk of recurrent fracture. Because anatomic reduction with end-to-end bony apposition is achieved, overgrowth can be seen, although it has not been reported to be a clinical problem.⁸³

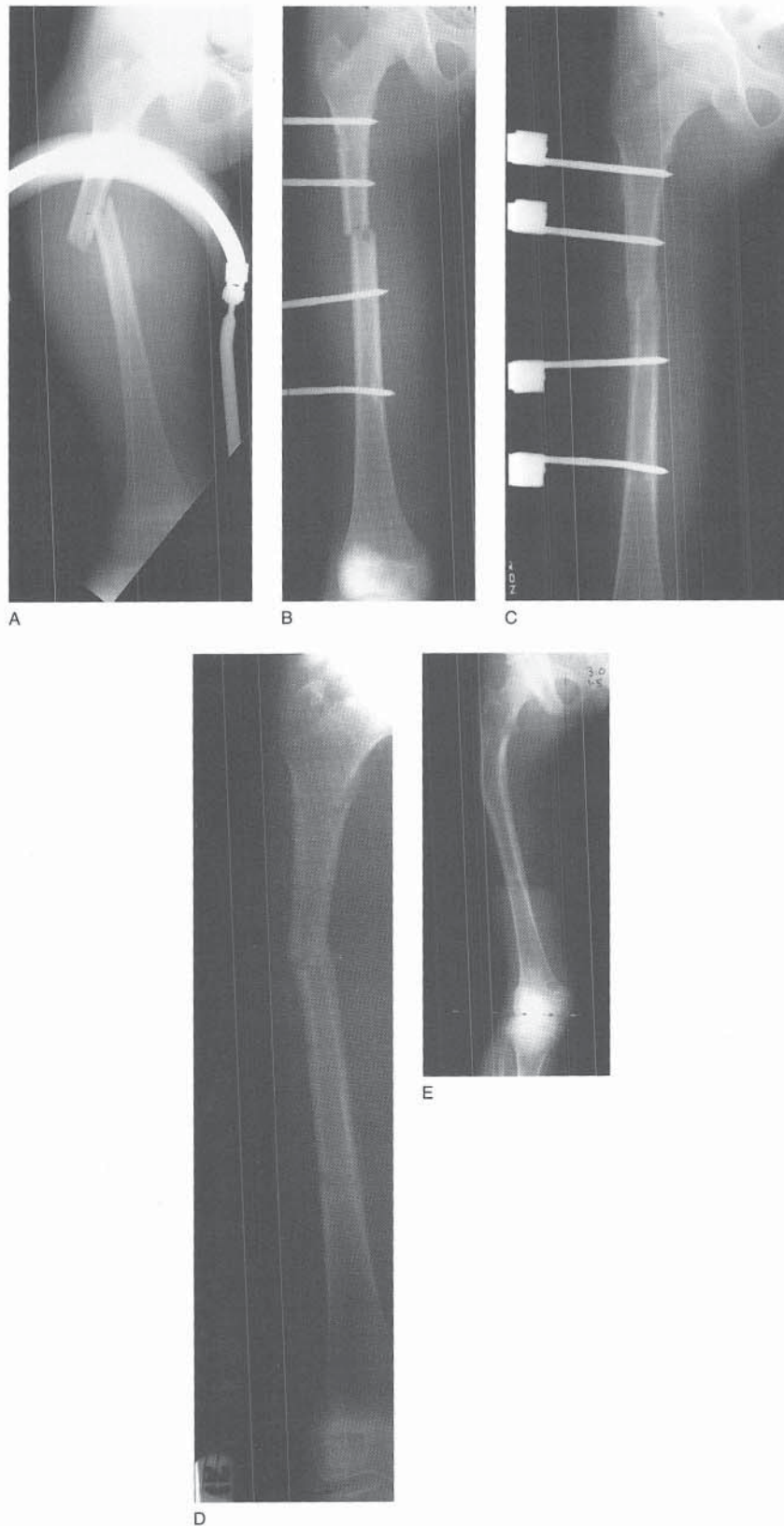
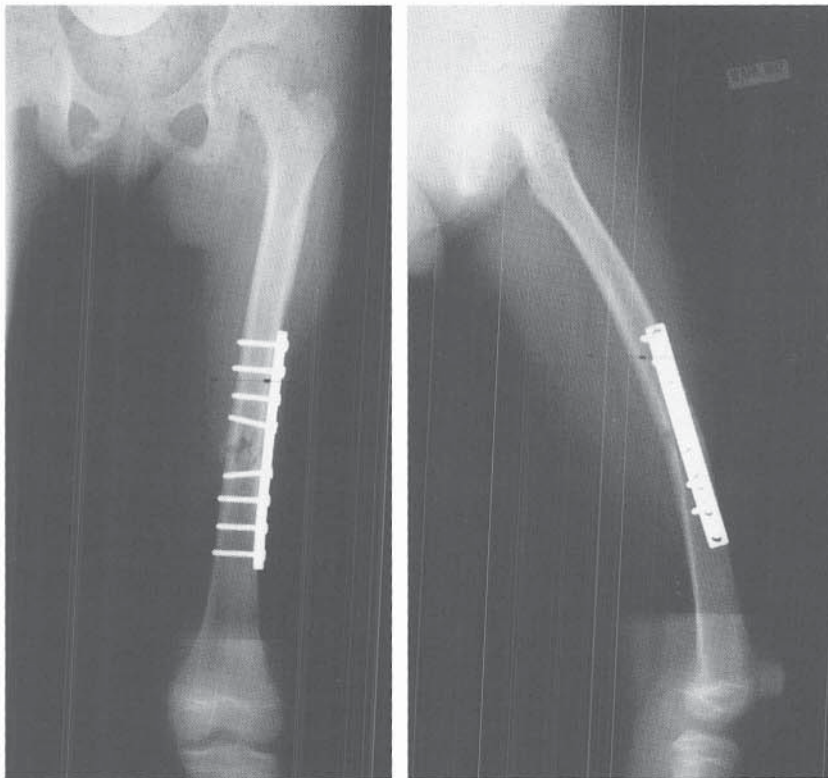
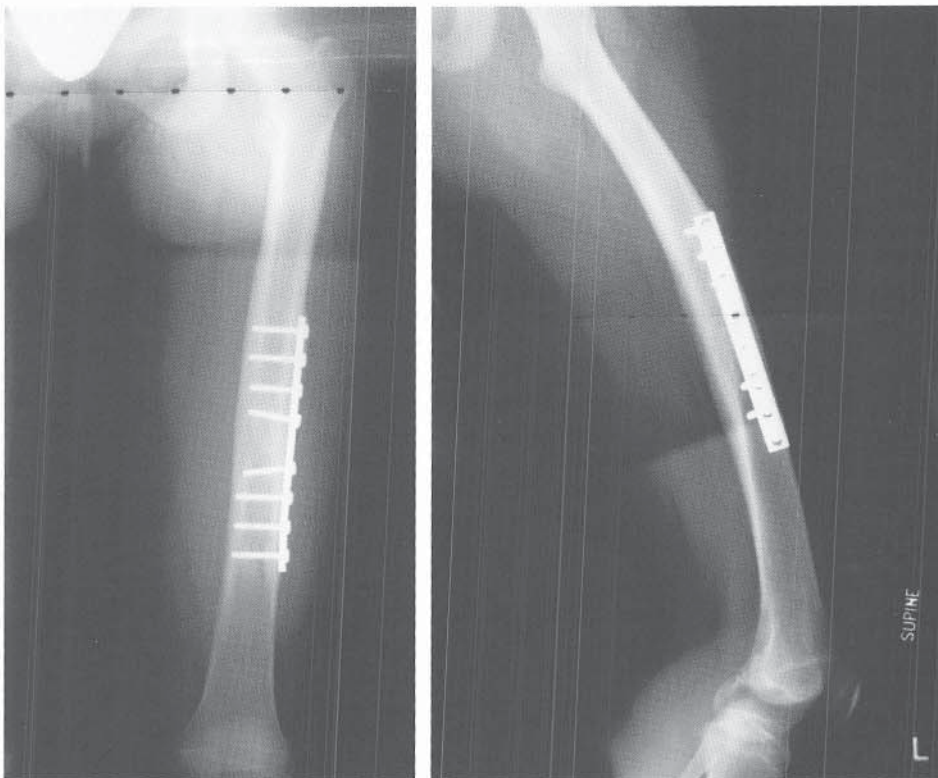


FIGURE 42-80 Femoral shaft refracture following removal of an external fixator. **A**, Initial radiograph obtained in a 12-year-old child with a proximal femoral shaft fracture. **B**, Radiographic appearance following application of an external fixator. **C**, Radiographic appearance at 9 weeks. Fracture healing was felt to be adequate at this point, and the external fixator was removed. **D**, Refracture through the original fracture site occurred days after fixator removal. A hip spica cast was used to treat the refracture. **E**, Radiograph obtained after complete healing demonstrating varus deformity at the refracture site.



A



B

FIGURE 42–81 Plate fixation of a femoral shaft fracture. **A**, Radiographic appearance in a 12-year-old with a transverse femoral fracture. **B**, At 8 months after injury abundant callus has formed and there is solid healing. The plate was not removed.

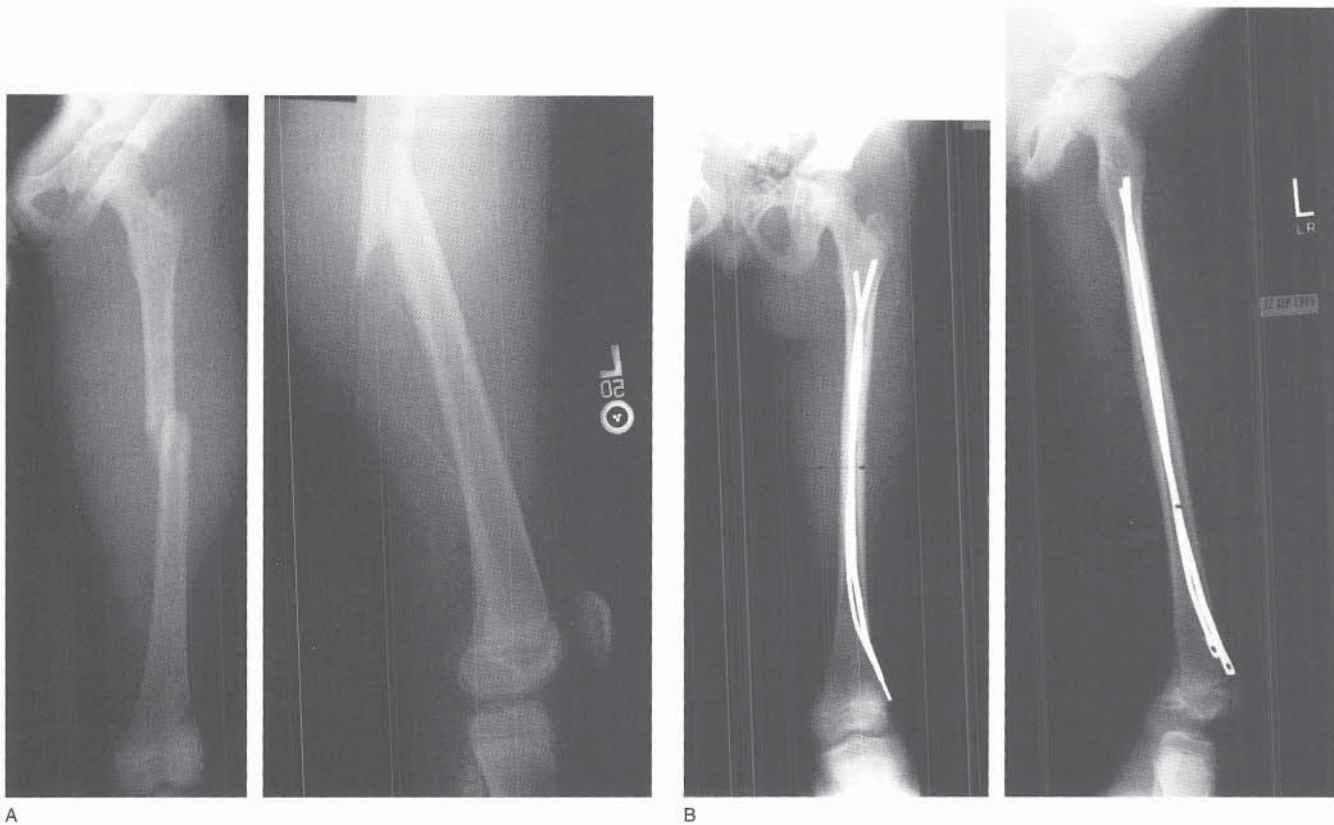


FIGURE 42-82 Flexible Enders nailing of a femoral shaft fracture. A, Injury radiographs of an 8-year-old who was struck by a car. A mid-shaft transverse stable fracture pattern is seen. B, Radiographs 3 weeks following retrograde Enders nailing.

Most reports of the use of open reduction with internal fixation in the child's femur are of patients with multiple injuries. Ward and colleagues reported on 25 patients, 22 of whom had multiple injuries. Fracture union occurred in 11 weeks in 23 of the 24 patients available for follow-up. They concluded that this technique is acceptable in the child who is less than 11 years old with a severe head injury or associated polytrauma.⁸³ Similarly, Kregor and colleagues reported on 15 fractures, six of which were open, in patients who had sustained multiple injuries or a head injury. Radiographic union of the fracture occurrence at an average of 8 weeks. The compression plates were removed at an average of 10 months postoperatively, with no restriction of activities at an average follow-up of 26 months.⁵⁰

INTRAMEDULLARY FIXATION. Intramedullary fixation has assumed a more prominent role in the treatment of femoral shaft fractures in children and adolescents. The main advantages to intramedullary fixation are that external immobilization is usually not required and, because of the load-sharing capability of the rod(s), immediate or early weight-bearing is allowed. The two implants most often used are the flexible Enders nails in younger children and the rigid locked intramedullary nail for older children and adolescents.

FLEXIBLE INTRAMEDULLARY FIXATION. Flexible nail fixation has generally been reported to result in excellent fracture union with few complications in the pediatric population (Fig. 42-82).^{*} The additional advantage of the flexible nail over

the rigid interlocking rod is that the proximal insertion site avoids the piriformis fossa and the greater trochanter, preventing the possibility of AVN of the femoral head and growth arrest, respectively. In addition, the distal insertion site does not require dissection into the knee joint or violation of the distal physis. The Enders flexible nails can be used in the child 6 to 16 years, although it has been reported to be used in children as young as 4 years. Flexible nailing may be done in the child with multiple injuries, concomitant head injury, open fractures, and in an extremity with an ipsilateral tibial fracture (floating knee).

The fracture pattern most amenable to this treatment is a transverse stable fracture with minimal comminution. Long spiral fractures are a relative contraindication since rotational deformity and shortening are likely to occur. Flexible nails can be used with caution in long oblique and spiral fractures; however, the stability of the fracture site should be evaluated at the time of surgery. Any concern about the stability of the fracture in this setting should prompt the surgeon to apply a single-limb hip spica cast to supplement the fixation for a short period of time. Rathjen and DeLaGarza compared 41 stable and 40 unstable femur fractures treated with flexible intramedullary nails and demonstrated comparably good results. All patients healed within 7 weeks with no clinically apparent angular or rotational deformity, and only one patient with Winquist IV comminution had greater than 2 cm of shortening. Rathjen and DeLaGarza concluded that flexible intramedullary fixation of the unstable femur fracture in children was effective and should be supplemented with a single-limb hip spica cast when severe

*See references 7, 19, 28, 40, 43, 48, 54, 55, 69.

comminution is present.^{1a} Carey and Galpin reported on 25 femur fractures, eight of which were long oblique or spiral fractures treated with antegrade flexible nailing.¹⁹ No significant problems occurred with regard to angular or rotational deformity or shortening. Postoperatively, weightbearing is generally started immediately, as tolerated by the patient, especially in children with a stable fracture pattern, although some authors wait 4 to 8 weeks before allowing full weightbearing.^{28,55} We prefer to have the patient gradually progress to full weightbearing over 1 to 2 weeks without any external immobilization, although unstable or distal fractures may require a knee immobilizer or walking single-limb hip spica cast (Fig. 42–83).

The flexible nails may be placed antegrade or retrograde, depending on the location of the fracture site and the overall preference and experience of the surgeon. We prefer to place the insertion site in the larger of the two fragments to promote greater stability at the fracture site. Two flexible nails should be used, one in a C shape and the other in an S shape, to allow three-point fixation of the fracture site. When beginning distally we prefer to have a single starting hole laterally and place two flexible nails through this insertion site, the C-shaped rod ending in the metaphyseal region of the greater trochanter and the S-shaped rod ending at the mid-area or base of the femoral neck (Fig. 42–84). Others prefer to use both lateral and medial entry sites distally with two “C” sloped rods. We prefer to use the 4.5-mm rods whenever possible, using the 3.5-mm rods in a child with a small intramedullary canal or when a second 4.5-mm rod cannot be placed. The nail should be left in place until solid union has occurred; we do not recommend removal until 1 year following their placement. The need to remove an asymptomatic flexible intramedullary nail is a controversial subject on which no consensus has been reached. The theoretical advantages to nail removal are that a stress riser at the insertion site is eliminated, and nail removal is far easier at 1 year compared to years later, when the nail end is covered by bone.

The incidence of complications when using a flexible nail is very low. Complications include loss of fixation, refracture after rod removal, nail migration, mild angular deformities, and shortening. Heinrich and associates reported an 11 percent incidence of varus or valgus malalignment, an 8 percent incidence of anterior or posterior malalignment and an 8 percent incidence of rotational malalignment, while 68 percent of patients had equal limb lengths at follow-up.⁴⁰ Skak and colleagues reported a 16-year follow-up of 52 femoral shaft fractures treated by either plate fixation, rigid intramedullary rodding, or flexible nailing. An average shortening of 9 mm occurred in the flexible nail group, and shortening was more likely to occur in older patients than in younger ones.⁶⁹

Comparison studies of other techniques generally indicate that flexible nails yield excellent results in treating femoral diaphyseal fractures.^{7,48,69} Kissel and Miller compared external fixation with flexible intramedullary nailing and concluded that retrograde nailing provides superior results, with the main advantage being early discharge from the hospital and return to school.⁴⁸ Similarly, Bar-On and associates compared external fixation with flexible intramedullary nailing and found less limb length discrepancy, malalignment, and other complications and greater parental satisfac-

tion when flexible nails were used.⁷ They concluded that flexible intramedullary nailing is the treatment of choice for femoral shaft fractures in children ages 5 to 13 years, and that external fixation should be reserved for open and severely comminuted fractures. In 1998 Greene reviewed the treatment options for the child with a displaced femoral shaft fracture and concluded that flexible intramedullary nails have several advantages over other techniques and are the treatment of choice.³⁴

INTRAMEDULLARY NAILING. Rigid interlocking intramedullary nailing has been successfully used in the treatment of femoral shaft fractures in adults. The rigid fixation imparted by the nail, along with the rotational control from the interlocking screws, allows this device to be used in highly unstable fractures, allows weightbearing immediately postoperatively, limits the risk of angular deformity, and can be dynamized to promote fracture healing. These advantages have led some to use the rigid intramedullary nail in the adolescent population, with relatively good results (Fig. 42–85).^{9,10,31,75,87} A recent series reported 55 femoral shaft fractures treated with an intramedullary rod in children with an average age of 12.8 years.¹⁰ All fractures united without rotational or angular deformity, and the average limb length discrepancy was 0.7 cm. Complications occurred in 13 patients: five patients had an articulo-trochanteric distance difference of more than 1 cm, seven patients had a limb length discrepancy of more than 2 cm, and in one patient AVN of the entire femoral head developed. All complications occurred in younger patients (average age, 11.7 years) in whom an adult-type nail with a large diameter (10 and 11 mm) and larger proximal diameter (13 mm) had been placed. The recommendations from this study were to use pediatric-type nails with smaller diameters (8 to 10 mm) and to place the insertion site at the greater trochanter.

Although relatively rare, the most severe complication from intramedullary nailing of a femoral shaft fracture in an adolescent is AVN of the femoral head (Fig. 42–86). It is thought that injury to the medial circumflex artery occurs during insertion of the nail medial to the tip of the greater trochanter, as was recognized by Küntschner during the development of his intramedullary nail.⁵¹ There have been approximately 17 reported cases of AVN following intramedullary nailing in children and adolescents; all cases occurred in children in whom a large, adult-sized nail had been placed through the piriformis fossa.* Because of this complication, newer nails have been developed with a smaller diameter throughout the entire length of the nail (8 to 10 mm) and a design that allows insertion through the greater trochanter. However, entrance of the nail through the greater trochanter can lead to premature greater trochanteric epiphysiodesis, coxa valga, and hip subluxation.^{32,65} Orlor and colleagues have suggested that the entry point in a child or adolescent with an open proximal femoral physis should not be in the piriformis fossa (to avoid AVN), but below the greater trochanteric physis (to avoid epiphysiodesis and subsequent deformity).⁶³

In a recently reported series, 60 pediatric patients with femoral shaft fractures were treated with intramedullary

Text continued on page 2319

*See references 6, 9, 26, 41, 56, 57, 61, 63, 81

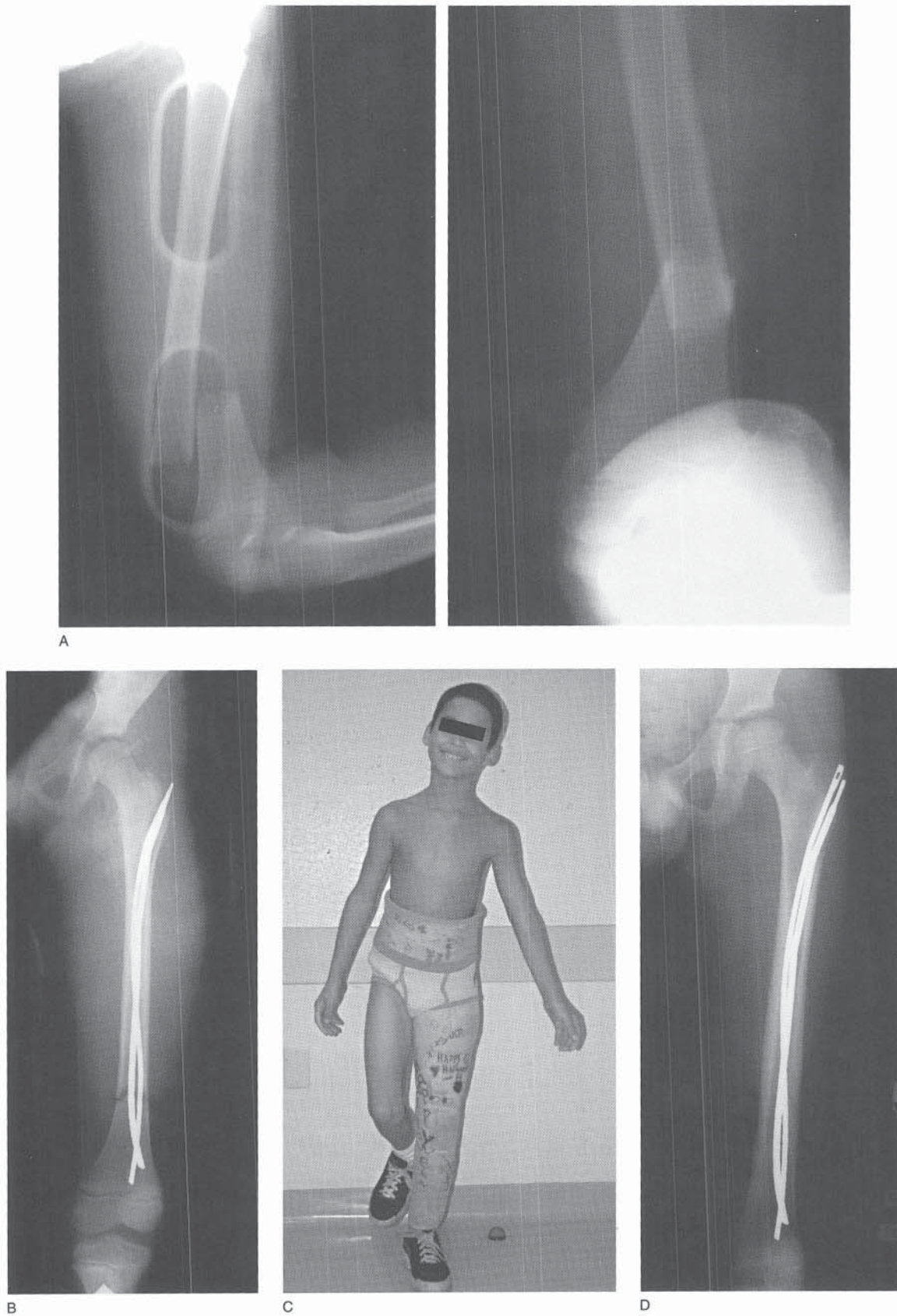


FIGURE 42-83 Radiographic and clinical appearance of a 9-year-old boy who had a distal femoral shaft fracture that was treated with Enders nailing, supplemented with a single-limb hip spica walking cast for 4 weeks for rotational control of the fracture. **A**, Initial radiographs demonstrating the distal location and displacement of the fracture. **B**, Postoperative radiograph. **C**, Clinical photograph at 10 days showing the single-limb walking hip spica cast. **D**, Radiograph obtained at 4 months demonstrating complete healing.

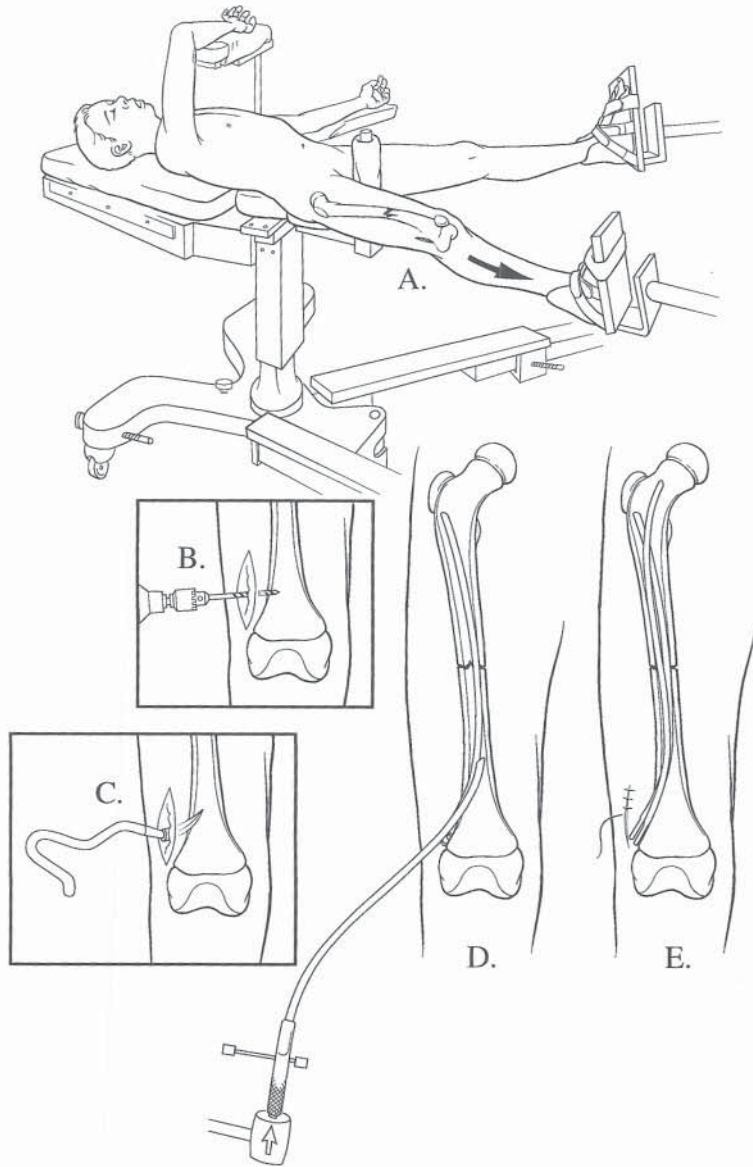


FIGURE 42-84 Enders nailing of a femoral fracture. **A**, Patient position on the fracture table. **B**, A lateral skin incision is made just proximal to the physis and a starting drill hole is made. **C**, The drill hole is enlarged with a sharp awl and rongeurs in an oval pattern. **D**, The initial C-shaped rod is advanced past the fracture site. **E**, The second S-shaped rod is then placed and advanced into the femoral neck.

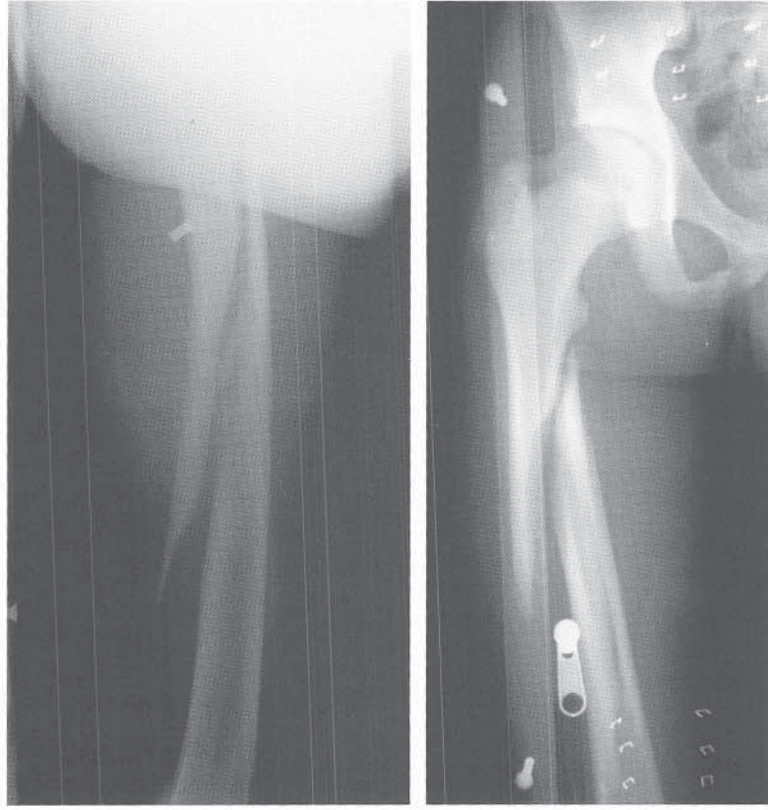
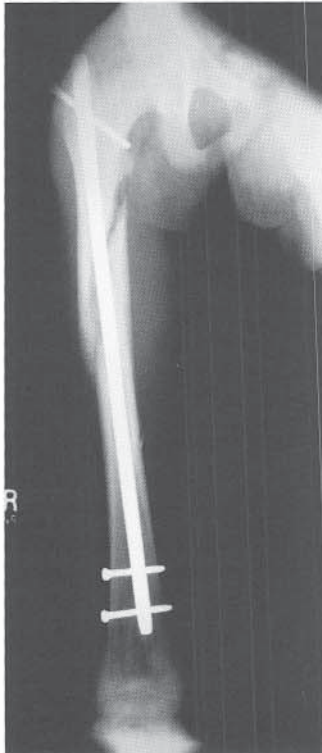
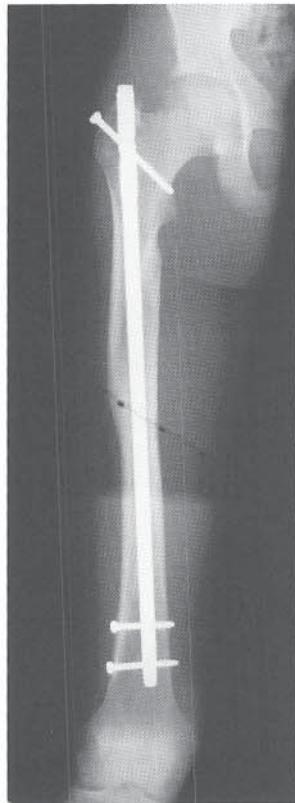
FIGURE 42-85 Locked intramedullary nailing of a femoral fracture in a skeletally mature patient. A, Initial injury films in a 14-year-old boy who sustained a twisting injury while playing football. B, Initial postoperative obtained following statically locked intramedullary nailing. C, Final AP and lateral radiographs obtained 8 months postoperatively.


A



B



C



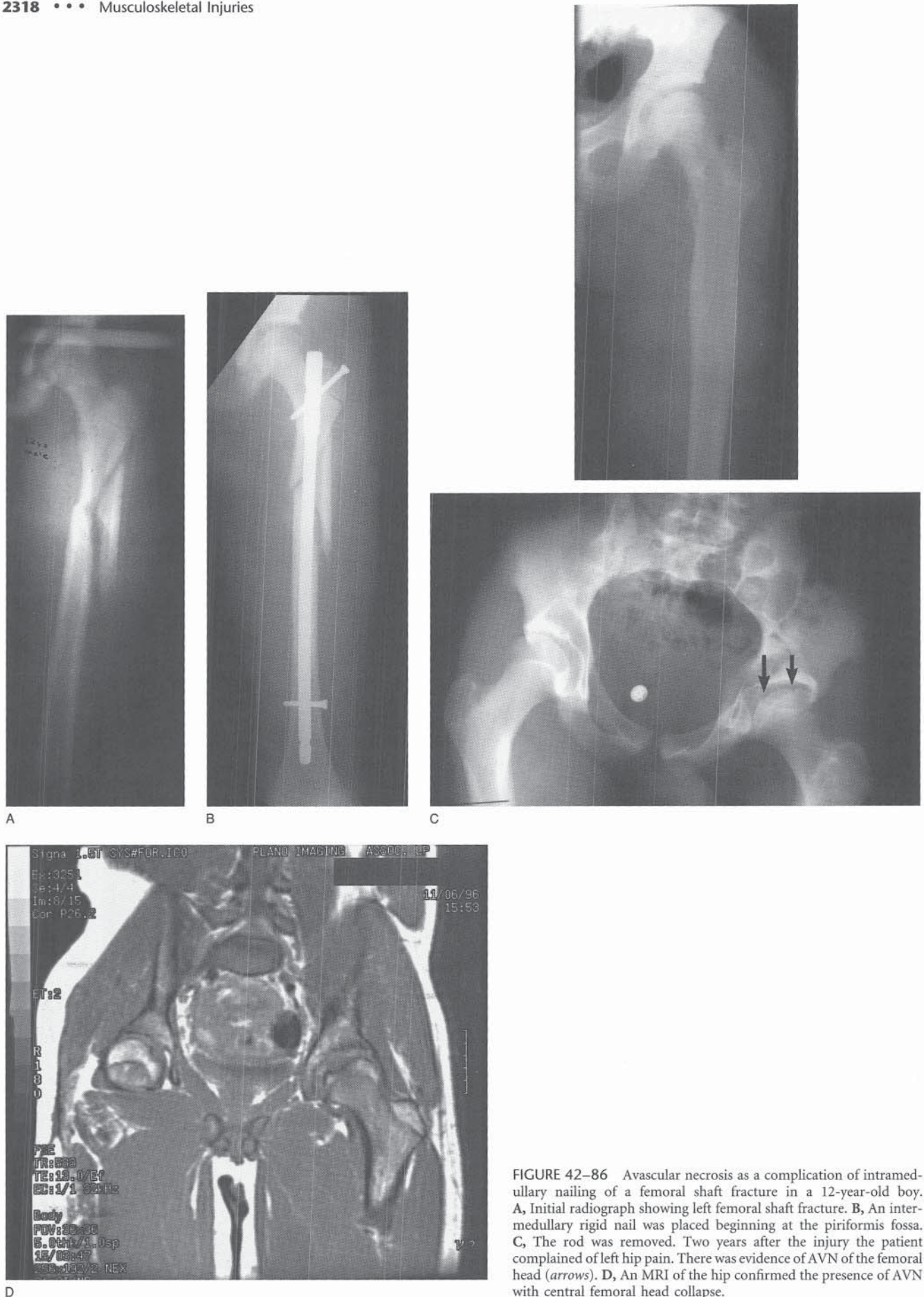


FIGURE 42-86 Avascular necrosis as a complication of intramedullary nailing of a femoral shaft fracture in a 12-year-old boy. A, Initial radiograph showing left femoral shaft fracture. B, An intermedullary rigid nail was placed beginning at the piriformis fossa. C, The rod was removed. Two years after the injury the patient complained of left hip pain. There was evidence of AVN of the femoral head (arrows). D, An MRI of the hip confirmed the presence of AVN with central femoral head collapse.

nailing with the entry portal placed slightly more lateral and posterior to the piriformis fossa to avoid the retinacular vessels of the femoral neck region. In 33 patients the nail was removed at 10 months, and only two patients had subclinical AVN detected on MRI. The AVN was attributed to the soft tissue dissection necessary to remove the implant.¹⁶

At present, there are no rigid nails specifically designed for entrance below the greater trochanter. We prefer to use flexible nails wherever possible to avoid the complications associated with the use of rigid intramedullary nails, and we prefer to use the greater trochanter insertion site in the adolescent when intramedullary nailing is utilized.

Treatment of Complications from Femoral Shaft Fractures. Limb length inequality is the most common complication following a femoral shaft fracture in children, and may be due to accelerated growth in the involved femur or to shortening at the fracture site. Femoral growth acceleration is greatest within the first 3 months following fracture and declines to normal by 18 to 24 months postfracture.^{67,68} Overgrowth is generally thought to occur more often in the younger patient (less than 10 years old),⁷⁰ in boys,²⁰ in those with comminuted or long oblique fractures,²⁵ and in those with more proximal fractures. The average amount of overgrowth is reported to be between 0.8 and 1.5 cm. In addition, overgrowth of the ipsilateral tibia is seen in the majority of patients, with an average overgrowth of approximately 0.3 cm.⁶⁸ Because of the overgrowth phenomenon, an ideal reduction of a femoral shaft fracture in a younger child should allow for up to 1.5 to 2.0 cm of shortening.

Treatment of excessive shortening of the fractured femur depends on the time when it is recognized. If immediate spica casting results in excess shortening, the cast should be removed and the surgeon should repeat a closed reduction with cast application under anesthesia. If that fails to regain length, the child may be placed in traction for a short period of time, followed by hip spica casting after the fracture begins to consolidate. If excess shortening is seen at a time when callus formation is already present, the surgeon should consider osteoclasis followed by external fixation or traction. An alternative is to allow healing to continue and to perform an equalization procedure at a later time.

Acceptable angular alignment is most dependent on the age of the patient, the proximity of the fracture to the physis, and the plane of the angular deformity. Younger children, fractures near the physis, and angular deformity in the plane of motion of the adjacent joint tend to have a greater remodeling potential. General guidelines for acceptance for angular alignments should be followed, although there is some controversy concerning these numbers. (Wallace and Hoffman state that as much as 25 degrees of angular deformity can be accepted in any plane in a child less than 13 years old.⁸²) When significant angular deformity persists after fracture healing, a corrective osteotomy should be performed. General principles regarding corrective osteotomy are to perform the osteotomy as close to the apex of the deformity as possible; to rigidly fix the osteotomy site, preferably with an interlocking rod, to promote healing; and to use an Ilizarov frame or similar device in the situation of concomitant shortening.

Rotational deformities of the femur are generally agreed to have less remodeling potential than angular deformities.²³

However, in animal models an average rotational remodeling potential of 55 percent has been demonstrated.⁷³ Others have shown remodeling of rotational deformities in patients with femoral shaft fractures, although the remodeling has been somewhat limited.^{14,37,62} Some reports suggest that rotational deformities of 15 or even 25 degrees are well-tolerated. These deformities may occur more often than was previously thought; however, they are usually asymptomatic,^{53,80} and only the most severe deformities require corrective surgery.

Nonunion and delayed union of femoral shaft fractures in the pediatric population are relatively rare. We treat an established nonunion with rigid fixation and add autogenous bone grafting unless the nonunited bone is hypertrophic. In younger children we use plate fixation and in older children flexible intramedullary rods. Delayed union is most often seen in the child treated with an external fixator and should be treated with dynamization of the fixator. An alternative treatment is removal of the fixator followed by internal fixation with an intramedullary rod in an older child or plates and screws. However, the risk of infection is increased after previous treatment with an external fixator, and a 10- to 14-day course of oral antibiotics is recommended prior to fixation.

Although compartment syndrome following a femoral fracture is rare because of the large muscle mass of the thigh, the soft tissue envelope should be evaluated in every patient with a femoral fracture. Fractures at risk are those resulting from high-impact, direct trauma, prolonged Bryant's traction,⁶⁰ elevation of the leg in a hypotensive patient,²² and in some treated with intramedullary fixation.⁵⁸ The diagnosis should be suspected in any patient with excessive pain and a tense, swollen thigh. When these findings are present, pressures should be measured in all three compartments (adductor, hamstrings, and quadriceps) and fasciotomy of the compartment(s) should be performed if pressures are elevated. The quadriceps is the most common compartment involved, and can be released through an anterolateral incision with splitting of the iliotibial band and release of the vastus lateralis fascia.

Infection is very rare when nonoperative treatment is used. Canale and colleagues reported three cases of osteomyelitis of closed fractures, two of which were femoral fractures.¹⁸ Symptoms began 1 and 6 weeks following the original injury and were characterized as constant pain that was unrelieved by rest. Fever is associated with an uncomplicated femoral fracture but should subside in 2 to 3 days.⁷⁰ Treatment of osteomyelitis should be open debridement followed by intravenous antibiotics.

Inflammation surrounding external fixation pins is relatively common; however, the prevalence of true infection is reported to be less than 5 percent, and the infection can be treated with a short course of oral or intravenous antibiotics.^{5,12}

Vascular injury following a femoral fracture is rare, reported in approximately 1 percent of cases.⁴⁹ If there are clinical signs of arterial insufficiency and an abnormal Doppler examination, angiography may be indicated to look for a complete vascular disruption or intimal tear. If a vascular injury is present, immediate fixation of the bony anatomy with external fixation or plating should precede exploration and repair of the vessel. Careful serial examination of the

peripheral pulses is necessary in every patient with a femoral shaft fracture to detect vascular injuries.

REFERENCES

The Femur

- Allen BL Jr, Kant AP, Emery FE: Displaced fractures of the femoral diaphysis in children: Definitive treatment in a double spica cast. *J Trauma* 1977;17:8.
- Alonso JE, Horowitz M: Use of the AO/ASIF external fixator in children. *J Pediatr Orthop* 1987;7:594.
- Advanced Trauma Life Support Course. American College of Surgeons, Committee on Trauma: Chicago, American College of Surgeons, 1985.
- Aronson DD, Singer RM, Higgins RF: Skeletal traction for fractures of the femoral shaft in children: a long-term study. *J Bone Joint Surg* 1987;69-A:1435.
- Aronson J, Tursky EA: External fixation of femur fractures in children. *J Pediatr Orthop* 1992;12:157.
- Astion DJ, Wilber JH, Scoles PV: Avascular necrosis of the capital femoral epiphysis after intramedullary nailing for a fracture of the femoral shaft: a case report. *J Bone Joint Surg* 1995;77-A:1092.
- Bar-On E, Sagiv S, Porat S: External fixation or flexible intramedullary nailing for femoral shaft fractures in children: a prospective, randomized study. *J Bone Joint Surg* 1997;79-B:975.
- Beals RK, Tufts E: Fractured femur in infancy: the role of child abuse. *J Pediatr Orthop* 1983;3:583.
- Beaty JH, Austin SM, Warner WC, et al: Interlocking intramedullary nailing of femoral-shaft fractures in adolescents: preliminary results and complications. *J Pediatr Orthop* 1994;14:178.
- Beaty JH, Herman MJ, Warner WC, et al: Interlocking intramedullary nailing of femoral shaft fracture in adolescents. Presented at a meeting of the Pediatric Orthopaedic Society of North America, Banff, Alberta, Canada, 1997.
- Bennett FS, Zinar DM, Kilgus DJ: Ipsilateral hip and femoral shaft fractures. *Clin Orthop* 1993;296:168.
- Blasier RD, Aronson J, Tursky EA: External fixation of pediatric femur fractures. *J Pediatr Orthop* 1997;17:342.
- Bone L: Emergency treatment of the injured patient. In Browner BD, Jupiter JB, Levine AM, et al. (eds): *Skeletal Trauma*, vol 1, p 127. Philadelphia, WB Saunders Co, 1992.
- Brouwer KJ, Molenaar JC, van Linge B: Rotational deformities after femoral shaft fractures in childhood: a retrospective study 27–32 years after the accident. *Acta Orthop Scand* 1981;52:81.
- Bryant T: *The Practice of Surgery*. Philadelphia, HC Lea, 1873.
- Buford D Jr, Christensen K, Weatherall P: Intramedullary nailing of femoral fractures in adolescents. *Clin Orthop* 1998;350:85.
- Burks RT, Sutherland DH: Stress fracture of the femoral shaft in children: report of two cases and discussion. *J Pediatr Orthop* 1984;4:614.
- Canale ST, Puhl J, Watson FM, et al: Acute osteomyelitis following closed fractures: report of three cases. *J Bone Joint Surg* 1975;57-A:415.
- Carey TP, Galpin RD: Flexible intramedullary nail fixation of pediatric femoral fractures. *Clin Orthop* 1996;332:110.
- Clement DA, Colton CL: Overgrowth of the femur after fracture in childhood: an increased effect in boys. *J Bone Joint Surg* 1986;68-B:534.
- Clinkscales CM, Peterson HA: Isolated closed diaphyseal fractures of the femur in children: comparison of effectiveness and cost of several treatment methods. *Orthopedics* 1997;20:1131.
- Dameron TB, Thompson HA: Femoral shaft fractures in children: treatment by closed reduction and double spica cast immobilization. *J Bone Joint Surg* 1959;41-A:1201.
- Davids JR: Rotational deformity and remodeling after fracture of the femur in children. *Clin Orthop* 1994;302:27.
- de Sanctis N, Gambardella A, Pempinello C, et al: The use of external fixators in femur fractures in children. *J Pediatr Orthop* 1996;16:613.
- Edwardsen P, Syversen SM: Overgrowth of the femur after fracture of the shaft in childhood. *J Bone Joint Surg* 1976;58-B:339.
- Ekelund A, Gretzer H: Intramedullary nailing of femoral fractures in children. *Acta Orthop Scand* 1989;60[Suppl]:231.
- Fardon DP: Fracture of neck and shaft of same femur: report of a case in a child. *J Bone Joint Surg* 1970;52-A:797.
- Fein LH, Pankovich AM, Spero CM, et al: Closed flexible intramedullary nailing of adolescent femoral shaft fractures. *J Orthop Trauma* 1989;3:133.
- Ferry AM, Edgar MS Jr: Modified Bryant's traction. *J Bone Joint Surg* 1966;48-A:533.
- Fry K, Hoffer MM, Brink J: Femoral shaft fractures in brain-injured children. *J Trauma* 1976;16:371.
- Galpin RD, Willis RB, Sabano N: Intramedullary nailing of pediatric femoral fractures. *J Pediatr Orthop* 1994;14:184.
- Gonzalez-Herranz P, Burgos-Flores J, Rapariz JM, et al: Intramedullary nailing of the femur in children: effects on its proximal end. *J Bone Joint Surg* 1995;77-B:262.
- Green M, Haggerty R: *Ambulatory Pediatrics*. Philadelphia, WB Saunders Co, 1968.
- Greene WB: Displaced fractures of the femoral shaft in children: unique features and therapeutic options. *Clin Orthop* 1998;353:86.
- Gross RH, Stranger M: Causative factors responsible for femoral fractures in infants and young children. *J Pediatr Orthop* 1983;3:341.
- Gustilo RB, Anderson JT: Prevention of infection in the treatment of one thousand and twenty-five open fractures of long bones: retrospective and prospective analyses. *J Bone Joint Surg* 1976;58-A:453.
- Hagglund G, Hansson LI, Norman O: Correction by growth of rotational deformity after femoral fracture in children. *Acta Orthop Scand* 1983;54:858.
- Hedequist D, Starr AJ, Wilson P, et al: Early versus delayed stabilization of pediatric femur fractures: analysis of 387 patients. *J Orthop Trauma* 1999;13:490.
- Hedlund R, Lindgren U: The incidence of femoral shaft fractures in children and adolescents. *J Pediatr Orthop* 1986;6:47.
- Heinrich SD, Drvaric DM, Darr K, et al: The operative stabilization of pediatric diaphyseal femur fractures with flexible intramedullary nails: a prospective analysis. *J Pediatr Orthop* 1994;14:501.
- Herzog B, Affolter P, Jani L: Spätbefunde nach Marknagelung kindlicher Femurfracturen. *Z Kinderchir* 1976;19:74.
- Hoeksema HD, Olsen C, Rudy R: Fracture of femoral neck and shaft and repeat neck fracture in a child: case report. *J Bone Joint Surg* 1975;57-A:271.
- Huber RI, Keller HW, Huber PM, et al: Flexible intramedullary nailing as fracture treatment in children. *J Pediatr Orthop* 1996;16:602.
- Hughes BF, Sponseller PD, Thompson JD: Pediatric femur fractures: effects of spica cast treatment on family and community. *J Pediatr Orthop* 1995;15:457.
- Hull JB, Sanderson PL, Rickman M, et al: External fixation of children's fractures: use of the Orthofix Dynamic Axial Fixator. *J Pediatr Orthop B* 1997;6:203.
- Humberger FW, Eyring EJ: Proximal tibial 90-90 traction in treatment of children with femoral-shaft fractures. *J Bone Joint Surg* 1969;51-A:499.
- Irani RN, Nicholson JT, Chung SM: Long-term results in the treatment of femoral-shaft fractures in young children by immediate spica immobilization. *J Bone Joint Surg* 1976;58-A:945.
- Kissel EU, Miller ME: Closed Ender nailing of femur fractures in older children. *J Trauma* 1989;29:1585.
- Kluger Y, Gonze MD, Paul DB, et al: Blunt vascular injury associated with closed mid-shaft femur fracture: a plea for concern. *J Trauma* 1994;36:222.
- Kregor PJ, Song KM, Rouff ML Jr, et al: Plate fixation of femoral shaft fractures in multiply injured children. *J Bone Joint Surg* 1993;75-A:1774.
- Küntscher G: Intramedullary surgical technique and its place in orthopaedic surgery: my present concept. *J Bone Joint Surg* 1965;47-A:809.
- Loder RT: Pediatric polytrauma: orthopaedic care and hospital course. *J Orthop Trauma* 1987;1:48.
- Malkawi H, Shannak A, Hadidi S: Remodeling after femoral shaft fractures in children treated by the modified Blount method. *J Pediatr Orthop* 1986;6:421.
- Mann DC, Weddington J, Davenport K: Closed Ender nailing of femoral shaft fractures in adolescents. *J Pediatr Orthop* 1986;6:651.
- Mazda K, Khairouni A, Pennecot GF, et al: Closed flexible intramedullary nailing of the femoral shaft fractures in children. *J Pediatr Orthop B* 1997;6:198.
- Mileski RA, Garvin KL, Crosby LA: Avascular necrosis of the femoral head in an adolescent following intramedullary nailing of the femur: a case report. *J Bone Joint Surg* 1994;76-A:1706.
- Mileski RA, Garvin KL, Huurman WW: Avascular necrosis of the

- femoral head after closed intramedullary shortening in an adolescent. *J Pediatr Orthop* 1995;15:24.
58. Miller DS, Markin L, Grossman E: Ischemic fibrosis of the lower extremity in children. *Ann J Surg* 1952;84:317.
 59. Miller PR, Welch MC: The hazards of tibial pin replacement in 90–90 skeletal traction. *Clin Orthop* 1978;135:97.
 60. Nicholson J, Foster R, Heath R: Bryant's traction: a provocative cause of circulatory complications. *JAMA* 1955;187:4118.
 61. O'Malley DE, Mazur JM, Cummings RJ: Femoral head avascular necrosis associated with intramedullary nailing in an adolescent. *J Pediatr Orthop* 1995;15:21.
 62. Oberhammer J: Degree and frequency of rotational deformities after infant femoral fractures and their spontaneous correction. *Arch Orthop Trauma Surg* 1980;97:249.
 63. Orler R, Hersche O, Helfet DL, et al: [Avascular femoral head necrosis as severe complication after femoral intramedullary nailing in children and adolescents]. *Unfallchirurg* 1998;101:495.
 64. Probe R, Lindsey RW, Hadley NA, et al: Refracture of adolescent femoral shaft fractures: a complication of external fixation. A report of two cases. *J Pediatr Orthop* 1993;13:102.
 65. Raney EM, Ogen JA, Grogan DP: Premature greater trochanteric epiphysiodesis secondary to intramedullary femoral rodding. *J Pediatr Orthop* 1993;13:516.
 66. Rang M: *Children's Fractures*. Philadelphia, JB Lippincott Co, 1974.
 67. Reynolds DA: Growth changes in fractured long-bones: a study of 126 children. *J Bone Joint Surg* 1981;63-B:83.
 68. Shapiro F: Fractures of the femoral shaft in children: the overgrowth phenomenon. *Acta Orthop Scand* 1981;52:649.
 69. Skak SV, Overgaard S, Nielsen JD, et al: Internal fixation of femoral shaft fractures in children and adolescents: a ten- to twenty-one-year follow-up of 52 fractures. *J Pediatr Orthop B* 1996;5:195.
 70. Staheli LT: Femoral and tibial growth following femoral shaft fracture in childhood. *Clin Orthop* 1967;55:159.
 71. Staheli LT, Sheridan GW: Early spica cast management of femoral shaft fractures in young children: a technique utilizing bilateral fixed skin traction. *Clin Orthop* 1977;126:162.
 72. Stannard JP, Christensen KP, Wilkins KE: Femur fractures in infants: a new therapeutic approach. *J Pediatr Orthop* 1995;15:461.
 73. Strong ML, Wong-Chung J, Babikian G, et al: Rotational remodeling of malrotated femoral fractures: a model in the rabbit. *J Pediatr Orthop* 1992;12:173.
 74. Swiontkowski MF, Hansen ST Jr, Kellam J: Ipsilateral fractures of the femoral neck and shaft: a treatment protocol. *J Bone Joint Surg* 1984;66-A:260.
 75. Timmerman LA, Rab GT: Intramedullary nailing of femoral shaft fractures in adolescents. *J Orthop Trauma* 1993;7:331.
 76. Tolo VT: External skeletal fixation in children's fractures. *J Pediatr Orthop* 1983;3:435.
 77. Tolo VT: External fixation in multiply injured children. *Orthop Clin North Am* 1990;21:393.
 78. Treiman GS, Yellin AE, Weaver FA, et al: Examination of the patient with a knee dislocation. The case for selective arteriography. *Arch Surg* 1992;127:1056.
 79. Vangness CT Jr, De Campos J, Merritt PO, et al: Meniscal injury associated with femoral shaft fractures: an arthroscopic evaluation of incidence. *J Bone Joint Surg* 1993;75-B:207.
 80. Verbeek HO: Does rotation deformity, following femur shaft fracture, correct during growth? *Reconstr Surg Traumatol* 1979;17:75.
 81. von der Oelsnitz G: Marknagelung kindlicher Oberschenkelkfrakturen. *Z Kinderchir* 1972;11[Suppl]:803.
 82. Wallace ME, Hoffman EB: Remodelling of angular deformity after femoral shaft fractures in children. *J Bone Joint Surg* 1992;74-B:765.
 83. Ward WT, Levy J, Kaye A: Compression plating for child and adolescent femur fractures. *J Pediatr Orthop* 1992;12:626.
 84. Wascher DC, Dvirnak PC, De Coster TA: Knee dislocation: initial assessment and implications for treatment. *J Orthop Trauma* 1997;11:525.
 85. Weiss AP, Schenck RC Jr, Sponseller PD, et al: Peroneal nerve palsy after early cast application for femoral fractures in children. *J Pediatr Orthop* 1992;12:25.
 86. Winquist RA, Hansen ST Jr, Clawson DK: Closed intramedullary nailing of femoral fractures: a report of five hundred and twenty cases. *J Bone Joint Surg* 1984;66-A:529.
 87. Ziv I, Rang M: Treatment of femoral fracture in the child with head injury. *J Bone Joint Surg* 1983;65-B:276.

ADDED REFERENCE

The Femur

- 1a. Rathjen K, DeLaGarza, D: Flexible intramedullary of unstable femoral shaft fractures in children. Presented at a meeting of the Pediatric Orthopaedic Society of North America, Vancouver, British Columbia, Canada, May 1–4, 2000.

The Knee

DISTAL FEMORAL INJURIES AND FRACTURES

Fractures of the distal femur are relatively rare, are due to high-energy trauma, and are often associated with other injuries. Treatment consists of anatomic reduction and usually stable internal fixation. Complications are common and often require further operative intervention to take down a physeal bar, correct an angular deformity or limb length discrepancy, or reconstruct an anterior cruciate ligament injury.

Anatomy. The distal femoral epiphysis is formed from a single ossific nucleus, which is present at birth and is the first epiphysis in the body to ossify. The distal femoral physis grows at a rate of 8 to 10 mm per year, contributing approximately 40 percent of the growth of the lower extremity. It closes at approximately 13 years in girls and 15 years in boys.^{6,83} The ossific nucleus of the proximal tibial epiphysis appears by 2 months of age, with the secondary center of ossification of the tibial tubercle appearing between 10 and 14 years. The annual growth rate of the proximal tibial physis is approximately 6 mm, and fusion of the proximal tibial physis occurs at approximately 14 to 15 years of age.

The distal femur has a characteristic shape and inclination of the joint line at the knee. The anatomic axis of the femur (a line drawn down the femoral shaft) angles medially approximately 9 degrees from vertical, and the mechanical axis of the femur (a line drawn between the center of the femoral head and the center of the knee) deviates 3 degrees from vertical, with the difference between the mechanical and anatomic axes being 6 degrees (Fig. 42–87). The distal femoral articular angle, best measured between the mechanical axis of the femur and the knee joint line, is 3 degrees of valgus, or an angle of 87 degrees between the mechanical axis line and the lateral articular surface.

The muscular attachment of both heads of the gastrocnemius and the plantaris muscles are on the posterior aspect of the distal femoral metaphysis, just proximal to the physis. This will lead to flexion of the distal fracture fragment when the fracture line is proximal to the muscle insertion. The adductor magnus muscle attaches to the medial aspect of the femoral metaphysis, which leads to varus of the distal fracture fragment when the fracture line is proximal to its insertion. The collateral ligaments, however, attach distal to the physis at the level of the distal femoral epiphysis. Excess varus or valgus stress on the knee in the growing child will place tension on the collateral ligaments, which transfer these forces to the distal femoral physis, often resulting in injury to the physis without injury to the collateral ligaments. The anterior and posterior cruciate ligaments attach to the distal femoral epiphysis at the intercondylar notch and can

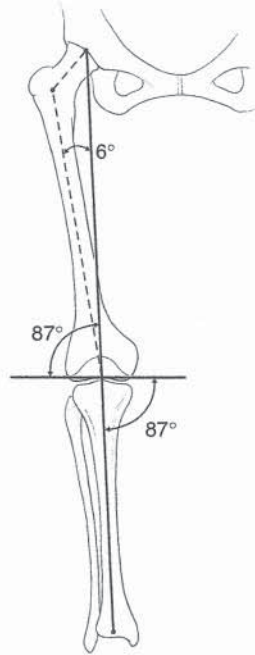


FIGURE 42-87 The relationship between the mechanical axis (*solid line*) and the anatomic axis (*dotted line*) of the lower extremity. The normal distal, femoral, and proximal tibial articular angles are shown.

be injured at the time of distal femoral epiphyseal fracture or physeal injury.¹⁹

Knowledge of the vascular anatomy is important in managing knee injuries in the pediatric population. The femoral artery travels through the adductor canal medially, just

above the distal femoral metaphysis, and then courses posteriorly directly behind the popliteal space. The popliteal artery is directly posterior to the distal femur, from which it is separated by a thin layer of soft tissue. It trifurcates at this level into the anterior interosseous, posterior interosseous, and peroneal artery. The superior geniculate arteries branch from the popliteal artery at the distal femoral metaphyseal area, traveling to the distal epiphysis deep to the muscle layer. Because of relatively poor collateral circulation around the knee, popliteal artery injury frequently results in loss of lower limb viability.

The peroneal nerve travels laterally, posterior to the biceps femoris muscle and the lateral head of the gastrocnemius muscle, and descends just distal to the fibular head. At the knee level the peroneal nerve lies superficial and is vulnerable to both direct trauma and a stretch injury when a varus stress is applied to the knee.

Classification. Fractures of the distal femur in children can be separated into two groups, isolated fractures of the metaphysis and physeal injuries. Injuries to the distal femoral physis represent approximately 7 percent of all lower extremity physeal fractures.^{135,173} Distal femoral injuries can be grouped according to the Salter-Harris classification.

The Salter-Harris type I injury is rare, accounting for 7.7 percent of all physeal injuries of the distal femur.^{53,128,184,221} It is most often seen in two age groups, newborns and adolescents. In the newborn, these birth fractures are more often associated with breech presentation and are often undisplaced and therefore unrecognized at the initial presentation until fracture callus is seen 2 to 3 weeks later (Fig. 42-88).¹⁸⁴ In the adolescent, the injury can also go unde-

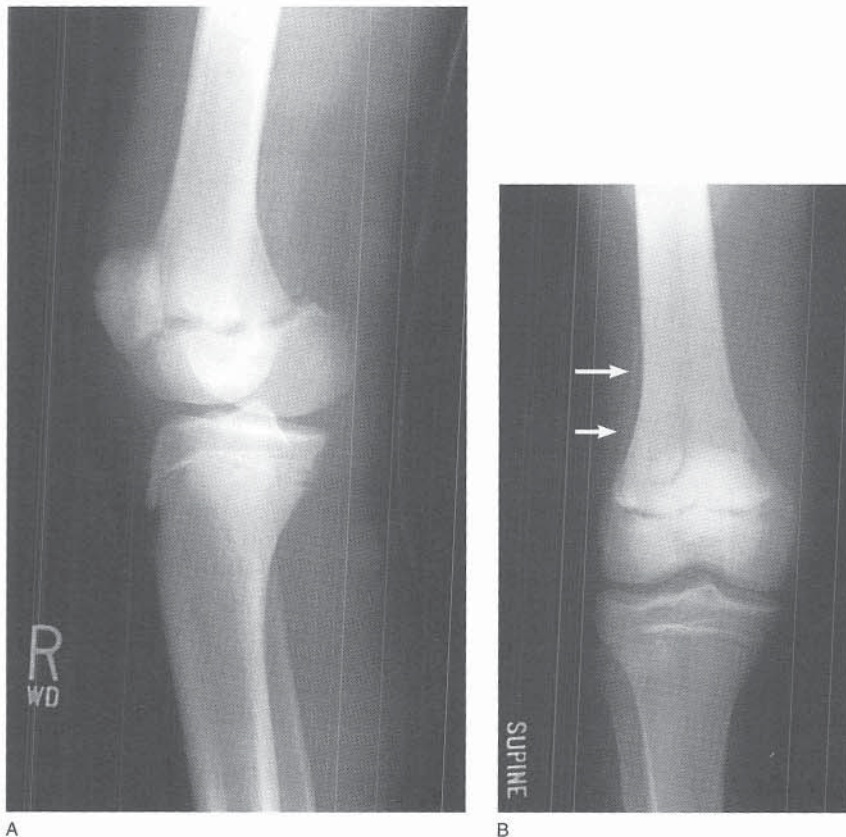


FIGURE 42-88 Salter-Harris type I distal femoral fracture. **A**, Oblique radiograph of the distal femur suggesting physeal injury with minimal rotational displacement of the distal epiphysis and physeal widening. **B**, After 6 weeks of long-leg cast treatment, evidence of healing is present, with periosteal elevation and new bone formation (*arrows*).

tected when undisplaced and should be confirmed with stress radiographs. Salter-Harris type II fractures are by far the most common distal femoral physeal injury, accounting for approximately 60 percent.^{53,128,184,221} The majority of these fractures occur in the adolescent age group and are displaced at the time of presentation (Fig. 42–89).

Salter-Harris type III and IV fractures each occur approximately 10 percent of the time and are usually displaced, requiring operative intervention. The Salter-Harris type V fracture is relatively rare, accounting for approximately 6 percent of all distal femoral physeal injuries.

Unlike other physeal injuries, the Salter-Harris classification alone has not been as accurate in predicting the overall outcome of the distal femoral fracture with respect to future growth arrest, limb length discrepancy, and angular deformity. The mechanism of injury and the degree of initial displacement should be classified at the time of the initial evaluation since these, in combination with the Salter-Harris classification, have been shown to be accurate predictors of outcome.^{128,184}

Mechanism of Injury. The mechanism of injury is varied and is partly dependent on the age of the child. In the newborn period, breech presentation is often associated with birth fractures and usually results in a type I Salter-Harris fracture.¹²⁸ In the age group from 3 years to 10 years the fractures are more often due to severe trauma, especially falls from a significant height or being struck by an automobile, and only a few fractures result from sports activities.¹⁸⁴ In the adolescent age group the majority of fractures result from sports injuries, with a smaller percentage resulting from automobile accidents in which the patient was a pedestrian.¹⁸⁴ Overall, pedestrian–motor vehicle accidents account for approximately 45 to 50 percent of fractures, sports inju-

ries account for 25 percent, and falls account for approximately 20 percent of injuries.^{53,128,184}

Another component that should be included in defining the mechanism of injury is the direction in which the force is applied to the knee. The two most common are the valgus-type force and the hyperextension force. Direct trauma results in epiphyseal separation on the tension side of the knee, with fracture of the metaphysis, epiphysis, or both on the compression side of the knee.

The valgus type of force is caused by a blow to the lateral side of the distal femur, usually occurring on the high school football field. This usually results in a type II or type III Salter-Harris physeal injury with the periosteum ruptured on the medial side and the distal femoral epiphysis displaced laterally with a lateral fragment of the metaphysis (Fig. 42–90). Torg and colleagues reported on six Salter-Harris type III fractures of the medial femoral condyle that occurred while the adolescents were playing football (five) or soccer (one).²²⁷ These six fractures resulted from direct trauma to a fixed leg in which a valgus stress was imparted to the knee, resulting in physeal separation on the medial side and a fracture through the center of the epiphysis.

The hyperextension-type injury results in the distal femoral epiphysis being displaced anteriorly by the hyperextension force and by the pull of the contraction of the quadriceps muscle. The periosteum on the posterior aspect is torn, and the fibers of the gastrocnemius muscle are stretched or partially torn (Fig. 42–91). The triangular metaphyseal fragment and the intact periosteal hinge are anterior in location. The distal end of the femoral shaft is driven posteriorly into the soft tissues of the popliteal fossa, where it may injure the popliteal vessels as well as the common peroneal or posterior tibial nerves. Hyperextension of the knee without direct trauma may result in physeal fracture when the energy

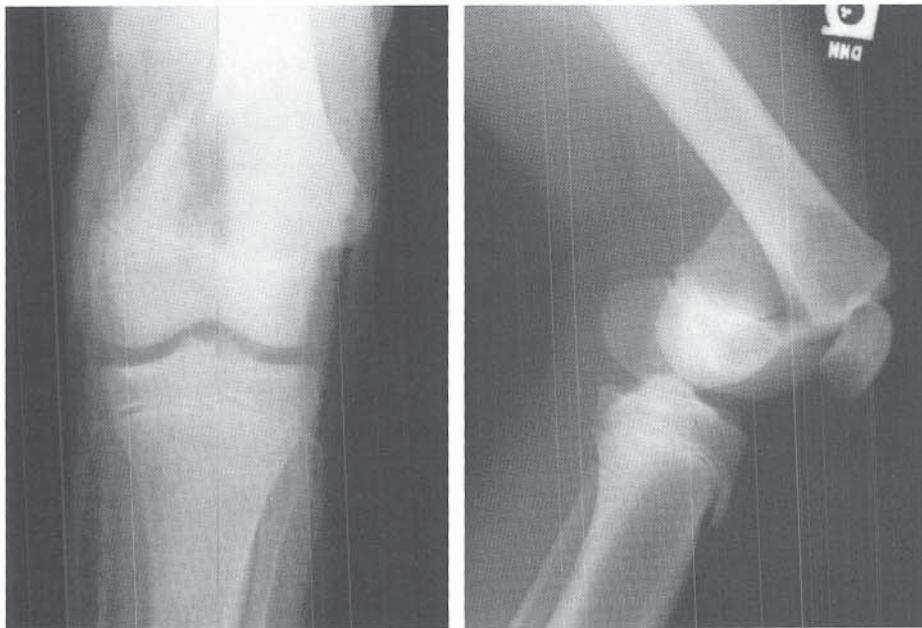


FIGURE 42–89 A displaced Salter-Harris type II fracture of the distal femur in an 11-year-old boy. The Thurston-Holland fragment is on the medial aspect of the distal femur.

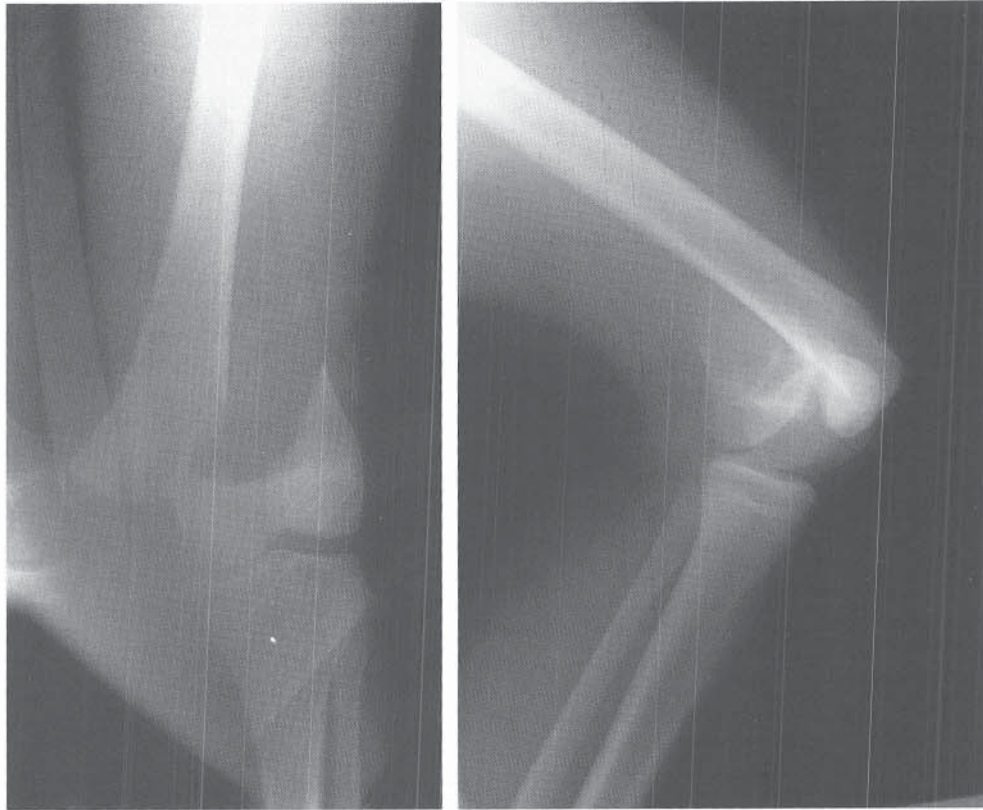


FIGURE 42-90 A typical Salter-Harris type II fracture of the distal femur in a 15-year-old boy who sustained a valgus force to the knee while playing football. Note the significant fracture displacement and the Thurston-Holland fragment on the lateral side.

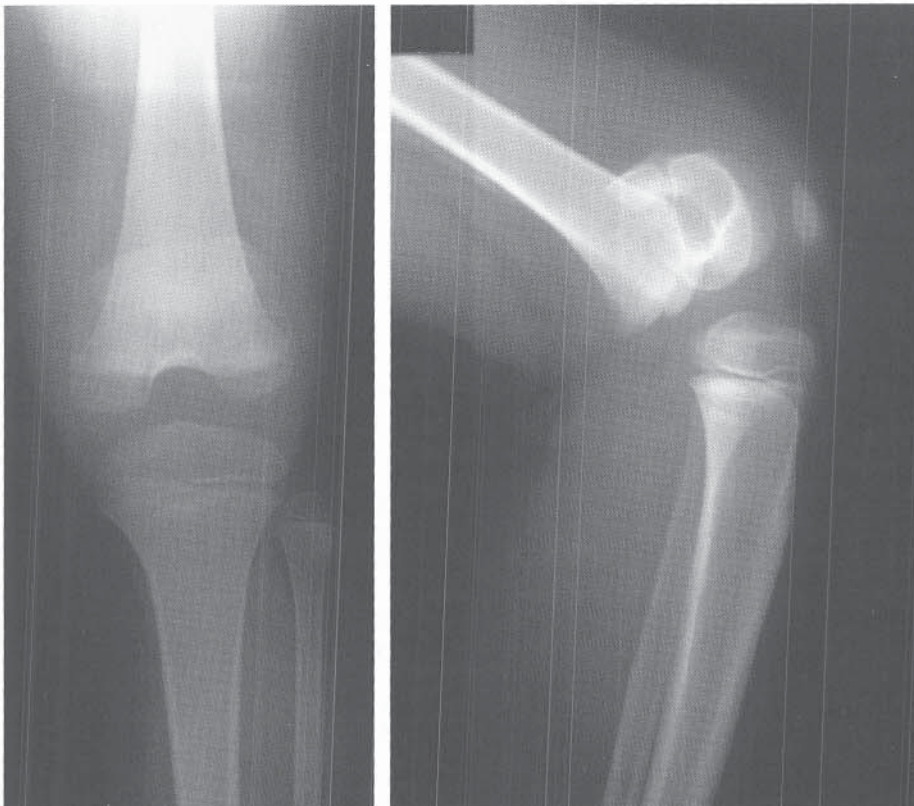


FIGURE 42-91 A hyperextension-type injury of the distal femoral physis in a 4-year-old patient. Note that the distal fragment is anteriorly displaced.

is significant. Grogan and Bobechko reported on a triple long-jumper who sustained a Salter-Harris type II fracture of the distal femoral epiphysis while landing.⁸⁵

Distal femoral fractures have been reported in a variety of conditions, including arthrogryposis multiplex congenita (following manipulation of the patients' stiff knees)⁶⁰ and myelomeningocele. In patients with myelomeningocele, a longer period of external immobilization may be needed for fracture healing.^{63,121,218}

Diagnostic Features. There is usually a history of significant trauma. In patients less than 11 years old (juveniles), more energy is required to produce the distal femoral physeal fracture than in the adolescent. Most often, this involves being struck by a motor vehicle or falling from a significant height. In the adolescent, sports injuries, especially football, account for a large proportion of injuries. The direction of the direct trauma is important to identify because many injuries may appear undisplaced radiographically at the time of the initial presentation but may have been displaced at the time of the injury, predisposing to soft tissue, vascular, or neurologic injury.

On physical examination, the patient is in acute distress secondary to pain in the knee region and is unable to walk. In the displaced fracture the knee is swollen and tense, although the patient with a nondisplaced separation will have less pain and may be able to ambulate. The knee is often in a flexed position because of hamstring muscle spasm, and deformity of the knee may be present with extension of the distal extent of the femur or valgus deformity. The soft tissue envelope should be inspected for traumatic open skin wounds, ecchymotic areas, and areas of excess swelling. Ecchymotic areas will provide information as to the deforming forces, such as a valgus stress with ecchymosis on the medial aspect of the knee from the displacement of the medial distal femoral metaphysis at the time of injury. Swelling in the popliteal space may alert the surgeon to a vascular injury or disruption.

A careful neurovascular examination should be performed in all patients with a distal femoral fracture or physeal injury. The soft tissue envelope should be palpated to evaluate for compartment syndrome at the time of initial presentation and during the first 48 hours after injury.

Finally, a thorough orthopaedic evaluation of the remaining extremities, pelvis, and spine is always necessary, especially in patients who have sustained high-energy injuries.

Radiologic Evaluation. Radiographic examination should include AP and lateral images of the knee and entire femur to include the hip joint. When no fracture is present radiographically despite a strong suspicion that a fracture exists, oblique views should be obtained and may reveal the injury. Additional radiographs should include stress views of the knee supervised by a physician. The patient should be relaxed with intravenous sedation to alleviate the muscle spasm and allow a good examination.²¹⁴

Additional imaging studies may be required. CT is helpful to define the amount of displacement and the amount of step-off in Salter-Harris type III and IV fractures. Although relatively rare in this type of injury, arteriography is indicated in any patient who has diminution of the peripheral pulses relative to the opposite extremity to identify arterial injury.

In the newborn child it is often difficult to diagnose a distal femoral physeal separation because of the limited ossification, which can best be visualized with MRI or ultrasound.

The Salter-Harris type V fracture is relatively rare, is difficult to diagnose at the initial evaluation, and is often missed. Lombardo and Harvey reported on 34 fractures of the distal femur, of which there was one type V fracture that was not initially recognized.¹²⁸ Radiographs of the affected knee and the contralateral knee should be compared, especially with regard to the thickness and configuration of the physis.

Treatment of Distal Femoral Metaphyseal Fractures.

Distal femoral metaphyseal fractures are treated differently than the typical distal femoral physeal injury. The various treatment options include external fixation, skeletal traction followed by casting, closed or open reduction followed by percutaneous pinning and casting, or open reduction and internal fixation. In general, we recommend closed reduction, percutaneous pinning, and cast immobilization whenever possible and do not often use skeletal traction and casting techniques. These techniques can be found in the previous discussion under Fractures of the Femoral Shaft. Fracture reduction should be as close to anatomic as possible, with acceptable residual angulation in the sagittal plane being less than 20 degrees in the child younger than 10 years and less in the older child.²⁴ No rotational malalignment is acceptable. Less than 5 degrees of varus or valgus alignment is acceptable.

EXTERNAL FIXATION. We limit the indications for external fixation to significant soft tissue injury associated with an open fracture; the polytrauma patient, when urgent stabilization is needed so that the patient can be transported for multiple diagnostic studies; and finally, highly comminuted fractures, which may require stabilization across the knee joint.

The external fixator should be placed with two pins in the distal metaphyseal fragment and two pins placed proximal to the fracture site. To avoid injury, the pins should be placed at least 1 cm from the distal physis.²²⁶ The fracture should be reduced before the external fixator is applied. Under fluoroscopic guidance, the pins are inserted laterally and placed parallel to the distal femoral articular surface, to avoid malalignment and malunion. At the completion of the application of the external fixator the knee should be fully extended and the overall alignment should be checked visually and radiographically. Varus and valgus malalignment should be corrected, as well as any rotational deformities. If the configuration of the fracture is stable, the patient can be partially weightbearing at the start of the rehabilitation process and gradually advanced to full weightbearing status. In the unstable fracture, the patient should be non-weightbearing initially until good fracture callus is seen radiographically, and then slowly advanced to full weightbearing. Mature callus should be present, and the external fixator should be dynamized for a period of 3 to 4 weeks before the external fixator is removed, to avoid refracture through the initial fracture site.²²⁵ An alternative is to remove the external fixator and then apply a long-leg walking cast until solid callus formation is present. In the rare case in which application of the external fixator spans the knee joint in the highly comminuted fracture, two pins are placed in the proximal tibia, at least 3 cm distal to the tibial tubercle. The

external fixation of the tibia should be removed to allow range of motion of the knee in approximately 4 to 6 weeks, when fracture stability has improved.

The most common complication associated with external fixation of distal metaphyseal fractures is pin tract infection, which can usually be treated with oral antibiotics and aggressive pin care. Malunion can occur and is best prevented by careful assessment of alignment at the time of application of the external fixator. Assessment includes extending the knee and clinically assessing the lower extremity alignment, and fluoroscopic visualization of the knee joint when a mechanical axis line is made with the Bovie cord held over the femoral head and the center of the ankle. Radiographs should be obtained weekly for 2 to 3 weeks following fracture stabilization to ensure that the reduction of the fracture has been maintained. Finally, distal femoral physeal injury may occur when pins are placed less than 1 cm from the physis.

CLOSED REDUCTION AND INTERNAL FIXATION. The method of closed reduction of the distal metaphyseal fracture depends on the deformity at the time of treatment. In a hyperextension-type injury the distal fragment is flexed because of the pull of the gastrocnemius muscles, and the proximal fragment is posteriorly displaced. In the hyperflexion type of fracture, again the distal fragment is flexed because of the pull of the gastrocnemius muscle, but the proximal fragment is anterior to the distal fragment. Reducing these fractures is often difficult because the plane of displacement and the plane of the knee joint motion are the same and there is lack of an adequate lever arm of the distal femoral fragment. The technique we prefer for reduction is performed with the patient supine on a radiolucent operating table.

For the hyperextension-type fracture the hip is flexed to relax the quadriceps muscle and the knee is flexed to relax the gastrocnemius and hamstring muscles. Longitudinal traction is applied to the lower leg while the knee flexion is increased in an attempt to bring the distal femoral fragment posteriorly. Manual pressure is applied to the distal femoral condyles, pushing them posteriorly, while the proximal femoral segment is pushed anteriorly (Fig. 42-92). The knee should be flexed 60 degrees at this point to help stabilize the fracture, and the reduction is checked on fluoroscopy. For the hyperflexion-type injury, reduction is begun by placing axial traction on the injured leg with the knee in extension. The posteriorly displaced distal fragment is then pushed anteriorly as the proximal fragment is pushed posteriorly.

Once an acceptable reduction is achieved, threaded Steinmann pins are placed in a crossed fashion, beginning as far from the physis as possible without jeopardizing stability. Because the pins are often close to the knee joint, we prefer to cut the pins just below the skin so that they do not communicate with the external environment or rub the inside of the cast. External immobilization is required following fracture reduction and stabilization and can vary from a hip spica cast with the knee flexed 60 degrees to a long-leg cast with the knee flexed to 30 degrees. This is dependent on the surgeon's assessment of fracture stability at the time of reduction and pin fixation and should err on the side of caution. In those fractures stabilized with external immobilization only, the knee should be flexed to 60 degrees

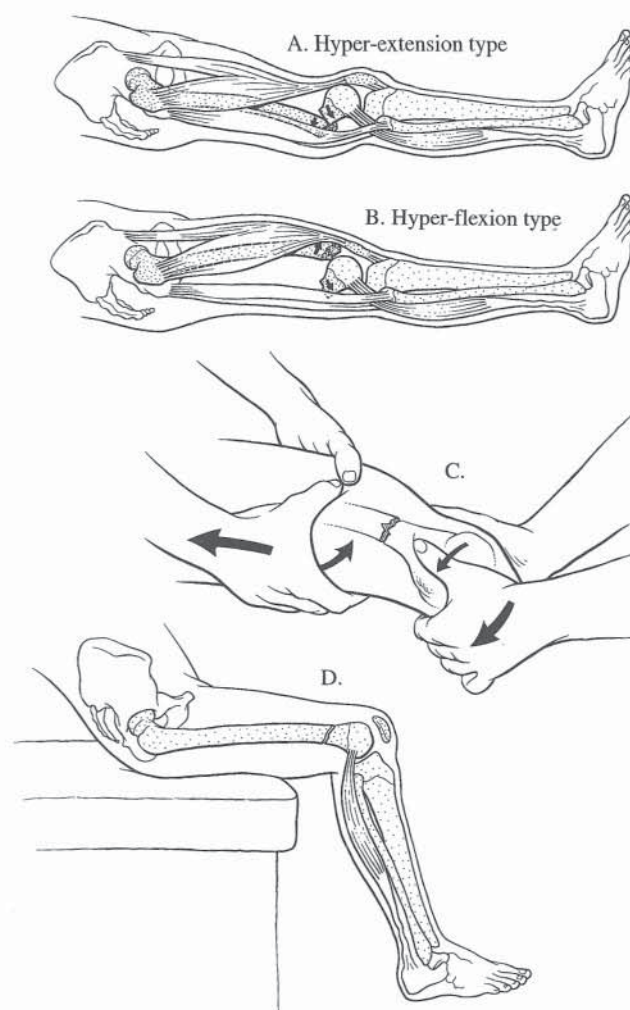


FIGURE 42-92 Reduction of a distal femoral physeal injury. A, Hyperextension-type injury. B, Hyperflexion-type injury. Note the distal fragment posterior to the proximal fragment. C, Reduction maneuver to reduce a hyperextension-type distal femoral physeal injury. Axial traction is initially applied with the knee in extension, followed by gradual flexion of the knee to bring the distal fragment posteriorly. D, The knee is flexed to hold the reduction and then casted in this position.

for the first 2 to 3 weeks and then gradually brought up into knee extension.^{3,84}

OPEN REDUCTION AND INTERNAL FIXATION. The indications for this technique include fractures that are irreducible by closed means, and the requirement for stable internal fixation, for example when an associated arterial injury is present. Failure of closed reduction is usually due to the proximal fracture fragment buttonholing through the quadriceps muscle, which becomes interposed between the fracture fragments, preventing fracture reduction.

The operative approach is usually through a standard lateral approach; however, when an arterial injury is present, a medial approach to both the fracture and the arterial injury is necessary. The lateral approach passes through the tensor fascia lata and the fascia of the vastus lateralis. The musculature of the vastus lateralis is then gently teased off its fascia posteriorly to the posterolateral aspect of the femur, followed by subperiosteal dissection. Usually soft tissue injury created by the fracture will disturb the tissue planes, which may

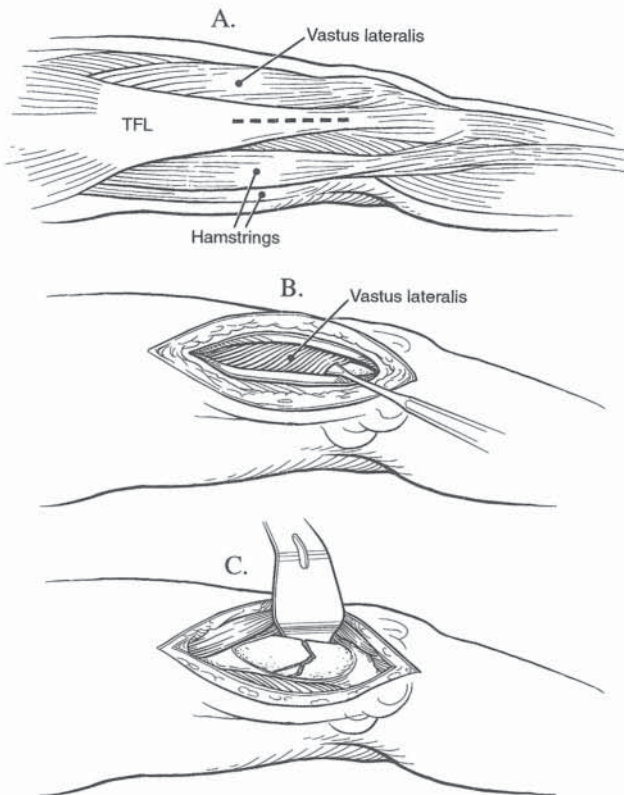


FIGURE 42-93 Lateral approach to the distal femur. A, The skin incision is made directly over the lateral aspect of the distal thigh. B, The tensor fascia lata is incised and the posterior aspect of the vastus lateralis is dissected off the lateral aspect of the femur. C, The vastus lateralis is retracted anteriorly, exposing the fracture site.

alter the dissection slightly. Once the fracture has been exposed, the interposed muscle must be cleared from the fracture site to allow fracture reduction (Fig. 42-93). The reduction maneuver is similar to that used in a closed reduction.

The most common indication for a medial approach to these fractures is a concomitant arterial injury requiring repair. The medial approach allows for exposure to carry out fracture and arterial repair and saphenous vein harvest for the arterial anastomosis. The medial incision is begun in the midcoronal plane, just proximal to the knee. An incision is made directly over the adductor tubercle, which lies on the posterior aspect of the medial femoral condyle and defines the interval between the vastus medialis and the medial hamstring muscles. Superficially, the interval is between the sartorius and vastus medialis and the deep dissection is between the vastus medialis and the adductor magnus. Posterior to the adductor magnus lie the popliteal artery and vein and the tibial nerve. Retraction of the adductor magnus posteriorly will protect the neurovascular structures and allow the vastus medialis to be dissected off the medial aspect of the femur (Fig. 42-94).

We prefer rigid internal fixation with a 4.5 dynamic compression plate or a clover-type plate in the child older than 12 or in a patient with a severely comminuted fracture (Fig. 42-95). Any internal fixation device should be placed at least 1 cm proximal to the distal physis. In most children, threaded Steinmann pins placed in a crossed fashion provide enough stability; this fixation is supplemented with a long-leg cast with the knee in approximately 30 degrees of flexion

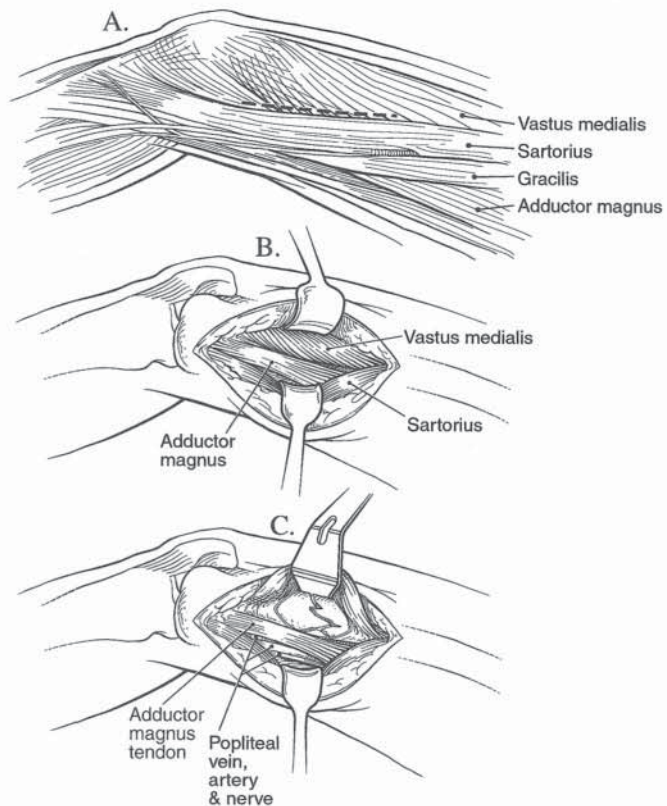


FIGURE 42-94 Medial approach to the distal femur. A, A skin incision is made parallel and just superior to the sartorius. B, Dissection is carried out between the sartorius and vastus medialis. The adductor magnus is seen in this interval. C, Subperiosteal dissection is carried out at the distal femur. Access to the neurovascular structure can be achieved below the adductor magnus.

for a total of 6 to 8 weeks. The pins should be left deep to the skin and can be removed after good callus formation at 4 weeks, followed by an additional 2 to 4 weeks in a long-leg cast.

Treatment of Distal Femoral Physeal Injuries. The general principles applicable to treating physeal fractures must be followed in treating the distal femoral physeal injury because of the higher risk of developing a physeal osseous bridge, with subsequent limb length discrepancy or angular deformity. These principles include the following:

1. All attempts at a closed reduction should be performed under general anesthesia or sedation.
2. The reduction maneuver should consist of predominantly traction, followed by manipulation.
3. The reduction should not be performed more than 10 days after the original injury.
4. An anatomic reduction should be achieved, especially in type III and IV injuries.
5. Internal fixation should avoid the physis or should be nonthreaded if passing across the physis.¹⁹³

Salter and colleagues have stated that when excessive manipulation appears to be necessary to achieve an acceptable reduction, it is better to maintain growth potential and perform corrective osteotomy at a later date rather than overstress the physis, causing more injury.¹⁹²

The goal of treatment of the distal femoral physeal injury is to gain an anatomic reduction with stable fixation, espe-

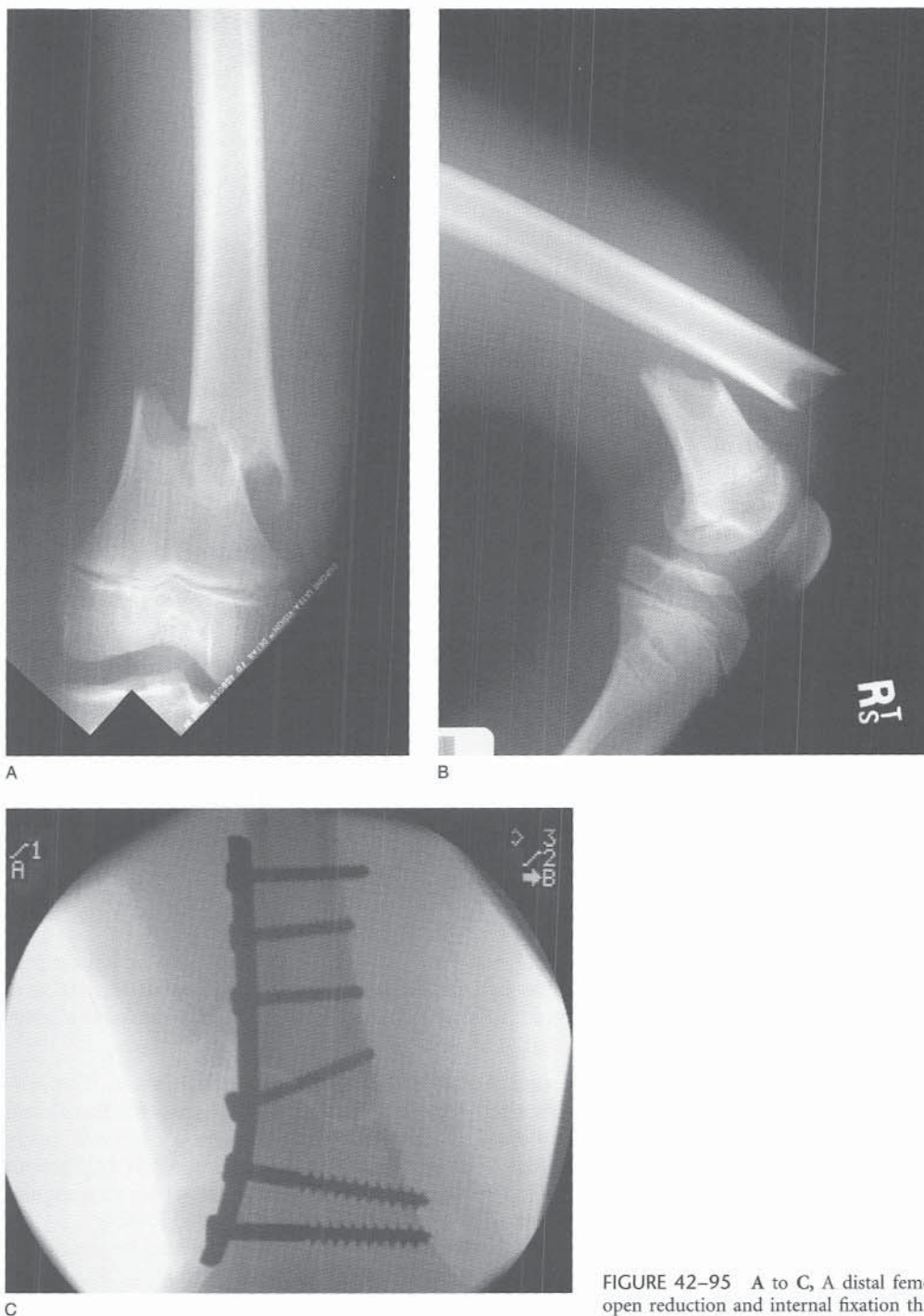


FIGURE 42-95 A to C, A distal femoral metaphyseal fracture treated with open reduction and internal fixation through a lateral approach.

cially in the older child (more than 10 years old). In the younger child, acceptable alignment includes up to 20 degrees of angulation in the sagittal plane,²⁴ less than 5 degrees of varus or valgus angulation, and no rotational deformity.

Nondisplaced physal injuries can be treated with a long-leg cast for 4 to 6 weeks, depending on the age of the child (Fig. 42-96). Nonweightbearing crutch walking is continued during this time, followed by weightbearing as tolerated and range-of-motion knee exercises when the cast is discontinued.

The type I Salter-Harris injury in the newborn can be

treated with immobilization without attempts at reduction, since significant remodeling potential exists.¹⁸⁴ Immobilization in the newborn is difficult but often requires only a bulky soft dressing. The older child with a complete physal separation will need a closed reduction performed under general anesthesia. The reduction of the hyperextension injury in which the distal fragment is displaced anteriorly and flexed relative to the tibia is similar to that described for distal femoral metaphyseal fractures. Immobilization is in a hip spica or long-leg cast with the knee flexed, usually to 60 degrees, followed by gradual extension of the knee over

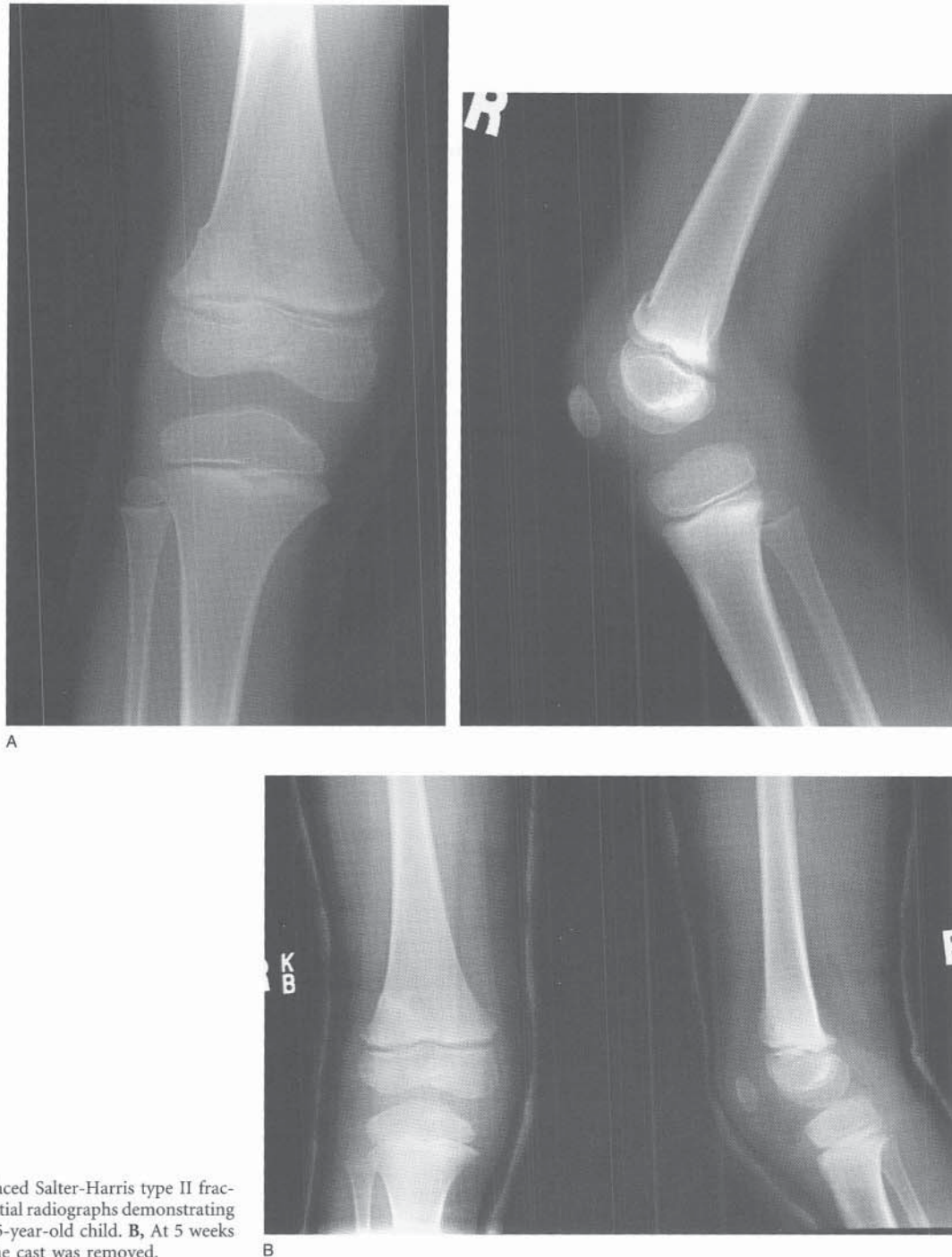


FIGURE 42-96 An undisplaced Salter-Harris type II fracture treated with casting. **A**, Initial radiographs demonstrating the undisplaced fracture in a 5-year-old child. **B**, At 5 weeks the fracture has healed and the cast was removed.

the ensuing 3 to 4 weeks. However, Aitken and Magil pointed out that the distal femoral physal separation occurs distal to the medial head of the gastrocnemius, with the distal fragment displaced posteriorly, and therefore the reduction of these fractures should occur with the knee in extension. Likewise, the knee should be immobilized in extension to allow “the taut medial head of the gastrocnemius to act as a posterior splint and prevent posterior displacement.”²³ In the older child or the patient with an unstable physal separation, smooth pin fixation may be necessary to provide stable fixation. We prefer to place smooth wires or pins in crossed fashion; they are removed at 4 weeks, and the limb

is then recasted for an additional 2 weeks in a long-leg cast (Fig. 42-97). To prevent knee contractures, aggressive therapy is then started to regain range of motion of the knee. We prefer a long-leg cast in most children. A spica cast may be necessary in the obese child, in whom control of the knee in a long-leg cast is difficult, or if there is any concern about compliance with nonweightbearing status.

Of all type II fractures, 60 to 75 percent are displaced at the time of the initial evaluation.^{53,128,184} In the juvenile group, the incidence is closer to 100 percent¹⁸⁴ owing to the high energy required to disrupt the thick periosteal and perichondrial sheaths in children less than 10 years old.³¹

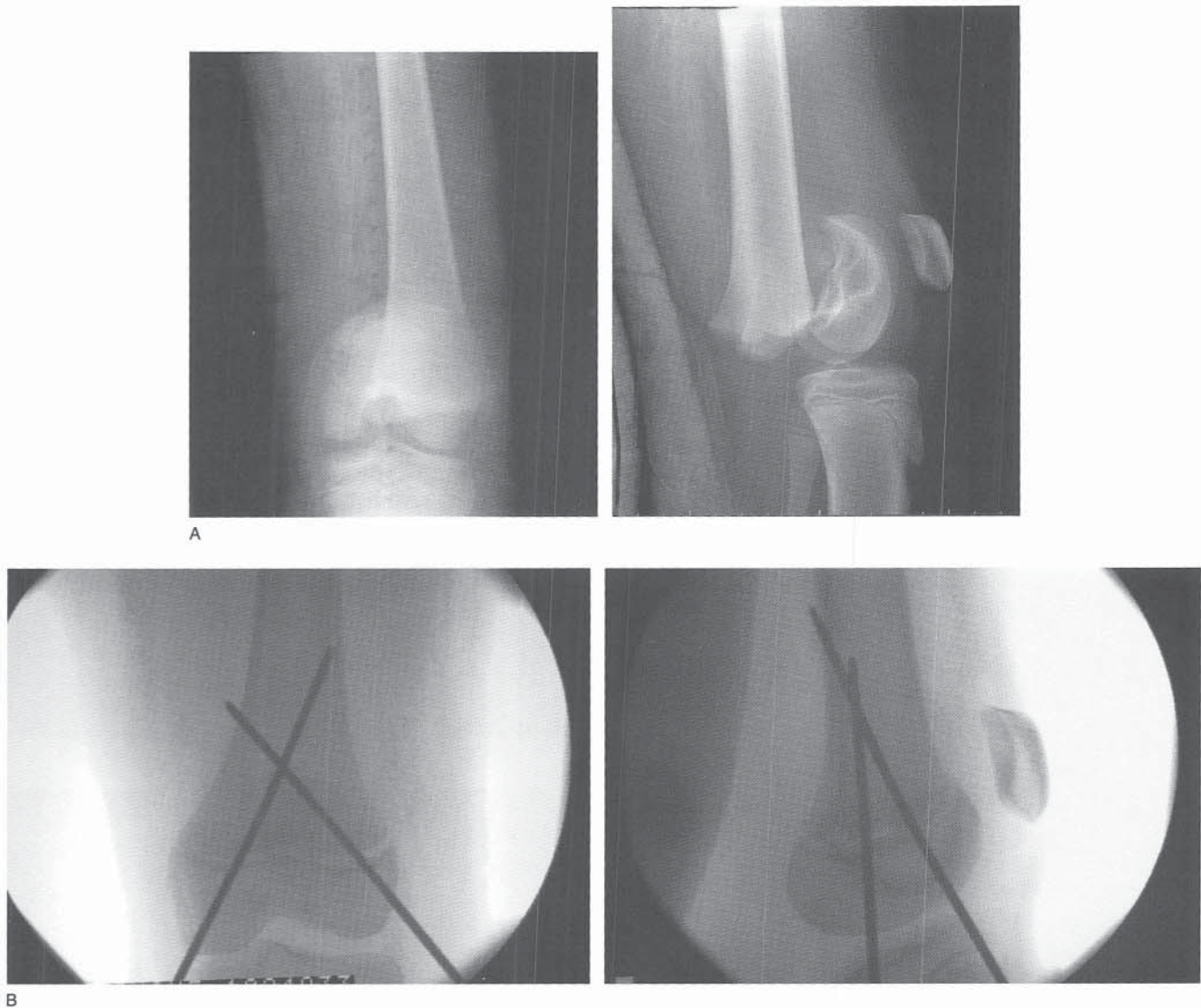
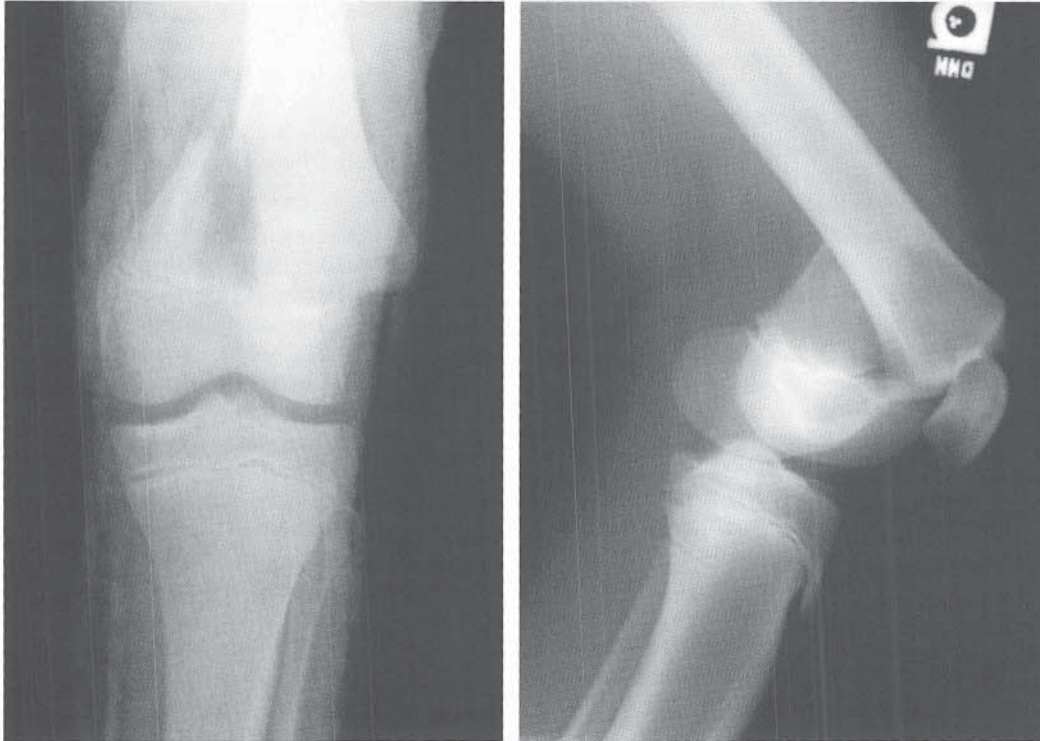

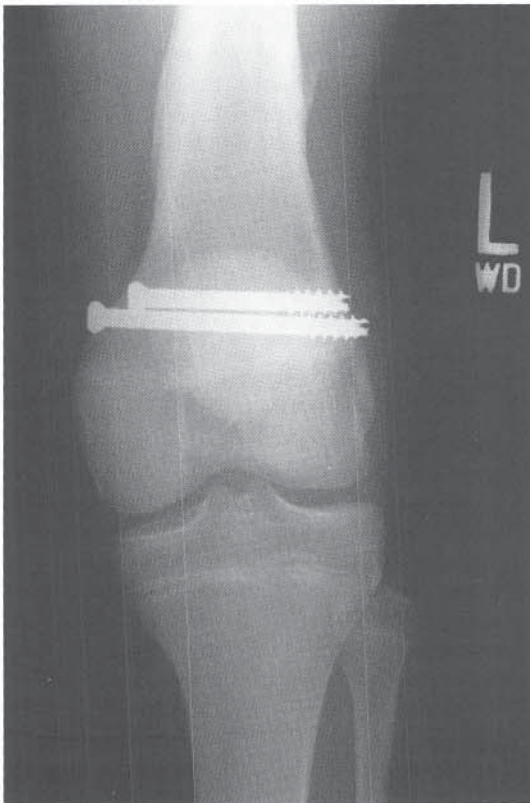
FIGURE 42-97 Closed reduction and percutaneous pinning of a distal femoral physeal injury. **A**, Initial injury films in a 5-year-old girl showing a Salter-Harris type II hyperextension distal femoral physeal injury. **B**, Intraoperative films obtained after a closed reduction and percutaneous pinning. The pins were cut below the skin and a long-leg cast was applied.

The nondisplaced or minimally displaced type II fractures can be successfully treated with closed reduction and external immobilization. The reduction maneuver should be performed under general anesthesia or sedation, with the principal maneuver being in-line traction followed by an overcorrection maneuver to reduce the angulation of the distal fragment. This should tighten the intact periosteum attached to the metaphyseal fragment. For example, when the metaphyseal fragment is on the lateral side, the distal fragment will be in valgus and can be reduced with a varus-producing maneuver to overcorrect the deformity. A well-molded plaster long-leg cast is applied with the knee in 20 to 30 degrees of flexion and overwrapped in fiberglass. It is important to identify any knee ligamentous injury, since this will make the reduction maneuver difficult, may cause further damage to the ligament, and will usually require internal fixation to maintain the reduction. Bertin and Goble reported that six of 16 patients with distal femoral physeal

injuries had associated ligamentous injuries, which were type II fractures in three patients, all of whom had residual coronal and sagittal plane deformity.¹⁹ In the displaced type II fracture, a closed reduction under general anesthesia is performed, followed by percutaneous fixation to fix the metaphyseal fragment. In the young child, Kirschner wires should be used, and in the child older than 10 years, cannulated screws (4.0- or 6.5-mm screws) should be placed percutaneously (Fig. 42-98). Although the literature reports only a 10 to 15 percent rate of type II fracture stabilization with internal fixation,^{128,184} we prefer an anatomic reduction under general anesthesia, followed by stable internal fixation of the metaphyseal fragment. The leg should be casted with the knee in 20 to 30 degrees of flexion until healing occurs which is usually 6 weeks. A failed closed reduction of a type II fracture of the distal femur requires open reduction in approximately 5 percent of cases.¹²⁸ This irreducible type II fracture is most often due to interposed periosteum on the



A



B

FIGURE 42-98 Closed reduction and screw fixation of Salter-Harris type II fracture. **A**, Initial injury films demonstrating displacement in a Salter-Harris type II fracture in a 13-year-old boy. **B**, Closed reduction with percutaneous screw fixation was performed, and radiographs at 1 year post injury are shown.

tension side of the fracture or less often muscle interposition, requiring open reduction followed by internal fixation.

Type III injuries of the distal femur are relatively less common, are usually displaced, and generally require open reduction and internal fixation. Type III fractures must be anatomically reduced to preserve articular anatomy and reduce the likelihood of a growth arrest. Historically, some of these fractures have been treated successfully by closed reduction and casting;¹⁸⁴ however, loss of reduction can easily occur, since little control of the fracture fragments is achieved in a long-leg cast. We prefer an open reduction of all type III fractures, to anatomically reduce the joint surface and physis and to provide stable fixation of the fracture. An anteromedial or anterolateral incision is made, depending on the fracture pattern. Anatomic reduction must be achieved under direct visualization, followed by percutaneous fixation of the epiphysis, preferably with cannulated cancellous screws (4.0 mm or 6.5 mm). If possible, two screws should be placed in the epiphysis, and they should be placed so that the threads are on one side of the fracture line only, to gain compression across the fracture (Fig. 42–99). Long-leg cast immobilization for 6 weeks with the knee in 20 to 30 degrees of flexion is required. It is rare to have a type III fracture that is nondisplaced at the time of presentation, and in this setting we continue to prefer to internally fix these fractures to maintain anatomic reduction.

The management of type IV fractures is similar to that of type III fractures: an anatomic reduction to preserve the joint and prevent growth arrest. This usually means an open reduction stabilized with internal fixation. Cannulated screws or Kirschner wires should be placed parallel to the joint line in both the metaphysis and the epiphysis to achieve stable fixation.

For all types of distal femoral physal injuries, long-leg casting is continued for 6 to 8 weeks, depending on the age of the child and the radiographic appearance of fracture healing. In general, after callus formation becomes evident on radiographs, range-of-motion exercises should be started, using a removable cast or knee immobilizer until solid fracture healing has occurred. Close follow-up of these patients should continue for at least 18 months to monitor the growth of the distal femoral epiphysis.

The prognosis for these fractures depends on the age of the child at the time of injury, the amount of fracture displacement, the adequacy of the reduction and fracture stabilization, and the type of fracture. Distal femoral physal injuries in the juvenile age group (less than 10 years old) are the result of a high-energy injury that imparts greater trauma to the physis, and with worse outcomes, than similar fractures in adolescents.¹⁸⁴ Riseborough and colleagues reported that 83 percent of patients in the juvenile age group who sustained distal femoral physal fractures had growth problems, compared to 50 percent in the adolescent age group. This difference is also related to the amount of residual growth remaining in the two age groups, with adolescents having less time to develop limb length discrepancies or angular deformities than younger patients. Fracture displacement at the time of injury is a strong predictor of outcome.¹²⁸ Lombardo and Harvey reported limb length discrepancies of 5 mm and 8 mm respectively in nondisplaced fractures and displaced fractures that were reduced satisfactorily. Patients in whom an adequate reduction is

not achieved have an average limb length discrepancy of 25 mm.¹²⁸ Finally, type I and II fractures generally have a better outcome than type III, IV, and V fractures.^{53,128,184,221}

Complications. Acute complications are relatively rare and include associated injuries to the popliteal artery, peroneal nerve, or knee ligaments, and loss of fracture reduction. Late complications are more common and include limb length discrepancy, angular deformity, knee contracture and stiffness, and residual knee instability secondary to ligamentous injury.

ACUTE COMPLICATIONS. Arterial injury is rare in the distal femoral epiphyseal injury, being most common with a complete separation of the physis in a hyperextension injury in which the posteriorly displaced proximal fragment injures the popliteal artery (Fig. 42–100). To our knowledge, injury to the arterial wall has been reported in only three cases in the literature.^{156,184} In another report, a patient with ipsilateral injuries to the distal femur and proximal tibia underwent exploration of the popliteal artery because of a cool, pulseless foot with findings consistent with severe spasm of the popliteal artery that responded to papaverine injection.²²¹ Careful physical examination of the peripheral pulses is necessary at the time of the initial presentation. If a discrepancy is identified between limbs, then a gentle, closed reduction should be performed and the pulses reexamined. Arteriography is performed if the examination findings remain unchanged, and arterial exploration is then undertaken. Although some recommend immediate exploration of the artery without arteriography, we prefer to obtain an arteriogram to identify the site and nature of the injury prior to exploration, especially since arterial injury is so rare. However, excessive delays are unacceptable, since warm ischemia times of more than 6 hours have been associated with worse outcomes with respect to limb salvage, neurologic compromise, and muscle death.¹²³ Fasciotomy of the leg should be considered in the following situations: prolonged warm ischemia times, significant hypotension in the perioperative period, tense soft tissue compartments, and associated crush injury with significant venous injury in the popliteal or femoral area.⁷³ When an arterial injury is present, fracture stabilization should be performed urgently with a medial approach to the fracture to allow rapid open reduction and internal fixation and subsequent arterial repair. A patient with a warm foot without palpable pulses and a normal arteriogram should be observed in the hospital for 48 hours.

Peroneal nerve injury may be due to direct trauma on the posterolateral aspect of the leg or to a severe varus-producing injury causing overstretching of the nerve. The incidence is approximately 5 percent (six of 111 cases in a compilation of five studies).^{3,19,53,128,221} All peroneal nerve injuries reported in the literature have resolved completely over a 6-month period. If there is no return of nerve function by 3 months, an electromyographic study should be performed. Exploration of the nerve with direct repair or nerve grafting is indicated if fibrillation or denervation is seen or if there is a delay in nerve conduction velocity. Open fractures with associated peroneal nerve injury should be explored at the time of the initial irrigation and debrided, with microscopic direct repair if the nerve is divided.

Associated ligamentous injuries occur relatively com-

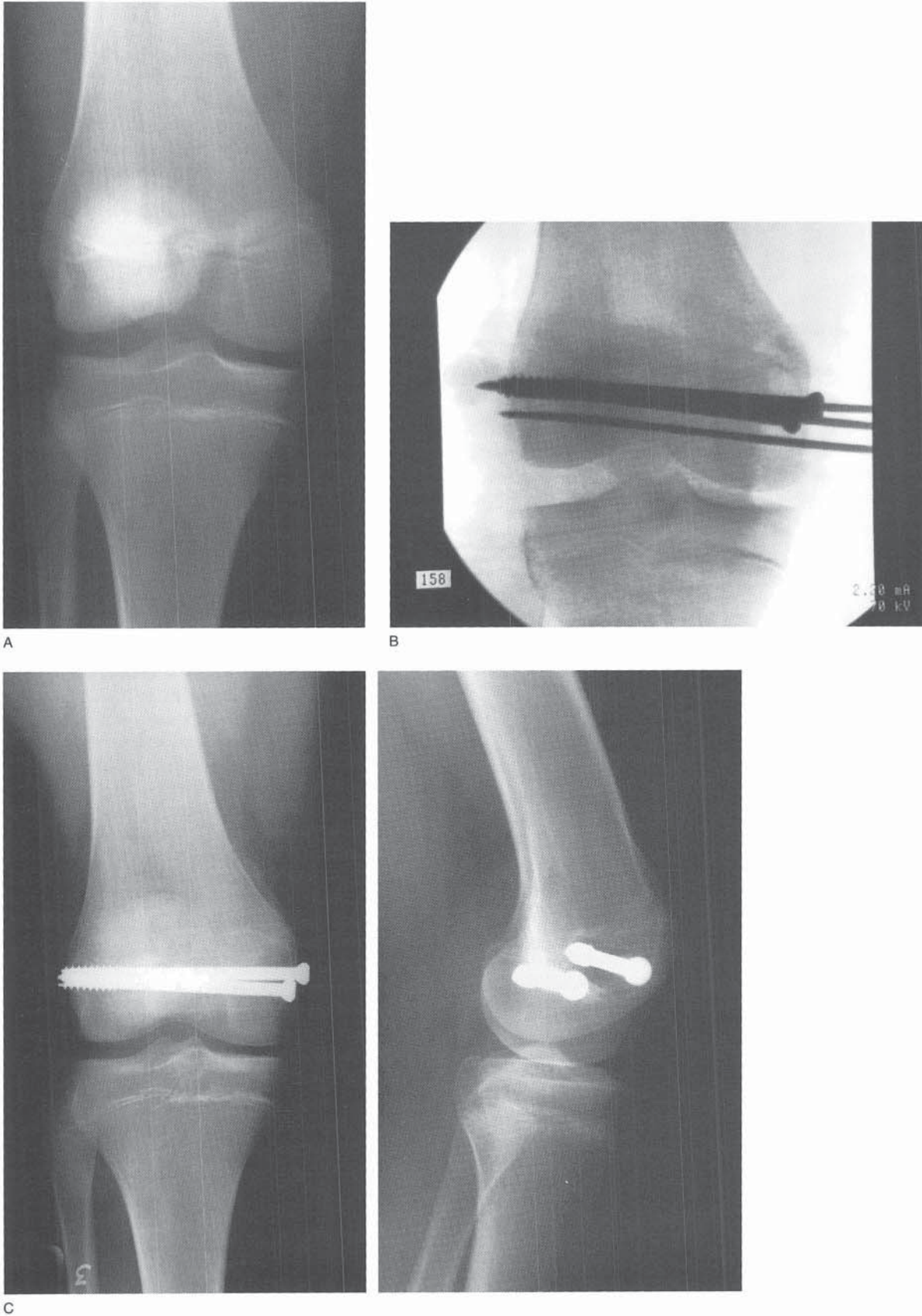


FIGURE 42-99 A Salter-Harris type III distal femoral fracture in a 13-year-old boy that was treated by open reduction and internal fixation. **A**, Initial radiograph showing displacement of approximately 4 to 5 mm. **B**, Open reduction and internal fixation was performed using percutaneously placed screws. **C**, Appearance 4 months after injury. Healing has occurred, with no loss of reduction.

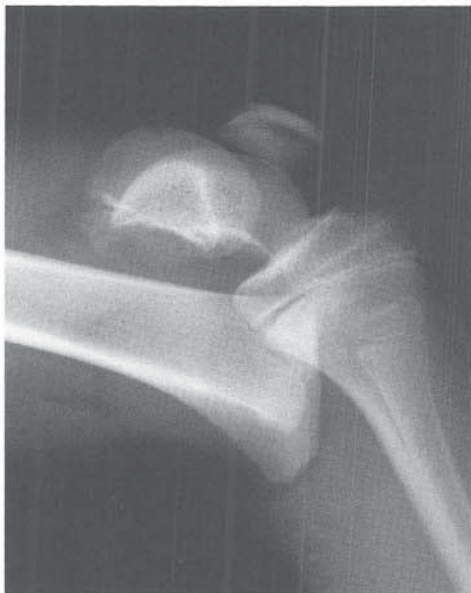

FIGURE 42–100 Severely displaced Salter-Harris type II fracture with hyperextension. Arterial injury was caused by the high-energy force driving the proximal fragment into the posterior compartment of the knee. Arterial reconstruction after closed reduction with pin fixation was performed.

monly in injuries to the distal femoral physis. Bertin and Goble specifically reported on ligamentous injuries associated with physeal fractures about the knee and noted that six (38 percent) of 16 patients with distal femoral physeal injuries had anterior cruciate ligament (ACL) instability; one of them also had valgus instability.¹⁹ A compilation of 111 patients from five studies showed 26 associated ligamentous injuries (23 percent),^{3,53,128,221,227} with the most commonly injured ligament being the ACL, followed by the lateral collateral and then the medial collateral ligament. It is often difficult to fully assess the integrity of the knee ligaments at the time of the initial presentation. However, a careful assessment should be done as soon as fracture healing has occurred. It is also important to examine for meniscal pathology, and arthroscopic examination and treatment may be necessary.

Loss of reduction occurs because of suboptimal stabilization of the unstable fracture, with inadequate external immobilization. Aitken and Magil reported nine fractures treated by closed reduction and cast immobilization, with only two patients maintaining an anatomic reduction.³ They attributed this outcome to not maintaining knee flexion in the anteriorly displaced fractures and inadequate knee extension in those patients with posterior displacement. Others have reported loss of reduction in 40 percent of fractures after the initial reduction and cast immobilization.¹⁴ With the greater utilization of internal fixation devices and strict adherence to correct leg immobilization techniques, loss of reduction has become less prevalent in more recent studies.^{53,184}

LATE COMPLICATIONS. Physeal arrest with residual limb length discrepancy or angular deformity continues to occur relatively frequently despite more exact anatomic reductions and the use of stable internal fixation (Fig. 42–101). Limb length inequality of greater than 2 cm has been reported to occur in 37 percent of cases (64 of 171 patients in five

studies).^{3,53,128,184,221} Risk factors for developing a growth disturbance include high-energy trauma, juvenile age group, severely displaced fractures, and comminuted fractures that produce injury in multiple areas of the physis.¹²⁸

Suspected physeal injury should be thoroughly evaluated with CT. Physeal bar resection is indicated when less than 50 percent of the physis is involved, and when remaining growth is at least 2.5 cm.¹¹⁴ Limb lengths should be plotted on the Moseley straight-line graph over a 1- to 2-year period to determine the projected discrepancy at skeletal maturity.¹⁵³ An alternative method to obtain an approximate estimation of discrepancy at the initial presentation of the patient, or following the identification of the physeal bar, is evaluation of growth remaining using the Green-Anderson tables.⁸³ General treatment guidelines are the following: no treatment is necessary when the discrepancy is less than 2 cm; between 2 and 6 cm, epiphysiodesis of the contralateral distal femur or proximal tibia is indicated; and larger discrepancies should be treated by a femoral lengthening procedure. In the excessively short femur following injury in a young child, multiple femoral lengthening or a femoral lengthening procedure with a contralateral epiphysiodesis is necessary.

Angular deformity is less frequently seen than limb length discrepancy, with a reported incidence of 29 percent (49 of 171 patients in five series).^{3,53,128,184,221} The risk factors are similar to those for development of a limb length discrepancy, and the indications for physeal bar resection are the same. No correlation has been seen between the direction of fracture displacement and the development of a valgus or varus deformity.¹⁸⁴ Treatment is indicated when more than 5 degrees of abnormal angulation is present and consists of angular corrective osteotomies or epiphysiolysis.

Loss of knee motion occurs in approximately 27 percent of distal femoral physeal injuries (45 of 167 patients in five series).^{19,53,128,184,221} It may be due to excessive duration of immobilization with intra-articular adhesions, capsular contraction, or hamstring or quadriceps contraction. In addition, articular incongruities from type III and IV Salter-Harris injuries may predispose to knee joint contractures. Contractures are best prevented by restricting the duration of external immobilization, removing crossed Kirschner wires as soon as possible, and anatomic reduction of intra-articular fractures. Aggressive active and active-assisted range-of-motion exercises should be started as soon as 4 to 6 weeks from the time of fracture. A removable posterior splint can be worn beginning at 4 weeks so that the patient can begin range-of-motion exercises twice per day as the fracture heals.

Once fracture healing occurs, knee ligament integrity should be reevaluated and appropriate treatment instituted if necessary (see subsequent discussion of ACL injuries under Ligament Injuries).

PATELLAR FRACTURES

Fractures of the patella in children are rare, accounting for less than 5 percent of all knee injuries.^{17,160,181,198} The injury is most often caused by a forceful active extension of the knee that usually occurs during jumping or from direct anterior knee trauma, and the diagnosis is difficult to make and often missed. Treatment is similar to the treatment of

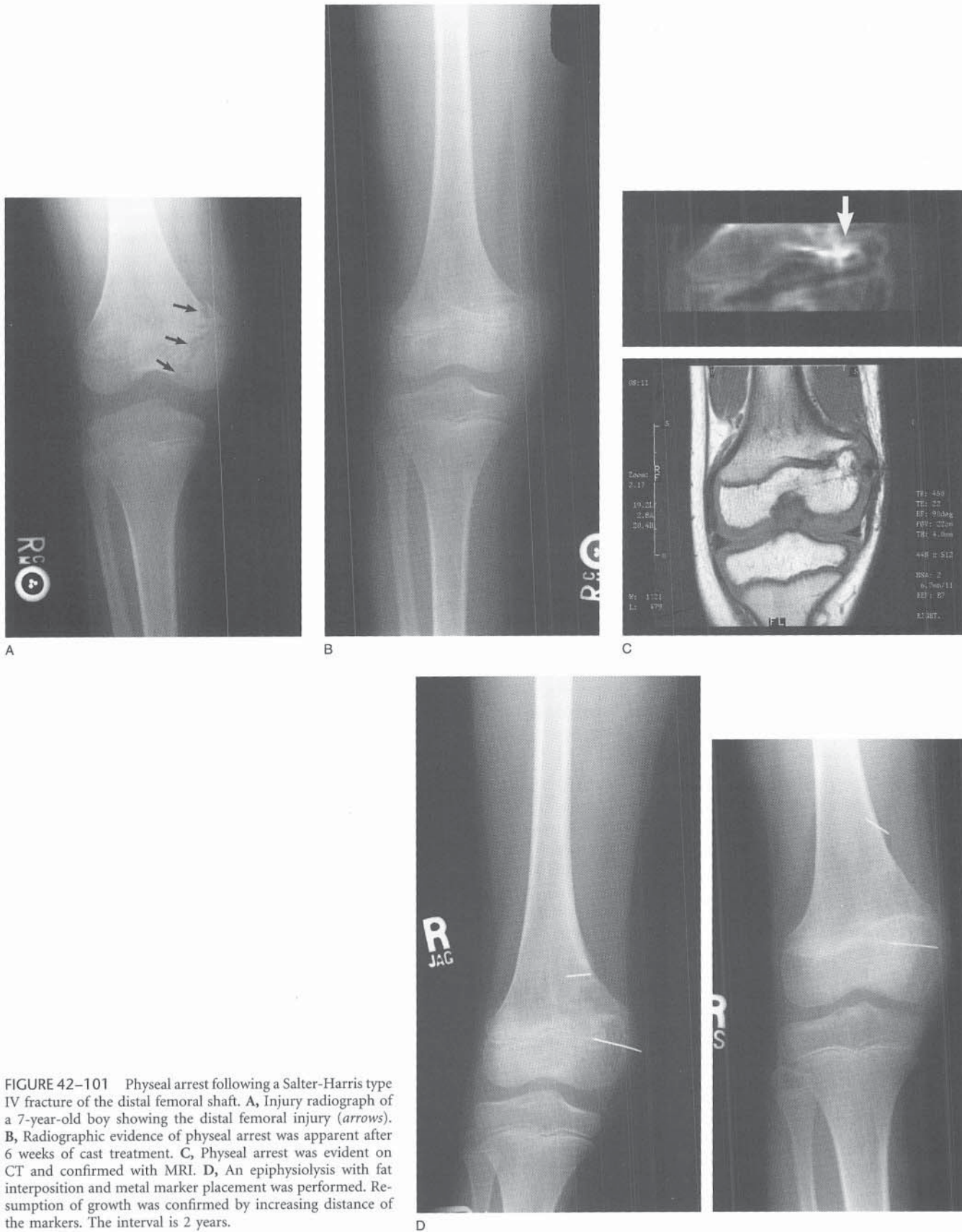


FIGURE 42-101 Physeal arrest following a Salter-Harris type IV fracture of the distal femoral shaft. **A**, Injury radiograph of a 7-year-old boy showing the distal femoral injury (*arrows*). **B**, Radiographic evidence of physeal arrest was apparent after 6 weeks of cast treatment. **C**, Physeal arrest was evident on CT and confirmed with MRI. **D**, An epiphysiolytomy with fat interposition and metal marker placement was performed. Resumption of growth was confirmed by increasing distance of the markers. The interval is 2 years.

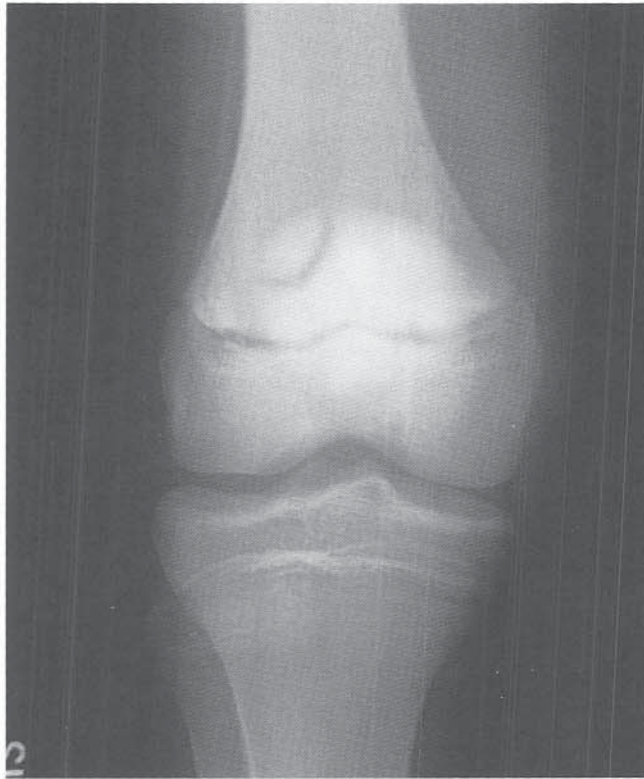

FIGURE 42-102 AP radiograph demonstrating a bipartite patella in the superolateral quadrant.

patellar fractures in adults, with the majority of fractures requiring operative treatment with open reduction and internal fixation. The complication rate from operative fixation is low. When the injury is unrecognized, late reconstruction is needed and may result in a knee extensor lag and unsatisfactory outcome.

Anatomy. The patella is a sesamoid bone that lies within the quadriceps tendon and provides added biomechanical advantage for knee extension. The patella usually has one center of ossification which appears at 2 to 3 years of age, but its appearance may be delayed until the sixth year. There can be up to six smaller associated centers of ossification, which lie peripheral to the primary center of ossification. These centers of ossification coalesce, and ossification begins centrally and continues in a peripheral fashion. Bipartite patella is generally thought to occur in less than 5 percent of all patients. It is thought to be due to failure of the cartilaginous segments to coalesce and ossify, and is usually seen in the superolateral aspect of the patella (Fig. 42-102).^{77,82,163,166}

The articular surface is divided into seven facets separated by ridges. Vertically, a major ridge separates the medial and lateral facets, with a secondary ridge near the medial border that demarcates the odd facet. Two transverse ridges separate the superior, intermediate, and inferior facets. The distal-most pole is nonarticular.^{28,182}

The quadriceps mechanism converges onto a single, trilaminar tendon, with the rectus femoris superficial, the vasti in the middle layer, and the intermedius in the deep layer.¹²⁶ The fascia lata is the deep fascial layer that spreads over the

anterior knee, and those fibers combine with the vastus medialis and lateralis to form the patellar retinaculum, which inserts into the tibia. The retinaculum is completed by contributions from the patellofemoral ligaments, the lateral aspect of the vastus lateralis, and the iliotibial tract.²⁸ The patellar tendon is primarily an extension of the rectus femoris and inserts into the tibial tubercle. Expansions of the iliotibial tract and patellar retinaculum converge onto the patellar tendon at its insertion into the tibia.

The blood supply of the patella has been thoroughly studied by Scapinelli¹⁹⁵ and Crock.⁵⁰ It is organized into two arterial networks. The first is the extraosseous arterial ring, which lies in the thin layer of connective tissue, with contributions from the supreme geniculate, the superior medial and lateral geniculate, the inferior medial and lateral geniculate arteries, and the anterior tibial recurrent artery (Fig. 42-103). The inferior geniculate arteries branch into the ascending parapatellar, oblique prepatellar, and transverse infrapatellar arteries; these arteries anastomose with branches from the superior geniculate arteries. The second network is the intraosseous arterial pattern, which consists of midpatellar vessels that enter in the middle third of the patella, and the infrapatellar branches that run upward from behind the patellar ligament. AVN of the patella following transverse fractures is most often seen in the superior pole, which is more easily isolated from blood flow than the inferior pole.

Classification. In children, patellar fractures can be divided into two basic patterns: primary osseous fractures and sleeve or avulsion fractures. The most common bony fracture is the transverse fracture through the midportion of the patella; however, vertical fractures and stellate-type fractures also occur.¹³⁴ These fractures should be assessed and classified according to whether they are open or closed injuries, following Gustilo's classification.⁸⁹ The second major group of patellar fractures comprises the avulsion-type fractures, better known as sleeve fractures.⁹⁸ This fracture type is most

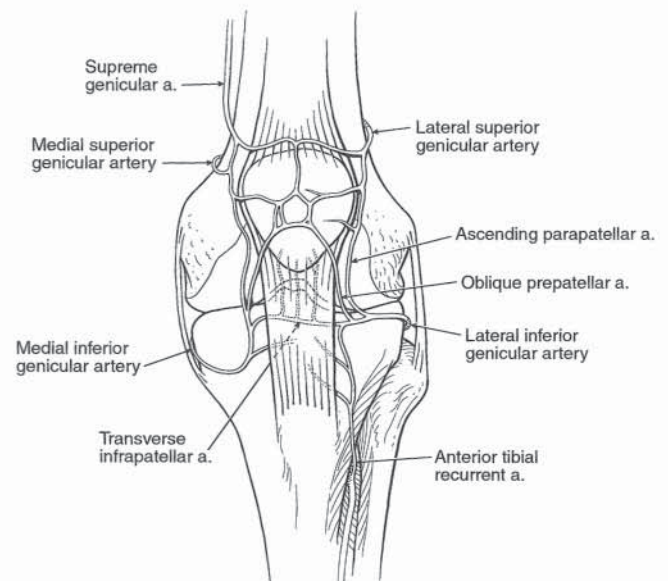


FIGURE 42-103 Arterial blood supply of the patella. The extraosseous arterial ring depicted here demonstrates the rich blood supply of the patella.

often described, and most common, in the inferior pole of the patella; however, it can occur in the proximal pole of the patella, and medial avulsion of the patella is associated with patellar dislocations.^{86,109}

Mechanism of Injury. The mechanism of injury is usually associated with the pattern of the patellar fracture seen radiographically. The majority of transverse midpatellar fractures are due to direct trauma to the patella, often when the patient is involved in a motor vehicle accident, sustains a direct blow to the knee, or falls onto the knee.^{17,134,160,181} Less often such traumatic impact results in a vertical or a stellate-type fracture. Maguire and Canale reported that 22 of 24 patients with patellar fractures sustained the fracture as a result of a direct blow or fall or impact incurred in a motor vehicle accident; only two patients sustained the fracture in a sports activity. There were 20 fractures of the midportion of the patella (comminuted, transverse, or vertical fractures) and four chip or avulsion fractures.¹³⁴ Sleeve fractures are most often associated with a forceful contraction of the quadriceps muscle that usually occurs at the start of a jump during basketball, or in the track and field events of high or long jumping.^{34,98,246} Wu and colleagues reported on five patients with sleeve fractures, all of whom sustained their injuries at the time of take-off for a long or high jump.²⁴⁶ However, direct trauma may also result in the inferior sleeve fracture.¹⁸¹ The superior sleeve or avulsion fracture is often due to a direct blow, and the medial avulsion fracture is associated with lateral dislocation of the knee.

Diagnostic Features. Patellar fractures in children occur between the ages of 8 and 14 years, with the average age being approximately 11 to 12 years. Most patients are boys.^{134,181}

The history should elicit the type of injury and the mechanism, and any manifestations of patellar dislocation at the time of injury. If a direct injury has resulted in a patellar fracture, the instrument or offending object should be determined, especially when an open injury has occurred.

In the complete fracture or avulsion, the patient's symptoms are more pronounced and the physical examination is diagnostic. The knee is swollen, often with a tense hemarthrosis, and tender. Patients are often unable to bear weight because of pain. Knee extension is often difficult, although possible because of residual integrity of the retinacular fibers; however, full active knee extension is usually lacking. Palpation reveals a high-riding patella in the inferior sleeve and transverse type of fractures, and a palpable defect is present.

In the incomplete injury (the undisplaced transverse patellar fracture, the minimally displaced inferior sleeve fracture), symptoms and physical examination findings are less dramatic. Grogan and colleagues reported findings in eight of 17 patients with inferior sleeve fractures who presented 1 week to 4 months following the onset of symptoms. These patients were all involved in competitive sports; however, none could document a specific traumatic episode that triggered the symptoms.⁸⁶ Similarly, undisplaced stress fractures of the patella result in minimal symptoms and inability to recognize a specific inciting event.⁵⁹

The orthopaedic examination should always include evaluation of the entire skeleton and the soft tissue envelope, inspecting for open fractures. Associated fractures are reported to occur in up to one-third of cases, with ipsilateral diaphyseal fractures of the tibia and/or femur accounting

for the majority of associated injuries.¹³⁴ Open fractures account for approximately 30 to 40 percent of all patellar fractures in children and are usually associated with a motor vehicle accident and direct trauma.^{134,181}

Radiographic examination includes AP and lateral radiographs of the knee. The lateral radiograph should be taken with the knee flexed 30 degrees and is usually more informative than the AP radiograph for patellar fractures. The fracture may be undisplaced; mildly displaced, with the anterior aspect displaced while the articular surface remains intact; or completely displaced (Fig. 42–104).¹⁷ Sleeve fractures are often difficult to detect radiographically. It is important to obtain a good lateral radiograph of the knee in order to discern the typical findings. The radiograph should be inspected for small bony fragments coming from the inferior pole of the patella associated with patella alta. The bony fragment seen radiographically is often small but is associated with a large cartilaginous fragment attached to the patellar tendon. The radiograph must be used in conjunction with the clinical assessment to make the diagnosis. A patient with indeterminate radiographs but significant tenderness at the level of the injury or a palpable defect should be treated as if he or she had a sleeve fracture. Other entities that can resemble a sleeve fracture include accessory centers of ossification, which are more often on the anterior aspect of the distal pole of the patella, and the Sinding-Larsen-Johansson lesion, an overuse condition manifesting as small calcifications within the patellar tendon.²¹⁰

The AP radiograph is used to detect a bipartite patella,

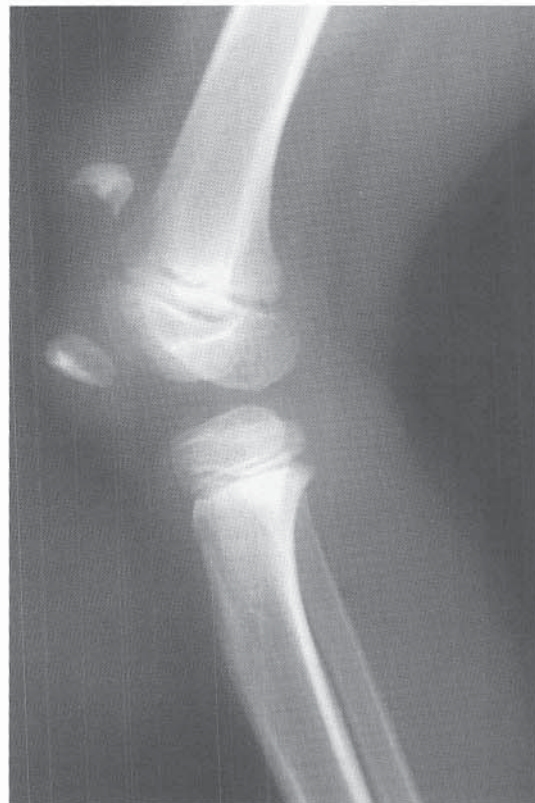

FIGURE 42–104 Displaced transverse fracture of the patella in a 5-year-old.

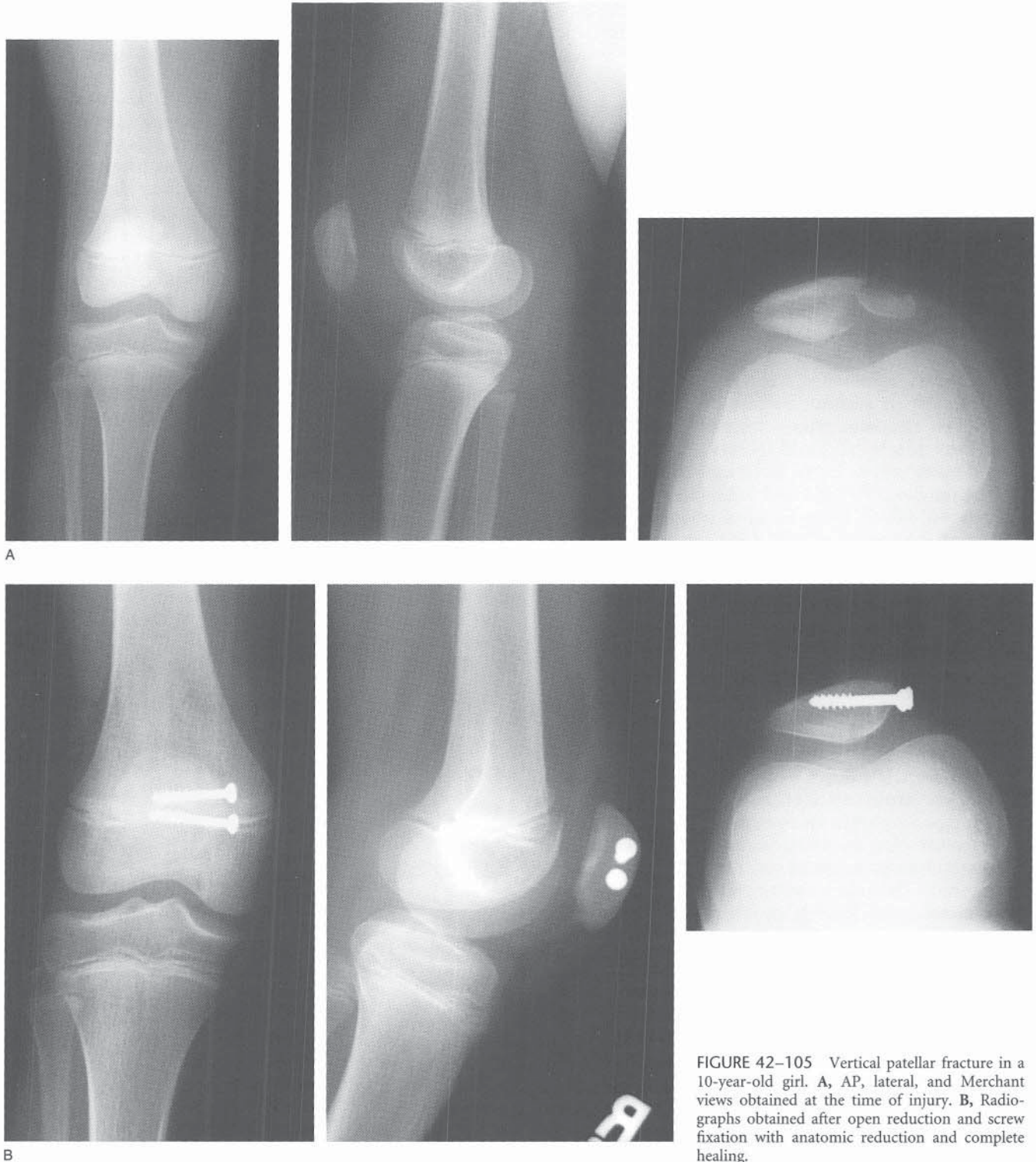

FIGURE 42-105 Vertical patellar fracture in a 10-year-old girl. **A**, AP, lateral, and Merchant views obtained at the time of injury. **B**, Radiographs obtained after open reduction and screw fixation with anatomic reduction and complete healing.

usually seen on the superolateral aspect of the patella. In addition, the uncommon vertical fracture is best seen in this view, as is the comminuted fracture (Fig. 42-105). Comparison radiographs are very helpful in defining the normal anatomy of the particular patient, including confirming the presence of a bipartite patella.

Treatment. The indications for nonoperative and operative treatment are similar to those in adults. Nonoperative

treatment is used in the undisplaced fracture.^{134,180,181} This is especially true when active knee extension is present, indicating that the supporting soft tissue structures (retinaculum) are intact. External immobilization in the form of a long-leg cast with near extension is worn for 6 to 8 weeks and is followed by progressive weightbearing. Maquire and Canale report 83 percent good results in patients with undisplaced patellar fractures treated by external immobilization only.¹³⁴

Operative treatment is indicated in the displaced fracture with more than 4 mm of articular displacement or if the articular step-off is more than 3 mm.^{17,98,134,180,181} The most important aspect of evaluation is to assess the integrity of the articular surface. We prefer operative intervention if displacement or step-off of the articular surface exceeds 2 to 3 mm. In addition, open fractures require operative intervention to include irrigation and debridement and, if necessary, reduction and internal fixation.^{17,98,134,180,181}

For the young child (10 years old or younger) with a sleeve fracture, we prefer nonabsorbable suture repair followed by immobilization in a long-leg cast for 6 to 8 weeks. Anatomic reduction of the sleeve fracture is performed, followed by

suture repair, with the suture placed into the cartilaginous sleeve and the patellar tendon to provide stable fixation (Fig. 42–106). In the child older than 10 years we prefer firm fixation with tension band wiring and Kirschner wire fixation (Fig. 42–107). Patients are allowed to bear weight in the cast and should begin straight-leg-raising exercises 2 weeks following cast application. Grogan and colleagues reported successful treatment with full return to function in nine patients (10 knees) with acute sleeve fractures that were treated operatively.

Sleeve fractures that present late often are minimally displaced. These injuries may be treated with cast immobilization in extension, and despite lack of radiographic union,

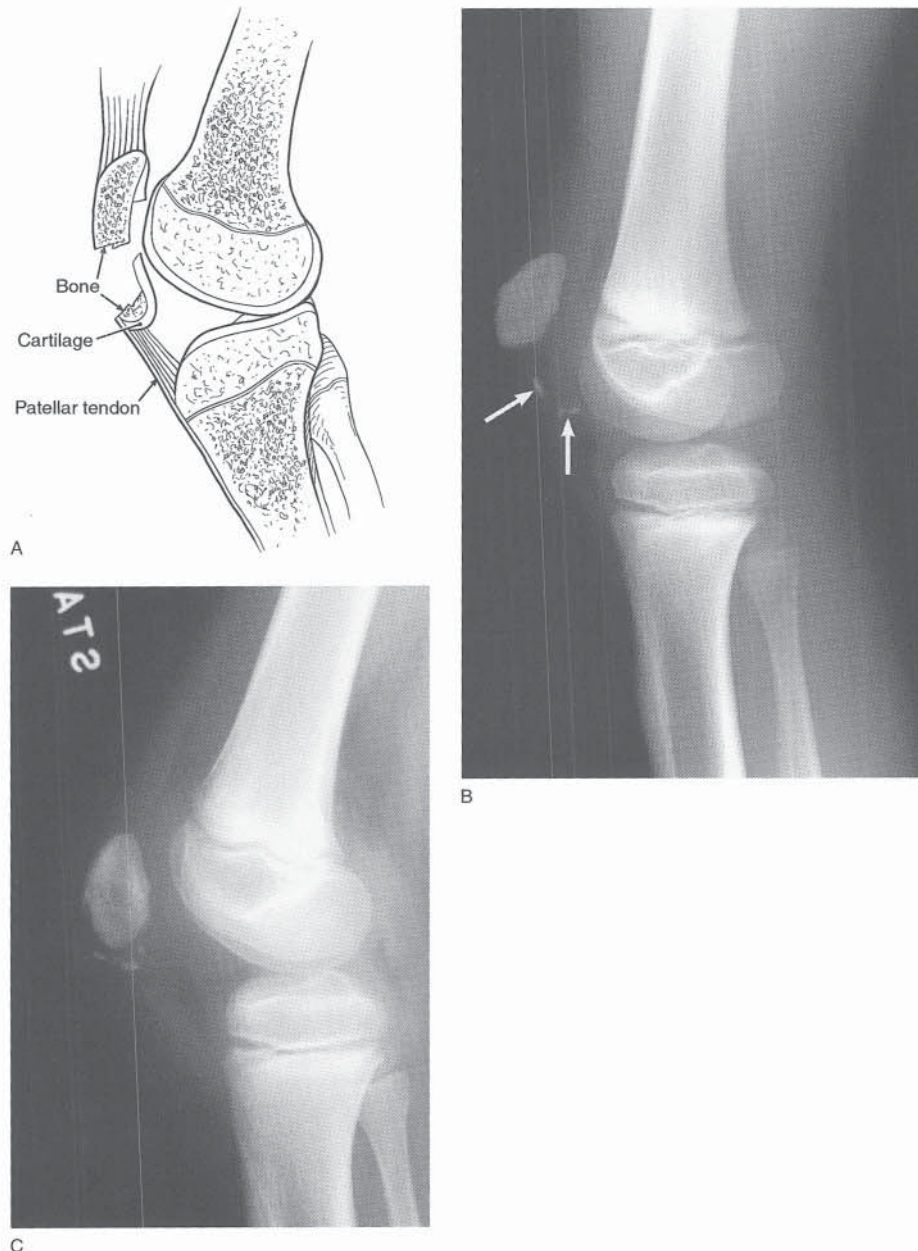


FIGURE 42–106 Patellar sleeve fracture in an 8-year-old boy. **A**, Diagram of a patellar sleeve fracture. The patellar tendon avulses an osteocartilaginous fragment from the distal pole of the patella. **B**, Initial radiographs in an 8-year-old boy, demonstrating a patellar sleeve fracture with the distal osteocartilaginous fragment seen (*arrows*). **C**, Lateral radiograph obtained 6 weeks after open reduction and suture fixation using No. 2 nonabsorbable suture.

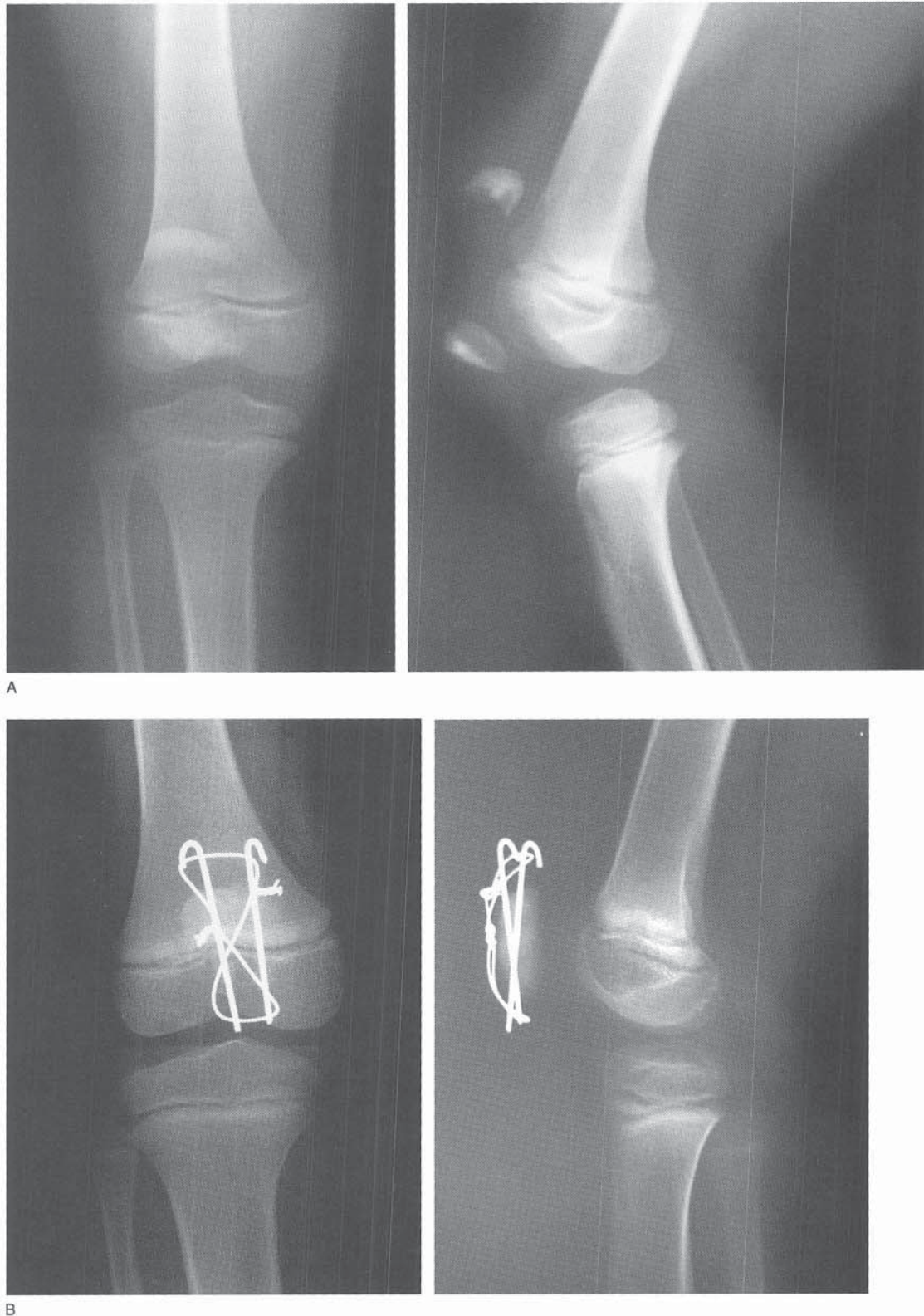

FIGURE 42-107 The tension band technique used to treat a displaced transverse patellar fracture in a 5-year-old girl. A, Initial AP and lateral radiographs. B, Radiographic appearance 4 months after open reduction and internal fixation using a tension band technique.

many patients return to full function.⁸⁶ If extensor lag is noted at the time of the initial evaluation, operative intervention is required to correct the extensor lag.⁸⁶

For the displaced transverse patellar fracture we prefer an open reduction and internal fixation using tension band wiring and Kirschner wire fixation. A vertical incision is made over the patella and fracture reduction is performed, ensuring that the articular surface is reduced anatomically. Wires are then placed starting inferiorly and coming out superiorly, followed by AO-type tension band wiring (Fig. 42–108). Weber and colleagues compared several wiring techniques and demonstrated that Magnusson wiring and the modified tension band wiring techniques prevented separation of the fracture fragments better than circumferential or tension band wiring.²³⁵ Some have advocated the circumferential wiring technique in children to avoid intraosseous penetration and the potential risk of developing a growth disturbance. This, however, has not been seen with internal fixation of patellar fractures in children and may be due, in part, to the older age of the patients.^{17,134,181} Ray and Hendrix reported excellent results and radiographic healing in four transverse patellar fractures treated with open reduction and internal fixation—two with suture repair, two with tension band wiring.¹⁸¹

Comminuted fractures are difficult to treat and tend to have worse results.¹³⁴ Operative intervention is usually required and should consist of thorough evaluation of the fracture pattern and inspection of the joint. Anatomic reduction of the larger fragments should be performed, followed by either excision and removal of small nonarticular fragments or internal fixation of the remaining fragments to the larger fragments, if possible. Although patellectomy was used in the past for the comminuted fracture pattern in children

and was not necessarily associated with a poor result,^{134,181} we prefer to save the patella whenever possible.

Patellar fractures associated with ipsilateral femoral or tibial fractures have been reported to have the worst results.¹³⁴ However, these fractures were treated with traction followed by hip spica casting without internal fixation. In the setting of an ipsilateral femoral shaft fracture, we recommend stable fixation of both fractures with Enders nailing of the femur and open reduction with internal fixation of the patella, followed by a single-leg hip spica cast for 4 to 6 weeks. Range-of-motion exercises of the knee can then be started. When an ipsilateral tibial fracture is present, displaced fractures of the patella should be internally fixed and a closed reduction of the tibia performed, followed by immobilization in a long-leg cast.

For marginal fractures of the patella that are not large and do not contain a significant portion of the articular surface, excision of the fragment usually yields good results.

Complications. Sleeve fractures have few complications when they are recognized early and treated with anatomic reduction and internal fixation.⁸⁶ Reported complications, however, include nonunion due to inadequate fixation and loss of flexion.²⁴⁶ Inadequate fixation may also lead to an extensor lag, as was reported in two of three patients with sleeve fractures treated inadequately with suture and casting alone, respectively.⁹⁸

Undisplaced transverse patellar fractures have uniformly good results with cast immobilization. Displaced transverse patellar fractures do well with anatomic reduction and stable internal fixation; however, loss of reduction may result in extensor lag, chronic infection, and, rarely, AVN of the patella.

TIBIAL TUBEROSITY FRACTURES

Tibial tuberosity fractures are the result of a forced extension of the knee or of being struck with the leg planted on the ground. Operative treatment is the treatment of choice for any displaced fracture or the minimally displaced fracture with significant soft tissue swelling. The results of operative treatment are universally good. Compartment syndrome has been reported in displaced fractures that were treated with closed reduction and casting. Patients awaiting operative treatment should be monitored closely for an impending compartment syndrome, and all displaced fractures require operative treatment.

Anatomy. The tibial tubercle is the most anterior aspect of the proximal tibial epiphysis and contributes to the growth of the proximal tibia. The cartilaginous aspect of the tibial tubercle is the initial stage of development and persists until the age of 9 or 10 years. The two to three secondary centers of ossification begin to appear at the tibial tubercle at age 8 to 12 years in girls and 10 to 14 years in boys. This stage is then followed by the formation of a single tibial tubercle as the secondary centers of ossification begin to fuse together, later followed by physeal closure between the epiphysis and metaphysis.⁶⁴ Fusion of the physis begins centrally and proceeds centrifugally, with the area beneath the tuberosity fusing last.

In the early stages of development of the tibial tubercle the patellar ligament inserts into a fibrous cartilage near

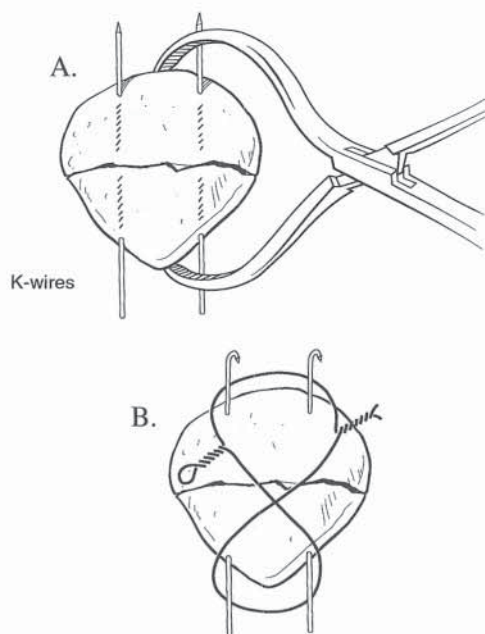


FIGURE 42–108 Tension band technique. **A**, After an open reduction, Kirschner wires are placed in a parallel fashion from inferior to superior. **B**, A loop of wire is then placed in a figure-eight fashion. A loop is then placed both medially and laterally to allow for compression across the fracture site.

the secondary center of ossification. Later the insertion is through fibrocartilage on the anterior aspect of the proximal tibial epiphysis, finally inserting directly into bone following ossification of the tibial tubercle. Retinacular fibers reinforce the attachment of the patellar ligament into the tibial tubercle; the fibers are distributed from both the medial and lateral margins of the patella and distally. These accessory attachments may allow the patient to continue to demonstrate some knee extension despite a tibial tubercle avulsion.

Classification. Watson-Jones first classified tibial tubercle fractures into three types.²³⁴ This classification was later modified by Ogden to better define the pathomechanics of this injury (Fig. 42–109).¹⁶⁷ In type I injuries, the fracture

is distal to the normal junction of the ossification centers of the proximal end of the tibia and tuberosity. Type IA injuries are minimally displaced and the type IB injury is hinged anteriorly and proximally. Type II fractures occur at the junction of the ossification of the proximal end of the tibia and the tuberosity. Type IIA injuries are simple fractures and type IIB injuries are comminuted. Type III fractures extend to the joint and are associated with displacement of the anterior fragment with discontinuation of the joint surface—the type IIIA injury is single fragment, and the type IIIB injury has a comminuted fragment.

Mechanism of Injury. Tibial tuberosity fractures are most often incurred during jumping activities, with the most com-

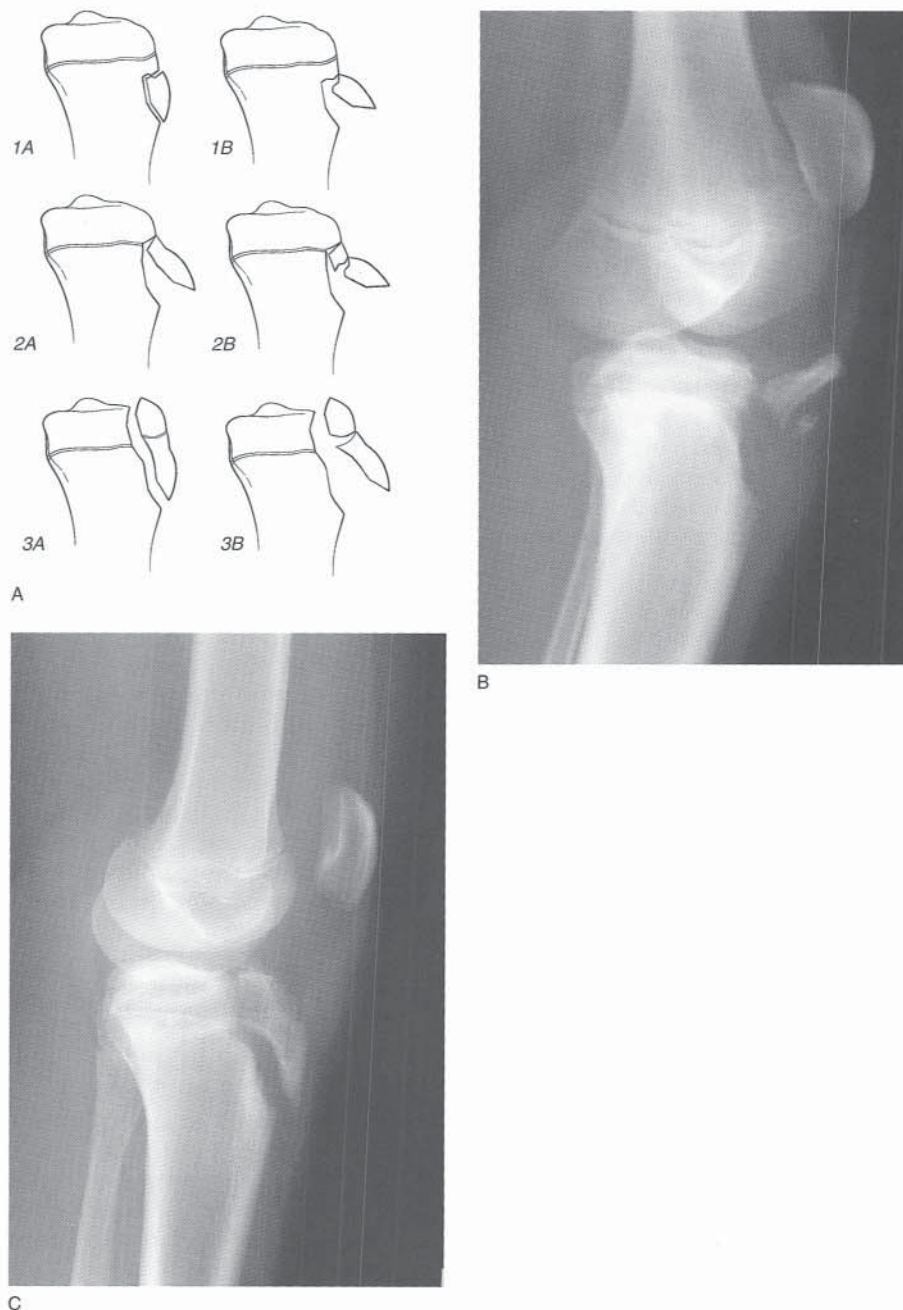

FIGURE 42–109 The Ogden modification of the Watson-Jones classification of tibial tubercle fractures. A, The Ogden classification. B, Lateral radiograph of a type II tibial tubercle fracture. C, Lateral radiograph of a type III tibial tubercle fracture.

mon sports being basketball, football, and long jumping and high jumping.^{41,91,167,175,243} This injury occurs from two types of mechanisms: active extension of the knee with sudden, strong contraction of the quadriceps, especially during jumping, and acute passive flexion against a contracted quadriceps, which often occurs when a football player is tackled.²⁵⁴

Several authors have given an account of an association between Osgood-Schlatter disease and tibial tuberosity fractures.^{56,125,167,243} Ogden and colleagues reported that 64 percent of patients in their series had an associated Osgood-Schlatter lesion,¹⁶⁷ and Levi and Coleman reported a 27 percent incidence in their series.¹²⁵ Ogden and colleagues suggest that this may be due to the change in the secondary center of ossification of the tibial tubercle in which the primarily fibrocartilaginous pattern turns into hypertrophic columnar cartilage, which is structurally weaker.¹⁶⁷

Diagnostic Features. The patient with a tibial tubercle fracture presents with a history of pain in the knee, most often with onset during basketball, football, or at the time of a jump. The patient is unable to fully extend the leg and complains of pain and weakness.

On physical examination swelling and tenderness are noted over the tibial tubercle area, and the knee is usually held in 20 to 40 degrees of flexion. In many type II and III injuries a defect can be palpated at the level of the tibial tubercle. In the displaced fractures the patella rides abnormally high on the femur. The patient is unable to extend the leg, and extension is painful when attempted. It is important to examine the soft tissue compartments of the leg, especially the anterior compartment, since anterior compartment syndromes have been reported.^{170,175,243} In addition, a neurovascular examination should be performed.

The lateral radiograph of the knee will show the fracture, which can then be classified according to the Ogden classification.¹⁶⁷ In the skeletally mature patient the diagnosis is readily apparent; however, in the younger child various stages of development may make diagnosis more difficult. In this situation a lateral radiograph of the contralateral knee is helpful. The level of the patella is an important indication of the degree of displacement of the tibial tubercle. This is best estimated using either the Blumensaat or Insall technique.^{25,105} The Insall technique compares the longitudinal distance of the patella with the distance from the inferior pole of the patella to the tibial tubercle. This ratio should be 0.8 or greater, with smaller numbers indicating some disruption of the patellar ligament or tibial tubercle. Associated bony injuries are rare and do not warrant additional radiographs unless indicated by the history and physical examination.

Treatment. Operative management is the mainstay of treatment for tibial tubercle fractures. However, Ogden type I fractures with minimal displacement have been successfully treated with closed reduction and casting.^{41,91,167,175} In the minimally displaced fracture the knee can be extended fully and then flexed to 30 degrees and held in a long-leg or cylinder cast for 6 to 8 weeks. The patient can then be taken out of the cast and weightbearing begun as tolerated.

We prefer operative management for all type II and III fractures to allow for decompression of the fracture hematoma, anatomic reduction, assessment of intra-articular pa-

thology in type III fractures, and stable internal fixation. A longitudinal incision is made lateral or medial to the patellar tendon. Fracture hematoma is thoroughly evacuated and the fracture bed is cleared of any interposed soft tissue. The fracture fragments are anatomically reduced with the knee extended. We prefer two 4.0-mm or 6.5-mm cancellous screws placed parallel to the joint surface. Washers are frequently used to prevent screw head penetration of the anterior cortex (Fig. 42-110). The fragment can be provisionally fixed with the first drill bit or a smooth Kirschner wire while the second screw is placed. The patellar tendon and its lateral attachments are then sutured securely. Since these fractures are most often seen in patients nearing skeletal maturity, and since physeal arrest with angular deformity has not been reported following these fractures, it is not necessary to go to great efforts to avoid the physis. In the comminuted fracture multiple screws may be necessary, or a tension band wiring technique can be employed to allow fracture stabilization and provide a buttress for the small fracture fragments.¹⁷⁵

Postoperatively, a long-leg or cylinder cast should be used for 6 weeks, followed by gentle active and active-assisted range-of-motion exercises and quadriceps strengthening. Full athletic activities are generally restricted for an additional 4 to 6 weeks until full range of motion and quadriceps strength return.

Complications. In general, operative repair of tibial tubercle avulsion injuries produces excellent results with return to full, preinjury activities. Although rare, the most common complications following these injuries are: compartment syndrome, loss of knee motion, prominent tibial tubercle, and reinjury.

Compartment syndrome has been reported in six patients. It occurred in the anterior compartment, and all patients had been treated without, or were awaiting, operative treatment.^{170,175,243} Pape and colleagues described two patients who had been managed with external immobilization for type II and III fractures.¹⁷⁰ These authors noted the proximity of the tibial tubercle to the anterior compartment and the anterior tibial recurrent artery. They suggested that tibial tuberosity fractures are associated with significant soft tissue injury, which predisposes to compartment syndrome. The treating physician should be aware of this complication and monitor any patient who initially presents with a displaced tibial tubercle fracture awaiting operative treatment or the undisplaced or minimally displaced fracture treated with nonoperative methods.

In type III fractures, meniscal injury may occur and therefore should be evaluated for at the time of surgery through a small knee arthrotomy. The medial or lateral meniscus, or both, may be torn at the time of the initial injury. Wiss and associates reported that two of 15 patients with type III avulsions had peripheral detachments of both menisci, and a third had a transverse tear of the anterior horn of the medial meniscus.²⁴³ Loss of motion of the knee has been reported in a single case in which there was lack of extension by 25 degrees following an open reduction and internal fixation of a type III injury. Other complications are rare and include infection, nonunion, refracture when activities are begun early, and nonunion of the distal fragment in a type III fracture, and, in a single reported case, a pulmonary embolism, which was treated successfully.^{41,167,243} Bursitis over

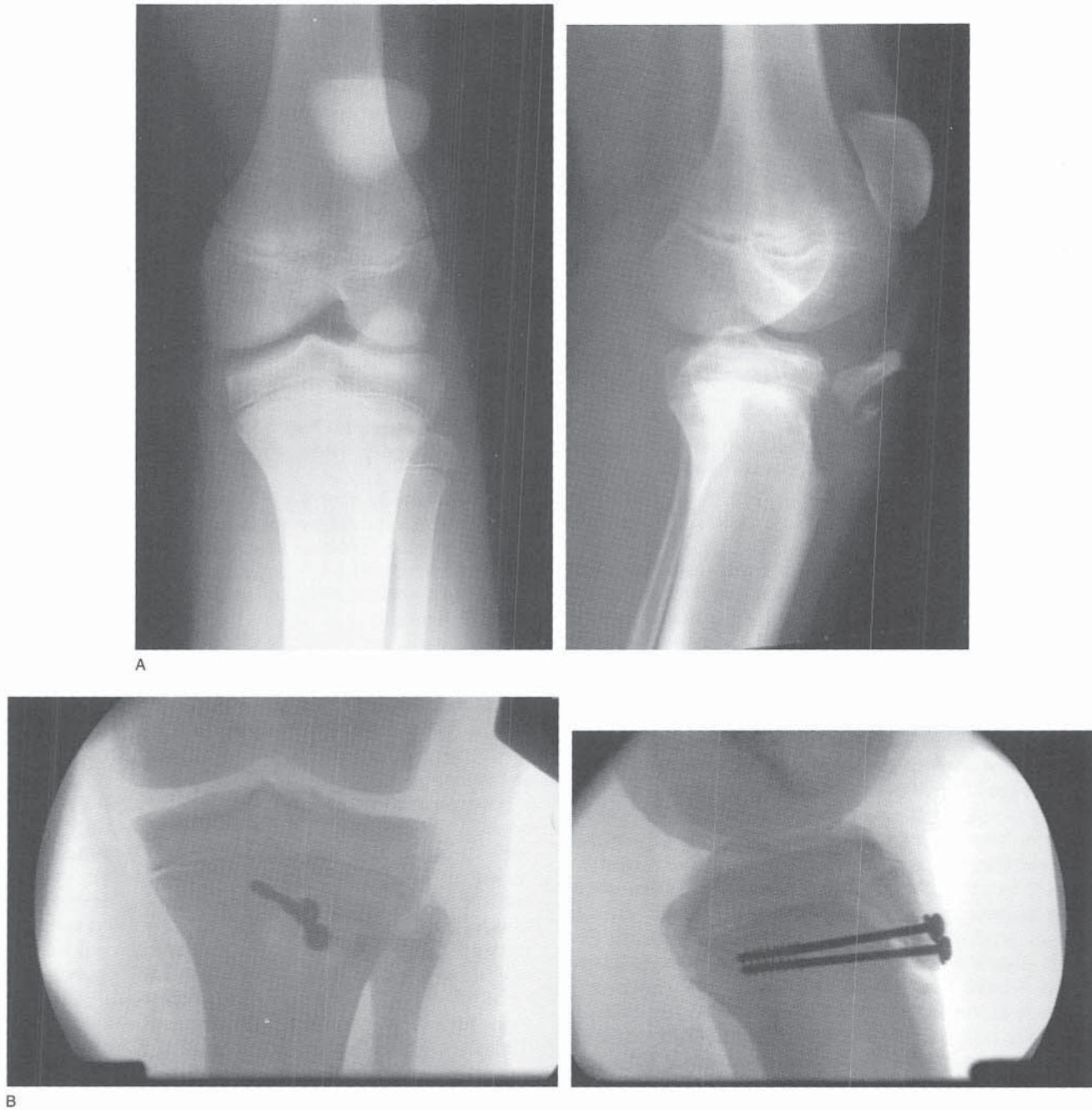


FIGURE 42-110 Open reduction and internal fixation of a displaced (type II) tibial tubercle fracture in a 14-year-old boy who sustained the fracture while long-jumping. **A**, Initial radiographs. **B**, Postoperative views showing anatomic reduction with internal fixation achieved using partially threaded cancellous screws with washers.

the screw heads has been reported in five of 15 patients treated with open reduction and internal fixation for type III fractures; the bursitis resolved following screw removal.²⁴³

PROXIMAL TIBIAL PHYSIS FRACTURES

Injuries to the proximal tibial physis are rare, accounting for approximately 0.5 to 3 percent of all physeal injuries in children.^{35,156,173} This is due to the lack of collateral ligamentous attachments to the proximal tibial epiphysis, which allows valgus or varus forces to be transmitted through these

ligaments to their attachments on the distal femoral physis, fibular head, and the tibial metaphysis. These fractures may be difficult to diagnose when the radiographs look normal, and complications, including significant arterial injury, are relatively common.

Anatomy. The proximal tibial ossific nucleus forms at approximately 2 months of age, with the secondary center of ossification of the tibial tubercle appearing between 10 and 14 years. This unites with the proximal tibial epiphysis at approximately 15 years. Closure of the proximal tibial physis

is thought to begin centrally and proceed to the periphery.¹⁶⁷ Radiographic investigations of patients ages 12 to 20 years have shown that the proximal tibial physis appears to fuse posteriorly, followed by anterior fusion.²³

The joint capsule incompletely surrounds the knee with a defect to allow the popliteus tendon to travel from the proximal tibia to the posterior aspect of the distal femoral epiphysis. The capsule inserts into the tibial epiphysis and the lateral and medial collateral ligaments attach distally to the fibular head and the proximal medial tibial metaphysis, respectively.

The vascular anatomy is important in understanding the relatively high incidence of vascular injuries associated with this fracture. The popliteal artery travels close to the proximal tibia and has fibrous attachments to the posterior capsule. At the level of the proximal tibial epiphysis it branches, giving off the lateral and medial inferior geniculate arteries, which further tether the popliteal artery. The three major branches (peroneal, anterior tibial, and posterior tibial arteries) divide off the popliteal artery distal to the soleus muscle. Immediately distal to the trifurcation the anterior tibial artery penetrates the interosseous membrane to travel to the anterior compartment of the leg, again tethering the artery. Additional fixation points include the connective tissue septa in the terminal aspect of the adductor canal, in the posterior aspect of the articular capsule, and in the deep portion of the peroneal muscle. These multiple levels of tethering and the close proximity of the artery to the proximal tibial epiphysis result in a high incidence of arterial injury.

Classification. Fractures of the proximal tibial physis should be classified according to both the Salter-Harris classification and the mechanism of injury to provide a guideline for patient evaluation, fracture treatment, and give the most accurate prognosis. For example, the patient with a displaced, hyperextension Salter-Harris type I injury is at high risk for vascular injury; the type I fracture is also associated with a high incidence of physeal arrest.^{35,207,245}

Type I fractures account for 15 percent of proximal tibial physeal fractures and are usually nondisplaced. These injuries must be carefully evaluated to avoid missing the undisplaced fracture. When a type I injury is suspected, stress radiographs may confirm the diagnosis (Fig. 42–111).

Type II injuries are the most common, accounting for approximately 37 percent in a combined series of patients (41 of 112 in four series).^{35,177,207,245} These injuries are usually the result of a valgus stress to the knee with a lateral metaphyseal fragment and a medial physis injury (Fig. 42–112).^{35,207,244} The majority of type II fractures are displaced at the time of evaluation, with Shelton and Canale reporting that 71 percent of fractures were displaced, predominantly in the medial direction.²⁰⁷ If significant displacement exists, these injuries may not be reducible with a closed reduction, owing to interposition of soft tissue structures such as the periosteum or the pes anserinus.²⁴⁴ The rare flexion type II fracture is caused by an injury while jumping and results in the metaphyseal fragment being posterior.²³

Type III injuries account for 21 percent of these injuries (24 of 112 in four combined series).^{35,177,207,245} Two major types of fractures occur. The first, and the more common, travels through either the lateral or medial plateau and is best seen on an AP radiograph. The second is an injury

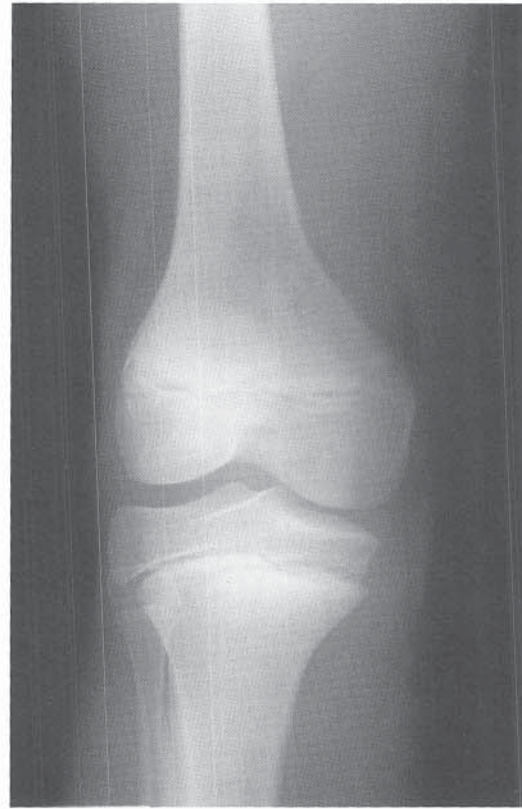

FIGURE 42–111 Salter-Harris type I proximal tibial fracture. Note the medial displacement of the metaphysis.

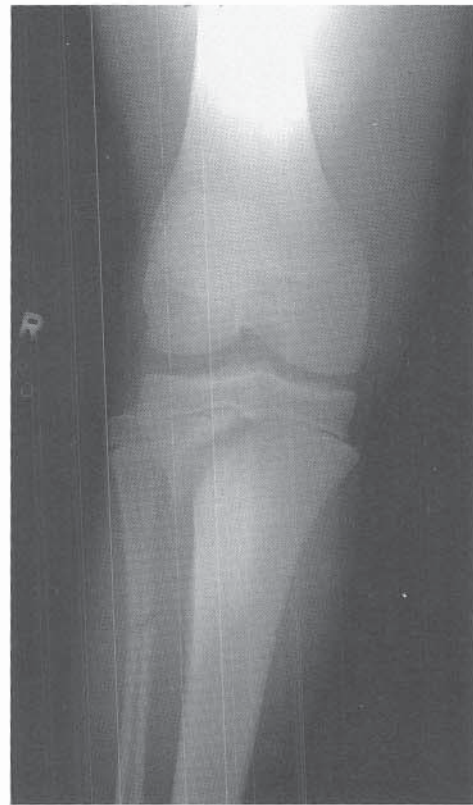


FIGURE 42–112 Salter-Harris type II fracture of the proximal tibia with an associated proximal fibular fracture. This was due to valgus force applied to the lateral aspect of the knee while the patient was playing football.

involving both the tibial tubercle and the anterior aspect of the proximal tibial epiphysis and is best seen on the lateral radiograph.²⁰⁷ These fractures are commonly displaced, and the majority require operative intervention.

Type IV fractures are the least common, accounting for 16 percent of all proximal tibial physeal injuries (18 of 112).^{35,177,207,245} Patients who have sustained indirect trauma usually have injury to the lateral tibial plateau and require operative intervention (Fig. 42–113). Of the five patients with lawnmower injuries in the series reported by Burkhardt and Peterson, all five had type IV injuries; four developed angular deformity requiring further surgery, and the fifth patient developed osteomyelitis.³⁵

Type V fractures are rare, often being recognized only after physeal arrest has occurred. Burkhardt and Peterson were the first to report a type V proximal tibial physeal injury in two patients who had an associated distal tibial fracture and unrecognized proximal physeal injuries. Both patients had limb length discrepancies, which were treated by a 5-cm shortening of the contralateral femur in the first patient and by lengthening of the tibia (which was complicated by compartment syndrome) in the second patient.³⁵ A second report in the literature described an associated displaced tibial spine injury in a patient who, at final follow-up, had a varus deformity of 2 degrees, a flexion contracture of 30 degrees, and early degenerative joint disease.¹⁷⁷

Mechanism of Injury. Both indirect and direct trauma to the knee can result in fractures of the proximal tibial physis. The most common mechanism is an indirect blow to a hyperextended knee when the lower leg is in a fixed posi-

tion.^{35,177,207,245} Similarly, valgus, varus, and, rarely, flexion-type indirect trauma can result in these injuries.^{23,35,207,245} Direct trauma can account for these injuries, with the leg fixed and then struck while the individual is playing football or is run over by a motor vehicle or lawnmower.^{35,238,244}

Sporting activities and motor vehicle accidents account for most of these fractures reported in the literature. Shelton and Canale reported that 18 (47 percent) of 38 patients were injured while participating in sports—most commonly football, followed by basketball. Twelve (32 percent) were injured in automobile or motorcycle accidents. Others have reported a higher incidence of proximal tibial physeal injuries being incurred in motor vehicle accidents.^{35,177} Flexion-type injuries are rare and have only been reported in patients who were engaged in jumping activities, which can produce the avulsion, shear, and compression stresses that produce this injury.²³ The patients are typically older (16 years), an age when the anterior proximal tibial physis remains open but the posterior physis has closed. Lawnmower accidents are most often reported in younger children (2 to 6 years old), accounting for up to 18 percent of patients in one series.³⁵

Associated injuries may occur in up to 42 percent of patients, with fibular fractures being most common.^{207,245} Other associated injuries include ipsilateral tibial and femoral shaft fractures, collateral ligament tears, patellar fractures, quadriceps rupture, and patellar avulsion injuries.^{35,172,207}

Finally, miscellaneous causes account for a small percentage of proximal tibial physeal injuries. Among them are a difficult birth, especially with a breech presentation,²¹⁵ and

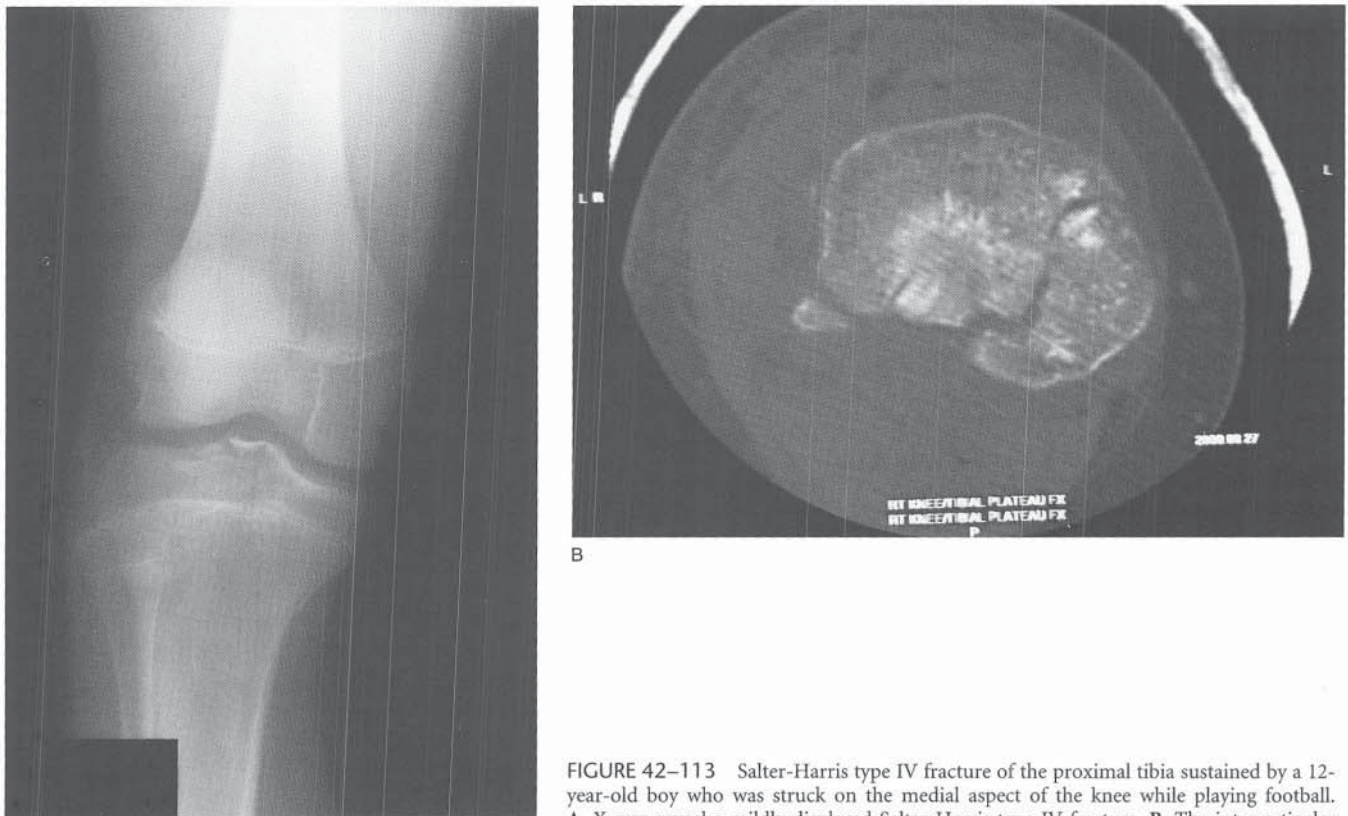


FIGURE 42–113 Salter-Harris type IV fracture of the proximal tibia sustained by a 12-year-old boy who was struck on the medial aspect of the knee while playing football. **A**, X-rays reveal a mildly displaced Salter-Harris type IV fracture. **B**, The intra-articular fracture is seen on CT, with a split in the medial plateau.

the patient with myelomeningocele, who presents without a history of trauma and will have local warmth, redness, swelling, and increased body temperature. Patients with myelomeningocele and proximal tibial physeal fractures, usually present late, have callus formation on radiographs, and require immobilization for at least 8 weeks.¹²¹

Diagnostic Features. The typical patient is a boy between the ages of 13 and 16 years.^{23,35,207,245} A careful history is important to determine the mechanism of injury (direct or indirect trauma), the time the injury occurred, and the location of pain and other symptoms.

On examination, the affected knee usually has an effusion and is held in a flexed position. Knee extension is painful and resisted by hamstring spasm. The alignment of the leg may provide information as to the mechanism of injury. With a hyperextension injury the knee may be flexed only 10 degrees, whereas in a flexion-type injury the knee is more flexed at the time of presentation. An injury due to direct impact on the lateral aspect of the leg will produce a valgus-type deformity that often is a Salter-Harris type II injury, with the metaphyseal fragment on the lateral side and an associated fibular fracture and medial collateral tear.

Because vascular injury is relatively common, palpation of the distal pulses (dorsalis pedis and posterior tibial) is critical in any patient who may have a proximal tibial physeal injury. Serial examinations of the leg with normal pulses is mandatory during the initial 24 to 48 hours, no matter what type of treatment has been rendered. In the displaced fracture with absent pulses, fracture reduction should be performed urgently, followed by reexamination of the pulses. The pulses usually return at that point and serial examinations should be performed. Arteriography is indicated if the pulses do not return to normal following fracture reduction.

The leg should be carefully evaluated to ensure that a compartment syndrome is not present or developing. The soft tissue compartments should be palpated to ensure they are supple and not tense. Passive hyperextension of the toes should not result in excess pain in the anterior compartment of the leg. Radiographic examination should always include a true AP and lateral view of the knee so that pure flexion or extension injuries are not missed. The radiograph should be analyzed for separation or displacement of the physis and for metaphyseal or epiphyseal fracture lines. The initial radiographs may not reveal any abnormalities; however, in the setting of a history and physical examination suggestive of this injury, stress radiographs should be obtained. This may be done using plain radiography; however, we prefer to obtain stress radiographs in the fluoroscopy suite, with the patient under conscious sedation, to allow real-time imaging. Stress should be applied to the knee in both the coronal and sagittal planes to fully assess the proximal tibial physis. It is important that the initial manipulation be gentle, as the physis may be very unstable and excess hyperextension can result in injury to the popliteal artery. In addition, excess stress to the physis can result in physeal bar formation.

Further imaging studies are useful for Salter-Harris type III and IV injuries to assess joint incongruity, fracture line orientation, and fracture displacement. MRI is rarely used in assessing these injuries; however, it may be useful in the patient with a suspected ligamentous injury or when soft

tissue interposition at the fracture site is thought to be present.

Treatment. Only after careful analysis of the distal pulses can treatment of these fractures begin. The goals of treatment are to obtain an anatomic reduction without imparting further damage to the proximal tibial physis, and to maintain the reduction until healing has occurred. Treatment of the displaced fracture that requires manual reduction should be performed at least under conscious sedation and preferably under general anesthesia to allow a gentle reduction to be performed without stressing the physis unnecessarily.

Nonoperative treatment is indicated for the undisplaced fracture as well as for the minimally displaced fracture that can be reduced under general anesthesia and is stable with external immobilization without excess flexion of the knee (more than 60 degrees). The most common type of fracture is the hyperextension Salter-Harris type I or II fracture. Reduction is performed by an anteriorly directed translation of the metaphyseal fragment while manual traction is applied to the leg with the thigh stabilized by an assistant. Flexion of the knee is necessary to obtain and maintain the reduction. Cast immobilization should be used for 4 to 6 weeks, with the knee in no more than 60 degrees of flexion to avoid an increased risk of arterial compromise and subsequent compartment syndrome. The cast should be removed at 3 weeks to place the knee into 20 to 30 degrees of knee flexion. Aitken described nine patients who had mild displacement following reduction but experienced complete spontaneous correction without deformity or clinical shortening in all cases.² Similar results were reported by Burkhardt and Peterson, who treated 12 patients with type I or II fractures with casting alone or closed reduction followed by casting. Two patients required operative procedures at a later date to excise a physeal bar.³⁵ However, Shelton and Canale described two patients with displaced hyperextension-type Salter-Harris type II injuries who initially underwent closed reduction.²⁰⁷ One patient had a satisfactory result despite some mild recurrence of the posterior displacement, and in the other patient the closed reduction was unsuccessful, requiring open reduction. Similarly, Wozasek and colleagues reported successful casting or closed reduction and casting in six of 11 patients with type II fractures.²⁴⁵

The patient with a valgus-type Salter-Harris type II injury may initially be treated with a closed reduction and casting. The reduction maneuver employs a varus force applied to the knee while axial traction is applied to the leg with the knee extended, followed by immobilization in a long-leg cast, with mild varus molded into the cast (Fig. 42-114). Successful closed reduction and casting was reported in seven patients with displaced valgus-type injuries.²⁰⁷ Anatomic reduction should be achieved without any excess widening of the physis or a springy feeling when a varus reduction maneuver is applied, because soft tissue interposition (pes anserinus or periosteum) may be present.²⁴⁴

If a closed reduction is to be performed, careful assessment of the peripheral pulses is required following reduction and casting. Our preference is to apply a well-molded plaster cast followed by leg elevation and close observation of the patient in the hospital for 24 to 48 hours, with serial examinations of the peripheral pulses and passive motion of the toes. If significant swelling is present at the time of reduction

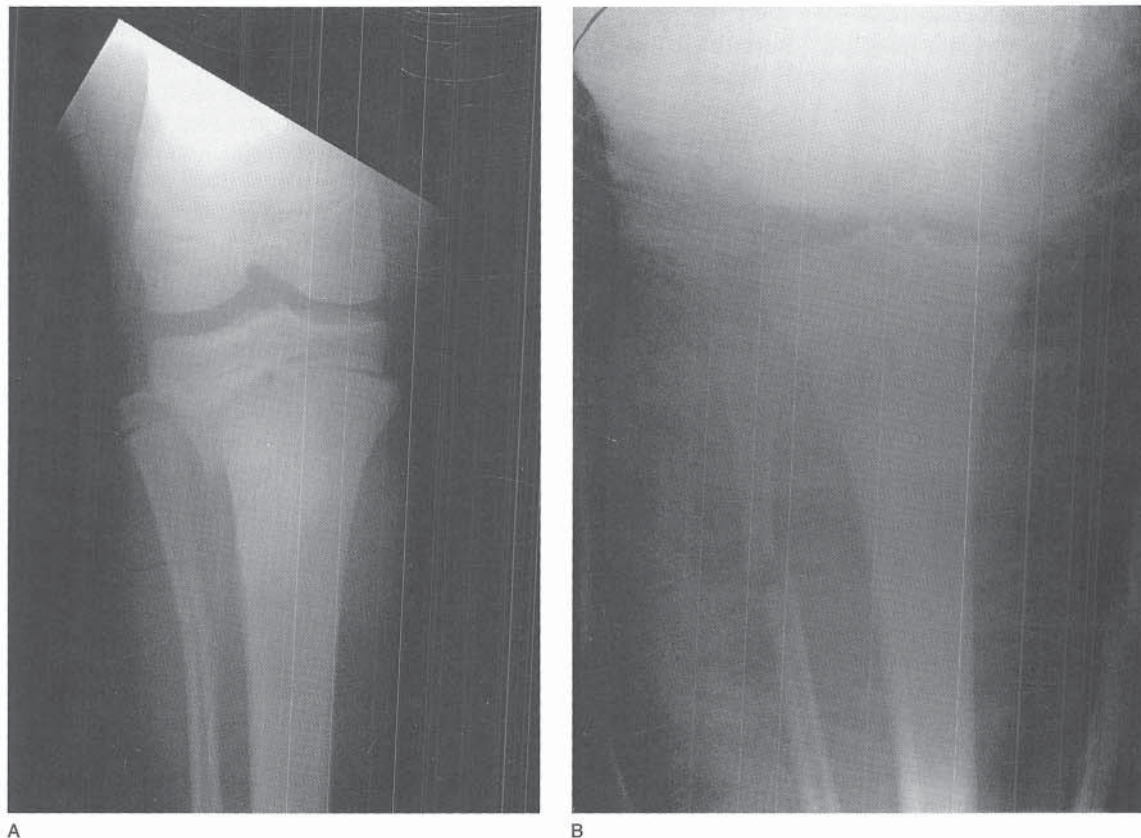


FIGURE 42-114 Closed reduction and casting of a Salter-Harris type II fracture in a 13-year-old boy. A, Initial radiograph. B, Accurate reduction was achieved by applying axial traction and a varus force to the patient's knee.

or there is any concern for an impending compartment syndrome, the cast should be bivalved at the time of application. Radiographs should be obtained weekly for the initial 2 weeks to ensure that fracture reduction is maintained. A mild displacement of a few millimeters is acceptable within the first 2 weeks, since re-reduction may increase the risk for physeal bar formation.

In the patient with a Salter-Harris type III or IV fracture that is undisplaced, long-leg casting can be performed.^{207,245} In those type III fractures that involve the anterior aspect of the epiphysis, displacement is usually present, and the fracture should be treated by open reduction and internal fixation.²⁰⁷

The indications for operative treatment of these injuries include the following: (1) failed closed reduction (following a maximum of two attempts) with residual displacement in type I and II fractures; (2) failure to maintain reduction in a long-leg cast with less than 40 degrees of knee flexion; (3) all displaced type III and IV fractures; (4) the presence of an associated arterial injury; and (5) the presence of an associated ipsilateral fracture that makes immobilization of the leg difficult or impossible.

In the unstable physeal injury that cannot be maintained with external immobilization, smooth pins should be placed in a crossed fashion, crossing distal to the physis. The pins can be left out of the skin to make removal at 4 to 6 weeks easier (Fig. 42-115). Cast immobilization is utilized for 6

to 8 weeks. In the displaced type II fracture, pin fixation should be used to stabilize the metaphyseal fragment to prevent penetration across the physis.

Open reduction with internal fixation is required in the displaced type III and IV fractures. A small arthrotomy is used to visualize the articular surface to allow anatomic reduction. This is then followed by percutaneous screw fixation of the epiphysis for type III injuries and/or the metaphyseal fragment in type IV injuries. An alternative method is to use arthroscopic visualization of the articular surface to guide fracture reduction and confirm articular congruity following percutaneous fixation of the fracture fragments. We prefer cancellous screw fixation (4.0- or 6.5-mm screws) to gain some compression across the fracture site (Fig. 42-116). Cast immobilization should be performed for 6 to 8 weeks. Early motion can be started at 4 to 6 weeks by allowing the patient to wear a removable splint, which can be taken off to perform these exercises.

Arterial injury in the setting of a hyperextension injury requires stable fixation of the fracture prior to repair of the arterial injury. Fixation can be achieved with percutaneous smooth pin fixation.

Complications. The results of treatment of proximal tibial physeal injuries are good (when lawnmower injuries are excluded), with satisfactory outcomes reported in 74 to 86 percent.^{35,207,245} All patients with lawnmower injuries had unsatisfactory results.³⁵

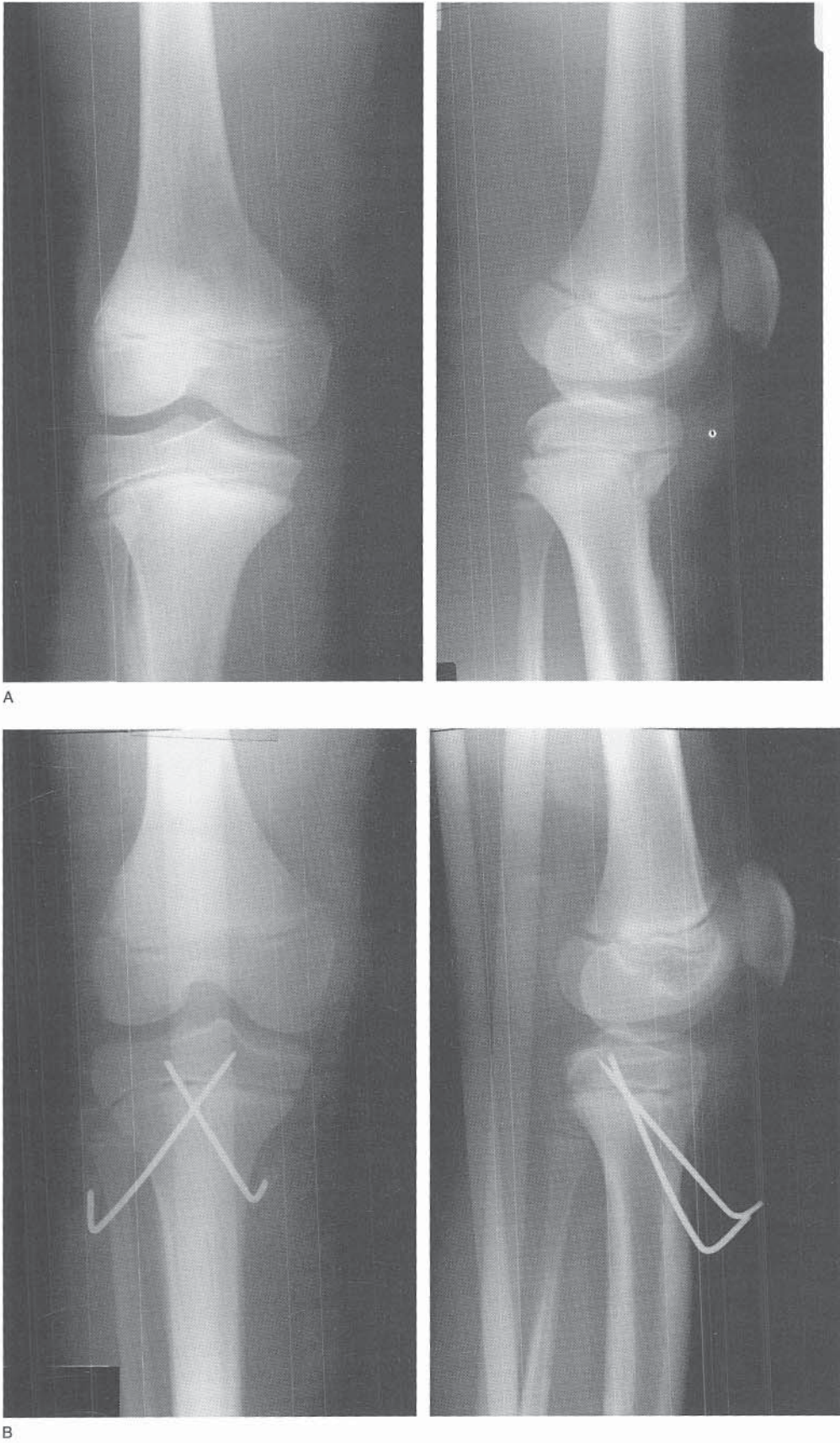


FIGURE 42-115 Salter-Harris type I fracture in a 9-year-old child. **A**, Initial AP and lateral radiographs demonstrating mild displacement. **B**, Radiographic appearance after closed reduction and percutaneous pinning in which the pins were placed in retrograde fashion.

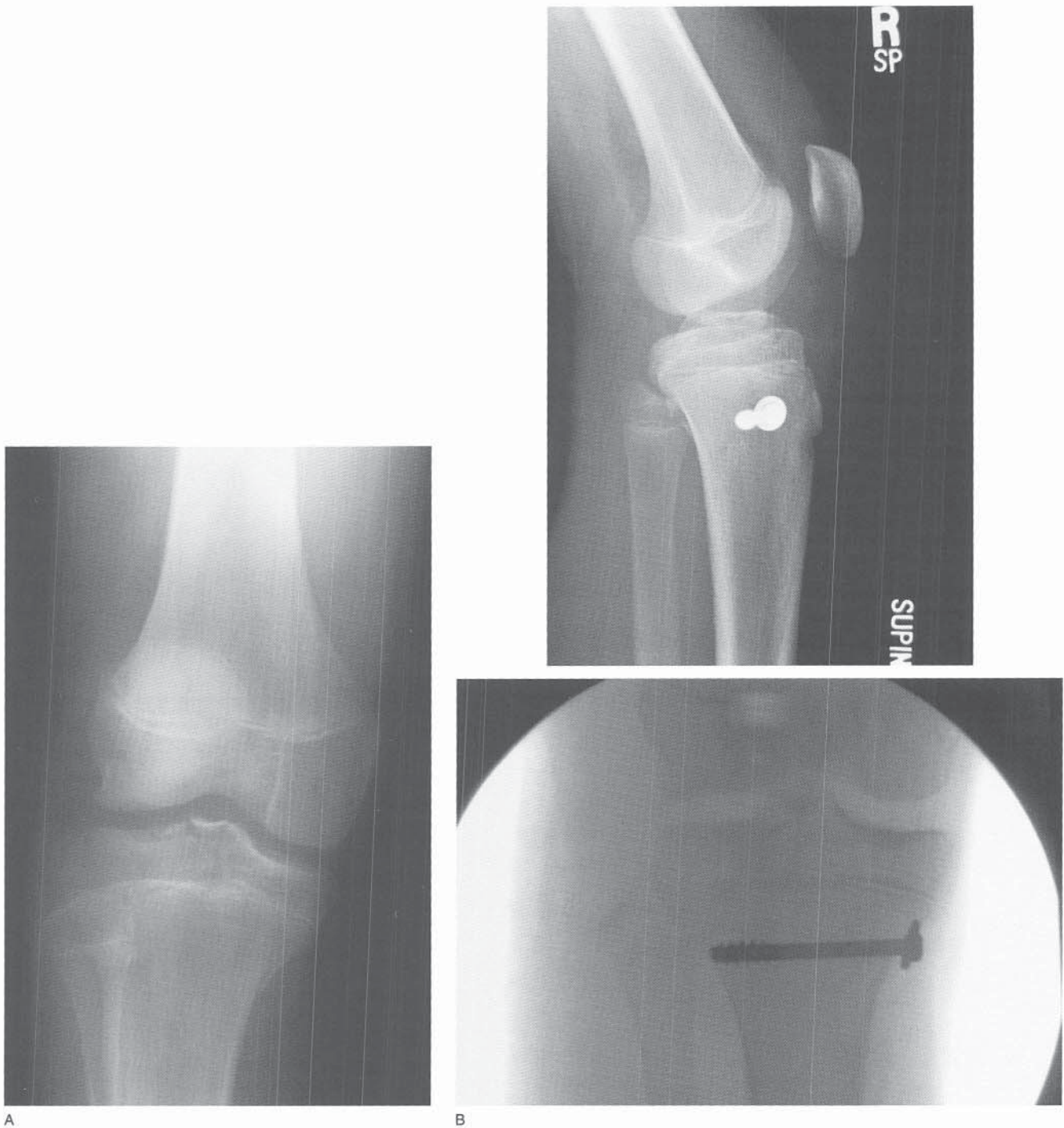


FIGURE 42-116 Salter-Harris type IV fracture involving the medial proximal tibia in a 13-year-old boy who was playing football when a varus force was directed to his knee. **A**, Initial radiograph shows a mildly displaced Salter-Harris type IV fracture with varus angulation of the proximal articular surface of the tibia. **B**, A closed reduction with single screw fixation was performed.

The most devastating complication is injury to the popliteal artery, which is reported to occur in 3 to 7 percent of cases.^{35,177,207} The importance of a thorough vascular examination at the time of the initial assessment, following fracture reduction, and serially within the first 48 hours, cannot be overemphasized. A delay in diagnosis and treatment significantly decreases the likelihood of a good outcome. The detection of discrepant or absent peripheral pulses should be

followed by immediate reduction of the fracture. If peripheral pulses do not return, then emergency arterial exploration is required. There is no role for arteriography in the setting of an isolated proximal tibial physeal injury with absent distal pulses, since arteriography delays definitive treatment and will only confirm the level of injury posterior to the knee. If the study is required by the vascular surgeons, it can be performed in the operating room. In the

setting of a viable foot with diminished or absent distal pulses, arteriography is indicated and should be performed on an emergency basis. Fracture fixation should be performed expeditiously, followed by thrombectomy, repair, or vein grafting.

Compartment syndrome has been associated with these fractures and should be carefully monitored for at the time of the initial evaluation and throughout the hospital stay. The long-leg cast should be split immediately following application if there is any concern over an impending compartment syndrome, if the patient is unreliable, or if the patient has an associated head injury with altered consciousness. Compartment pressures should be measured if there is any concern using standard techniques.^{154,240} Patients with pressures above 40 mm Hg or less than 30 mm Hg below the diastolic pressure should undergo four-compartment fasciotomies.

Physcal arrest and angular deformity or limb length discrepancy is relatively common, with the reported incidence between 10 and 20 percent.^{35,177,207,245} Patients at risk for physcal arrest and limb length discrepancy include those with displaced type I or II fractures,²⁰⁷ those with any type IV or type V fracture,³⁵ patients with an associated ipsilateral fracture,²⁴⁵ and patients with lawnmower injuries.³⁵ Physcal arrests should be treated in the standard fashion.^{114,174}

Associated ligamentous injuries should be assessed at the time of the initial evaluation. Often this is difficult because of instability, or potential instability, at the fracture site. The assessment of ligamentous instability should therefore be completed following operative stabilization of the fracture or soon after fracture healing has occurred. The incidence of associated ligamentous injury is reported to be up to 60 percent, as reported by Bertin and Goble. In their study, eight of 13 patients with proximal tibial physcal injuries had anterior instability at the time of healing.¹⁹ Similarly, Poulsen and colleagues reported an associated avulsion of the anterior tibial spine with anterior instability in five (33 percent) of 15 patients. These studies are in contrast to larger series, in which only one patient in the combined series had a collateral ligament injury, and no patient had sagittal plane instability.^{35,207}

PATELLAR DISLOCATIONS

Patellar dislocation is rare in the normal child. It is most often due to a twisting injury or direct trauma. Most injuries occur in the early adolescent age group, usually in girls, and most dislocations are lateral. Osteochondral fractures of both the patella and the femur are associated with an acute patellar dislocation. Initial treatment is nonoperative. The most common complication is recurrence of dislocation or chronic instability.

Anatomy. The extensor mechanism of the knee is formed from the quadriceps, its tendon, the patella, and the patellar tendon. The alignment of this mechanism is in slight valgus, with the apex at the center of the knee, the quadriceps angle (or Q-angle) being formed by the line of pull of the quadriceps to the patella and the line of the patella to the tibial tubercle. In children with a propensity for patellar dislocations and recurrent dislocations the Q-angle is increased into more valgus alignment. The inferior pole of

the patella articulates with the femoral groove beginning at approximately 20 degrees of knee flexion, and the contact area increases between the patella and femoral groove with increases in flexion.

The majority of patients with patellar dislocations have some abnormality of the extensor mechanism of the affected knee. These abnormalities include passive lateral hypermobility of the patella, a dysplastic distal one-third of the vastus medialis obliquus (VMO), a high or lateral position of the patella, or a previous history of patellar dislocation or subluxation.³⁸

The medial patellofemoral ligament (MPFL) was first described by Warren and Marshall lying superficial to the joint capsule and deep to the VMO.²³³ In cadaver studies it has been demonstrated that this ligament extends from the anterior aspect of the femoral epicondyle to the superomedial margin of the patella (Fig. 42–117).⁷¹ The fibers of the MPFL fan out and insert with the vastus medialis tendon. The MPFL has been shown to be the primary medial soft tissue constraint to lateral displacement of the extensor mechanism.⁴⁹

Classification. Patellar dislocations can best be classified either as acute injuries, in which the injury occurred without a prior history of patellar subluxation or dislocation, or as chronic or recurrent dislocations. The incidence of recurrent dislocation following an initial episode of dislocation treated nonoperatively is relatively high, as much as 60 percent in patients ages 11 to 14 years and 30 percent in patients ages 15 to 18 years.³⁸ The dislocation is almost always laterally displaced, and associated osteochondral injuries of the lateral femoral condyle and the medial aspect of the patella should be identified.

Mechanism of Injury. Patellar dislocations occur in two ways. The first is indirect trauma, in which the femur is

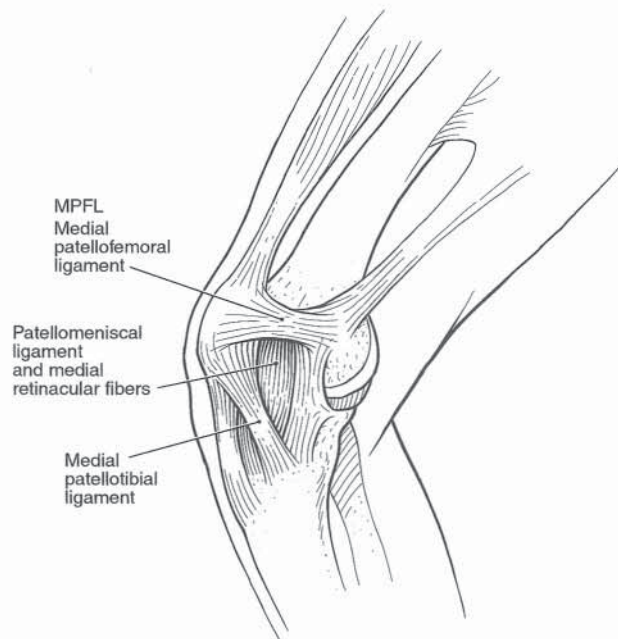

FIGURE 42–117 The medial patellofemoral ligament (MPFL), which extends from the superomedial margin of the femoral epicondyle to the superomedial margin of the patella.

internally rotated on a fixed foot. Contraction of the quadriceps muscle during this twisting injury further pulls the patella laterally and results in patellar dislocation.¹⁰¹ The second type of mechanism is a direct force applied either on the lateral aspect of the knee, creating a valgus stress that leads to lateral patellar dislocation, or medially, applied to the patella and pushing it directly laterally. Following both types of injuries the patella usually will reduce spontaneously without requiring a formal reduction. The most common activities in which these injuries are incurred are ball sports (football, basketball, baseball), falls, and gymnastics.^{38,141}

Diagnostic Features. The clinical history usually includes a twisting injury or direct blow while the individual is engaged in a sports activity. Patients often report a “giving way” or “going out of joint” sensation at the time of the initial presentation. Although girls are more often thought to have patellar instability, this may not hold true for patellar dislocations. Some studies report a greater proportion of boys having this injury,³⁸ while others report a higher incidence in girls.^{157,189}

The patella most often reduces spontaneously with extension of the knee or with a combination of extension of the knee along with manipulation of the patella at the scene of the injury. On the rare occasion when the patella remains dislocated at the time of the initial evaluation, the knee is in the flexed position and the patient has significant pain and swelling. The knee is maintained flexed, and both flexion and active extension are limited; however, passive extension of the knee can be performed. The patella can be palpated on the lateral aspect of the knee, the femoral condyles are easily palpated, occasionally a longitudinal tear on the medial aspect of the joint capsule and patellar retinaculum is felt, and there is usually a large knee effusion. In the more common situation the patella has been reduced to an anatomic position. There is a knee effusion which may be tense, especially when an osteochondral fracture is present,^{157,189} and there is tenderness on the medial aspect of patella and the insertion of the vastus medialis.

Radiographic assessment should include AP, lateral, and tangential views of both knees. The radiographs are assessed to ascertain that the patella is reduced to an anatomic position and to look for osteochondral fractures of the patella, most often on the medial aspect, and of the lateral femoral condyle. On the lateral radiograph the physician assesses the position of the patella relative to the femur and tibia using the Insall index.¹⁰⁵ It is important to obtain tangential views of both knees for comparison. Although many techniques are available for obtaining a tangential view of the patella, we prefer the Merchant view of the knee, in which the knee is flexed 45 degrees.¹⁴⁵ The Merchant view should be analyzed for the following parameters: the sulcus angle (SA), the lateral patellofemoral angle (LPA), and the lateral patellar displacement (LPD). The radiographic parameters that predispose to patellar dislocation are more shallow SA, greater than 142 degrees,^{30,61} LPD greater than on the contralateral side,¹⁵⁷ an LPA that opens medially, and an Insall index greater than 1.3.¹⁹¹ However, these parameters do not necessarily predict which patients will be predisposed to recurrent dislocations, and therefore they are not a useful guide to treatment.¹⁴¹

Treatment. The acute treatment of a patellar dislocation rarely requires reduction of the patella, as most patients present with the patella reduced. However, in the occasional patient who presents with an unreduced patella, the diagnosis should be evident, and radiographs are not necessary. (We prefer to obtain radiographs only following reduction.) Following sedation, a gentle closed reduction should be performed by slowly extending the knee while applying a medially directed pressure on the patella. Care must be taken to achieve a gentle reduction, since some investigators believe that osteochondral injury can occur after the acute dislocation when the medial edge of the patella slides back tangentially over the lateral condyle.^{189,212} At this time the inferomedial border of the patella may be sheared off by the lateral femoral condyle due to the tangential force resulting from contraction of the quadriceps as the patella is reduced.

In the more common situation in which the patient presents with a reduced patella, arthrocentesis of the joint can be performed to reduce the patient's discomfort and may be useful in the diagnosis of an associated osteochondral fracture when fatty marrow is present. This diagnostic aspect of the knee aspiration is especially important in the young child, in whom osteochondral fracture can be difficult to ascertain radiographically.

The majority of patellar dislocations can be treated with long-leg cast or cylinder cast immobilization for 2 to 4 weeks. Following cast treatment, range-of-motion and strengthening exercises should be started. In the review of patellar dislocations in children by McManus and colleagues, six (21 percent) of 29 patients who were treated with cast immobilization for 6 weeks later underwent operative intervention for recurrent dislocation.¹⁴¹ Of the 21 patients who did not have a recurrent dislocation, 50 percent had some symptoms but were participating in their preinjury activities. Cash and Hughston reported 52 percent good results in patients with some evidence of congenital abnormality of the knee, compared to 75 percent good results in those without congenital abnormality.³⁸

The indications for operative intervention for an acute patellar dislocation include a completely torn VMO and the presence of an osteochondral fracture. For the torn VMO, open operative repair is performed through an anteromedial incision, followed by cast immobilization for 6 weeks. Surgical repair in the patient with an acute patellar dislocation is becoming more common as a consequence of the high incidence of recurrent dislocations and better understanding of the pathoanatomy. For example, surgical repair of the MPFL has assumed a more prominent role in the treatment of the young athletic patient who has sustained indirect trauma resulting in a patellar dislocation. An incision is made anterior to the medial epicondyle at the distal edge of the VMO. The MPFL is then identified deep to the fascial layer of the VMO. Typically, the MPFL is avulsed from the femur, and direct repair via suture anchors can be performed. If residual patellar tilt is present, a lateral release is performed at the same time.

Osteochondral fractures associated with an acute patellar dislocation have been reported to occur in 5 to 39 percent of cases.^{141,157,189} We prefer to perform knee arthroscopy in this situation to visualize the fragment and decide whether excision or fixation of the fragment is indicated. In general,

the osteochondral fragment is too small for fracture fixation, and excision is performed.^{141,157,189} Nietosvaara and associates reported 26 (39 percent) patients to have an osteochondral fracture, 21 of which were detached, and only three of these were fixed intraoperatively. Similarly, Rorabeck and Bo-bechko reported only one of 18 patients having operative repair of an osteochondral fracture; their best results were achieved following excision of the osteochondral fragment combined with repair of soft tissues to prevent recurrent dislocation.¹⁸⁹ We are more inclined to fix the osteochondral fragment when it is large (more than 2 cm) and has a large osseous fragment, when the fragment is on the femoral condyle, and when the patients are older. We prefer absorbable pin fixation or Herbert-type screw fixation, and this is generally performed through an open arthrotomy.²²⁴ Postoperatively the patient is placed in a cast for 6 weeks and then started on physical therapy for range-of-motion and strengthening exercises.

Complications. Recurrent dislocation is the most common complication of an acute patellar dislocation and is more often seen in children whose dislocation occurred prior to 16 years of age, in those with an increased Q-angle, in those with evidence of ligamentous laxity, in patients with radiographic evidence of femoral condylar or patellar dysplasia, and in children with a weak VMO.¹²⁴ Initial treatment is similar to that for acute patellar dislocation, followed by aggressive rehabilitation of the VMO and quadriceps, with operative intervention indicated in patients in whom this treatment protocol fails. The many operative procedures available include the lateral retinacular release, which has been reported to have excellent results in up to 75 percent of patients, and we prefer to perform this arthroscopically.¹⁴⁹ A lateral retinacular release is best used in patients who have

pain following an acute patellar dislocation but who do not have chronic dislocations. In patients with chronic dislocations a more aggressive realignment procedure should be performed. In the skeletally immature patient we prefer the Galeazzi procedure, in which the semitendinosus is transferred into the patella to act as a check rein, combined with a lateral retinacular release and a medial retinacular and VMO advancement procedure (Fig. 42–118). In the skeletally mature patient, medial transfer of the tibial tubercle (Elmslie-Trillat procedure) is helpful in those patients with an abnormally high Q-angle. Patellar subluxation and recurrent dislocation are discussed in Chapter 20, Disorders of the Knee.

Osteochondral fractures are occasionally not seen on the initial radiographs, especially in young patients. Nietosvaara and colleagues described three patients who had loose osteochondral fragments and two medial marginal patellar avulsions that were not seen radiographically.¹⁵⁷ To avoid missing these lesions, aspiration of the knee joint will often disclose fatty droplets, indicating the presence of these lesions. If there is any doubt, CT is helpful in this situation.

TIBIAL SPINE FRACTURES

Tibial spine fractures are rare injuries in skeletally immature children. They usually occur following a fall from a bicycle or a motorcycle, and associated injuries are rare. A three-part classification described by Meyers and McKeever is used for treatment decision making. Type I injuries are treated in a long-leg cast in extension, type II injuries are usually treated with a closed reduction followed by casting, and type III injuries should be treated by open reduction, performed either arthroscopically or through an open arthrotomy, fol-

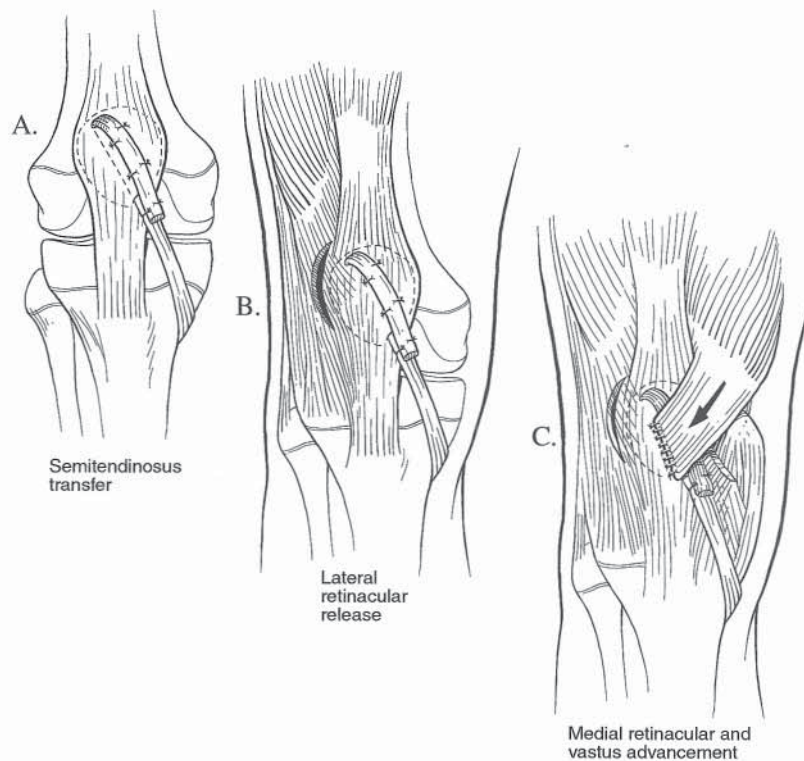


FIGURE 42–118 A Galeazzi-type procedure for realignment of the knee extensor mechanism. A, Semitendinosus transfer through the patella, which is then sutured back onto itself. B, Lateral retinacular release. C, Medial retinacular and vastus advancement.

lowed by internal fixation and casting. The outcome of treatment is usually very good, despite some anterior laxity.

Anatomy. The intercondylar eminence is the region between the articular portions of the adjacent plateaus of the tibia. The eminence consists of two bone spines or tuberosities: the medial one, which has attached to it the ACL, and the lateral spine. Between and adjacent to these two elevations are the bony attachments of the anterior and posterior horns of the medial and lateral menisci. The ACL fibers fan out at its attachment to the medial tibial spine and its fibers merge with the attachments of the menisci. The posterior cruciate ligament (PCL) does not attach to either tibial spine but attaches to the tibia just posterior to the tibial eminence, with its fibers extending distally on the posterior aspect of the tibia (Fig. 42–119).

In the skeletally immature child the intercondylar eminence is incompletely ossified and is more prone to fail than the ligamentous structures that attach to it. Failure occurs through the cancellous bone beneath the subchondral plate. Anterior condylar eminence injuries have been simulated in cadavers by placing traction on the ACL following an osteotomy of the tibial eminence.¹⁸⁶ The fracture line usually is confined to the intercondylar eminence; however, it may propagate into the weightbearing portion of the tibial plateau, most often the medial plateau.²⁴¹

Mechanism of Injury. The anterior spine avulsion occurs when an axially loaded knee undergoes hyperextension and the femur externally rotates. A blow to the front of the flexed knee may drive the femur posteriorly on the fixed tibia and result in avulsions of the anterior part of the tibial spine. Avulsion of the PCL occurs from a hyperextension injury of the knee or by posterior displacement of the tibia on the femur with the knee flexed. The most common activity in which a tibial avulsion occurs is a fall from a bicycle or motorcycle, accounting for approximately 50 to 65 percent of injuries.^{148,241,242} In Meyers and McKeever's

series of 35 fractures, 17 patients sustained injuries after falling from a bicycle. The authors pointed out that during the fall, there is medial rotation of the tibia on the femur, resulting in tensile loading of the ACL. When an adolescent presents with knee pain following a fall from a bicycle, the radiographs should be carefully inspected for a tibial spine avulsion injury. Other activities such as falls from a height, being struck by a motor vehicle, and sports activities result in this injury.

Classification. Meyers and McKeever developed a classification of these injuries based on the degree of displacement of the tibial spine as seen on the lateral radiograph (Fig. 42–120).^{146,148}

Type I: The fragment is minimally displaced from its bed, with slight elevation of the anterior margin.

Type II: The anterior third to half of the avulsed fragment is elevated, producing a beaklike appearance.

Type III: The avulsed fragment is completely elevated from its bed and no bony apposition remains. A variant of this injury is an avulsed fragment that is completely lifted off the bed and rotated so that the cartilaginous surface of the fragment faces the bony bed.

Diagnostic Features. The average patient is between 10 and 14 years old and presents with a knee hemarthrosis. The knee is flexed, and any attempt at passive extension is painful and inhibited by muscle spasm. The knee can be flexed to approximately 80 to 100 degrees. Palpation of the knee will reveal tenderness in the central region of the anterior aspect of the joint line. At the time of the initial evaluation it is difficult to obtain a good assessment of knee stability because the patient guards the knee, owing to pain. However, varus and valgus instability can be assessed at the initial presentation.

The radiographic assessment includes an AP and lateral view. The notch view or oblique views are occasionally needed to confirm the diagnosis. The lateral radiograph is the most important and best shows the fractured fragment.

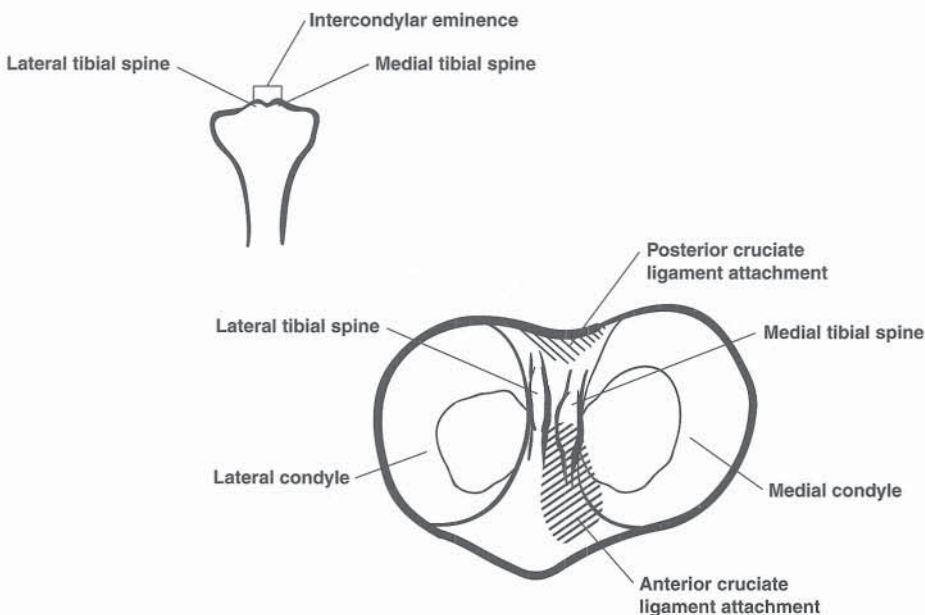


FIGURE 42–119 Diagram of a tibial plateau, depicting the relationship of the ACL, PCL, and the tibial spine superior.

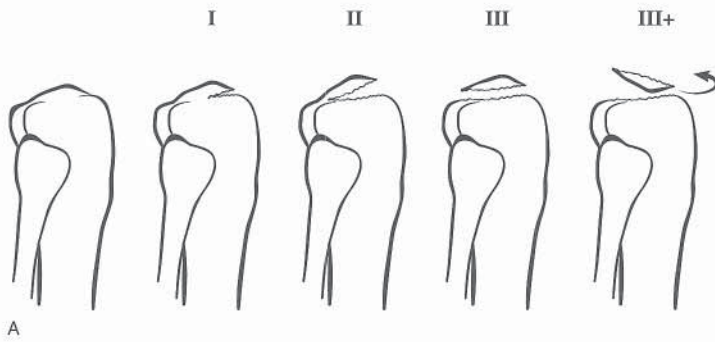
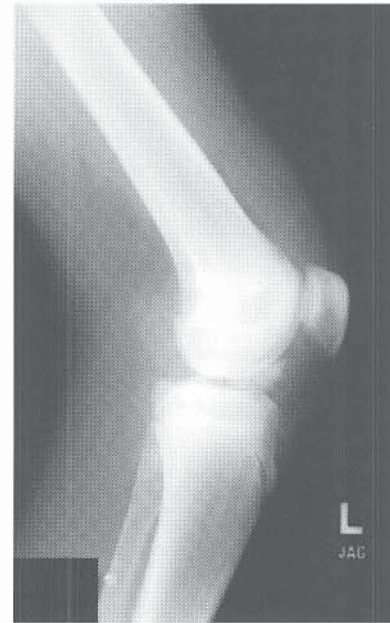
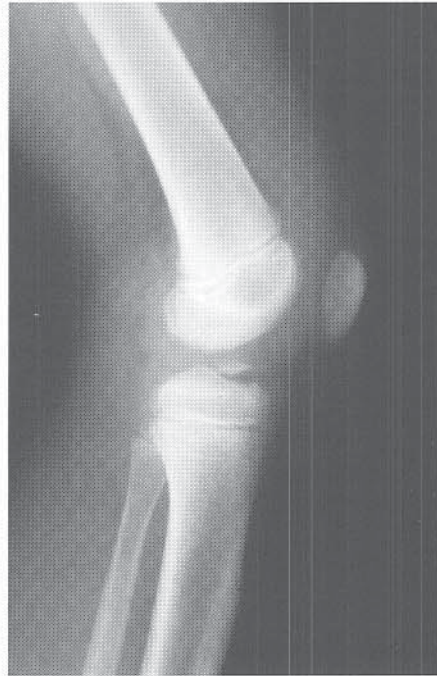
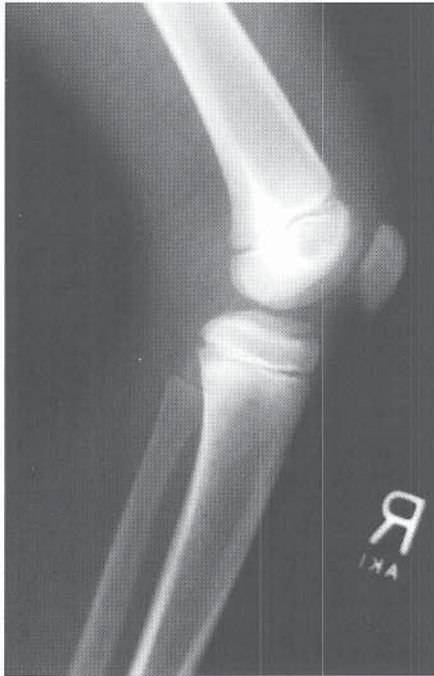FIGURE 42-120 A, The Meyers and McKeever classification of tibial spine injuries in children. B, Lateral radiograph demonstrating a type I tibial spine injury. C, Lateral radiograph demonstrating a type II tibial spine injury. D, Lateral radiograph demonstrating a type III tibial spine injury.



CT is occasionally used to image the fracture that is not fully seen on the plain radiographs.

Treatment. The treatment guidelines that Meyers and McKeever outlined in their initial works are still followed today.^{146,148} For all type I injuries, in which the fracture is nondisplaced or minimally displaced, no attempt at reduction is made. We prefer treatment in a long-leg cast with the knee flexed approximately 10 to 20 degrees. This is the optimal position of the knee because the ACL is taut with the knee in extension and hyperextension, relaxed at the start of flexion, and then becomes tight again in full flexion. When a tense hemarthrosis is present, needle aspiration will help bring the knee out to the extended position to obtain the 20 to 30 degrees of knee flexion. At the time of needle aspiration of the joint, lidocaine can be injected into the joint to provide some additional pain relief. For the type II fracture in which there is anterior displacement of the fracture fragment, we prefer closed treatment. It is controversial whether a closed reduction can reduce the fracture or may, in fact, result in displacement of the fracture. Meyers and McKeever reported a patient who had a type II fracture that was converted to a type III fracture following manipulation

and subsequently required an open reduction.¹⁴⁸ Others have reported closed reduction and casting in an attempt to reduce the displaced type II fracture; however, documented reductions were not discussed.* However, Hakalim and Wilpulla described ten patients who underwent successful closed reduction without evidence of anterior laxity at final follow-up.¹⁰ The closed reduction is performed slowly by extending the knee to full or hyperextension and then slowly returning the knee to a position of 10 degrees of flexion (Fig. 42-121). A radiograph is then taken to view the position of the tibial spine and confirm the reduction. If reduction has been achieved, then a long-leg cast with the knee in 10 degrees of flexion is placed and radiographs are taken on a weekly basis for the first 2 weeks to ensure that the reduction has been maintained.

Type III fractures are best treated operatively using either an arthroscopic or an open technique. If an open technique is used, the incision should be placed on the anteromedial aspect of the knee. With either technique, the anterior horns of both menisci should be fully visualized to ensure that

*See references 15, 87, 111, 140, 241, 242.

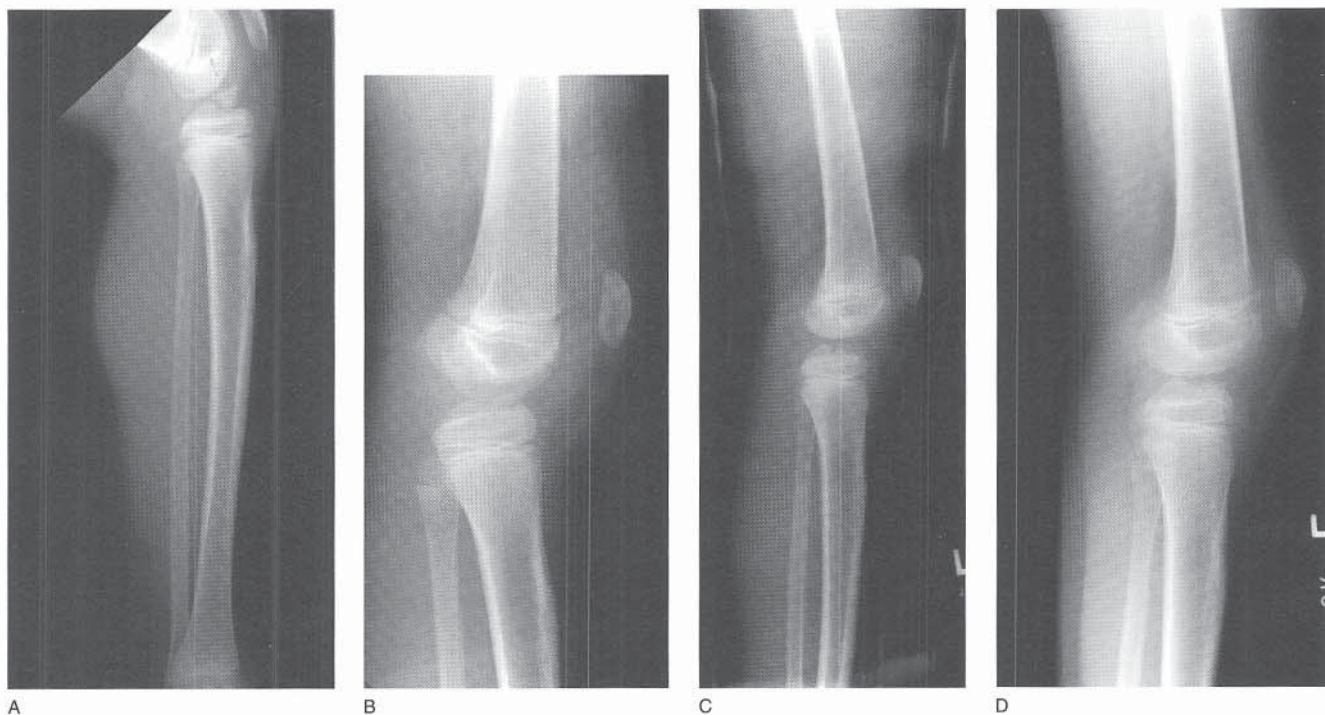


FIGURE 42-21 Closed reduction of a tibial spine fracture in a 9-year-old patient. A, Initial injury radiographs demonstrating a displaced tibial spine fracture. B, Hyperextension of the leg to reduce the fracture. C, Position in cast. D, Final radiographic appearance at 6 months, demonstrating healing of the fracture in a mildly displaced position.

they are not interposed between the displaced tibial spine and its bony bed.

We prefer an arthroscopic technique to reduce and repair type III injuries. In the young child, the fragment is larger because of its osteocartilaginous nature, and repair with sutures of the avulsed fragment will provide stable fixation (Fig. 42-122). In the older child and adolescent, the fragment is smaller and requires fixation, to begin within the distal aspect of the ACL. This can best be done by inserting spade-tipped guide wires into the ACL and passing No. 1 Ethibond sutures and tying them to allow fixation of the ACL. This is performed so that double-stranded sutures hold the ACL/bony fragment in a reduced position. The sutures can then be pulled down through the proximal tibia and tied as the fragment is visualized. Medler and Jansson reported two cases in which this was performed with excellent results and without evidence of instability at final follow-up (Fig. 42-123).¹⁴³ McLennan reviewed ten cases of type III injuries that had been treated by various techniques and concluded that arthroscopic reduction and internal fixation provided better results than closed reduction or arthroscopic reduction without internal fixation.¹⁴⁰

In the open technique, a small anteromedial incision is made at the joint line and the menisci and avulsed fragment are inspected. The fracture bed is cleared of fracture hematoma and menisci and the knee is extended to reduce the fracture and allow passage of sutures. The sutures are passed as in the arthroscopic technique by drilling from the proximal epiphysis into the avulsed fragment. Sutures are then placed into the ACL using a Krackow-type stitch, after which the sutures are passed through the avulsed fragment and out the two drill holes (Fig. 42-124). The knee is extended

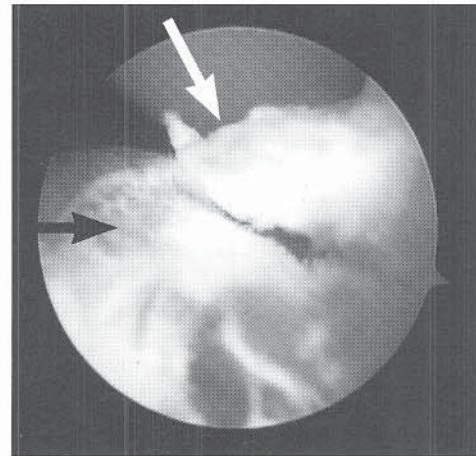
and the sutures are tied down over the anterior aspect of the proximal tibia.

After the repair, performed by either the open or arthroscopic technique, radiographs should be taken to be used for later comparison. The knee is then placed in a long-leg cast with the knee flexed to 10 degrees. Radiographs are obtained weekly in the first 2 weeks to ensure that the fragment remains in the reduced position. The cast is left in place for 6 weeks, followed by strengthening and active range-of-motion exercises.

The treatment of PCL avulsion fractures is somewhat controversial.* In those patients with an undisplaced fracture, casting for 6 weeks provides excellent results.¹⁴⁷ The minimally displaced fracture has a high propensity to displace while in the cast and therefore should be repaired.¹⁴⁷ The displaced fracture always requires open reduction and internal fixation.^{81,147,190,228} We prefer a direct posterior incision to the knee with anatomic reduction. Internal fixation is best accomplished with screw fixation when the fragment is large enough, and with suture fixation when a smaller avulsed fragment is present. Postoperatively the patient should be placed in a long-leg cast for 6 weeks, followed by active range-of-motion and strengthening exercises.

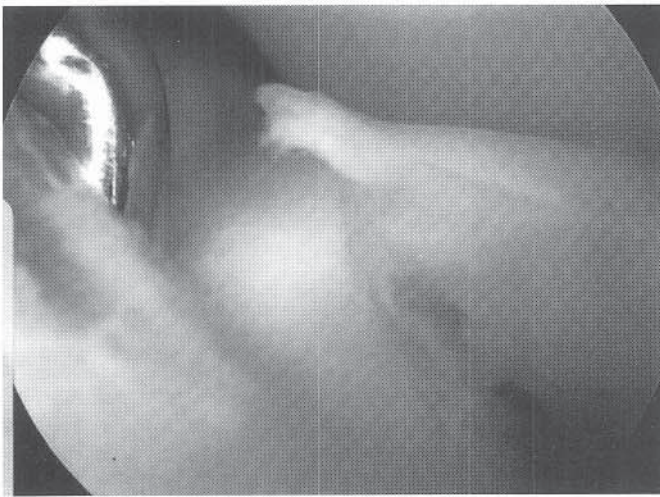
Complications. The overall prognosis for these injuries is good especially in patients in whom an anatomic reduction is achieved and maintained, with 85 percent of patients in one series returning to preinjury levels of activity.²⁴² The two most prominent complications from this injury are

*See references 54, 81, 138, 147, 190, 194, 228.

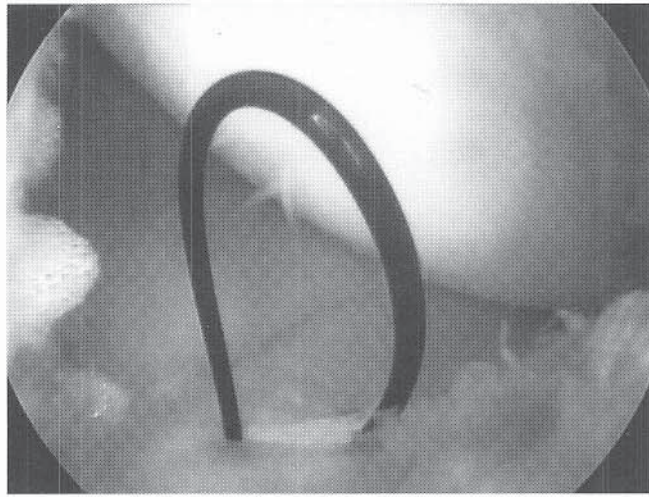


A

FIGURE 42–122 A, Intraoperative arthroscopic view of a patient with a tibial spine fracture. The avulsed fragment is displaced (*white arrow*) and lying over the medial meniscus (*black arrow*). B, A hook probe is used to pull the meniscus from beneath the fracture fragment to allow reduction of the tibial spine. C, The fragment in the reduced position. A loop of suture is through the fragment and holds this in the reduced position when pulled taut.



B



C

residual anterior instability and loss of motion, especially knee extension.*

ACL laxity has been objectively measured and reported in 38 to 100 percent of cases.^{111,213,242} However, only a small proportion of patients have symptomatic instability. The laxity may be due to inadequate reduction of the avulsed fragment or to the initial injury, in which stretching of the ACL initially occurs before avulsion of the tibial spine.⁹³ Unrecognized injuries of the medial collateral ligament have been reported and should be assessed during the initial evaluation.^{87,93,213}

One of the most common complications is loss of extension from a displaced fragment impinging on the femoral notch. Wiley and Baxter reported that all 45 patients in their series had some loss of knee extension, with 60 percent of patients having greater than 10 degrees of loss. Treatment of symptomatic knee extension loss of more than 10 degrees has been successfully reported in ten patients who had between 10 and 25 degrees of loss of extension.¹⁶⁹ These patients underwent arthroscopic debridement and abrasion of the tibial spine, and five patients had a notchplasty performed at the same time. At final follow-up, eight patients had full

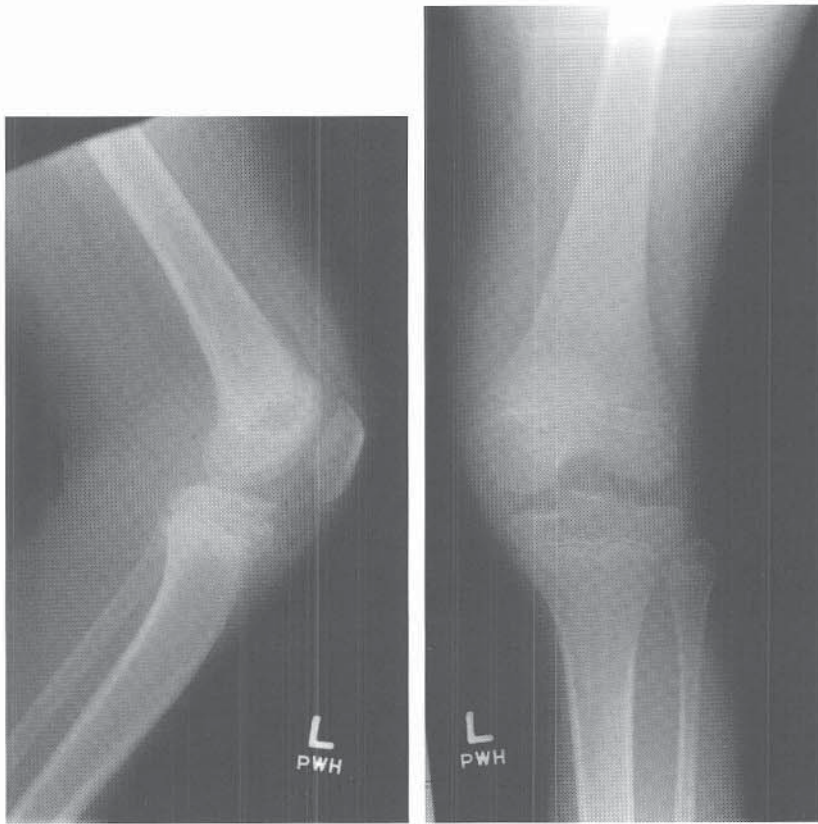
extension and two had residual extension deficits between 3 and 5 degrees.

Transphyseal screw fixation in the skeletally immature child should not be performed, as it leads to anterior epiphyseal diesis and a recurvatum deformity.¹⁵⁵ In addition, although no cases of physeal arrest have been reported, the physis should be avoided when placing drill holes for suture passage as long as the ability to achieve stable fixation is not compromised.

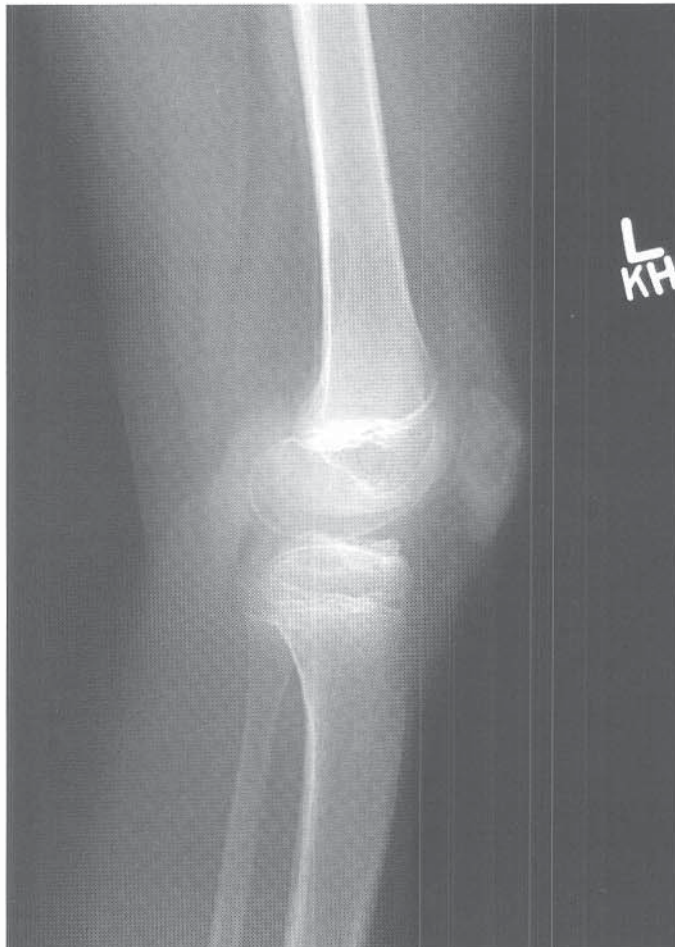PROXIMAL TIBIOFIBULAR JOINT DISLOCATIONS

These injuries are extremely rare and occur during athletic activities in which the patient's foot is inverted and plantar flexed, with simultaneous flexion of the knee and twisting of the body. Approximately one-third of these injuries are initially missed on initial presentation. The treatment of a tibiofibular dislocation or subluxation is closed reduction followed by long-leg casting. Some injuries become recurrent, with a chronic subluxating proximal fibula. These patients are best treated by reconstruction of the soft tissues to prevent future subluxation or by proximal fibular head resection.

*See references 15, 87, 111, 140, 148, 213, 241, 242.

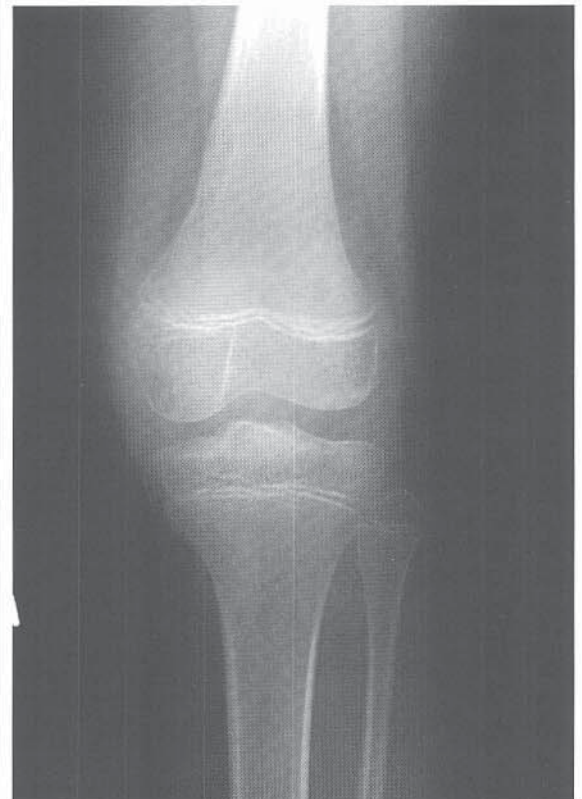


A



B

FIGURE 42-123 Mildly displaced tibial spine fracture in a 9-year-old patient that was treated with arthroscopically assisted reduction. A, Initial radiographic appearance. B, Arthroscopically assisted reduction and casting was performed. This final radiographic picture shows minimal displacement of the tibial spine fracture.



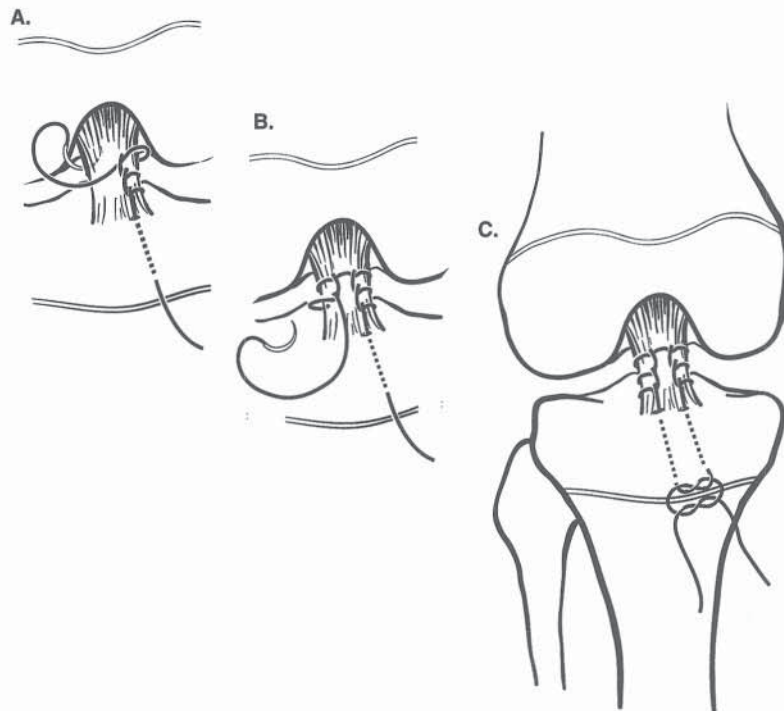


FIGURE 42-124 Open reduction and internal fixation of a tibial spine fracture. A and B, Krackow-type suture placed in the anterior cruciate ligament. C, Sutures are brought out through the proximal tibial epiphysis and tied.

Anatomy. Ogden has classified the proximal tibiofibular joint into two basic types. The first type is the horizontal joint, in which the fibular articular surface is circular and planar and articulates with a similar surface on the tibia. This type of joint is usually under and behind the lateral edge of the tibia, providing some stability (Fig. 42-125). The second type is the oblique tibiofibular joint, in which the joint line is angled more than 20 degrees compared to the femoral-tibial joint; this type generally has less area of

articular surface than the horizontal type.¹⁶⁴ Over 70 percent of subluxations and dislocations occur in patients with an oblique joint pattern.

The syndesmosis between the proximal tibia and fibula provides stability to the joint and is supplemented by the fibular collateral ligament and the biceps femoris, which insert into the fibular head.

Classification. The classification of proximal tibiofemoral joint dislocations was first described by Lyle in 1925.¹³² Ogden later developed the more commonly used classification in 1974, when he described four basic types of injuries to the proximal tibiofibular joint (Fig. 42-126).^{164,165} Subluxation of the joint occurs in approximately 25 percent of cases when the fibula exhibits increased motion laterally, medially, anteriorly, and posteriorly. The most common type of dislocation is the anterolateral dislocation, accounting for 67 percent of cases; in this type of dislocation the proximal fibula displaces laterally to free itself from the lateral edge of the tibia, followed by anterior displacement. The posteromedial dislocation is relatively rare (5 percent) and occurs with posterior displacement of the fibula followed by medial displacement. The superior dislocation is the least common (2 percent) and occurs when upward displacement occurs along with mild lateralization.

Mechanism of Injury. Most injuries occur in adolescents engaged in athletic activities, parachute landings, or motor vehicle accidents.^{52,68,79,164,165,236} The best understood mechanism results in an anterolateral dislocation. Initially, sudden inversion and plantar flexion of the foot results in an anteriorly directed pull of the fibular head by the peroneals and long toe extensors. Simultaneously, flexion of the knee relaxes the biceps tendon and fibular collateral ligament, while twisting of the body results in external rotation of the tibia. The combined forces pull the fibula out laterally and anteriorly. Associated injuries are relatively rare, but a proximal

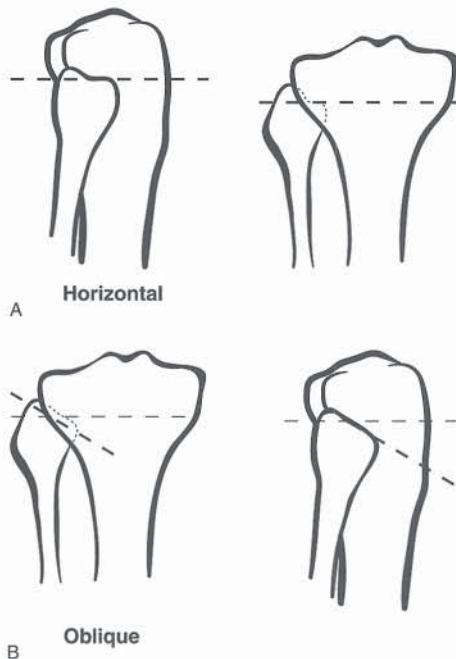


FIGURE 42-125 Anatomy of the proximal tibiofibular joint. A, Horizontal-type joint. B, Oblique-type joint.

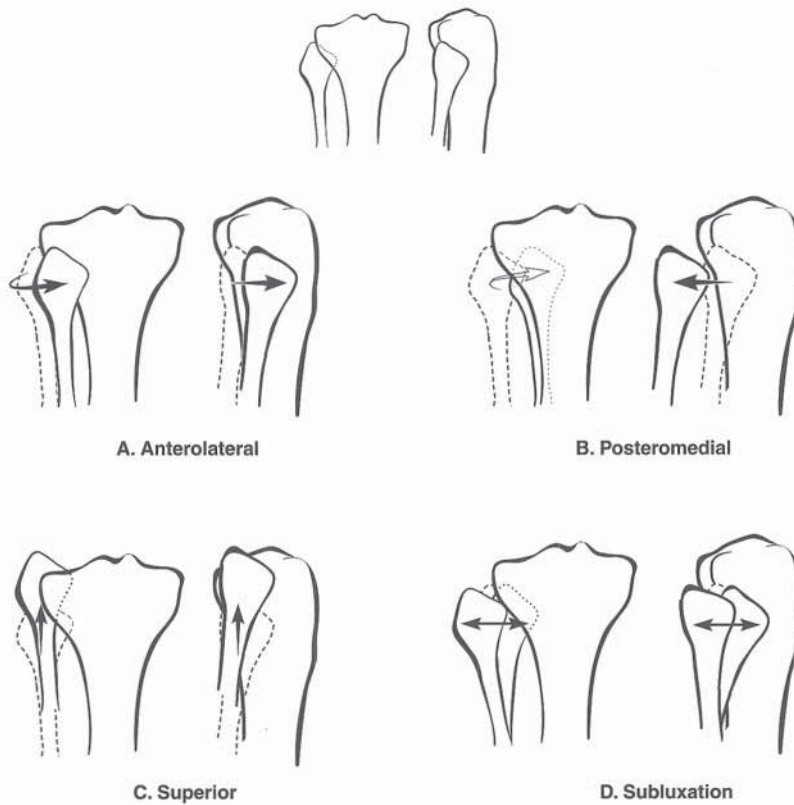


FIGURE 42-126 A to D, Classification of proximal tibiofibular dislocations.

tibial fracture is seen with these injuries.²⁰⁴ Other injuries include hip fractures, fracture-dislocations of the ankle, and fracture-dislocation of the distal femoral epiphysis.^{164,165} The posterolateral dislocations are more often a result of violent direct trauma as opposed to the twisting athletic injury resulting in the anterolateral dislocation.

Predisposing conditions such as generalized ligamentous laxity or muscular dystrophy may predispose patients to develop a subluxating or dislocated joint.¹⁶⁸

Diagnostic Features. The patient with a subluxation of the fibula usually presents with pain along the lateral aspect of the knee and lower limb. These patients typically have generalized joint hyperlaxity or an underlying condition such as Ehlers-Danlos syndrome. Patients with dislocations of the joint present following an injury that usually involved a twisting of the extremity during an athletic activity. Patients will often have symptoms in the lateral popliteal fossa in the location of the biceps tendon that has been stretched, and dorsiflexing and everting the foot may accentuate the pain. In addition, the patient may complain of transient paresthesias along the distribution of the peroneal nerve, although foot drop is rare.

The physical examination in patients with chronic subluxation will elicit tenderness on deep palpation over the fibular head. One of the most striking features in a patient with a dislocated tibiofibular joint is a prominent fibular head on visual inspection. It is important to fully image any injured extremity to search for a proximal tibiofibular dislocation. Ogden described 16 of 43 patients with associated fractures, and these were the patients in whom the tibiofibular dislocation was most often missed.¹⁶⁴ The knee can often be put through its range of motion without sig-

nificant symptoms and may lack only a small amount of full knee extension; a knee joint effusion is rare.

The radiographic examination includes AP and lateral views of the knee, and often an oblique radiograph to fully image the dislocation.

Treatment. The subluxed proximal tibiofibular joint usually requires no treatment. Stretching of the hamstrings and modification of activities is usually all that is required. Patients often have some generalized hyperlaxity of the joints that resolves with continued growth and maturity, and the joint subluxation and associated symptoms resolve. There are reports of adults with habitual chronic subluxations who developed peroneal nerve symptoms that required resection of the fibular heads for symptom relief.⁵⁷

For the dislocated tibiofibular joint, we prefer a closed reduction for all types of dislocation. The anterolateral dislocation is best reduced by dorsiflexing and everting the foot, which externally rotates the fibula, followed by flexing the knee to relax the biceps and collateral ligament. The proximal fibula can then be manually reduced with direct pressure, which usually results in a loud, audible popping sound (Fig. 42-127). A long-leg cast with the knee flexed to 30 degrees is then used for 2 to 3 weeks, after which normal activities are gradually resumed.

The posteromedial dislocation is a more severe injury, with disruption of the lateral collateral ligament and the biceps tendon. This injury requires an open reduction and reconstruction of these structures, followed by cast immobilization for 6 weeks to allow complete healing.

The superior dislocation is very rare and is most often associated with a proximal tibial fracture, which requires open reduction and internal fixation.

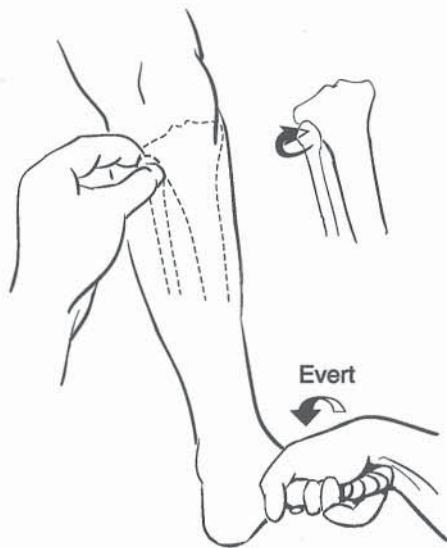


FIGURE 42-127 Reduction maneuver for a proximal tibiofibular dislocation. As the foot is manually everted, the fibular head is palpated and reduced, producing a “clunk.”

Complications. Long-term studies of patients with proximal tibiofemoral joint dislocations are not available. In the short term, patients do very well. The exceptions are those who continue to have a chronically subluxating joint, which is best treated with a proximal fibular head resection. We do not recommend fusion of the proximal tibiofibular joint, since patients usually develop symptoms at the ankle owing to the restricted motion of the proximal joint. This ultimately requires proximal fibular head resection or osteotomy below the arthrodesed joint.

Recurrent dislocation of the tibiofibular joint is rare.^{79,168,202,236} Treatment of the child with joint hyperlaxity usually requires no treatment, and the child can be watched until skeletal maturity, when the symptoms resolve.¹⁶⁸ In

patients in whom conservative treatment fails, the surgical options include proximal fibular head resection or reconstruction of the stabilizing structures of the joint. We prefer to attempt to surgically stabilize the joint using either a split biceps tendon, an iliotibial band, or a combination of both.^{79,202,236}

LIGAMENT INJURIES

Anatomy. The ACL originates on the lateral wall of the intercondylar notch at its posterior margin and inserts just anterior to the tibial spine on the tibia (Fig. 42-128). The orientation of the ACL within the knee results in its fibers being twisted approximately 90 degrees as the knee moves from flexion to extension. Because of this, the fibers can be functionally differentiated into two bundles, the anteromedial bundle and the posterolateral bundle. In flexion, the anteromedial band lengthens and the posterolateral bundle shortens, while in extension the opposite occurs. The ACL is intracapsular but is surrounded by a synovial fold. Its primary blood supply is derived from the middle genicular artery, which comes off the popliteal artery and penetrates the posterior joint capsule. An indirect blood supply comes from the inferior medial and lateral genicular arteries, which penetrate the fat pad.

The PCL originates on the posteromedial aspect of the intercondylar notch and inserts into the posterior sulcus of the tibia between the medial and lateral joint surfaces. Like the ACL, the PCL has two functionally separate bundles—the anterolateral fibers, which are taut in flexion, and the posteromedial fibers, which are taut in extension.

The capsuloligamentous constraints include the capsule, the medial collateral ligament (MCL), the lateral collateral ligament (LCL), the joint capsule, and the posterolateral and posteromedial complexes. On the medial aspect of the knee, three layers of soft tissue structural support can be identified. The first layer is the deep fascia, which overlies the gastrocne-

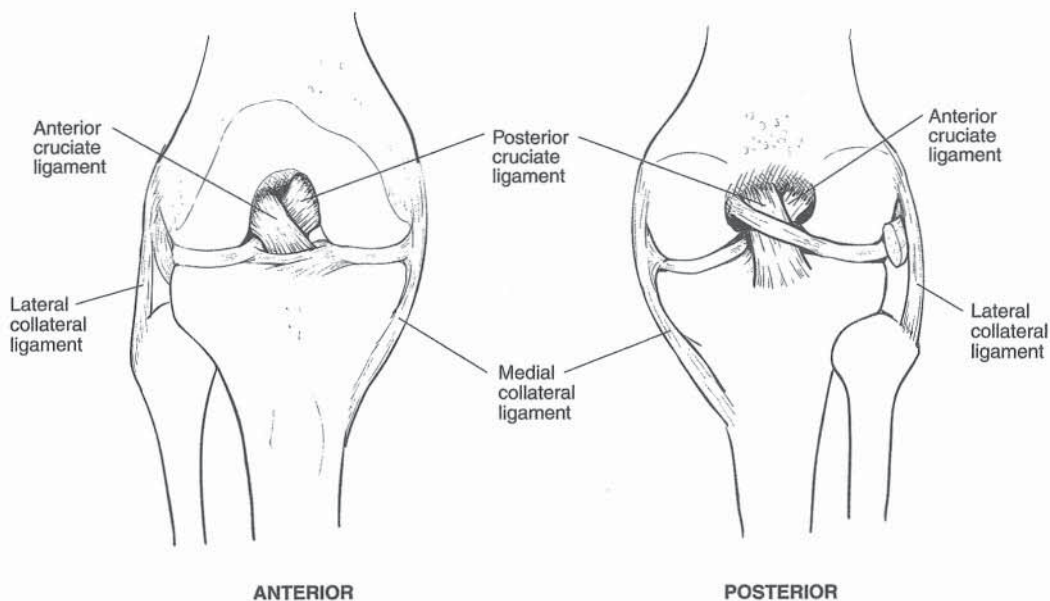


FIGURE 42-128 Anatomic location of the anterior cruciate and posterior cruciate ligaments, along with the lateral and mediolateral ligaments.

mius muscles posteriorly, while anteriorly it becomes confluent with the second layer and the medial patellar retinaculum. The second layer contains the superficial MCL, which is the primary stabilizer of the knee to valgus forces; the MCL travels from the medial epicondyle to the medial tibia deep to the gracilis and semitendinosus. The third layer consists of the joint capsule, which is thin anteriorly, becomes the deep MCL medially, and blends with the second layer posteriorly to become the posteromedial capsule.

On the lateral aspect of the knee the three layers include the lateral retinaculum, composed of the superficial oblique and deep transverse components. The second layer is composed of the LCL, which runs from the lateral epicondyle to the proximal fibula, and the arcuate ligament, a triangular ligament that fans out proximally from the fibula and inserts onto the femur. The third layer is the joint capsule, which is thin anteriorly and stronger posteriorly with support from the arcuate complex.

These ligamentous structures work synchronously to provide stability to the knee joint. The ACL is the primary restraint to anterior translation, while the deep MCL is a secondary restraint. The PCL is the primary restraint to posterior translation, while the LCL, posterolateral complex, and superficial MCL are secondary restraints.

Mechanism of Injury. Two types of injuries result in an ACL tear: a direct traumatic event and a twisting injury of the knee, most often occurring during participation in an athletic event. In the younger child direct trauma is more often the cause of a tear or avulsion of the ACL. Clanton and colleagues described nine children at an average age of 10 years, all of whom sustained direct trauma resulting in knee ligamentous injury, with six patients having ACL attenuation or avulsion.⁴⁶ In patients between 12 and 15 years, Lipscomb and Anderson reported 24 patients with ACL injuries, all the result of a twisting injury sustained during an athletic event.¹²⁷ Others have reported similar results with most adolescents reporting injury to the knee with subsequent confirmation of an ACL injury following a twisting injury.^{171,239} The ACL injury is most commonly seen in sports such as basketball, football, soccer, volleyball, and gymnastics in which cutting, jumping, and sudden changes in direction and velocity (predominantly deceleration) occur. In all mechanisms of ACL injury, the foot is fixed or anchored while the leg sustains a deforming force, whether the force is direct or indirect. The most common types of deforming forces can be defined by the direction of the tibial displacement. The tibia can be adducted and internally rotated, in which case the ACL is stretched over the PCL; the tibia may undergo a valgus stress with external rotation, in which case the ACL is stretched over the lateral femoral condyle; or the tibia may be forced directly anteriorly.^{78,99,158}

The PCL injury usually occurs from either a motor vehicle accident, in which case there are often other ligamentous or bony injuries, or athletic injuries.* In athletic injuries the typical mechanism is a fall onto the flexed knee while the foot is in a plantar flexed position, resulting in posterior displacement of the tibia on the femur. A direct blow to the anterior aspect of the tibia while the knee is flexed may also

result in a tear of the PCL. When a PCL rupture is associated with other ligamentous injuries, more severe trauma is often required to produce this injury. This usually is due to a rotatory force combined with a varus or valgus deforming force. For example, a PCL-MCL injury results from a valgus-external rotation stress sustained by a flexed knee with the foot in a fixed, nonweightbearing position.²⁰³

Injury to the MCL is very common and most often occurs during athletic events in which the knee sustains a sudden valgus moment from a direct blow to the lateral aspect of the knee. Patients often describe a sensation of the knee "opening" on its medial aspect, with associated pain. MCL injury may also occur from a noncontact event in which the knee receives a valgus stress, often during a fall. The patient feels pain on the medial aspect of the knee that slowly subsides over the first 30 minutes, with the athlete often wishing to resume play. The knee then stiffens, with increasing pain and swelling over the ensuing 12 to 16 hours. Isolated injury of the lateral collateral ligament (LCL) is far less frequent than MCL injury and occurs when a varus moment of the knee occurs. Because isolated injury of the LCL is rare, a careful assessment for other ligamentous injuries and meniscal injuries is necessary.

Diagnostic Features. The patient with an ACL tear describes a characteristic sudden movement in the knee, often with a "giving way" or "shifting" sensation. Patients often describe hearing a "pop" at the time of the initial injury, reported to occur in 40 to 60 percent of cases.^{73,158} The patient is unable to resume participating in the event and is usually assisted off the field, with subsequent development of a large effusion. Although the majority of patients describe significant pain at the time of injury and shortly thereafter, some have mild symptoms and attempt to return to activities prior to seeking a medical opinion. This most often results in the athlete's realizing that the knee is unstable and prevents performance at the preinjury level.

The physical examination is diagnostic of an injury of the ACL. The knee should be inspected and palpated, since the majority of ACL injuries are associated with a knee effusion.^{7,29,46,65} Stanitski and colleagues demonstrated that in the presence of an acute traumatic knee hemarthrosis, 47 percent of preadolescents (ages 7 to 12 years) and 65 percent of adolescents had an injury to the ACL.²¹⁹ Range of motion of the knee should be evaluated, with careful attention to the amount of extension of the knee. Full knee extension may be limited by two mechanisms. The first is a mechanical block to extension by the stump of the torn ACL, which lies in the notch of the femur and prevents full extension; the second is the patient guarding against full extension to maintain the tibia in a reduced position, avoiding the anteriorly subluxed position, as in the pivot shift test.

The Lachman test is the most sensitive test for isolating an ACL injury. It is performed by applying an anteriorly directed force to the proximal tibia with the knee in 20 to 30 degrees of flexion and the leg slightly externally rotated to relax the hip flexors (Fig. 42-129). The amount of anterior displacement of the tibia should be determined in order to grade the anterior instability: grade 1, 1 to 5 mm; grade 2, 6 to 10 mm; grade 3, 11 to 15 mm; and grade 4, 16 to 20 mm. The end point should also be characterized as firm (normal), marginal, or soft. In the larger adolescent it is

*See references 51, 102, 116, 129, 229.

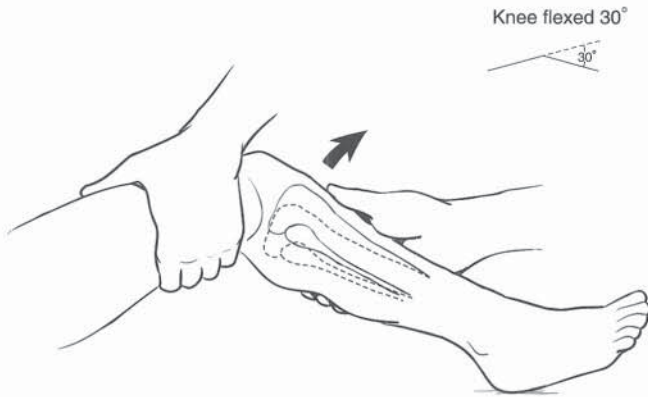


FIGURE 42-129 The Lachman test. The knee is flexed to 90 degrees with slight external rotation of the hip. The examiner holds the patient's distal thigh with one hand while stabilizing the proximal tibia with the other (the thumb is placed on the tibial tubercle to determine the amount of displacement anteriorly). An anteriorly directed force is then applied to the proximal tibia.

often difficult to stabilize the thigh while performing this test, and therefore it is helpful for the examiner to place his or her flexed knee onto the examining table and rest the patient's distal thigh on it (Fig. 42-130). The examiner can then control the distal thigh with posteriorly directed pressure applied to the distal thigh while the examination is performed. The anterior drawer test is performed with the knee flexed to 90 degrees (Fig. 42-131). The examiner then ensures that the hamstrings are relaxed, and an anteriorly directed force is applied to the proximal tibia. The final test, the pivot shift test, is the most difficult to perform, especially in the patient with an acutely injured knee, and requires considerable cooperation from the patient. Although there are many variations of this test, they all rely on the anterior subluxation of the tibia on the femur when the knee is in extension and the reduction of the tibia with knee flexion of 20 to 40 degrees.^{130,131} The relocation of the tibia should be classified as 0, absent relocation (normal); 1+, glide with reduction; 2+, shift of the tibia with reduction; or 3+, temporary locking of the tibia prior to reduction.

The physical examination findings consistent with a PCL injury are similar to those for ACL injuries but opposite in

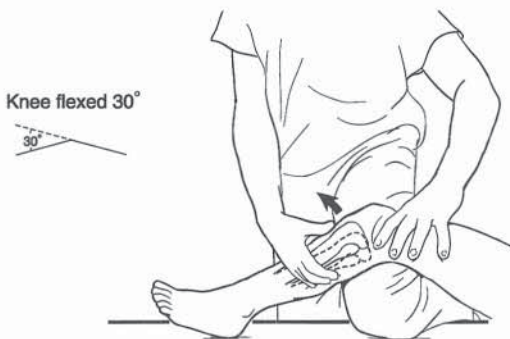

FIGURE 42-130 Modified position for the Lachman test in a larger patient. The examiner stabilizes the patient's thigh by placing it over the examiner's flexed thigh on the examination table. The examiner then fully stabilizes the thigh with one hand while applying an anteriorly directed force with the other hand.

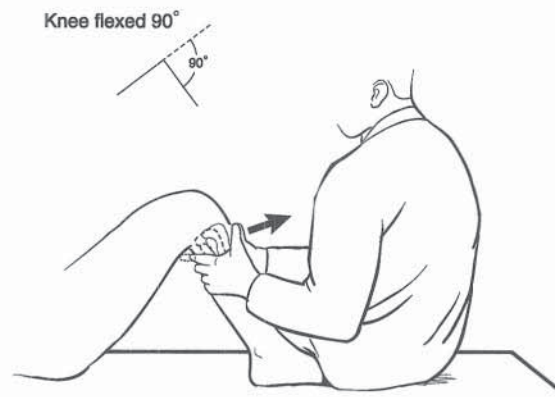


FIGURE 42-131 The anterior drawer test. With the patient's knee flexed to 90 degrees, the examiner stabilizes the patient's foot on the bed. The examiner then uses both hands to provide an anterior force, while the index fingers ensure that the patient's hamstrings are relaxed.

direction. Initially the position of the tibia can be evaluated with the knee flexed to 90 degrees while the heel is supported. The examiner looks for "posterior sag" of the proximal tibia when compared with the opposite extremity.⁸⁰ The posterior drawer test is more useful in the suspected PCL-deficient knee because instability in this situation is most pronounced with the knee in 70 to 90 degrees of flexion.^{36,76} With the patient supine on the examining table, the patient's knee is flexed to 90 degrees. The examiner can sit lightly on the distal aspects of both feet. The examiner then grasps the proximal aspect of the tibia with both hands and ensures that the hamstrings are relaxed, then applies a direct posterior force to the proximal tibia. The examiner's thumbs are placed on the tibial tubercle during this maneuver and are used to identify the amount of posterior displacement of the tibia, which is graded as in the anterior drawer test. Comparisons can be made with the opposite side when the examination is difficult to perform or when the starting point is obscure, for example when the proximal tibia is subluxed posteriorly before the posteriorly directed force is applied to the tibia. Often a PCL dislocation is associated with injuries of the posterolateral corner (arcuate complex, popliteus, and LCL). The Hughston and Norwood posterolateral drawer test helps to define associated posterolateral corner injuries.¹⁰³ When a posterolateral corner injury is associated with a PCL injury, there is more posterolateral spin of the tibia on the femur with the knee flexed to 90 degrees than when it is flexed to 30 degrees. This is best assessed with the patient supine and the hip flexed to 90 degrees, followed by external rotation of the tibia on the femur, comparing the amount of external foot rotation at 30 degrees and 90 degrees of knee flexion. The isolated posterolateral corner injury has a greater thigh-foot angle at 30 degrees than at 90 degrees (Fig. 42-132). Other tests for PCL instability include the reverse pivot shift test, which relies on the tibia subluxing posteriorly when the knee is flexed to approximately 20 to 30 degrees.¹¹⁰

The patient with a suspected MCL injury should be evaluated with initial palpation of the MCL at its points of insertion on the medial femoral condyle and at its insertion on the anteromedial aspect of the proximal tibia just under the pes anserinus. Tenderness along the ligament or at its insertion point raises the suspicion of a ligament tear. Stress

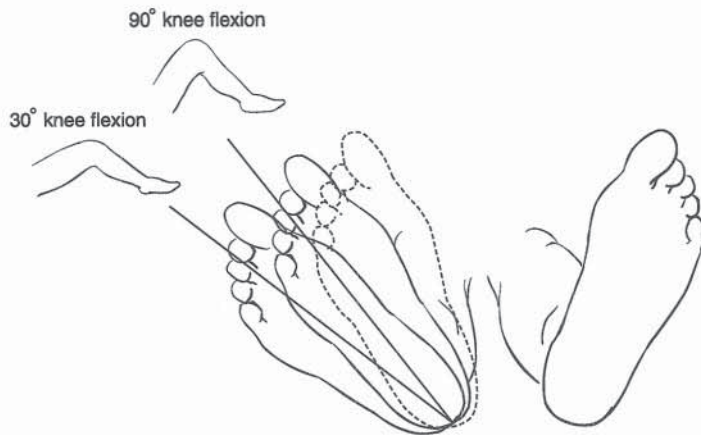


FIGURE 42-132 Asymmetric thigh-foot angles are present in a posterolateral corner tear of the right knee, more prominent in 30 degrees of knee flexion than in 90 degrees of knee flexion.

tests are then performed with the knee in full extension while a valgus stress is applied to the knee. Opening on the medial aspect of the knee in this position indicates a substantial tear of the MCL along with the medial capsule and one or both cruciate ligaments. The knee should be then be flexed to 10 to 15 degrees of flexion and the valgus stress repeated, as this position of the knee relaxes the posterior capsule and allows specific testing of the MCL.^{72,88} MCL injuries are best classified according to the Marshall grading system, since it is easy to use and offers prognostic information:⁷² grade I, MCL tender without laxity; grade II, increased valgus laxity in flexion without instability in full extension; and grade III, valgus laxity in both flexion and full extension. The LCL can be easily palpated with the knee in the figure-four position as it travels from the lateral femoral condyle to the head of the fibula. Tenderness or obvious disruption of the ligament indicates injury of the LCL. Stress testing of the knee should be performed with the knee in an extended position, since normal varus laxity occurs with knee flexion.

Although isolated injuries of the various ligaments occur, there is a high incidence of associated injuries within the knee; these injuries should be carefully evaluated prior to determining treatment. One of the most common injury patterns is that of an ACL-MCL combination injury, which has a reported incidence of 15 to 40 percent.^{75,161,162,206} Meniscal tears are relatively common in patients with an ACL tear. It is generally agreed that the medial meniscus is more often torn in the normal knee and in the ACL-deficient knee. However, in the acutely torn ACL, the lateral meniscus is more often torn at the time of injury.*

Radiographs of the knee should be obtained in any patient with a suspected ligamentous injury to assess for fractures or bony avulsions indicating ligamentous injury. Images should include an AP, lateral, tunnel, and skyline views. Skeletal maturity should be assessed on these radiographs, with careful inspection of the physes to determine their degree of closure. Bony abnormalities should be assessed, including tibial spine avulsion fractures, physeal fractures, and collateral ligament avulsions of the MCL or LCL. The clinician should evaluate for associated osteochondral lesions, which are seen in up to 23 percent of acute ACL injuries.^{69,70} In the chronically ACL-deficient knee the incidence is far higher. A capsular avulsion on the lateral aspect

of the proximal tibia, the so-called Segond fracture, is seen in approximately 10 percent of cases and can help to make the diagnosis of an ACL tear. MRI should be used only as an adjunct to a good history and physical examination when the extent and degree of the injury are difficult to determine.

Treatment. Each patient must be carefully evaluated and the treatment decision based on which ligamentous structures are injured, the age and skeletal maturity of the child, the anticipated activity level of the child, and the expectations of the parents.

The initial treatment for an ACL-deficient knee is to restore the normal range of motion of the knee. Although treatment of an ACL-deficient knee depends partly on the activity level of the child and the status of the physes, in most cases the ultimate treatment is surgical reconstruction to reestablish joint stability, which allows the patient to return to normal physical activities but does not jeopardize the remaining intact structures of the knee. A comparison of young patients treated nonoperatively with those treated with reconstruction demonstrated that those who had nonoperative treatment experienced instability, with recurrent pain and effusion, and many did not return to sports activities and required operative intervention for torn menisci.¹³⁹ There is no role for direct repair of the ligament, owing to the rapid inflammatory reaction that occurs soon after injury.

The most controversial issue surrounding injury to the skeletally immature child with an ACL injury is whether to perform surgical intervention shortly after injury or to postpone the intra-articular surgical reconstruction until the physes have closed. Most reports of intra-articular reconstruction in the skeletally immature knee do not indicate a high incidence of limb length discrepancy or angular deformity secondary to physeal injury. Lipscomb and Anderson reported results in 24 adolescent patients with open physes who had undergone open intra-articular reconstruction performed using semitendinosus and gracilis tendons. The tibial tunnel was centered through the tibia and penetrated the physis, while the femoral tunnel exited distal to the distal femoral physis. They reported 96 percent good or excellent results, and only one patient had a limb length discrepancy of 2 cm.¹²⁷ Similarly, Parker and colleagues reported a 33-month follow-up of five children with open physes who had undergone autogenous hamstring intra-articular reconstruction of the ACL in which the graft tunnels avoided the

*See references 16, 21, 40, 42, 43, 118, 201.

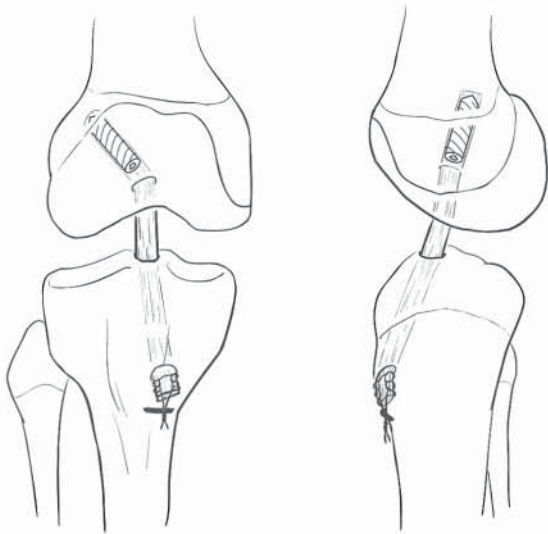


FIGURE 42-133 Surgical reconstruction of the anterior cruciate ligament in a skeletally immature patient.

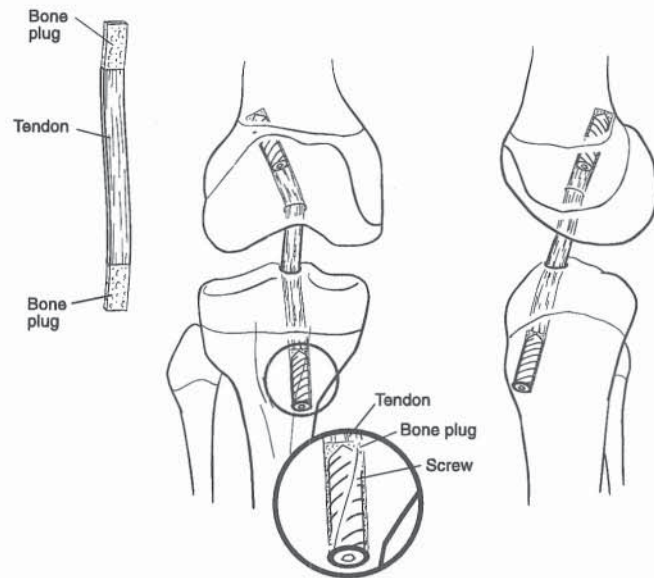


FIGURE 42-134 Surgical reconstruction of the anterior cruciate ligament in a skeletally mature patient.

physes. Results were good, and no patient had a leg length discrepancy.¹⁷¹ Others have reported similar results, without deformity or limb length discrepancy.^{22,209} We prefer to treat the skeletally immature child nonoperatively if the child and parents have limited goals for participation in athletic activities and if there are no instability symptoms when the child participates in his or her present activities. Nonoperative treatment should consist of initial measures to maintain comfort, including a brief period of knee immobilization, followed by attempts to regain normal range of motion of the knee. A good home exercise program consists of quadriceps and hamstring strengthening exercises to help restore knee stability. Within 6 to 8 weeks the patient should have achieved normal motion and strength and can begin to participate in athletic activities. These activities should be limited to noncontact sports and sports that do not require quick turns and stops and starts. If the patient experiences symptoms of instability during moderate activities and is very active in competitive contact sports, we prefer to perform an intra-articular reconstruction using a hamstring graft, which is tunneled through the center of the tibial physis but placed in the over-the-top femoral position to avoid the distal femoral physis (Fig. 42-133). In the skeletally mature adolescent we prefer an intra-articular reconstruction performed using either a patellar tendon or a hamstring graft (Fig. 42-134). The two most common graft materials are patellar tendon and hamstring. The proposed advantages of the patellar tendon include greater strength and better fixation to the femur and tibia.* The advantages of a hamstring graft include less donor site morbidity and patellar pain, material properties similar to the ACL, with a more circular cross-sectional area, and the ability to double, triple, and quadruple the tendons.^{32,220}

Combined ACL and MCL tears are relatively common and therefore should be carefully sought in any patient with a suspected ACL tear. Patients with a grade I or II MCL injury should be treated with a hinged knee brace for 4 to

6 weeks, followed by rehabilitation to obtain normal range of motion and strength. In the young child with open physes, surgical reconstruction of the ACL can be performed at a later date (or earlier, depending on symptoms), while the adolescent should undergo reconstruction as previously described. The results of operative treatment of the ACL without surgical repair of the MCL have been uniformly good, without residual valgus instability.^{11,12,97,196,205} In the patient with a grade III injury of the MCL, we recommend operative treatment to directly repair the torn ligament, with simultaneous reconstruction of the ACL in the older child. Aggressive rehabilitation is needed to regain motion of the knee, especially in patients with MCL disruptions at or proximal to the joint line.¹⁸⁷

Isolated MCL injuries are treated nonoperatively, with excellent results. Grade I and II injuries are treated symptomatically with a hinged brace or crutches until the patient is asymptomatic, which is usually between 1 and 3 weeks. Grade III injuries should be treated with immobilization with a hinged knee brace for 4 to 6 weeks, during which time quadriceps and hamstring strengthening exercises should be performed. Athletic activities can be resumed when full range of motion of the knee is achieved and the strength of the leg is similar to the opposite side.

Treatment of the patient with a PCL tear is usually nonoperative, with good results reported.^{51,208} In the acutely torn PCL, the initial treatment is symptomatic, together with active range-of-motion and strengthening exercises. The grade III PCL tear may result in continued instability requiring reconstruction, especially in the high-performance athlete.⁴⁵

Isolated tears of the lateral collateral ligament are rare and are treated similarly to isolated tears of the MCL. Grade III injuries are most often associated with tears of the ACL. Treatment of this clinical situation is controversial, with

*See references 44, 62, 66, 113, 122, 159.

little data available in the pediatric literature. In the skeletally immature child, the grade III LCL tear should be repaired primarily, with delayed reconstruction of the ACL performed at skeletal maturity. In the adolescent, simultaneous reconstruction of the ACL with direct repair of the LCL should be performed.

MENISCAL INJURIES

Anatomy. The menisci are composed of fibrocartilage, with its circumferentially arranged collagen fibers designed to bear the tensile loads of the weightbearing surface. In addition to the circumferential arrangement, some collagen fibers are arranged in radial fashion to provide additional support. The blood supply to the menisci comes from the surrounding capsular and synovial perimeniscal capillary plexus, which branches from the medial, lateral, and middle geniculate arteries.⁹ The peripheral 30 percent of the meniscus, the so-called red-red zone, has the richest blood supply. The development of the menisci begins during the 10th week of fetal life when they have a semilunar appearance.⁴⁷ At birth there is an abundance of cells compared to matrix, and this slowly declines until the age of 10, when the adult microscopic appearance of the menisci is present. The medial meniscus is larger than the lateral meniscus and takes on a more C-shaped structure that is narrower and thinner. The anterior attachment of the medial meniscus is anterior to the intercondylar eminence and the ACL. The posterior horn attaches anterior to the attachment of the PCL and just posterior to the intercondylar eminence. At its periphery, the meniscus is attached to the medial capsule and attaches to the proximal tibia through the coronary ligaments. The lateral meniscus is thicker, smaller, and more mobile than the medial meniscus. The anterior horn attaches to the tibia anterior to the tibial eminence and the posterior horn attaches to the intercondylar eminence just anterior to the posterior attachment of the medial meniscus. Additional attachments via the meniscofemoral ligaments (the ligament of Humphry and Wrisberg) help stabilize the posterior horn of the lateral meniscus.

Classification. There are four basic types of meniscal tears: the vertical longitudinal, horizontal, oblique, and radial (Fig. 42–135). Tears may occur in one of these basic patterns or in a combination of these patterns. In a longitudinal tear the collagen fibers split in line with the circumferentially directed fibers, which can result in instability of the innermost fragment when the tear is full-thickness. The location of the tear with respect to the peripheral aspect of the meniscus

should be identified to help determine whether repair can be performed. The partial longitudinal tear may begin on the superior or inferior surface of the meniscus and should be carefully evaluated. The horizontal cleavage tear occurs in a plane parallel to the superior and inferior surfaces of the meniscus and is rare in children. The oblique tear is a full-thickness vertical tear through the inner free margin of the meniscus that extends peripherally. The radial tear begins on the innermost aspect of the free edge of the meniscus and extends peripherally perpendicular to the free edge.

Mechanism of Injury. The majority of meniscal tears occur with a twisting motion of the knee without direct trauma to the knee. This most often occurs when the knee is partially flexed and a rotational force drives the femoral condyle into the meniscus, producing a shearing force which results in meniscal failure. These tears usually occur in older children who are involved in relatively strenuous high-competitive activities that involve quick cuts and turns. Direct trauma to the knee may also result in meniscal injury when the blow forces the knee to suddenly rotate, producing the shearing force to the menisci.

Diagnostic Features. Patients may remember the traumatic event in which they had a twisting injury of the knee and may have heard or felt a “pop.” However, up to 40 percent experience the spontaneous onset of symptoms without a known inciting event.¹¹⁷ Often the pain diminishes following injury; however, it returns and is associated with a knee effusion 24 to 48 hours later. Other symptoms include locking, giving way, and clicking sensations. King reported that 82 percent of patients had pain, 63 percent had giving way, 43 percent had locking, and 45 percent had the sensation of clicking in the knee, while only 34 percent of patients had recurrent effusions—a lower rate than in adults.¹¹⁷

The physical examination should include a thorough assessment of the ligamentous structures of the knee. A focused examination for meniscal pathology includes inspecting the knee for joint effusion and palpating the medial and joint line in an attempt to elicit tenderness. The provocative maneuvers of McMurray and Apley may help confirm or identify pathology, especially tears of the most posterior horn of the medial meniscus.

Radiographs of the knee should be obtained to identify occult fractures, injuries to the physis, osteochondral injuries, or avulsion fractures. Currently MRI is the most accurate diagnostic study to identify a meniscal injury in the pediatric population, with a reported accuracy of up to 95 percent.*

Treatment. We have learned that complete meniscectomy as treatment for a torn or injured meniscus is detrimental to the long-term outcome of the knee.† Today, the preferred options for treatment include observation, partial meniscectomy, and meniscal repair.

Most meniscal tears require operative intervention; however, some can be left alone. These include partial-thickness split tears that arise from the femoral or tibial surfaces and are stable to probing, and short tears that are vertical peripheral tears or radial, since sufficient healing to resolve

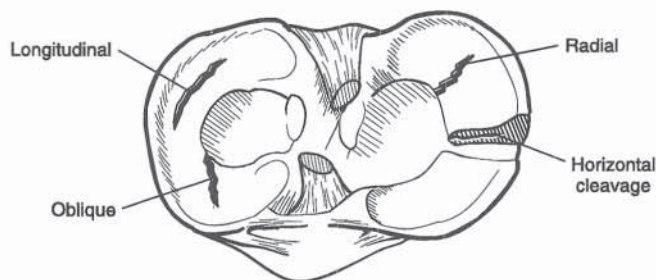


FIGURE 42–135 The four basic types of meniscal tears: longitudinal, oblique, radial, and horizontal cleavage.

*See references 20, 104, 133, 150, 179, 222, 247.

†See references 8, 100, 142, 178, 223, 231.

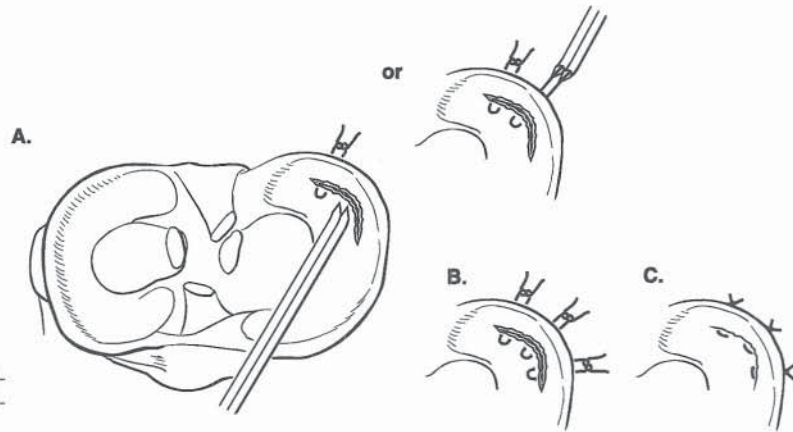


FIGURE 42-136 Meniscal repair A, The inside-out (or outside-in) technique. B, The sutures have been placed in a horizontal fashion. C, The sutures are then tied on the outside.

symptoms often occurs.²³⁷ The indications for meniscal repair include the long (15 to 25 mm) vertical longitudinal tears at the periphery without significant damage to the body of the meniscus.^{39,55,90,200} Although the tear should be clearly in the vascular zone of the meniscus, vascular penetration is greater in children than in adults, allowing greater potential for healing. For example, the best results of meniscal repair in adults are achieved in tears within 3 mm of the periphery; however, in children it is likely that tears extending more than 3 mm from the periphery will heal. Various techniques for repair have been described; these include inside-out, outside-in, and all-inside procedures (Fig. 42-136).^{*} Fibrin clot sutured into the repair site appears to increase the likelihood of healing.[†] The newer techniques for meniscal repair include fixation with meniscal arrows or darts, which make stabilization of the meniscus easier and have been demonstrated to have holding strength similar to that of traditional sutures.^{4,5,26,58,144,217} However, this is a new technique, and no long-term studies have been reported in the literature.

The primary indications for partial meniscectomy are tears that are not amenable to repair because of location, chronicity of the tear, or configuration. The goal of partial meniscectomy is to remove the torn aspect of the meniscus while preserving as much of the meniscus as possible. The zone between torn and normal meniscus should be tapered to create a smooth transition area, thus decreasing the likelihood of creating a starting point for a new tear. The results of partial meniscectomy are generally very good, with immediate and long-term symptom relief.[‡]

REFERENCES

The Knee

1. Aglietti P, Zaccherotti G, De Biase P, et al: A comparison between medial meniscus repair, partial meniscectomy, and normal meniscus in anterior cruciate ligament reconstructed knees. *Clin Orthop* 1994;307:165.
2. Aitken A: Fractures of the proximal tibial epiphyseal cartilage. *Clin Orthop Rel Res* 1965;41:92.
3. Aitken A, Magil H: Fractures involving the distal femoral epiphyseal cartilage. *J Bone Joint Surg* 1952;34-A:96.

*See references 33, 37, 48, 67, 136, 151, 152, 183, 188, 199, 211.

†See references 74, 92, 106-108, 176, 185, 230, 232.

‡See references 1, 13, 18, 27, 94-96, 112, 115, 119, 120, 137, 197, 216.

4. Albrecht-Olsen P, Kristensen G, Burgaard P, et al: The arrow versus horizontal suture in arthroscopic meniscus repair: a prospective randomized study with arthroscopic evaluation. *Knee Surg Sports Traumatol Arthrosc* 1999;7:268.
5. Albrecht-Olsen P, Lind T, Kristensen G, et al: Failure strength of a new meniscus arrow repair technique: biomechanical comparison with horizontal suture. *Arthroscopy* 1997;13:183.
6. Anderson M, Green WT, Messner MD: Growth and predictions of growth in the lower extremities. *J Bone Joint Surg* 1963;45-A:1.
7. Angel K, Hall D: Anterior cruciate ligament injury in children and adolescents. *Arthroscopy* 1989;5:197.
8. Appel H: Late results after meniscectomy in the knee joint: a clinical and roentgenologic follow-up investigation. *Acta Orthop Scand Suppl* 1970;133:1.
9. Arnoczky SP, Warren RF: Microvasculature of the human meniscus. *Am J Sports Med* 1982;10:90.
10. Bakalim G, Wilppula E: Closed treatment of fracture of the tibial spines. *Injury* 1974;5:210.
11. Ballmer PM, Ballmer FT, Jakob RP: Reconstruction of the anterior cruciate ligament alone in the treatment of a combined instability with complete rupture of the medial collateral ligament: a prospective study. *Arch Orthop Trauma Surg* 1991;110:139.
12. Barber FA: Snow skiing combined anterior cruciate ligament/medial collateral ligament disruptions. *Arthroscopy* 1994;10:85.
13. Barrett GR, Treacy SH, Ruff CG: The effect of partial lateral meniscectomy in patients > or = 60 years. *Orthopedics* 1998;21:251.
14. Bassett FHI, Goldner JL: Fractures involving the distal femoral epiphyseal growth line. *South Med J* 1962;55:545.
15. Baxter MP, Wiley JJ: Fractures of the tibial spine in children: an evaluation of knee stability. *J Bone Joint Surg* 1988;70-B:228.
16. Bellabarba C, Bush-Joseph CA, Bach BR Jr: Patterns of meniscal injury in the anterior cruciate-deficient knee: a review of the literature. *Am J Orthop* 1997;26:18.
17. Belman DA, Neviasser RJ: Transverse fracture of the patella in a child. *J Trauma* 1973;13:917.
18. Benedetto KP, Rangger C: Arthroscopic partial meniscectomy: 5-year follow-up. *Knee Surg Sports Traumatol Arthrosc* 1993;1:235.
19. Bertin KC, Goble EM: Ligament injuries associated with physeal fractures about the knee. *Clin Orthop* 1983;177:188.
20. Biedert RM: Intrasubstance meniscal tears: clinical aspects and the role of MRI. *Arch Orthop Trauma Surg* 1993;112:142.
21. Binfield PM, Maffulli N, King JB: Patterns of meniscal tears associated with anterior cruciate ligament lesions in athletes. *Injury* 1993;24:557.
22. Bisson LJ, Wickiewicz T, Levinson M, et al: ACL reconstruction in children with open physes. *Orthopedics* 1998;21:659.
23. Blanks RH, Lester DK, Shaw BA: Flexion-type Salter II fracture of the proximal tibia: proposed mechanism of injury and two case studies. *Clin Orthop* 1994;301:256.
24. Blount W: *Fractures in Children*. Baltimore, Williams & Wilkins Co, 1955.
25. Blumensaat C: Die Lageabweichungen und Verrenkungen der Kniescheibe. *Ergeb Chir Orthop* 1938;31:149.
26. Boenisch UW, Faber KJ, Ciarelli M, et al: Pull-out strength and stiffness of meniscal repair using absorbable arrows or Ti-Cron vertical and horizontal loop sutures. *Am J Sports Med* 1999;27:626.

27. Bolano LE, Grana WA: Isolated arthroscopic partial meniscectomy: functional radiographic evaluation at five years. *Am J Sports Med* 1993;21:432.
28. Bostrom A: Fracture of the patella: a study of 422 patellar fractures. *Acta Orthop Scand Suppl* 1972;143:1.
29. Bradley GW, Shives TC, Samuelson KM: Ligament injuries in the knees of children. *J Bone Joint Surg* 1979;61-A:588.
30. Brattstrom H: Shape of the intercondylar groove normally and in recurrent dislocation of patella: a clinical and x-ray-anatomical investigation. *Acta Orthop Scand Suppl* 1964;68:1.
31. Bright R, Burstein A, Elmore S: Epiphyseal-plate cartilage: a biomechanical and histological analysis of failure modes. *J Bone Joint Surg* 1974;56-A:688.
32. Brown CH Jr, Steiner ME, Carson EW: The use of hamstring tendons for anterior cruciate ligament reconstruction: technique and results. *Clin Sports Med* 1993;12:723.
33. Brown GC, Rosenberg TD, Deffner KT: Inside-out meniscal repair using zone-specific instruments. *Am J Knee Surg* 1996;9:144.
34. Bruijn JD, Sanders RJ, Jansen BR: Ossification in the patellar tendon and patella alta following sports injuries in children: complications of sleeve fractures after conservative treatment. *Arch Orthop Trauma Surg* 1993;112:157.
35. Burkhart SS, Peterson HA: Fractures of the proximal tibial epiphysis. *J Bone Joint Surg* 1979;61-A:996.
36. Butler D, Noyes F, Grood E: Ligamentous restraints to anterior-posterior drawer in the human knee: a biomechanical study. *J Bone Joint Surg* 1980;62-A:259.
37. Cannon WD Jr: Arthroscopic meniscal repair: inside-out technique and results. *Am J Knee Surg* 1996;9:137.
38. Cash JD, Hughston JC: Treatment of acute patellar dislocation. *Am J Sports Med* 1988;16:244.
39. Cassidy RE, Shaffer AJ: Repair of peripheral meniscus tears: a preliminary report. *Am J Sports Med* 1981;9:209.
40. Cerabona F, Sherman MF, Bonamo JR, et al: Patterns of meniscal injury with acute anterior cruciate ligament tears. *Am J Sports Med* 1988;16:603.
41. Christie MJ, Dvonch VM: Tibial tuberosity avulsion fracture in adolescents. *J Pediatr Orthop* 1981;1:391.
42. Cimino PM: The incidence of meniscal tears associated with acute anterior cruciate ligament disruption secondary to snow skiing accidents. *Arthroscopy* 1994;10:198.
43. Cipolla M, Scala A, Gianni E, et al: Different patterns of meniscal tears in acute anterior cruciate ligament (ACL) ruptures and in chronic ACL-deficient knees: classification, staging and timing of treatment. *Knee Surg Sports Traumatol Arthrosc* 1995;3:130.
44. Clancy WG Jr, Nelson DA, Reider B, et al: Anterior cruciate ligament reconstruction using one-third of the patellar ligament, augmented by extra-articular tendon transfers. *J Bone Joint Surg* 1982;64-A:352.
45. Clancy WG Jr, Shelbourne KD, Zoellner GB, et al: Treatment of knee joint instability secondary to rupture of the posterior cruciate ligament: report of a new procedure. *J Bone Joint Surg* 1983;65-A:310.
46. Clanton TO, De Lee JC, Sanders B, et al: Knee ligament injuries in children. *J Bone Joint Surg* 1979;61-A:1195.
47. Clark CR, Ogden JA: Development of the menisci of the human knee joint: morphological changes and their potential role in childhood meniscal injury. *J Bone Joint Surg* 1983;65-A:538.
48. Coen MJ, Caborn DN, Urban W, et al: An anatomic evaluation of T-Fix suture device placement for arthroscopic all-inside meniscal repair. *Arthroscopy* 1999;15:275.
49. Conlan T, Garth WP Jr, Lemons JE: Evaluation of the medial soft-tissue restraints of the extensor mechanism of the knee. *J Bone Joint Surg* 1993;75-A:682.
50. Crock H: The arterial supply and venous drainage of the bones of the human knee joint. *Anat Rec* 1962;144:199.
51. Cross MJ, Powell JF: Long-term followup of posterior cruciate ligament rupture: a study of 116 cases. *Am J Sports Med* 1984;12:292.
52. Crothers OD, Johnson JT: Isolated acute dislocation of the proximal tibiofibular joint: case report. *J Bone Joint Surg* 1973;55-A:181.
53. Czitrom A, Salter R, Willis R: Fractures involving the distal epiphyseal plate of the femur. *Int Orthop* 1981;4:269.
54. Dandy DJ, Pusey RJ: The long-term results of unrepaired tears of the posterior cruciate ligament. *J Bone Joint Surg* 1982;64-B:92.
55. De Haven KE, Black KP, Griffiths HJ: Open meniscus repair: technique and two to nine year results. *Am J Sports Med* 1989;17:788.
56. Deliyannis SN: Avulsion of the tibial tuberosity: report of two cases. *Injury* 1973;4:341.
57. Dennis J, Rutledge B: Bilateral recurrent dislocations of the superior tibiofibular joint with peroneal-nerve palsy: a case summary. *J Bone Joint Surg* 1958;40-A:1146.
58. Dervin GF, Downing KJ, Keene GC, et al: Failure strengths of suture versus biodegradable arrow for meniscal repair: an in vitro study. *Arthroscopy* 1997;13:296.
59. Devas M: Stress fractures of the patella. *J Bone Joint Surg* 1960;42-B:71.
60. Diamond L, Alegado R: Perinatal fractures in arthrogryposis multiplex congenita. *J Pediatr Orthop* 1981;1:189.
61. Dowd G, Bailey G: Radiographic assessment in patellar instability and chondromalacia patellae. *J Bone Joint Surg* 1986;68-B:297.
62. Drez DJ Jr, De Lee J, Holden JP, et al: Anterior cruciate ligament reconstruction using bone-patellar tendon-bone allografts: a biological and biomechanical evaluation in goats. *Am J Sports Med* 1991;19:256.
63. Edvardsen P: Physioepiphyseal injuries of lower extremities in myelomeningocele. *Acta Orthop Scand* 1972;43:550.
64. Ehrenborg G: The Osgood-Schlatter lesion: a clinical and experimental study. *Acta Chir Scand* 1962;288:1.
65. Eiskjaer S, Larsen ST, Schmidt MB: The significance of hemarthrosis of the knee in children. *Arch Orthop Trauma Surg* 1988;107:96.
66. Eriksson E: Reconstruction of the anterior cruciate ligament. *Orthop Clin North Am* 1976;7:167.
67. Esser RD: Arthroscopic meniscus repair: the easy way. *Arthroscopy* 1993;9:231.
68. Falkenberg P, Nygaard H: Isolated anterior dislocation of the proximal tibiofibular joint. *J Bone Joint Surg* 1983;65-B:310.
69. Feagin JA Jr: The syndrome of the torn anterior cruciate ligament. *Orthop Clin North Am* 1979;10:81.
70. Feagin JA Jr, Lambert KL: Mechanism of injury and pathology of anterior cruciate ligament injuries. *Orthop Clin North Am* 1985;16:41.
71. Feller JA, Feagin JA Jr, Garrett WE Jr: The medial patellofemoral ligament revisited: an anatomical study. *Knee Surg Sports Traumatol Arthrosc* 1993;1:184.
72. Fetto JF, Marshall JL: Medial collateral ligament injuries of the knee: a rationale for treatment. *Clin Orthop* 1978;132:206.
73. Fetto JF, Marshall JL: The natural history and diagnosis of anterior cruciate ligament insufficiency. *Clin Orthop* 1980;147:29.
74. Forman SK, Oz MC, Lontz JF, et al: Laser-assisted fibrin clot soldering of human menisci. *Clin Orthop* 1995;310:37.
75. Frolke JP, Oskam J, Vierhout PA: Primary reconstruction of the medial collateral ligament in combined injury of the medial collateral and anterior cruciate ligaments: short-term results. *Knee Surg Sports Traumatol Arthrosc* 1998;6:103.
76. Fukubayashi T, Torzilli PA, Sherman MF, et al: An in vitro biomechanical evaluation of anterior-posterior motion of the knee: tibial displacement, rotation, and torque. *J Bone Joint Surg* 1982;64-A:258.
77. George R: Bilateral bipartite patellae. *Br J Surg* 1935;22:555.
78. Gersoff W, Clancy W: Diagnosis of acute and chronic anterior cruciate ligament tears. *Clin Sports Med* 1988;7:727.
79. Giachino AA: Recurrent dislocations of the proximal tibiofibular joint: report of two cases. *J Bone Joint Surg* 1986;68-A:1104.
80. Godfrey J: Ligamentous injuries of the knee. *Curr Pract Orthop Surg* 1973;5:56.
81. Goodrich A, Ballard A: Posterior cruciate ligament avulsion associated with ipsilateral femur fracture in a 10-year-old child. *J Trauma* 1988;28:1393.
82. Green WT Jr: Painful bipartite patellae: a report of three cases. *Clin Orthop* 1975;110:197.
83. Green WT, Anderson M: Epiphyseal arrest for the correction of discrepancies in length of the lower extremities. *J Bone Joint Surg* 1957;39-A:853.
84. Griswold A: Early motion in the treatment of separation of the lower femoral epiphysis: report of a case. *J Bone Joint Surg* 1928;10:75.
85. Grogan DP, Bobechko WP: Pathogenesis of a fracture of the distal femoral epiphysis: a case report. *J Bone Joint Surg* 1984;66-A:621.
86. Grogan DP, Carey TP, Leffers D, et al: Avulsion fractures of the patella. *J Pediatr Orthop* 1990;10:721.
87. Gronkvist H, Hirsch G, Johansson L: Fracture of the anterior tibial spine in children. *J Pediatr Orthop* 1984;4:465.
88. Grood ES, Noyes FR, Butler DL, et al: Ligamentous and capsular restraints preventing straight medial and lateral laxity in intact human cadaver knees. *J Bone Joint Surg* 1981;63-A:1257.

89. Gustilo RB, Anderson JT: Prevention of infection in the treatment of one thousand and twenty-five open fractures of long bones: retrospective and prospective analyses. *J Bone Joint Surg* 1976;58-A:453.
90. Hamberg P, Gillquist J, Lysholm J: Suture of new and old peripheral meniscus tears. *J Bone Joint Surg* 1983;65-A:193.
91. Hand WL, Hand CR, Dunn AW: Avulsion fractures of the tibial tubercle. *J Bone Joint Surg* 1971;53-A:1579.
92. Hashimoto J, Kurosaka M, Yoshiya S, et al: Meniscal repair using fibrin sealant and endothelial cell growth factor: an experimental study in dogs. *Am J Sports Med* 1992;20:537.
93. Hayes JM, Masear VR: Avulsion fracture of the tibial eminence associated with severe medial ligamentous injury in an adolescent: a case report and literature review. *Am J Sports Med* 1984;12:330.
94. Hede A, Larsen E, Sandberg H: The long term outcome of open total and partial meniscectomy related to the quantity and site of the meniscus removed. *Int Orthop* 1992;16:122.
95. Hede A, Larsen E, Sandberg H: Partial versus total meniscectomy: a prospective, randomized study with long-term follow-up. *J Bone Joint Surg* 1992;74-B:118.
96. Hede A, Larsen E, Sandberg H: [Partial versus total meniscectomy: a prospective, randomized study]. *Ugeskr Laeger* 1994;156:48.
97. Hillard-Sembell D, Daniel DM, Stone ML, et al: Combined injuries of the anterior cruciate and medial collateral ligaments of the knee: effect of treatment on stability and function of the joint. *J Bone Joint Surg* 1996;78-A:169.
98. Houghton GR, Ackroyd CE: Sleeve fractures of the patella in children: a report of three cases. *J Bone Joint Surg* 1979;61-B:165.
99. Howe J, Johnson R: Knee studies in skiing. *Clin Sports Med* 1982;1:277.
100. Huckell JR: Is meniscectomy a benign procedure? A long term follow-up study. *Can J Surg* 1965;8:254.
101. Hughston J: Reconstruction of the extensor mechanism for subluxing patella. *J Sports Med* 1972;1:6.
102. Hughston JC, Bowden JA, Andrews JR, et al: Acute tears of the posterior cruciate ligament: results of operative treatment. *J Bone Joint Surg* 1980;62-A:438.
103. Hughston JC, Norwood LA Jr: The posterolateral drawer test and external rotational recurvatum test for posterolateral rotatory instability of the knee. *Clin Orthop* 1980;147:82.
104. Hutchinson CH, Wojtyl EM: MRI versus arthroscopy in evaluating knee meniscal pathology. *Am J Knee Surg* 1995;8:93.
105. Insall J, Salvati E: Patella position in the normal knee joint. *Radiology* 1971;101:101.
106. Ishimura M, Ohgushi H, Habata T, et al: Arthroscopic meniscal repair using fibrin glue. Part I. Experimental study. *Arthroscopy* 1997;13:551.
107. Ishimura M, Ohgushi H, Habata T, et al: Arthroscopic meniscal repair using fibrin glue. Part II. Clinical applications. *Arthroscopy* 1997;13:558.
108. Ishimura M, Tamai S, Fujisawa Y: Arthroscopic meniscal repair with fibrin glue. *Arthroscopy* 1991;7:177.
109. Iwaya T, Takatori Y: Lateral longitudinal stress fracture of the patella: report of three cases. *J Pediatr Orthop* 1985;5:73.
110. Jakob RP, Hassler H, Staeubli HU: Observations on rotatory instability of the lateral compartment of the knee: experimental studies on the functional anatomy and the pathomechanism of the true and the reversed pivot shift sign. *Acta Orthop Scand Suppl* 1981;191:1.
111. Janarv PM, Westblad P, Johansson C, et al: Long-term follow-up of anterior tibial spine fractures in children. *J Pediatr Orthop* 1995;15:63.
112. Jaureguito JW, Elliot JS, Lietner T, et al: The effects of arthroscopic partial lateral meniscectomy in an otherwise normal knee: a retrospective review of functional, clinical, and radiographic results. *Arthroscopy* 1995;11:29.
113. Jones K: Reconstruction of the anterior cruciate ligament: a technique using the central 1/3 of the patellar ligament. *J Bone Joint Surg* 1963;45-A:929.
114. Kasser JR: Physeal bar resections after growth arrest about the knee. *Clin Orthop* 1990;255:68.
115. Katz JN, Harris TM, Larson MG, et al: Predictors of functional outcomes after arthroscopic partial meniscectomy. *J Rheumatol* 1992;19:1938.
116. Kennedy JC, Grainger RW: The posterior cruciate ligament. *J Trauma* 1967;7:367.
117. King AG: Meniscal lesions in children and adolescents: a review of the pathology and clinical presentation. *Injury* 1983;15:105.
118. King SJ, Carty HM, Brady O: Magnetic resonance imaging of knee injuries in children. *Pediatr Radiol* 1996;26:287.
119. Kruger-Franke M, Kugler A, Trouillier HH, et al: [Clinical and radiological results after arthroscopic partial medial meniscectomy: are there risk factors?]. *Unfallchirurg* 1999;102:434.
120. Kruger-Franke M, Siebert CH, Kugler A, et al: Late results after arthroscopic partial medial meniscectomy. *Knee Surg Sports Traumatol Arthrosc* 1999;7:81.
121. Kumar S, Cowell H, Townsend P: Physeal, metaphyseal, and diaphyseal injuries of the lower extremities in children with myelomeningocele. *J Pediatr Orthop* 1984;4:25.
122. Lambert KL: Vascularized patellar tendon graft with rigid internal fixation for anterior cruciate ligament insufficiency. *Clin Orthop* 1983;172:85.
123. Lange RH, Bach AW, Hansen ST Jr, et al: Open tibial fractures with associated vascular injuries: prognosis for limb salvage. *J Trauma* 1985;25:203.
124. Larsen E, Lauridsen F: Conservative treatment of patellar dislocations: influence of evident factors on the tendency to redislocation and the therapeutic result. *Clin Orthop* 1982;171:131.
125. Levi JH, Coleman CR: Fracture of the tibial tubercle. *Am J Sports Med* 1976;4:254.
126. Lieb F, Perry J: Quadriceps function. *J Bone Joint Surg* 1968;50-A:1535.
127. Lipscomb AB, Anderson AF: Tears of the anterior cruciate ligament in adolescents. *J Bone Joint Surg* 1986;68-A:19.
128. Lombardo SJ, Harvey JP Jr: Fractures of the distal femoral epiphyses: factors influencing prognosis. A review of thirty-four cases. *J Bone Joint Surg* 1977;59-A:742.
129. Loos WC, Fox JM, Blazina ME, et al: Acute posterior cruciate ligament injuries. *Am J Sports Med* 1981;9:86.
130. Losee RE: Concepts of the pivot shift. *Clin Orthop* 1983;172:45.
131. Losee RE: Diagnosis of chronic injury to the anterior cruciate ligament. *Orthop Clin North Am* 1985;16:83.
132. Lyle H: Traumatic luxation of the head of the fibula. *Ann Surg* 1925;82:635.
133. Magee TH, Hinson GW: MRI of meniscal bucket-handle tears. *Skeletal Radiol* 1998;27:495.
134. Maguire JK, Canale ST: Fractures of the patella in children and adolescents. *J Pediatr Orthop* 1993;13:567.
135. Mann DC, Rajmaira S: Distribution of physeal and nonphyseal fractures in 2,650 long-bone fractures in children aged 0–16 years. *J Pediatr Orthop* 1990;10:713.
136. Maruyama M: The all-inside meniscal suture technique using new instruments. *Arthroscopy* 1996;12:256.
137. Matsusue Y, Thomson NL: Arthroscopic partial medial meniscectomy in patients over 40 years old: a 5- to 11-year follow-up study. *Arthroscopy* 1996;12:39.
138. Mayer PJ, Micheli LJ: Avulsion of the femoral attachment of the posterior cruciate ligament in an eleven-year-old boy: case report. *J Bone Joint Surg* 1979;61-A:431.
139. McCarroll JR, Rettig AC, Shelbourne KD: Anterior cruciate ligament injuries in the young athlete with open physes. *Am J Sports Med* 1988;16:44.
140. McLennan JG: Lessons learned after second-look arthroscopy in type III fractures of the tibial spine. *J Pediatr Orthop* 1995;15:59.
141. McManus F, Rang M, Heslin DJ: Acute dislocation of the patella in children: the natural history. *Clin Orthop* 1979;139:88.
142. Medlar RC, Mandiberg JJ, Lyne ED: Meniscectomies in children: report of long-term results (mean, 8.3 years) of 26 children. *Am J Sports Med* 1980;8:87.
143. Medler RG, Jansson KA: Arthroscopic treatment of fractures of the tibial spine. *Arthroscopy* 1994;10:292.
144. Menche DS, Phillips GI, Pitman MI, et al: Inflammatory foreign-body reaction to an arthroscopic bioabsorbable meniscal arrow repair. *Arthroscopy* 1999;15:770.
145. Merchant A, Mercer R, Hacobsen R, et al: Roentgenographic analysis of patellofemoral congruence. *J Bone Joint Surg* 1974;56-A:1391.
146. Meyers M, McKeever F: Fracture of the intercondylar eminence of the tibia. *J Bone Joint Surg* 1959;41-A:209.
147. Meyers MH: Isolated avulsion of the tibial attachment of the posterior cruciate ligament of the knee. *J Bone Joint Surg* 1975;57-A:669.
148. Meyers MH, McKeever FM: Follow-up notes: fracture of the intercondylar eminence of the tibia. *J Bone Joint Surg* 1970;52-A:1677.

149. Micheli LJ, Stanitski CL: Lateral patellar retinacular release. *Am J Sports Med* 1981;9:330.
150. Miller GK: A prospective study comparing the accuracy of the clinical diagnosis of meniscus tear with magnetic resonance imaging and its effect on clinical outcome. *Arthroscopy* 1996;12:406.
151. Miura H, Kawamura H, Arima J, et al: A new, all-inside technique for meniscus repair. *Arthroscopy* 1999;15:453.
152. Morgan CD: The "all-inside" meniscus repair. *Arthroscopy* 1991;7:120.
153. Moseley CF: A straight-line graph for leg-length discrepancies. *J Bone Joint Surg* 1977;59-A:174.
154. Mubarak S, Hargens A, Owen C, et al: The wick catheter technique for measurement of intramuscular pressure. *J Bone Joint Surg* 1976;58-A:1016.
155. Mylle J, Reynders P, Broos P: Transepiphyseal fixation of anterior cruciate avulsion in a child: report of a complication and review of the literature. *Arch Orthop Trauma Surg* 1993;112:101.
156. Neer CSI: Separation of the lower femoral epiphysis. *Am J Surg* 1960;99:756.
157. Nietosvaara Y, Aalto K, Kallio PE: Acute patellar dislocation in children: incidence and associated osteochondral fractures. *J Pediatr Orthop* 1994;14:513.
158. Noyes F, Matthews D, Moar P: The symptomatic ACL deficient knee. Part II. The results of rehabilitation, activity modification, and counseling on functional disability. *J Bone Joint Surg* 1983;65-A:163.
159. Noyes FR, Barber-Westin SD: The treatment of acute combined ruptures of the anterior cruciate and medial ligaments of the knee. *Am J Sports Med* 1995;23:380.
160. Nummi J: Fractures of the patella: a clinical study of 707 patellar fractures. *Ann Chir Gynecol Fen* 1971;60(suppl 79):1.
161. Odensten M, Gillquist J: Functional anatomy of the anterior cruciate ligament and a rationale for reconstruction. *J Bone Joint Surg* 1985;67-A:257.
162. O'Donoghue DH: Treatment of acute ligamentous injuries of the knee. *Orthop Clin North Am* 1973;4:617.
163. Oetteking B: Anomalous patellae. *Anat Rec* 1922;23:269.
164. Ogden JA: Subluxation and dislocation of the proximal tibiofibular joint. *J Bone Joint Surg* 1974;56-A:145.
165. Ogden JA: Subluxation of the proximal tibiofibular joint. *Clin Orthop* 1974;101:192.
166. Ogden JA, McCarthy SM, Jokl P: The painful bipartite patella. *J Pediatr Orthop* 1982;2:263.
167. Ogden JA, Tross RB, Murphy MJ: Fractures of the tibial tuberosity in adolescents. *J Bone Joint Surg* 1980;62-A:205.
168. Owen R: Recurrent dislocation of the superior tibio-fibular joint: a diagnostic pitfall in knee joint derangement. *J Bone Joint Surg* 1968;50-B:342.
169. Panni AS, Milano G, Tartarone M, et al: Arthroscopic treatment of malunited and nonunited avulsion fractures of the anterior tibial spine. *Arthroscopy* 1998;14:233.
170. Pape JM, Goulet JA, Hensinger RN: Compartment syndrome complicating tibial tubercle avulsion. *Clin Orthop* 1993;295:201.
171. Parker AW, Drez D Jr, Cooper JL: Anterior cruciate ligament injuries in patients with open physes [see comments]. *Am J Sports Med* 1994;22:44.
172. Perez Carro L: Avulsion of the patellar ligament with combined fracture luxation of the proximal tibial epiphysis: case report and review of the literature. *J Orthop Trauma* 1996;10:355.
173. Peterson C, Peterson H: Analysis of the incidence of injuries to the epiphyseal growth plate. *J Trauma* 1972;12:275.
174. Peterson HA: Partial growth plate arrest and its treatment. *J Pediatr Orthop* 1984;4:246.
175. Polakoff D, Bucholz R, Ogden J: Tension band wiring of displaced tibial tuberosity fractures in adolescents. *Clin Orthop Rel Res* 1985;209:161.
176. Port J, Jackson DW, Lee TQ, et al: Meniscal repair supplemented with exogenous fibrin clot and autogenous cultured marrow cells in the goat model. *Am J Sports Med* 1996;24:547.
177. Poulsen TD, Skak SV, Jensen TT: Epiphyseal fractures of the proximal tibia. *Injury* 1989;20:111.
178. Raber DA, Friederich NF, Hefti F: Discoid lateral meniscus in children: long-term follow-up after total meniscectomy. *J Bone Joint Surg* 1998;80-A:1579.
179. Rand T, Imhof H, Breitenseher M, et al: [Comparison of diagnostic sensitivity in meniscus diagnosis of MRI examinations with a 0.2 T low-field and a 1.5 T high field system] [published erratum appears in *Radiologie* 1998;38:193]. *Radiologie* 1997;37:802.
180. Rang M: *Children's Fractures*. Philadelphia, JB Lippincott Co, 1974.
181. Ray JM, Hendrix J: Incidence, mechanism of injury, and treatment of fractures of the patella in children. *J Trauma* 1992;32:464.
182. Reider B, Marshall J, Koslin B: The anterior aspect of the knee joint. *J Bone Joint Surg* 1981;64-A:351.
183. Reigel CA, Mulholland JS, Morgan CD: Arthroscopic all-inside meniscus repair. *Clin Sports Med* 1996;15:483.
184. Riseborough EJ, Barrett IR, Shapiro F: Growth disturbances following distal femoral physal fracture-separations. *J Bone Joint Surg* 1983;65-A:885.
185. Ritchie JR, Miller MD, Bents RT, et al: Meniscal repair in the goat model: the use of healing adjuncts on central tears and the role of magnetic resonance arthrography in repair evaluation. *Am J Sports Med* 1998;26:278.
186. Roberts JM, Lovell WW: Fractures of the intercondylar eminence of the tibia. *J Bone Joint Surg* 1970;52-A:827.
187. Robins AJ, Newman AP, Burks RT: Postoperative return of motion in anterior cruciate ligament and medial collateral ligament injuries: the effect of medial collateral ligament rupture location. *Am J Sports Med* 1993;21:20.
188. Rodeo SA, Warren RF: Meniscal repair using the outside-to-inside technique. *Clin Sports Med* 1996;15:469.
189. Rorabeck CH, Bobeck WP: Acute dislocation of the patella with osteochondral fracture: a review of eighteen cases. *J Bone Joint Surg* 1976;58-B:237.
190. Ross AC, Chesterman PJ: Isolated avulsion of the tibial attachment of the posterior cruciate ligament in childhood. *J Bone Joint Surg* 1986;68-B:747.
191. Runow A: The dislocating patella: etiology and prognosis in relation to generalized joint laxity and anatomy of the patellar articulation. *Acta Orthop Scand Suppl* 1983;201:5.
192. Salter RB, Czitrom A, Willis RB: Fractures involving the distal femoral epiphyseal plate. In Kennedy JC (ed): *Injury to the Adolescent Knee*. Baltimore, Williams & Wilkins Co, 1979.
193. Salter RB, Harris WR: Injuries involving the epiphyseal plate. *J Bone Joint Surg* 1963;45-A:587.
194. Sanders WE, Wilkins KE, Neidre A: Acute insufficiency of the posterior cruciate ligament in children: two case reports. *J Bone Joint Surg* 1980;62-A:129.
195. Scapinelli R: Blood supply of the human patella: its relation to ischaemic necrosis after fracture. *J Bone Joint Surg* 1967;49-B:563.
196. Schierl M, Petermann J, Trus P, et al: Anterior cruciate and medial collateral ligament injury: ACL reconstruction and functional treatment of the MCL. *Knee Surg Sports Traumatol Arthrosc* 1994;2:203.
197. Schimmer RC, Brulhart KB, Duff C, et al: Arthroscopic partial meniscectomy: a 12-year follow-up and two-step evaluation of the long-term course. *Arthroscopy* 1998;14:136.
198. Schoenbauer H: Brüche der Kniescheibe. *Ergeb Chir Orthop* 1959;42:56.
199. Schulte KR, Fu FH: Meniscal repair using the inside-to-outside technique. *Clin Sports Med* 1996;15:455.
200. Scott GA, Jolly BL, Henning CE: Combined posterior incision and arthroscopic intra-articular repair of the meniscus: an examination of factors affecting healing. *J Bone Joint Surg* 1986;68-A:847.
201. Seitz H, Marlovits S, Wielke T, et al: [Meniscus lesions after isolated anterior cruciate ligament rupture]. *Wien Klin Wochenschr* 1996;108:727.
202. Shapiro GS, Fanton GS, Dillingham MF: Reconstruction for recurrent dislocation of the proximal tibiofibular joint: a new technique. *Orthop Rev* 1993;22:1229.
203. Shelbourne K, Mesko J: Combined posterior cruciate-medial collateral ligament rupture: mechanism of injury. *J Knee Surg* 1990;3:41.
204. Shelbourne KD, Pierce RO, Ritter MA: Superior dislocation of the fibular head associated with a tibia fracture. *Clin Orthop* 1981;160:172.
205. Shelbourne KD, Porter DA: Anterior cruciate ligament-medial collateral ligament injury: nonoperative management of medial collateral ligament tears with anterior cruciate ligament reconstruction. A preliminary report. *Am J Sports Med* 1992;20:283.
206. Shelbourne KD, Whitaker HJ, McCarroll JR, et al: Anterior cruciate ligament injury: evaluation of intraarticular reconstruction of acute tears without repair. Two to seven year followup of 155 athletes. *Am J Sports Med* 1990;18:484.

207. Shelton WR, Canale ST: Fractures of the tibia through the proximal tibial epiphyseal cartilage. *J Bone Joint Surg* 1979;61-A:167.
208. Shino K, Horibe S, Nakata K, et al: Conservative treatment of isolated injuries to the posterior cruciate ligament in athletes. *J Bone Joint Surg* 1995;77-B:895.
209. Simonian PT, Metcalf MH, Larson RV: Anterior cruciate ligament injuries in the skeletally immature patient. *Am J Orthop* 1999;28:624.
210. Sinding-Larsen M: A hitherto unknown affection of the patella in children. *Acta Radiol* 1922;1:171.
211. Skie MC, Mekhail AO, Deitrich DR, et al: Operative technique for inside-out repair of the triangular fibrocartilage complex. *J Hand Surg* 1997;22-A:814.
212. Smillie I: *Injuries of the Knee Joint*. Edinburgh, E & S Livingstone, 1951.
213. Smith JB: Knee instability after fractures of the intercondylar eminence of the tibia. *J Pediatr Orthop* 1984;4:462.
214. Smith L: A concealed injury to the knee. *J Bone Joint Surg* 1962;44-A:1659.
215. Snedcor S, Wilson H: Some obstetrical injuries to the long bones. *J Bone Joint Surg* 1949;31-A:378.
216. Sommerlath KG: Results of meniscal repair and partial meniscectomy in stable knees. *Int Orthop* 1991;15:347.
217. Song EK, Lee KB: Biomechanical test comparing the load to failure of the biodegradable meniscus arrow versus meniscal suture. *Arthroscopy* 1999;15:726.
218. Soutter FE: Spina bifida and epiphyseal displacement. *J Bone Joint Surg* 1962;44-B:106.
219. Stanitski CL, Harvell JC, Fu F: Observations on acute knee hemarthrosis in children and adolescents. *J Pediatr Orthop* 1993;13:506.
220. Steiner ME, Hecker AT, Brown CH Jr, et al: Anterior cruciate ligament graft fixation: comparison of hamstring and patellar tendon grafts. *Am J Sports Med* 1994;22:240.
221. Stephens DC, Louis E, Louis DS: Traumatic separation of the distal femoral epiphyseal cartilage plate. *J Bone Joint Surg* 1974;56-A:1383.
222. Takeda Y, Ikata T, Yoshida S, et al: MRI high-signal intensity in the menisci of asymptomatic children. *J Bone Joint Surg* 1998;80-B:463.
223. Tapper EM, Hoover NW: Late results after meniscectomy. *J Bone Joint Surg* 1969;51-A:517.
224. ten Thije JH, Frima AJ: Patellar dislocation and osteochondral fractures. *Neth J Surg* 1986;38:150.
225. Tolo VT: External skeletal fixation in children's fractures. *J Pediatr Orthop* 1983;3:435.
226. Tolo VT: External fixation in multiply injured children. *Orthop Clin North Am* 1990;21:393.
227. Torg JS, Pavlov H, Morris VB: Salter-Harris type-III fracture of the medial femoral condyle occurring in the adolescent athlete. *J Bone Joint Surg* 1981;63-A:586.
228. Torisu T: Isolated avulsion fracture of the tibial attachment of the posterior cruciate ligament. *J Bone Joint Surg* 1977;59-A:68.
229. Trickey EL: Rupture of the posterior cruciate ligament of the knee. *J Bone Joint Surg* 1968;50-B:334.
230. Tsai CL, Liu TK, Liu CN, et al: [Meniscal repair with autogenous periosteum and fibrin adhesive system]. *Chung Hua I Hsueh Tsai Chih (Taipei)* 1992;49:170.
231. Vahvanen V, Aalto K: Meniscectomy in children. *Acta Orthop Scand* 1979;50:791.
232. van Trommel MF, Simonian PT, Potter HG, et al: Arthroscopic meniscal repair with fibrin clot of complete radial tears of the lateral meniscus in the avascular zone. *Arthroscopy* 1998;14:360.
233. Warren LF, Marshall JL: The supporting structures and layers on the medial side of the knee: an anatomical analysis. *J Bone Joint Surg* 1979;61-A:56.
234. Watson-Jones R: *Fractures and Joint Injuries*. New York, Churchill Livingstone, 1982.
235. Weber MJ, Janecki CJ, McLeod P, et al: Efficacy of various forms of fixation of transverse fractures of the patella. *J Bone Joint Surg* 1980;62-A:215.
236. Weinert CR Jr, Raczka R: Recurrent dislocation of the superior tibio-fibular joint: surgical stabilization by ligament reconstruction. *J Bone Joint Surg* 1986;68-A:126.
237. Weiss CB, Lundberg M, Hamberg P, et al: Non-operative treatment of meniscal tears. *J Bone Joint Surg* 1989;71-A:811.
238. Welch PH, Wynne GF Jr: Proximal tibial epiphyseal fracture-separation: case report. *J Bone Joint Surg* 1963;45-A:782.
239. Wester W, Canale ST, Dutkowsky JP, et al: Prediction of angular deformity and leg-length discrepancy after anterior cruciate ligament reconstruction in skeletally immature patients. *J Pediatr Orthop* 1994;14:516.
240. Whitesides T, Hanet T, Morimoto K, et al: Tissue pressure measurements as a determinant for the need of fasciotomy. *Clin Orthop Rel Res* 1975;113:43.
241. Wiley JJ, Baxter MP: Tibial spine fractures in children. *Clin Orthop* 1990;255:54.
242. Willis RB, Blokker C, Stoll TM, et al: Long-term follow-up of anterior tibial eminence fractures. *J Pediatr Orthop* 1993;13:361.
243. Wiss DA, Schilz JL, Zions L: Type III fractures of the tibial tubercle in adolescents. *J Orthop Trauma* 1991;5:475.
244. Wood KB, Bradley JP, Ward WT: Pes anserinus interposition in a proximal tibial physeal fracture: a case report. *Clin Orthop* 1991;264:239.
245. Wozasek GE, Moser KD, Haller H, et al: Trauma involving the proximal tibial epiphysis. *Arch Orthop Trauma Surg* 1991;110:301.
246. Wu CD, Huang SC, Liu TK: Sleeve fracture of the patella in children: a report of five cases. *Am J Sports Med* 1991;19:525.
247. Zaman TM, Roberts J, Oni OO, et al: MRI findings in simultaneous bilateral meniscal lesions. *Injury* 1997;28:303.

The Tibia

FRACTURES OF THE TIBIA AND FIBULA

Diaphyseal fractures of the tibia and fibula are common in children, being third in frequency, following fractures of the femur and both-bone forearm fractures. They occur most commonly in boys younger than 10 years. The mechanism depends on the age of the child, with more benign fractures in the younger age group. The typical tibial fracture is usually treated with external immobilization, with or without reduction, and outcomes are generally good. The relatively rare open fractures require meticulous evaluation and treatment, with usually satisfactory results.

Anatomy. The tibia has a triangular shape with an anteriorly directed apex that gradually broadens distally. The anteromedial surface of the tibia has no muscular or ligamentous attachments distal to the pes anserinus and has a mildly concave shape in the mid-diaphyseal area. This anteromedial surface is immediately subcutaneous and easily palpable. The anterolateral surface has many muscular attachments and forms the medial wall of the anterior compartment of the leg. The tibialis anterior, extensor hallucis longus, and the neurovascular bundle are adjacent to this surface. Posteriorly the tibia has a large soft tissue envelope with attachments from the semimembranosus, popliteus, soleus, tibialis posterior, and flexor digitorum longus muscles. The anterolateral and posterior aspects of the tibia are not palpable.

The fibula is subcutaneous proximally and has attachments from the lateral collateral ligament and the biceps femoris to the fibular head. At its proximal end the peroneal nerve travels anteriorly over the distal aspect of the fibular head and then divides into the superficial and deep portions. A large soft tissue envelope surrounds the fibula and is composed predominantly of muscular attachments. The lateral malleolus is the distal aspect of the fibula. It articulates with the distal tibia and talus, providing significant stability to the ankle joint. In the midleg area the tibia and fibula are connected through a thick interosseous membrane running between the lateral crest of the tibia and the anteromedial border of the fibula. The anterior tibial artery and vein course over the interosseous membrane to enter the anterior compartment of the leg.

Three ossification centers arise to form the tibia. The tibial diaphysis ossifies at 7 weeks' gestation, the proximal epiphysis appears a few months following birth, and the distal epiphysis appears in the second year of life. The fibular diaphysis ossifies at 8 weeks' gestation, while the proximal secondary center of ossification appears at 4 years and the distal epiphysis at 2 years. Closure of the proximal physis occurs between 16 and 18 years, while the distal physis closes usually at 16 years.

The blood supply to the tibia comes from three main areas: the nutrient artery, a branch of the posterior tibial artery, which provides the endosteal and medullary supply; the epiphyseal vessels; and the periosteal vessels.⁷³ The nutrient artery enters the posterior aspect of the proximal portion of the tibia and then courses proximally and distally to anastomose with the metaphyseal endosteal vessels (Fig. 42-137). The inner two-thirds of the tibial diaphysis is supplied by this nutrient artery and the outer one-third is supplied by the anastomosing periosteal vessels.⁷² Following a fracture of the tibia, the peripheral vessels are recruited to supply the majority of blood flow to the tibial cortex to revascularize necrotic areas.^{72,73,92}

There are four compartments in the leg (Fig. 42-138). The anterior compartment contains the dorsiflexors of the ankle and toes (the tibialis anterior, extensor hallucis longus, and the extensor digitorum communis), the neurovascular bundle, consisting of the anterior tibial artery and vein, and the deep peroneal nerve. The artery is assessed through palpation of the dorsalis pedis pulse, while the nerve provides sensation between the first and second toes. The lateral compartment contains the peroneus brevis and longus muscles and the superficial peroneal nerve, which provides sensation to the dorsum of the foot. The superficial posterior compartment contains the gastrocnemius, soleus, and plantaris muscles, and the sural nerve, which provides sensation to the lateral heel. The deep posterior compartment contains the posterior tibial vessels, peroneal artery, and the tibial nerve, the flexor digitorum longus, the flexor hallucis longus, the tibialis posterior, and the plantar intrinsic muscles.

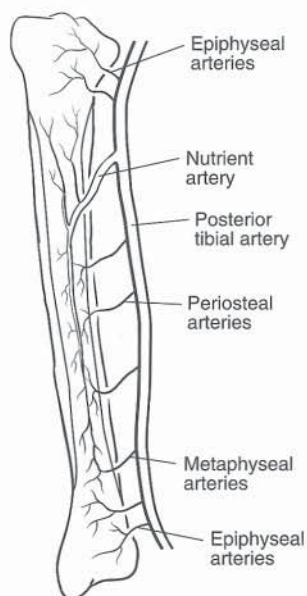


FIGURE 42-137 Blood supply to the tibial diaphysis.

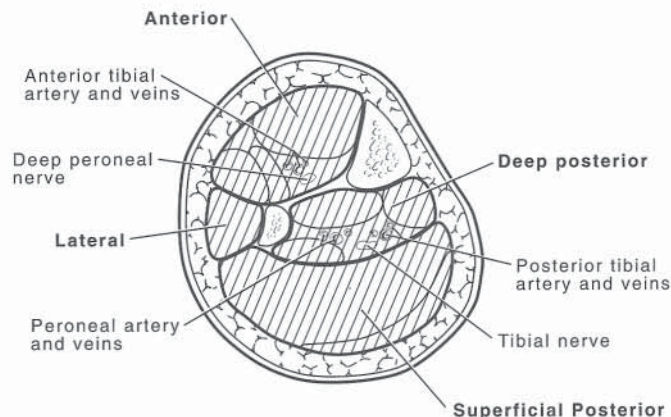


FIGURE 42-138 Cross-section of the leg demonstrating the four compartments.

Classification. Tibial and fibular fractures that do not involve the physis are best classified by the anatomic location of the fracture: proximal metaphyseal, diaphyseal, and distal metaphyseal fractures. The diaphyseal fractures are further subdivided into proximal, middle, and distal third fractures. The configuration of the fracture is defined as a torus or compression, greenstick, or complete fracture. Standard nomenclature applicable to all diaphyseal fractures should be used for classification, including the amount of angulation and displacement, the presence and degree of comminution, whether a segmental fracture is present, and whether there is an open injury, which can be defined according to the Gustilo and Anderson classification.³¹ All these factors play a role in determining the treatment and prognosis for these fractures.

Mechanism of Injury. Tibial fractures in children can be due to indirect or direct trauma, and the fractures vary with the age of the child. In the infant and child less than 4 years old, an indirect injury resulting from a fall from a height or a standing position or a bicycle spoke injury results in a spiral or oblique fracture.^{20,45,102} In the child older than 4 years, the most common injury is the result of a pedestrian accident in which the child is struck by a car, sustaining a complete, often comminuted fracture.^{20,45,86,91,102} Shannak reported 63 percent of tibial fractures to be due to road traffic accidents, with 18 percent resulting from falls.⁸⁶ Sporting activities also account for a large proportion of tibial fractures in the older age group, with Yang and Letts reporting 41 percent of their cases to be due to skiing or skating accidents, falls accounting for 40 percent of injuries, and only 16 percent of fractures due to motor vehicle accidents.¹⁰² Child abuse accounts for less than 5 percent of tibial fractures in children.⁴⁵ Open injuries in children occur in up to 8 percent of all tibial fractures and are predominantly incurred in motor vehicle accidents, which account for between 75 and 85 percent of these injuries.^{11,29,39,46,75,88}

Diagnostic Features. A good history should be obtained from the patient, parents, or other witnesses. It is important to determine whether the mechanism of injury was a direct or indirect force. Direct trauma to the leg, such as being run over by a motor vehicle, may have grave complications, since the soft tissue injury is much greater than may be apparent on the initial examination. Often the mechanism of

injury in a young child is uncertain, with the only presenting information being pain over the tibia and the inability to walk.

The physical examination begins with inspection of the leg for soft tissue injury, including evidence for an open injury. Often there is no obvious deformity of the leg, because the majority of tibial fractures are undisplaced or minimally displaced. In the young child who presents with the inability to ambulate, palpation of the thigh and leg is necessary to help define the location of the injury. In the older child who is able to point to the location of the pain, it is not necessary to deeply palpate the leg in an attempt to identify the fracture. However, it is of paramount importance to assess the condition of the soft tissue envelope surrounding the leg at the time of the initial presentation. This is especially true in the child who has sustained direct trauma to the leg in a pedestrian–motor vehicle accident or a severe twisting injury to the leg. Although compartment syndromes are relatively rare in the child with a tibial fracture, a full assessment should include evaluation of the pain elicited on passive dorsiflexion and plantar flexion of the toes, a complete neurologic examination, including a motor and sensory examination, palpation of the distal pulses, and assessment of the capillary refill time. At the completion of the physical examination, the injured leg should be splinted if transport of the patient is necessary.

Radiographic examination consists of AP and lateral radiographs of the leg to include the knee and ankle joints. Most fractures of the tibia can be seen on at least one view of the tibia; however, in the young child with a nondisplaced fracture, a radiograph of the contralateral leg is occasionally used for comparison.

Rarely are further diagnostic studies required for the patient with a tibial fracture. The instances in which further tests are needed include a suspected occult fracture, in which a technetium bone scan can detect the fracture, which appears as mildly increased uptake along the entire length of the tibia,^{51,67,70} and a pathologic fracture, in which CT may be helpful to define the extent and nature of the lesion. A skeletal survey or bone scan may be indicated if child abuse is suspected.

PROXIMAL TIBIAL METAPHYSEAL FRACTURES

Fractures of the proximal aspect of the tibia are most common in the 3- to 6-year-old age group and are usually undisplaced complete fractures or greenstick fractures.* The mechanism of injury is usually a torsional stress applied to the medial aspect of the leg or a direct blow to the lateral aspect of the extended knee. The most common fracture pattern is the greenstick fracture, in which the medial cortex is fractured while the lateral aspect of the cortex remains intact (Fig. 42–139). The fibula is often not fractured in the greenstick or minimally displaced tibial fracture, although plastic deformation may occur. In high-energy injuries involving direct trauma, the fibula is often fractured despite a relatively benign-appearing tibial fracture (Fig. 42–140). Robert and colleagues reported 13 proximal fibular fractures in association with 25 cases of proximal tibial metaphyseal fractures, of which most were due to motor vehicle acci-

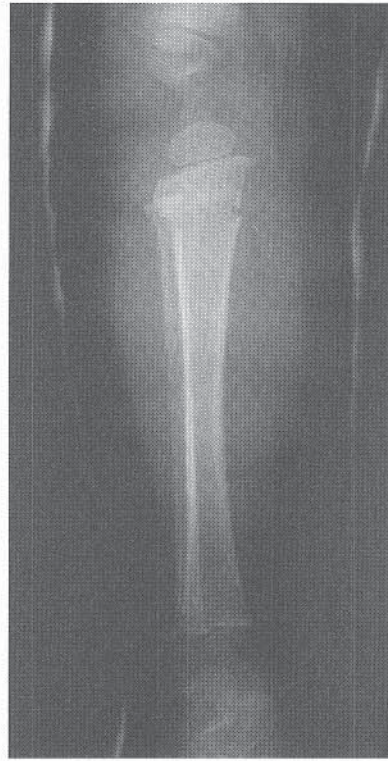


FIGURE 42–139 Proximal tibia fracture, demonstrating a greenstick injury to the lateral cortex and a medial cortical fracture.

dents.⁷⁴ Neurovascular injury is rare in the minimally displaced or greenstick proximal tibial fractures.

The second major type of proximal tibial metaphyseal fracture is much less common and involves significant high-energy trauma in the older child. This type of injury was discussed in the previous section on proximal tibial physal injuries.

The patient with the typical proximal metaphyseal fracture usually presents with pain in the proximal aspect of the tibia, minimal soft tissue swelling, and little or no clinical deformity. The radiographic examination reveals three basic fracture patterns: torus, greenstick, and complete fractures, with the majority of fractures being undisplaced. Robert and colleagues reported nine torus, ten greenstick, and six complete fractures. All torus fractures are undisplaced and approximately 50 percent of greenstick and complete fractures are displaced at the time of the initial injury.⁷⁴

The most common complication or difficulty encountered with proximal metaphyseal fractures is a valgus deformity, which develops within the first 6 months and continues to progress up to 2 years following injury (Fig. 42–141).^{*} The likelihood of developing tibial valgus following a proximal tibial metaphyseal fracture must be discussed with the parents at the time of the initial treatment and reiterated at each subsequent visit.

Several theories have been proposed to explain the development of posttraumatic tibial valgus deformity: lack of an initial accurate reduction, early weightbearing, tethering of the iliotibial tract, soft tissue interposition, tethering by the

*See references 27, 34, 44, 54, 74, 97, 106, 107.

*See references 3–6, 10, 27, 34, 38, 40, 44, 50, 54, 74, 76, 82, 97, 98, 106, 107.

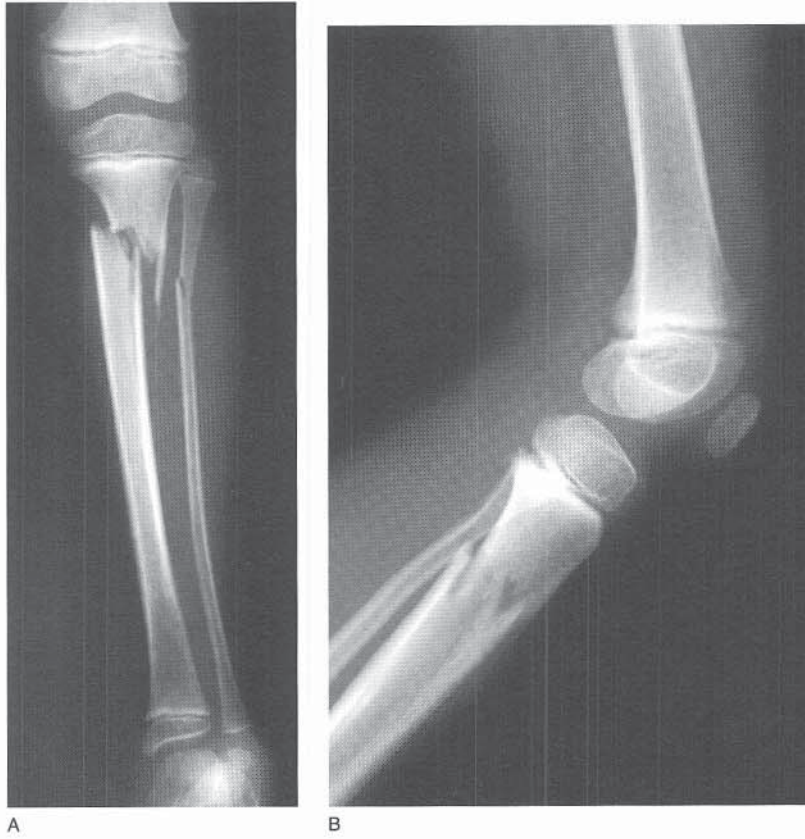


FIGURE 42-140 A and B, High-energy proximal tibia fracture in which the proximal fibula was also fractured.

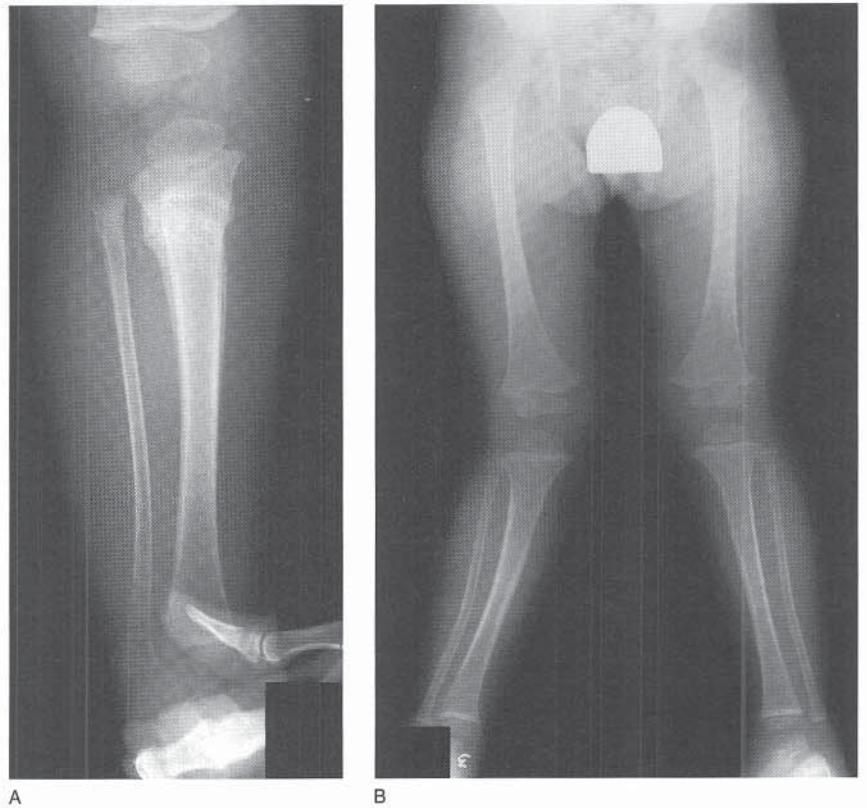


FIGURE 42-141 Valgus deformity following a proximal metaphyseal tibial fracture in a 3-year-old boy. A, Radiograph showing fracture healing at 4 weeks. B, One year later there was obvious valgus deformity of the injured leg.

intact fibula, asymmetric growth of the proximal tibial epiphysis, and injury to the lateral proximal tibial physis.

The theory of inadequate reduction was proposed early on because of the apparently innocuous nature of these fractures and the initial lack of an attempted reduction.^{2,6,71,82} However, there are reports of posttraumatic valgus developing following adequate fracture reductions, including overreductions of the tibia into varus.⁴⁴

Early weightbearing has been postulated to result in compressive forces on the lateral aspect of the tibia with distractive forces on the medial aspect, leading to increased valgus.^{69,6,82} On the other hand, valgus deformity has occurred in the nonambulatory patient following these fractures.⁵⁶

Soft tissue imbalance with tethering of the iliotibial tract on the lateral aspect of the tibia or disruption of the pes anserinus on the medial aspect has been proposed as a cause of valgus deformity.⁹⁹ Similarly, some feel that the fibula tethers the tibia and results in overgrowth on the medial side and inhibition of growth laterally.^{94,99} Soft tissue interposition has been reported by many authors, with the most common offending tissues being the pes anserinus, periosteum, and the medial collateral ligament.^{40,74,98,99} Weber reported two cases of posttraumatic tibia valgus that were explored with removal of interposed pes anserinus, followed by uncomplicated fracture healing.⁹⁹ However, others have reported valgus deformity following similar treatment.⁷⁴

Asymmetric growth of the proximal tibial epiphysis caused by premature arrest of the lateral portion has been postulated to cause tibial valgus.⁵⁸ One proposed mechanism is that a valgus moment creates a Salter-Harris type V injury of the lateral epiphysis and results in asymmetric growth between the medial and lateral aspects of the proximal tibia.^{44,62} Asymmetric growth has also been theorized to occur from an asymmetric vascular response to injury.^{16,34,106}

Treatment. The treatment of proximal tibial metaphyseal fractures is nonoperative in the majority of cases. We prefer to have the patient under conscious sedation to obtain a reduction when there is valgus deformity of the tibia following injury. An angled greenstick fracture of the proximal tibia should be broken through by bending the leg toward the angulation, then slightly overcorrecting the deformity. The leg is then placed in a long-leg cast with three-point fixation to maintain reduction. Following reduction, a true AP radiograph of the tibia should be obtained to document normal alignment, and a radiograph of the contralateral leg can be obtained for comparison. The patient is kept nonweightbearing while in the long-leg cast, and serial radiographs are obtained for the first 2 weeks to ensure maintenance of alignment. The long-leg cast should be worn for approximately 5 to 7 weeks, depending on the age of the child.

After the cast is removed the patient can be fully weightbearing and should be followed at regular intervals of approximately 3 to 6 months. The evolution of developing valgus deformity has been characterized.* The time at which deformity is greatest is between 12 and 18 months following injury, with an average maximum deformity of 18 degrees.⁹⁷ Resolution of the deformity usually occurs within 3 years

of the initial injury, with correction occurring through both the proximal and distal physes.^{3,87} Residual radiographic deformity averaging 6 degrees persists, with the knee slightly medial to the mechanical axis; however, this is usually not apparent clinically (Fig. 42–142).⁹⁷

Operative treatment is rarely indicated in these fractures. The only exception is the case in which a closed reduction fails to reduce the valgus deformity, most often because of soft tissue interposition (pes anserinus, periosteum, or the medial collateral ligament). A small medial incision is made over the fracture site, the soft tissue interposition is removed, and an anatomic reduction is performed under direct vision. We recommend suturing the torn periosteum and applying a long-leg cast. If fracture stability is a concern, Kirschner wires can be placed in a crossed fashion, but internal plate fixation is not required for these fractures.

In addition to the angular deformity following these injuries, overgrowth of the affected extremity is also seen and averages approximately 1.0 cm, with a maximum overgrowth of 1.7 cm.^{97,107} The overall outcome in these patients is universally good with respect to daily activities; however, some complain of occasional knee discomfort with strenuous athletic activities.⁹⁷

It is often difficult to persuade concerned parents that the marked valgus deformity will improve with time, since they have observed a progressive, worsening deformity up to 18 months following injury. The deformity resolves gradually over a period of years. It is important for the surgeon to avoid the temptation to perform a varus tibial osteotomy, for two main reasons. The first is that the osteotomy may initiate the same process, resulting in recurrence of the de-

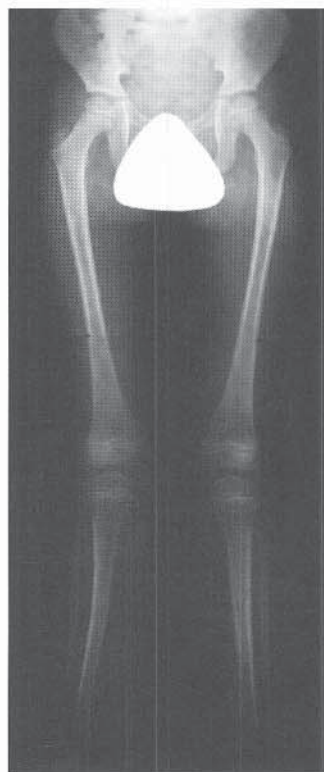

FIGURE 42–142 Spontaneous improvement of the valgus deformity of the proximal tibia 6 years after the original injury in the boy seen in Figure 42–141.

*See references 10, 16, 27, 63, 74, 87, 94, 98, 99, 106.

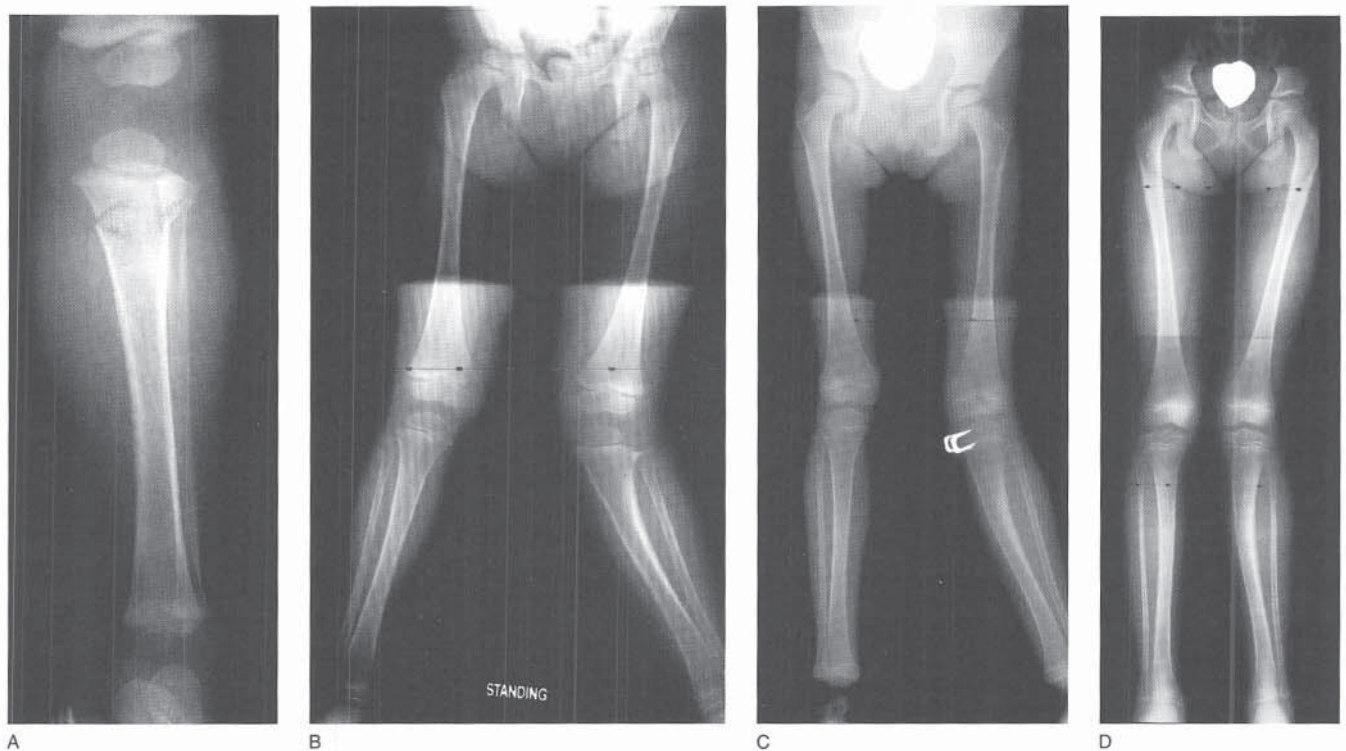


FIGURE 42-143 Epiphyseal stapling to correct residual proximal tibial valgus deformity following fracture in a 12-month-old girl. **A**, Injury film showing the proximal tibial fracture. **B**, Three years later there was continued severe valgus deformity. **C**, Medial proximal tibial physal stapling was performed. **D**, Two years after physal stapling the valgus deformity has resolved.

formity and the second is to avoid the significant incidence of compartment syndrome. Robert and colleagues reported that after four varus osteotomies performed for posttraumatic valgus deformity, valgus deformity recurred in two patients and compartment syndrome occurred in two patients.⁷⁴ Balthazar and Pappas described nine patients who developed a valgus deformity after treatment of a proximal tibial fracture.³ Six underwent a corrective osteotomy, but all did poorly, with recurrence of the valgus deformity.³ Others have reported similar results.^{10,34}

We prefer to treat residual valgus deformity if it is more than 15 to 20 degrees. This is best done near the end of growth with a well-timed medial proximal tibial epiphysiodesis (Fig. 42-143). The indications for a varus osteotomy in the younger child are limited and include severe valgus deformity (more than 20 degrees) that persists at least 3 years following injury. A fibular osteotomy and a tibial osteotomy are performed proximally and must be accompanied by a fasciotomy of the anterior and lateral compartments of the leg. We prefer to internally fix the fracture with crossed Kirschner wires. The patient wears a long-leg cast until healing occurs, usually around 6 weeks.

TIBIAL AND FIBULAR DIAPHYSEAL FRACTURES

Fractures of the diaphysis of the tibia are of two major types, depending on the age of the child and the mechanism of the injury. In the child less than 11 years old, the fracture is typically a nondisplaced or minimally displaced fracture of the tibia, often without an associated fracture of the fibula. The fracture pattern in the child less than 6 years old is

usually an oblique or spiral fracture with minimal displacement. The mechanism of injury is usually indirect trauma resulting from a fall or a twisting injury. In children ages 6 to 11 years the most common fracture is a simple transverse fracture with a fractured fibula; it usually results from direct trauma. In adolescents, fractures of the tibia are usually associated with fibular fractures, are due to higher-energy trauma, and behave as adult fractures.

Classification. Tibial fractures in children are located in the proximal third in 13 percent, in the middle third in 45 percent, and in the lower third in 59 percent.⁸⁶ Approximately 70 percent of all children's tibial fractures have an associated fibular fracture.^{9,45,86} Open fractures are rare in children, occurring in less than 5 percent of all tibial fractures,^{45,86} are associated with delayed union, and have a relatively high complication rate when compared to closed fractures.^{11,29,39,46,75,88}

Mechanism of Injury. Shannak reported on 117 children with tibial shaft fractures; the average age was 8 years and the male-female ratio was 2.7:1.⁸⁶ In a study by Karrholm and colleagues, the peak incidence of fractures in boys occurred at 3 to 4 years of age with undisplaced fractures and at 15 to 16 years of age with transverse fractures resulting from athletic and motor vehicle accidents.⁴⁵ In girls the incidence was more evenly distributed up to age 11 or 12 years of age, with a steady decline thereafter.⁴⁵ The mechanism of injury is thought to be predominantly indirect trauma; however, this varies among series, depending on the geographic location. In the northern climates, 30 to 40 percent of tibial fractures are from skiing or skating, falls

account for 30 percent of injuries, and only 15 to 25 percent of tibial fractures are from motor vehicle accidents.^{35,45,102} In more temperate climates, motor vehicle accidents can account for up to 63 percent of tibial fractures.⁸⁶ Child abuse accounts for up to 3 percent of these injuries¹⁰² and bicycle spoke injuries account for 7 to 10 percent of injuries.⁴⁵

Diagnostic Features. In the young child, very little history may be available because of an unwitnessed event or an event that was not felt to cause a fracture. The young patient may refuse to ambulate or may ambulate with a significant limp. No deformity is present, and there is little swelling; however, there is tenderness on palpation at the fracture site. In contrast, the older child with a complete tibial fracture with or without a fibular fracture will have sustained fairly significant trauma, will be unable to ambulate, and may have a significant deformity. The mechanism of injury should be elicited, especially the nature of the deforming force and whether a crush-type injury occurred. This information is important to have at the outset so that special precautions can be taken to diagnose and treat a compartment syndrome.

The physical examination in any child who presents with a tibial fracture includes assessment of the clinical deformity and a search for evidence of an open soft tissue injury.³¹ The soft tissue envelope should be palpated and assessed for the presence of an impending compartment syndrome. This examination includes passive flexion and extension of the toes, assessment of the capillary refill time, and a thorough neurologic evaluation. An associated vascular injury is rare in these injuries; however, the posterior tibial and dorsalis pedis pulses should be evaluated.

Radiographic evaluation should include AP and lateral radiographs of the tibia that include the knee and the ankle joints. Rarely are contralateral views necessary; however, the undisplaced, incomplete fracture is not always easily seen, and comparison views should be taken in this circumstance (Fig. 42–144). Stress fractures are not often seen early and are confirmed by CT, MRI, or bone scan.^{24,70}

Treatment. The majority of children's tibial fractures can be treated with cast immobilization following fracture reduction. This is most appropriate in the so-called toddler's fracture, first described by Dunbar and colleagues in 1964.²¹ This is seen in children, usually less than 6 years old, who have sustained a twisting injury of the foot while walking or running, resulting in an undisplaced oblique or spiral fracture of the tibia with an intact fibula.^{65,96} An oblique radiograph may best show the fracture. Once the diagnosis is made the limb should be immobilized in a long-leg cast with the knee bent to approximately 30 to 40 degrees of flexion to prevent significant weightbearing by the child. The cast is left on for approximately 3 to 4 weeks, depending on the age of the child and the amount of callus formation on follow-up radiographs. The cast is removed at that point and the child is allowed full weightbearing status without further immobilization. It is not necessary to obtain serial weekly radiographs in the child with a toddler's fracture. Because of the innocuous nature of the injury and the difficulty in making the diagnosis, it is often beneficial to place a child who is thought to have a toddler's fracture in a long-leg cast. Radiographs can be obtained 2 weeks following application of the cast to identify whether a fracture is pres-

ent. If no signs of callus formation are present, the cast can be removed. Fracture callus confirms the diagnosis, and immobilization should continue for an additional 4 weeks.

The second category of fracture is the displaced fracture with an intact fibula in the older child. These fractures tend to angle into a varus position secondary to the anterolateral muscle forces pulling the distal fragment medially while the fibula stabilizes the lateral aspect of the leg (Fig. 42–145). We prefer to manipulate the fracture with the child under conscious sedation in the emergency room using a mini-fluoroscopy unit to check the reduction following an initial roll of plaster cast material. The tendency for the fracture to reduce into a varus position should be countered by the surgeon during the reduction maneuver and during cast application. An initial role of plaster below the knee creating a three-point bending force is essential to obtain an adequate reduction. An acceptable fracture reduction in the child is alignment to within 5 to 10 degrees in all planes, with special emphasis on obtaining near anatomic alignment in the coronal plane. The remaining cast is then applied after the plaster cast has set and adequate fracture reduction is confirmed. The patient is nonweightbearing in the cast for 4 to 6 weeks; the cast may be changed to a short-leg walking cast depending on the age of the child and the amount of radiographic healing. Radiographs should be obtained weekly during the first 2 to 3 weeks after reduction to assess whether reduction has been maintained and to allow for manipulation, if necessary. We recommend manipulation of the fracture when varus angulation of greater than 5 degrees is present on the follow-up radiographs.

Yang and Letts reported on 95 children with isolated tibial fractures, most of which were distal third spiral fractures. Angular deformity was present initially in 76 (80 percent) fractures and recurred following a closed reduction in 32 patients, all of which drifted into varus and were posteriorly angled. Wedging of the cast with manipulation of the fracture was most successful in those patients with a single-plane deformity.¹⁰² Yang and Letts recommended close monitoring of isolated tibial fractures on a weekly basis for the first 3 weeks. Teitz and colleagues reported similar difficulties in adults with an isolated tibial fracture: 26 percent of fractures had a varus malunion, and 33 percent of these patients developed radiographic changes and pain in the affected ankle within 2 years of injury.⁹⁵

The third major category of tibial diaphyseal fractures in children is the displaced fracture in the older child with an associated fibular fracture. These injuries are usually seen in children more than 10 years old and result from direct, high-energy trauma. Because of significant instability from the associated fibular fracture, these injuries are difficult to reduce adequately in the emergency room, and general anesthesia is often a requirement for reduction. An acceptable reduction must include at least 50 percent bony apposition of the fracture fragments and less than 5 to 8 degrees of angulation in both the sagittal and coronal planes. We prefer to manipulate the fracture with the patient under conscious sedation or general anesthesia, followed by application of a provisional short-leg cast. We use plaster because we are able to manipulate the fracture as the plaster hardens. Plaster also allows the surgeon to mold the cast to protect the soft tissues and the bony prominences. These fractures are prone to residual varus in the coronal plane and posterior

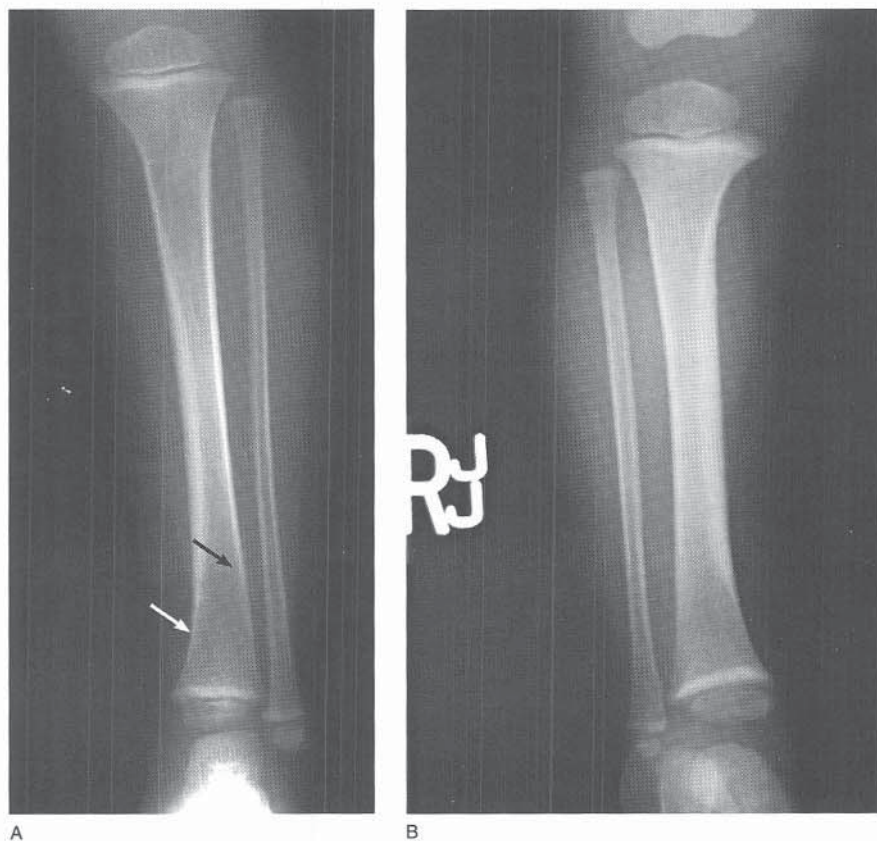


FIGURE 42-144 Diagnosis of undisplaced tibial fracture in an infant. A, Radiographic appearance. The undisplaced distal tibial fracture is difficult to identify (*arrows*). B, Contralateral radiographs used for comparison help the examiner identify the fracture in the injured leg.

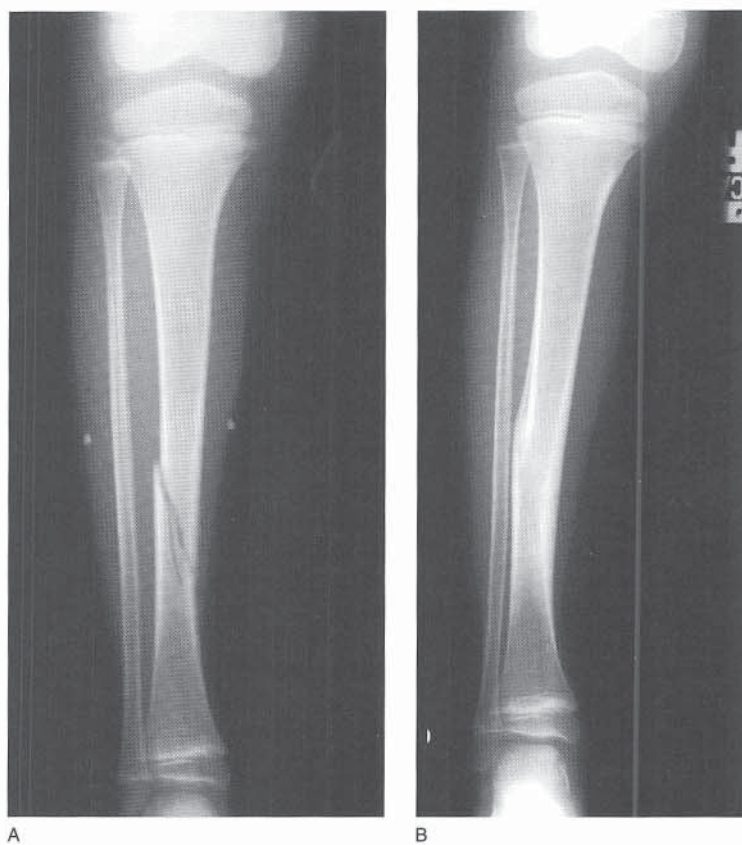


FIGURE 42-145 Isolated tibial fracture in a 5-year-old patient. A, Spiral fracture in the midportion of the tibia. The fibula is intact. B, At the time of healing there was a slight varus angulation, which often occurs secondary to the presence of an intact fibula.

angulation (apex anterior) in the sagittal plane. To correct this, a three-point mold should be placed to compensate for varus, and the ankle should be placed into 15 to 20 degrees of plantar flexion to prevent posterior angulation. Once the initial plaster cast has set, the remaining part of the cast can be applied with the knee in 30 to 45 degrees of knee flexion to provide rotational control of the fracture and to restrict the patient from weightbearing on the affected extremity. We prefer plaster material for the remainder of the cast, which will yield an excellent supracondylar mold. This can then be overwrapped with fiberglass to increase the durability of the exterior of the cast. These patients should be admitted to the hospital for soft tissue monitoring, with the leg elevated, ice packs placed at the level of the fracture, and neurovascular checks every 2 hours by the nursing staff. Requests for excess narcotic medication throughout the night should raise the suspicion that an impending compartment syndrome is present. Close radiographic monitoring on a weekly basis is required for the initial 3 weeks to ensure that the initial fracture reduction is maintained.

In the closed tibial fracture in children, operative treatment is rarely required (less than 5 percent of cases). The main indications are (1) excessive fracture instability that cannot be maintained with external immobilization, (2) loss of reduction that cannot be corrected by cast wedging during

the follow-up period, (3) significant comminution and shortening that cannot be corrected with closed treatment, and (4) a displaced fracture in a skeletally mature patient. The primary modes of operative treatment in the pediatric patient include temporary skeletal traction, percutaneous pin fixation after adequate closed reduction, open reduction with internal fixation, external fixation, flexible intramedullary rods, and locking rigid intramedullary rods.

For the patient with an unstable fracture pattern or one that is likely to be unstable in a cast, we prefer percutaneously placed crossed Kirschner wires. The wires are left outside the skin to allow easy removal in the clinic 4 weeks from the time of injury (Fig. 42-146). Cast immobilization is performed as in the closed fracture, without internal fixation. Alternatively, flexible intramedullary rods can be used for fixation; however, they require an additional anesthetic to remove, are difficult to place, and do not provide rotational fracture control (Fig. 42-147). External fixation is best used in the patient with an open fracture; however, it can be used in the highly unstable closed tibial fracture to provide fracture stability for 4 to 6 weeks, until adequate callus is present (Fig. 42-148). Removal requires a general anesthetic and is followed by application of a short-leg walking cast for an additional 3 to 4 weeks. We do not recommend plate fixation of diaphyseal fractures in children because of the significant soft tissue stripping required, the increased risk

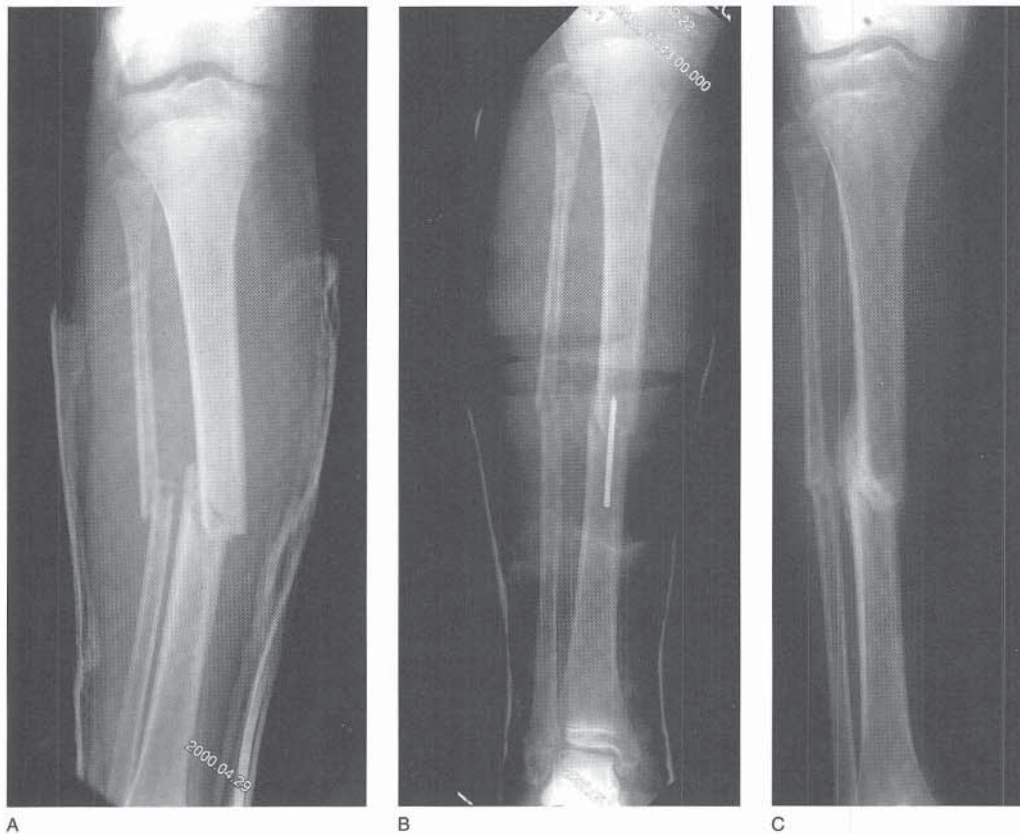
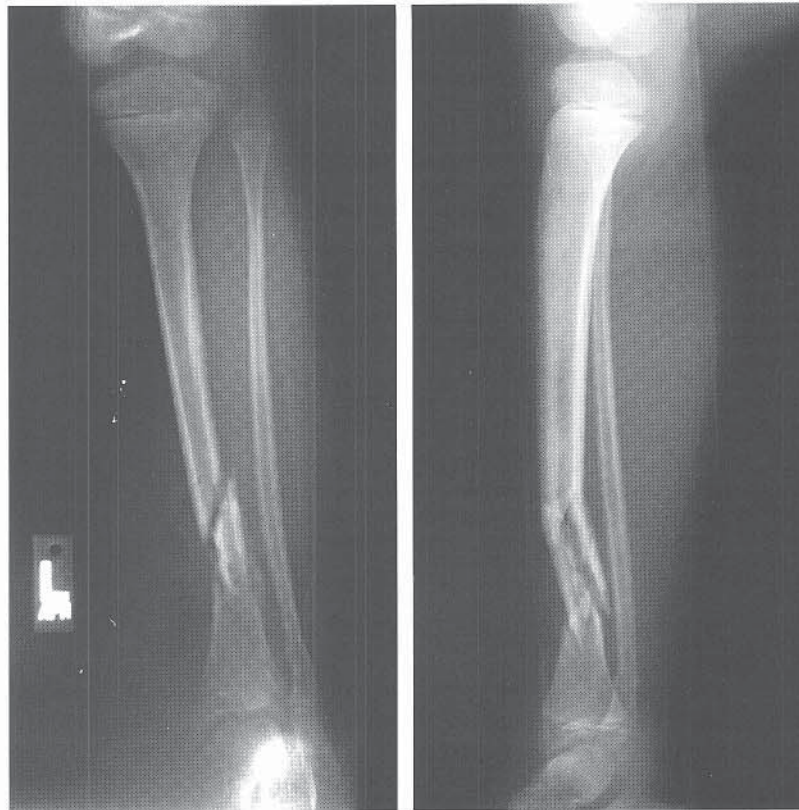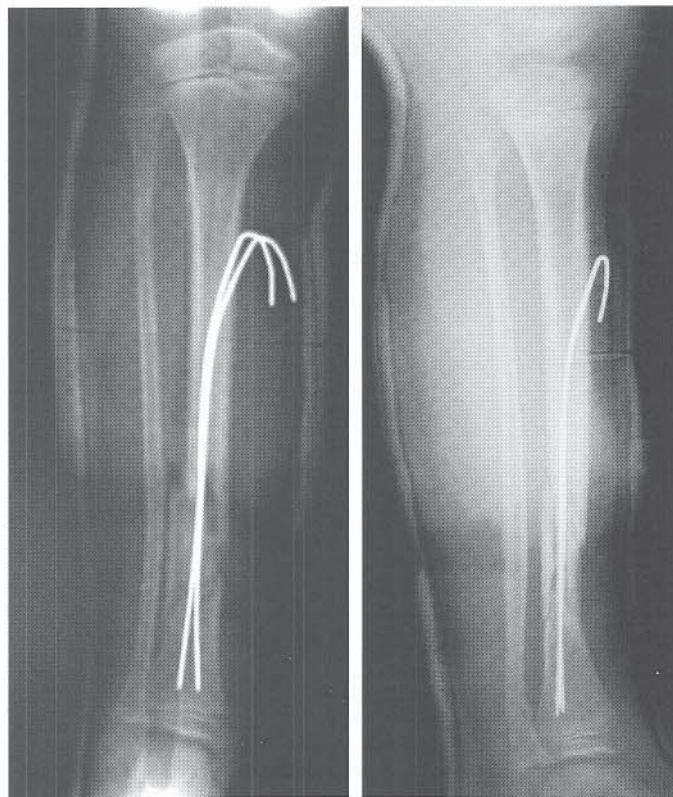


FIGURE 42-146 Percutaneous closed reduction and percutaneous pinning of a tibial fracture. **A**, Radiograph of a 15-year-old boy with a displaced midshaft tibiofibular fracture. Attempts at closed reduction and casting were unsuccessful owing to unacceptable alignment. **B**, Closed reduction with percutaneous pinning was performed. **C**, Healing with near-anatomic alignment was achieved at 4 months.



A



B

FIGURE 42-147 Flexible intermedullary nailing of a displaced tibiofibular fracture. A, Injury films demonstrating a segmental tibial fracture and a distal fibular fracture. B, Two K-wires were fashioned as intermedullary flexible rods to lend stability to the fracture. This was followed by casting.

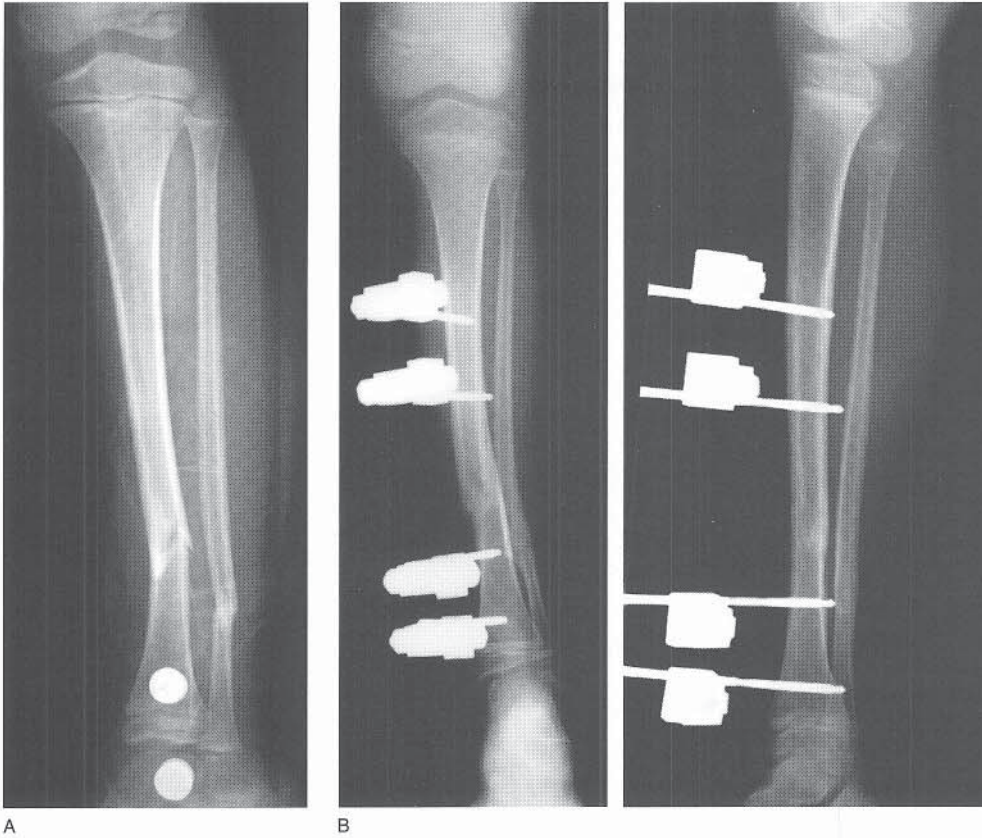


FIGURE 42-148 External fixation of an open tibiofibular fracture. A, Injury films demonstrating a distal tibiofibular fracture associated with a grade I open injury. B, Following external fixation, adequate alignment and healing occurred after 2 months.

for infection and nonunion, and the need to remove the hardware at a later date. Rigid intramedullary fixation has revolutionized the treatment of tibial fractures in adults and can be used in the older adolescent who is skeletally mature (Fig. 42-149).

OPEN TIBIAL DIAPHYSEAL FRACTURES

Although open fractures in children account for less than 5 percent of all tibial fractures, the topic has taken on considerable interest recently.* Unlike closed tibial fractures, these injuries are all due to high-energy trauma that results in significant injury to the surrounding soft tissues, which leads to delayed unions and a high risk for infection. These fractures are often associated with other fractures and with chest and abdominal trauma. The mechanism of injury in over 80 percent of open tibial fractures is an automobile striking a pedestrian, bicyclist, or motorcyclist.† The average age of the children is between 8 and 10 years, boys are injured more often than girls, by a 3:1 ratio, and the left leg is injured more often than the right.‡

Fractures should be classified according to the Gustilo and Anderson classification for open fractures:

Type I: Low-energy injury in which the wound is less than 1 cm in length and there is little soft tissue injury or wound contamination.

Type II: A moderately low-energy injury in which the wound is longer than 1 cm, there is little soft tissue injury, and the wound is mildly contaminated.

Type III: Significant soft tissue injury with wound contamination.

IIIA: Despite significant soft tissue injury the fracture can be adequately covered without using skin graft or tissue flap.

IIIB: The local soft tissue envelope cannot cover the fracture site and a skin graft or a muscle flap is required.

IIIC: An associated arterial injury is present, requiring revascularization of the limb.

In a compilation of five series, open fractures were evenly distributed among Gustilo and Anderson grades I, II, and III: 32 percent were grade I, 38 percent grade II, and 30 percent were grade III (17 percent A, 8 percent B, and 5 percent C).^{11,29,46,75,88}

Because of the high energy required to produce these injuries, associated injuries occur in up to 58 percent of patients.^{11,17} These injuries include other skeletal injuries, closed head injuries, abdominal and thoracic injuries, and maxillo-facial injuries.^{11,29,46,75} In addition, open tibial diaphyseal fractures can be associated with a mortality of up to 7 percent because of the severe head, chest, and abdominal trauma.^{29,46}

*See references 11, 17, 29, 39, 46, 75, 88, 104.

†See references 11, 17, 29, 39, 46, 75, 88, 104.

‡See references 11, 29, 39, 46, 75, 88, 104.

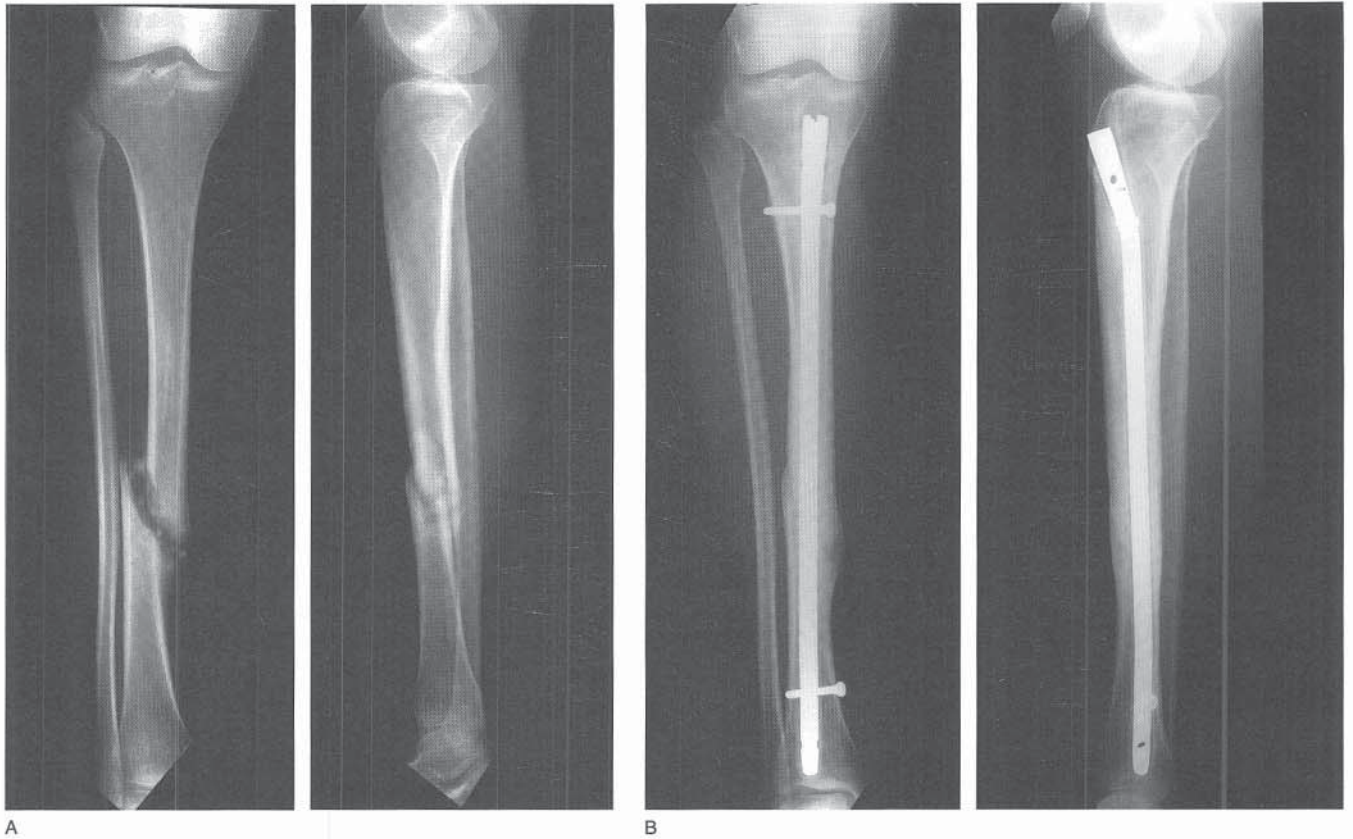


FIGURE 42-149 Rigid intramedullary fixation of an isolated fracture in an adolescent patient. **A**, Radiographs at 2 weeks following injury demonstrating an isolated midshaft tibial fracture. **B**, Three months following surgery the fracture has healed in anatomic alignment.

Treatment of open fractures in children is similar to that in adults and should follow an established protocol. The first step in management is prompt evaluation and initial classification of the soft tissue injury in the emergency room, followed by application of a Betadine-soaked dressing and splinting of the fracture. Intravenous administration of a second-generation cephalosporin (cephazolin) is indicated for all fractures, with the addition of an aminoglycoside for all grade III injuries and severely contaminated wounds, and penicillin for all farm-related accidents. The patient should then be urgently taken to the operating room for thorough irrigation and debridement of the wound, followed by stabilization of the fracture. Initial wound management entails extending grade I and smaller grade II wounds to allow thorough debridement of the bone and soft tissue. If the wound is on the medial aspect of the leg, with little soft tissue coverage, an anterolateral incision should be used to gain access to the fracture site and injured soft tissue. All incisions made by the surgeon can be closed at the initial surgery, while traumatic wounds are left open. We prefer to place nonabsorbable horizontal mattress sutures in grade I and II wounds without tying the sutures (Fig. 42-150). This will allow drainage of the leg to help prevent the accumulation of infectious material. These sutures can be closed at the bedside in 24 to 48 hours. Any bony fragment with little or no soft tissue attachment should be discarded. Any concern as to the amount of contamination of grade I or II wounds at the initial surgery warrants serial repeat irrigation and debridement every 48 hours

until adequate, viable tissue is seen. All grade III injuries require repeat irrigation and debridement. Necrotic muscle or muscle that is thought to be ischemic should be debrided. Signs of muscle viability are muscle contraction when stimulated by pinching with a forceps, arterial bleeding when incised, and the presence of a healthy pink color. Repeat irrigation of the soft tissue with 5 to 10 liters of normal saline using a pulse lavage system should then be performed.

Soft tissue management in the severely injured leg often requires coverage with the use of split- or full-thickness skin grafts, myocutaneous flaps, or free muscle flaps. We prefer to have the plastic surgeon present to assess the wound as soon as possible, and certainly by the second debridement, to determine the type of soft tissue coverage needed and the timing

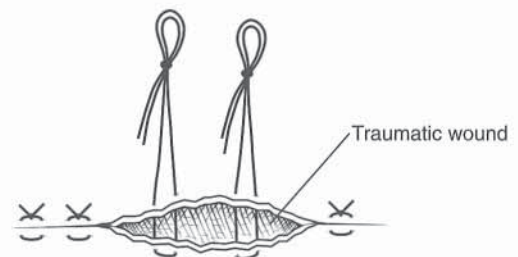


FIGURE 42-150 Suture placement in a traumatic wound at the time of the initial debridement. The sutures are not tied at the time of surgery but are left to tie at the bedside in 24 to 48 hours. In those areas in which the traumatic wound was extended, suture placement with tying is appropriate.

of this procedure. Coverage procedures should be done as soon as possible, preferably within 5 to 7 days to prevent seeding of the leg with a secondary infection.^{12,13,15,64,68,81} Most injuries in children can be treated with split-thickness skin graft or with a local flap consisting of a gastrocnemius flap in the proximal leg or a soleus flap in the middle aspect of the leg.³⁶ However, injuries in the lower aspect of the leg often require a vascularized free flap.^{55,103} Free muscle flaps are used for massive soft tissue injuries in any part of the leg. Free flaps are an excellent barrier to secondary infections and have a rich blood supply, which enhances soft tissue and bone healing.^{26,55,89,103}

The surgeon addressing large bony defects first must ensure that the native bony bed is clear of all infection. This is best done with antibiotic-impregnated polymethyl methacrylate (PMMA) beads. Although these beads are commercially available, we prefer to prepare them at the time of operation by mixing 1 g of powdered cefazolin and 2.4 g of powdered tobramycin with powdered cement. The beads are rolled by hand and strung together on a heavy Prolene suture. An alternative is to shape the cement into a solid spacer to prevent ingrowth of soft tissue into the defect site and to provide some additional stability to the tibia. When reentering this site for bone grafting, the surgeon often finds a pseudoperiosteum surrounding the cement spacer providing a confined space for the graft material. The options for treating large segmental bone defects include bone transport, vascularized fibular transfer, or autologous bone grafting. We prefer to perform autologous bone grafting of the defect site 6 to 10 weeks following soft tissue coverage, after the flap has completely epithelialized and the edges of the wound are free of all eschars. This time delay eliminates bacterial contamination of the operative site and enhances fracture healing by the autologous bone.³⁰ Christian and colleagues reported eight adult patients with grade IIB open tibial fractures with average segmental bone loss of 10 cm in whom the tibia successfully healed by 9 months with massive autologous bone grafting.¹⁴ The patient is placed prone initially so that bone can be obtained from the posterior iliac crest(s), and then is placed supine. If a free flap was used for soft tissue coverage, the plastic surgeon should be present to elevate the flap without injuring the vascular pedicle.

Patients who present with deformity, with shortening, or with chronic osteomyelitis in addition to a large bone defect are best addressed with the Ilizarov apparatus^{66,89} or other external fixation.

The two primary modes of fracture stabilization for open tibial fractures in children are long-leg cast immobilization with a window over the traumatic wound and external fixation. We prefer cast immobilization for all grade I and smaller grade II wounds that will not require repeat debridement in the operating room. A window is placed in the cast at the time of application to allow for wound access. For larger grade II and all grade III injuries, we prefer an AO external fixator with two sets of half-pins to span the fracture (Fig. 42-151). This provides excellent stability and allows for multiple debridement of the soft tissue injury without jeopardizing fracture fixation. Two external fixator pins should be placed on either side of the fracture no closer than 1 cm to the physis. The bars should then be attached to the pins and a reduction maneuver performed, after which the external fixator is tightened. When good callus is seen, the external fixator frame is removed and

a short-leg walking cast is applied. Approximately 50 percent of all open tibial fractures are treated with cast immobilization, with the rest treated with an external fixator or internal fixation and a cast.^{11,29,46,75} In 1996 Cullen and colleagues reported that 48 percent of children with open tibial fractures were treated with percutaneous pin fixation, with a shorter healing time and fewer complications than patients treated with an external fixator.¹⁷

The severe open tibial fracture with neurovascular injury is rare in children, accounting for approximately 5 percent of all tibial fractures.^{11,39,75} The distal pulses should be promptly evaluated and any vascular injury confirmed with a Doppler study. Revascularization of the leg should be performed within 4 to 6 hours of injury and should not be delayed by arteriography in the radiology suite. If the ischemia time is approaching the 4-hour limit, an arteriogram obtained with the patient on the operating room table is the best way to determine the exact location of the arterial injury. The timing of bony stabilization and revascularization also depends on the ischemia time. We prefer to stabilize the fracture by applying an external fixator so that definitive revascularization can be performed. However, if the ischemia time is approaching 4 hours, inserting temporary intraluminal shunts to provide a vascular supply to the distal leg takes precedence over fracture stabilization.⁴² Compartment pressures should be measured in any child with an open fracture that requires revascularization, and the surgeon should have a low threshold for performing four-compartment fasciotomies. Prophylactic fasciotomies should be performed in any patient with an ischemia time of 4 hours or longer.⁷⁸ The indications for amputation in the child with a severe tibial fracture are (1) vascular injury that is not reconstructible, owing to extensive soft tissue destruction, (2) associated neurologic injury that does not allow protective sensation on the sole of the foot, and (3) severe muscle injury associated with extensive bone loss. The Mangled Extremity Severity Score (MESS) can be used to help determine the need for amputation; a score greater than 7 indicates the need to perform an amputation in adults.⁴³ Although no definitive data exist in children, it is imperative to avoid sepsis from attempts at salvaging limbs that are on the borderline of survivability, as this can lead to multisystem organ failure and death.⁸

In general, open tibial fractures fare worse than closed fractures. The outcome depends on the condition of the soft tissue envelope, on healing without infection, on revascularization of the limb when arterial injury is present, and on the prompt assessment and treatment of any compartment syndrome. The incidence of infection in these open injuries is between 5 and 15 percent and depends most on the severity of the open injury and the time between injury and surgical debridement. Kreder and Armstrong reported a 14 percent incidence of infection in a series of 56 open tibial fractures in children.⁴⁶ However, a delay of more than 6 hours correlated with a 25 percent infection rate, compared to a 12 percent infection rate in children operated on less than 6 hours from the time of injury.⁴⁶ Most infections involve *Staphylococcus aureus*, which can be treated with aggressive debridement and administration of intravenous antibiotics. It is important to be aggressive in debriding all areas of necrotic soft tissue to provide the optimal chance for soft tissue healing to occur and to avoid infection. Arterial injury occurs in 2 to 10 percent of cases.^{11,29,39,46,75,88} Ap-

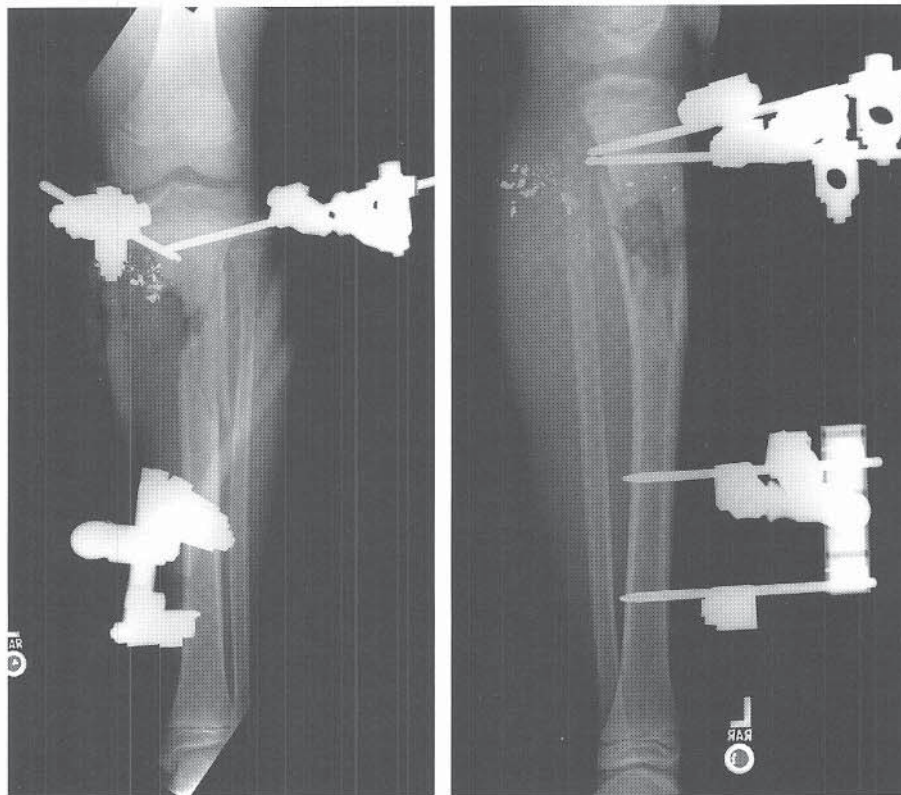
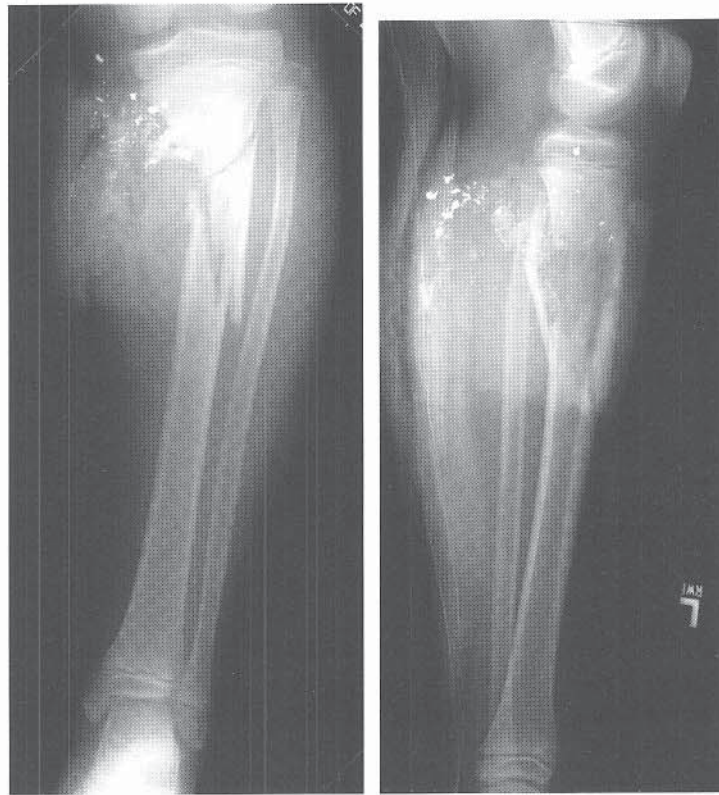


FIGURE 42-151 External fixation in a 10-year-old patient who sustained an open tibiofibular fracture from a close-range gunshot. **A**, Injury films. Note the significant bone loss and comminution of the proximal tibia. **B**, The initial treatment was placement of an external fixator utilizing two proximal half-pins placed parallel to the joint and connected to two distal half-pins in a T fashion.

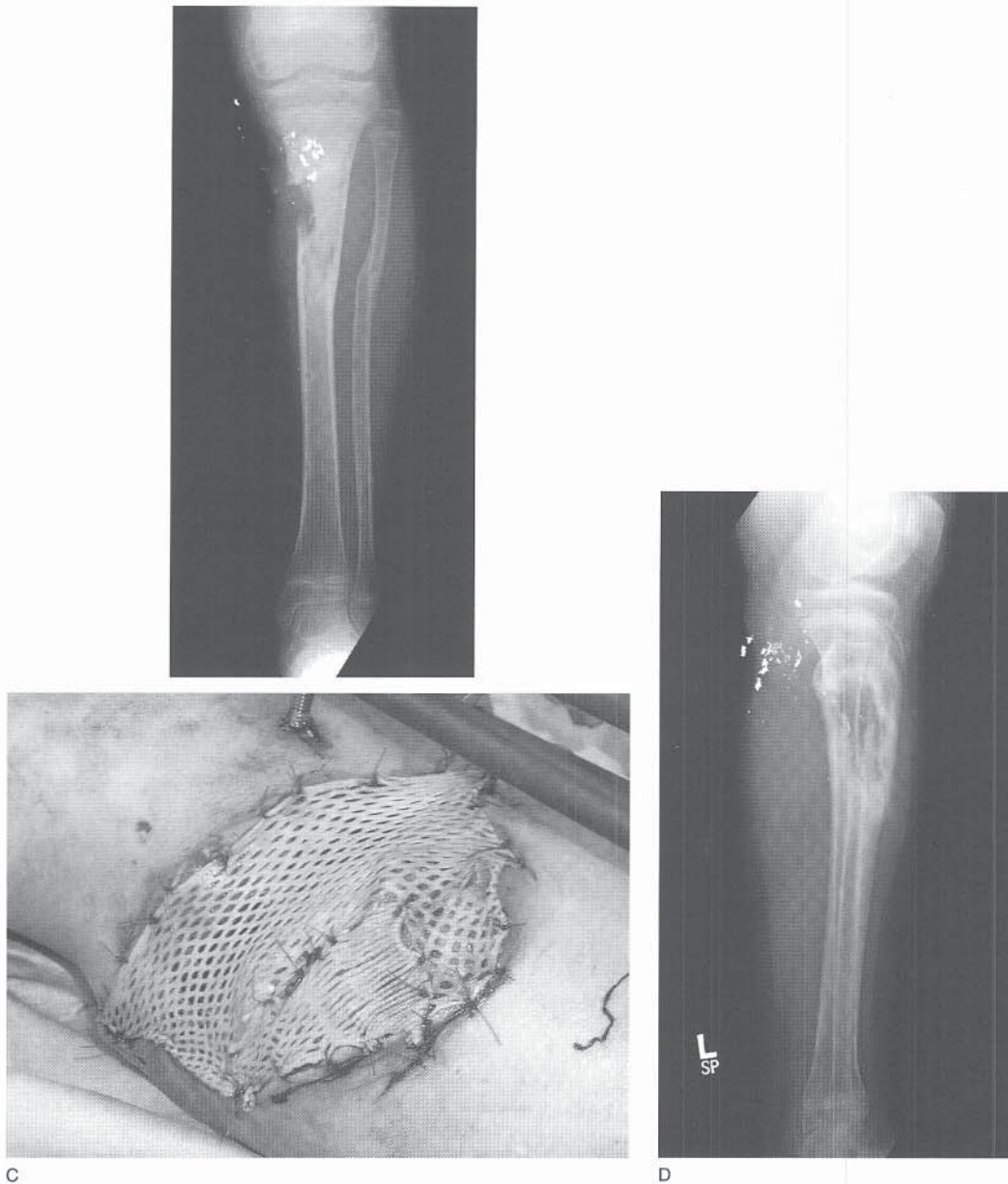


FIGURE 42-151 *Continued.* C, To allow for closure of the soft tissue defect, a shortening fibular osteotomy was performed, followed by skin grafting over the muscle. D, Healing was evident 4 months after injury. Bone grafting was not required.

proximately 50 percent of all type IIIC open injuries result in amputation, either at the initial debridement, because of the severe nature of the injury, or later, because of failed vein interposition grafting.^{11,75} Although severe soft tissue injury occurs with these fractures, compartment syndrome occurs in less than 5 percent of patients; most of these injuries are grade II open fractures.^{11,39}

The average time to union is approximately 5 to 6 months and depends on the extent of the soft tissue injury, the age of the child at the time of injury, the fracture pattern, the amount of segmental bone loss, and the presence of infection.* Buckley and colleagues reported an average healing time of 4.8 months; however, comminuted fractures healed

at 5.7 months whereas spiral and transverse fractures healed at approximately 4.2 months; fractures with segmental bone loss healed at 14.7 months; and fractures associated with infection healed in 7.1 months, compared to 4.6 months when infection was not present.¹¹ Children older than 11 years behave more like adults, with delayed fracture healing when compared with younger children.^{29,46,88} Angular deformity occurs in a small proportion of patients and can usually be corrected with manipulation of the external fixator or wedging of the cast. Overgrowth of the affected tibia by up to 3 cm occurs in approximately 8 to 10 percent of cases, most often in patients who had an initial reduction in which restoration of limb length was achieved.¹¹

Complications of Tibial Diaphyseal Fractures. The most common complications associated with tibial diaphyseal

*See references 11, 17, 29, 39, 46, 75, 88.

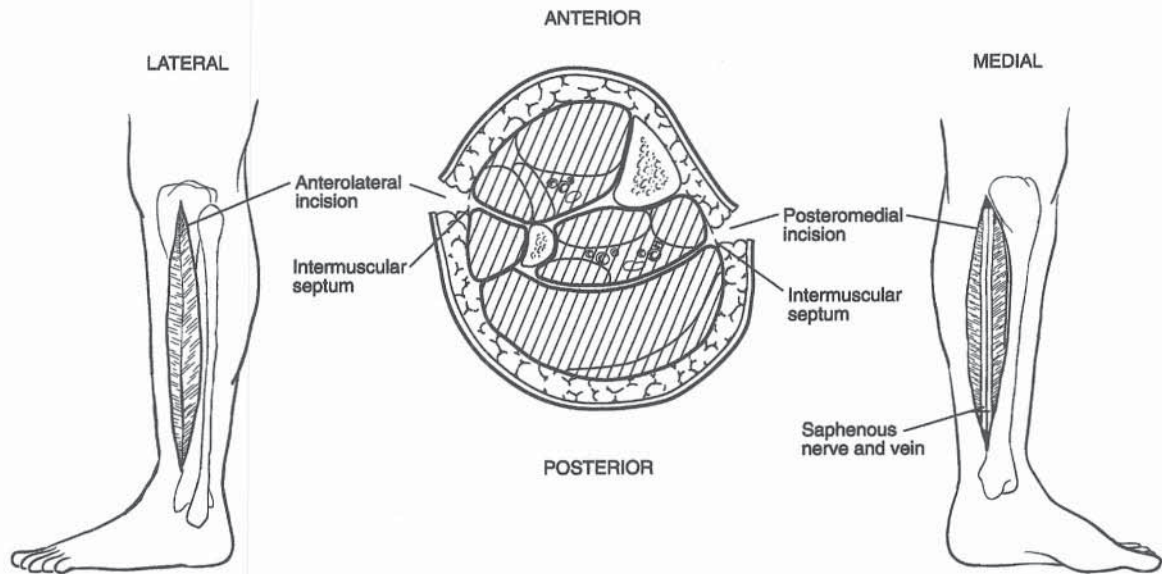


FIGURE 42-152 Four-compartment release for fasciotomy. An anterolateral and a posteromedial incision are made to provide access to all four compartments of the leg.

fractures are compartment syndrome, delayed union or nonunion, limb length discrepancy, angular deformity, malrotation, and vascular injury.

COMPARTMENT SYNDROME. Compartment syndrome is due to increased fluid in the compartments of the leg, which results in an increase in intracompartmental pressures, which inhibits venous return. Compartment syndrome can occur in any or all four compartments of the leg and is seen with tibial fractures in both adults and children.^{22,47,60} As the pressure continues to increase, the smaller arterioles and capillaries become occluded, leading to ischemia, which results in muscle and nerve injury within 6 hours.^{33,85} The diagnosis is often difficult to make, and the medical team must have a high index of suspicion and must act promptly when warning signals are present. Physical findings that warn of a compartment syndrome are pain on passive range of motion of the toes and swollen and tense compartments that are tender on palpation. When these signs and symptoms are present, prompt compartment pressure measurements and four-compartment fasciotomies should be performed. By the time that sensory and motor neurologic abnormalities or discrepancies in the distal pulses have appeared, severe ischemic changes with tissue destruction have already occurred.^{33,60,77,78} A high index of suspicion is needed in any child with pain out of proportion to the injury, any child who is unresponsive because of associated head or other injuries, and the young child who is unable to describe symptoms or cooperate with the physical examination.⁶¹ Initial management of the patient in a cast should be to split the cast, padding, and stockinette, followed by reexamination of the leg. It has been our experience that the diagnosis is made on the basis of serial histories and physical examinations and a high index of suspicion. At that stage, compartment pressure measurements are principally used to confirm the diagnosis.

Compartment pressures can be measured by a variety of techniques.* The slit catheter technique works well at the

bedside; however, we prefer to obtain compartment measurements in the operating room using the needle technique. The threshold pressures that have been used to define abnormal compartment pressures have included greater than 45 mm Hg (using the continuous infusion technique), 35 mm Hg (using the slit catheter technique), and compartment pressures within 15 to 30 mm Hg of diastolic pressure. The pressures in all four compartments should be measured and documented. Although some compartments may not have elevated pressures, all four compartments should be released. We prefer the two-incision technique (Fig. 42-152).

OTHER COMPLICATIONS. Delayed union or nonunion is relatively rare in the child with a closed tibial fracture. Predisposing factors include isolated tibial fracture without a fibular fracture, severe soft tissue injury, treatment in an external fixator, infection, a tibial fracture in an older child, or an open fracture. Delayed union in a young child without a fibular fracture is best treated with a fibular osteotomy distant to the tibial fracture, to allow compression across the fracture site. The young patient can then be recasted until healing occurs. Iliac crest bone grafting can be performed through a posterolateral approach to promote healing in an atrophic nonunion (Fig. 42-153). Stabilization of the tibia can be achieved with plate fixation in the young child and with intramedullary nailing in the older child.

Limb length discrepancy following tibial fractures is due to overgrowth of the affected tibia and is most often seen in children less than 10 years old with comminuted fractures, proximal and distal fractures, and open tibial fractures.^{11,86} The overgrowth seen in tibial fractures is less than is seen in femoral shaft fractures, with average overgrowth measuring 4 mm.⁸⁶ Although overgrowth following tibial fractures is usually not clinically apparent, discrepancies projected to be more than 2 cm require monitoring with serial scangrams to plan for an appropriately timed epiphysiodesis.

Angular deformity is most often due to inadequate reduction and stabilization or to asymmetric growth. Although remodeling occurs following angular deformity in the tibia, the potential is far less than in the femur. The greatest

*See references 53, 59, 61, 77-79, 100.

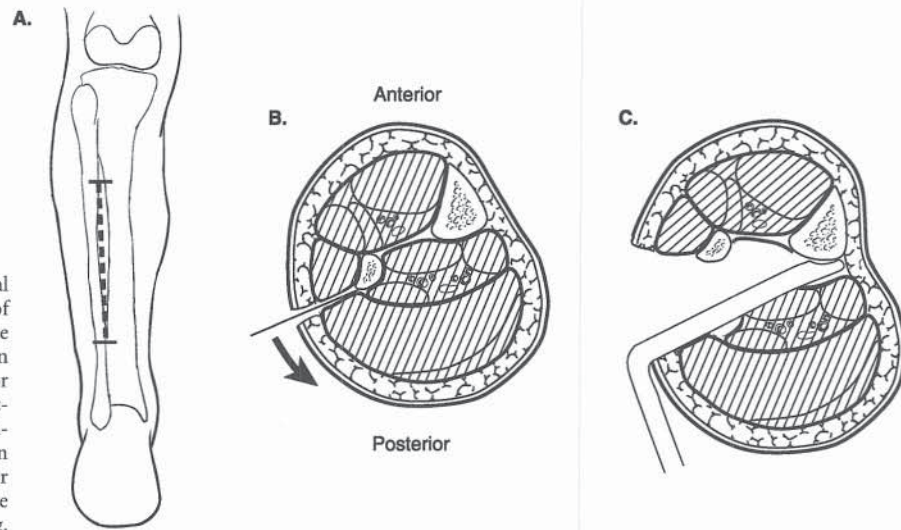


FIGURE 42-153 Approach for posterolateral bone grafting for delayed union or nonunion of the tibia. **A**, The skin incision is made over the posterolateral aspect of the leg. **B**, The dissection is carried out between the lateral and the posterior compartments down to the fibula. **C**, The dissection continues between the deep posterior compartment and the intermuscular septum between the tibia and fibula. A large Hohmann's retractor can be placed around the posterior aspect of the tibia to allow direct observation and bone grafting.

potential for tibial remodeling occurs in young children (girls less than 8 years old and boys less than 10 years old)⁹³ who have single-plane deformities, procurvatum, varus deformities, and deformities that are close to the physis.⁸⁶ Rotational deformities are rare following tibial diaphyseal fractures in children and generally do not require operative treatment when they do occur. At the time of reduction, rotational malalignment should not be accepted, since remodeling of this deformity does not generally occur, especially in the older child.^{32,86,90} Shannak reported a 3 percent incidence of rotational deformities following closed tibial fractures; all were in children more than 11 years old.⁸⁶ We prefer to observe rotational deformities of less than 30 degrees and perform a derotational tibial osteotomy at the supramalleolar level together with a fibular osteotomy when a greater than 30 degree deformity persists 2 years following injury. Proximal osteotomies are performed only if most of the deformity is in the proximal aspect of the tibia, since these corrective procedures are associated with a high incidence of compartment syndrome and neurologic injury.^{41,52,84}

Vascular injury in the child with a tibial fracture is rare and is most often seen in open tibial fractures.^{11,29,75,88} However, it can be seen in closed fractures, especially the proximal metaphyseal or diaphyseal fracture, and is associated with a high complication rate, especially when recognized late.^{1,25} A careful assessment of the distal pulses should be performed at the initial examination, following reduction, and serially thereafter. Any question or concern about a discrepancy in the peripheral pulses, including Doppler examinations, should prompt an immediate arteriogram.^{25,101} Proximal tibial metaphyseal and diaphyseal fractures are at risk for injuring the anterior tibial artery due to its proximity and tethering by the soft tissues; this artery and can also be injured with posteriorly directed distal tibial fractures. The treatment of arterial injuries should consist of stabilization of the bony anatomy, most often with an external fixator, followed by definitive arterial repair or reconstruction and four-compartment fasciotomies.

DISTAL TIBIAL METAPHYSEAL FRACTURES

These fractures are similar to proximal metaphyseal fractures in that they occur in younger patients, are generally torus

or greenstick fractures, and heal well with closed treatment in a cast. The greenstick fracture is the most common fracture pattern: the posterior cortex is fractured while the anterior cortex undergoes compression, resulting in an impaction type of fracture.

Treatment consists of cast immobilization for the nondisplaced fracture or minimally displaced fracture in a young child, or fracture reduction under conscious sedation or general anesthesia followed by cast immobilization. In the young child (less than 6 years old) with a minimally displaced fracture, a short-leg cast may be sufficient to maintain adequate alignment of the fracture for 5 to 6 weeks. In the older child or in any child with a displaced fracture, a long-leg cast with the knee flexed to 40 degrees for 3 to 4 weeks is necessary, followed by 2 to 3 weeks in a short-leg cast. It is often necessary to place the cast with the foot in 20 degrees of plantar flexion to maintain the reduction of the apex-posterior fracture.

The outcome of these fractures is usually very good, with prompt fracture healing, little residual angulation, and, unlike the proximal metaphyseal fracture, no subsequent angular deformity.

STRESS FRACTURES OF THE TIBIA

The tibia is the most common site for stress fractures in the pediatric population. Tibial stress fractures are more common in boys than in girls, and occur most often in adolescents active in sports.^{23,57}

Patients present with pain over the mid to proximal leg area but without a history of a traumatic injury. The incidence of these injuries peaks between 10 and 15 years, when children are participating in strenuous activities that place undue stress on the tibia. Stress fractures of the fibula are less common in children and occur at a younger age (3 to 8 years), often in ice skaters.^{28,37} Usually the children are not prepared or conditioned for the particular activity they are involved in. The pain is mild and aching, with onset dependent on activity level and relieved by rest.¹⁹ Usually the patient can point to the exact location of the pain, and there is point tenderness at the level of the stress fracture, without soft tissue swelling, erythema, or discoloration.

The radiographic findings are usually not present within

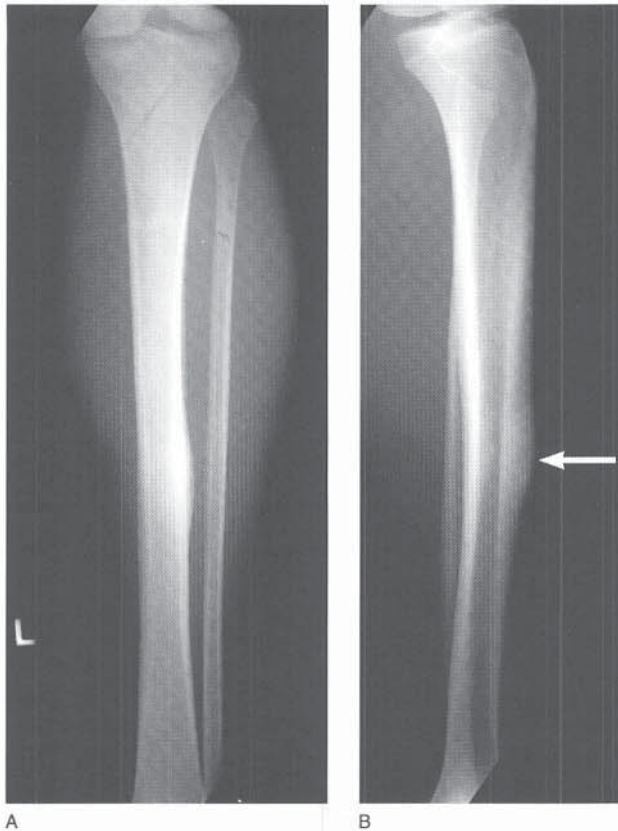


FIGURE 42-154 Tibial stress fracture. A and B, AP and lateral radiographs demonstrating periosteal thickening of the cortex consistent with a tibial stress fracture. Note the radiolucent area on the anterior cortex (arrow).

the first 2 weeks from the onset of symptoms but are seen later as thickening of the cortical surface from periosteal and endosteal bone formation.^{18,19,23,83} Three phases of radiographic changes have been defined, although these phases are rarely seen in each patient.²³ The initial findings include a radiolucent area within the cortex, followed by periosteal and endosteal new bone formation and finally the resorption of this new bone (Fig. 42-154). Occasionally a fracture line is seen during the second phase. The most common site for a tibial stress fracture is on the posteromedial or posterolateral aspect.

Tibial stress fractures are often difficult to diagnose from plain radiographs or may need to be confirmed with other tests to rule out infection, osteoid osteoma, or osteogenic sarcomas. The technetium bone scan can help the physician make the diagnosis earlier than plain radiographs when a stress fracture is suspected without confirmatory radiographic findings.^{51,70,80} The findings on bone scan consist of increased uptake in a localized area that is sharply demarcated. Other tests to confirm the diagnosis include CT and MRI. CT will demonstrate endosteal and periosteal new bone formation (Fig. 42-155), and MRI will demonstrate intracortical low-signal intensity that is continuous with the intramedullary space, with surrounding areas of decreased signal intensity on T1-weighted images.⁴⁸

The mainstay of treatment of tibial stress fractures is activity modification to decrease the continuous forces placed on the tibia. The fracture should heal completely before these activities are resumed. Cast immobilization is not required unless the patient is uncooperative with treatment. Activity restriction should continue for 6 weeks or until symptoms completely resolve, followed by gradual re-




FIGURE 42-155 CT scans of a stress fracture of the tibia. A, Sagittal image demonstrating the thickened anterior cortex with a radiolucent area in the center. B, Axial image demonstrating thickened cortices and evidence of endosteal bone formation.

sumption of activities. Stress fractures in children have universally good outcomes when treated appropriately.

IPSILATERAL FEMORAL AND TIBIAL FRACTURE (“FLOATING KNEE”)

Children involved in significant trauma can sustain a fracture of the tibia and the ipsilateral femur, the so-called floating knee. These injuries are relatively uncommon in children, are usually due to pedestrian–motor vehicle accidents, are often open fractures, and are associated with other organ system injuries. The results of treatment are generally satisfactory; however, these injuries are associated with higher complication rates than an isolated tibial or femoral fracture.

A careful assessment of the soft tissue structures to include the neurovascular system is very important. These injuries are often associated with a popliteal artery injury, and an arteriogram should be obtained whenever any concern for this injury is present.

Treatment of the floating knee in the child depends on the age and particular injury to the child, including the state of the soft tissue envelope. In general, we prefer to obtain stable fixation whenever possible so that loss of reduction

does not occur. This also provides stability for transportation. Letts and colleagues reviewed 15 patients, all of whom had been involved in a motor vehicle accident resulting in a floating knee and had undergone a variety of treatment modalities. The worst results were in those patients who had undergone nonoperative treatment of both fractures, and they recommended that one or both bones be rigidly fixed.⁴⁹ Treatment is partially dependent on the age of the child, with children younger than 7 having good results when both fractures are treated with a closed reduction and immobilization in a hip spica cast.⁷ A short period of skeletal traction is often needed in the young patient with a proximal femoral fracture. In children 7 years old or older, surgical stabilization of the femur fracture with flexible intramedullary rodding will provide stable fixation of the fracture and allow easier manipulation and cast immobilization or external fixation of the tibia, and will also prevent angular deformity and shortening (Fig. 42–156). In the adolescent, in whom the physes are closed, rigid intramedullary fixation of both the femur and the tibia through a single knee incision will allow treatment without external immobilization and will allow early weightbearing and range-of-motion exercises of the knee and ankle. Alternatively, the tibia can be placed in a cast, internally fixed, or externally stabilized.

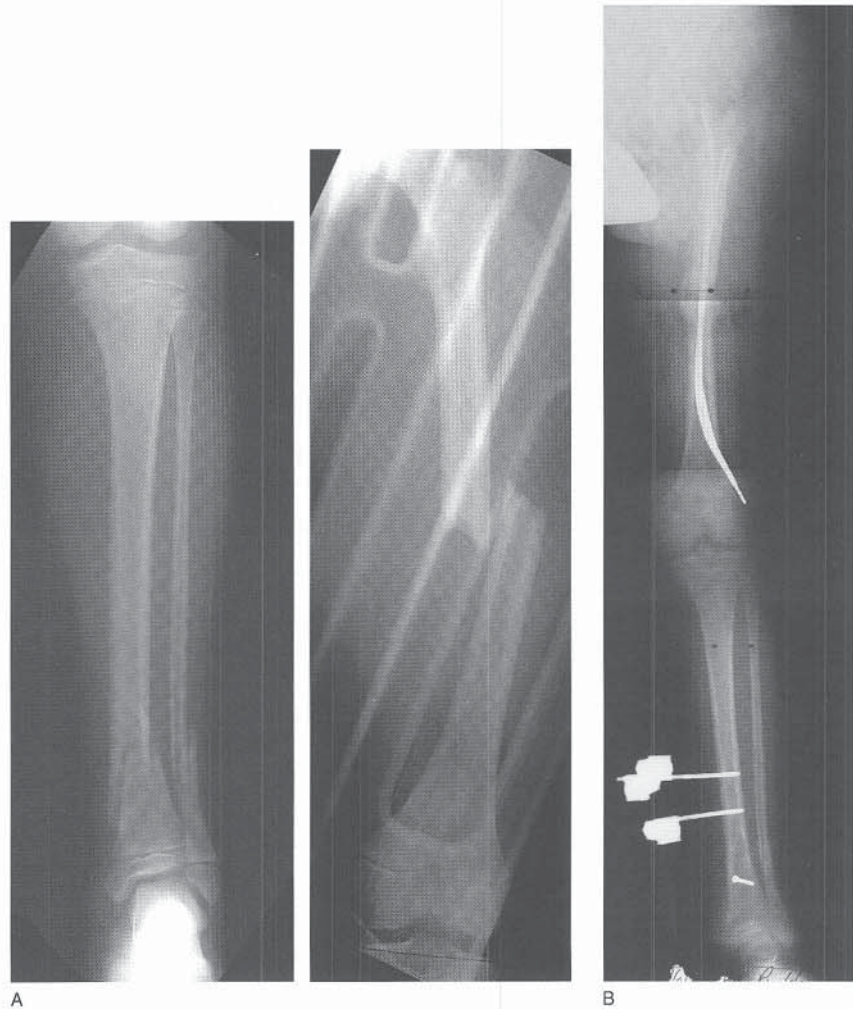


FIGURE 42–156 Treatment of a floating knee in an 11-year-old. **A**, Injury films demonstrating ipsilateral femoral and distal tibial fractures. **B**, The femoral fracture was treated with retrograde Enders nailing, while the distal tibia-fibular fracture was treated with an ankle-bridging external fixator and percutaneous screw fixation.

The results of treatment of the ipsilateral femoral and tibial fracture in children are generally satisfactory; however, complication rates can be high. Complications include malunion, premature physal closure, nonunion, pin tract infection, limb length discrepancy, and knee ligament injuries. Yasko and colleagues reported a 29 percent complication rate, with four of six patients requiring additional surgical procedures, including bone grafting for tibial nonunion and an osteotomy for angular deformity.¹⁰⁵ It is important to evaluate the stability of the knee joint at the time of the initial evaluation, since many patients return at follow-up with unrecognized ligamentous injuries.⁷

REFERENCES

The Tibia

- Allen M, Nash J, Ioannides T, et al: Major vascular surgeries associated with orthopaedic injuries to the lower limb. *Ann R Coll Surg Engl* 1984;66:101.
- Bahnon D, Lovell W: Genu valgum following fracture of the proximal tibial metaphysis in children. *Orthop Trans* 1980;4:306.
- Balthazar DA, Pappas AM: Acquired valgus deformity of the tibia in children. *J Pediatr Orthop* 1984;4:538.
- Bassey LO: Valgus deformity following proximal metaphyseal fractures in children: experiences in the African tropics. *J Trauma* 1990;30:102.
- Ben-Itzhak I, Erken EH, Malkin C: Progressive valgus deformity after juxta-epiphyseal fractures of the upper tibia in children. *Injury* 1987;18:169.
- Best TN: Valgus deformity after fracture of the upper tibia in children. *J Bone Joint Surg* 1973;55-B:222.
- Bohn WW, Durbin RA: Ipsilateral fractures of the femur and tibia in children and adolescents. *J Bone Joint Surg* 1991;73-A:429.
- Bondurant FJ, Cotler HB, Buckle R, et al: The medical and economic impact of severely injured lower extremities. *J Trauma* 1988;28:1270.
- Briggs TW, Orr MM, Lightowler CD: Isolated tibial fractures in children. *Injury* 1992;23:308.
- Brougham DI, Nicol RO: Valgus deformity after proximal tibial fractures in children. *J Bone Joint Surg* 1987;69-B:482.
- Buckley SL, Smith G, Sponseller PD, et al: Open fractures of the tibia in children. *J Bone Joint Surg* 1990;72-A:1462.
- Byrd H, Spicer T, Cierney G: Management of open tibial fractures. *Plast Reconstr Surg* 1985;76:719.
- Caudle R, Stern P: Severe open fractures of the tibia. *J Bone Joint Surg* 1987;69-A:801.
- Christian EP, Bosse MJ, Robb G: Reconstruction of large diaphyseal defects, without free fibular transfer, in Grade-IIIB tibial fractures. *J Bone Joint Surg* 1989;71-A:994.
- Cierney G, Byrd H, Jones R: Primary versus delayed tissue coverage for severe open tibial fractures: a comparison of results. *Clin Orthop* 1983;178:54.
- Cozen I: Fracture of the proximal portion of the tibia followed by valgus deformity. *Surg Gynecol Obstet* 1953;97:183.
- Cullen MC, Roy DR, Crawford AH, et al: Open fracture of the tibia in children. *J Bone Joint Surg* 1996;78-A:1039.
- Devas M: Stress fracture of the fibula. *J Bone Joint Surg* 1956;38-B:818.
- Devas M: Stress fractures in children. *J Bone Joint Surg* 1963;45-B:528.
- Drewes J, Schulte H: Brüche im Bereich des Unterschenkels bei Kindern infolge von Fahrradspeichenverletzungen. *Chirurg* 1965;36:464.
- Dunbar J, Owen H, Nogrady M, et al: Obscure tibial fracture of infants: the toddler's fracture. *J Can Assoc Radiol* 1964;25:136.
- Ellis H: Disabilities after tibial shaft fractures with special reference to Volkmann's ischemic contracture. *J Bone Joint Surg* 1957;40-B:190.
- Engh CA, Robinson RA, Milgram J: Stress fractures in children. *J Trauma* 1970;10:532.
- Fredericson M, Bergman AG, Hoffman KL, et al: Tibial stress reaction in runners: correlation of clinical symptoms and scintigraphy with a new magnetic resonance imaging grading system. *Am J Sports Med* 1995;23:472.
- Friedman RJ, Jupiter JB: Vascular injuries and closed extremity fractures in children. *Clin Orthop* 1984;188:112.
- Georgiadis GM, Behrens FF, Joyce MJ, et al: Open tibial fractures with severe soft-tissue loss: limb salvage compared with below-the-knee amputation. *J Bone Joint Surg* 1993;75-A:1431.
- Green NE: Tibia valga caused by asymmetrical overgrowth following a nondisplaced fracture of the proximal tibial metaphysis. *J Pediatr Orthop* 1983;3:235.
- Griffiths A: Fatigue fracture of the fibula in childhood. *Arch Dis Child* 1952;27:552.
- Grimard G, Naudie D, Laberge LC, et al: Open fractures of the tibia in children. *Clin Orthop* 1996;332:62.
- Gustilo R: Bone grafting in open fractures. *J Orthop Trauma* 1988;2:54.
- Gustilo RB, Anderson JT: Prevention of infection in the treatment of one thousand and twenty-five open fractures of long bones: retrospective and prospective analyses. *J Bone Joint Surg* 1976;58-A:453.
- Hansen BA, Greiff J, Bergmann F: Fractures of the tibia in children. *Acta Orthop Scand* 1976;47:448.
- Harman J, Guinn R: The recovery of skeletal muscle fibers from acute ischemia as determined by histologic and chemical methods. *Am J Pathol* 1948;25:751.
- Herring JA, Moseley C: Posttraumatic valgus deformity of the tibia. *J Pediatr Orthop* 1981;1:435.
- Hill SA: Incidence of tibial fracture in child skiers. *Br J Sports Med* 1989;23:169.
- Horowitz JH, Nichter LS, Kenney JG, et al: Lawnmower injuries in children: lower extremity reconstruction. *J Trauma* 1985;25:1138.
- Ingersoll C: Ice skater's fracture: a form of fatigue fracture. *AJR Am J Roentgenol* 1943;50:469.
- Ippolito E, Pentimalli G: Post-traumatic valgus deformity of the knee in proximal tibial metaphyseal fractures in children. *Ital J Orthop Traumatol* 1984;10:103.
- Irwin A, Gibson P, Ashcroft P: Open fractures of the tibia in children. *Injury* 1995;26:21.
- Jackson DW, Cozen L: Genu valgum as a complication of proximal tibial metaphyseal fractures in children. *J Bone Joint Surg* 1971;53-A:1571.
- Jackson JP, Waugh W: The technique and complications of upper tibial osteotomy: a review of 226 operations. *J Bone Joint Surg* 1974;56-B:236.
- Johansen K, Bandyk D, Thiele B, et al: Temporary intraluminal shunts: resolution of a management dilemma in complex vascular injuries. *J Trauma* 1982;22:395.
- Johansen K, Daines M, Howey T, et al: Objective criteria accurately predict amputation following lower extremity trauma. *J Trauma* 1990;30:568.
- Jordan SE, Alonso JE, Cook FF: The etiology of valgus angulation after metaphyseal fractures of the tibia in children. *J Pediatr Orthop* 1987;7:450.
- Karrholm J, Hansson LI, Svensson K: Incidence of tibiofibular shaft and ankle fractures in children. *J Pediatr Orthop* 1982;2:386.
- Kreder HJ, Armstrong P: A review of open tibia fractures in children. *J Pediatr Orthop* 1995;15:482.
- Leach RE, Hammond G, Stryker WS: Anterior tibial compartment syndrome: acute and chronic. *J Bone Joint Surg* 1967;49-A:451.
- Lee JK, Yao L: Stress fractures: MR imaging. *Radiology* 1988;169:217.
- Letts M, Vincent N, Gouw G: The "floating knee" in children. *J Bone Joint Surg* 1986;68-B:442.
- Mahnken RF, Yngve DA: Valgus deformity following fracture of the tibial metaphysis. *Orthopedics* 1988;11:1317.
- Matin P: The appearance of bone scans following fractures, including immediate and long-term studies. *J Nucl Med* 1979;20:1227.
- Matsen FA III, Staheli LT: Neurovascular complications following tibial osteotomy in children: a case report. *Clin Orthop* 1975;110:210.
- Matsen FA III, Winquist RA, Krugmire RB Jr: Diagnosis and management of compartmental syndromes. *J Bone Joint Surg* 1980;62-A:286.
- McCarthy JJ, Kim DH, Eilert RE: Posttraumatic genu valgum: operative versus nonoperative treatment. *J Pediatr Orthop* 1998;18:518.
- Meland NB, Fisher J, Irons GB, et al: Experience with 80 rectus abdominis free-tissue transfers. *Plast Reconstr Surg* 1989;83:481.
- Mellick LB, Reesor K: Spiral tibial fractures of children: a commonly accidental spiral long bone fracture. *Am J Emerg Med* 1990;8:234.
- Micheli LJ, Gerbino PG: Etiologic assessment of stress fractures of the lower extremity in young athletes. *Orthop Trans* 1980;41:51.
- Morton K, Starr D: Closure of the anterior portion of the upper tibial epiphysis as a complication of tibial-shaft fracture. *J Bone Joint Surg* 1964;46-A:570.

59. Mubarak SJ: A practical approach to compartmental syndromes. Part II. Diagnosis. Instr Course Lect 1983;32:92.
60. Mubarak SJ, Carroll NC: Volkman's contracture in children: aetiology and prevention. J Bone Joint Surg 1979;61-B:285.
61. Mubarak SJ, Owen CA, Hargens AR, et al: Acute compartment syndromes: diagnosis and treatment with the aid of the wick catheter. J Bone Joint Surg 1978;60-A:1091.
62. Ogden J: Skeletal Injury in the Child. Philadelphia, Lea & Febiger, 1982.
63. Ogden J, Ogden D, Pugh L, et al: Tibia valga after proximal metaphyseal fractures in childhood: a normal physiological response. J Pediatr Orthop 1995;15:489.
64. Osterman P, Henry S, Seligson D: Timing of wound closure in severe compound fractures. Orthopedics 1994;17:397.
65. Oudjhane K, Newman B, Oh KS, et al: Occult fractures in preschool children. J Trauma 1988;28:858.
66. Paley D, Catagni MA, Argani F, et al: Ilizarov treatment of tibial nonunions with bone loss. Clin Orthop 1989;146.
67. Park HM, Kernek CB, Robb JA: Early scintigraphic findings of occult femoral and tibial fractures in infants. Clin Nucl Med 1988;13:271.
68. Patzakis MJ, Wilkins J: Factors influencing infection rate in open fracture wounds. Clin Orthop 1989;243:36.
69. Pollen A: Fractures and Dislocations in Children. Edinburgh, Churchill Livingstone, 1973.
70. Prather JL, Nusynowitz ML, Snowdy HA, et al: Scintigraphic findings in stress fractures. J Bone Joint Surg 1977;59-A:869.
71. Rang M: Children's Fractures. Philadelphia, JB Lippincott Co, 1974.
72. Rhinelander F: Blood supply to developing, mature, and healing bone. In Sumner-Smith G (ed): Bone in Clinical Orthopaedics, p 81. Philadelphia, WB Saunders Co, 1982.
73. Rhinelander FW: Tibial blood supply in relation to fracture healing. Clin Orthop 1974;105:34.
74. Robert M, Khouri N, Carlioz H, et al: Fractures of the proximal tibial metaphysis in children: review of a series of 25 cases. J Pediatr Orthop 1987;7:444.
75. Robertson P, Karol LA, Rab GT: Open fractures of the tibia and femur in children. J Pediatr Orthop 1996;16:621.
76. Rooker G, Salter R: Prevention of valgus deformity following fracture of the proximal metaphysis of the tibia in children. J Bone Joint Surg 1980;62-B:527.
77. Rorabeck CH: A practical approach to compartmental syndrome. Part III. Management. Instr Course Lect 1983;32:102.
78. Rorabeck CH: The treatment of compartment syndromes of the leg. J Bone Joint Surg 1984;66-B:93.
79. Rorabeck CH, Macnab L: Anterior tibial-compartment syndrome complicating fractures of the shaft of the tibia. J Bone Joint Surg 1976;58-A:549.
80. Roub LW, Gumerman LW, Hanley EN Jr, et al: Bone stress: a radionuclide imaging perspective. Radiology 1979;132:431.
81. Russel G, Henderson R, Arnett G: Primary or delayed closure for open tibial fractures. J Bone Joint Surg 1990;72-B:125.
82. Salter RB, Best T: The pathogenesis and prevention of valgus deformity following fractures of the proximal metaphyseal region of the tibia in children. J Bone Joint Surg 1973;55-A:1324.
83. Savoca CJ: Stress fractures: a classification of the earliest radiographic signs. Radiology 1971;100:519.
84. Schrock RD Jr: Peroneal nerve palsy following derotation osteotomies for tibial torsion. Clin Orthop 1969;62:172.
85. Scully R, Shannon J, Dickerson J: Factors involved in recovery from experimental skeletal ischemia in dogs. Am J Pathol 1961;39:721.
86. Shannak AO: Tibial fractures in children: follow-up study. J Pediatr Orthop 1988;8:306.
87. Skak SV, Jensen TT, Poulsen TD: Fracture of the proximal metaphysis of the tibia in children. Injury 1987;18:149.
88. Song KM, Sangeorzan B, Benirschke S, et al: Open fractures of the tibia in children. J Pediatr Orthop 1996;16:635.
89. Spiro SA, Oppenheim W, Boss WK, et al: Reconstruction of the lower extremity after grade III distal tibial injuries using combined microsurgical free tissue transfer and bone transport by distraction osteosynthesis. Ann Plast Surg 1993;30:97.
90. Stanford TC, Rodriguez RP Jr, Hayes JT: Tibial-shaft fractures in adults and children. JAMA 1966;195:1111.
91. Steinert V, Bennek J: [Tibial fractures in children]. Zentralbl Chir 1966;91:1387.
92. Strachan RK, McCarthy I, Fleming R, et al: The role of the tibial nutrient artery: microsphere estimation of blood flow in the osteotomized canine tibia. J Bone Joint Surg 1990;72-B:391.
93. Swaan JW, Oppers VM: Crural fractures in children: a study of the incidence of changes of the axial position and of enhanced longitudinal growth of the tibia after the healing of crural fractures. Arch Chir Neerl 1971;23:259.
94. Taylor S: Tibial overgrowth: a cause of genu valgum. J Bone Joint Surg 1963;45-A:659.
95. Teitz CC, Carter DR, Frankel VH: Problems associated with tibial fractures with intact fibulae. J Bone Joint Surg 1980;62-A:770.
96. Tenenbein M, Reed MH, Black GB: The toddler's fracture revisited [see comments]. Am J Emerg Med 1990;8:208.
97. Tuten HR, Keeler KA, Gabos PG, et al: Posttraumatic tibia valga in children: a long-term follow-up note. J Bone Joint Surg 1999;81-A:799.
98. Visser JD, Veldhuizen AG: Valgus deformity after fracture of the proximal tibial metaphysis in childhood. Acta Orthop Scand 1982;53:663.
99. Weber BG: Fibrous interposition causing valgus deformity after fracture of the upper tibial metaphysis in children. J Bone Joint Surg 1977;59-B:290.
100. Whitesides TE, Hancy TC, Morimoto K, et al: Tissue pressure measurements as a determinant for the need of fasciotomy. Clin Orthop 1975;113:43.
101. Wolma FJ, Larriue AJ, Alsop GC: Arterial injuries of the legs associated with fractures and dislocations. Am J Surg 1980;140:806.
102. Yang JP, Letts RM: Isolated fractures of the tibia with intact fibula in children: a review of 95 patients. J Pediatr Orthop 1997;17:347.
103. Yaremchuk MJ: Acute management of severe soft-tissue damage accompanying open fractures of the lower extremity. Clin Plast Surg 1986;13:621.
104. Yasko A, Wilber JH: Open tibial fractures in children. Orthop Trans 1989;13:547.
105. Yasko AW, Thompson GH, Wilber JH: Ipsilateral fractures of the femur and tibia in children. Presented at a combined meeting of Pediatric Orthopaedic Society of North America and the European Pediatric Orthopaedic Societies, Montreal, 1990.
106. Zions LE, Harcke HT, Brooks KM, et al: Posttraumatic tibia valga: a case demonstrating asymmetric activity at the proximal growth plate on technetium bone scan. J Pediatr Orthop 1987;7:458.
107. Zions LE, MacEwen GD: Spontaneous improvement of posttraumatic tibia valga. J Bone Joint Surg 1986;68-A:680.

The Ankle

ANATOMY

The distal tibial epiphysis ossifies between 6 and 12 months of age while the medial malleolus appears at 7 years in girls and 8 years in boys. The medial malleolus usually ossifies as a downward extension of the distal tibial ossific nucleus, although it may develop as a separate center of ossification and can be mistaken for a fracture line. The distal aspect of the tibia is completely ossified by 14 to 15 years of age and fuses with the diaphysis at 18 years of age. The physis closes beginning centrally, then medially, and continuing laterally, with the entire process lasting approximately 18 months. This is responsible for the fracture patterns seen in the distal tibia prior to complete physal closure leading to physal fractures of the lateral distal tibial physis without injury to the medial side. The distal tibial physis contributes 45 percent of the growth of the tibia. The distal fibula ossifies during the second year of life, usually between the ages of 18 and 20 months. This physis usually closes 12 to 24 months later than the distal tibia.

The ankle joint is composed of the dome of the talus and the distal aspect of the tibia and fibula, which are joined together by the syndesmosis composed of three distinct ligaments: the inferior transverse ligament and the anterior and posterior inferior tibiofibular ligaments (Fig. 42–157).

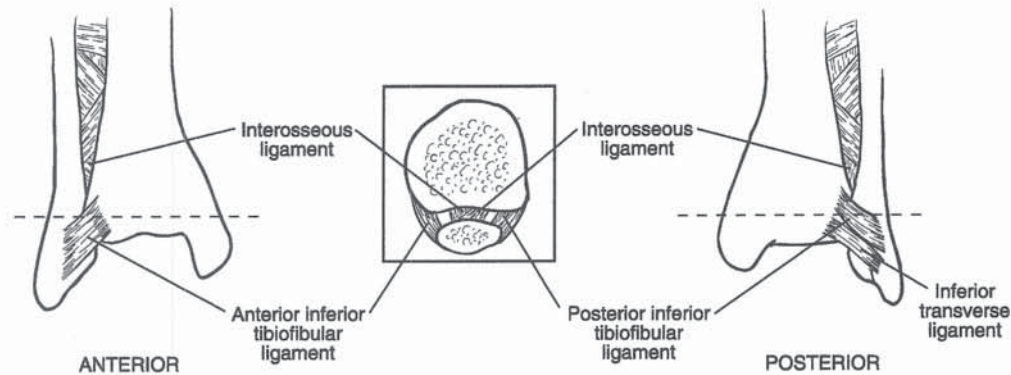


FIGURE 42-157 The ankle syndesmosis, anterior and posterior views. The syndesmosis is composed of the interosseous ligament, the anterior and posterior inferior tibiofibular ligaments, and the inferior transverse ligament posteriorly.

Ligamentous structures stabilize the distal tibia-fibula complex to the talus and foot. On the medial aspect of the ankle the medial malleolus is attached to the foot by the deltoid ligament, which has a deep component attaching to the talus (the anterior tibiotalar ligament) and a superficial component that is composed of three distinct ligaments and named according to the anatomy that they span—the calcaneotibial, tibionavicular, and posterior talotibial ligaments (Fig. 42-158). The lateral aspect of the ankle is stabilized by three ligaments that originate at the lateral malleolus and insert onto the talus (anterior and posterior talofibular ligaments) and the calcaneus (calcaneofibular ligament). The attachment of these ligaments to the distal tibia and fibula occurs at the epiphysis, distal to the physis. Since ligamentous structures are stronger than the physis in the child, avulsion-type injuries are common.

For the purposes of classifying injuries to the distal tibia, four major headings will be used in the discussion of injuries and their treatment:

Ankle fractures:

- Supination-inversion
- Supination-plantar flexion
- Supination-external rotation
- Pronation-eversion-external rotation
- Axial compression
- Other physeal injuries
- Tillaux fractures
- Triplane fractures
- Distal fibular fractures

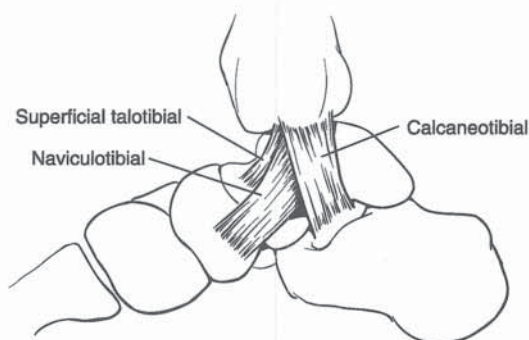


FIGURE 42-158 The medial collateral ligamentous complex of the ankle.

ANKLE FRACTURES

Fractures of the distal tibia and fibula are relatively common, being second only to distal radius fractures as the most common physeal fractures in children.¹⁶⁵ This is due to the horizontal orientation of the physis and the strong ligamentous attachments distal to the physis. Fractures of the distal tibia and fibula occur most commonly between 10 and 15 years of age and are more common in boys than in girls. These physeal injuries more often require operative intervention than fractures of the distal radius and are also more likely to be associated with subsequent premature growth arrest.

Classification. The Salter-Harris classification for physeal fractures is well-known, easy to use, describes the anatomic characteristics of distal tibial injuries, provides treatment guidelines, and best prognosticates the status of the growth plate. However, the complexity of the ankle anatomy and its ligamentous attachments, together with various deforming forces at the time of ankle injury, makes it important to use a classification scheme that provides information as to the mechanism of injury. This is most important in predicting the likelihood of achieving a closed reduction and in determining the type of maneuver necessary to achieve reduction. The first mechanistic classification of ankle fractures in children was proposed by Bishop, who modified the adult Ashhurst-Bromer classification.¹⁶ Carothers and Crenshaw further modified the classification to include the direction of the injuring force.³³ The most commonly used ankle classification in adults was described by Lauge-Hansen and is based on three characteristics: the position of the foot at the time of injury, the axial load at the time of injury, and the direction of the deforming force.¹¹²⁻¹¹⁶ However, this classification does not specifically apply to children since it does not take into account the presence of the distal physis of the tibia and fibula. Therefore, Dias and Tachdjian modified the Lauge-Hansen classification to include the Salter-Harris classification so that it applies to injuries in children.^{54,55} The original classification defined four types of fractures, each with a two-part name: the first term refers to the position of the foot at the time of injury and the second to the direction of the deforming force, with grades of injury described in increasing severity (Fig. 42-159). Subsequently the last four types of fractures were added: the juvenile Tillaux, triplane, axial compression, and miscellane-

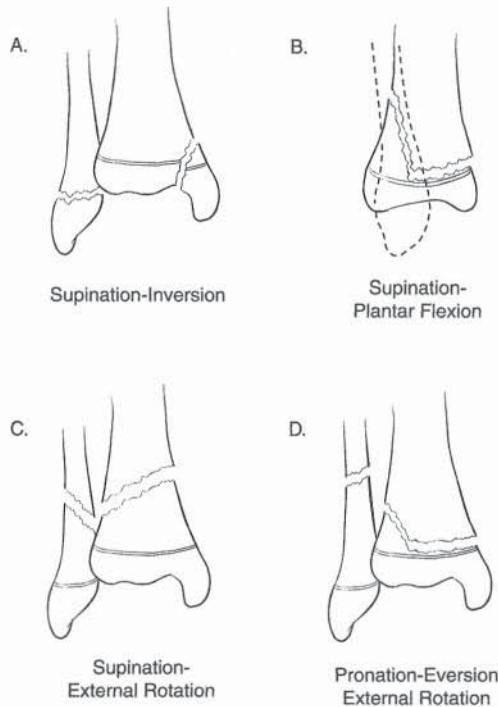


FIGURE 42-159 A to D, The Dias-Tachdjian modification of the Lauge-Hansen classification for ankle fractures in children.

ous physal injuries.²⁰⁹ To fully utilize this classification, the following characteristics should be defined: the Salter-Harris type of injury, the direction of the fracture line, the direction of displacement of the epiphyseal-metaphyseal fracture fragment, and the relation of this fracture fragment to localized swelling and tenderness.

SUPINATION-INVERSION INJURY. This injury occurs with an inversion deforming force applied to the foot in the supinated position.

Grade I injuries occur when traction by the lateral ligaments produces a Salter-Harris type I or II fracture of the distal fibular physis. The fracture may occasionally be at the tip of the lateral malleolus, and rarely, injury of the lateral ligaments occurs. Displacement of the distal fibular epiphysis is minimal, and injury to the distal fibular physis may go undiagnosed because of this minimal displacement.

Grade II injuries are a continuation of the grade I injury in which the talus is further pushed medially against the medial malleolus and tilts the talus up into the medial half of the distal end of the tibia (Fig. 42-160). This results in a Salter-Harris type III or IV injury. The type III fracture extends from the articular surface to the zone of the hypertrophic cartilage cells of the physis, exiting medially. In the type IV fracture the epiphysis, physis, and a portion of the metaphysis are completely split, with upward displacement of the medial fragment (Fig. 42-161). A Salter-Harris type II fracture of the distal tibia occasionally occurs in which the distal tibial fracture involves the lateral physis and exits medially through a metaphyseal fracture. Rarely, the fracture extends through the distal tibial physis only, resulting in a Salter-Harris type I injury.

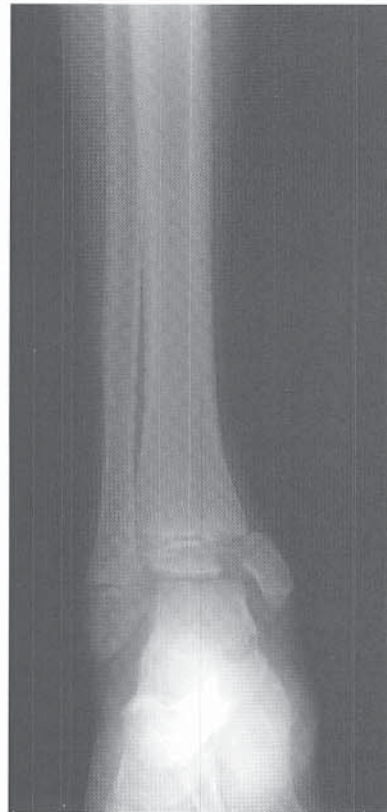

FIGURE 42-160 Grade II supination-inversion injury pattern in a 12-year-old who sustained a distal tibial Salter-Harris type III fracture and a displaced Salter-Harris type I distal fibular fracture as a result of an inversion injury of the ankle.

SUPINATION-PLANTAR FLEXION INJURY. This injury occurs with the foot fixed in full supination while a plantar flexion force is exerted on the ankle (Fig. 42-162).

The most common fracture pattern is one in which a Salter-Harris type II physal injury of the distal tibial physis occurs with posterior displacement of the epiphyseal-metaphyseal fracture fragment and no fracture of the fibula. The metaphyseal fragment of the tibia is posterior and is best seen on the lateral radiograph (Fig. 42-163).

SUPINATION-LATERAL ROTATION FRACTURE. This injury occurs with the foot fixed in full supination while a lateral rotation force is exerted on the ankle (Fig. 42-164).

Grade I injuries result in a Salter-Harris type II fracture of the distal tibial epiphysis with a posterior metaphyseal-diaphyseal fragment and posterior displacement of the fracture. The distal tibial fracture begins on the lateral distal aspect and spirals medially and proximally. The fibula remains intact (Fig. 42-165). This fracture is very similar to the supination-plantar flexion injury, especially when seen on the lateral radiograph: however, the distinction is that the distal tibial fracture line begins on the distal lateral aspect and spirals medially when viewed on the AP view.

Grade II injuries result from a further lateral rotation force that produces a spiral fracture of the fibula. The fracture begins medially and extends superiorly and posteriorly.

PRONATION-EVERSION-LATERAL ROTATION FRACTURE. This injury results when an eversion and lateral rotation force is applied to the fully pronated foot (Fig. 42-166). Typically, a Salter-

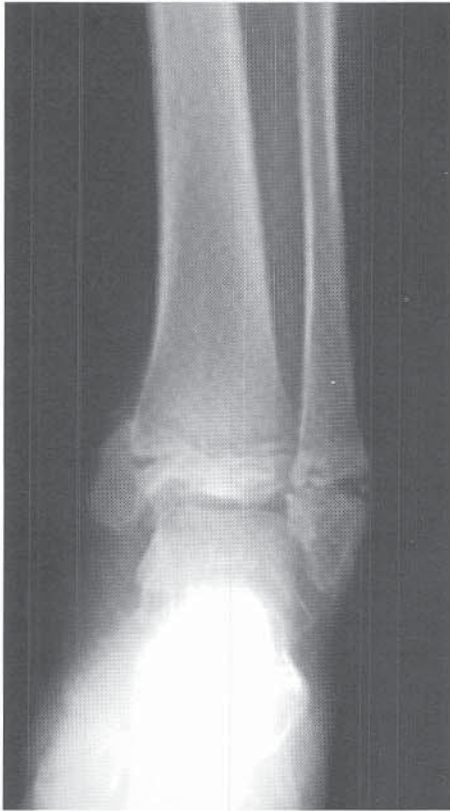

FIGURE 42-161 Grade II is a supination injury pattern in which treatment was not undertaken. There is a partially healed Salter-Harris type IV injury of the distal tibia and a Salter-Harris type I injury of the distal fibula.

Harris type I or II fracture of the distal tibia occurs, together with a transverse or short oblique fibular fracture located 4 to 7 cm proximal to the tip of the lateral malleolus. When a Salter-Harris type II fracture occurs the metaphyseal fragment is located laterally or posterolaterally and the distal tibial fragment is displaced laterally and posteriorly (Fig. 42-167).

AXIAL COMPRESSION INJURIES AND OTHER PHYSEAL INJURIES. These Salter-Harris type V injuries occur from an axial load applied to the distal tibia and are often recognized late because of subsequent physseal arrest. They are rare injuries, accounting

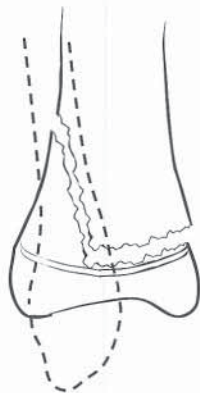


FIGURE 42-162 The supination plantar flexion injury. The injury occurs through the anterior aspect of the distal tibial physis and exits through the posterior aspect of the tibial metaphysis.

for less than 1 percent of all distal tibial physseal or ankle fractures.²⁰³ When this injury is suspected and it is difficult to ascertain from radiographs whether a Salter-Harris type V fracture has occurred, MRI may be helpful in identifying this injury.²⁰⁰

Other physseal injuries are fractures that cannot be classified according to the current ankle fracture classification, among them stress fractures and miscellaneous injuries of the distal fibula.

Diagnostic Features. The patient with an ankle fracture usually describes a twisting injury to the ankle but is unable to precisely define the position of the foot or the deforming force at the time of injury. The history provided by the patient with an ankle fracture is slightly different from the history provided by a patient with an ankle sprain in that the fracture patient will have pain at the time of the initial injury that persists on weightbearing. The patient with an ankle sprain has initial pain at the time of the injury, followed shortly by some relief of the pain, which slowly returns with increasing swelling and progressive pain with weightbearing.

The physical examination should include a visual inspection of the skin for lacerations and for evidence of an open fracture. The site of any ecchymosis and predominant area of swelling will provide some clue as to the nature of the injury and the deforming forces. The distal pulses should be evaluated and a good neurologic examination performed, as well as an assessment of the soft tissue envelope to ensure that an impending compartment syndrome is not present. The ankle should be evaluated for specific areas of tenderness over the bony anatomy, especially the medial and lateral malleoli, the anterior tibia, and the tibial and fibular shafts. In the young child it is especially important to determine whether tenderness is present over the distal fibular physis and/or distal medial tibial physis, since radiographs may not show a Salter-Harris type I fracture. Tenderness of the soft tissue structures of the ankle should also be assessed, especially the lateral ankle ligaments (anterior and posterior talofibular and calcaneofibular ligaments). Examination of the medial ankle ligaments is especially important in the isolated distal fibular fracture. Tenderness medially in this situation requires a careful assessment of the stability of the ankle, and in the older patient requires internal fixation of the fibular fracture.¹⁴⁵⁻¹⁴⁷ Although rare, subluxation of the peroneal tendons is often missed, mistaken for an ankle sprain or a distal fibular fracture.^{62,144,206} Tenderness posterior to the distal fibula with subluxation of the peroneal tendons elicited on dorsiflexion and eversion of the ankle confirms the diagnosis, and operative treatment usually provides good results.²⁰⁶

The radiographic examination of a suspected ankle fracture should include AP, lateral, and mortise views of the ankle (Fig. 42-168). If only two views can be obtained, it is best to obtain the mortise and lateral views and omit the AP view. The radiographs should be closely inspected for fracture, the relationship of the tibia and fibula, and to ensure that the mortise is intact by comparing the joint space throughout the mortise, confirming that there is symmetry throughout. In those injuries in which there is suspected instability with an innocuous-appearing fracture, stress x-rays should be obtained (Fig. 42-169).

Accessory centers of ossification may be seen on the medial and lateral aspects of the ankle, are commonly bilat-

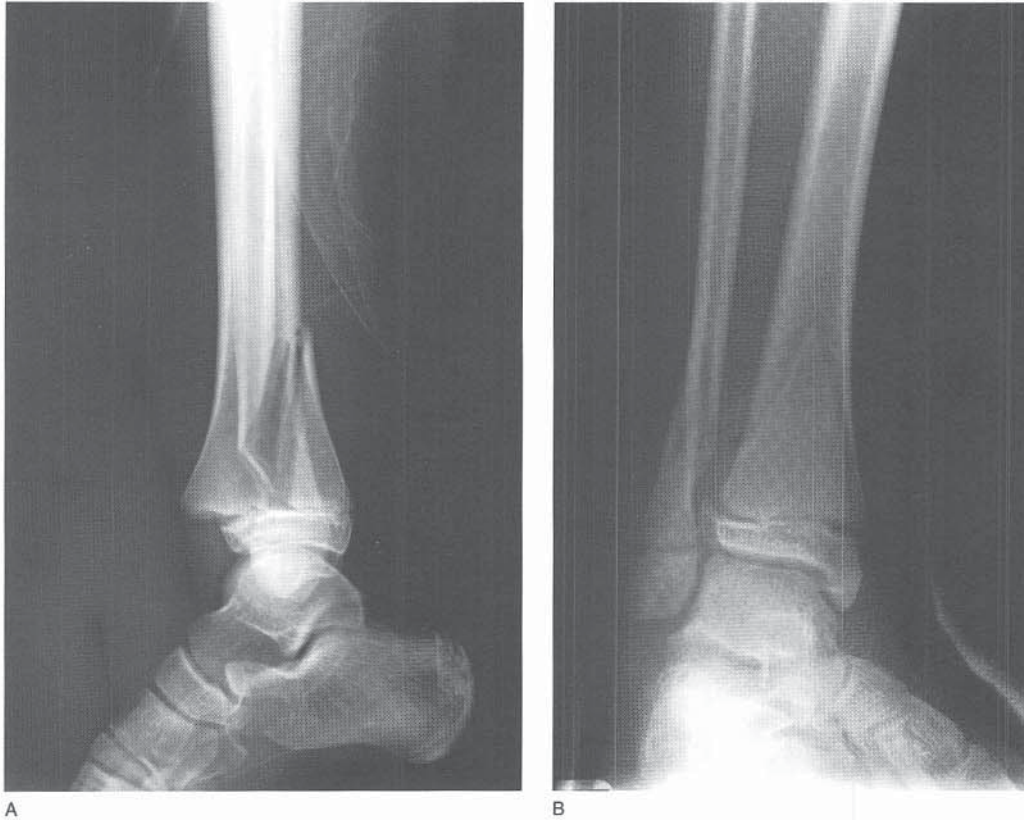
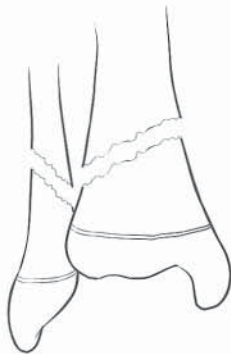

FIGURE 42-163 Radiographic appearance of a supination plantar flexion injury. A, Lateral radiograph showing the posterior metaphyseal fragment on the distal tibia. B, AP radiograph similarly demonstrating this metaphyseal fragment on the distal tibia, and also the distal fibular fracture.

eral, and can be seen on both the medial and lateral aspects of the foot (Fig. 42-170).^{77,111,118,156} On the medial side the os subtibiale can be seen in up to 20 percent. On the lateral side the os subfibulare is seen less often, in only 1 percent of cases.¹⁷³ This is often mistaken for an avulsion injury and is best evaluated by assessing the presence of tenderness distal to the medial and lateral malleoli.

Treatment. The mechanistic classification described by Dias and Tachdjian is invaluable in understanding the deforming forces of the fracture and therefore the reduction

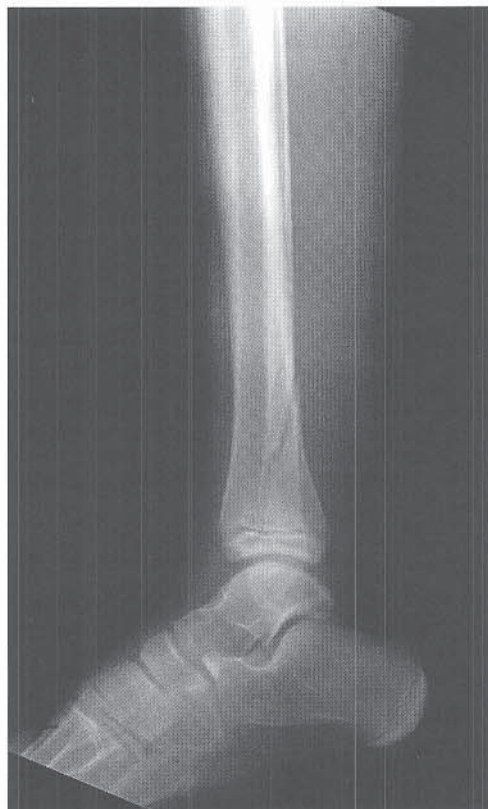

Supination-
External Rotation

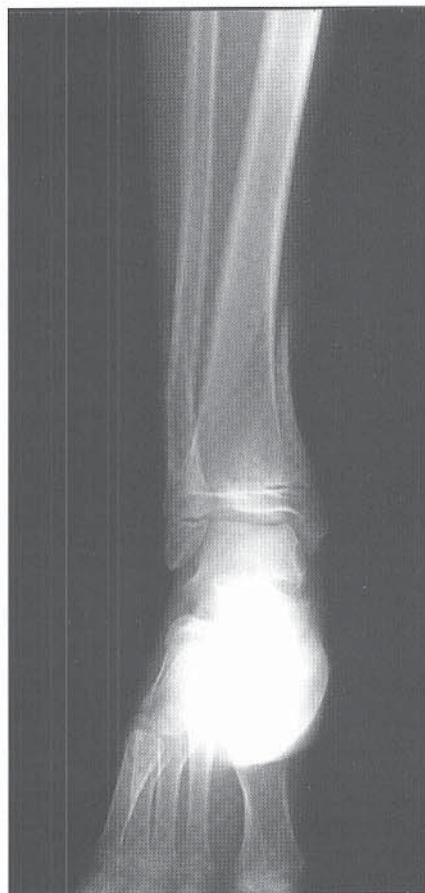FIGURE 42-164 The supination lateral rotation fracture pattern.

maneuver required to obtain a satisfactory reduction. The majority of ankle fractures in children can be treated with closed reduction followed by external immobilization; therefore, a thorough understanding of this classification and the mechanism of injury is important. The type of anesthesia required for a closed reduction of ankle fractures in children depends on the age of the child, the type of fracture, and the amount of fracture displacement. A young child with a minimally displaced fracture that can be easily reduced without a great deal of force may only require a hematoma block, while a larger child with a significantly displaced fracture may need conscious sedation or a general anesthetic. As in any physeal injury, the reduction should be performed as gently as possible and as soon as possible to avoid having to use considerable force. Each day of delay will make it more difficult to achieve fracture reduction and places the viability of the physis at risk when a forceful reduction is required. When the time from injury to treatment is 10 days or more, we recommend that reduction be avoided, since excess force is required for reduction and has a high likelihood of injuring the physis. The initial deformity is accepted, especially when it is in the sagittal plane, and time is allowed for remodeling to occur. If the deformity is in the coronal plane and the fracture is seen late, we prefer to allow fracture consolidation, preserving the growth of the distal tibial physis, followed by corrective osteotomy at a later date.

When operative treatment is required, the Salter-Harris classification is used to guide the surgeon in the treatment plan. In addition, the Salter-Harris classification provides



A



B

FIGURE 42-165 A and B, Radiographic appearance of a supination-lateral rotation fracture pattern. The distal tibia fracture begins distally-laterally and spirals proximally-medially. The distal fibula has sustained a spiral fracture as a result of the external rotation force.

better prognostic predictions, as it correlates with the incidence and type of complications.²⁰³ In a review of 237 fractures of the distal tibia, three groups of fractures were identified based on the risk of developing complications and were best correlated with the type of fracture (Salter-Harris classification), the severity of displacement or comminution, and the adequacy of reduction.²⁰³

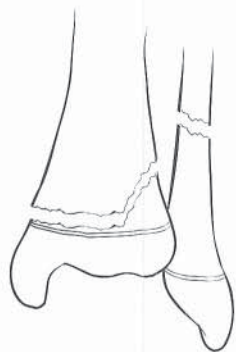The primary indications for operative treatment of ankle fractures in children are inability to obtain or maintain a closed reduction, displaced physal fractures, displaced

articular fractures, open fractures, and ankle fractures with significant tissue injury.

The following treatment outline uses the Salter-Harris classification as a framework to guide fracture treatment and the Dias-Tachdjian classification principally to identify the deforming forces and the type of closed reduction maneuvers.

SALTER-HARRIS TYPE I AND II DISTAL FIBULAR FRACTURES. Type I fracture of the fibula is the most common fracture of the ankle in children and is often misdiagnosed as an ankle sprain. Because children are more likely to sustain physal injuries than ankle sprains, the surgeon should have a high index of suspicion that an injury to the distal fibular physis has occurred. The mechanism of injury is usually inversion of the supinated foot and can be associated with a distal tibial physal fracture. The average age of patients with a type I injury is 12 years, while type II injuries are seen in younger patients, with an average age of 10 years.²⁰³

The physical examination begins with inspection of the lateral aspect of the ankle to identify swelling and ecchymosis, followed by palpation of the distal physis and the lateral ligaments. In addition, the medial aspect of the ankle, including the ligaments and the medial malleolus, should be palpated. The undisplaced Salter-Harris type I injury is most often not seen on radiographs; however, a soft tissue swelling is seen directly over the distal fibular physis and the diagnosis is confirmed by the presence of tenderness. Salter-Harris type II fractures and displaced Salter-Harris I fractures are



Pronation-Eversion
External Rotation

FIGURE 42-166 The pronation-eversion-lateral rotation fracture pattern.

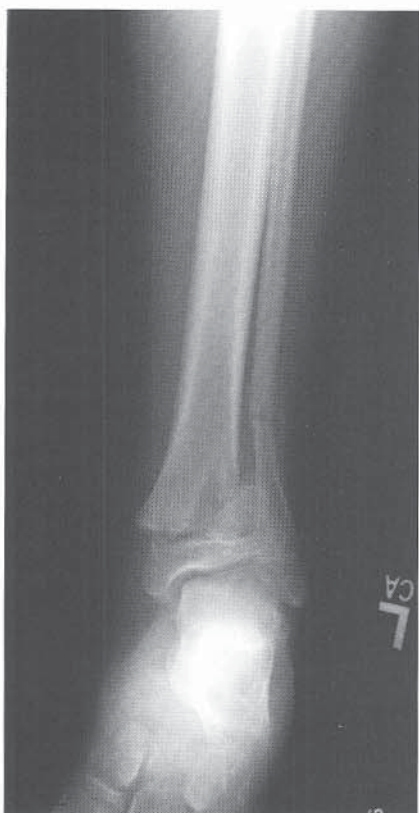

FIGURE 42-167 Radiographic appearance of a pronation-eversion-lateral rotation injury. Note the Salter-Harris type II fracture of the distal tibia with the metaphyseal fragment on the lateral aspect. The distal fibular fracture is a transverse fracture that occurs just proximal to the syndesmosis.

easily identified and are often associated with a distal tibial Salter-Harris type III or IV injury.

Treatment of the isolated nondisplaced distal fibular Salter-Harris type I injury is a short-leg walking cast for 4 weeks. The displaced fracture requires a closed reduction and a short-leg nonweightbearing cast for 4 to 6 weeks. Complications from this injury are rare, although Spiegel and colleagues reported that three of 16 patients had premature symmetric physeal closure, with two of the patients having subsequent shortening.²⁰³ Salter-Harris type II fractures can be treated with a short-leg nonweightbearing cast for 4 to 6 weeks and usually heal without complications.²⁰³ The displaced distal fibular fracture associated with a displaced distal tibial fracture will usually reduce on reduction of the tibial fracture. The reduction is usually stable and does not require internal fixation.

SALTER-HARRIS TYPE I TIBIAL FRACTURES. This injury is relatively rare in children, accounting for approximately 15 percent of all distal tibial-fibular fractures in children. It occurs in the younger child (average age, 10 years).²⁰³ All four mechanisms of injury described by Dias and Tachdjian can result in this injury,^{54,55} and the exact mechanism can be determined by the location of the fracture fragments at the time of the initial radiographic examination. An associated fibular fracture is seen in approximately 25 percent of tibial fractures and helps determine the mechanism of injury. Treatment consists of gentle closed reduction, with reversal of the original mechanism of injury, followed by cast immobilization. We prefer

a long-leg cast for most fractures, especially those that are displaced at the time of the initial injury. A short-leg cast can be applied beginning at 4 weeks and worn for an additional 2 weeks. Complications from these injuries, although rare, include premature physeal arrest with subsequent limb length discrepancy, which has been reported in 3 percent of cases. Growth stimulation on the affected side has also been reported but does not usually exceed 1.5 cm.²⁰³

SALTER-HARRIS TYPE II DISTAL TIBIAL FRACTURES. This injury is the most common distal tibial physeal injury in children, accounting for 40 percent of all ankle fractures.²⁰³ The average age of these children is 12.5 years, and an associated fibular fracture occurs in the diaphysis in approximately 20 percent of cases. The mechanism of injury can be any of the four mechanisms described by Dias and Tachdjian; however, the most common are supination-external rotation (57 percent) and supination-plantar flexion injuries (32 percent), while pronation-eversion and miscellaneous injuries each account for 5 percent.²⁰³ The location of the metaphyseal fragment is most helpful in determining the mechanism of injury. A posterior metaphyseal fragment indicates a supination-plantar flexion injury and therefore requires a reversal of this mechanism with anterior displacement of the distal fragment to reduce the fracture (Fig. 42-171).

Treatment of nondisplaced fractures require a well-molded long-leg plaster cast, which can then be overwrapped in fiberglass for 3 to 4 weeks and changed to a short-leg cast for an additional 2 to 3 weeks. The displaced Salter-Harris type II fracture requires a gentle closed reduction, which should be performed under sedation or a general anesthetic to allow muscle relaxation so that further injury to the physis is limited. A long-leg cast should be worn for 4 weeks, followed by a short-leg cast for 2 to 3 weeks. A closed reduction should include initial flexion of the knee 90 degrees and plantar flexion of the foot to relax the triceps surae. An assistant should apply countertraction to the thigh while the surgeon grasps the foot at the heel while steadying the distal tibia with the opposite hand. Axial traction on the distal segment is first applied in line with the deformity, followed by manipulation opposite the initial deforming force (Fig. 42-172). For supination-external rotation injuries, distal traction is first applied medially, followed by eversion of the foot. A plaster cast is first applied distal to the knee, with the foot slightly internally rotated and in pronation to maintain reduction of the fracture. For the supination-plantar flexion injury the reduction maneuver includes initial axial traction with the foot in the plantar flexed position, followed by gradual dorsiflexion of the foot to approximately 20 degrees. The foot should then be placed into a neutral position and a provisional short-leg plaster cast applied. After a radiograph of the ankle confirms that an adequate reduction has been achieved, the cast is extended above the knee. For the pronation-eversion injury the reduction maneuver consists of in-line traction with the foot in a pronated position, followed by gentle supination and inversion of the foot past the neutral position, followed by casting of the leg.

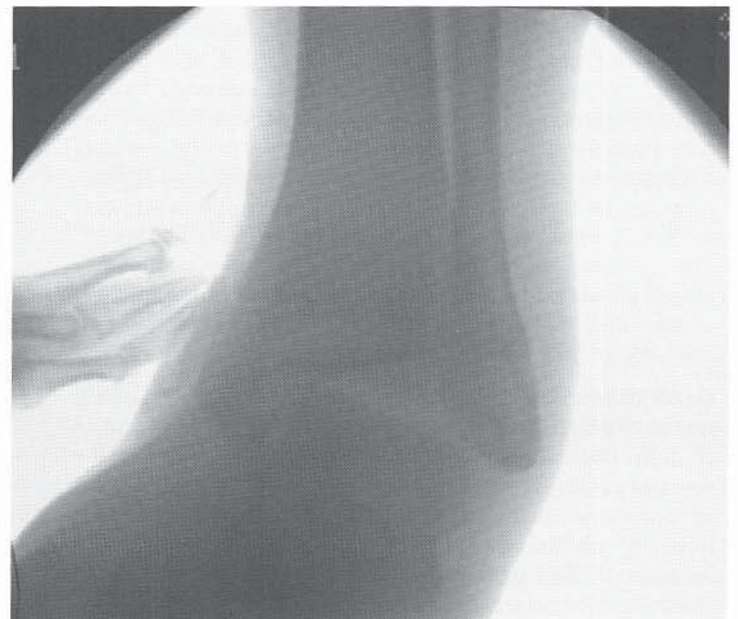
It is imperative that the patient be relaxed during the reduction maneuver to limit the number of attempts to achieve an adequate reduction. Relaxation can be achieved with adequate conscious sedation in the emergency room

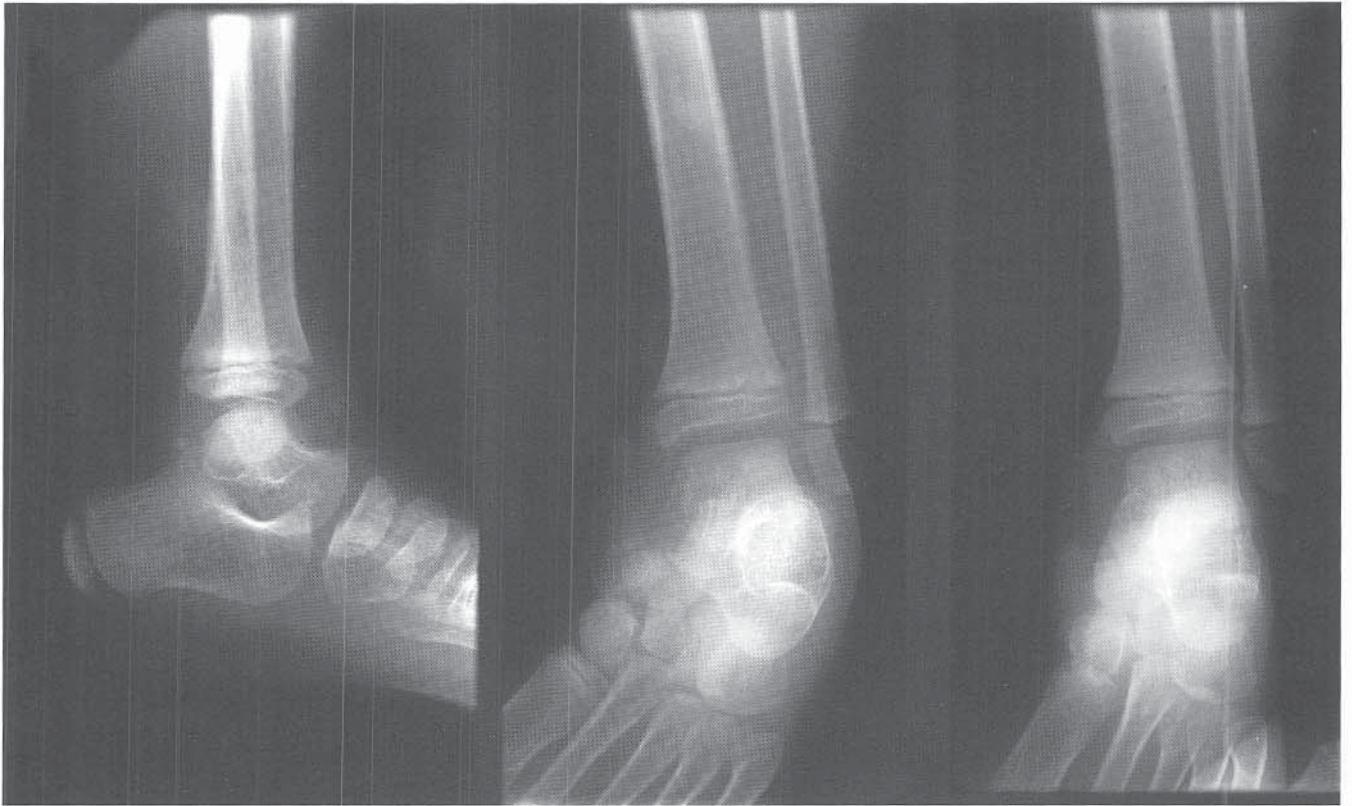
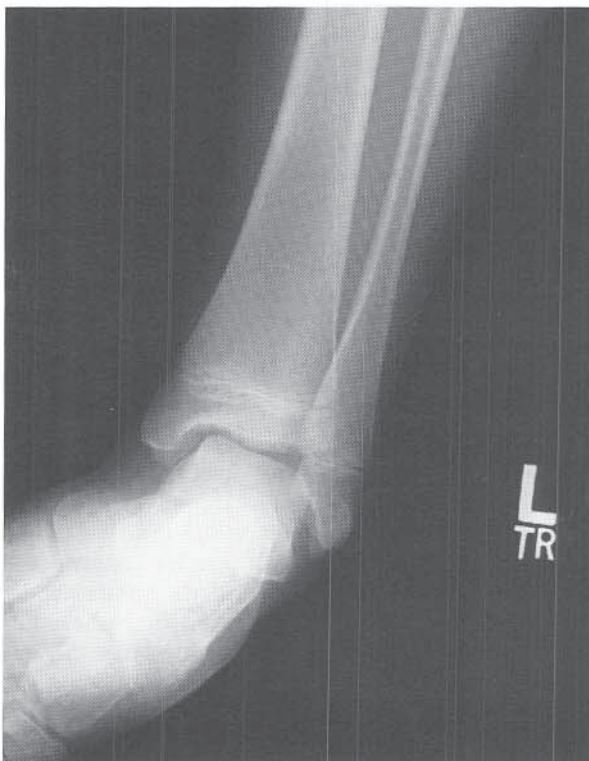
FIGURE 42-168 A complete radiographic examination for suspected ankle fracture should include lateral, mortise, and AP views of the ankle.



A



B

FIGURE 42-169 Stress radiographs obtained with the examiner inverting the foot in an attempt to define a ligamentous injury. A, Normal stress radiograph with less than 20 degrees of talar tilt. B, Abnormal stress radiograph with more than 20 degrees of talar tilt.

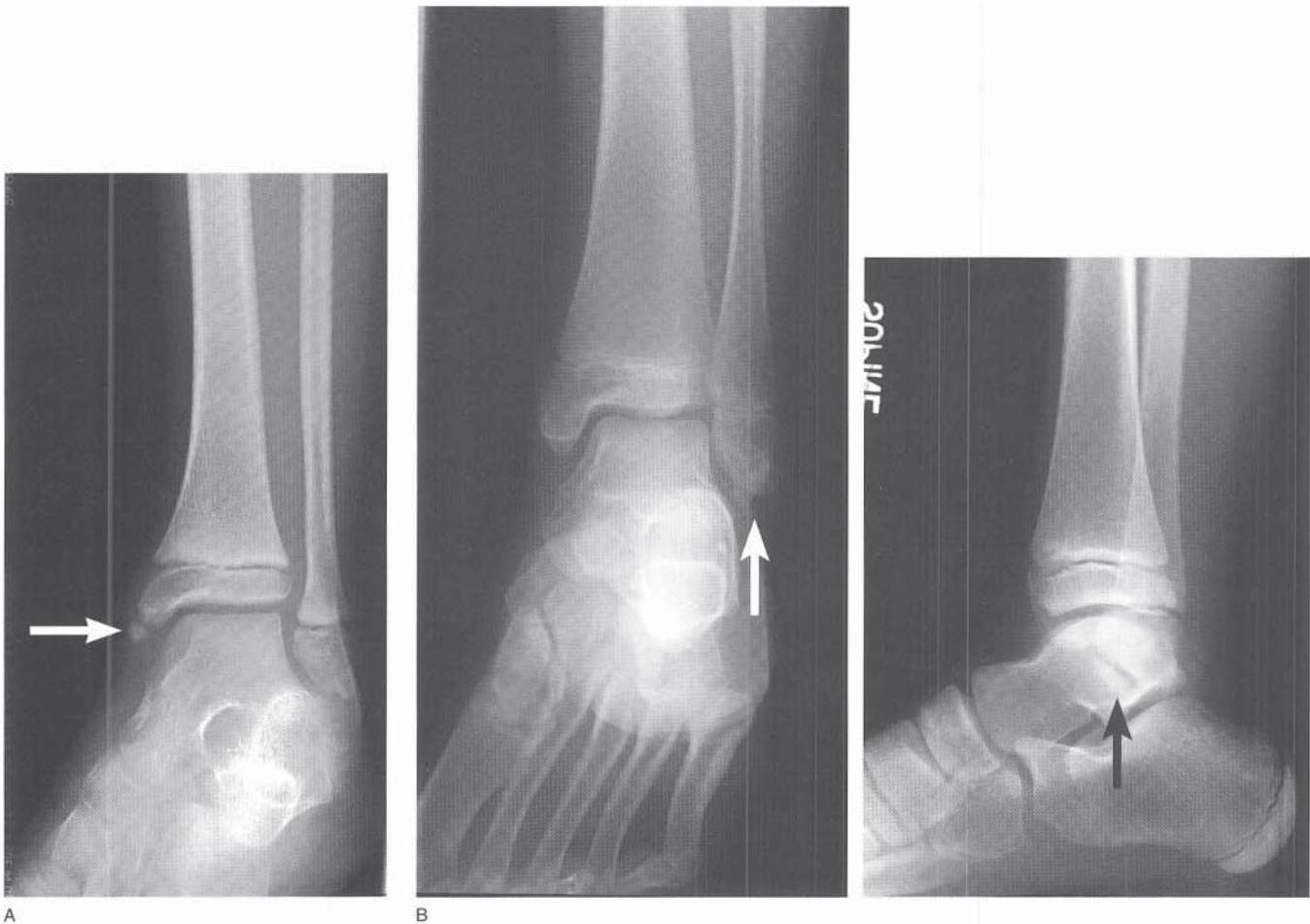


FIGURE 42-170 Accessory centers of ossification. A, An accessory center of ossification on the medial malleolus (arrows) in a 10-year-old patient. B, AP and lateral radiographs demonstrating a lateral accessory center of ossification (arrows).

or with general anesthesia in the operating room. This is best judged by the treating surgeon and depends on the age of the child, the amount of fracture displacement, the type of fracture, and the quality of the conscious sedation provided by the emergency room. Any active guarding by the patient during the initial in-line traction maneuver warrants more medication to sedate the patient or changing the plan to include a general anesthetic so that an unimpeded initial attempt at a closed reduction can be performed. This will allow the best attempt at a closed reduction and instills confidence in the surgeon that a failed attempt at closed reduction is due to interposition of periosteum or other soft tissue and not to resistance by the patient. If an attempt at closed reduction does not succeed, open reduction should be performed, with removal of interposed soft tissue. This situation most often arises in the patient with a supination-plantar flexion injury in which the anterior periosteum is torn and interposed in the fracture site, preventing reduction. Grace reported three cases of irreducible Salter-Harris type II fractures of the distal tibia that were due to interposition of the anterior neurovascular bundle; the result was a dysvascular foot in two cases after a closed reduction.⁷³ Satisfactory results are achieved when an open reduction with removal of the interposed soft tissue is performed, followed by external immobilization in a long-leg cast.

A balance exists between repeat closed reductions and acceptance of the reduction in order to avoid premature growth arrest. The amount of fracture displacement that is acceptable has not been fully established or agreed upon.* We prefer to obtain a near anatomic reduction of these injuries to prevent residual angular deformity, especially in the child older than 10 years, and when the deformity is in the coronal or frontal plane. An initial reduction attempt can be performed under adequate intravenous sedation in the emergency room; however, failure to achieve an adequate reduction should be followed by a repeat reduction performed under general anesthesia, followed by an open reduction if necessary. Spiegel and colleagues reported that Salter-Harris type II fractures of the distal tibia do not remodel an angular deformity, and an anatomic reduction is necessary.²⁰³

SALTER-HARRIS TYPE III DISTAL TIBIAL FRACTURES. These injuries occur in approximately 20 percent of all distal tibia-fibular fractures in children, with an average age of 11 to 12 years.²⁰³ The mechanism is always a supination-inversion injury as described by Dias and Tachdjian and is associated with a distal fibular fracture in 25 percent of cases. The supinated foot sustains an inversion force that stresses the lateral ligaments of

*See references 33, 105, 106, 165, 186, 203.

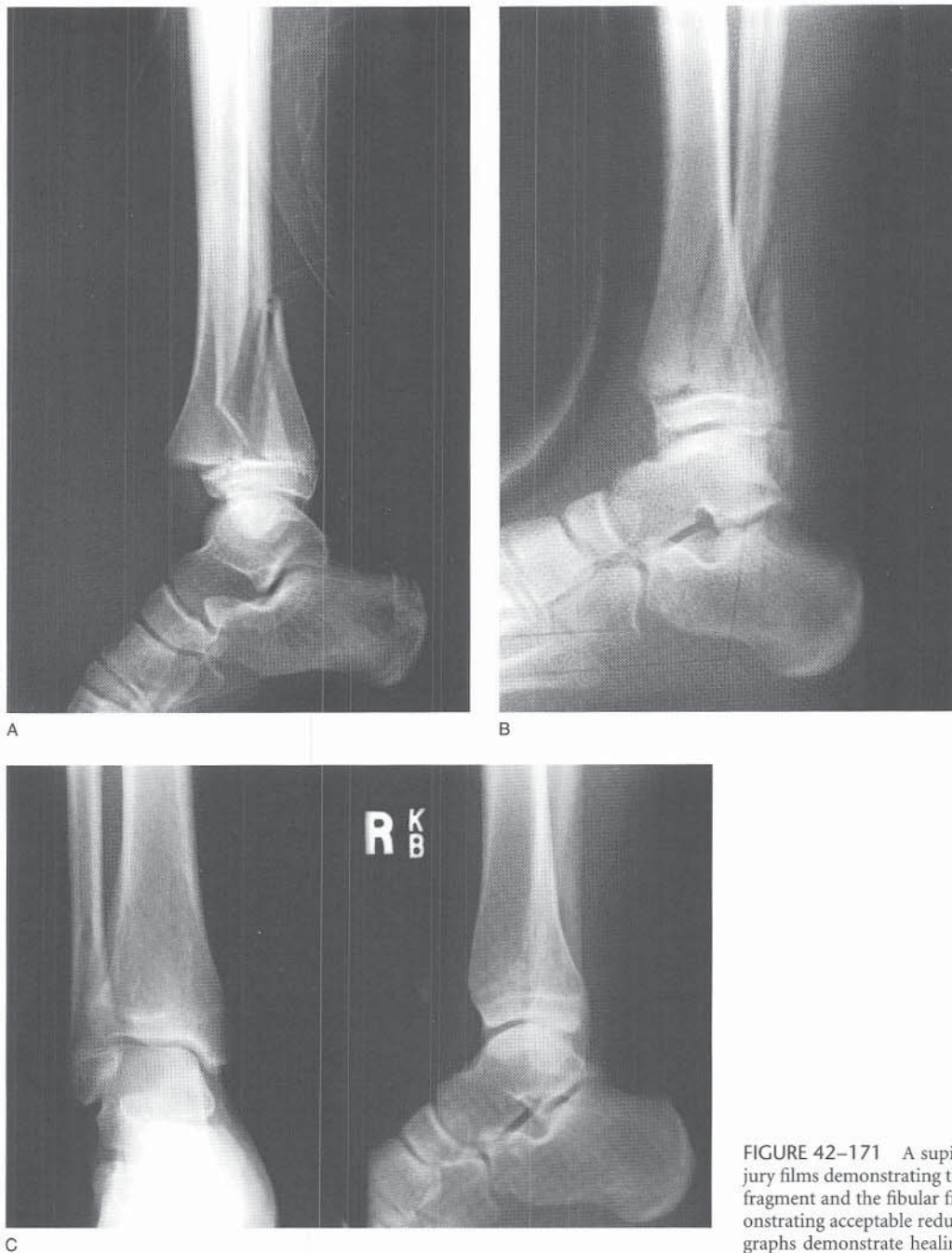


FIGURE 42-171 A supination plantar flexion injury. **A**, Injury films demonstrating the distal posterior tibial metaphyseal fragment and the fibular fracture. **B**, Postreduction films demonstrating acceptable reduction. **C**, At 1-year follow-up, radiographs demonstrate healing in an anatomic position.

the ankle, avulsing the distal fibula while driving the talus into the medial aspect of the distal tibia. The epiphyseal fracture component of the Salter-Harris type III fracture is always medial to the midline, not to be mistaken for a Tillaux or triplane fracture when the epiphyseal fracture is at the midline or lateral to it (Fig. 42-173). Treatment of nondisplaced fractures consists of 4 weeks in a long-leg cast, followed by an additional 4 weeks in a short-leg cast. The initial plaster cast should be placed with the foot in 5 to 10 degrees of eversion, with a good mold on the medial aspect of the ankle. Spiegel and colleagues reported results in 26 patients with mildly displaced or nondisplaced type III fractures treated by closed reduction, with one patient developing a premature closure of the medial phy-

sis and a resultant 5-degree angular deformity.²⁰³ Careful follow-up of these fractures on a weekly basis to ensure maintenance of fracture reduction is essential.

Fractures that are displaced more than 2 mm should be reduced in the operating room with either a closed or open reduction followed by screw fixation. We prefer to view the articular cartilage in the displaced distal tibial fracture through a small, 3- 4-cm anterior arthrotomy using the interval between the extensor digitorum longus and the extensor hallucis longus (Fig. 42-174). The fracture can then be reduced using a Weber bone reduction forceps and rigidly fixed with a percutaneously placed screw. The cannulated screws (3.5 or 4.0 mm) are useful in this setting;

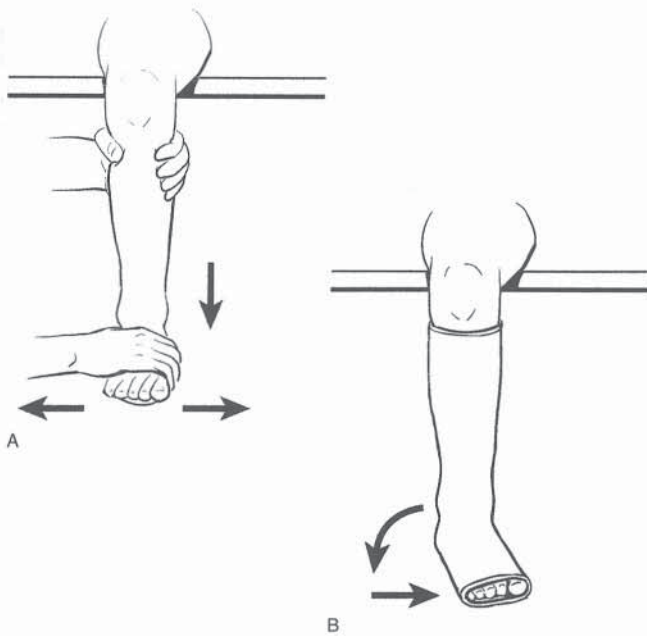


FIGURE 42-172 Reduction of ankle fractures. A, Following conscious sedation, the leg can be placed over the hospital bed. Axial traction is applied, followed by reversal of the mechanism of injury. B, A temporary short-leg cast is then placed and allowed to set in the desired position. The cast is then extended proximally above the knee for optimal control.

lar component as well as the metaphyseal fragment (Fig. 42-176). The saphenous vein is dissected free of soft tissue to allow posterior retraction out of the surgical site, then both the intra-articular and metaphyseal fracture lines are identified. Reduction is performed with a bone-reduction forceps and screw fixation parallel to the physis in the epiphysis and the metaphysis (Fig. 42-177). Smooth Steinmann pins or Kirschner wires can be used; they are left out of the skin and removed at 6 weeks. Postoperatively a long-leg cast should be worn for 3 to 4 weeks, followed by a short-leg cast for an additional 3 weeks.

After treatment of these fractures, monitoring of the distal tibial physis with serial radiographs and/or scanograms every 6 months is warranted. If growth arrest is suspected, screw removal followed by CT or MRI is necessary to fully define the presence and extent of a physal osseous bridge. Otherwise we do not routinely remove internal fixation devices for these fractures.

The use of bioabsorbable pins and screws has been reported in adult ankle fractures, with mixed results.^{13,19,20,26,87} We do not have any experience with these devices in the care of the distal tibial fracture in children.

SALTER-HARRIS TYPE V DISTAL TIBIAL FRACTURES. These injuries are extremely rare, are due to an axial compression force, and are usually noted following the appearance of a physal

however, complications are relatively common,¹⁹⁶ and the purchase achieved is often marginal. An alternative is to use the small-fragment 3.5- or 4.0-cm screw, which can also be placed percutaneously under fluoroscopic guidance and provides excellent bone purchase and fracture compression (Fig. 42-175). Short-leg cast immobilization is required for 6 weeks, followed by progressive weightbearing. The results of operative fixation of these displaced fractures are generally good, with an approximately 15 percent incidence of premature physal closure and subsequent angular deformity.²⁰³ When displaced fractures are not reduced anatomically, early degenerative arthritis can occur, and onset of painful symptoms begins 5 to 8 years following the injury.³⁶ In addition, those patients treated with a closed reduction tend to have a growth disturbance secondary to a bony bridge.¹⁰⁵

SALTER-HARRIS TYPE IV DISTAL TIBIAL FRACTURES. These fractures are rare, accounting for approximately 1 percent of injuries of the distal tibia in children.²⁰³ The mechanism of injury is a supination-inversion injury in which the talus is pushed medially into the medial malleolus, with a fracture line traveling from the articular surface through the epiphysis and metaphysis.

We prefer an open reduction with internal fixation for these fractures, since most are displaced and the fracture line extends into the joint. These fractures are likely to be associated with subsequent early degenerative arthritis and growth arrest if not treated with open reduction and internal fixation.¹⁰⁵ The approach is similar for a medial malleolus fracture in which the skin incision is curvilinear with the convexity anterior to allow direct viewing of the intra-articu-

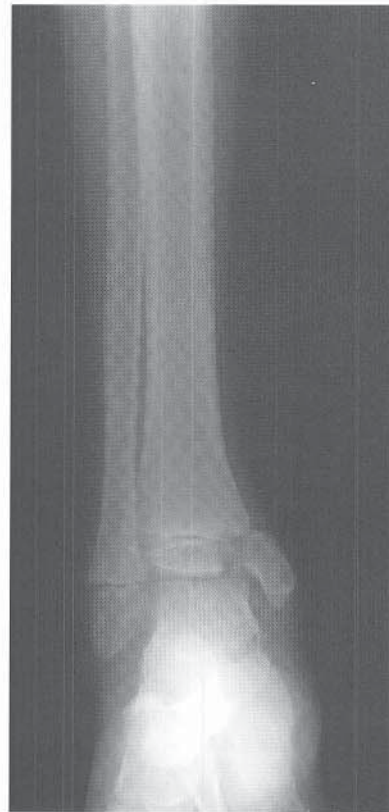

FIGURE 42-173 Radiographs of a Salter-Harris type III fracture due to a supination-inversion injury, in which the talus drives into the medial malleolus. Note the epiphyseal fracture line medial to the midline, unlike the Tillaux fracture, which is located more laterally in the epiphysis.

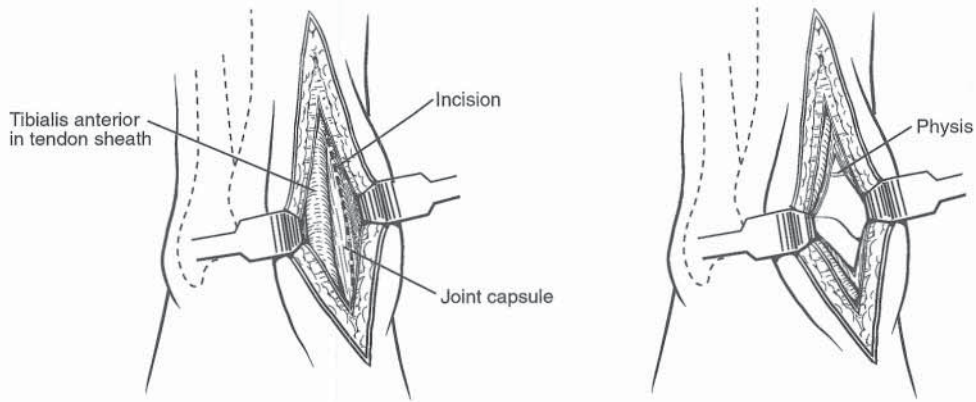
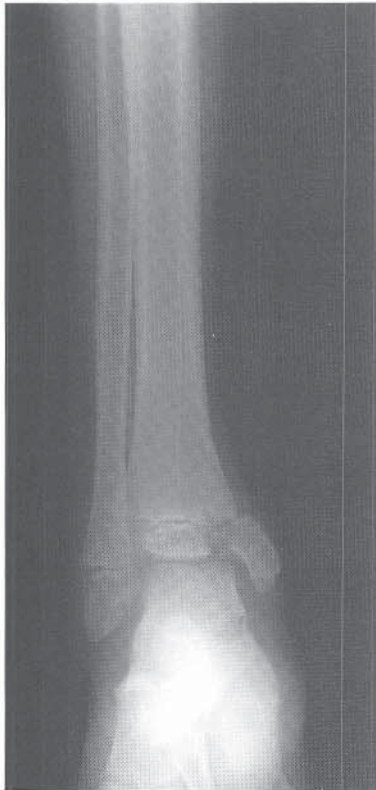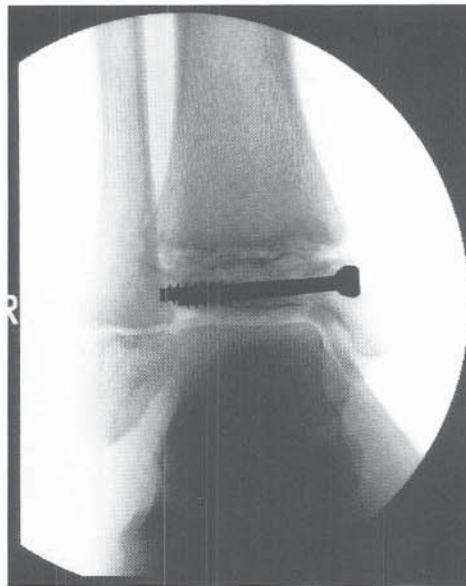


FIGURE 42-174 Anterior approach to the medial ankle joint. An incision is made over the anterior tibialis tendon. The incision is carried just distal to the ankle joint. The tendon sheath is left intact, and the incision is carried just medial to this. This will preserve the tendon and allow access to the medial aspect of the ankle joint, to visualize Salter-Harris type III injuries.



A

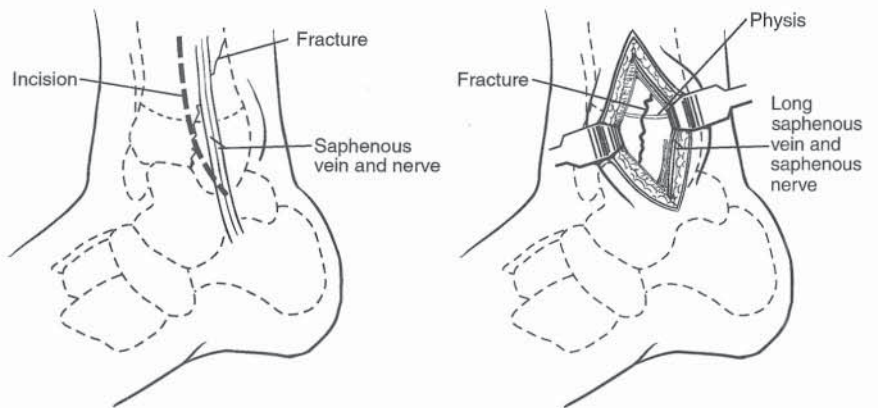


B

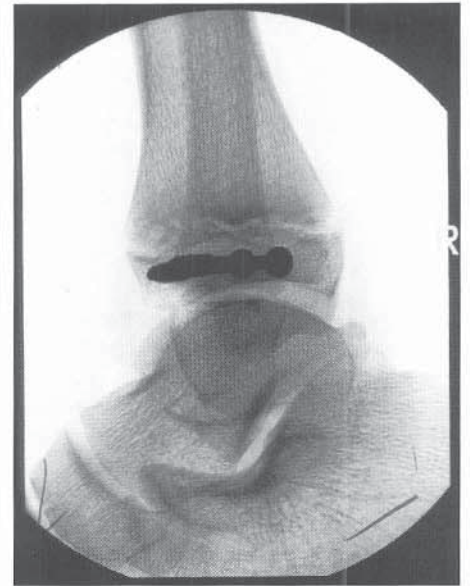

FIGURE 42-175 Open reduction and internal fixation of a Salter-Harris type III distal tibia fracture. A, Injury radiograph showing supination-inversion injury of the ankle, with a resultant Salter-Harris type III distal tibial fracture. B, AP and lateral radiographs obtained after an open reduction using the anterior approach to the ankle, as noted in Figure 42-174, followed by percutaneous screw fixation using cannulated screws. Note the reduction and the screw fixation to achieve compression across the fracture site.

FIGURE 42-176 The approach to the medial ankle in the treatment of Salter-Harris type IV fractures of the distal tibia. A curvilinear incision is made over the anterolateral aspect of the distal tibia. This allows access to the medial aspect of the joint and direct observation of the fracture fragment. The long saphenous vein and saphenous nerve are retracted posteriorly.



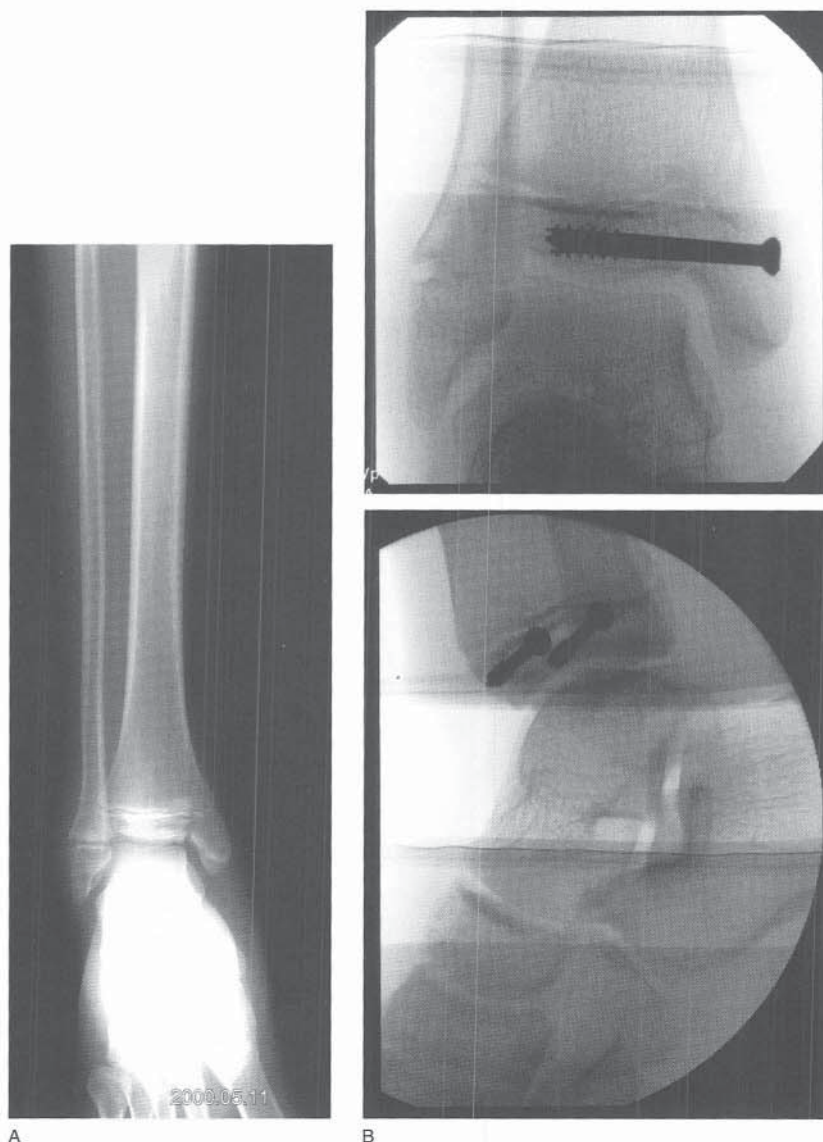


FIGURE 42-177 Open reduction and internal fixation of a Salter-Harris type IV distal tibial fracture due to a supination-inversion injury. **A**, AP radiograph demonstrating the fracture. Although it is mildly displaced, there is a significant risk for further displacement. **B**, Intraoperative radiographs obtained following open reduction and internal fixation with cannulated screws.

arrest of the distal tibia after trauma without radiographic findings. The mechanism of injury to the physis is either compression of the germinal layer, vascular insult, or both. These injuries should be analyzed in the same fashion as all physeal arrests and treated appropriately.

Complications

PREMATURE CLOSURE OF THE PHYISIS. Injury to the germinal layer of the physis may lead to asymmetric or symmetric growth arrest. This is the most common complication following a distal tibial physeal injury in children. Those fractures at highest risk are the displaced Salter-Harris type III and IV injuries.* Although it is the most common complication seen with these injuries, it is still relatively rare. Spiegel and colleagues reported findings in 39 patients with a Salter-Harris type III or IV fracture who had adequate follow-up. Premature growth arrest developed in three (7.7 percent) patients.²⁰³

The adduction force imparted in these fractures leads to

injury to the medial aspect of the distal tibial physis, producing an asymmetric growth arrest and a subsequent varus deformity. Kling and colleagues reported findings in 16 patients with Salter-Harris type III injuries and 12 patients with Salter-Harris type IV fractures who experienced growth arrest of the distal tibia with subsequent varus and shortening.¹⁰⁵ The average age of the patients was 8 to 9 years, and the time to the development of partial physeal growth arrest was 17 months for type III fractures and 20 months for type IV fractures. The average shortening was 1.6 and 1.1 cm for the type III and type IV injuries respectively, and both types of fracture had an average varus deformity of 15 degrees. Most of these fractures had been treated by closed reduction followed by external immobilization in a cast. Kling and colleagues studied a second group of 20 patients who presented to their institution with an acute Salter-Harris type III or IV fracture that was treated by open reduction and internal fixation; 19 healed without evidence of a growth disturbance. It is therefore imperative to achieve an anatomic reduction through an open arthrotomy, followed by stable internal fixation to prevent this complication. Even

*See references 33, 45, 54, 55, 71, 110, 143, 165, 203.

though an anatomic reduction is achieved, significant injury to the growth plate at the time of the initial event may lead to subsequent growth arrest (Fig. 42-178).³⁵ The Salter-Harris type II fracture with significant displacement at the time of injury is also at risk for development of a premature growth arrest and should be treated by open reduction and

internal fixation if an anatomic reduction cannot be achieved closed. Spiegel and colleagues reported that six (9 percent) of 66 patients with Salter-Harris type II fractures developed an angular deformity of more than 5 degrees following closed treatment.²⁰³

It is important to follow patients with distal tibial physal

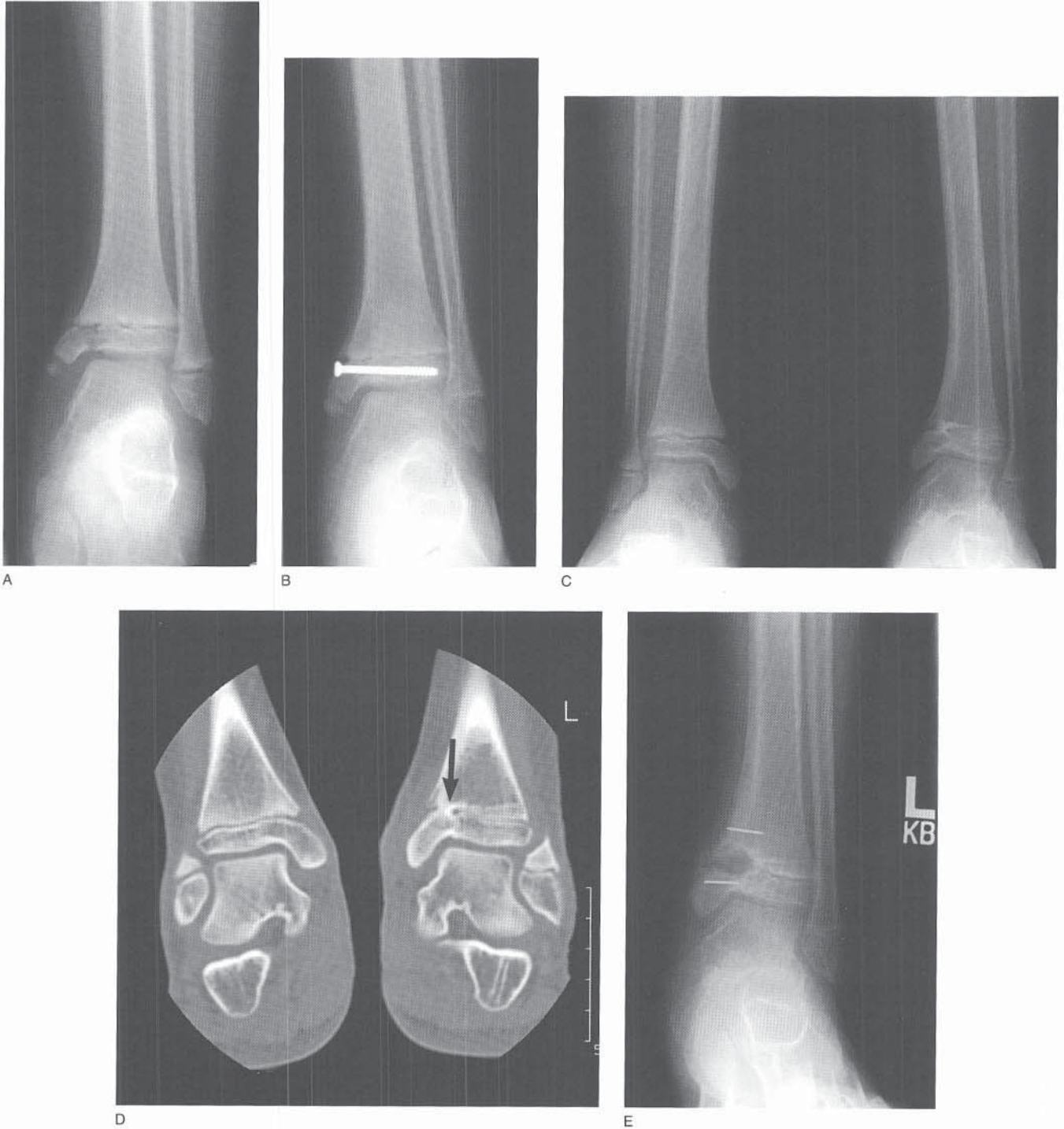


FIGURE 42-178 Distal tibial growth arrest following a Salter-Harris type III fracture in a 9-year-old girl. **A**, Injury radiographs. **B**, An open reduction with screw fixation was performed. **C**, Varus deformity of the distal tibia developed secondary to a medial physal bar. **D**, CT scan showing a distal tibial physal growth arrest (arrow). **E**, Postoperative radiograph obtained after excision of a physal bar, followed by fat interposition for a distal tibial physal growth arrest. Small K-wires were placed on both sides of the resection. Their distance should increase if the physis resumes symmetric growth.

injuries closely during the first 2 years after the injury. Physeal arrest can appear more than 2 years after the injury, and therefore follow-up should extend until near skeletal maturity. When growth arrest is suspected on plain radiographs, further diagnostic studies should be performed. The plain radiographs should be analyzed for evidence of an osseous bar within the physis. Park-Harris growth arrest lines should be observable and can be helpful in determining the presence of premature asymmetric growth arrest.⁸⁹ Internal fixation devices should be removed prior to further studies, which should include CT or MRI (see Fig. 42–178D). The treatment of growth arrest depends on its location, size, and the amount of growth remaining. In general, when there is more than 2 years of growth remaining and the physeal arrest is less than 50 percent the width of the physis, we prefer to resect the osseous bar and replace the area with adipose tissue or cranioplast (see Fig. 42–178E). Small metal markers should be placed in the epiphysis and metaphysis to allow accurate assessment of future growth and the success of this procedure. When the patient is closer to skeletal maturity (girls older than 11 years and boys older than 13 years), an epiphysiodesis of the lateral aspect of the tibial physis and the entire fibular physis is performed. This procedure should be combined with a contralateral epiphysiodesis to prevent a large limb length discrepancy. If significant varus deformity is present at the time of the epiphysiodesis, an opening wedge osteotomy of the tibia can be performed together with a fibular osteotomy. The opening wedge osteotomy is made 2 cm proximal to the distal physis with interposition of tricortical iliac crest graft and fixation with crossed Kirschner wires or screws, while the fibula is cut obliquely proximal to the tibial cut (Fig. 42–179). External cast immobilization is used until healing of the osteotomy occurs. Takakura and associates recently reviewed the results in seven adult and two adolescent patients who had undergone an opening wedge osteotomy for posttraumatic varus of the ankle.²¹⁰ Both adolescent patients had a significant improvement in their preoperative ankle scores and had resumed athletic activities.

DELAYED UNION OR NONUNION. This is a very rare complication in younger children, although it may occur in the adolescent with a distal tibial fracture. In the largest series of distal tibial fractures reported in children, no patients were reported to develop a nonunion or delayed union. If nonunion is present, we prefer an open procedure to debride fibrous tissue at the fracture site, followed by autologous bone grafting and internal fixation, especially if there is motion at the fracture site.

VALGUS DEFORMITY SECONDARY TO MALUNION. This complication usually results from inadequate reduction of a pronation-eversion-lateral rotation fracture. A valgus tilt of the ankle of more than 15 to 20 degrees will not correct by remodeling with skeletal growth and must be treated surgically. When sufficient growth remains, an epiphyseal arrest of the medial distal tibia can be performed to allow the lateral tibial and the distal fibula to continue to grow and correct the deformity. We prefer to perform the distal medial epiphysiodesis by placing a single screw across the medial physis so that medial growth will be disturbed, and will allow removal of the screw to resume medial growth if overcorrection is anticipated. When growth is complete, then the distal tibial

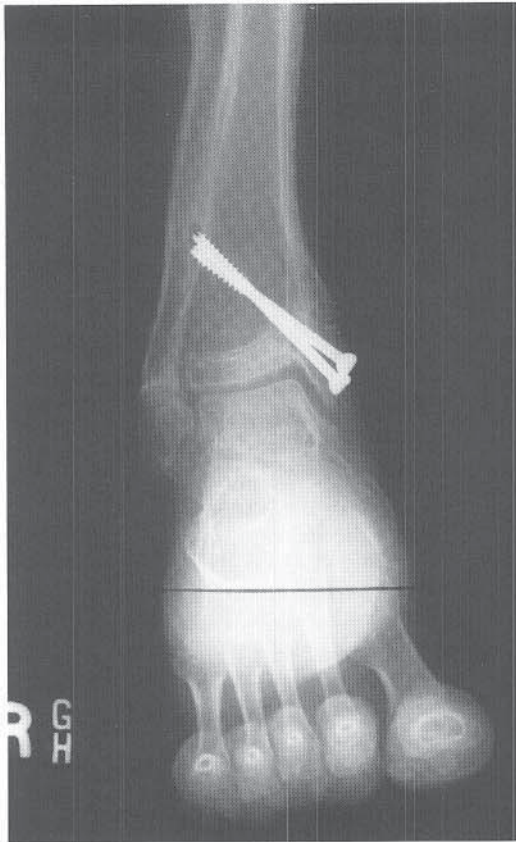osteotomy is best performed using the Wiltse technique to obtain correction, without excess shortening of the limb or creating a prominent medial aspect of the ankle (Fig. 42–180).²³

THE TILLAUX FRACTURE. Fractures of the lateral portion of the distal end of the tibia in the adult were first described by Sir Astley Cooper;⁴¹ however, this fracture is referred to as the fracture of Tillaux. This fracture results from an external rotation of the ankle and occurs because of the asymmetric closure of the distal tibial physis, which initially begins centrally, followed by medial closure, and finally lateral closure. The medial closure occurs at approximately 13 to 14 years of age, with lateral closure beginning at 14.5 to 16 years of age; therefore, an 18 month window of time will predispose patients to this particular fracture.¹⁰⁴ When the distal lateral physis is still open and an external rotation force is applied to the foot, an avulsion fracture of the anterolateral distal epiphysis occurs as the inferior tibiofibular ligament pulls this fragment free (Fig. 42–181). This is a Salter-Harris type III fracture with a vertical fracture line that extends from the articular surface proximally, through the lateral physis, and out the lateral cortex (Fig. 42–182). In the older child the fracture line occurs more laterally since the physis has closed medially. The fracture fragment and the amount of displacement tend to be less in this age group, although this is variable.

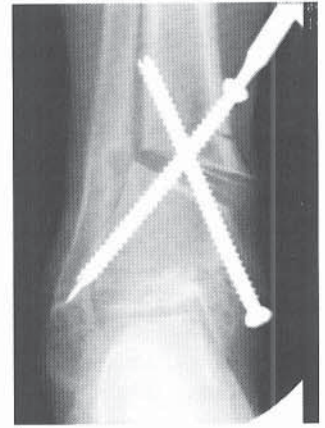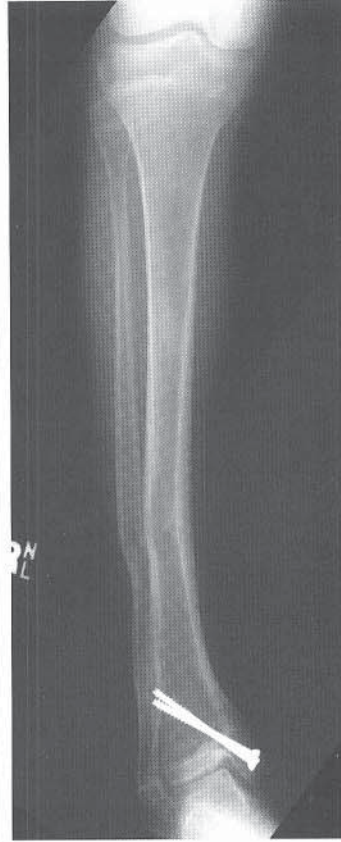The patient typically presents with pain and swelling in the affected ankle after a traumatic event, often without knowing the exact mechanism of injury or the position of the foot at the time of injury. The injuries can be misdiagnosed as a sprain when careful evaluation of the patient is not performed. The diagnosis is often missed in the emergency department by those who are unfamiliar with the pattern of distal tibial physeal closure and this specific injury. Letts described five of 26 patients in whom the diagnosis was not made and who returned only because of persistent inability to bear weight for 2 to 3 days after being diagnosed with an ankle sprain.¹²² The initial radiographs of the ankle should include a mortise view to best demonstrate the fracture.

The treatment of these avulsion fractures has traditionally been to initially attempt a closed reduction to reduce the fracture to within 2 mm of the anatomic position. However, there are no studies to directly support long-term good outcomes when fracture displacement of up to 2 mm is achieved, and we prefer an open anatomic reduction for displacement of 2 mm or greater.

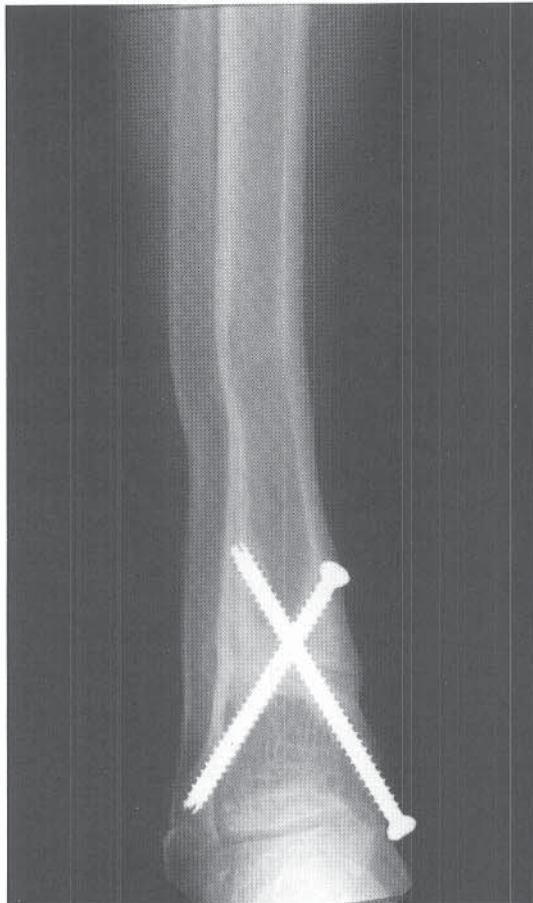When a closed reduction is attempted, the maneuver includes internal rotation of the foot, to allow the anterior tibiofibular ligament to relax, together with digital pressure applied to the distal tibial epiphyseal fragment. This reduction should be performed while the patient is under conscious sedation or general anesthesia. An above-knee cast can then be applied with the foot internally rotated to maintain fracture reduction. Following the reduction maneuver, radiographs should be obtained as an initial screening measure to evaluate the amount of displacement of the fracture fragment on mortise and lateral views of the ankle. If it is clear that the initial reduction is not within 2 mm of the anatomic position, the surgeon should proceed to an open reduction and internal fixation of the fracture. Acceptable reduction has been defined as within 2 mm of the anatomic position



A



B



C

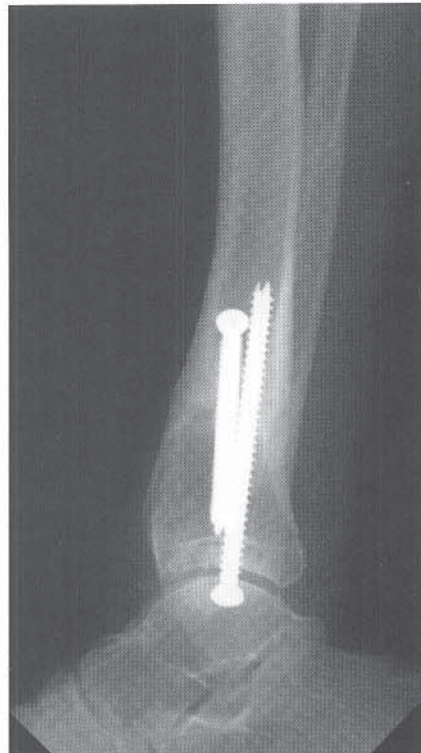

FIGURE 42-179 See legend on opposite page

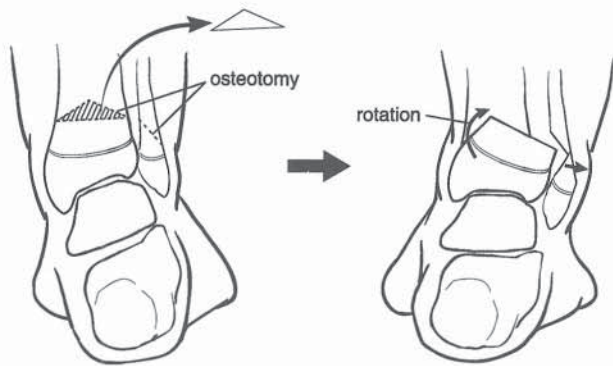


FIGURE 42-180 The Wiltse-type distal tibial osteotomy for a valgus deformity.

to prevent early degenerative arthritis. Frequently, however, fracture reduction is difficult to adequately assess, in part because the fracture fragments are obscured by the cast. A postreduction CT scan best quantifies the amount of residual fracture displacement and makes the decision of whether or not to perform an open reduction more definitive. If an acceptable closed reduction is achieved, an above-knee cast should be worn for 3 to 4 weeks. It is changed to a short-leg cast, at which time the foot can be brought to a plantigrade position, for an additional 3 weeks. Serial radiographs to include a mortise view should be obtained to assess the reduction and compare it with the original one.

The indications for open reduction and internal fixation are fracture displacement of more than 2 mm following an attempt at a closed reduction or if the fracture is seen more than 2 to 3 days following injury with more than 2 mm of fracture displacement. The 2 mm of fracture displacement has always been used as the threshold for performing an open reduction, despite the lack of long-term studies on the incidence of early degenerative arthritis. Also, it is difficult to accurately define the amount of fracture displacement on plain radiographs. In our experience, in fractures that are displaced 2 mm or more at the time of the initial evaluation, the initial reduction attempt usually fails or an acceptable reduction is not maintained, and an open procedure is necessary. Fractures with less than 2 mm of displacement can be treated by closed reduction and an above-knee cast. Some argue that an anatomic reduction of the articular surface must be achieved to prevent ankle instability, joint incongruity, and subsequent early degenerative arthritis.²⁰⁴ We prefer an open reduction in all Tillaux fractures that have 2 mm or more of fracture displacement because an open reduction with stable fixation is a relatively small procedure that reproducibly achieves an anatomic reduction of the articular surface and presumably a good long-term result.

The open reduction is performed through an anterior approach to the ankle between the extensor digitorum lon-

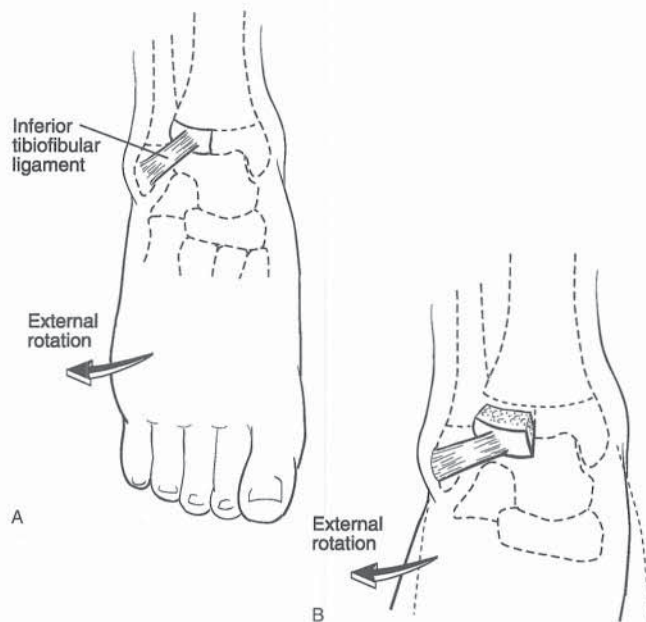


FIGURE 42-181 Tillaux fracture mechanism. A, The inferior tibiofibular ligament travels from the distal fibula to the distal lateral tibial epiphysis. B, When an external rotational force is applied, the distal tibial epiphysis is avulsed.

gus and extensor hallucis tendon interval to allow direct observation of the fracture fragment (Fig. 42-183). Following fracture hematoma evacuation and inspection of the articular surface of the talar dome, the foot is positioned in internal rotation and the fracture is reduced. It is most important to restore the articular surface of the distal tibia anatomically, and this is best visualized directly anteriorly. In addition, the physeal fracture line should be anatomically restored to ensure that the posterior aspect of the articular surface is anatomically reduced. Following reduction, we prefer fixation with a single 4.0-mm partially threaded cancellous screw placed from anterolateral to posteromedial (Fig. 42-184). It may be necessary to place a small Kirschner wire temporarily while the screw hole is drilled, tapped, and filled with a cancellous screw, to prevent rotation while the fragment is fixed. It is not necessary to avoid the remaining aspect of the open physis during the internal fixation of these fractures, since physeal closure is near completion. A short-leg nonweightbearing cast should be worn for 6 weeks postoperatively. Percutaneous reduction and fixation has been described for these fractures, with good results in six patients.¹⁹⁴

The outcome of Tillaux fractures is generally very good in the short-term period. Kleiger and Mankin reported on four true Tillaux fractures, two of which needed an open reduction and internal fixation to achieve an adequate reduction while the two remaining patients had a satisfactory

FIGURE 42-179 Corrective opening wedge osteotomy of the distal tibia to correct significant varus deformity. A, Injury radiograph. A 13-year-old boy was involved in a motor vehicle accident, sustaining multiple fractures. He had two episodes of fractures on the right distal tibia associated with a growth arrest, leaving him with a varus deformity. B, An opening wedge osteotomy using iliac crest bone fixed with crossed cannulated screws was performed. C, At 1 year the deformity had corrected and the tibia had healed.

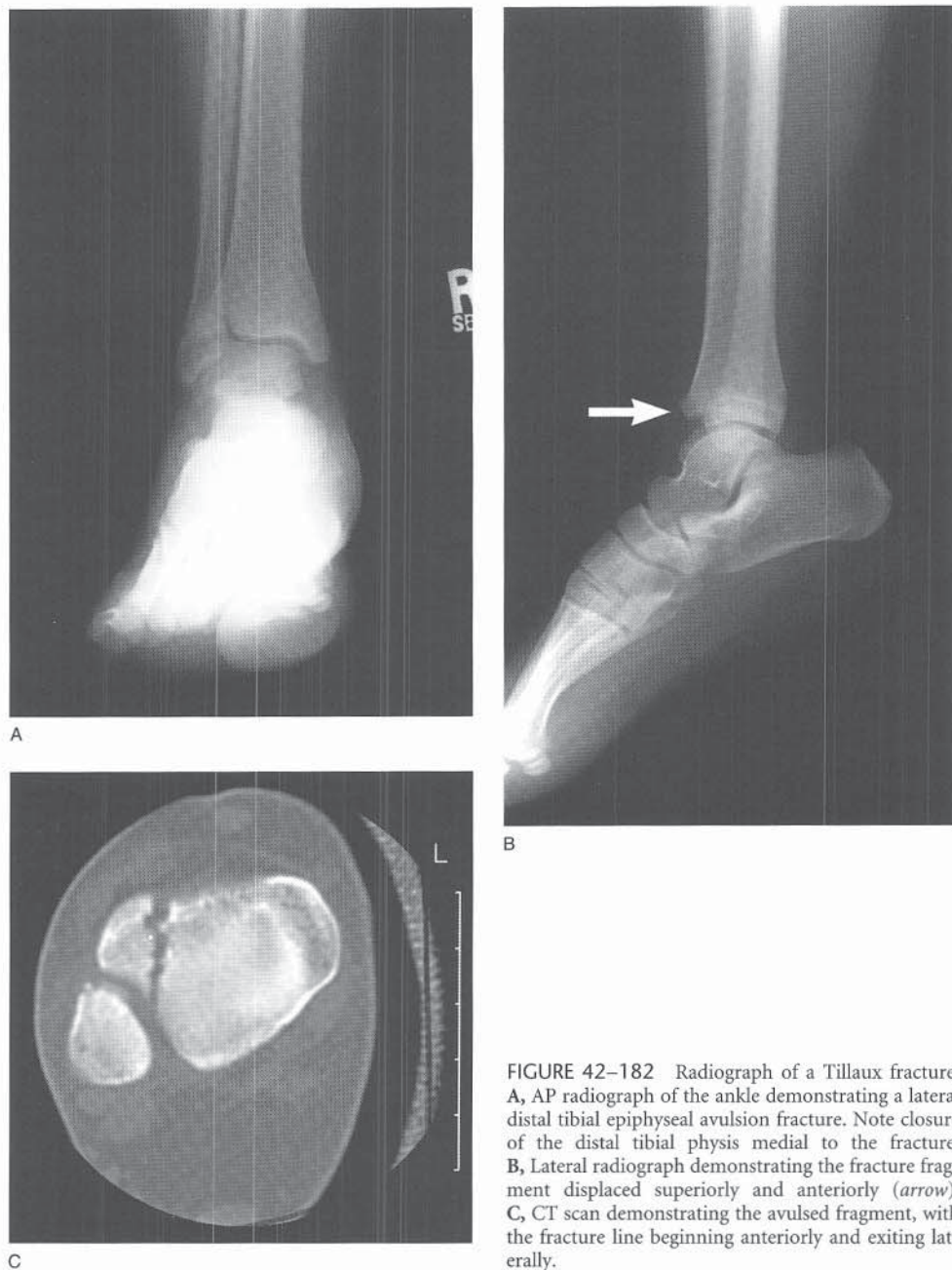

FIGURE 42-182 Radiograph of a Tillaux fracture. A, AP radiograph of the ankle demonstrating a lateral distal tibial epiphyseal avulsion fracture. Note closure of the distal tibial physis medial to the fracture. B, Lateral radiograph demonstrating the fracture fragment displaced superiorly and anteriorly (*arrow*). C, CT scan demonstrating the avulsed fragment, with the fracture line beginning anteriorly and exiting laterally.

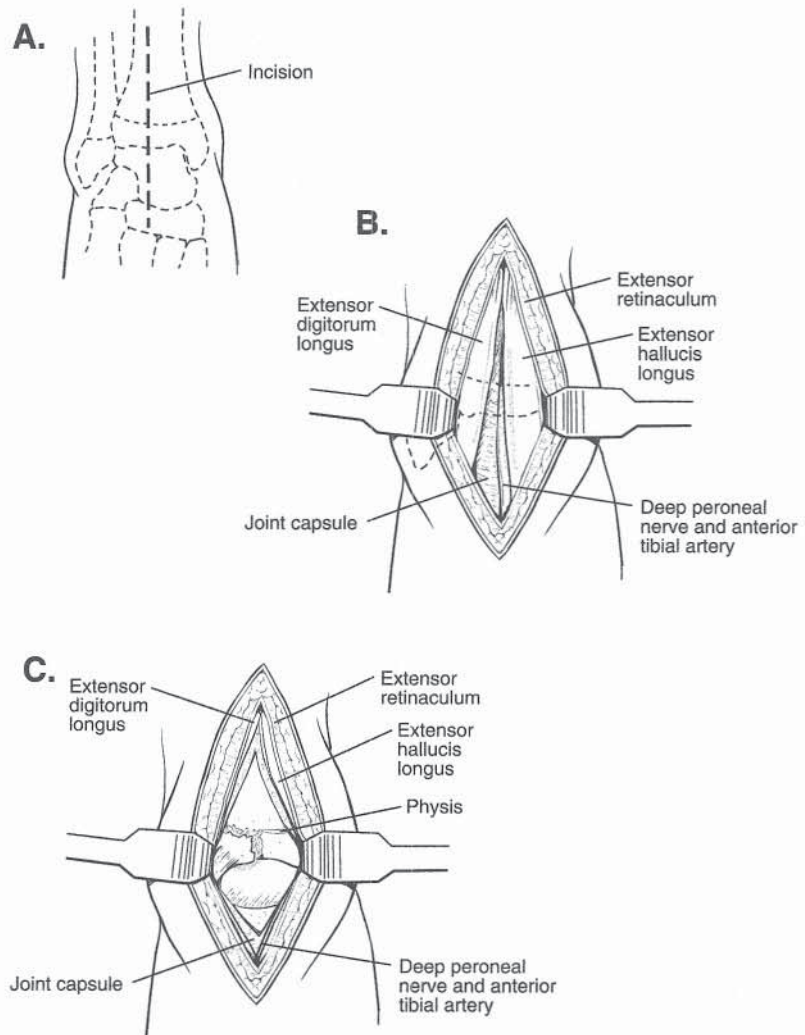


FIGURE 42-183 The anterior approach to the ankle for reduction of the Tillaux fracture. **A**, A midline anterior incision is made directly over the ankle joint. **B**, The interval between the extensor digitorum longus and the extensor hallucis longus is developed. The surgeon carefully identifies the deep peroneal nerve and anterior tibial artery. **C**, The interval is enlarged and the neurovascular bundle is retracted medially. The capsule is incised and the fracture is easily identified.

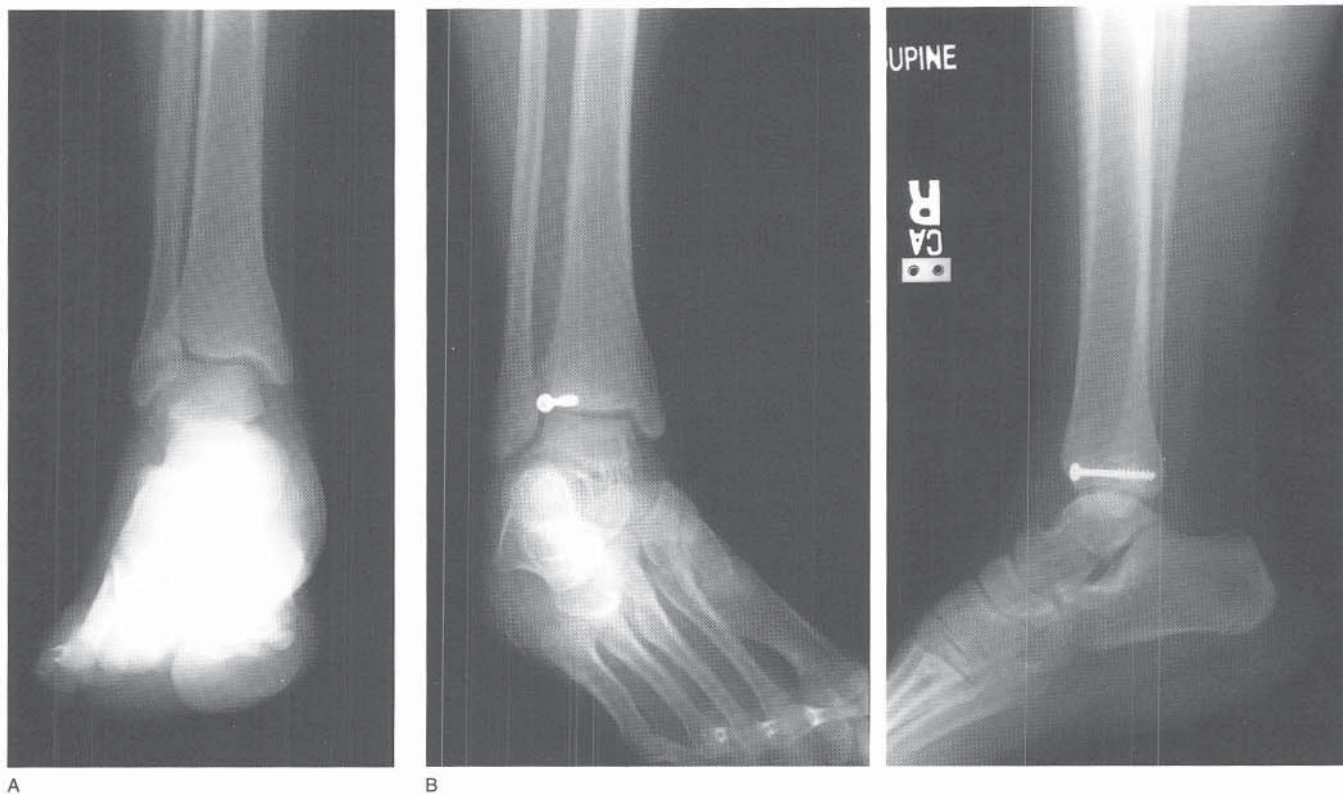


FIGURE 42-184 Open reduction and internal fixation of a Tillaux fracture. A, AP radiograph. B, Mortise and lateral views after an anatomic reduction with single screw fixation.

closed reduction and all four fractures healed with satisfactory outcome at 1 year.¹⁰⁴ Letts reported on 26 patients; eight required an open reduction and internal fixation with smooth Kirschner wires. There were no complications at an average follow-up of 2.5 years.¹²² Dias and Giegerich reported nine cases.⁵⁴ Five patients were treated with closed reduction and casting, and four had more than 2 mm of displacement following an attempt at closed reduction and then underwent an open reduction and internal fixation. All patients had full, pain-free ankle motion with a healed fracture at 18- to 36-month follow-up.⁵⁴

TRIPLANE FRACTURES. Although it was initially described by Marmor,¹³⁵ this fracture was best described by Lynn who coined the term “triplane fracture” in 1972.¹³² Others subsequently described similar cases in which the fracture lines occurred in the coronal, transverse, and sagittal planes.* This is a relatively rare fracture, occurring in approximately 6 to 8 percent of all distal tibial physeal injuries in children.^{42,54,203} These injuries occur in the adolescent age group, generally slightly younger than the child with a Tillaux fracture, with an average age of approximately 13.5 years (range, 10 to 16 years).⁴² Because the distal tibial physis closes earlier in females, usually girls with a triplane fracture are younger than boys, by approximately 1 year.⁶¹ The mechanism of injury is thought to be an external rotation force applied to a supinated foot. This is supported by the fact that these fractures tend to reduce, at least partially, with internal rotation of the foot, and residual deformity with an incom-

plete reduction results in slight external rotation to the leg.^{42,54,61}

The triplane fracture is so named because the fracture lines occur in three planes. The coronal fracture line begins in the physis and travels proximally through the posterior metaphysis; the sagittal fracture travels from the midjoint line to the physis, resulting in an anteromedial and often anterolateral fragment; and the transverse fracture travels through the physis (Fig. 42-185). These fracture lines can result in either a two-part or three-part triplane fracture (Fig. 42-186). In the two-part fracture, the medial fragment consists of the tibial shaft, the medial malleolus, and the anteromedial aspect of the epiphysis; the lateral fragment includes the remainder of the epiphysis and the posterior aspect of the metaphysis. In the three-part fracture the medial fragment remains the same and the lateral fragment is

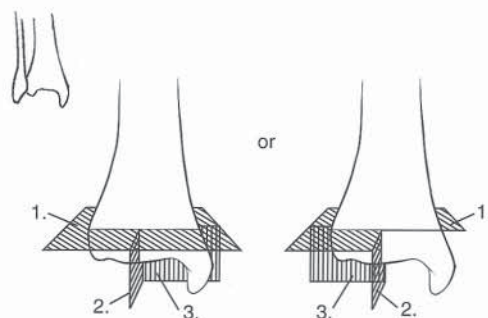


FIGURE 42-185 The triplane fracture pattern. Note the three planes in which the fracture occurs: 1, axial plane; 2, sagittal plane; 3, frontal plane.

*See references 42, 44, 52, 54, 61, 65, 102, 133, 161, 216, 222, 225.

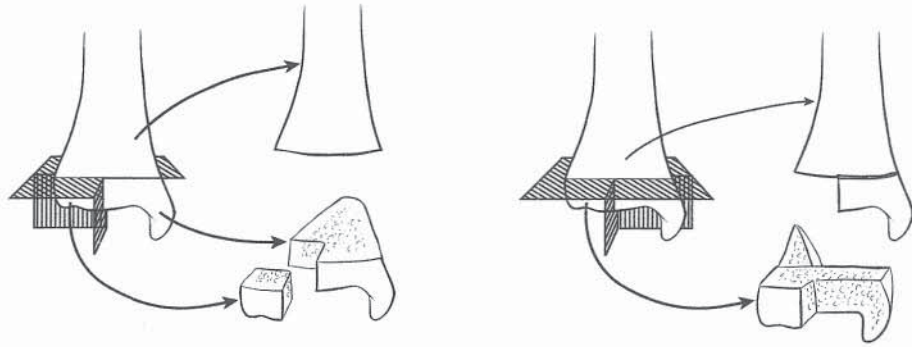


FIGURE 42-186 The triplane fracture can be two-part or three-part.

in two parts, with the rectangular anterolateral quadrant of the epiphysis as a separate fragment. Further variants of this fracture include the four-part fracture and the extra-articular triplane fracture, in which the fracture travels through the medial malleolus.* Cooperman and colleagues used tomography in five of the 15 cases to demonstrate the two-part fracture: a medial fragment, which included the tibial shaft, medial malleolus, and an anteromedial fragment of the epiphysis, and a lateral fragment, which included the posterior metaphysis and the remainder of the epiphysis.⁴² Dias and Giegerich reported that six of eight patients had a three-part triplane fracture and two had the two-part triplane fracture described by Cooperman.⁵⁴ In the largest series of patients reported to date, Ertl and colleagues reported on 23 fractures. In 15 cases the anatomic configuration of the fracture was confirmed: 11 were three-part fractures and four were two-part fractures.⁶¹ An extra-articular triplane fracture or intra-articular fracture in the nonweightbearing zone has been described; in these cases the fracture line travels in the sagittal plane, exiting through the anterior medial malleolus, while the transverse fracture occurs through the physis and the coronal fracture occurs through the posterior metaphysis of the distal tibia (Fig. 42-187).^{65,198} It is important to recognize this particular variant of the triplane fracture since it can be successfully treated with a closed reduction.

The patient typically presents following a twisting injury of the foot. Most injuries occur during participation in sports, but they may be due to a fall from a height or a twisting injury sustained while walking. Of 23 fractures, 15 occurred during sporting activities, four resulted from a fall from a height, three from stepping into a hole or off a curb while walking, and one patient was involved in a motor vehicle accident.⁶¹

Radiographic examination of these fractures should include AP, lateral, and mortise views of the ankle, for a Salter-Harris type III fracture is demonstrated on the AP radiograph and a Salter-Harris type II fracture is demonstrated on the lateral radiograph (Fig. 42-188). The vertical fracture line in the sagittal plane travels up from the articular surface and enters the physis, then extends out the physis laterally. The vertical component of the fracture line is usually in the center of the tibia, although it may be just medial to the midline and is most often displaced. Ertl and colleagues described eight patients with less than 2 mm of displacement and 15 patients with more than 2 mm of

displacement.⁶¹ Occasionally the fracture lines are difficult to see on plain radiographs, especially when good ankle radiographs are not obtained at the time of the initial evaluation. The fibula is fractured in approximately 50 percent of all triplane fractures.⁶¹ The mortise view better demonstrates the epiphyseal sagittal fracture line and best defines the amount of fracture displacement. Further evaluation of these fractures is best done with CT to assess the amount of articular surface step-off both before and after treatment, especially when a closed reduction is attempted (Fig. 42-189).

The principal goal in the treatment of triplane fractures is to achieve an anatomic reduction of the distal tibial articular surface, since long-term follow-up indicates painful symptoms and early degenerative arthritis when an anatomic reduction is not achieved. Ertl and colleagues reported short- (3-year) and long-term (up to 13 years) follow-up of patients following treatment of triplane fractures and found a significant decline in satisfactory results, especially in patients who had more than 1 mm of fracture displacement.⁶¹ They further found that three of eight minimally displaced fractures treated by closed reduction and casting declined an outcome grade (e.g., excellent to good, good to fair) between the 3-year follow-up and the final follow-up (averaging 6 years).⁶¹

Most authors recommend nonoperative treatment of those fractures with minimal or mild displacement, less than 2 mm. In these cases a closed reduction can be performed with axial traction placed on the ankle and internal rotation of the foot with the patient under general anesthesia.⁵⁴ The patient is placed in a long-leg nonweightbearing cast with the foot internally rotated for 3 to 4 weeks, followed by a short-leg cast for an additional 2 to 3 weeks. Following a closed reduction, lateral and mortise views should be obtained to confirm an adequate reduction. If the fracture can be adequately seen on the plain radiographs, a residual fracture displacement of less than 2 mm is acceptable, although we prefer an anatomic reduction at the time of the initial reduction to allow for some mild displacement, which is likely to occur in the cast with time. In addition, one can argue that a successful closed reduction in the operating room should be followed by single smooth Kirschner wire or screw fixation of the articular fragment to provide more secure fixation and less risk for future fracture displacement. This can be done percutaneously or through a small, 2- to 3-cm arthrotomy.

It is difficult to accurately assess mild displacement in the distal articular surface of the tibia using plain radiographs

*See references 42, 52, 65, 102, 161, 198, 222.

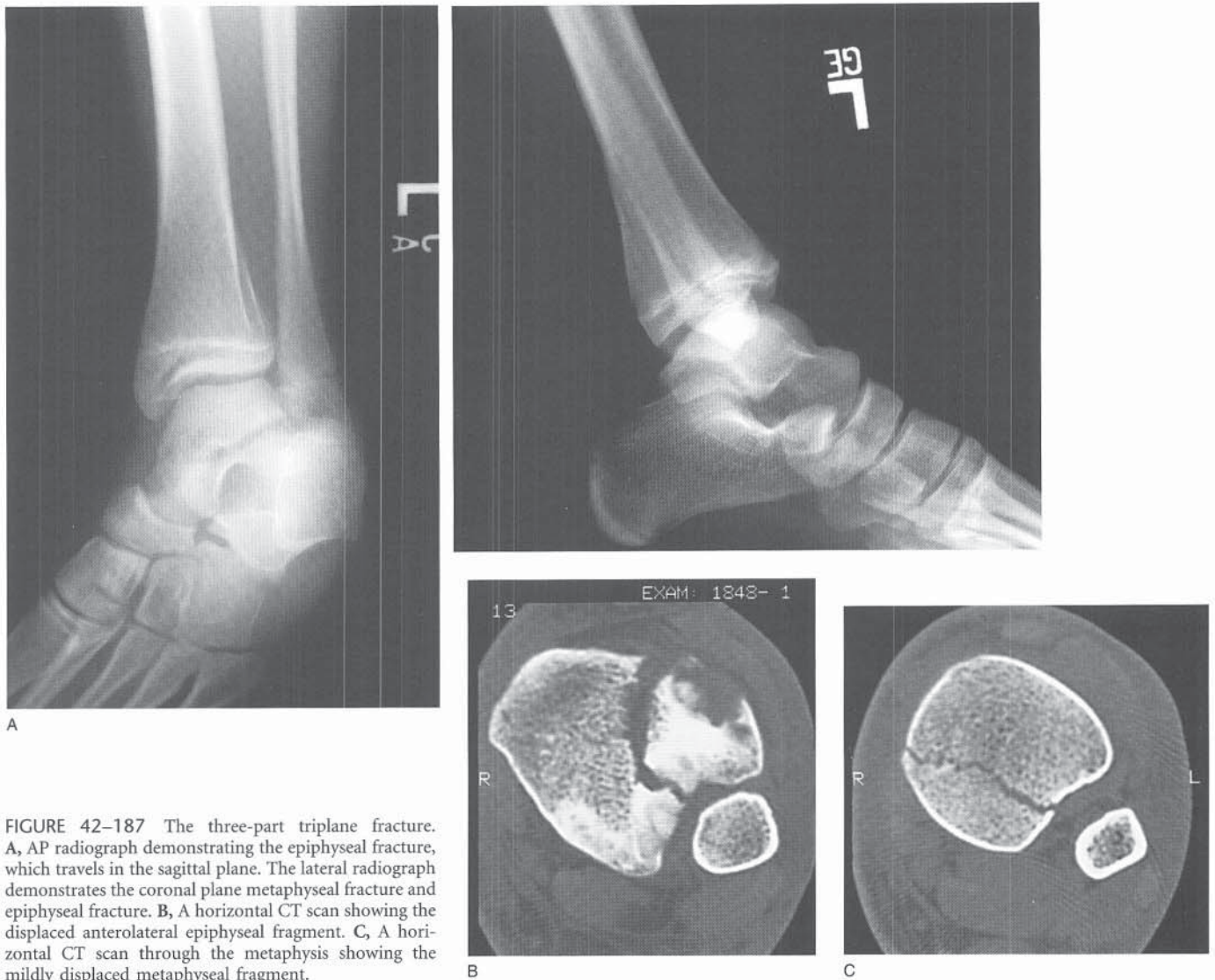


FIGURE 42-187 The three-part triplane fracture. A, AP radiograph demonstrating the epiphyseal fracture, which travels in the sagittal plane. The lateral radiograph demonstrates the coronal plane metaphyseal fracture and epiphyseal fracture. B, A horizontal CT scan showing the displaced anterolateral epiphyseal fragment. C, A horizontal CT scan through the metaphysis showing the mildly displaced metaphyseal fragment.

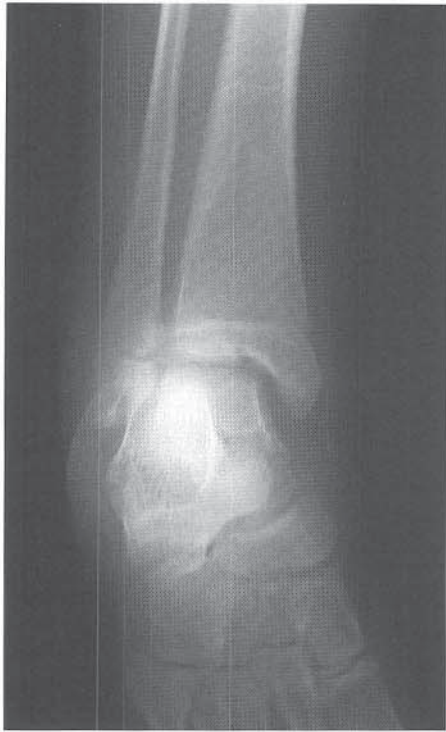alone, and we prefer to obtain a CT scan following any closed reduction to confirm a near-anatomic reduction. It is important to obtain serial weekly radiographs following the initial reduction to ensure that an unacceptable loss of reduction has not occurred during this period of time. It may be also necessary to repeat the CT study at 1 week so that an open reduction and internal fixation can be performed if loss of reduction has occurred. An associated greenstick or displaced fracture of the fibula makes reduction difficult, as the strong ligamentous attachments to the fibula maintain the angular deformity and the resultant shortening of the attached tibial fragment, making it necessary to reduce the fibular fracture prior to attempting any reduction of the tibia.⁴²

When the fracture displacement is more than 3 mm at the time of the initial evaluation, the likelihood of achieving an acceptable reduction is low, owing to the energy imparted at the time of injury, soft tissue swelling, and soft tissue interposition at the fracture site. Of five fractures with displacement of more than 3 mm, no patient had a successful closed reduction, and at the time of open reduction, inter-

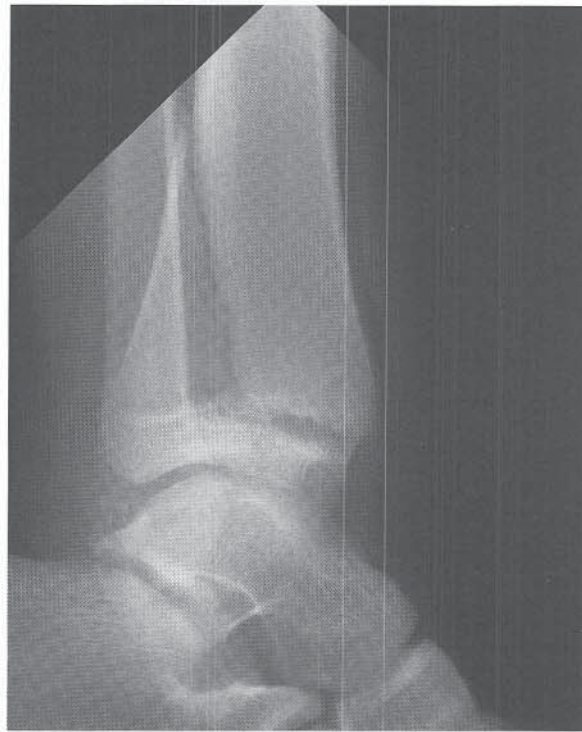posed soft tissue consisting of periosteum or the extensor hallucis longus tendon was present at the fracture site.⁶¹

The extra-articular triplane fracture is recognized by the two-part nature of the fracture in which the sagittal fracture exits the anterior medial malleolus, the axial fracture travels through the physis, and the coronal fracture travels through the posterior metaphysis.^{65,222} These fractures can be treated by closed reduction and long-leg casting for 4 weeks, followed by short-leg casting for 2 weeks, since they are extra-articular.⁶⁵ A variant of this fracture pattern was recently described as three types of intramalleolar triplane fractures: an intra-articular fracture within the weightbearing zone, which may require operative intervention; an intra-articular fracture outside the weightbearing zone; and an extra-articular fracture. The latter two can be treated with a closed reduction.¹⁹⁸

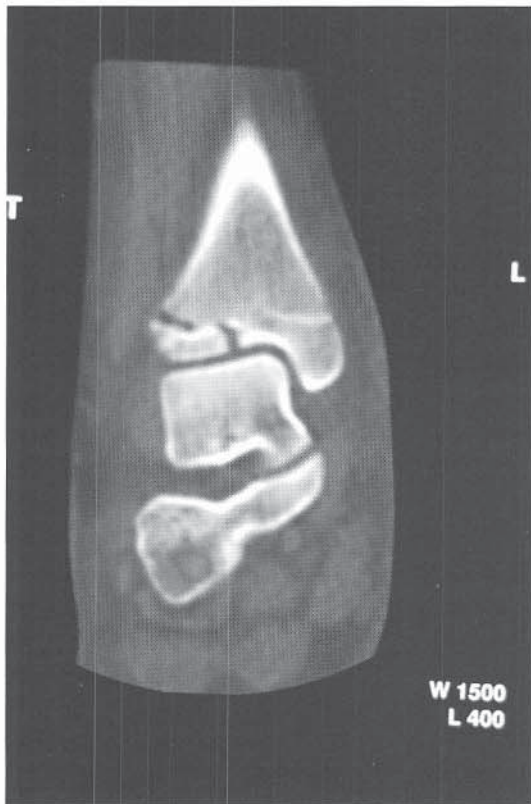The indications for open reduction and internal fixation are failure to achieve an adequate reduction (to within 2 mm of the anatomic position) and a displaced fracture (more than 3 mm) at the time of the initial evaluation. The preoperative assessment should include a thorough physical exami-



A



B



C

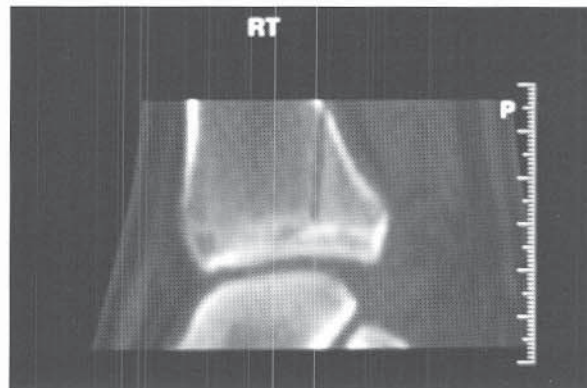


FIGURE 42-188 The typical radiographic examination of the triplane fracture. **A**, On the AP radiograph, a Salter-Harris type III fracture pattern is seen. **B**, On the lateral radiograph, a Salter-Harris type II fracture pattern is seen. **C**, The triplane fracture is well seen on these coronal and sagittal plane CT scans.

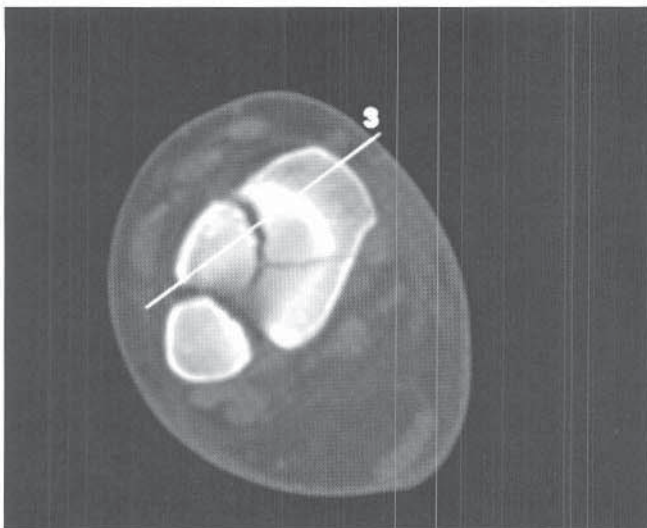


FIGURE 42-189 CT scan of a triplane fracture. Note the fracture is similar to a Tillaux fracture, running from the anterior cortex out laterally. The second fracture line seen runs from anterior to posterior. There is minimal displacement of this fracture.

nation with special emphasis on the status of the soft tissue envelope, since significant swelling can occur with these fractures and should resolve prior to performing an open reduction. The method of operative intervention depends on the fracture pattern and the degree of displacement. This should be assessed on plain films and CT.

When the Salter-Harris type II posterior fragment is minimally displaced or when there is a two-part fracture, then an anterior exposure of the ankle is the only necessary operative incision (Fig. 42-190). These fractures are usually not associated with a fracture of the fibula. The fracture hematoma is removed and the fracture is reduced with internal rotation of the foot followed by compression across the fracture site using a bone reduction forceps. A small stab incision is then made over the medial malleolus and a 4.0-mm cancellous screw is placed under fluoroscopic visualization. Cannulated systems can be used; however, we prefer the small-fragment 4.0-mm cancellous screw to obtain better purchase and reduce the risk of pin breakage with the smaller cannulated screw systems. Arthroscopic visualization has been used in two patients with two-part fractures to allow direct visualization during hematoma evacuation and fracture reduction, with good results.²²⁵ A short-leg cast with the foot internally rotated should be worn for 6 weeks after anatomic reduction and stable internal fixation. If there is any concern about the purchase or reliability of the screw fixation, a long-leg cast should be worn for the initial 4 weeks, followed by a short-leg cast for 2 to 3 weeks.

The displaced triplane fracture with a large displaced Salter-Harris type II metaphyseal fragment, often associated with a fibular fracture, requires a more extensive operative procedure with reduction of the fragments. The initial incision is an anterior approach to the ankle with visualization and manual displacement of the anterolateral epiphyseal fragment. Next, a closed reduction of the posterior metaphyseal fragment should be attempted with direct compression and internal rotation of the foot, which can be assessed fluoroscopically. A second attempt at a reduction can be

made using a Weber bone reduction forceps placed through a stab incision in the posterolateral aspect of the ankle, just lateral to the Achilles tendon (Fig. 42-191). If neither of these techniques is successful, then an open reduction with direct visualization of the fracture fragment should be performed through a posterolateral incision, lateral to the Achilles tendon, developing the interval between the flexor hallucis longus and the peroneus brevis (Fig. 42-192). The fracture is then reduced under direct vision, held with a bone-reduction forceps, and internally fixed with one or two cancellous screws placed from anterior to posterior. The fibular fracture should be reduced temporarily during the reduction maneuver of the posterior metaphyseal fragment and re-reduced if necessary following internal fixation of the posterior fragment. The last fragment to be reduced is the anterolateral epiphyseal fragment, which can be reduced under direct vision and fixed as described previously. The leg should be placed into a long-leg nonweightbearing cast for 4 weeks, followed by a short-leg cast for an additional 2 to 3 weeks.

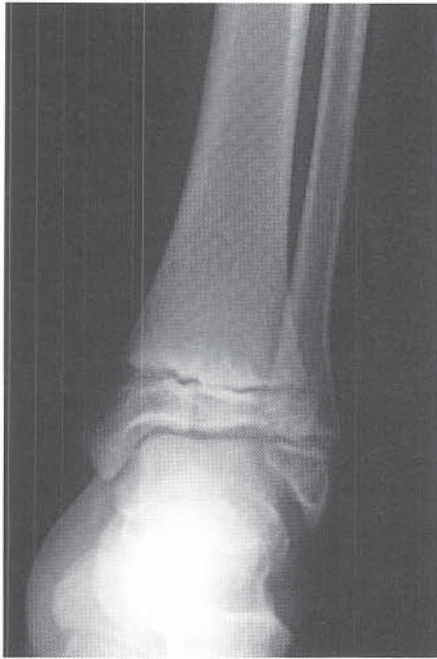The results of treatment of triplane fractures are generally good in the short term.* Patients generally return to their preinjury level of activities without symptoms. The long-term outcome of these fractures, however, is not fully defined. The only study examining the relatively long-term outcome of treatment of triplane fractures noted a deterioration in successful results between the early results at 3 years and the final results (averaging just over 6 years), with pain and swelling the most common reasons for the decline in outcome.⁶¹ This is postulated to be due to several factors. First, it is generally accepted that less than 2 mm of fracture displacement is acceptable, leading to good results; however, three of eight patients with minimally displaced fractures at the time of injury had a deterioration in outcome between year 3 and year 6 follow-up. Second, loss of reduction may have occurred during the immobilization period of some fractures and was not assessed by the more accurate CT in those cases. Third, in some severely displaced fractures function deteriorated over time despite an anatomic reduction achieved through an open reduction followed by stable internal fixation, suggesting significant articular cartilage damage at the time of the initial injury.

The Foot

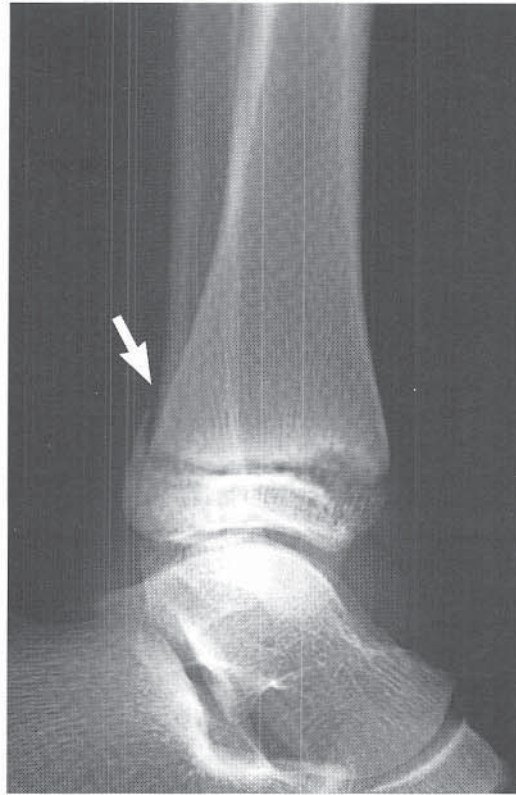TALAR FRACTURES

Fractures of the talus in children are very rare, accounting for less than 10 percent of all talar fractures reported in the literature. Fractures of the neck of the talus are more common and generally have a better prognosis than talar body fractures. The mechanism of injury is usually a fall from a height with a forced dorsiflexion injury at the ankle with some supination component to the injury, resulting in associated malleolar fractures. The diagnosis is often difficult to make in the young child because of mild radiographic changes at the initial visit. Treatment in the young child is usually nonoperative, with cast immobilization producing good results. In the adolescent, treatment is similar to that

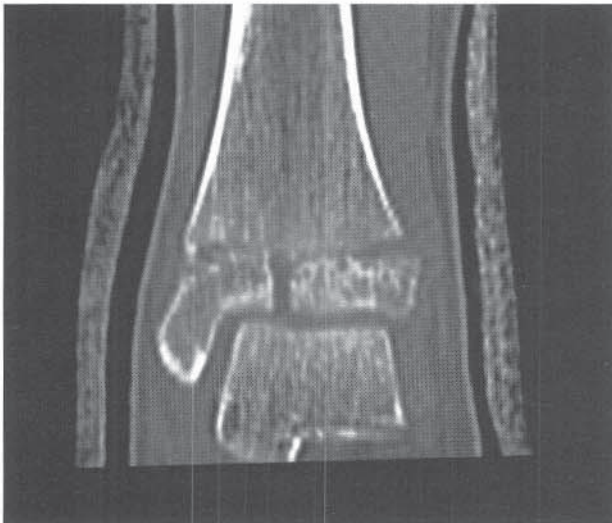
*See references 39, 42, 44, 54, 102, 106, 132, 161, 203, 216, 222.



A

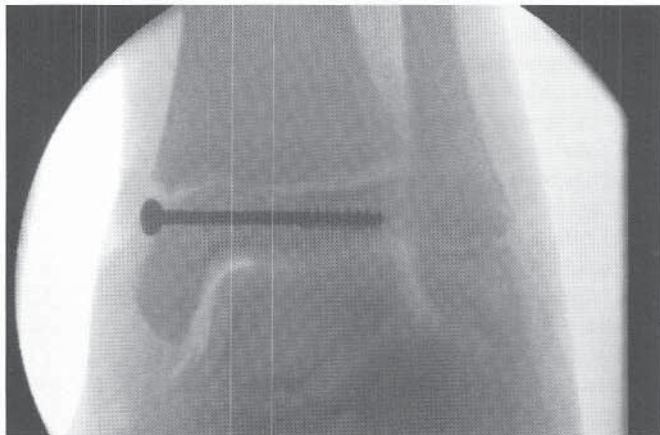
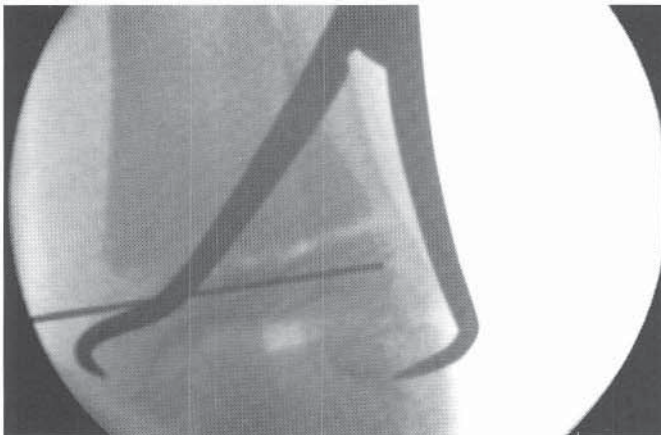


B



C

FIGURE 42-190 Open reduction and internal fixation of a triplane fracture. **A**, AP radiograph demonstrating the Salter-Harris type III fracture pattern in the tibial epiphysis. There is approximately 4 mm of displacement. **B**, The lateral radiograph does not show an obvious Salter-Harris type II pattern. However, the Salter-Harris type II fracture pattern of the distal fibula is apparent (*arrow*). **C**, The CT scan demonstrates the intra-articular fracture with displacement. **D**, Intraoperative radiographs obtained after an open reduction with cannulated screw fixation. A Weber clamp was placed to compress the fracture site, which was viewed directly with an open approach. The guide pin was then placed across under fluoroscopic guidance.



D

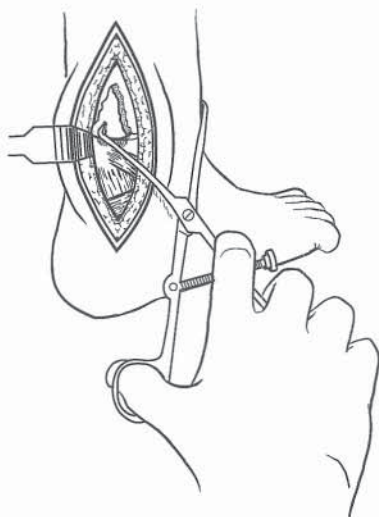


FIGURE 42–191 Reduction of posterior metaphyseal fragmented and displaced triplane fracture. The fracture can be reduced with a Weber bone reduction forceps directly on the posterior metaphyseal fragment, and by making a small stab incision in the anterior tibia to gain reduction.

for adults, with similar results and a high risk of AVN in the displaced fracture.

Anatomy. The talus is the transition bone between the foot and the leg. It is divided anatomically into the body, the neck, and the head. The superior dome of the talar body articulates with the distal tibial articular surface and has a quadrilateral surface, which is wider anteriorly than posteriorly and is composed of the medial and lateral facets. From front to back the talar dome is convex; from side to side it is slightly concave (Fig. 42–193). The neck is relatively short and is the only surface of the talus not covered by articular cartilage, allowing passage of nutrient blood vessels to the body. The lateral process of the talus is a large, wedge-shaped prominence that is covered with articular cartilage. It articulates with the fibula superolaterally and with the lateralmost portion of the subtalar joint inferiorly (Fig. 42–194). The distal end of the lateral process is the origin of the lateral talocalcaneal ligament.^{82,84} The posterior region of the talus often exhibits a radiographically separate ossification center, which occurs at 11 to 13 years in boys and 8 to 10 years in girls and usually fuses to the talus 1 year after its appearance.¹⁴² The inferior surface is composed of three facets that articulate with the superior aspect of the calcaneus.

The blood supply to the talus has been well studied. It is susceptible to injury following the displaced talar neck or body fracture, with subsequent development of AVN.* There are four main sources of extraosseous blood supply, branches of the posterior tibial, anterior tibial, and the peroneal arteries (Fig. 42–195). The first is the artery of the tarsal canal, which branches from the posterior tibial artery approximately 1 cm proximal to the origin of the medial and lateral plantar arteries and passes between the tendon sheaths of the flexor digitorum longus and the flexor hallucis longus tendons. There it enters the tarsal canal, which is formed by the sulci of the talus and calcaneus and narrows

from posteromedial to anterolateral. Branches of this artery are given off in the canal to supply the body of the talus. The second source of blood supply is the deltoid branch of the artery of the tarsal canal, which travels between the talotibial and talocalcaneal aspects of the deltoid ligament and supplies the medial periosteal surface of the body; anastomoses with the dorsalis pedis artery occur. The third major source of blood supply is the arterial branches to the dorsal neck, which arise from the anastomoses between branches of the dorsalis pedis artery (extension of the anterior tibial artery). Finally, the artery of the sinus tarsi, primarily a branch of the perforating peroneal artery, supplies the lateral aspect of the talus. A rich intraosseous blood supply is present within the talus; in a simulated fracture model this blood supply becomes compromised.^{166–168}

Classification. Talus fractures can be broadly divided into talar neck fractures and talar body fractures. A further division of the more common talar neck fractures was first described by Hawkins in 1970. His three-part classification was primarily based on the amount of fracture displacement and provided information on the prognosis for AVN.⁸³ This classification was later modified by Canale to include a fourth type (Fig. 42–196).³² The type I injury is an undisplaced vertical fracture of the talar neck. A type II fracture is a displaced fracture; the subtalar joint is subluxed or dislocated but the ankle joint is normal. The type III injury is similar to the type II injury; however, there is a subluxation or dislocation of both the ankle and subtalar joints. The type IV injury is very rare and is characterized by dislocation of the talar head from the talonavicular joint. In adults, type II and III fractures are most common, accounting for approximately 75 to 90 percent of all talar neck fractures.^{32,83}

Fractures of the body of the talus were first classified, in 1977, by Sneppen and colleagues,²⁰² whose classification was later modified by Delee⁵¹ into a five-part classification: type I, transchondral dome fractures; type II, shear fractures; type III, posterior tubercle fractures; type IV, lateral process fractures; type V, crush fractures (Fig. 42–197).

Children's talar fractures are probably best classified according to the age of the child, with children younger than 6 years having a better prognosis than older children.¹³⁹ Treatment of talar fractures in younger children is more often nonoperative, with generally good results, while talar fractures in older children are best addressed as talar fractures in adults.

Mechanism of Injury. Most talar neck fractures in children are due to falls from a height, with a dorsiflexion injury of the ankle.^{93,123,139} The excess dorsiflexion and axial loading result in a dorsally directed shear force exerted against the sole of the foot while the body of the talus is fixed between the tibia and the calcaneus. The fracture line typically occurs in a vertical or slightly oblique direction between the middle and posterior subtalar facets, with displacement of the distal fragment superiorly and medially.³² One reason why these injuries are uncommon is that high-energy forces are usually necessary to produce them, estimated to be approximately twice the force needed to produce a calcaneal or navicular fracture.¹⁶⁹

Diagnostic Features. A history of a fall with axial loading of the ankle, followed by pain and swelling in the area of

*See references 80, 103, 151, 166, 167, 226.

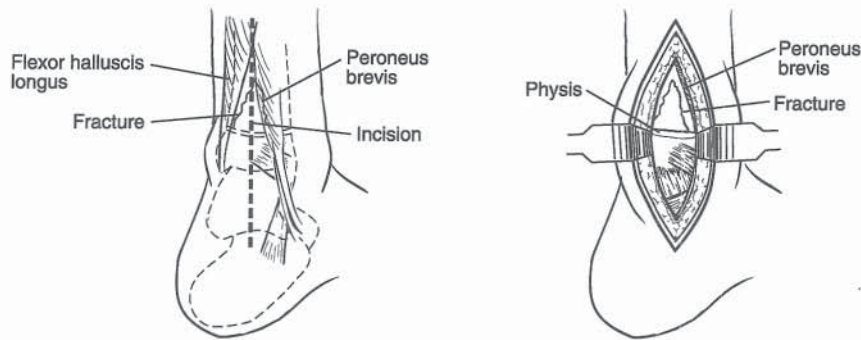


FIGURE 42-192 The approach to the posterior metaphyseal fragment in a triplane fracture. An incision is made in the posterolateral aspect of the distal ankle. The interval between the peroneus brevis and the flexor hallucis longus muscles is developed. The capsule is incised and the fracture is identified.

the talus, should alert the physician to the possibility of a talus fracture. The child is usually unable to bear weight on the affected extremity, and the physical examination reveals ankle effusion and pain on motion of the ankle joint, especially dorsiflexion. The patient with a displaced talar neck fracture and fractures of one or more malleoli presents in significant pain and with massive swelling in the region of the talus and the ankle. In a young child a talar fracture may be difficult to diagnose, especially when the talus has not fully ossified. Mazel and associates reported on 23 talar fractures in children, dividing them into two groups based on the age of the patient.¹³⁹ Fractures in patients less than 6 years old were difficult to diagnose, and when the diagnosis was made the amount of fracture displacement was often underestimated.

Radiographic examination should include AP, lateral, and oblique views centered at the ankle. A pronated oblique radiograph of the talus, first described by Canale and Kelly, is an excellent view to see the talus (Fig. 42-198).³² The foot is placed into equinus, pronated approximately 15 degrees, and the x-ray beam is angled 75 degrees to the horizontal. Associated fractures of the medial and lateral malleoli are seen most commonly with the displaced talar fracture.⁹³ If a talar fracture is suspected but not confirmed on the initial radiographs, CT can be used to identify or confirm the presence of the fracture and the amount of fracture displacement.

Treatment. The treatment of talar fractures in children largely depends on the age of the child and the amount of fracture displacement. Most children younger than 8 with minimally displaced fractures respond well to nonoperative treatment.^{93,123,139,148}

FRACTURES OF THE NECK OF THE TALUS. The treatment of talar neck fractures in children is solely dependent on the amount of displacement and the classification of Hawkins. The majority of talar neck fractures are undisplaced at the time of the initial presentation (Hawkins type I) and should be treated in a short-leg cast for 6 to 8 weeks to allow fracture consolidation. Weightbearing can then be instituted at the time the cast is removed. In the young child with a displaced fracture but without subluxation of the ankle or subtalar joints (Hawkins type II), an attempt at a closed reduction should be made with the patient under conscious sedation or general anesthesia. The definition of an acceptable reduction in children's talar neck fractures has not been established; however, we prefer to attempt a gentle closed reduction of any talar neck fracture with residual angulation of more than 15 to 20 degrees. The distal fragment is usually dorsally and medially displaced, and therefore gentle plantar flexion and pronation of the foot should be performed. The foot may need to remain in some plantar flexion and is placed into a long-leg cast for the initial 4 weeks. The foot can then be brought up to a neutral position and placed in

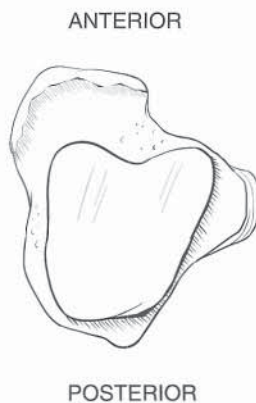

FIGURE 42-193 The superior surface of the talus. Note the increased width of the anterior dome of the talus compared to the posterior dome.

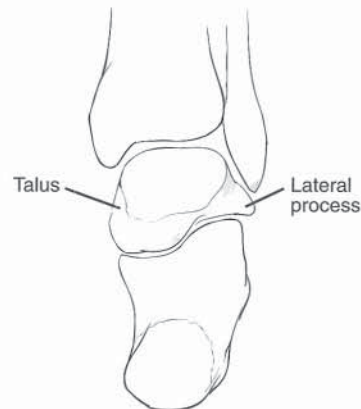


FIGURE 42-194 The lateral process of the talus. Note its articulation with both the fibula and the calcaneus.

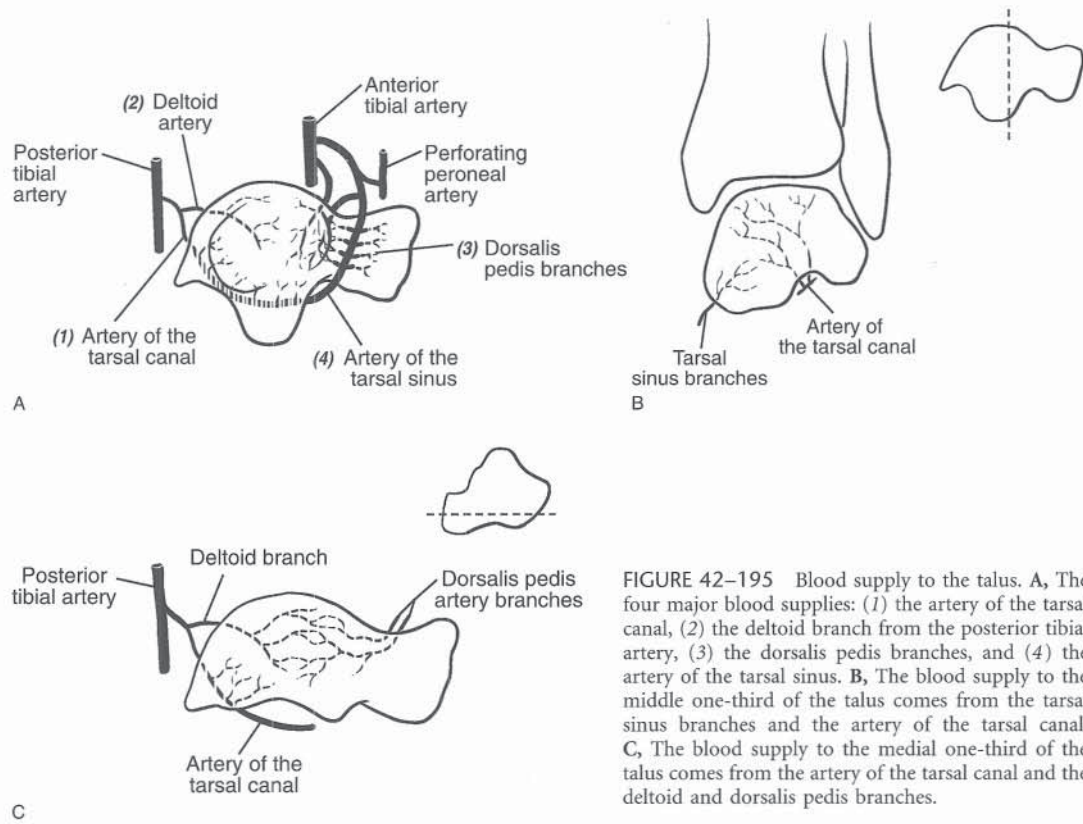


FIGURE 42-195 Blood supply to the talus. **A**, The four major blood supplies: (1) the artery of the tarsal canal, (2) the deltoid branch from the posterior tibial artery, (3) the dorsalis pedis branches, and (4) the artery of the tarsal sinus. **B**, The blood supply to the middle one-third of the talus comes from the tarsal sinus branches and the artery of the tarsal canal. **C**, The blood supply to the medial one-third of the talus comes from the artery of the tarsal canal and the deltoid and dorsalis pedis branches.

a short-leg cast for an additional 3 to 4 weeks. If the fracture cannot be reduced to within 15 to 20 degrees on the initial attempt at a closed reduction, then an open reduction should be performed.

Children older than 10 years with talar neck fractures should be treated as adults with this injury. The type I fracture in an older child can usually be treated in a short-

leg cast with the foot in slight plantar flexion and inversion for 6 to 8 weeks, until fracture healing has occurred. The majority of displaced fractures (Hawkins type II and III fractures) occur in older children and should be treated as in adults, with open reduction and internal fixation. Reduction of type II fractures can often be achieved using closed methods; however, because of significant soft tissue dis-

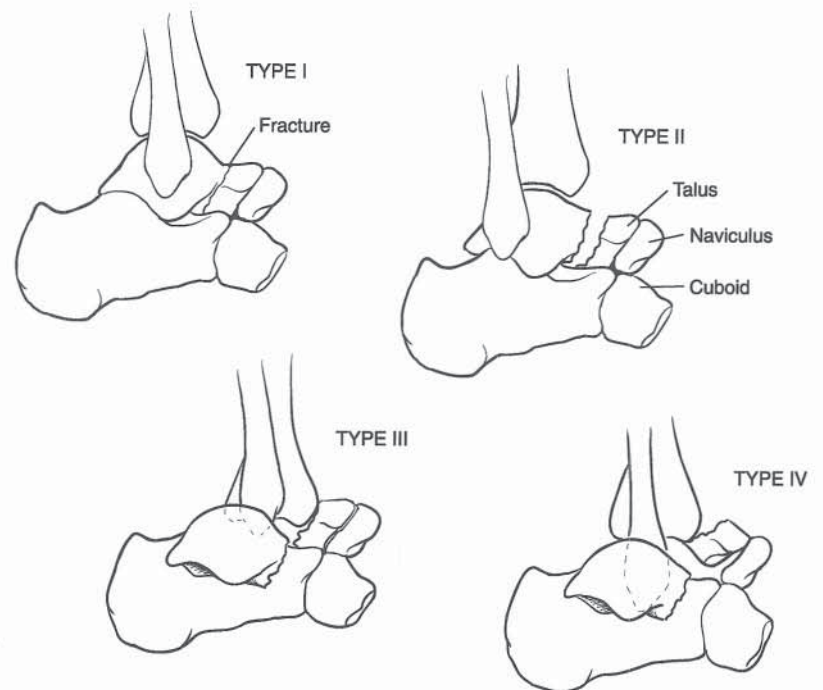


FIGURE 42-196 Classification of talar neck fractures: type I—nondisplaced fracture; type II—displaced fracture with subluxation or dislocation of the subtalar joint; type III—displaced fracture with dislocation of the talar body from both the ankle and subtalar joints; type IV—subluxation or dislocation of talar head and dislocation of talar body.

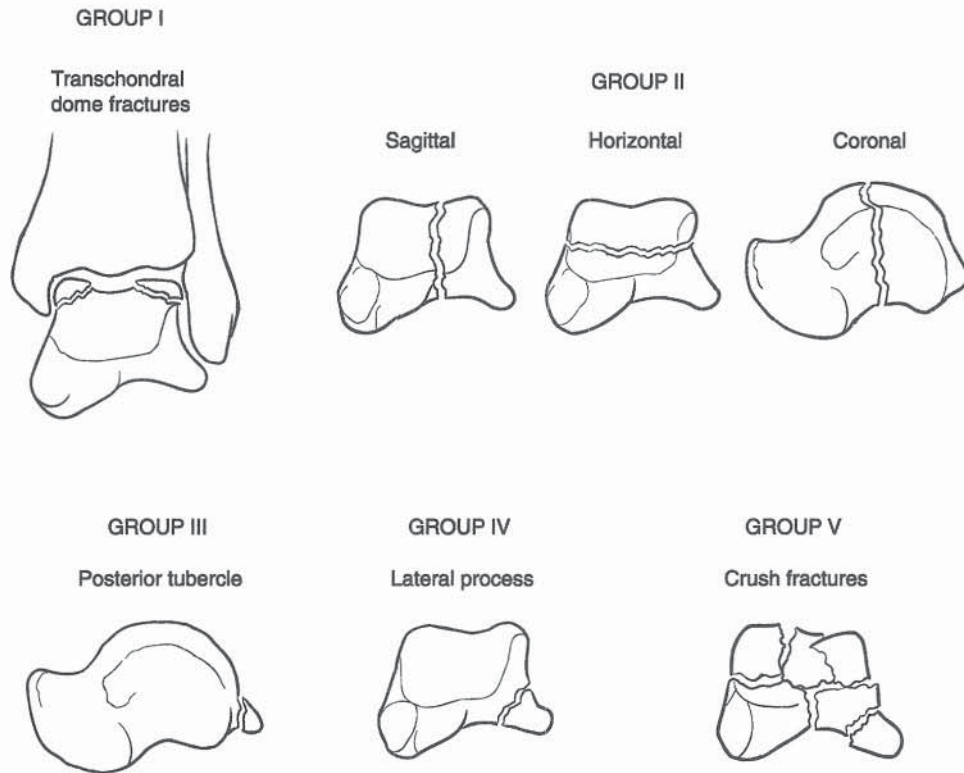


FIGURE 42-197 Classification of talar body fractures.

ruption, the ability to maintain the reduction with external immobilization is poor. Early reduction and rigid internal fixation helps in reestablishing circulation and allows early motion.

Type III injuries require open reduction and internal fixation, which is best done through a posterolateral incision, allowing access to the fracture for reduction and initiation of screw placement without risking further injury to the important blood supply to the talus. When the posterior approach fails to achieve a reduction, an alternative approach is through an anteromedial incision. Care must be taken to avoid the deltoid branch of the posterior tibial artery during this approach (Fig. 42-199). The best fixation is provided by partially threaded cancellous screws, which are placed to provide compression across the fracture site. The result is biomechanically strongest when the screws are

placed from the posterior talus into the neck anteriorly.^{138,207} In children, a single 6.5- or 4.0-mm screw works well and should be protected with a short-leg nonweightbearing cast for 4 to 6 weeks. As in adults, these injuries have a poor prognosis despite the best of treatments. A case report describes a 10-year old girl with a type III talar neck fracture who underwent open reduction and internal fixation. The fracture healed within 3 months, but AVN developed.¹⁶³

In a patient with a talar neck fracture, good AP and mortise radiographs of the ankle should be obtained between 6 and 8 weeks following injury to look for Hawkins sign, which is described as subchondral atrophy of the talar dome.⁸³ This is a good prognostic sign that excludes the presence of AVN. When the Hawkins sign is absent at this time, the patient should be kept nonweightbearing to prevent talar dome collapse.

FRACTURES OF THE BODY OF THE TALUS. Osteochondral injuries to the dome of the talus will be discussed separately. A fracture through the body of the talus is much more uncommon than talar neck fractures in both adults and children, and generally carries a worse prognosis, especially when displaced. In a series of 14 fractures in children, four (29 percent) were fractures of the talar body.⁹³ The majority of these fractures are undisplaced at the time of the initial evaluation and can be treated with a short-leg cast for 6 to 8 weeks, until fracture healing has occurred. Open reduction and internal fixation is required in the displaced fracture to prevent early degenerative osteoarthritis.

FRACTURES OF THE LATERAL PROCESS. These are rare injuries, accounting for less than 1 percent of all ankle injuries.¹⁴⁹ The mechanism of injury is forced dorsiflexion and inversion of the foot.⁸² The diagnosis is difficult to make, in part because it is so uncommon, in part because it is difficult

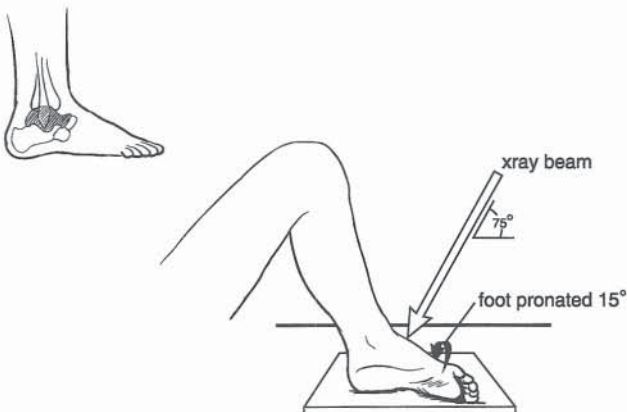


FIGURE 42-198 Positioning of the foot for the oblique radiograph to best visualize the talar neck when this fracture is suspected.

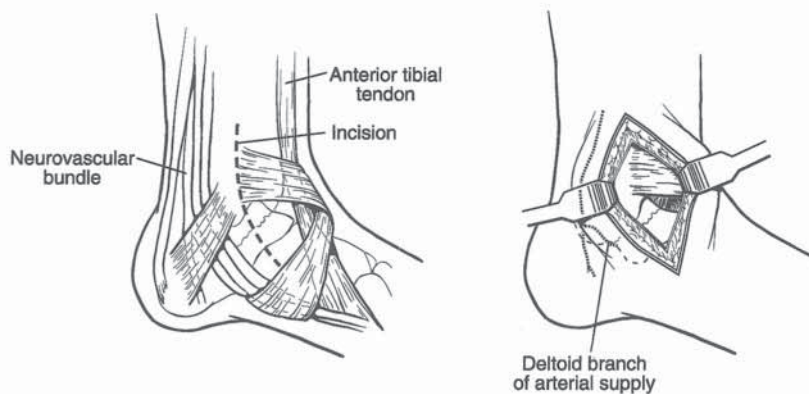


FIGURE 42-199 The anteromedial approach to the talus. A curvilinear skin incision is made just anterior to the medial malleolus. This incision is extended over the medial aspect of the midfoot. Dissection is then carried out just medial to the anterior tibialis tendon. Retraction will permit access to the fracture site and fracture fixation.

to identify the fracture on radiographs on the initial visit, especially when the fracture is undisplaced.^{82,84} Of 13 fractures of the lateral process of the talus, six (46 percent) were missed at the initial presentation.⁸² The clinician should have a high index of suspicion when there is any lateral ankle pain following an ankle injury, especially in the child who participates in athletic activities requiring quick cutting movements, which stress the ankle joint. An increase in the incidence of these injuries has been seen in snowboarders over the last decade.^{140,155} Treatment of these injuries depends on the amount of displacement of the fracture at the initial visit. These fractures are most commonly undisplaced and are best treated in a short-leg weightbearing cast for 6 weeks. Fractures displaced more than 1 cm require reduction and internal fixation with a single compression screw to restore the congruity of the articular surfaces.^{82,84,189,219}

Complications. AVN is the most serious complication following a talar fracture and is well-defined in the adult literature, with the incidence of this complication directly related to the location of the fracture and the amount of fracture displacement.^{32,83,148} The reported incidence of AVN with fractures of the talar neck is 0 to 10 percent for type I fractures, 40 to 50 percent for type II fractures, 80 to 90 percent for type III fractures, and 100 percent for type IV fractures.^{32,83} These figures were derived in predominantly adult populations and may not reflect the true incidence of AVN in the pediatric population. In addition, newer treatment techniques, including earlier reduction with stable internal fixation of these displaced fractures, may provide improved results.²⁰⁸

The few reports in the literature on talar fractures in children offer conflicting data with respect to factors predisposing to AVN. Letts and Gibeault reported a 25 percent incidence of AVN in 12 patients; however, two of these three patients had undisplaced fractures that were unrecognized at the time of injury, and AVN later developed.¹²³ Similarly, Linhart and Hollwarth reported a 27 percent incidence of AVN in children, some of whom had undisplaced fractures.¹²⁶ Mazel and associates reported two of seven complete talar neck fractures in children older than 6 years who later developed AVN.¹³⁹ However, Jensen and colleagues reported no evidence of AVN in 11 nondisplaced fractures and three displaced talar fractures in children.⁹³

Radiographic assessment for the Hawkins sign should be performed between 6 and 8 weeks following injury. The Hawkins sign, described as a radiolucency in the subchon-

dral area, indicates that the body of the talus has not undergone an avascular process. If the Hawkins sign is present, there is a high likelihood that the talar body has a good blood supply and will remain viable, allowing the patient to begin weightbearing 6 to 8 weeks following the injury. Absence of the Hawkins sign is not considered an entirely reliable indicator that AVN will develop.³² The patient should be kept nonweightbearing and reevaluated 3 months after the injury. MRI of the talus is indicated at 3 months if there is no radiographic indication of the Hawkins sign; MRI performed at that time will accurately show AVN.^{85,214} It is important to use titanium implants at the time of internal fixation of displaced talar neck fractures to allow clear visualization of the talus on MRI. Although not proved to be effective, when AVN is present and fracture healing has occurred, activity restriction is recommended, in an effort to prevent collapse.

OSTEOCHONDRAL FRACTURES OF THE TALUS

Also known as osteochondritis dissecans, an osteochondral fracture of the talus typically involves the posteromedial or anterolateral aspect of the talar dome. Although the etiology of this lesion is not completely understood, most patients recall a traumatic episode, especially those who have an anterolateral lesion. The diagnosis is based on the plain radiographic appearance, or on bone scan and MRI when the initial radiographs are normal. The Berndt and Hardy classification scheme is based on the radiographic nature of the injury and is used when deciding on treatment. Most children respond well to nonoperative treatment when the lesion is stable; however, operative intervention is necessary in some patients to remove or stabilize a detached fragment.

Mechanism of Injury. The etiology of osteochondral fractures of the talus has been debated for many years; however, trauma appears to be the principal cause.* Berndt and Hardy created osteochondral injuries of the talus in cadavers. They found that the anterolateral aspect of the talar dome impacts the medial aspect of the fibula when the dorsiflexed foot is subjected to an inversion force. The posteromedial aspect of the talar dome is injured as it strikes the distal tibial articular surface when the plantar flexed foot is forcibly inverted and externally rotated.¹⁵

The link to trauma as the etiology of these lesions is

*See references 4, 6, 15, 31, 86, 90, 127, 134, 170, 175, 193, 224.

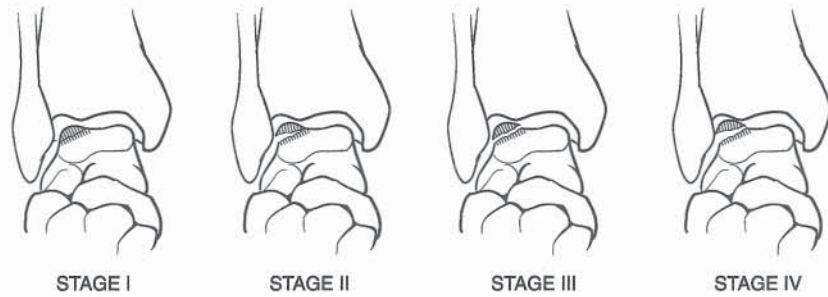


FIGURE 42-200 The Berndt and Harty classification of talar osteochondral lesions. Stage I—small area of subchondral compression. Stage II—partially detached osteochondral fragment. Stage III—a completely detached fragment remains within the crater of the lesion. Stage IV—the osteochondral fragment is loose in the joint.

strongest for lesions that occur on the lateral aspect of the talus.* Canale and Belding reported that all 15 patients with lateral lesions had a history of trauma, whereas only nine (64 percent) of 14 patients with medial lesions had a history of previous trauma.³¹ A review of the literature prior to 1985 found that 98 percent of patients with lateral lesions and 70 percent of patients with medial lesions had sustained trauma.⁶⁹ Patients who present after an acute traumatic event more often have a lateral lesion. Canale suggested that the morphology of the lateral lesions—wafer-shaped and shallower than the deeper, cup-shaped lesions—is more consistent with a traumatic shearing force producing these lesions.³¹

Other factors may contribute to the development of these lesions. A familial association has been described in which more than one family member had a lesion.^{3,233} Also, lesions of the talus occur bilaterally in 5 to 10 percent of cases.

Classification. Berndt and Hardy published their four-part radiographic classification of these lesions in 1959 (Fig. 42-200).¹⁵

Stage I: A small subchondral trabecular compression fracture not seen radiographically.

Stage II: Incomplete avulsion or separation of the fragment.

Stage III: Complete avulsion without displacement.

Stage IV: The fragment is detached and rotated, and may be free within the joint.

Because this classification is based on radiographic criteria, which may be difficult to interpret and cannot distinguish a stage I lesion, Anderson and associates modified the Berndt and Hardy classification to include the associated MRI findings.⁴ MRI is useful in two circumstances. The first is to identify an osteochondral injury when the radiographs are normal (stage I). MRI findings consistent with an osteochondral injury were decreased signal intensity on both T1- and T2-weighted images. At times there may be an increased signal on T2-weighted images due to the presence of marrow edema in a stage I lesion. The second situation in which MRI is useful is to identify a subchondral cyst in a stage II lesion, which is felt to represent areas of posttraumatic necrosis of bone followed by a cascade of host responses leading to ultimate free separation of the fragment. This finding places the lesion into the stage IIa category, which is treated by unroofing the lesion and drilling down to bleeding bone.⁴ They found no utility of MRI in stage III and IV lesions.

Although CT is not useful in defining the Berndt and Hardy stage I lesion,¹⁷⁷ it can be used to further define the

remaining lesions.^{127,224} A previously unreported lesion has been described using CT and consists of a radiolucent defect, seen in 77 percent of cases. It is best treated with curettage and drilling.¹²⁷

Further comparison of the radiographic classification and visualization of the lesion through the arthroscope was investigated by Pritsch and colleagues, who provided some guidelines for the treatment of these lesions.¹⁷⁴ The cartilage overlying the lesion was grouped into three grades: grade I indicated intact, firm, shiny cartilage; grade II cartilage was intact but soft; and grade III indicated frayed cartilage. They reported a poor correlation between the radiographic appearance of the lesion and the state of the overlying cartilage, and therefore treatment of the osteochondral lesions was based on the visual appearance of the cartilage: for grade I, simple restriction of sports activities was recommended; for grade II, arthroscopic drilling; for grade III, curettage of the lesion through the arthroscope was recommended. MRI best correlates with the arthroscopic findings, accurately predicting the stability of the fragment in 92 percent of cases.^{53,101}

Diagnostic Features. The patient usually presents following an ankle injury. Presentation can occur in the acute stage, immediately following the injury, and the diagnosis is made from the plain radiographic findings. Often, however, the patient does not seek medical attention following the acute injury but presents at a later date with chronic ankle symptoms that have not resolved, or with chronic painful symptoms without an inciting traumatic event.

The physical examination in the patient who presents with chronic pain is often benign, without any specific findings. There may be generalized swelling in the ankle region secondary to synovitis and a joint effusion. In a stable lesion, forced dorsiflexion and inversion may cause symptoms in an anterolateral lesion, while a posteromedial lesion may become symptomatic when a plantar flexed foot is inverted and externally rotated at the ankle. In the loose or completely displaced fragment, passive motion of the ankle is painful.

The initial radiographs include AP, lateral, and mortise views of the ankle. These views should be scrutinized for evidence of an osteochondral lesion. When seen, the lesion should be classified according to the Berndt and Hardy classification. Radiographs of the opposite ankle are useful to identify the rare bilateral lesions and to provide comparison views. When no radiographic lesion is seen on the initial radiographs but an osteochondral lesion is strongly suspected, further studies are indicated. We recommend a radionuclide bone scan at this point to help confirm the diagnosis and also to identify other areas of abnormality,

*See references 31, 69, 86, 142, 194, 236.

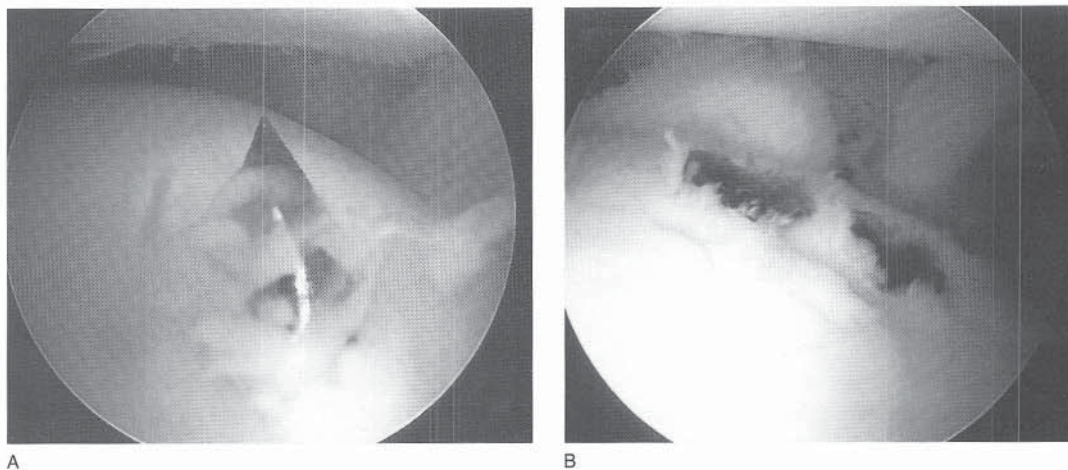


FIGURE 42–201 Arthroscopic treatment of a partially detached osteochondritis dissecans lesion. **A**, Arthroscopic view of the talar dome demonstrating the guide wire which has been used to drill retrograde through the osteochondral lesion. **B**, Arthroscopic view of the talus from the anterolateral portal showing two bioabsorbable pins which have been placed in a loose osteochondral lesion. The pins were cut off at the joint level.

especially when the talus does not exhibit increased uptake. Loomer and colleagues reported a sevenfold increase in the frequency with which these lesions were diagnosed when bone scans were utilized.¹²⁷ Anderson and colleagues diagnosed a talar osteochondral lesion in 17 (57 percent) of 30 patients who had been evaluated because of posttraumatic chronic instability and normal radiographs.⁴

As the next step in the evaluation of the lesion diagnosed on bone scan without radiographic changes or the type II lesion, we prefer MRI, to analyze the status of the cancellous bone and to evaluate for the presence of a subchondral cyst, respectively. CT is most useful in stage III and IV lesions to determine the exact location of the lesion, its size, and its stability.

Treatment. Treatment of stage I and II lesions is nonoperative. The patient is placed in a short-leg nonweightbearing cast for 6 weeks. The patient is then allowed weightbearing as tolerated; however, we restrict patients from strenuous athletic activities for an additional 6 weeks. Although the concept has not been scientifically tested, the lack of load bearing should allow the talus to partially revascularize somewhat to allow healing of the fragment. Although many reports do not stage and size the lesion, most pediatric series report excellent results when conservative treatment is used. Bauer and colleagues reported results in five children with an average age of 10 years at the time of treatment; in four patients the lesion healed without operative intervention, and all patients had a good or excellent result at 22-year follow-up.¹² Similarly, a 7.5-year follow-up of nonoperative treatment of stage I or II lesions demonstrated 78 percent good results, compared to only 16 percent good results for stage III or IV lesions.¹⁷⁰ Conservative treatment of stage III lesions on the medial aspect of the talus has also had good results.^{31,86} Higuera and colleagues reported good results in 11 of 12 patients when conservative treatment was used; seven of the patients had type III lesions.⁸⁶ They recommended initially treating all stage I to III lesions in children conservatively, since good results are seen in young patients. If conservative treatment fails to produce a good clinical

result or if radiographs show progression to a stage III or IV lesion, then operative treatment is indicated. A delay of more than 12 months from the time of the initial symptoms to operative treatment results in a worse clinical outcome.¹⁷⁰

The indications for operative intervention include lateral stage III lesions and all stage IV lesions, or failure of nonoperative treatment in any stage lesion. We prefer an arthroscopic approach to the ankle to minimize soft tissue injury while allowing good observation of the entire dome of the talus. We use anteromedial, anterolateral, and posteromedial portals and a 30-degree arthroscope.* The options for treatment of the specific lesion fall into three broad categories: drilling of the intact lesion, drilling and fixing the lesion with internal fixation, or curettage and drilling of the displaced lesion.

A stage II lesion with intact overlying cartilage can be drilled in a retrograde fashion to promote healing and revascularization of the osteochondral fragment. To drill the bony bed of the osteochondral fragment, we prefer to use the tibial guide from the ACL reconstruction setup to allow for accurate placement of the drill without penetration of the articular surface (Fig. 42–201). Posteromedial lesions are difficult to approach, often requiring a transmalleolar drilling, which partially disrupts the articular cartilage of the medial malleolus. A newer technique using meniscal repair instrumentation allows accurate arthroscopic localization and drilling, obviating transmalleolar drilling.²⁴ Immobilization and nonweightbearing are continued for 6 to 8 weeks postoperatively.

The stage III lesion with minimal fraying of the articular cartilage can be treated in a similar fashion as stage II lesions; however, the fragment should be stabilized with internal fixation. The ideal patient is one who has sustained an acute injury with a resulting small lesion that has good overlying articular cartilage. We prefer bioabsorbable pins, since they

*See references 5, 10, 11, 24, 30, 38, 66, 70, 79, 109, 130, 157, 160, 174, 175, 211, 234.

do not require removal at a later date and are not associated with tibial cartilage injury if subsequent collapse occurs. At least two pins should be placed in a divergent manner to provide optimal fragment stability. Immobilization and nonweightbearing are continued for 6 to 8 weeks postoperatively, followed by gradual weightbearing until the lesion heals.

In large (more than 1 cm) chronic stage III lesions with frayed articular cartilage, we prefer to curette the lesion, followed by drilling or abrading the base of the lesion. Debridement is carried out until healthy, bleeding subchondral bone is seen and continued peripherally until good articular cartilage is visible. The ankle is immobilized for approximately 2 weeks, then allowed to undergo range-of-motion exercises to promote fibrocartilage formation.

An open arthrotomy can be performed; however, it generally requires fairly large incisions and may require medial or lateral malleolar osteotomies to obtain good visualization and access to the osteochondral fragment.^{6,23,131}

The final treatment option is bone grafting of the base of the lesion, replacing the necrotic bone in the hope of stimulating more rapid healing. The articular surface is left intact, and no defect is left behind. Metal implants are not used in the talus.^{76,119} When bone grafting was compared to excision of the lesion in children with more than 2 years of follow-up, good results were seen in 83 percent of patients treated by bone grafting compared with 50 percent of patients who had undergone excision.⁷⁶ Patients remain nonweightbearing in a short-leg cast for 6 to 8 weeks and are then allowed gradual motion and partial weightbearing until healing of the lesion is seen.

FRACTURES OF THE CALCANEUS

Fractures of the calcaneus in children are rare. The usual mechanism is a fall from a height, usually a short distance in younger children and more than 10 feet in adolescents. The diagnosis in young children is often difficult to make and is often made only when fracture callus is seen on follow-up evaluation. Treatment is usually nonoperative and the outcomes are generally good in the young child. Operative treatment is best used in the adolescent with a displaced intra-articular fracture.

Anatomy. The calcaneus is the largest tarsal bone in the foot. Its anatomy is designed to provide a lever arm to increase the power of the gastrocnemius-soleus complex and to help transmit body weight to the remaining lower extremity. The posterior tuberosity is palpable as one follows

the Achilles tendon inferiorly to its insertion. The inferior surface of the calcaneus extends obliquely and dorsally toward the calcaneocuboid joint. The sinus tarsi is the depression anterior and distal to the lateral malleolus and marks the lateralmost aspect of the subtalar joint. The calcaneus is irregularly shaped, yielding six surfaces with four articulating facets, three for the talus and one for the cuboid. On the superior surface the posterior, middle, and anterior facets all lie at different angles to one another, with the sinus tarsi and the floor of the tarsal canal separating the posterior facet from the anterior and middle facets (Fig. 42–202). The posterior facet is oval and convex along the longitudinal axis and articulates with the undersurface of the talus, while the middle facet is concave and oval and articulates with the middle facet on the head of the talus. The sustentaculum tali projects from the medial side of the calcaneus and, together with the talus, forms the lateral boundary of the tarsal tunnel. Its inferior surface is grooved by the tendon of the flexor hallucis longus.

On the lateral radiograph in the more mature patient, Bohler's angle is formed as the angle subtended by a line from the superior point on the posterior articular surface to the superior point of the calcaneal tuberosity and a line drawn from the anterior process to the highest aspect of the posterior articular surface. This angle varies from 25 to 40 degrees and is a relative measurement of the degree of compression and deformity in calcaneal fractures. The "crucial angle" of Gissane is the angle formed by a line drawn from the sulcus calcaneus to the tip of the anterior process and varies between 120 and 145 degrees. With a calcaneal fracture, the talus compresses down onto the crucial angle, producing the primary fracture line in older patients.

Mechanism of Injury. The mechanism of injury in the majority of calcaneal fractures is an axial load applied to the lower extremity, most often as a result of a fall from a height. The forces are transmitted through the talus, which is then driven down into the calcaneus, resulting in fracture. In young children the height fallen is usually less than 4 feet; in children older than 10 years the fall is usually more than 14 feet.²²⁹ In 56 children with calcaneal fractures, 25 (45 percent) were due to a fall from a height.¹⁹⁵ Motor vehicle accidents, lawn mower injuries, and a direct blow from an object can also result in calcaneal fractures in children.

Classification. The most common classification systems for calcaneal fractures in adults are the Essex-Lopresti and Le-

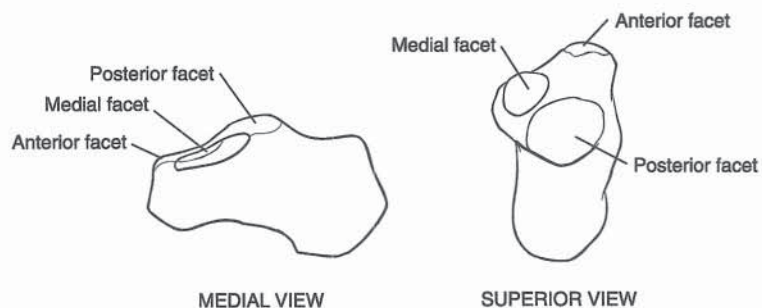


FIGURE 42–202 The articular facets of the calcaneus.

tournel classifications.^{63,121} Schmidt and Weiner modified the classifications of Essex-Lopresti, Rowe,¹⁸⁵ and Chapman and Galway³⁷ to better describe the fracture types in children (Fig. 42–203).¹⁹⁵

Type 1

- A—Fracture of the tuberosity or apophysis
- B—Fracture of the sustentaculum tali
- C—Fracture of the anterior process
- D—Distal inferolateral aspect
- E—Small avulsion of the body

Type 2

- A—Beak fracture
- B—Avulsion fracture of the insertion of the Achilles tendon

Type 3: Linear fracture not involving the subtalar joint.

Type 4: Linear fracture involving the subtalar joint.

Type 5

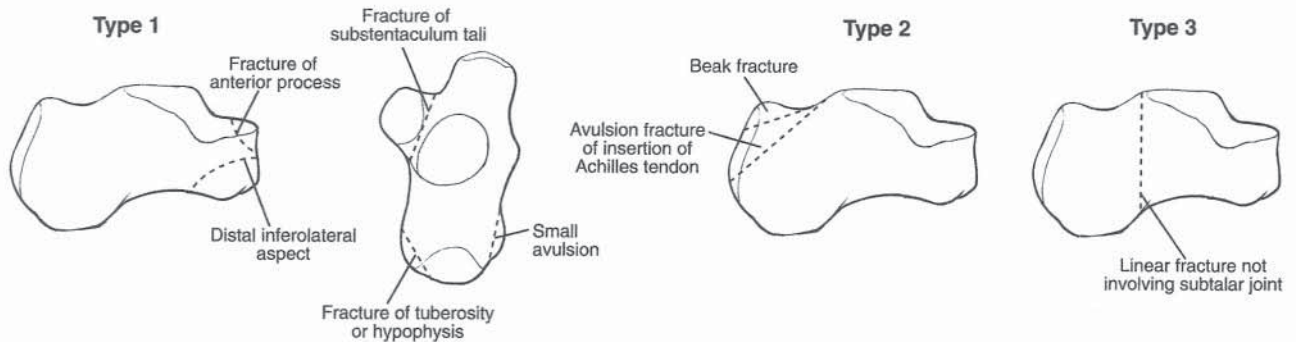
- A—Tongue type
- B—Joint-depression type

Type 6: Any fracture with significant soft tissue injury, bone loss, and loss of the insertion of the Achilles tendon.

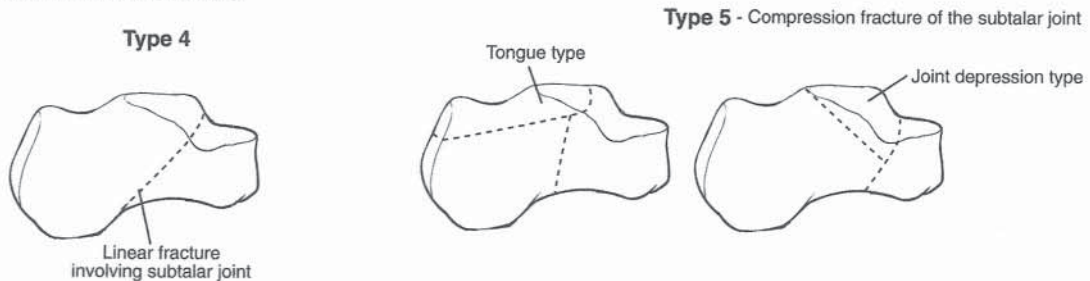
Diagnostic Features. The patient usually presents following a fall from a height and has pain in the area of the calcaneus. The older patient who falls from a height of more than 10 to 15 feet will often have significant swelling in the hindfoot area, and may also have complaints corresponding to injuries of the spine and the lower extremities. The physical examination should include an assessment of the foot for soft tissue swelling, a good neurologic examination, and inspection for open skin lacerations. As with any other orthopaedic injury, the patient should be thoroughly evaluated for the presence of other fractures or injuries, especially of the spine and lower extremities.

The radiographic examination is often difficult to interpret, especially in the young patient with a nondisplaced fracture. This may result in a missed diagnosis, which is reported to occur in 27 to 55 percent of cases.^{91,191,195,229} When a calcaneus fracture is suspected, standard radiographic views should include a lateral, axial, straight dorsoplantar, and an oblique dorsoplantar view.¹⁷⁹ Broden's views are especially useful when a fracture is suspected but not seen on the lateral or oblique views. Broden's views are obtained with the leg internally rotated 40 degrees and the x-ray beam

A. EXTRA-ARTICULAR FRACTURES



B. INTRA-ARTICULAR FRACTURES



C. SIGNIFICANT BONE LOSS

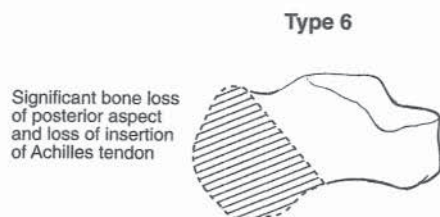


FIGURE 42–203 Classification of calcaneal fractures in children. A, Extra-articular fractures. B, Intra-articular fractures. C, Significant bone loss.

directed 10, 20, 30, and 40 degrees toward the head and centered on the sinus tarsi.²² These views show the posterior facet of the calcaneus from posterior to anterior as the beam is angled from 10 to 40 degrees.

For the adult-type fracture patterns with intra-articular joint involvement, CT scan is useful for defining the fracture pattern, determining the number of intra-articular fragments, and planning treatment.* The classification system of Sanders and colleagues analyzes the posterior facet and divides the fractures into four types, based on standard views:¹⁸⁹

Type I: Nondisplaced fractures.

Type II: Two-part or split fractures.

Type III: Three-part or split depression fractures.

Type IV: Four-part or highly comminuted articular fractures.

This classification has prognostic value with respect to articular reduction and overall outcome. Excellent or good results are achieved in 73 percent of type II fractures, 70 percent of type III fractures, and 9 percent of type IV fractures. CT is most useful in the older patient with an intra-articular fracture. By accurately showing the fracture pattern, it allows the surgeon to select the best treatment protocol.¹⁵⁹

In the young child, radiographs may appear normal despite the presence of a calcaneal fracture. When there is a high suspicion that a fracture is present, the child can be placed in a short-leg cast and radiographs can be repeated 2 to 3 weeks from the time of the injury. An alternative is to obtain a bone scan to help define the presence of fracture; however, the results with respect to clearly identifying the fracture are mixed,^{108,205} and we prefer the former option.

Treatment. In general, calcaneal fractures in children are successfully treated nonoperatively by means of a short-leg cast or splint worn for 3 to 6 weeks, followed by weightbearing as tolerated.† This is especially true in children less than 10 years, because of better healing potential and a lower incidence of intra-articular fractures in this age group.^{192,195}

In the patient less than 5 years, the fracture is universally undisplaced and often not seen on the initial radiographs. We prefer to treat these children with short-leg casts for 3 weeks, and we allow full weightbearing. A large proportion of these fractures are most likely missed on the initial presentation and do well without formal treatment. Matteri and Frymoyer reported results in two of three children with missed calcaneal fractures who were less than 3 years old. Treatment of the diagnosed fracture consisted of a posterior splint for 3 weeks, and all three children were back to full activities by 3 weeks.¹³⁷

Children 12 years old or younger have good results, even though a small proportion have displaced intra-articular fractures.‡ Schmidt and Weiner described 37 patients with extra-articular fractures, with an average age of 10 years, compared to 22 patients with intra-articular fractures, with an average age of 13 years.¹⁹⁵ In addition, the mechanism of injury imparts less energy to the calcaneus in young children because of their smaller size and because the height of the falls is generally less than 4 feet, versus more than 14

feet in children older than 10 years.²²⁹ We prefer to treat these children in short-leg nonweightbearing casts for 4 to 6 weeks, depending on the age of the child, followed by weightbearing as tolerated.

Children older than 12 years have a higher proportion of intra-articular fractures (63 percent vs 27 percent), sustain greater trauma to the extremity, and have a higher incidence of associated injuries (50 percent vs 20 percent) than younger children.¹⁹⁵ Because the associated injuries include lumbar vertebral fractures, other lower extremity fractures, pelvic fractures, and upper extremity fractures, the treating physician should anticipate associated injuries in the older child with a calcaneal fracture. This is especially true in the child involved in a motor vehicle accident, in which the incidence of associated injuries is highest.¹⁹¹ Treatment of extra-articular fractures is similar to that in younger children but may include a longer period of immobilization, up to 12 weeks. Intra-articular fractures in this age group are relatively common, and the results of closed treatment are generally good with regard to function.^{50,191,192} However, most studies have short³⁷ or inadequate follow-up,¹⁹⁵ some patients do experience pain on short-term follow-up, and radiographs do demonstrate residual deformity and some evidence of early degenerative changes in the subtalar joint.¹⁹² Schantz and Rasmussen reported a 12-year follow-up in 15 children with intra-articular calcaneal fractures that had been treated closed. Four had pain. Radiographs demonstrated an increased width of the calcaneus in nine patients, a step-off at the articular surface of the posterior facet in four, and early degenerative arthrosis in two.¹⁹² We prefer to perform CT in the older patient with an intra-articular fracture to assess the number of intra-articular fragments and the amount of displacement or step-off of the joint surface. The skeletally mature patient with a displaced intra-articular fracture should be treated as an adult, with an open reduction and internal fixation to restore the articular surface of the joint, restore the height of the heel, and reduce the width of the heel to a more normal position. Consultation with an adult foot and ankle surgeon is advised because of the low incidence of these fractures in a typical pediatric orthopaedic practice and the complexity of the surgical procedure.*

Complications. Complications from calcaneal fractures are infrequent. The most common complication in these fractures is residual pain and early arthrosis in the subtalar joint, especially with displaced intra-articular fractures. In adult calcaneal fractures, there is an associated 10 percent incidence of compartment syndrome of the foot, which is treated by nine-compartment releases.^{152,153} To our knowledge, compartment syndrome has not been reported in the pediatric population, but it must be evaluated for in all children, especially adolescents with displaced intra-articular fractures.

TARSOMETATARSAL (LISFRANC'S) FRACTURES

This is a very rare injury in adults and was only reported in children as individual cases^{18,178} until Wiley reported a series of 18 cases in pediatric patients.²²⁸ The diagnosis is often difficult to make because the anatomy is difficult to

*See references 46, 58, 107, 150, 159, 188.

†See references 25, 37, 40, 50, 91, 108, 137, 191, 192, 195, 213, 229.

‡See references 37, 50, 91, 191, 192, 195, 229.

*See references 59, 60, 63, 95, 121, 125, 188.

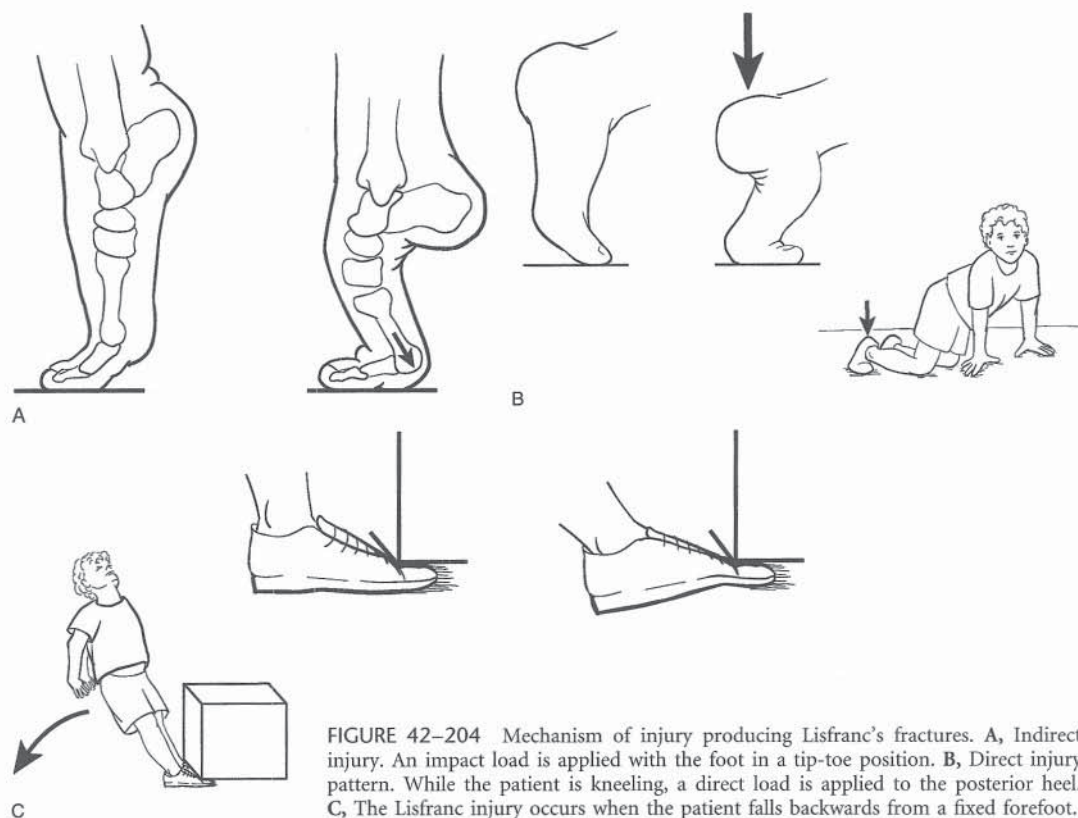


FIGURE 42-204 Mechanism of injury producing Lisfranc's fractures. A, Indirect injury. An impact load is applied with the foot in a tip-toe position. B, Direct injury pattern. While the patient is kneeling, a direct load is applied to the posterior heel. C, The Lisfranc injury occurs when the patient falls backwards from a fixed forefoot.

discern on plain radiographs and because fractures in children are usually undisplaced. Most children with these injuries can be treated with casting alone; however, displaced fractures require closed reduction with internal fixation or open reduction and internal fixation. The results are relatively good, although some patients continue to have persistent pain in the area of the Lisfranc's joint, especially if anatomic reduction is not achieved or if loss of reduction occurs. Salvage operations for persistent discomfort include tarsometatarsal arthrodesis.

Anatomy. The tarsometatarsal joints form articulations between the distal row of tarsals and the bases of the metatarsals: the medial three metatarsal bases articulate with their respective cuneiforms and the lateral two with the cuboid. Weak dorsal and stronger plantar tarsometatarsal ligaments connect the adjacent borders of the cuneiforms and the second and third metatarsals, the rigid keystones of the tarsometatarsal joint. The intermetatarsal ligaments provide greater strength than the dorsal and plantar ligaments. Lisfranc's ligament travels from the second metatarsal to the first cuneiform without connections to the first cuneiform. At the base of the first and second metatarsals lies the plantar branch of the anterior tibial artery and the deep peroneal nerve.

Mechanism of Injury. Three basic mechanisms have been described.^{227,228} The first involves an indirect injury in which the foot sustains an *impact load while in the tiptoe position* (Fig. 42-204A). Most commonly this is from a fall from a height in which the patient lands on the foot with the toes flexed, producing acute plantar flexion at the tarsometatarsal level. This often results in a sudden abduction moment to

the foot and results in lateral displacement of the metatarsals and fracturing at the base of the second metatarsal.

The second mechanism is a direct compression injury in which the patient is in a kneeling position and an object strikes the back of the heel, producing the *heel-to-toe compression* (Fig. 42-204B). This injury pattern may result in lateral displacement of the second through fourth metatarsals.

The third mechanism results from the foot being in a fixed position and sustaining a *fall backward* (Fig. 42-204C). The heel of the foot is the fulcrum around which the injury occurs; the injury can result in multiple fractures of the foot.²²⁸

In children the most common mechanism of injury is a fall from a height (56 percent), followed by a fall backward (22 percent) and heel-to-toe compression (18 percent).²²⁸ In adults a large proportion of these injuries are from motor vehicle accidents, crush injuries, and falls from heights.* Two of the pediatric patients described by Wiley had severe crushing injuries of the foot with associated tarsometatarsal fractures.²²⁸

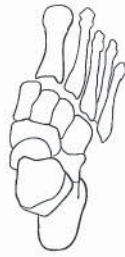Classification. The three-part classification of Hardcastle and colleagues,⁸¹ a modification of the original description by Quena and Kuss,¹⁷⁶ best defines these fractures, their mechanism, and their treatment (Fig. 42-205).

Type A—Total Incongruity. There is incongruity of the entire tarsometatarsal joint in a single plane, with lateral displacement (Fig. 42-205A).

Type B—Partial Incongruity. Only partial incongruity of

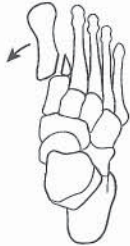*See references 8, 28, 47, 154, 164, 182, 190, 212, 218, 220, 227, 230, 231.

TYPE A
Total incongruity

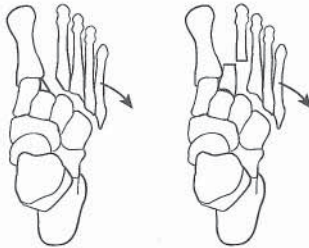


TYPE B
Partial incongruity

Medial
dislocation



Lateral
dislocation



TYPE C
Divergent

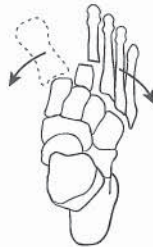

FIGURE 42-205 Classification of Lisfranc's injuries. Type A—total incongruity. Type B—partial incongruity; medial dislocation or lateral dislocation. Type C—divergent pattern.

the joint is seen, affecting either the medial or the lateral aspect of the foot. The medial dislocation involves the displacement of the first metatarsal from the first cuneiform because of disruption of Lisfranc's ligament or fracture at the base of the metatarsal, which remains attached to the ligament (Fig. 42-205B).

Type C—Divergent Pattern. There may be partial or total incongruity, with the first metatarsal displaced medially while any combination of the lateral four metatarsals may be displaced laterally (Fig. 42-205C).

In children, the type A and C patterns are extremely rare, and the type B injury pattern usually demonstrates minimal displacement.²²⁸ Similarly, in adults the incidence of types A, B, and C is 17 percent, 72 percent, and 10 percent, respectively.¹⁶⁴

Diagnostic Features. The diagnosis of these injuries is notoriously difficult, with as many as 20 percent of injuries misdiagnosed or overlooked.^{27,182} The prognosis of the untreated Lisfranc's fracture is generally poor. The child or

adolescent will present with pain in the foot and dorsal swelling, which may be localized over the dorsum of the tarsometatarsal joint. With significant trauma the entire dorsum of the foot may be swollen and localization of the pain may be difficult. However, a mild injury with more focal swelling may allow palpation of the foot to better identify the pain over the tarsometatarsal joint. Deformity of the foot is rare since the majority of injuries in children either are not displaced at the time of injury or reduce spontaneously following injury. Pain on attempted weightbearing or persistent inability to bear weight despite a normal physical examination and radiographs should raise the physician's suspicion that a tarsometatarsal injury is present. Ecchymosis on the plantar aspect of the midfoot implies trauma to the tarsometatarsal ligaments and an injury of that joint.¹⁸³

Radiographs of the extremity should include AP, lateral, and oblique views of the foot. The lateral border of the first metatarsal should be in line with the medial cuneiform and the medial aspect of the second metatarsal should line up with the medial aspect of the middle cuneiform on the oblique radiograph. A subtle Lisfranc's injury is detected with a fracture at the base of the second metatarsal, a diastasis between the base of the first and second metatarsals of 2 mm or more (Fig. 42-206). Weightbearing stress views to accentuate the diastasis with comparison views of the opposite foot are helpful.⁶⁴ CT has been useful to diagnose and define the extent of injury in patients whose radiographs are suspicious for but not confirmatory of a tarsometatarsal injury.^{72,120,129} MRI can delineate ligamentous injuries of the tarsometatarsal joint in patients whose radiographs are normal. In patients with radiographs demonstrating diastasis between 0 and 2 mm, Potter and colleagues reported three complete tears and 18 partial ligament tears.¹⁷² They recommend MRI for any patient whose history or physical examination findings are suspicious for Lisfranc's injury despite normal radiographs, with operative treatment indicated in any patient with a complete or nearly complete ligamentous tear. Bone scintigraphy has been reported to be useful in the diagnosis; however, it is not specific and does not accurately suggest the severity of injury.⁷⁸

Treatment. The amount of displacement and the adequacy and stability of fracture reduction determine the type of treatment. The majority of tarsometatarsal fractures in children are undisplaced or displaced less than 2 mm at the time of the initial evaluation and can be treated nonoperatively. When swelling is present, a bulky dressing for 2 to 3 days has been advocated to allow the soft tissue swelling to resolve.²²⁸ This is followed by short-leg cast immobilization for 5 to 6 weeks. Although some recommend weightbearing in the cast, we prefer to have the patient nonweightbearing so that the possibility of fracture displacement is minimized.

For fractures that are displaced 2 mm or more on the initial radiographs or CT scan, we prefer to perform a closed reduction under general anesthesia to achieve an anatomic reduction. A stable anatomic reduction must be achieved before application of external immobilization. The closed reduction is performed with manual manipulation, including axial traction along the affected toes, followed by manual pressure on the dorsum of the foot when dorsal displacement is present. Adequate radiographic assessment is needed to ensure that the fracture is reduced to an anatomic position. Residual displacement of more than 1 mm is an indication

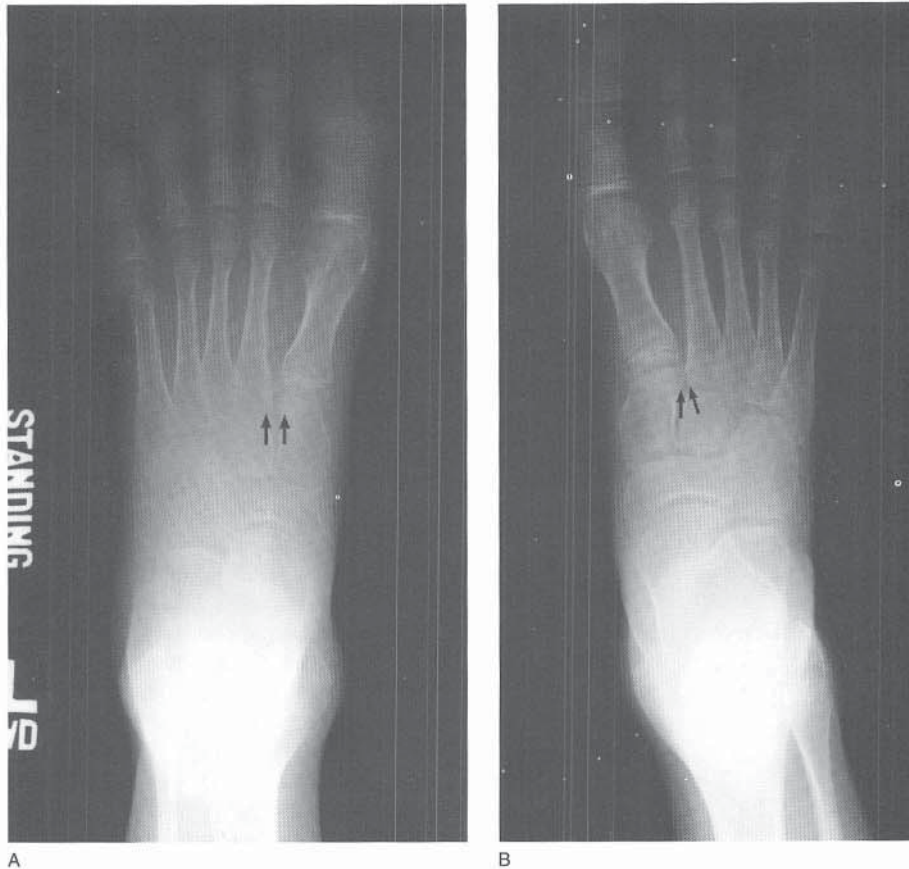


FIGURE 42-206 Lisfranc's injuries in a 10-year-old girl who sustained injury while performing gymnastics. **A**, Standing AP radiograph of the left foot. **B**, Comparison views of the right foot are used to identify increased joint space in Lisfranc's joint on the left (arrows).

for open reduction and internal fixation. The three main reasons for failure of closed reduction are anterior tibialis tendon interposition, incongruity of the medial cuneiform-first metatarsal articulation, and fracture fragment interposition in the second metatarsal-middle cuneiform joint.¹⁷ If the fracture is reduced anatomically but is unstable, then percutaneous wire fixation is required to maintain the anatomic alignment of the foot. We prefer to use smooth .0062-inch K-wires, with the most important pin traveling between the medial cuneiform and the second metatarsal and additional pins placed according to the type of fracture present. In the type A total incongruity pattern, Hardcastle and associates recommend medial and lateral pins for fixation. In the most common pattern, type B, with partial incongruity and medial dislocation, a second pin is placed between the first metatarsal and the medial cuneiform or between the first two metatarsals to stabilize the medial displacement of the first metatarsal (Fig. 42-207). For the lateral dislocation-partial incongruity pattern, lateral pins are needed. For the type C or divergent pattern, a similar pin construct can be used for the medial displacement pattern; however, an additional pin or pins may need to be placed from the third, fourth, or fifth metatarsals into the second or third cuneiform or the cuboid, respectively.

The indications for open reduction and internal fixation are inability to achieve an anatomic closed reduction, and chronic symptomatic injury with residual diastasis. The skeletally mature patient may best be treated similarly to adults, with open reduction and internal fixation for all tarsometatarsal

injuries to achieve optimal results.* One or two longitudinal incisions over the first-second metatarsal interspace and over the third-fourth metatarsal interspace are utilized. The injury is reduced to an anatomic position under direct visualization, and percutaneous pin fixation is placed as described above. We prefer to leave the pins outside the skin and pull these at 6 weeks from the time of injury. In the chronic symptomatic case, treatment should consist of removal of debris from the joint, roughening of any remaining articular cartilage, followed by pin fixation of the joint(s). Open injuries are usually due to a crush injury to the foot and should be treated with thorough irrigation and debridement of the foot. Treatment of the tarsometatarsal injury should follow the above guidelines.

Complications. The only series of tarsometatarsal fractures in children reported 14 of 18 patients with excellent results without residual symptoms at short-term follow-up (3 and 8 months).²²⁸ No patient required an open reduction; however, four patients had discomfort at 1 year follow-up, with two patients having residual malreduction—one due to inability to achieve a closed reduction and one whose injury was not recognized. They reported one complication; a 16-year-old patient developed asymptomatic AVN of the second metatarsal head. The most common complication in adults is residual pain, which may be associated with progressive flatfoot deformity or lateral impingement and is best treated with tarsometatarsal joint arthrodesis.^{190,217}

*See references 7-9, 28, 47, 154, 164, 180, 182, 212, 218, 220.

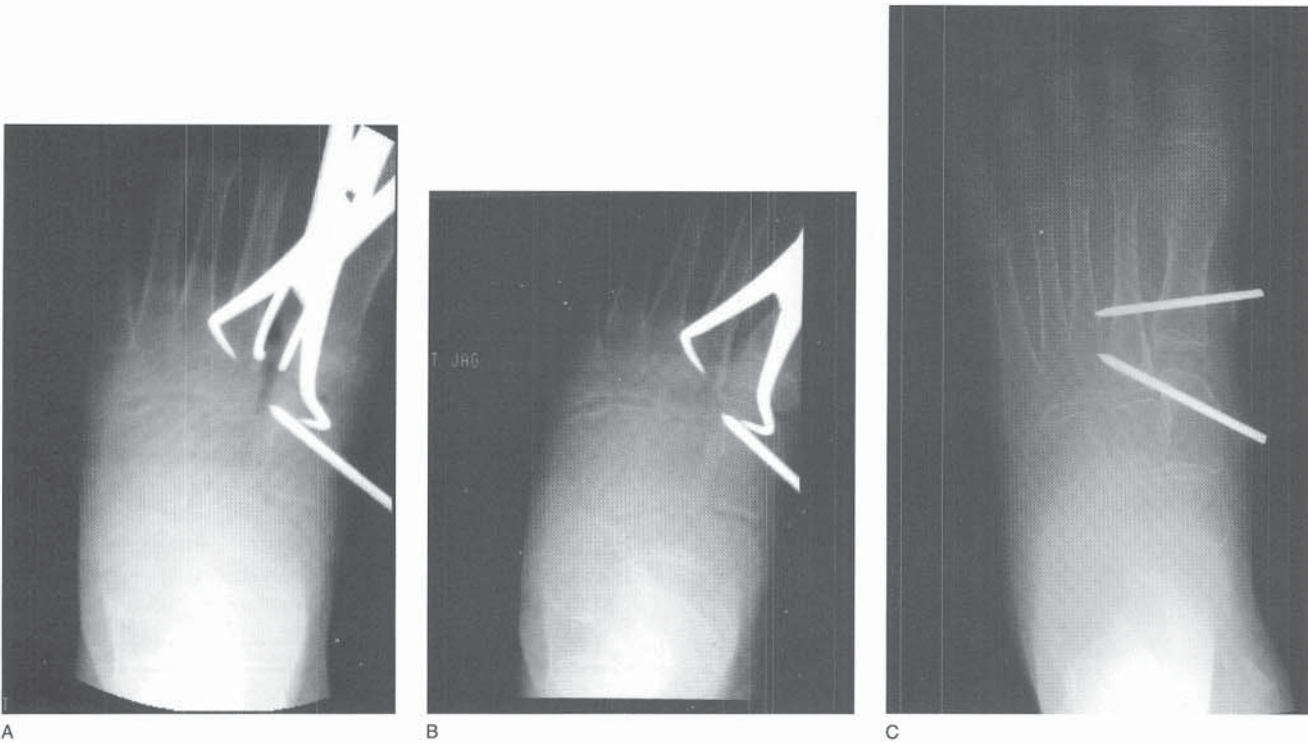


FIGURE 42-207 Open reduction and internal fixation of Lisfranc's fracture. Intraoperative radiographs during an open reduction and internal fixation of a Lisfranc's injury. **A**, The Lisfranc's joint is distracted to allow for debridement of the joint in this chronic injury. **B**, A bone reduction forceps is then used to reduce the joint. **C**, The Lisfranc's joint is stabilized between the first cuneiform and the second metatarsal using a threaded pin. Additional fixation is utilized between the first and second metatarsals.

METATARSAL FRACTURES

Fractures of the metatarsals are the most common fracture of the foot in children, accounting for approximately 15 percent of all foot injuries (Fig. 42-208).¹⁵⁸ These fractures can be due to direct trauma from an object falling onto the foot or from a crush injury from a bicycle or motor vehicle running over the foot. They can also be from indirect trauma in which the child lands on the foot with axial and torsional loads applied to the midfoot. The commonest fracture occurs at the fifth metatarsal, accounting for 45 percent of all metatarsal fractures in children. In the young child, less than 5 years old, the most common fracture is fracture of the first metatarsal, while in children older than 10 years the most commonly fractured metatarsal is the fifth.¹⁵⁸ In young children the base of the first metatarsal is often fractured and presents as a small buckle fracture. A small percentage of these fractures are missed at the time of initial presentation; however, fractures of the first metatarsal are especially prone to be overlooked, in 20 percent of cases.¹⁵⁸

The patient usually presents with pain in the foot after a twisting injury or following a direct blow to the foot. The mechanism of injury is important to define, since crush injuries need careful assessment of the soft tissues and evaluation for the uncommon but significant compartment syndrome. Silas and colleagues reported seven compartment syndromes of the foot in children, three of whom had metatarsal fractures following a crush injury.¹⁹⁹ In the multiply injured child the foot fractures may seem trivial when long bone or pelvic fractures are present. However, because of

the significant energy force required to produce these injuries, the metatarsal fractures may be associated with severe soft tissue trauma and impending compartment syndrome, especially when hypotension is present.

Radiographic examination should include AP, lateral, and oblique views of the foot, with full visualization of the metatarsals and phalanges. The initial radiographs in a young child may not show a fracture, and so radiographs may have to be repeated in 2 weeks to make the diagnosis. Metatarsal neck fractures are more often due to a torsional force applied to the foot, while direct compression results in shaft fractures.

Most metatarsal fractures can be treated nonoperatively since the majority are undisplaced at the time of the initial evaluation. Soft tissue swelling of the foot is a contraindication to applying a circumferential cast at the time of the initial evaluation. We prefer a short-leg posterior splint or a modification of the U-type splint with a foot plate (Fig. 42-209). The patient should keep the foot elevated for 24 to 48 hours, and the splint can then be overwrapped with fiberglass cast material in 1 week to enhance its durability. Weightbearing is allowed in the cast, which is worn for 3 to 6 weeks, depending on the age of the child and the amount of fracture displacement.

The indications for a closed reduction are not fully defined. We prefer to reduce fractures which are completely displaced, especially in the older child, and fractures angled greater than 20 degrees, especially when apex-dorsal. The child should be sedated in the emergency room, and if

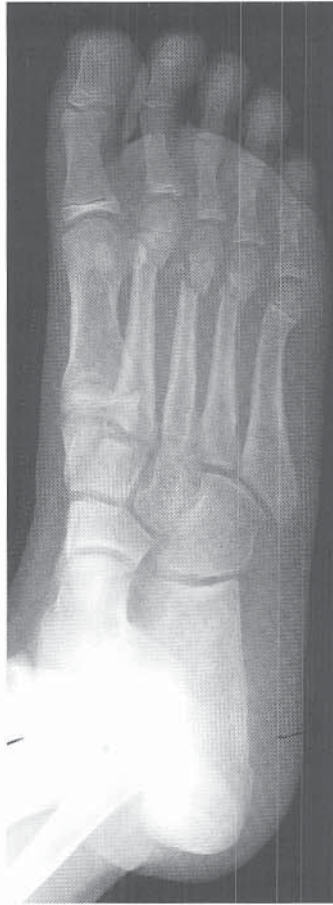

FIGURE 42-208 Radiographs of a right foot demonstrating fractures of the second, third, and fourth metatarsals.

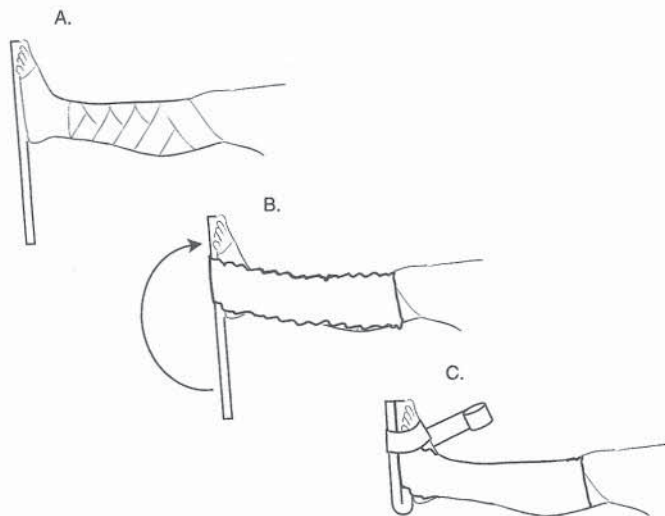


FIGURE 42-209 A short-leg splint. The leg is first wrapped with cast padding. A foot plate is then placed using plaster splint material. The foot plate is twice the length of the foot. While the foot plate is held in place, a U-slab is placed to reinforce the forefoot. The foot slab is then folded back onto itself to ensure there is no pressure on the heel. This is then overwrapped with cast padding and an elastic bandage.

closed reduction is difficult, finger traps can be placed on the affected toes to restore length and fracture reduction. The foot should be placed in a short-leg plaster cast that is well molded over the dorsal and plantar aspect of the foot; however, the ankle can be left in slight plantar flexion and should be well molded to promote resolution of the foot swelling. The unreliable patient can be admitted to maintain elevation of the foot and periodic ice pack application to the foot. If a compartment syndrome of the foot is suspected at the time of the initial evaluation or subsequent to treatment, compartment pressures should be measured and a nine-compartment foot release should be performed as described by Myerson and Manoli.¹⁵²

Open reduction and internal fixation is indicated for open fractures, irreducible fractures, and fractures that cannot be maintained reduced by external immobilization in a cast. However, it is rarely necessary to perform an open reduction of these fractures in children. The dorsal skin incision should be made directly over the fracture with exposure of the fracture. A Kirschner wire is then drilled antegrade out the distal fragment, followed by fracture reduction and retrograde pinning. The pin is bent and cut, and left on the plantar aspect of the skin, and the foot is immobilized in a short-leg nonweightbearing cast for 4 to 6 weeks. The pin (or pins) can be removed at 4 to 6 weeks, depending on the age of the child, and a walking cast or a fracture boot worn for an additional 2 weeks.

FRACTURES OF THE BASE OF THE FIFTH METATARSAL

The proximal fifth metatarsal can be anatomically divided into three regions: the proximal cancellous tuberosity, the more distal tuberosity, and the proximal metaphyseal-diaphyseal junction. The blood supply to the base of the fifth metatarsal is important in understanding the risk of nonunion.^{34,197,201} The nutrient artery enters medially into the cortex and branches proximally and distally, with a watershed area between the proximal branch of the nutrient artery and the metaphyseal vessels (Fig. 42-210). Fractures in this watershed area are at risk for delayed union or nonunion. The proximal apophyseal growth center is usually visible radiographically at age 9 and becomes united to the diaphysis between 12 and 15 years of age. This apophyseal growth center, or the os vesalianum, can be mistaken for a fracture in children but can be differentiated by the sagittal orientation of the apophysis and the metatarsal. In contrast, the true fracture line is oriented transversely, at a right angle to the shaft of the metatarsal.

Fractures of the base of the fifth metatarsal are best classi-

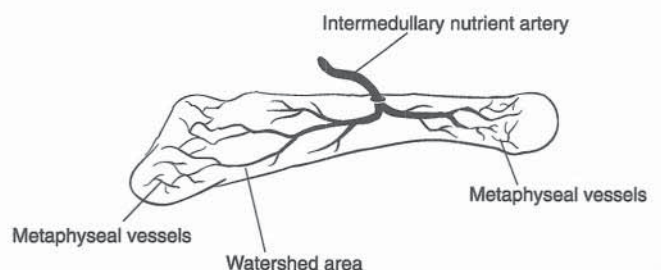


FIGURE 42-210 Blood supply of the proximal fifth metatarsal.

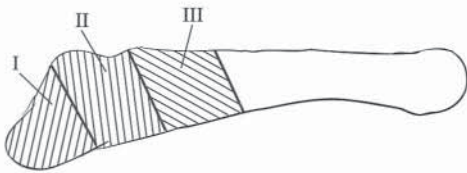


FIGURE 42–211 The three anatomic zones of the proximal fifth metatarsal.

fied according to their location, best defined by the anatomy of the three zones of the proximal metatarsal (Fig. 42–211). Zone 1 comprises the cancellous tuberosity, including the insertion of the peroneus brevis tendon and the calcaneo-metatarsal ligament of the plantar fascia; zone 2 is the distal aspect of the tuberosity, with dorsal and plantar ligamentous attachments to the fourth metatarsal; and zone 3 begins distal to the ligamentous attachments and extends to the mid-diaphyseal area. It is most important to recognize the zone 2 injury, the so-called Jones fracture, which is prone to nonunion due to the poor blood supply.^{97,117,162}

Treatment of these fractures is principally dependent on the location of the fracture and the activity level of the patient. Zone 1 injuries are traction-type fractures in which the peroneus brevis tendon and the lateral aspect of the plantar aponeurosis are under tension, resulting in avulsion of the proximal aspect of the metatarsal. Minimal treatment is needed in these patients since the outcome is universally good with healing of the fracture and full return to activities.⁴⁸ We prefer to treat these fractures in a short-leg cast and allow weightbearing as tolerated for 3 to 6 weeks. Other authors have recommended a hard-sole shoe, elastic wrap, or a functional brace; all of these have produced good results. Radiographic union generally lags behind the time to resolution of the patient's symptoms and is not a prerequisite for removal of the cast or return to activities at 3 to 4 weeks. There are reports of nonunion of these fractures, which are most often displaced more than 3 mm at the time of injury, and we prefer to immobilize these injuries in a cast for 6 weeks.¹⁸¹

The Jones fracture is located in zone 2, the proximal metaphyseal-diaphyseal junction, with the fracture line extending obliquely and proximally from the lateral cortex through the medial cortex, where articulation with the fourth metatarsal occurs. The mechanism of injury is thought to be a combination of vertical loading and coronal-plane shear forces that occur at the junction of the stable proximal metaphysis, provided by ligamentous attachment to the base of the fourth metatarsal and the mobile fifth metatarsal diaphysis. It is most likely that these fractures are stress injuries that occurred prior to the acute event that brings the patient to the hospital.^{29,43,98,117,187} These patients are usually adolescent, are most often involved in athletics, and present after a traumatic event despite having prior symptoms. A good history is important to determine the duration of symptoms, since patients with more chronic symptoms (3 to 4 months) may be more prone to nonunion. Josefsson and colleagues reported results in a large series of patients with Jones fractures; late surgery was required in 12 percent of patients with acute fractures and 50 percent of patients with chronic fractures when nonoperative treatment was initially used.⁹⁹ For the acute fracture, we prefer immobi-

lization in a short-leg cast and do not allow weightbearing for the initial 6 weeks. Serial radiographs are evaluated for evidence of fracture healing. Tenderness at the fracture site or lack of fracture callus formation at 6 weeks requires further immobilization in a short-leg nonweightbearing cast. With evidence of fracture callus and lack of tenderness, the patient can begin protected weightbearing in a hard-soled shoe for an additional 4 weeks. Return to full activities is allowed after solid fracture union is seen radiographically (Fig. 42–212). In adults, Torg and associates reported fracture healing at 7 weeks in 14 of 15 patients treated with a short-leg nonweightbearing cast, while only four of ten patients who were allowed to bear weight went on to union.²¹⁵ In the chronic injury, when symptoms have been present for more than 3 months, the likelihood of fracture healing with conservative treatment is significantly decreased. In the untreated patient, at the time of presentation, we prefer a trial of nonweightbearing in a cast for 6 weeks to attempt to obtain fracture healing. However, if this treatment does not result in fracture healing, we prefer intramedullary fixation using a compression screw and bone grafting (Fig. 42–213). We prefer the distal tibia as the site to harvest bone graft since only a small quantity of bone is needed, the harvest site is close to the operative site, and only a small incision is required. Postoperatively the patient is allowed to bear weight, initially in a short-leg cast for 3 to 4 weeks. The technique has been described using a 4.0-mm malleolar screw; however, we prefer a larger 6.5-mm screw with good distal cortical purchase when the size of the metatarsal permits. The results of intramedullary screw fixation and bone grafting have been good, with few complications.*

The zone 3 fracture is most often a stress fracture, usually occurring in the active athlete. Similar to the Jones fracture, the acute zone 3 fracture can be treated in a short-leg nonweightbearing cast for 6 weeks, followed by protection during weightbearing for 3 to 4 weeks. The active athlete with a chronic injury or nonunion should be treated with intramedullary screw fixation with or without bone grafting.

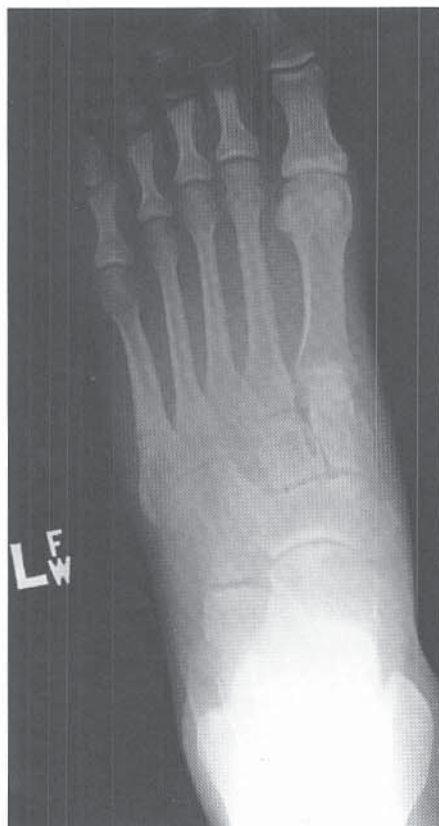PHALANGEAL FRACTURES

Phalangeal fractures are rare in children, are the result of direct trauma, and generally require minimal treatment. The proximal phalanx is more often injured than the more distal phalanges, and injuries of the hallux are more common than injuries of the lesser toes. The mechanism is usually “stubbing” the toe or direct trauma from a falling object. These fractures may be associated with significant soft tissue injury, especially when they result from direct trauma. Open injuries are rare and most often involve the nail plate and nail bed.

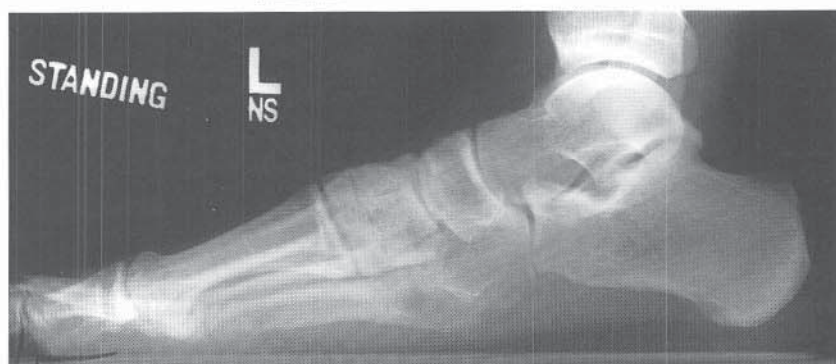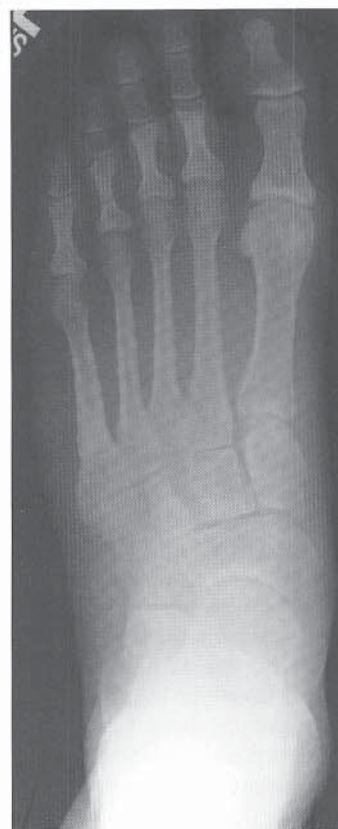Treatment for most phalangeal fractures is symptomatic, with weightbearing as tolerated in a stiff-soled shoe. In the severely displaced fracture, a manual reduction may be required, followed by taping to the adjacent toe (“buddy” taping). In the older child with a displaced fracture, percutaneous pin stabilization of the fracture may be required following reduction. The pin can be removed at 6 weeks, at which time the fracture should be healed and full weightbearing is allowed. Associated nail bed injuries should be

*See references 99, 117, 171, 181, 187, 215.

FIGURE 42–212 An acute zone II injury of the fifth metatarsal, the so-called Jones fracture, in a 15-year-old boy who had pain following a twisting injury while playing basketball. **A**, Injury radiographs. **B**, After 6 weeks of cast immobilization, the radiographs demonstrate healing of this acute Jones fracture.



A



B

repaired and open injuries should be irrigated and debrided and treated with intravenous antibiotics for 24 hours, followed by oral antibiotics for 5 to 7 days.

LAWNMOWER INJURIES

Approximately 25,000 injuries occur each year from power lawnmower accidents in the United States.² Children are involved in approximately 20 percent of these injuries and account for 12 percent of all deaths related to lawnmowers.⁴⁹ The average age of children is between 4 and 8 years, and boys are more often involved than girls.* Some studies report a higher proportion of injuries in children who are passengers or operators of the lawnmower,^{184,223} while others report a greater likelihood of injury in children bystanders.^{57,128}

*See references 14, 57, 96, 124, 128, 136, 223.

Riding lawnmowers are more often involved than push mowers and generally result in more severe injury patterns.²²³ The lower extremities are most often injured, and the majority of injuries result from direct contact with the power blades under the housing of the lawnmower. The wounds sustained from contact with the blades are of two main types, depending on the position of the child at the time of injury: the foot or toes are involved when the child is supine at the time of injury, and the plantar foot or heel is injured when the child is prone at the time of injury.

Assessment of the injured child should be thorough and prompt to allow urgent transfer to the operating room for initial irrigation and debridement. Antibiotics should be administered in the emergency room and should achieve broad coverage with triple antibiotics consisting of a cephalosporin, an aminoglycoside, and penicillin. We prefer multiple debridements at 48-hour intervals until viable tissue is

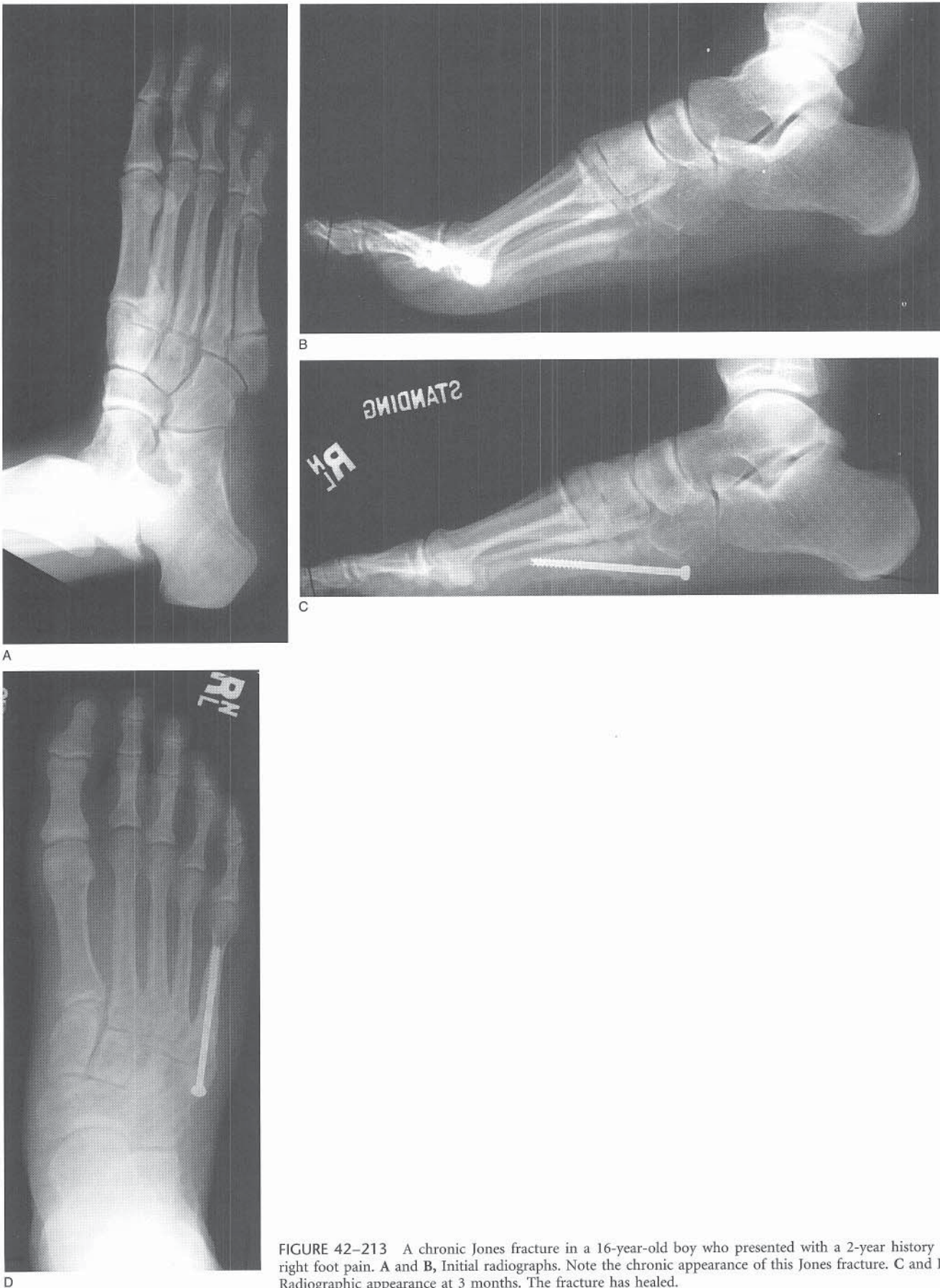


FIGURE 42-213 A chronic Jones fracture in a 16-year-old boy who presented with a 2-year history of right foot pain. A and B, Initial radiographs. Note the chronic appearance of this Jones fracture. C and D, Radiographic appearance at 3 months. The fracture has healed.

present at all wound edges, which usually requires at least three trips to the operating room.⁵⁷ Wounds should be left open between procedures. Significant foreign material can be forced under pressure into the soft tissue envelope, and therefore it is always preferable to repeat the irrigation and debridement procedure if there is any question about tissue viability and sterility prior to soft tissue closure or coverage. Bony injuries should be stabilized using standard techniques at the initial debridement. Up to 80 percent of these injuries require some form of ablative procedure, and attempts should be made to preserve as much length as possible and avoid transdiaphyseal amputation, to prevent difficulties with overgrowth.^{1,128} Although limb salvage is a natural goal following these injuries, an objective analysis of the long-term outcome and the duration of treatment with associated complications must be done.

Soft tissue coverage of most lawnmower injuries can be accomplished with delayed closure or a split thickness skin graft.^{57,88,128,223} Unlike in adults, a split-thickness skin graft works extremely well for most soft tissue injuries in children, including coverage on the plantar aspect of the foot. Vosburgh and colleagues reported results in nine patients with split-thickness skin grafts applied to the heel or plantar aspect of the foot; three had no difficulty and the remaining six had minor areas of junctional hyperkeratosis.²²³ It is important to obtain input from a plastic surgeon at the time of the second or third debridement to plan appropriate soft tissue coverage, especially when free flap coverage is anticipated.

The outcome in these patients is overall satisfactory and largely depends on the force imparted during the initial injury and the location of injury.²²³ Patients in whom the injury was confined to the toe and forefoot have 88 percent of normal function, whereas patients who sustain injuries to the posterior and plantar aspect of the foot retain 72 percent of normal function.²²³ Similarly, Dormans and colleagues reported excellent functional outcomes in patients who sustained paucilaceration-type injuries, while patients who sustained the more common shredding-type injury had poor results.⁵⁷

PUNCTURE INJURIES OF THE FOOT

Puncture injuries of the foot are common in children and most often result when a child steps on a nail.^{68,221} Treatment in the emergency room should consist of tetanus toxoid administration (when appropriate) and irrigation of the entry site with saline using a large syringe and plastic angiocatheter. This can be done under a local anesthetic using an ankle block or under conscious sedation. The use of antibiotics at the initial visit in the emergency room is controversial and without good scientific analysis, and we do not recommend prophylactic administration. If there is concern that the wound is severely contaminated, then a formal debridement in the operating room may be necessary. *Pseudomonas* is the most common organism cultured from children who have a puncture wound and is thought to be due to the presence of this organism in sneakers.*

Complications following these injuries are relatively rare. The incidence of cellulitis following puncture wounds of the foot is reported to be close to 10 percent. Cellulitis

usually can be treated with intravenous antibiotics but may require surgical debridement. The offending organism in cellulitis is usually *Staphylococcus aureus* and not *Pseudomonas*. However, osteomyelitis is the most serious complication from this injury. It is seen in up to 3 percent of these injuries and most often involves the metatarsals, followed by the calcaneus. Penetration of the offending object into the cartilaginous surface at the time of the initial injury is thought to occur.⁶⁸ Systemic signs are usually absent; however, the patient has continued pain and an antalgic gait. The diagnosis is often difficult to make and is best established with an initial radiograph, followed by bone scan and/or MRI if necessary. Treatment is thorough surgical debridement of the soft tissue, bone and cartilage, and/or joint, followed by a 7-day course of an intravenous antibiotic.⁹² *Pseudomonas* is the most common organism and may be associated with *Staphylococcus* infection.⁹² The sequelae of osteomyelitis include recurrent infection, physeal arrest, and early arthritis.

REFERENCES

The Ankle, The Foot

1. Abraham E, Pellicore RJ, Hamilton RC, et al: Stump overgrowth in juvenile amputees. *J Pediatr Orthop* 1986;6:66.
2. Adler P: Ride-on mower hazard analysis 1987-1990: Directorate for Epidemiology. US Consumer Product Safety Commission, Washington, DC, 1993.
3. Anderson DV, Lyne ED: Osteochondritis dissecans of the talus: case report on two family members. *J Pediatr Orthop* 1984;4:356.
4. Anderson IF, Crichton KJ, Grattan-Smith T, et al: Osteochondral fractures of the dome of the talus. *J Bone Joint Surg* 1989;71-A:1143.
5. Andrews JR, Previte WJ, Carson WG: Arthroscopy of the ankle: technique and normal anatomy. *Foot Ankle* 1985;6:29.
6. Angermann P, Jensen P: Osteochondritis dissecans of the talus: long-term results of surgical treatment. *Foot Ankle* 1989;10:161.
7. Arntz CT, Hansen ST Jr: Dislocations and fracture dislocations of the tarsometatarsal joints. *Orthop Clin North Am* 1987;18:105.
8. Arntz CT, Veith RG, Hansen ST Jr: Fractures and fracture-dislocations of the tarsometatarsal joint. *J Bone Joint Surg* 1988;70-A:173.
9. Babst R, Simmen BR, Regazzoni P: [The treatment of fresh Lisfranc dislocations and fracture-dislocations]. *Z Unfallchir Versicherungsmed* 1991;84:159.
10. Baker CL, Andrews JR, Ryan JB: Arthroscopic treatment of transchondral talar dome fractures. *Arthroscopy* 1986;2:82.
11. Barber FA, Britt BT, Ratliff HW, et al: Arthroscopic surgery of the ankle. *Orthop Rev* 1988;17:446.
12. Bauer M, Jonsson K, Linden B: Osteochondritis dissecans of the ankle: a 20-year follow-up study. *J Bone Joint Surg* 1987;69-B:93.
13. Benz G, Kallieris D, Seebock T, et al: Bioresorbable pins and screws in paediatric traumatology. *Eur J Pediatr Surg* 1994;4:103.
14. Bernardo LM, Gardner MJ: Lawn mower injuries to children in Pennsylvania, 1989 to 1993. *Int J Trauma Nurs* 1996;2:36.
15. Berndt A, Hardy M: Transchondral fractures (osteochondritis dissecans) of the talus. *J Bone Joint Surg* 1959;41-A:988.
16. Bishop P: Fractures and epiphyseal separation fractures of the ankle: a classification of 332 cases according to the mechanism of their production. *Am J Rheum* 1932;28:49.
17. Blair WF: Irreducible tarsometatarsal fracture-dislocation. *J Trauma* 1981;21:988.
18. Bonnel F, Barthelemy M: [Injuries of Lisfranc's joint: severe sprains, dislocations, fractures. Study of 39 personal cases and biomechanical classification]. *J Chir (Paris)* 1976;111:573.
19. Bostman O, Hirvensalo E, Vainionpaa S, et al: Degradable polyglycolide rods for the internal fixation of displaced bimalleolar fractures. *Int Orthop* 1990;14:1.
20. Bostman O, Makela EA, Sodergard J, et al: Absorbable polyglycolide pins in internal fixation of fractures in children. *J Pediatr Orthop* 1993;3:242.
21. Brand RA, Black H: *Pseudomonas* osteomyelitis following puncture wounds in children. *J Bone Joint Surg* 1974;56-A:1637.

*See references 21, 56, 67, 74, 75, 93, 94, 100.

22. Broden B: Roentgen examination of the subtaloid joint in fractures of the calcaneus. *Acta Radiol* 1949;31:85.
23. Bruns J, Rosenbach B: Osteochondrosis dissecans of the talus: comparison of results of surgical treatment in adolescents and adults. *Arch Orthop Trauma Surg* 1992;112:23.
24. Bryant DD III, Siegel MG: Osteochondritis dissecans of the talus: a new technique for arthroscopic drilling. *Arthroscopy* 1993;9:238.
25. Buchanan J, Greer RB III: Stress fractures in the calcaneus of a child: a case report. *Clin Orthop* 1978;135:119.
26. Bucholz RW, Henry S, Henley MB: Fixation with bioabsorbable screws for the treatment of fractures of the ankle. *J Bone Joint Surg* 1994; 76-A:319.
27. Burroughs KE, Reimer CD, Fields KB: Lisfranc injury of the foot: a commonly missed diagnosis. *Am Fam Physician* 1998;58:118.
28. Buzzard BM, Briggs PJ: Surgical management of acute tarsometatarsal fracture dislocation in the adult. *Clin Orthop* 1998;353:125.
29. Byrd T: Jones fracture: relearning an old injury. *South Med J* 1992; 85:748.
30. Cameron SE: Noninvasive distraction for ankle arthroscopy. *Arthroscopy* 1997;13:366.
31. Canale ST, Belding RH: Osteochondral lesions of the talus. *J Bone Joint Surg* 1980;62-A:97.
32. Canale ST, Kelly FB Jr: Fractures of the neck of the talus: long-term evaluation of seventy-one cases. *J Bone Joint Surg* 1978;60-A:143.
33. Carothers C, Crenshaw A: Clinical significance of a classification of epiphyseal injuries of the ankle. *Am J Surg* 1953;89:879.
34. Carp L: Fracture of the fifth metatarsal bone with special reference to delayed union. *Ann Surg* 1927;86:308.
35. Cass JR, Peterson HA: Salter-Harris type-IV injuries of the distal tibial epiphyseal growth plate, with emphasis on those involving the medial malleolus. *J Bone Joint Surg* 1983;65-A:1059.
36. Caterini R, Farsetti P, Ippolito E: Long-term followup of physeal injury to the ankle. *Foot Ankle* 1991;11:372.
37. Chapman H, Galway H: Os calcis fractures in childhood. *J Bone Joint Surg* 1977;59-B:510.
38. Chin TW, Mitra AK, Lim GH, et al: Arthroscopic treatment of osteochondral lesion of the talus. *Ann Acad Med Singapore* 1996;25:236.
39. Clement DA, Worlock PH: Triplane fracture of the distal tibia: a variant in cases with an open growth plate. *J Bone Joint Surg* 1987; 69-B:412.
40. Cole RJ, Brown HP, Stein RE, et al: Avulsion fracture of the tuberosity of the calcaneus in children: a report of four cases and review of the literature. *J Bone Joint Surg* 1995;77-A:1568.
41. Cooper A: *A Treatise on Dislocations and Fractures of the Joints*. London, Longman, Hurst, Orme & Brown, 1822.
42. Cooperman DR, Spiegel PG, Laros GS: Tibial fractures involving the ankle in children: the so-called triplane epiphyseal fracture. *J Bone Joint Surg* 1978;60-A:1040.
43. Craigen MA, Clarke NM: Bilateral "Jones" fractures of the fifth metatarsal following relapse of talipes equinovarus. *Injury* 1996;27:599.
44. Crawford AH: Triplane fracture. *Orthop Consult* 1983;68:12.
45. Crenshaw A: Injuries to the distal epiphyses. *Clin Orthop Rel Res* 1965;41:98.
46. Crosby LA, Fitzgibbons T: Computerized tomography scanning of acute intra-articular fractures of the calcaneus: a new classification system [see comments]. *J Bone Joint Surg* 1990;72-A:852.
47. Curtis MJ, Myerson M, Szura B: Tarsometatarsal joint injuries in the athlete. *Am J Sports Med* 1993;21:497.
48. Dameron TB Jr: Fractures and anatomical variations of the proximal portion of the fifth metatarsal. *J Bone Joint Surg* 1975;57-A:788.
49. David J: Deaths related to ride-on mowers 1987–1990. US Consumer Product Safety Commission, Washington, DC, 1993.
50. de Beer JD, Maloon S, Hudson DA: Calcaneal fractures in children. *S Afr Med J* 1989;76:53.
51. Delee J: Fractures and dislocations of the foot. In Mann R (ed): *Surgery of the Foot*. St. Louis, CV Mosby Co, 1986.
52. Denton JR, Fischer SJ: The medial triplane fracture: report of an unusual injury. *J Trauma* 1981;21:991.
53. DeSmet A, Fisher D, Burnstein M: Value of MR imaging in staging osteochondral lesions of the talus (osteochondritis dissecans): results in 14 patients. *AJR Am J Roentgenol* 1990;154:555.
54. Dias LS, Giegerich CR: Fractures of the distal tibial epiphysis in adolescence. *J Bone Joint Surg* 1983;65-A:438.
55. Dias LS, Tachdjian MO: Physeal injuries of the ankle in children: classification. *Clin Orthop* 1978;136:230.
56. Dixon RS, Sydnor CH IV: Puncture wound pseudomonas osteomyelitis of the foot. *J Foot Ankle Surg* 1993;32:434.
57. Dormans JP, Azzoni M, Davidson RS, et al: Major lower extremity lawn mower injuries in children. *J Pediatr Orthop* 1995;15:78.
58. Eastwood DM, Gregg PJ, Atkins RM: Intra-articular fractures of the calcaneus. Part I. Pathological anatomy and classification. *J Bone Joint Surg* 1993;75-B:183.
59. Eastwood DM, Langkamer VG, Atkins RM: Intra-articular fractures of the calcaneus. Part II. Open reduction and internal fixation by the extended lateral transcaneal approach. *J Bone Joint Surg* 1993; 75-B:189.
60. Eberle C, Rhomberg P, Metzger U: [Long-term follow-up of surgically treated intra-articular calcaneus fractures]. *Helv Chir Acta* 1994;60: 629.
61. Ertl JP, Barrack RL, Alexander AH, et al: Triplane fracture of the distal tibial epiphysis: long-term follow-up. *J Bone Joint Surg* 1988; 70-A:967.
62. Escalas F, Figueras JM, Merino JA: Dislocation of the peroneal tendons: long-term results of surgical treatment. *J Bone Joint Surg* 1980; 62-A:451.
63. Essex-Lopresti P: The mechanism, reduction technique, and results in fractures of the os calcis. *Br J Surg* 1952;39:395.
64. Faciszewski T, Burks RT, Manaster BJ: Subtle injuries of the Lisfranc joint [see comments]. *J Bone Joint Surg* 1990;72-A:1519.
65. Feldman DS, Otsuka NY, Hedden DM: Extra-articular triplane fracture of the distal tibial epiphysis. *J Pediatr Orthop* 1995;15:479.
66. Ferkel RD, Fasulo GJ: Arthroscopic treatment of ankle injuries. *Orthop Clin North Am* 1994;25:17.
67. Fisher MC, Goldsmith JF, Gilligan PH: Sneakers as a source of *Pseudomonas aeruginosa* in children with osteomyelitis following puncture wounds. *J Pediatr* 1985;106:607.
68. Fitzgerald RH Jr, Cowan JD: Puncture wounds of the foot. *Orthop Clin North Am* 1975;6:965.
69. Flick AB, Gould N: Osteochondritis dissecans of the talus (transchondral fractures of the talus): review of the literature and new surgical approach for medial dome lesions. *Foot Ankle* 1985;5:165.
70. Frank A, Cohen P, Beauflis P, et al: Arthroscopic treatment of osteochondral lesions of the talar dome. *Arthroscopy* 1989;5:57.
71. Gill G, Abbott I: Varus deformity of the ankle following injury to the distal epiphyseal cartilage of the tibia in growing children. *Surg Gynecol Obstet* 1941;72:659.
72. Goiney RC, Connell DG, Nichols DM: CT evaluation of tarsometatarsal fracture-dislocation injuries. *AJR Am J Roentgenol* 1985;144:985.
73. Grace DL: Irreducible fracture-separations of the distal tibial epiphysis. *J Bone Joint Surg* 1983;65-B:160.
74. Graham BS, Gregory DW: *Pseudomonas aeruginosa* causing osteomyelitis after puncture wounds of the foot. *South Med J* 1984;77:1228.
75. Green NE, Bruno J III: *Pseudomonas* infections of the foot after puncture wounds. *South Med J* 1980;73:146.
76. Greenspoon J, Rosman M: Medial osteochondritis of the talus in children: review and new surgical management. *J Pediatr Orthop* 1987; 7:705.
77. Griffiths J, Menelaus M: Symptomatic ossicles for the tip of the lateral malleolus in children. *J Bone Joint Surg* 1987;69-B:317.
78. Groshar D, Alpers M, Mendes DG, et al: Bone scintigraphy findings in Lisfranc joint injury. *Foot Ankle Int* 1995;16:710.
79. Guhl JF: New techniques for arthroscopic surgery of the ankle: preliminary report. *Orthopedics* 1986;9:261.
80. Haliburton B, Sullivan C, Kelly P, et al: The extra-osseous and intra-osseous blood supply of the talus. *J Bone Joint Surg* 1958;40-A:1115.
81. Hardcastle PH, Reschauer R, Kutscha-Lissberg E, et al: Injuries to the tarsometatarsal joint: incidence, classification and treatment. *J Bone Joint Surg* 1982;64-B:349.
82. Hawkins L: Fracture of the lateral process of the talus. *J Bone Joint Surg* 1965;47-A:1170.
83. Hawkins LG: Fractures of the neck of the talus. *J Bone Joint Surg* 1970;52-A:991.
84. Heckman JD, McLean MR: Fractures of the lateral process of the talus. *Clin Orthop* 1985;199:108.
85. Henderson RC: Posttraumatic necrosis of the talus: the Hawkins sign versus magnetic resonance imaging. *J Orthop Trauma* 1991;5:96.
86. Higuera J, Laguna R, Peral M, et al: Osteochondritis dissecans of the talus during childhood and adolescence. *J Pediatr Orthop* 1998;18:328.
87. Hirvensalo E: Fracture fixation with biodegradable rods: forty-one cases of severe ankle fractures. *Acta Orthop Scand* 1989;60:601.

88. Horowitz JH, Nichter LS, Kenney JG, et al: Lawnmower injuries in children: lower extremity reconstruction. *J Trauma* 1985;25:1138.
89. Hynes D, O'Brien T: Growth disturbance lines after injury of the distal tibial physis: their significance in prognosis. *J Bone Joint Surg* 1988;70-B:231.
90. Iannaccone WM, Dalton GP: Osteochondritis dissecans of the talus presenting as an ankle ganglion. *Orthopedics* 1997;20:348.
91. Inokuchi S, Usami N, Hiraishi E, et al: Calcaneal fractures in children. *J Pediatr Orthop* 1998;18:469.
92. Jacobs RF, McCarthy RE, Elser JM: *Pseudomonas* osteochondritis complicating puncture wounds of the foot in children: a 10-year evaluation. *J Infect Dis* 1989;160:657.
93. Jensen I, Wester JU, Rasmussen F, et al: Prognosis of fracture of the talus in children: 21 (7–34)-year follow-up of 14 cases. *Acta Orthop Scand* 1994;65:398.
94. Johanson PH: *Pseudomonas* infections of the foot following puncture wounds. *JAMA* 1968;204:170.
95. Johnson EE, Gebhardt JS: Surgical management of calcaneal fractures using bilateral incisions and minimal internal fixation. *Clin Orthop* 1993;290:117.
96. Johnstone BR, Bennett CS: Lawn mower injuries in children. *Aust NZ J Surg* 1989;59:713.
97. Jones R: Fracture of the base of the fifth metatarsal bone by indirect violence. *Ann Surg* 1902;35:697.
98. Josefsson PO, Karlsson M, Redlund-Johnell I, et al: Closed treatment of Jones fracture: good results in 40 cases after 11–26 years. *Acta Orthop Scand* 1994;65:545.
99. Josefsson PO, Karlsson M, Redlund-Johnell I, et al: Jones fracture: surgical versus nonsurgical treatment. *Clin Orthop* 1994;299:252.
100. Joseph WS, Le Frock JL: Infections complicating puncture wounds of the foot. *J Foot Surg* 1987;26:S30.
101. Jurgensen I, Bachmann G, Siaplaouras J, et al: [Clinical value of conventional radiology and MRI in assessing osteochondrosis dissecans stability]. *Unfallchirurg* 1996;99:758.
102. Karrholm J, Hansson LI, Laurin S: Computed tomography of intra-articular supination-eversion fractures of the ankle in adolescents. *J Pediatr Orthop* 1981;1:181.
103. Kelly P, Sullivan C: Blood supply of the talus. *Clin Orthop Rel Res* 1963;30:37.
104. Kleiger B, Mankin H: Fracture of the lateral portion of the distal tibial epiphysis. *J Bone Joint Surg* 1964;46-A:25.
105. Kling T, Bright R, Hensinger R: Distal tibial physeal fractures in children that may require open reduction. *J Bone Joint Surg* 1984;66-A:647.
106. Kling TF Jr: Operative treatment of ankle fractures in children. *Orthop Clin North Am* 1990;21:381.
107. Koval KJ, Sanders R: The radiologic evaluation of calcaneal fractures. *Clin Orthop* 1993;290:41.
108. Laliotis N, Pennie BH, Carty H, et al: Toddler's fracture of the calcaneum. *Injury* 1993;24:169.
109. Lamy C, Stienstra JJ: Complications in ankle arthroscopy. *Clin Podiatr Med Surg* 1994;11:523.
110. Langenskiöld A: Traumatic premature closure of the distal tibial epiphyseal plate. *Acta Orthop Scand* 1967;38:520.
111. Lapidus P: Os subtibiale: inconstant bone over the tip of the medial malleolus. *J Bone Joint Surg* 1933;15:766.
112. Lauge-Hansen N: Fractures of the ankle. I. Analytic historic survey as basis of new experimental, roentgenologic, and clinical investigations. *Arch Surg* 1948;56:259.
113. Lauge-Hansen N: Fractures of the ankle. II. Combined experimental-surgical and experimental-roentgenologic investigations. *Arch Surg* 1950;60:957.
114. Lauge-Hansen N: Fractures of the ankle. III. Genetic roentgenologic diagnosis of fractures of the ankle. *Am J Rheum* 1954;71:456.
115. Lauge-Hansen H: Fractures of the ankle. IV. Clinical use of genetic roentgen diagnosis and genetic reduction. *Arch Surg* 1952;64:488.
116. Lauge-Hansen N: Fractures of the ankle. V. Pronation-dorsiflexion fracture. *Arch Surg* 1953;67:813.
117. Lawrence SJ, Botte MJ: Jones' fractures and related fractures of the proximal fifth metatarsal. *Foot Ankle* 1993;14:358.
118. Lawson J, Ogden J, Sella E, et al: The painful accessory navicular. *Skeletal Radiol* 1984;12:250.
119. Lee CK, Mercurio C: Operative treatment of osteochondritis dissecans in situ by retrograde drilling and cancellous bone graft: a preliminary report. *Clin Orthop* 1981;158:129.
120. Leenen LP, van der Werken C: Fracture-dislocations of the tarsometatarsal joint: a combined anatomical and computed tomographic study. *Injury* 1992;23:51.
121. Letournel E: Open treatment of acute calcaneal fractures. *Clin Orthop* 1993;290:60.
122. Letts RM: The hidden adolescent ankle fracture. *J Pediatr Orthop* 1982;2:161.
123. Letts RM, Gibeault D: Fractures of the neck of the talus in children. *Foot Ankle* 1980;1:74.
124. Letts RM, Mardirosian A: Lawnmower injuries in children. *Can Med Assoc J* 1977;116:1151.
125. Leung KS, Yuen KM, Chan WS: Operative treatment of displaced intra-articular fractures of the calcaneum: medium-term results. *J Bone Joint Surg* 1993;75-B:196.
126. Linhart WE, Hollwarth M: [Fractures of the talus in children]. *Unfallchirurg* 1985;88:168.
127. Loomer R, Fisher C, Lloyd-Smith R, et al: Osteochondral lesions of the talus. *Am J Sports Med* 1993;21:13.
128. Love SM, Grogan DP, Ogden JA: Lawn-mower injuries in children. *J Orthop Trauma* 1988;2:94.
129. Lu J, Ebraheim NA, Skie M, et al: Radiographic and computed tomographic evaluation of Lisfranc dislocation: a cadaver study. *Foot Ankle Int* 1997;18:351.
130. Lundeen RO: Techniques of ankle arthroscopy. *J Foot Surg* 1987;26:22.
131. Ly PN, Fallat LM: Trans-chondral fractures of the talus: a review of 64 surgical cases. *J Foot Ankle Surg* 1993;32:352.
132. Lynn MD: The triplane distal tibial epiphyseal fracture. *Clin Orthop* 1972;86:187.
133. MacNealy GA, Rogers LF, Hernandez R, et al: Injuries of the distal tibial epiphysis: systematic radiographic evaluation. *AJR Am J Roentgenol* 1982;138:683.
134. Mandracchia VJ, Buddecke DE Jr, Giesking JL: Osteochondral lesions of the talar dome: a comprehensive review with retrospective study. *Clin Podiatr Med Surg* 1999;16:725.
135. Marmor L: An unusual fracture of the tibial epiphysis. *Clin Orthop* 1970;73:132.
136. Martin LI: Lawnmower injuries in children: destructive and preventable. *Plast Surg Nurs* 1990;10:69.
137. Matteri RE, Frymoyer JW: Fracture of the calcaneus in young children: report of three cases. *J Bone Joint Surg* 1973;55-A:1091.
138. Mayo K: Fractures of the talus: principles of management and techniques of treatment. *Tech Orthop* 1987;2(3):42.
139. Mazel C, Rigault P, Padovani JP, et al: [Fractures of the talus in children: apropos of 23 cases]. *Rev Chir Orthop* 1986;72:183.
140. McCrory P, Bladin C: Fractures of the lateral process of the talus: a clinical review. "Snowboarder's ankle." *Clin J Sport Med* 1996;6:124.
141. McCullough CJ, Venugopal V: Osteochondritis dissecans of the talus: the natural history. *Clin Orthop* 1979;144:264.
142. McDougall A: The os trigonum. *J Bone Joint Surg* 1955;37-B:257.
143. McFarland B: Traumatic arrest of the epiphyseal growth at the lower end of the tibia. *Br J Surg* 1931;19:78.
144. McLennan JG: Treatment of acute and chronic luxations of the peroneal tendons. *Am J Sports Med* 1980;8:432.
145. Michelson JD: Fractures about the ankle. *J Bone Joint Surg* 1995;77-A:142.
146. Michelson JD, Clarke HJ, Jinnah RH: The effect of loading on tibiotalar alignment in cadaver ankles. *Foot Ankle* 1990;10:280.
147. Michelson JD, Magid D, Ney DR, et al: Examination of the pathologic anatomy of ankle fractures. *J Trauma* 1992;32:65.
148. Mindell E, Cisek I, Kartalian G, et al: Late results of injuries to the talus: analysis of forty cases. *J Bone Joint Surg* 1963;45-A:221.
149. Mukherjee SK, Young AB: Dome fracture of the talus: a report of ten cases. *J Bone Joint Surg* 1973;55-B:319.
150. Mulcahy DM, McCormack DM, Stephens MM: Intra-articular calcaneal fractures: effect of open reduction and internal fixation on the contact characteristics of the subtalar joint. *Foot Ankle Int* 1998;19:842.
151. Mulfinger GL, Trueta J: The blood supply of the talus. *J Bone Joint Surg* 1970;52-B:160.
152. Myerson M, Manoli A: Compartment syndromes of the foot after calcaneal fractures. *Clin Orthop* 1993;290:142.
153. Myerson M, Quill GE Jr: Late complications of fractures of the calcaneus. *J Bone Joint Surg* 1993;75-A:331.
154. Myerson MS, Fisher RT, Burgess AR, et al: Fracture dislocations of

- the tarsometatarsal joints: end results correlated with pathology and treatment. *Foot Ankle* 1986;6:225.
155. Nicholas R, Hadley J, Paul C, et al: "Snowboarder's fracture": fracture of the lateral process of the talus. *J Am Board Fam Pract* 1994;7:130.
 156. Ogden JA, Lee J: Accessory ossification patterns and injuries of the malleoli. *J Pediatr Orthop* 1990;10:306.
 157. Ogilvie-Harris DJ, Sarrosa EA: Arthroscopic treatment of osteochondritis dissecans of the talus. *Arthroscopy* 1999;15:805.
 158. Owen RJ, Hickey FG, Finlay DB: A study of metatarsal fractures in children. *Injury* 1995;26:537.
 159. Pablot SM, Daneman A, Stringer DA, et al: The value of computed tomography in the early assessment of comminuted fractures of the calcaneus: a review of three patients. *J Pediatr Orthop* 1985;5:435.
 160. Parisien JS: Arthroscopic treatment of osteochondral lesions of the talus. *Am J Sports Med* 1986;14:211.
 161. Peiro A, Aracil J, Martos F, et al: Triplane distal tibial epiphyseal fracture. *Clin Orthop* 1981;160:196.
 162. Peltier LF: Eponymic fractures: Robert Jones and Jones's fracture. *Surgery* 1972;71:522.
 163. Pereles TR, Koval KJ, Feldman DS: Fracture-dislocation of the neck of the talus in a ten-year-old child: a case report and review of the literature. *Bull Hosp Jt Dis* 1996;55:88.
 164. Perez Blanco R, Rodriguez Merchan C, Canosa Sevillano R, et al: Tarsometatarsal fractures and dislocations. *J Orthop Trauma* 1988; 2:188.
 165. Peterson CA, Peterson HA: Analysis of the incidence of injuries to the epiphyseal growth plate. *J Trauma* 1972;12:275.
 166. Peterson L, Goldie I, Lindell D: The arterial supply of the talus. *Acta Orthop Scand* 1974;45:260.
 167. Peterson L, Goldie IF: The arterial supply of the talus: a study on the relationship to experimental talar fractures. *Acta Orthop Scand* 1975; 46:1026.
 168. Peterson L, Goldie IF, Irstam L: Fracture of the neck of the talus: a clinical study. *Acta Orthop Scand* 1977;48:696.
 169. Peterson L, Romanus B, Dahlberg E: Fracture of the collum tali: an experimental study. *J Biomech* 1976;9:277.
 170. Pettine KA, Morrey BF: Osteochondral fractures of the talus: a long-term follow-up. *J Bone Joint Surg* 1987;69-B:89.
 171. Pietropaoli MP, Wnorowski DC, Werner FW, et al: Intramedullary screw fixation of Jones fractures: a biomechanical study. *Foot Ankle Int* 1999;20:560.
 172. Potter HG, Deland JT, Gusmer PB, et al: Magnetic resonance imaging of the Lisfranc ligament of the foot. *Foot Ankle Int* 1998;19:438.
 173. Powell H: Extra center of ossification for the medial malleolus in children: incidence and significance. *J Bone Joint Surg* 1961;43-B:107.
 174. Pritsch M, Horoshovski H, Farine I: Ankle arthroscopy. *Clin Orthop* 1984;184:137.
 175. Pritsch M, Horoshovski H, Farine I: Arthroscopic treatment of osteochondral lesions of the talus. *J Bone Joint Surg* 1986;68-A:862.
 176. Quenu E, Kuss G: Étude sur les luxations du metatarsale (luxations metatarsotarsiennes) du diastasis entre le 1er et le 2^e metatarsien. *Rev Chir* 1909;39:281.
 177. Ragozzino A, Rossi G, Esposito S, et al: [Computerized tomography of osteochondral diseases of the talus dome]. *Radiol Med (Torino)* 1996;92:682.
 178. Rainaut JJ, Cedard C, D'Hour JP: [Tarso-metatarsal luxations]. *Rev Chir Orthop Reparatrice Appar Mot* 1966;52:449.
 179. Rasmussen F, Schantz K: Radiologic aspects of calcaneal fractures in childhood and adolescence. *Acta Radiol [Diagn] (Stockh)* 1986;27:575.
 180. Resch S, Stenstrom A: The treatment of tarsometatarsal injuries. *Foot Ankle* 1990;11:117.
 181. Rettig AC, Shelbourne KD, Wilckens J: The surgical treatment of symptomatic nonunions of the proximal (metaphyseal) fifth metatarsal in athletes. *Am J Sports Med* 1992;20:50.
 182. Rosenberg GA, Patterson BM: Tarsometatarsal (Lisfranc's) fracture-dislocation. *Am J Orthop* 1995;2(suppl 1):7.
 183. Ross G, Cronin R, Hauenblas J, et al: Plantar ecchymosis sign: a clinical aid to diagnosis of occult Lisfranc tarsometatarsal injuries. *J Orthop Trauma* 1996;10:119.
 184. Ross PM, Schwentker EP, Bryan H: Mutilating lawn mower injuries in children. *JAMA* 1976;236:480.
 185. Rowe C, Sakellarides H, Freeman P, et al: Fractures of the os calcis: a long-term follow-up study of 146 patients. *JAMA* 1963;184:920.
 186. Salter RB: Injuries of the ankle in children. *Orthop Clin North Am* 1974;5:147.
 187. Sammarco GJ: The Jones fracture. *Instr Course Lect* 1993;42:201.
 188. Sanders R, Gregory P: Operative treatment of intra-articular fractures of the calcaneus. *Orthop Clin North Am* 1995;26:203.
 189. Sanders TG, Ptaszek AJ, Morrison WB: Fracture of the lateral process of the talus: appearance at MR imaging and clinical significance. *Skeletal Radiol* 1999;28:236.
 190. Sangeorzan BJ, Veith RG, Hansen ST Jr: Salvage of Lisfranc's tarsometatarsal joint by arthrodesis. *Foot Ankle* 1990;10:193.
 191. Schantz K, Rasmussen F: Calcaneus fracture in the child. *Acta Orthop Scand* 1987;58:507.
 192. Schantz K, Rasmussen F: Good prognosis after calcaneal fracture in childhood. *Acta Orthop Scand* 1988;59:560.
 193. Scharling M: Osteochondritis dissecans of the talus. *Acta Orthop Scand* 1978;49:89.
 194. Schlesinger I, Wedge JH: Percutaneous reduction and fixation of displaced juvenile Tillaux fractures: a new surgical technique. *J Pediatr Orthop* 1993;13:389.
 195. Schmidt TL, Weiner DS: Calcaneal fractures in children: an evaluation of the nature of the injury in 56 children. *Clin Orthop* 1982;171:150.
 196. Schwend RK, Hennrikus WL, O'Brien TJ, et al: Complications when using the cannulated 3.5 mm screw system. *Orthopedics* 1997;20:221.
 197. Shereff MJ, Yang QM, Kummer FJ, et al: Vascular anatomy of the fifth metatarsal. *Foot Ankle* 1991;11:350.
 198. Shin AY, Moran ME, Wenger DR: Intramalleolar triplane fractures of the distal tibial epiphysis. *J Pediatr Orthop* 1997;17:352.
 199. Silas SI, Herzenberg JE, Myerson MS, et al: Compartment syndrome of the foot in children [see comments]. *J Bone Joint Surg* 1995;77-A:356.
 200. Smith BG, Rand F, Jaramillo D, et al: Early MR imaging of lower-extremity physal fracture-separations: a preliminary report. *J Pediatr Orthop* 1994;14:526.
 201. Smith JW, Arnoczky SP, Hersh A: The intraosseous blood supply of the fifth metatarsal: implications for proximal fracture healing. *Foot Ankle* 1992;13:143.
 202. Sneppen O, Christensen SB, Krogsoe O, et al: Fracture of the body of the talus. *Acta Orthop Scand* 1977;48:317.
 203. Spiegel PG, Cooperman DR, Laros GS: Epiphyseal fractures of the distal ends of the tibia and fibula: a retrospective study of two hundred and thirty-seven cases in children. *J Bone Joint Surg* 1978;60-A:1046.
 204. Spinella A, Turco V: Avulsion fracture of the distal tibial epiphysis in skeletally immature athletes (juvenile Tillaux fracture). *Orthop Rev* 1988;17:1245.
 205. Starshak RJ, Simons GW, Sty JR: Occult fracture of the calcaneus: another toddler's fracture. *Pediatr Radiol* 1984;14:37.
 206. Sucato D, Krackow K: Dislocation of the peroneal tendons: surgical treatment. *J Orthop Tech* 1995;3:91.
 207. Swanson TV, Bray TJ, Holmes GB Jr: Fractures of the talar neck: a mechanical study of fixation. *J Bone Joint Surg* 1992;74-A:544.
 208. Szyzkowitz R, Reschauer R, Seggl W: Eighty-five talus fractures treated by ORIF with five to eight years of follow-up study of 69 patients. *Clin Orthop* 1985;199:97.
 209. Tachdjian M: *The Child's Foot*. Philadelphia, WB Saunders Co, 1985.
 210. Takakura Y, Takaoka T, Tanaka Y, et al: Results of opening-wedge osteotomy for the treatment of a post-traumatic varus deformity of the ankle. *J Bone Joint Surg* 1998;80-A:213.
 211. Takao M, Ochi M, Shu N, et al: Bandage distraction technique for ankle arthroscopy. *Foot Ankle Int* 1999;20:389.
 212. Tan YH, Chin TW, Mitra AK, et al: Tarsometatarsal (Lisfranc's) injuries: results of open reduction and internal fixation. *Ann Acad Med Singapore* 1995;24:816.
 213. Thomas H: Calcaneal fractures in childhood. *Br J Surg* 1969;56:664.
 214. Thordarson DB, Triffon MJ, Terk MR: Magnetic resonance imaging to detect avascular necrosis after open reduction and internal fixation of talar neck fractures. *Foot Ankle Int* 1996;17:742.
 215. Torg JS, Balduini FC, Zelko RR, et al: Fractures of the base of the fifth metatarsal distal to the tuberosity: classification and guidelines for non-surgical and surgical management. *J Bone Joint Surg* 1984;66-A:209.
 216. Torg JS, Ruggiero RA: Comminuted epiphyseal fracture of the distal tibia: a case report and review of the literature. *Clin Orthop* 1975; 110:215.
 217. Treadwell JR, Kahn MD: Lisfranc arthrodesis for chronic pain: a cannulated screw technique. *J Foot Ankle Surg* 1998;37:28.
 218. Trillat A, Lerat JL, LeClerc P, et al: Tarsometatarsal fracture-dislocations. *Rev Chir Orthop* 1976;62:685.
 219. Tucker DJ, Feder JM, Boylan JP: Fractures of the lateral process of

- the talus: two case reports and a comprehensive literature review. *Foot Ankle Int* 1998;19:641.
220. van der Werf GJ, Tonino AJ: Tarsometatarsal fracture-dislocation. *Acta Orthop Scand* 1984;55:647.
221. Verdile VP, Freed HA, Gerard J: Puncture wounds to the foot. *J Emerg Med* 1989;7:193.
222. von Laer L: Classification, diagnosis, and treatment of transitional fractures of the distal part of the tibia. *J Bone Joint Surg* 1985;67-A:687.
223. Vosburgh CL, Gruel CR, Herndon WA, et al: Lawn mower injuries of the pediatric foot and ankle: observations on prevention and management. *J Pediatr Orthop* 1995;15:504.
224. Wester JU, Jensen IE, Rasmussen F, et al: Osteochondral lesions of the talar dome in children: a 24 (7–36) year follow-up of 13 cases. *Acta Orthop Scand* 1994;65:110.
225. Whipple TL, Martin DR, McIntyre LF, et al: Arthroscopic treatment of triplane fractures of the ankle. *Arthroscopy* 1993;9:456.
226. Wildenauer E: Die Blutversorgung des Talus. *Z Anat* 1950;115:32.
227. Wiley JJ: The mechanism of tarso-metatarsal joint injuries. *J Bone Joint Surg* 1971;53-B:474.
228. Wiley JJ: Tarso-metatarsal joint injuries in children. *J Pediatr Orthop* 1981;1:255.
229. Wiley JJ, Proffitt A: Fractures of the os calcis in children. *Clin Orthop* 1984;188:131.
230. Wilppula E: Tarsometatarsal fracture-dislocation: late results in 26 patients. *Acta Orthop Scand* 1973;44:335.
231. Wilson DW: Injuries of the tarso-metatarsal joints: etiology, classification and results of treatment. *J Bone Joint Surg* 1972;54-B:677.
232. Wiltse LL: Valgus deformity of the ankle: a sequel to acquired or congenital abnormalities of the fibula. *J Bone Joint Surg* 1972;54-A:595.
233. Woods K, Harris I: Osteochondritis dissecans of the talus in identical twins. *J Bone Joint Surg* 1995;77-B:331.
234. Yates CK, Grana WA: A simple distraction technique for ankle arthroscopy. *Arthroscopy* 1988;4:103.
235. Yvars MF: Osteochondral fractures of the dome of the talus. *Clin Orthop* 1976;114:185.