

Benign Musculoskeletal Tumors

Simple Bone Cysts (Solitary Bone Cyst, Unicameral Bone Cyst), 1901

Aneurysmal Bone Cyst, 1906

Fibrous Dysplasia, 1909

Osteofibrous Dysplasia of the Tibia and Fibula (Campanacci's Disease), 1914

Solitary Osteochondroma, 1917

Hereditary Multiple Exostoses, 1920

Solitary Enchondroma, 1926

Multiple Enchondromatosis (Ollier's Disease) and Maffucci's Syndrome, 1927

Chondroblastoma, 1929

Chondromyxoid Fibroma, 1930

Osteoid Osteoma, 1933

Osteblastoma, 1936

Histiocytosis X (Langerhans' Cell Histiocytosis), 1938

Nonossifying Fibroma and Fibrous Cortical Defect, 1942

Primary Synovial Chondromatosis, 1944

Pigmented Villonodular Synovitis and Giant-Cell Tumor of the Tendon Sheath, 1944

Dysplasia Epiphysealis Hemimelica (Trevor's Disease), 1946

Simple Bone Cysts (Solitary Bone Cyst, Unicameral Bone Cyst)

Simple bone cysts are benign tumors of childhood and adolescence. They represent approximately 3 percent of all biopsied primary bone tumors and nearly always occur during the first two decades of life, most often between 4 and 10 years of age.¹⁸⁵ There is a male predominance, with a 2:1 male-female ratio. The majority of cysts occur in the metaphyseal region of the proximal humerus or femur, with approximately 50 percent of cases involving the humerus and 18 to 27 percent affecting the femur. The next most common sites are the proximal and distal tibia. Occasionally, cysts may be found in the calcaneus, fibula, ulna, radius, pelvis, talus, or axial skeleton* (Fig. 37-1).

Rarely does more than one cyst occur in an individual, thus the term *solitary bone cyst*. The term *unicameral bone cyst* implies that one chamber exists. Although one large cavity is usually found, a cyst may become multiloculated following a fracture because of the formation of multiple bony septations, thus making the term *unicameral* technically incorrect.

Simple cysts are often categorized as "active" or "latent" based on their proximity to the growth plate.^{128,195} A cyst that is juxtaphyseal (less than 0.5 cm from the physis) is considered "active" and possesses greater potential for growth. A cyst that has grown away from the plate is considered "latent" and, theoretically, no longer has the capacity for growth (Fig. 37-2). In reality, though, latent cysts con-

tinue to have growth potential, as proved time and again by their unexpected recurrence following treatment in the young individual. After skeletal maturity, it is uncommon for the cysts to recur or progressively worsen.

ETIOLOGY

The cause of simple bone cysts remains uncertain. Any theory relating to the etiology of simple bone cysts should be able to explain the following factors: (1) more than 70 percent are discovered in childhood; (2) more than 95 percent arise from or involve the metaphysis; (3) most occur in the proximal humerus or femur; (4) a cyst wall and fluid high in protein content are common; and (5) simple bone cysts represent a benign process with a significant recurrence rate following treatment.¹⁸⁵

Mirra hypothesized an intraosseous synovial cyst in which a small amount of synovial tissue became entrapped in an intraosseous position during early infant development or secondary to trauma at birth.¹⁸⁵ Over time, increased pressure secondary to secretions would lead to expansion within the bone. Jaffe and Lichtenstein postulated that cysts resulted from a localized failure of ossification in the metaphyseal area during periods of rapid growth.¹³¹ Cohen proposed that the cause of the cyst was blockage of the circulation (venous obstruction) and drainage of interstitial fluid in rapidly growing bone. He based this theory on the finding that the chemical constituents of the fluid in simple bone cysts are similar to those of serum.^{61,62} Current literature further substantiates this theory of a disturbance in or occlusion of the intramedullary venous circulation.^{58,103,148,149,256,294}

Drilling, trepanation, and reaming of the medullary cavity

*See references 2, 3, 176, 189, 211, 251, 261, 307.

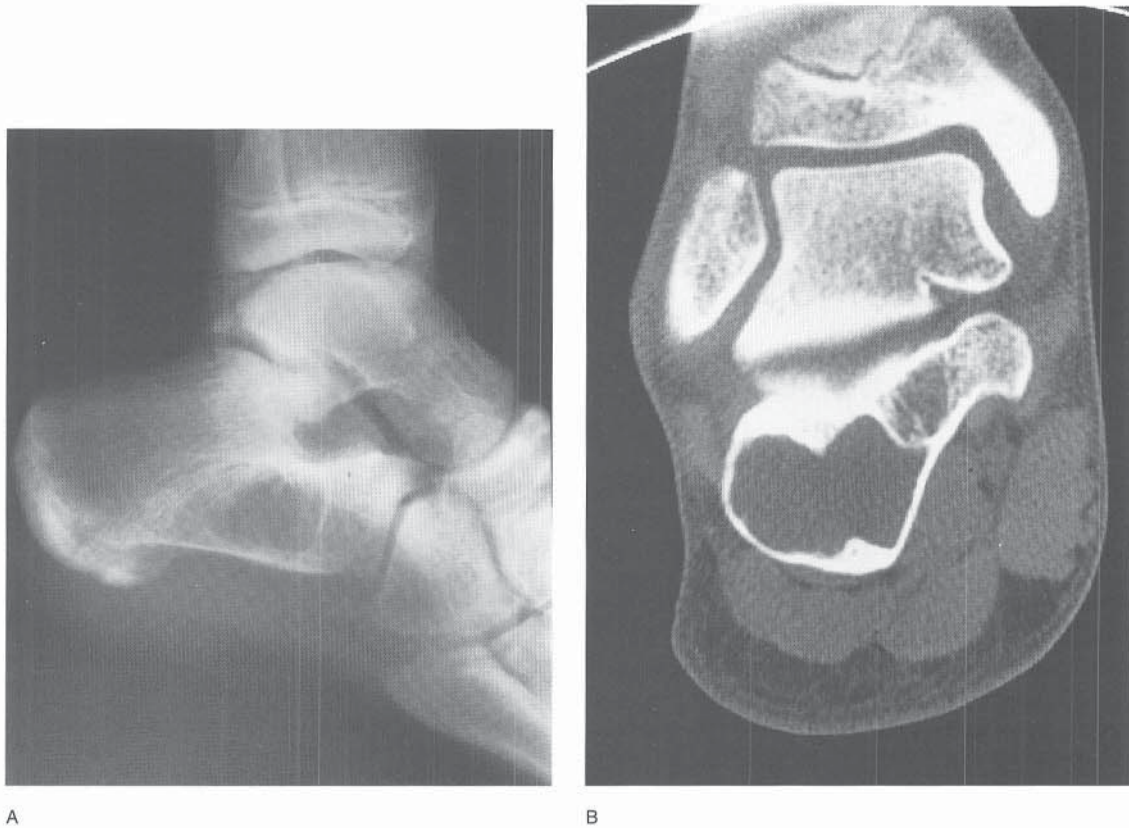


FIGURE 37-1 Imaging findings in a 14-year-old boy with pain in his heel. **A**, Radiograph demonstrating the lucent solitary bone cyst in the calcaneus. **B**, A CT scan showed the extent of the lesion, which is surrounded by a rim of cortical bone.

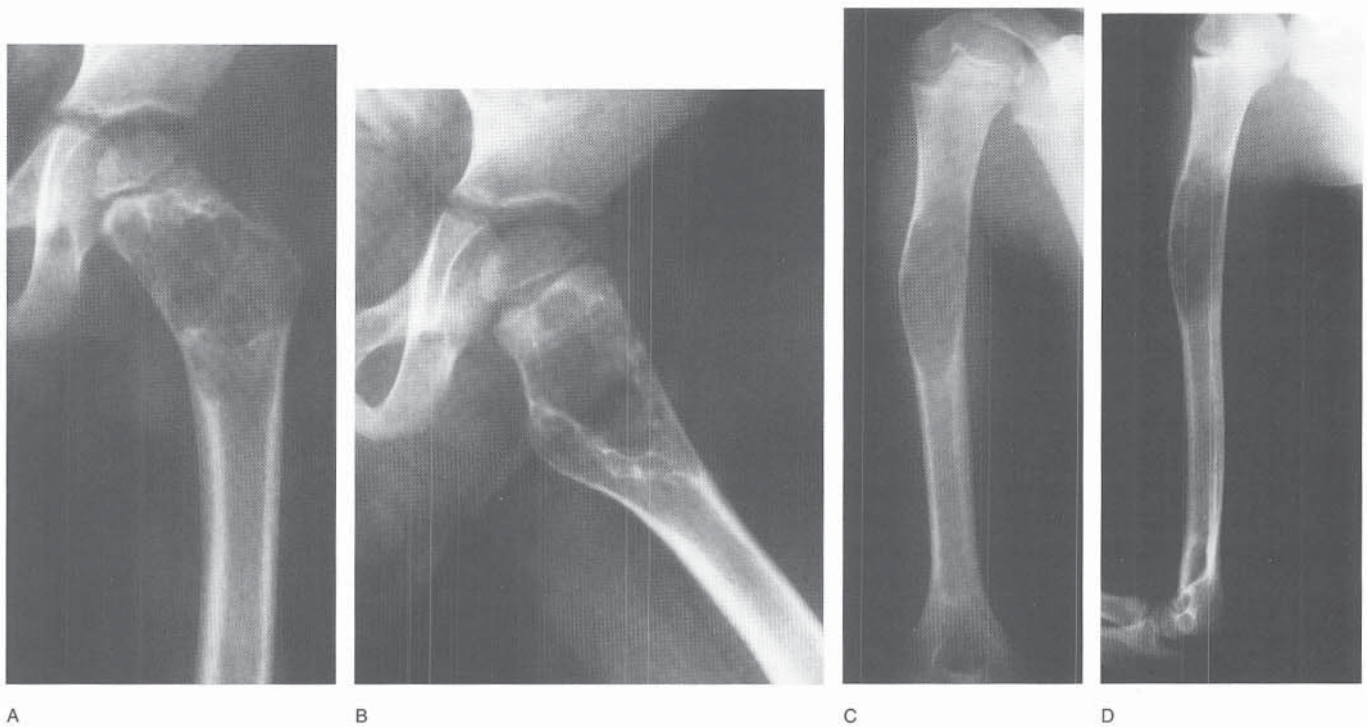


FIGURE 37-2 **A** and **B**, Active solitary bone cyst in the proximal left femur of a 4-year-old boy (D.J.). The cyst is juxtaphyseal. **C** and **D**, A latent solitary bone cyst has grown away from the proximal physis in the right humerus of an 8-year-old boy (D.T.). See Figure 37-4 for posttreatment results.

to open vascular channels between cysts and the intramedullary venous system have all been found effective in healing unicameral cysts. The cyst fluid itself may be both a causative factor and an obstacle to healing. Bone-resorptive factors, such as prostaglandins, interleukin-1, and lysosomal enzymes, are found in cyst fluid.^{104,148,255} Oxygen free radicals, which are cytotoxic and are known to be generated under ischemic conditions, have also been found in cysts.¹⁴⁹

PATHOLOGY

Simple bone cysts tend to expand by eroding the cortex, resulting in a localized bulge of the bone. Despite this fact, reactive or periosteal bone formation is not present unless a pathologic fracture occurs. Where the cortical tissue is thinnest, the wall can actually be fluctuant and a bluish tinge from the underlying fluid can be seen. Once the affected bone has fractured, the cortical wall is thicker and multiple bony septa may occur throughout the cyst.

The fluid found within simple bone cysts is straw-colored or serosanguineous, a feature distinguishing simple bone cysts from aneurysmal bone cysts. Often, significant pressure within the cyst (which can be greater than 30 cm H₂O) is evident when a needle is introduced. After a fracture, though, the cyst may become filled with blood clot, granulation, or fibro-osseous tissues. The most characteristic histopathologic finding is the thin membranous lining of the cyst (Fig. 37-3). Composed primarily of flattened to plump epithelial-like cells, the lining may also possess osteoclast-type giant cells, cholesterol cells, and fat cells. Hemosiderin, fibrin, calcification, and reactive bone may be seen in focal areas of the cyst.

CLINICAL FEATURES

Clinically, cysts can be asymptomatic and may be discovered incidentally when radiographs, such as a chest film, are obtained for other reasons. More often, though, the cysts are diagnosed because of pain. The pain may be mild and reflective of a microscopic pathologic fracture. More abrupt discomfort occurs when a pathologic fracture occurs following relatively minor trauma, such as a fall.⁵ The fractures heal readily, but the cysts do not. Following these pathologic

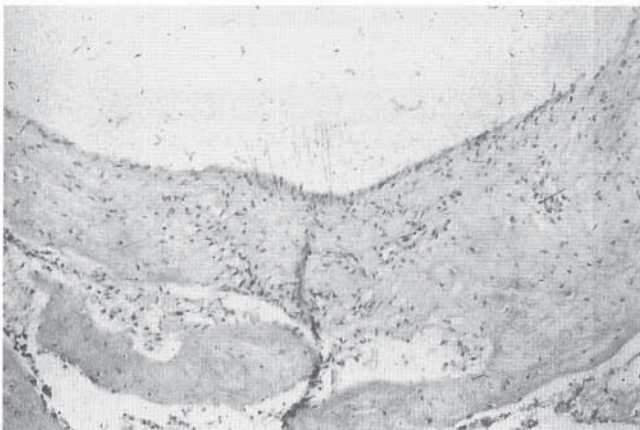


FIGURE 37-3 Histologic appearance of a simple bone cyst ($\times 10$). The thin membranous lining is composed primarily of epithelial-like cells.

fractures, premature physal closure has been reported in nearly 10 percent of patients.^{169,266}

RADIOGRAPHIC FINDINGS

There are several characteristic radiographic features of simple bone cysts.⁵⁰ Approximately 50 percent occur in the proximal humerus and 18 to 27 percent in the proximal femur. The cyst is metaphyseal and usually extends to, but not across, the physis. On rare occasions, it crosses the physis into the epiphysis.^{110,112} Typically the cyst is symmetrically expansile and radiolucent, with a thin cortical rim surrounding it. Over time, the physis grows away from the cyst, changing from the active to the latent phase. In many newly diagnosed cases there is a pathologic fracture with or without displacement. The one pathognomonic manifestation of a simple bone cyst is the “fallen fragment” sign.²⁶⁹ This represents a portion of fractured cortex that settles to the most dependent part of the fluid-filled cyst. However, it is seen in less than 10 percent of cases, and it should not be expected if the cyst has become multiloculated following a previous pathologic fracture.

DIFFERENTIAL DIAGNOSIS

The diagnosis can usually be established based on the presence of typical radiographic findings. Other lesions to be considered in the differential diagnosis include aneurysmal bone cyst, monostotic fibrous dysplasia, and atypical eosinophilic granuloma. All of these lesions may be radiolucent. Aneurysmal bone cysts and fibrous dysplasia may be expansile and metaphyseal. However, features typically associated with these lesions usually help differentiate them from simple bone cysts.

TREATMENT

A common misconception in the treatment of simple bone cysts in children is that once the pathologic fracture heals, the cyst also has an excellent chance of spontaneously healing. However, most investigators examining this phenomenon have found that the likelihood of spontaneous healing of the cyst following pathologic fracture is very low, probably less than 5 percent.^{5,100,195} Thus, if treatment of the cyst is deemed necessary, it should be undertaken as soon as the fracture has healed. However, overtreatment in mature persons should be avoided. In these individuals, if the cyst has a sufficiently thick cortex and is located in the upper extremity, periodic observation may be all that is needed. If the patient is asymptomatic, it may not be necessary to restrict activities.

The treatment approach is more aggressive for all simple bone cysts in younger children and in mature individuals when the cyst is located in weightbearing bones of the lower extremities. In these cases, plans should be made for definitive treatment of the cyst in order to prevent future fractures and possible associated complications (e.g., shortening due to growth arrest and deformity).¹⁶⁹

The preoperative evaluation of patients with simple bone cysts rarely requires more than good-quality radiographs of the lesion. If the diagnosis is equivocal, a bone scan will verify the presence or absence of other abnormal areas.

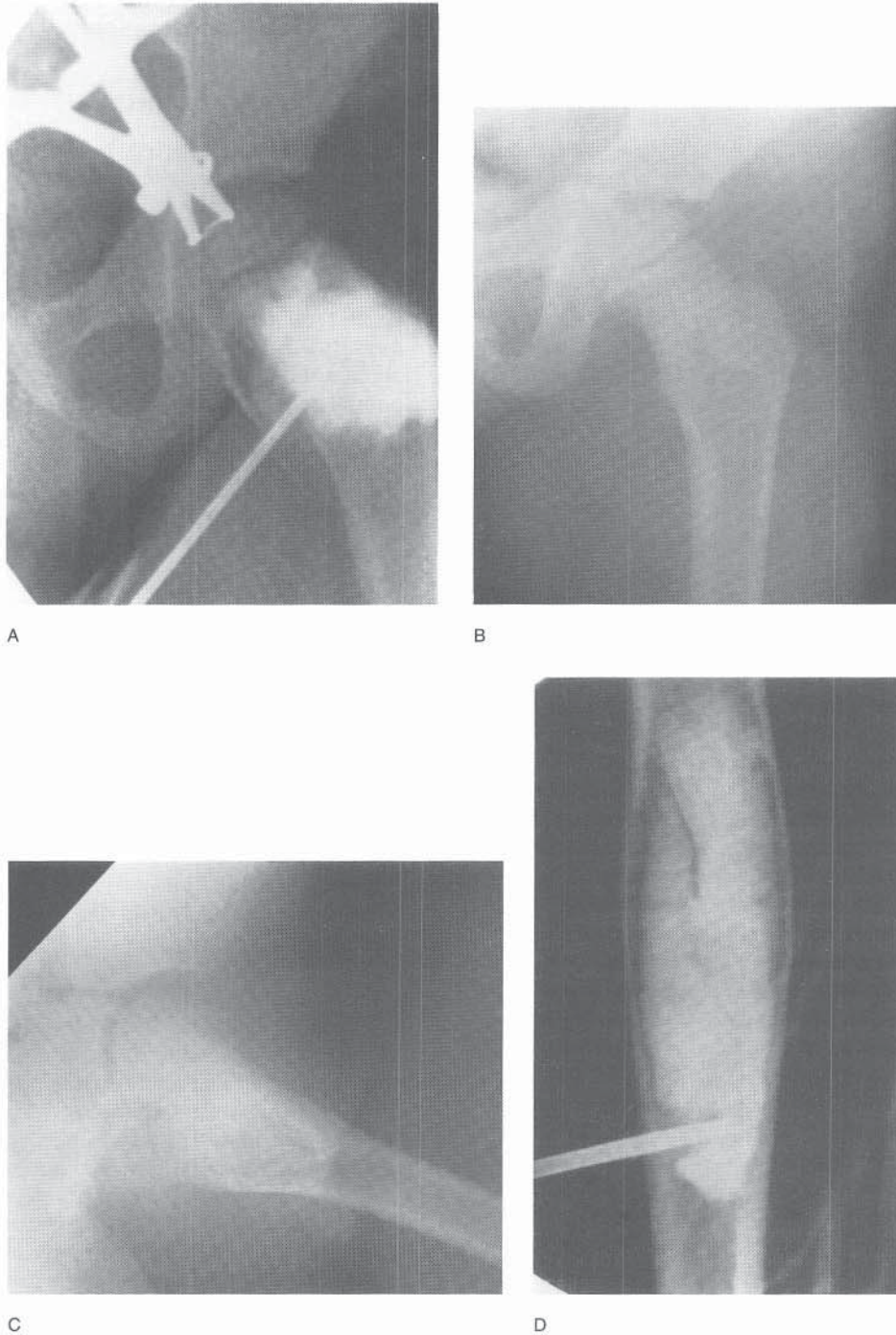


FIGURE 37-4 The patients whose pathologic findings are shown in Figure 37-2 underwent corticosteroid injections into the cysts. In patient D.J., Renografin injected during the first steroid treatment demonstrated filling of the cyst (A). Twenty months later, after a total of four injections, the cyst was healed (B, C). In patient D.T., the entire cyst filled during the first injection (D).

Computed tomography (CT) may be helpful in differentiating simple bone cysts from other lesions, such as aneurysmal bone cysts or fibrous dysplasia. The diagnosis is usually confirmed at surgery, when straw-colored fluid is aspirated through a large-bore needle introduced into the cystic cavity.

Treatment modalities include injection of corticosteroids into the cyst, injection of autologous bone marrow, multiple drilling and drainage of the cavity, and curettage of the membranous wall followed by bone grafting. Older forms

of treatment, such as subtotal resection with or without bone grafting and total resection, are rarely, if ever, used today.

Corticosteroid Injections. The successful healing of cysts following injections of methylprednisolone acetate was reported by Scaglietti and colleagues in 1979.²³⁸ They noted favorable results in 90 percent of lesions, and consequently concluded that treatment by curettage was seldom necessary. Healing was believed to have occurred if the cortex thickened and the cystic cavity became radiographically opaque. Filling

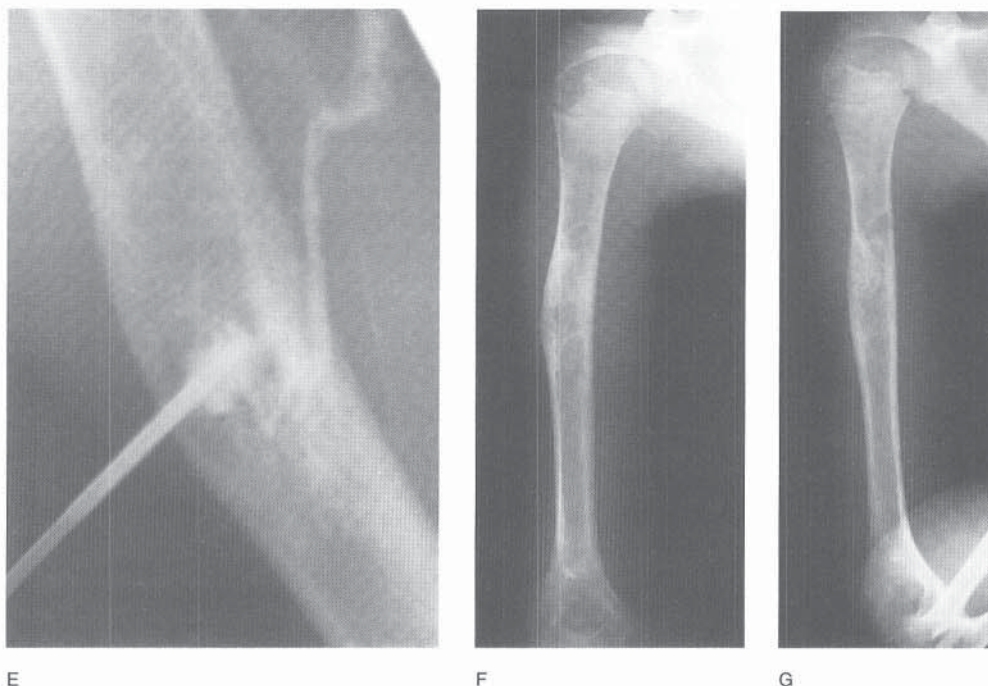


FIGURE 37-4 *Continued.* At the time of the fourth injection 6 months later, minimal cyst cavity was seen (E). A venogram was obtained at the time of contrast injection. Eight months after the initial steroid treatment, the cyst had healed (F, G).

of the cyst with “bone scar” was considered evidence of healing (Fig. 37-4). Actual remodeling, with complete disappearance of the cystic cavity, often took several years. Subsequent reports have continued to substantiate the effectiveness of injecting steroids into cysts, although the success rates have been lower, ranging from 40 to 80 percent.* This method continues to be the treatment of choice for the initial management of simple bone cysts. The antiprostaglandin action of steroids constitutes the rationale for their use in the treatment of cysts.²⁵⁵

Operative Technique of Corticosteroid Injections.¹⁰⁷ The patient is given a general anesthetic in the operating room and the procedure is performed using strict aseptic techniques. Fluoroscopy with image intensification is used to locate the margins of the cyst. Two large needles with stylets (≥ 14 -gauge or Craig biopsy needles) are utilized. The first needle is introduced percutaneously, the stylet is withdrawn, and fluid is allowed to drip out. The presence of straw-colored (serosanguineous) fluid confirms the diagnosis of simple bone cyst. Vigorous aspiration must be avoided since blood may be returned, making it difficult to distinguish a simple bone cyst from an aneurysmal bone cyst. If straw-colored fluid is returned, contrast material (usually Renografin diluted 1:1 with normal saline) is injected to confirm the presence or absence of intracystic fibrous or osseous septa and loculation. If the cyst is not filled completely, the incidence of failure of healing increases.⁴⁸ Needles must be introduced into each separate cystic cavity to ensure delivery of the steroid.

After the contrast material clarifies the structure of the cystic cavity, the second needle is introduced. The cavity is thoroughly flushed with normal saline solution. The opera-

tor should not aspirate when a second needle is in the cyst, as air can be aspirated *into* the cyst from the second needle, leading to an air embolus. When lavage with normal saline is completed, the second needle is withdrawn. Through the remaining needle, 40 to 120 mg (1 to 3 mL) of methylprednisolone acetate is introduced into the cyst and a simple compression dressing is applied.

This procedure is usually repeated every 2 months, requiring between two and five injections, with three being the usual minimal number to obtain healing. Radiographic changes usually are not noted in the first 2 to 3 months; thus radiographs are not needed before then. Subsequently, radiographs are obtained every 2 to 3 months to assess healing. Evidence of healing includes diminution in the size of the cyst, cortical thickening, remodeling of the surrounding bone, and increased internal density (such as “ground-glass” ossification).

Serial steroid injections is the most popular treatment mode because the procedure is simple, injury to the adjacent physis is avoided, the procedure causes a minimal operative scar, there is little morbidity, the patient is able to return promptly to a previous activity level, and the reported results are excellent. A potential disadvantage is a temporary systemic response to the steroid (Cushing’s syndrome). It is best not to exceed a total of 120 mg of methylprednisolone during any one injection.

Autologous Bone Marrow Injections. Recent interest in the injection of other materials to stimulate healing has led to the successful use of autologous bone marrow.¹⁶⁷ Collagen and demineralized bone matrix are other injectable materials that are under investigation.

Decompression of Cysts by Multiple Drilling. Multiple percutaneous drilling has been shown to be effective in the

*See references 36, 44, 50, 51, 89, 114, 193, 234, 239.

treatment of simple bone cysts.^{148,256} Following trepanation, the cyst is thoroughly lavaged with saline. Multiple holes are then created in the cyst wall. Fluid escapes through the drill holes, decreasing the internal pressure in the cyst. When the cysts are drilled with Kirschner wires, the wires are either left in place or removed. Leaving them in place theoretically keeps the holes open and allows for continuous drainage through the cyst wall. However, we have no personal experience with this technique.

Curettage of Cysts Followed by Bone Grafting. Once the common form of treatment for simple bone cysts, bone grafting was replaced in the late 1970s and early 1980s by steroid injections because of reports of better healing of cysts using methylprednisolone acetate (Fig. 37-5). Nearly 50 percent of cysts recur following curettage and bone grafting.⁸⁹ However, there are some cysts for which curettage followed by bone grafting remains necessary. Patients with displaced pathologic fractures of the hip may need open reduction and internal fixation. At the time of internal fixation, curettage of the cyst and bone grafting are also performed. Materials other than autogenous bone have recently been used with success, including cubes of high-porosity hydroxyapatite and tricalcium phosphate ceramic.^{12,123}

Aneurysmal Bone Cyst

An aneurysmal bone cyst is a solitary, expansile, radiolucent lesion of uncertain etiology. It is generally located in the metaphyseal region of the long bones. Seen much less often than simple bone cysts, aneurysmal cysts represent approximately 1 percent of all biopsied primary bone tumors.¹⁸⁵ Nearly 70 percent of affected patients are between 5 and 20 years of age, but the lesion has been reported in infants.^{22,96,185,205} There is no sex predilection.

Aneurysmal bone cysts can be found throughout the skeleton. Nearly 50 percent of reported cases occur somewhere within the long bones of the extremities. The most common sites are the femur and tibia. Although they usually involve the metaphyseal region, aneurysmal cysts may on occasion cross the physis into the epiphysis or may extend into the diaphysis.

Approximately 20 percent of aneurysmal bone cysts involve the spine,²⁷⁶ and they can occur anywhere between the axis^{34,279} and the sacrum.⁵³ Within the vertebra itself, the cyst may be found in the body, pedicles, lamina, and spinous process (Fig. 37-6). Involvement of two or more adjacent vertebrae is not uncommon. Aneurysmal bone cysts may also occur in the pelvis, maxilla, clavicle, hands, and feet.²⁸⁶

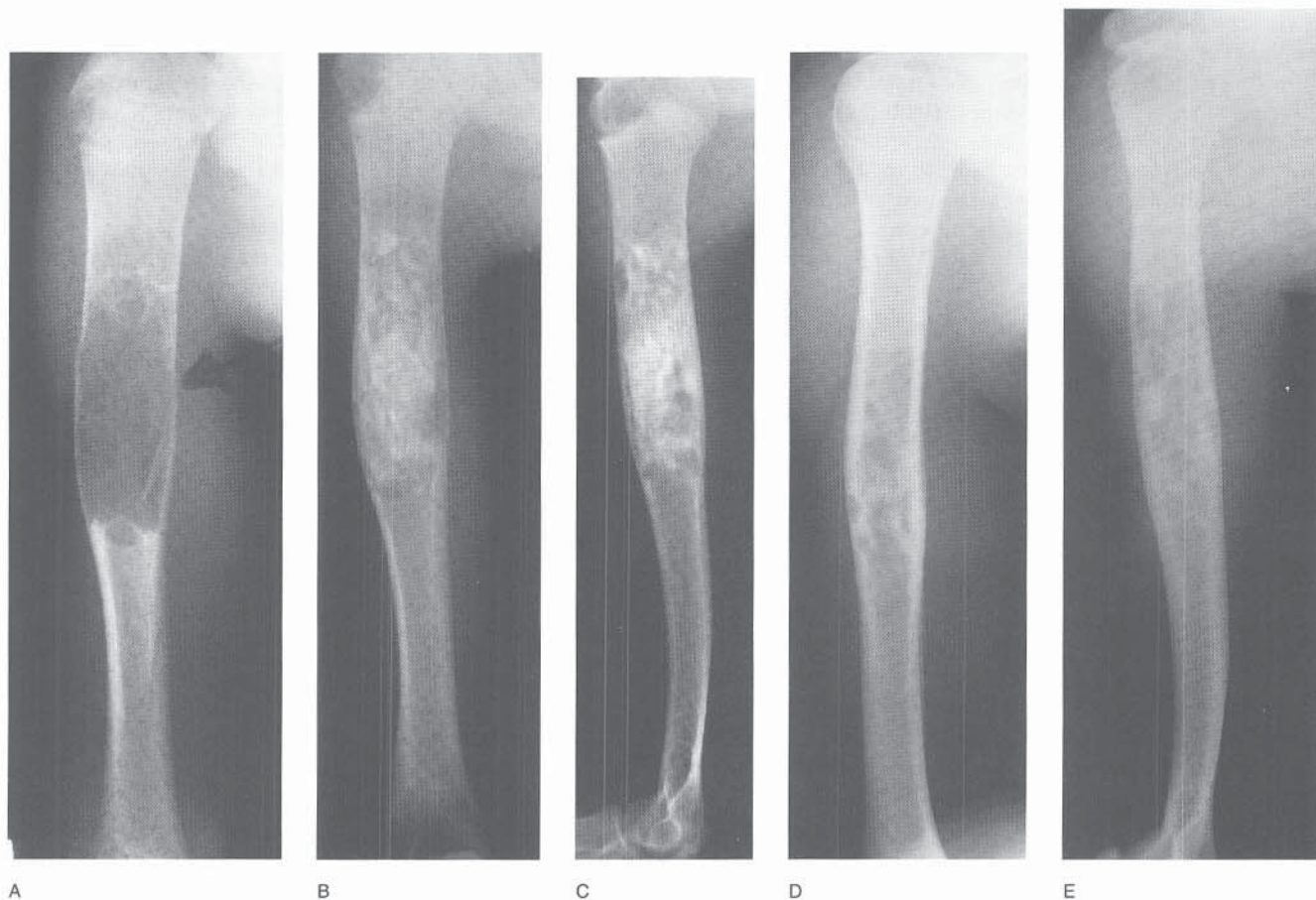
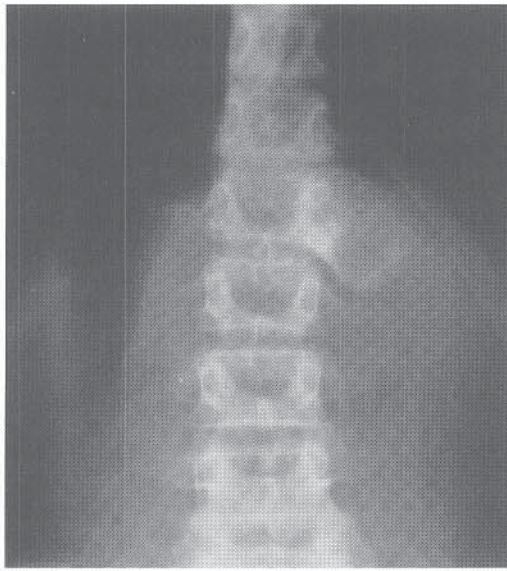
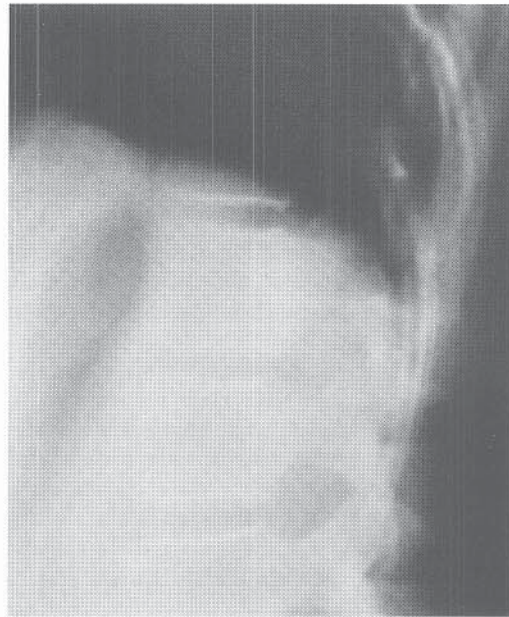
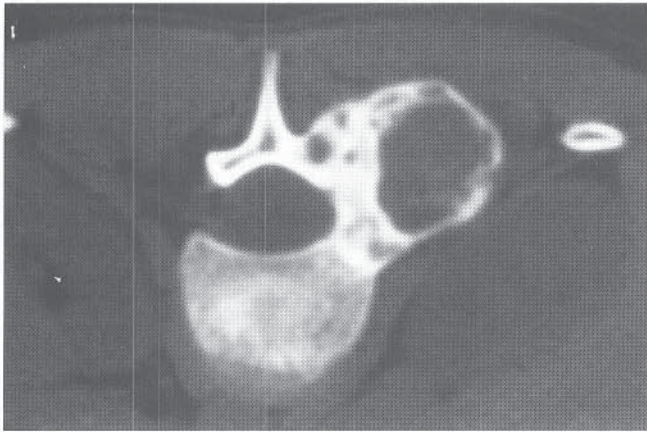
FIGURE 37-5 A 10-year-old boy with a latent solitary bone cyst in the humerus sustained a nondisplaced fracture two separate times (A). Once the fracture had healed for the second time, curettage and bone grafting was performed. Three months postoperatively the cyst was healing (B, C). Five years postoperatively the cyst had healed (D, E).



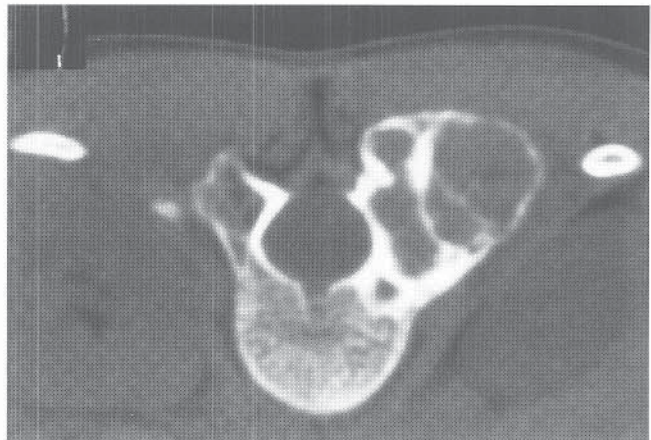A



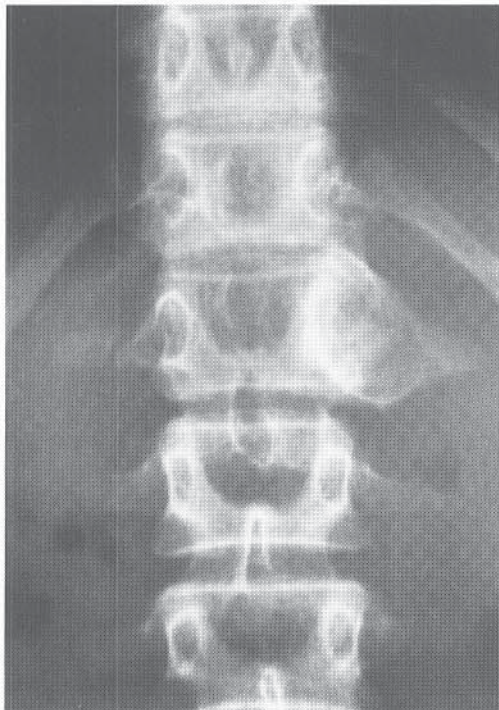
B



C



D



E

FIGURE 37-6 Imaging findings in an 11-year-old girl with moderate back pain in the thoracolumbar spine for 6 months. A and B, AP and lateral spine radiographs demonstrated an aneurysmal bone cyst of L1. C and D, CT showed that the cyst extensively involved the posterior elements on one side. E, Two years after resection and bone grafting, the radiograph still was not normal.

ETIOLOGY

Aneurysmal bone cysts represent either a primary neoplastic condition or a secondary response (arteriovenous malformation) to the destructive effects of an underlying primary tumor. Development of an aneurysmal cyst as a secondary response is supported by the association of aneurysmal cysts with other primary lesions, such as nonossifying fibromas, fibromyxomas, fibrous dysplasia, chondroblastomas, giant cell tumors, simple bone cysts, telangiectatic osteosarcomas, chondrosarcomas, and metastatic disease.^{150,173} Sixty-five percent of aneurysmal bone cysts have been reported to be primary, with 35 percent believed to be secondary to other lesions.^{33,159} Thus, once the diagnosis of aneurysmal bone cyst is considered, a thorough preoperative evaluation is necessary, adequate tissue must be obtained at the time of surgery, and careful pathologic studies are needed to ensure that the aneurysmal cyst is not secondary to a more serious primary neoplasm.

PATHOLOGY

Aneurysmal bone cysts vary considerably in size, with the potential of becoming quite large during the rapid destructive growth phase. On gross inspection, the cyst consists of an encapsulated mass of soft, friable, reddish brown tissue, usually contained within a thin subperiosteal shell of new bone. At the time of surgery, a large amount of blood may exude from a mesh of honeycomb spaces. In most cases the blood is dark red owing to a slow but continuous circulation. If the circulation to a portion of the aneurysmal cyst has been blocked, the cyst may be filled with serous or serosanguineous fluid or with focal organized blood clots.

Microscopy discloses a variable number of vascular spaces whose walls are lined with tissue composed of fibroblastic cells with collagen, giant cells, hemosiderin, and osteoid (secondary to microfractures) (Fig. 37-7). Extensive sampling should be performed to identify possible benign or malignant precursor lesions. The histologic diagnosis of primary aneurysmal bone cyst should be made only after other possible lesions have been excluded. Fibrous tissue, bone, and giant cells are the usual elements seen in most other

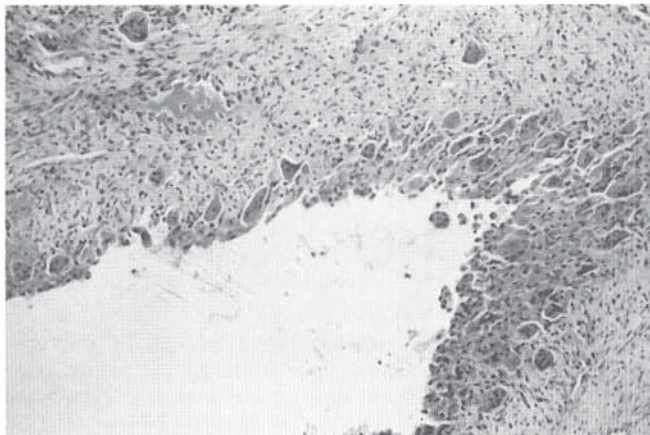


FIGURE 37-7 Aneurysmal bone cyst ($\times 10$). The wall of the vascular space is lined with giant cells, collagen, and osteoid.

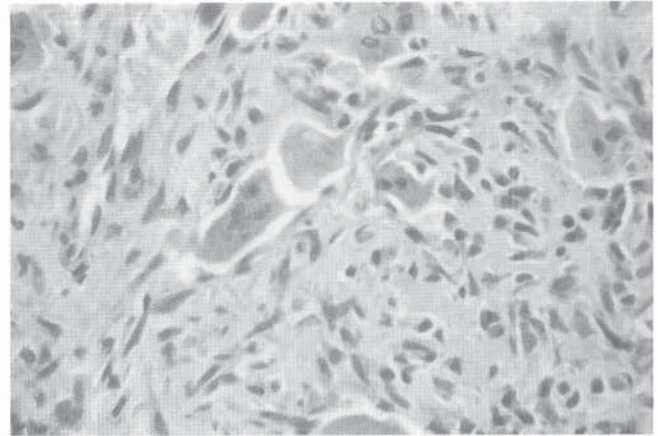


FIGURE 37-8 Solid aneurysmal bone cyst ($\times 40$). Clusters of giant cells are found throughout the lesion.

benign precursor lesions associated with an aneurysmal bone cyst. Any solid area that is 1 cm or greater should raise the suspicion that it may represent another lesion.

There is another entity known as a solid aneurysmal bone cyst or giant-cell reparative granuloma.^{27,40} This is a solid yet radiolucent lesion that appears grayish brown and often is friable. Histologic features include fibrous proliferation with giant cells, fibromyxoid areas, and bone production. Characteristically, the giant cells, which are clustered in areas of recent and old hemorrhage, are found throughout the lesion. The solid aneurysmal bone cyst lacks the normally large blood-filled channels (Fig. 37-8). In a recent review of a large series of aneurysmal bone cysts, the incidence of the solid entity was 7.5 percent.²⁷

CLINICAL FEATURES

The clinical presentation includes localized pain of several weeks' or months' duration, tenderness, and, if the aneurysmal bone cyst occurs in an extremity, swelling. When the cyst involves the spine, progressive enlargement may compress the spinal cord or nerve roots, resulting in neurologic deficits such as motor weakness, sensory disturbance, and loss of bowel or bladder control. Spinal involvement mandates urgent care.

RADIOGRAPHIC FINDINGS

The classic radiographic feature of aneurysmal bone cysts was described by Jaffe as a periosteal "blowout" or ballooned-out lesion that is outlined by a thin shell of subperiosteal new bone formation.¹²⁵ In about 80 percent of cases the cyst involves the metaphyseal region of the long bones and, unlike simple bone cysts, is eccentric in its location. In the spine, it more often involves the posterior elements (spinous process, transverse process, and pedicles) than the vertebral body. In the shorter tubular bones of the feet, the cysts are more central and extend into the diaphysis and subarticular region (this is explained by the smaller size of the bones).

Three phases of aneurysmal cysts have been described.¹⁸⁵ The *incipient* phase is characterized by either a small eccentric lucent lesion or by a pure lifting off of the periosteum

from the host bone without evidence of an intramedullary lesion. Most patients do not present with disease in this phase. Except for focal cortical thinning, the cortex may otherwise be preserved and the periosteum may show no reaction. In this phase, the lesion can be mistaken for a simple bone cyst, nonossifying fibroma, or possibly a lytic osteosarcoma. The *midphase* designates the period of rapid, destructive growth and is characterized by extreme lysis of the bone, focal cortical destruction, and the development of Codman's triangles (periosteal ossification at the corner of the expanded cyst). It is during this phase that the "blowout" appearance is seen on radiographs, and aneurysmal bone cysts can easily be mistaken for an aggressive malignant lesion. In the *late healing* or *stabilization* phase, the lesion grows more slowly and the periosteum has sufficient time to lay down new bone. The cyst will exhibit eccentric (or possibly concentric) smooth-bordered expansion, a trabeculated or "bubbly" intramedullary appearance, and surrounding host bone sclerosis.

Capanna and colleagues proposed a radiographic classification system that is commonly used today.^{49,50,52} *Inactive* denotes a complete periosteal shell, with the intraosseous margin defined by a sclerotic rim of reactive bone. *Active* indicates an incomplete periosteal shell and a sharply defined intraosseous border. *Aggressive* cysts show no evidence of reparative osteogenesis, no periosteal shell, and an ill-defined endosteal margin.

Once these lesions are identified on radiographs, the tumor can be better clarified with CT, particularly if it is located in the spine. The extent of involvement of the vertebra and any encroachment of the spinal canal will be readily evident. CT will also demonstrate the characteristic fluid-fluid levels if the patient is able to lie still long enough for the serosanguineous fluid to separate from the blood within the chambers of the cyst that do not have active circulation. Magnetic resonance imaging (MRI) is indicated if there is evidence of spinal cord compression or if the edges of the rapidly expanding cyst cannot be defined with CT. Fluid-fluid levels are readily evident on MRI (Fig. 37–9).

TREATMENT

Although spontaneous healing of aneurysmal bone cysts has been reported,¹⁷² it is uncommon. Thus, expectant management should be considered only when the diagnosis has been made with confidence and the lesion is in a location and at a stage that do not entail any risk of fracture or further destruction. More often, when the diagnosis of aneurysmal bone cyst is made, active treatment is recommended.

Curettage followed by bone grafting of aneurysmal cysts has been the standard treatment for many years (Fig. 37–10). Unfortunately, this tumor has a high incidence of local recurrence (20 to 59 percent) after curettage.^{173,185,276} Thus, adjunctive therapy, such as cementation, cryotherapy, or embolization, should be considered along with curettage. Cementation of the lesion with polymethylmethacrylate, followed 4 to 6 months later with replacement bone grafting, has been reported to be more effective than curettage and bone grafting alone.^{205,206} Cryotherapy as an adjunct to curettage and bone grafting also increases the likelihood of healing.^{173,242} Embolization has been used as the sole treatment for aneurysmal bone cysts,⁵⁹ but it is much more commonly

used preoperatively to interrupt the vascularity to the lesion. Embolization is useful in treating aneurysmal cysts located in areas of limited access, such as the spine and pelvis.^{78,81,105,146,209} If the cyst is located in an expendable bone, such as a rib or fibula, the surgeon should consider performing a wide or en bloc excision.

Anecdotal reports of techniques useful in the treatment of aneurysmal bone cysts include oral dexamethasone (an angiostatic agent),⁹⁴ and the use of multiple Kirschner pins inserted into the cyst.²¹⁰

Aneurysmal cysts in the spine most commonly involve the elements of the posterior column, but the cysts may extend anteriorly into the body. More than one vertebra may be affected. On occasion, neurologic deficit due to compression of the spinal cord by the lesion requires emergency resection. More often, however, time is available to plan the necessary preoperative embolization, surgical approaches, and reconstruction of a surgically destabilized spine.^{179,209,283}

Radiation therapy has been used for some aneurysmal bone cysts, especially those located in areas that are difficult to gain access to, such as the spine. The dose should be minimized (between 3,000 and 5,000 cGy) to decrease the risk of radiation-induced sarcoma.⁴² Because of this concern, radiation therapy should be limited to cases of cysts that are inoperable or have become inoperable and cases in which embolization has failed.^{173,209}

Fibrous Dysplasia

The term *fibrous dysplasia* was originally proposed by Lichenstein in 1938.¹⁶⁰ He, along with Jaffe, McCune, and Albright, described this disorder of bone, as well as other extraskeletal abnormalities with which it is occasionally associated.^{8,9,163,177} Their descriptions remain among the best for fibrous dysplasia—a benign, nonfamilial disorder characterized by the presence of expanding intramedullary fibroosseous tissue in one or more bones. The incidence of fibrous dysplasia is not known, but it is not an uncommon primary bone tumor. It occurs more frequently in females than in males, particularly the polyostotic form. Although most lesions are probably present in early childhood, they usually do not become evident before late childhood to adolescence.

In general, fibrous dysplasia can be classified into one of three categories. *Monostotic* fibrous dysplasia involves only one bone, and many of these patients remain asymptomatic unless a fracture or swelling occurs. The *polyostotic* form is more severe, involving multiple bones. Nearly any bone in the body may be affected, including the long bones of the extremities, the skull, vertebrae, pelvis, scapula, ribs, hands, and feet. Often one side of the body (in particular, one of the lower extremities) is more severely affected, resulting in deformity and limb length discrepancy.^{185,276} Craniofacial involvement occurs in nearly 50 percent of patients with polyostotic disease. The third category, *polyostotic form with endocrine abnormalities*, is the least common form. Precocious puberty, premature skeletal maturation, hyperthyroidism, hyperparathyroidism, acromegaly, and Cushing's syndrome can occur in these patients.¹ The triad of precocious puberty (endocrinopathy), café-au-lait spots, and polyos-

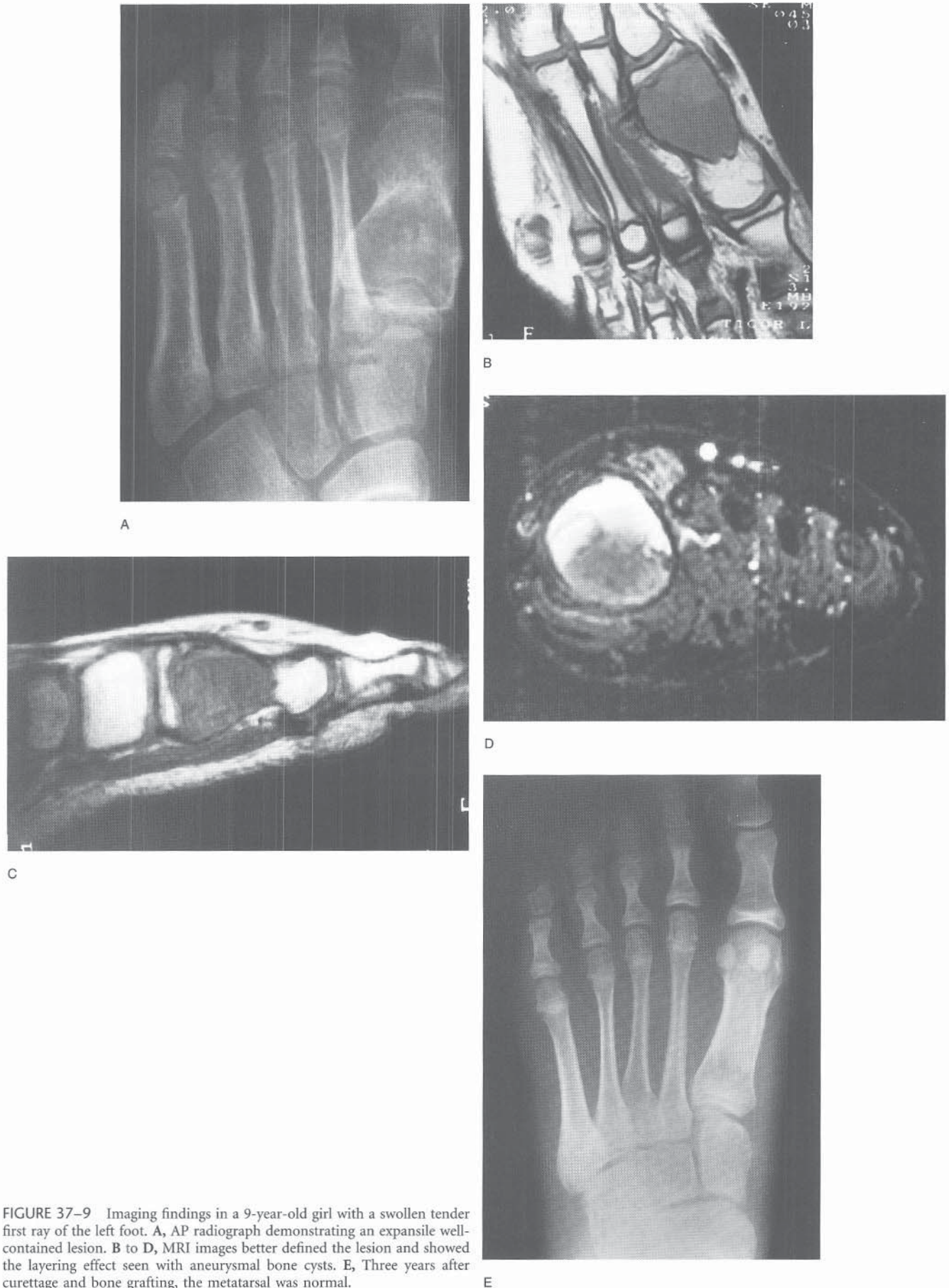


FIGURE 37-9 Imaging findings in a 9-year-old girl with a swollen tender first ray of the left foot. A, AP radiograph demonstrating an expansile well-contained lesion. B to D, MRI images better defined the lesion and showed the layering effect seen with aneurysmal bone cysts. E, Three years after curettage and bone grafting, the metatarsal was normal.

E

otic bone involvement is commonly referred to as McCune-Albright (or Albright's) syndrome.

ETIOLOGY

The exact cause of fibrous dysplasia is not known. The condition is not believed to be hereditary. Fibrous dysplasia probably results from a failure of maturation from woven to lamellar bone.¹⁶⁶ Recent studies have reported an abnormality of a gene encoding a G protein, which is important in the development of bone. Somatic activating mutations of the signal transducer Gs of the alpha chain differentiate fibrous dysplasia (particularly McCune-Albright syndrome) from other lesions, and the mutations may be responsible for the loss of control of local proliferation and growth factor expression.^{11,28,46,252}

PATHOLOGY

The outer surface of expanded bone is usually smooth and covered by reactive periosteal bone. The underlying dysplastic tissue is firm and grayish white, and the proliferative tissue is fibrous. It may feel gritty when palpated, almost like sandpaper. There may be degenerative cystic changes due to cellular necrosis. Islands of hyaline cartilage may be seen.

Histologically, irregular foci of woven (nonlamellar) bone trabeculae are seen in a cellular fibrous stroma (Fig. 37–11).^{40,292} Under the microscope, the bony spicules are often described as looking like the letters C, J, or Y, or resembling Chinese characters. Osteoclastic resorption may be seen, but osteoblastic rimming of the bony spicules is uncommon. In unusual cases, as much as 95 percent of the lesional tissue may be fibrous. Cartilage islands, multinucleated giant cells, foamy histiocytes, and callus may all be seen if a fracture has occurred. The histologic features of polyostotic lesions are identical to those of monostotic lesions.

CLINICAL FEATURES

The clinical manifestations are usually mild in monostotic fibrous dysplasia. Pain and a limp may be evident when the neck of the femur is involved. Local swelling may be seen when the lesion is in a superficial bone, such as the mandible, skull, or tibia. The skeletal changes are usually more severe in the polyostotic form and may result in pain, swelling, deformity, and limb length discrepancies. The classic example of this is found in the proximal femur.¹⁰⁹ Repetitive microfractures can lead to a “shepherd's crook” deformity with pain, significant varus at the femoral neck, shortening of the femur, an obvious Trendelenburg gait, and limited mobility. Deformity can occur in all of the long bones, but usually not to the degree seen in the femur. When the facial bones are affected, progressive deformity may become very evident to the patient and family. Numerous reports of craniofacial abnormalities are found in the dental and maxillofacial literature (Fig. 37–12).^{119,138,259} Spinal involvement is uncommon but can result in vertebral collapse, angular deformity, and possible spinal cord compression.^{199,221}

The most common nonskeletal manifestation associated with fibrous dysplasia is abnormal cutaneous pigmentation,

or café-au-lait spots. These have irregular borders (“coast of Maine”), are not raised from the surrounding skin, and may be extensive, involving large areas of the trunk, face, or limbs. The café-au-lait spots can coexist with polyostotic fibrous dysplasia without endocrine changes or precocious puberty, or they may be absent when endocrinopathies accompany fibrous dysplasia. The pigmentation changes usually are not present in the monostotic fibrous dysplasia.

When sexual precocity occurs, it is most often seen in the female secondary to premature ovarian stimulation and may occur as early as 1 year of age. Most cases of McCune-Albright syndrome occur in females and are accompanied by accelerated maturation and advanced skeletal age. In such children, abnormally rapid growth may result in tall stature at a young age. Ultimately, however, their adult stature will usually be below average because of their early maturation.

RADIOGRAPHIC FINDINGS

Fibrous dysplasia can affect any bone.¹⁸⁵ In the long bones, the lesions start in the metaphysis or diaphysis and rarely involve the epiphysis.¹⁹⁸ The flat bones, ribs, jaw, and skull are commonly involved, but the spine is not.

Some of the smaller lesions of fibrous dysplasia remain confined to the intramedullary region, are often surrounded by sclerosis, and may appear “bubbly” or trabeculated. Normally, though, there is slow replacement of the cortex as expansion takes place. Larger lesions may result in an even or eccentric, smooth-bordered expansion of the bone, but they usually remain confined within a rim of periosteal bone. Angular deformity may occur in the long bones, such as the shepherd's crook deformity in the proximal femur and occasionally in the humerus.⁷⁴ This is usually a result of remodeling of the bone following repetitive microfractures or obvious fractures through the dysplastic bone (Fig. 37–13).

The radiographic density of the lesions depends on the amount of woven bone produced and on the amount of cortex replaced. If the lesion is small, has produced little woven bone, or has not replaced cortex, it will appear radiolucent in comparison to surrounding normal bone. If the cortex is thinned and if the fibrous dysplasia has expanded and replaced most of the normal bone, the characteristic “ground-glass” appearance is seen. When this feature is extensive, it is nearly pathognomonic of fibrous dysplasia. CT will clearly demonstrate this appearance.

A bone scan will demonstrate increased uptake throughout the lesion and is helpful in determining the extent of the disorder if radiographs are unable to do so.²⁶⁰

DIFFERENTIAL DIAGNOSIS

With monostotic fibrous dysplasia, it may be difficult to differentiate small lesions from simple bone cysts on radiographs. Less often, small lesions may be confused with histiocytosis or enchondromas. In these cases a biopsy may be necessary. Larger lesions with cortical thinning and a ground-glass appearance usually do not require a biopsy to confirm the diagnosis. Polyostotic fibrous dysplasia is readily identified on radiographs.

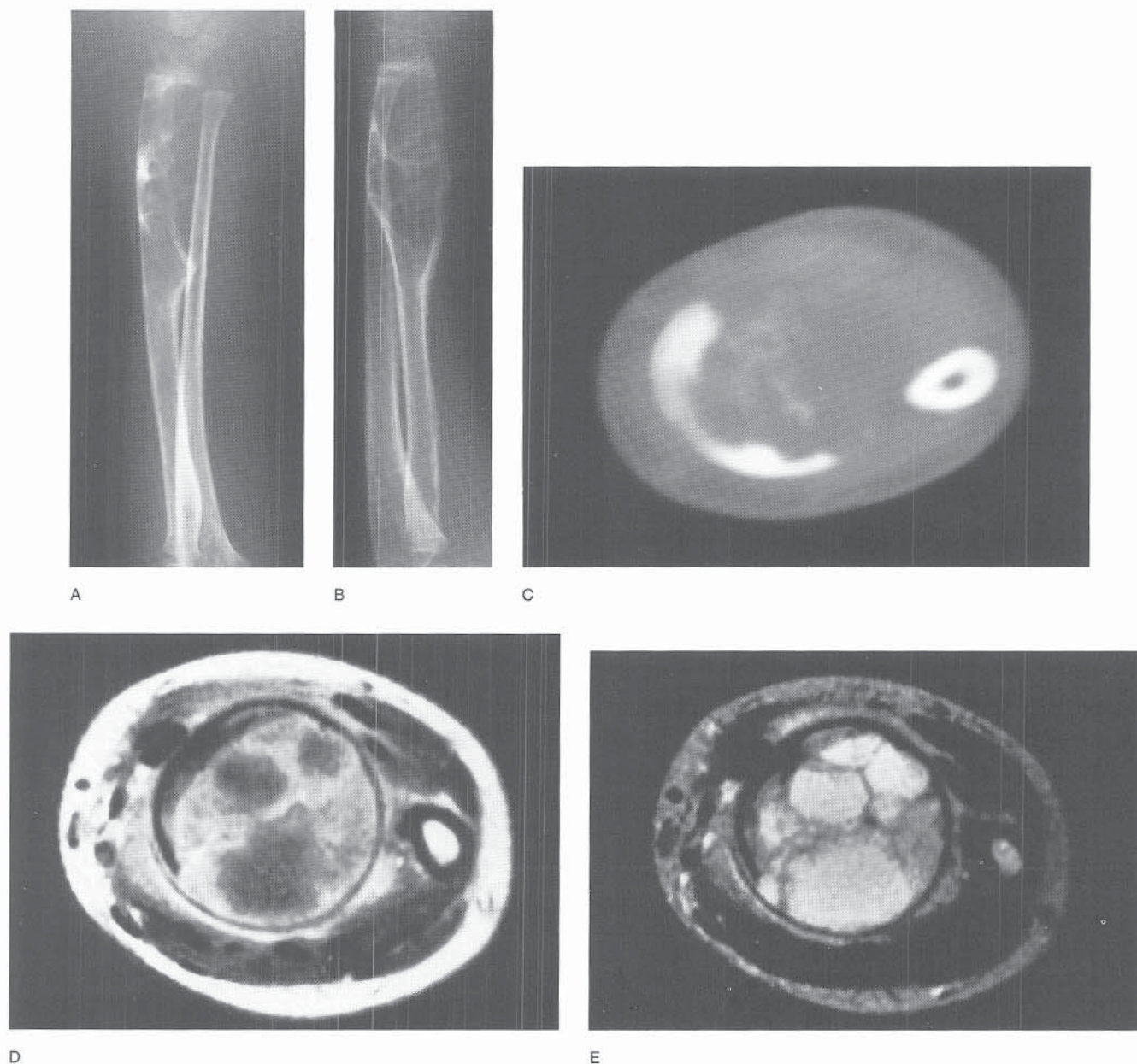


FIGURE 37-10 Aneurysmal bone cyst. Imaging findings in a 3-year-old boy who presented with a painful swollen distal forearm. A and B, AP and lateral radiographs demonstrating the “blown-out” appearance of the distal radius. C, The edges of the lesion could not be seen well on CT. D and E, MRI demonstrated containment of the lesion.

TREATMENT

The mere presence of fibrous dysplasia in bone is *not*, in itself, an indication for surgery, and surgical overtreatment should be avoided. Surgery is indicated when the lesions (1) are complicated by fractures, (2) cause significant or progressive deformity that jeopardizes the integrity of the long bone or that results in unacceptable disfigurement, or (3) are symptomatic and cause the patient pain.

In children, it is nearly impossible to restore dysplastic bone to normal bone following surgery. Thus, if the rare biopsy is needed to confirm the diagnosis of a monostotic lesion, surgical intervention probably should not be undertaken unless there is a fracture or painful deformity. The reason for this conservative approach is that simple curettage

of the lesion inevitably leads to local recurrence. In addition, the risk of pathologic fracture is increased during the months immediately following surgery. Bone graft used to replace part or even all of the tumorous bone is also predictably resorbed and replaced by the dysplastic bone.⁷⁶ A proposed exception to this nonoperative approach in children (in the absence of fracture or deformity) is infantile fibrous dysplasia.¹⁵ In these children with polyostotic disease, early surgical treatment to prevent development of skeletal deformities that are difficult to correct later may provide long-term benefit. Prophylactic intramedullary nailing with nails of appropriate size was found to be most effective. In the adult, bone grafting in fibrous dysplasia has been reported to be more successful in healing the dysplastic bone.¹⁰⁶

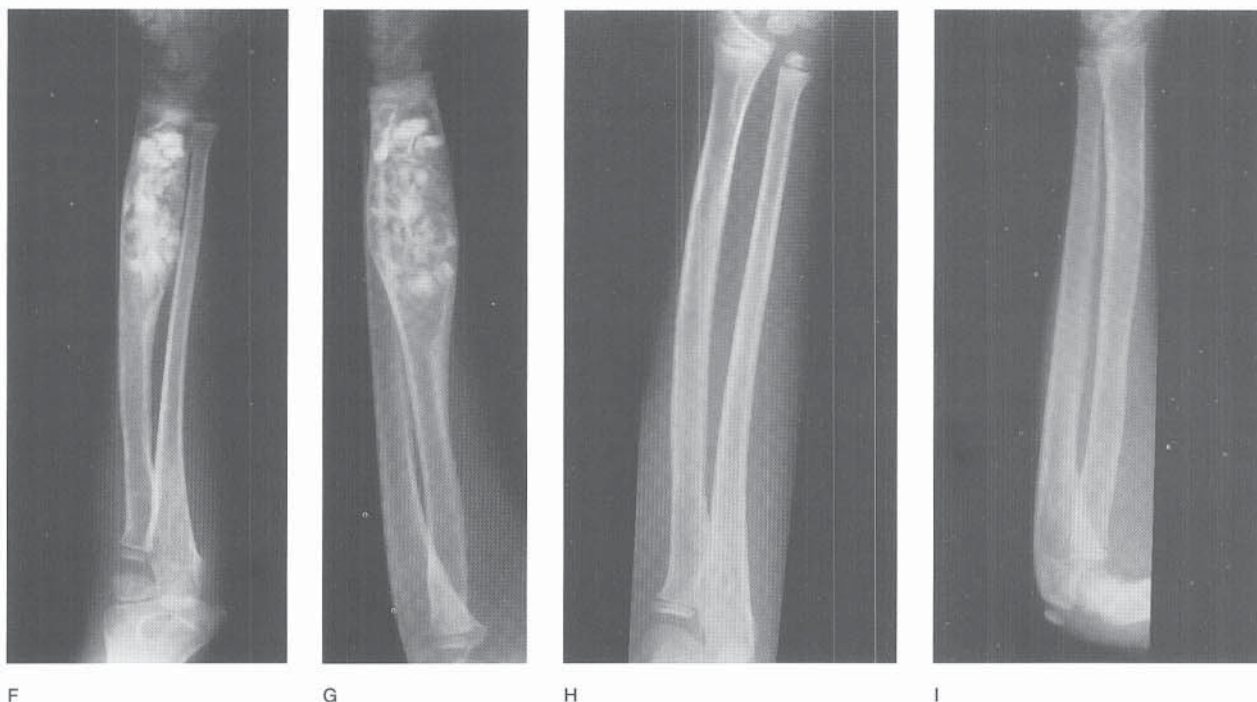

FIGURE 37-10 *Continued.* F and G, After a biopsy confirmed the diagnosis of aneurysmal bone cyst, curettage and bone grafting was performed. H and I, Three years postoperatively the radius had healed and remodeled.

Operative intervention is needed when repeated pathologic fractures have occurred, deformity increases, or associated pain becomes persistent. These pathologic fractures can occur following mild trauma, they are often minimally displaced, and they heal at a normal rate. Delayed union or nonunion is not a problem, but progressive deformity is. The primary goal of treatment is to realign the deformed bone, particularly in the weightbearing lower extremities. This objective, along with ready healing of the fracture, can often be achieved with cast immobilization in the young child. If repeated fractures occur in long bones or if a fracture involves the proximal femur, then surgical intervention is the preferred treatment approach. Internal fixation maintains proper alignment and can be achieved with intramedullary rods in the long bones or with compression screws

with side plates in the proximal femur.^{75,254,263} Prior to the insertion of internal fixation, osteotomies may be required to achieve satisfactory alignment because bowing of the bone (malunions) is common following fractures. This is particularly true in the proximal femur, in which a shepherd's crook deformity may be present.¹⁰⁹ Intraoperative blood loss may be excessive because of increased vascularity in the bone. In addition, the dysplastic bone may not allow good cortical screw purchase, necessitating alternative plans for internal fixation. Despite the successful use of internal fixation and near-anatomic bone realignment, progressive deformity can still occur, leading to the need for additional surgery.

Some authors advocate attempts to augment bone strength in addition to or in place of internal fixation. Enneking and associates reported that cortical strut grafting was effective in strengthening the bone in the proximal femur (Fig. 37-14).⁸⁴ In their opinion, the strength of the bone was greater if cortical rather than cancellous graft was used. Allograft cortical struts avoid the morbidity of harvesting autogenous graft and also appear to slow the resorption process by the dysplastic bone.²⁴⁷ Ultimately, though, the type of graft utilized probably does not affect the rate of recurrence.

Although malignancy in fibrous dysplasia is rare, when it does occur the prognosis is poor. Most cases occur in patients who have undergone radiation therapy.^{13,56,64,235,311,312} Thus, radiation treatments should be avoided because of the association with malignant transformation. In addition, no beneficial effects on the progression of polyostotic fibrous dysplasia have been demonstrated from medications or medical management.⁵⁵ The hormonal abnormalities in McCune-Albright disease should be managed by an endocrinologist.^{101,171,268}

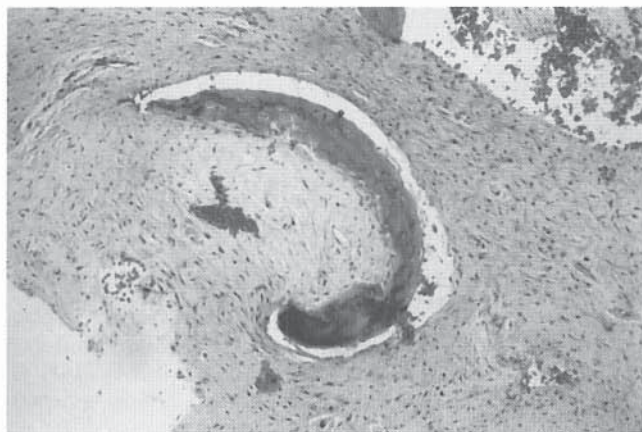
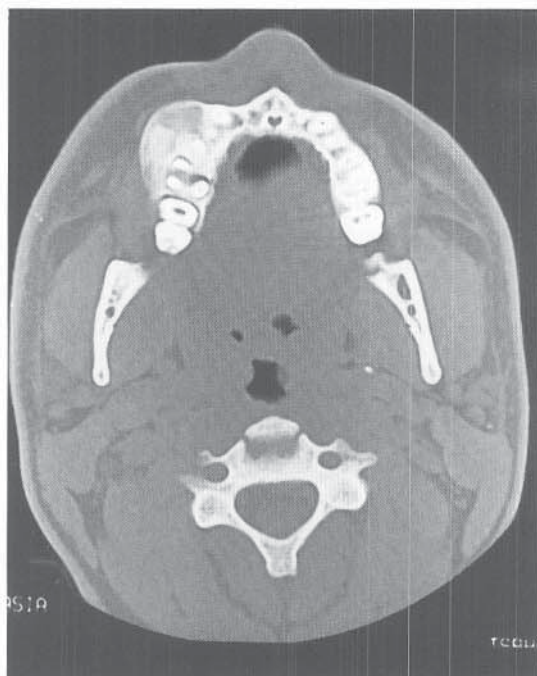
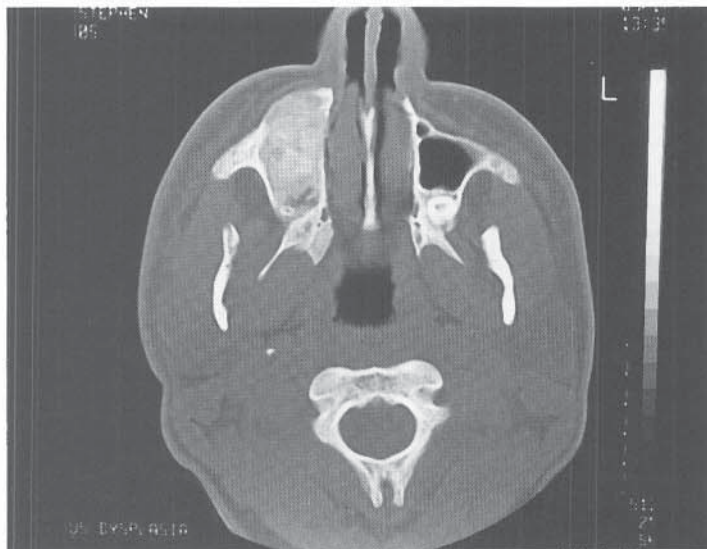
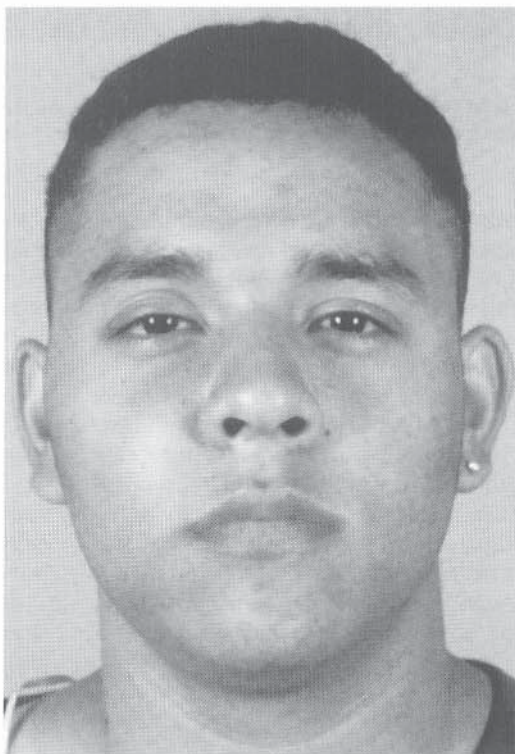
FIGURE 37-11 Histologic appearance of fibrous dysplasia ($\times 10$). Spicules of woven bone arise from the cellular fibrous stroma.



A



B



C

FIGURE 37-12 Fibrous dysplasia. CT scans of the head demonstrate expansion of the maxilla (A) and replacement of a normal sinus with fibrous dysplasia (B). Slight facial asymmetry is noted because of the affected bone on the right side (C).

Osteofibrous Dysplasia of the Tibia and Fibula (Campanacci's Disease)

Osteofibrous dysplasia of the tibia and fibula has been described as a variant of fibrous dysplasia.²¹² It may also have a histogenetic relationship to adamantinoma.* Cytokeratin-

positive cells are found in the stroma of both osteofibrous dysplasia and adamantinomas, but not in fibrous dysplasia.

The disorder was first reported in the literature in 1921 by Frangenheim,⁹³ who used the term *congenital osteitis fibrosa*. Other terms for this disorder include *congenital fibrous dysplasia*, *congenital fibrous defect of the tibia*, and *ossifying fibroma*. *Osteofibrous dysplasia of the tibia and fibula* was proposed by Campanacci in 1976.^{43,45}

Osteofibrous dysplasia differs from the more common fibrous dysplasia with regard to age distribution, site, radio-

*See references 10, 25, 31, 37, 116, 124, 155, 265, 275, 285.

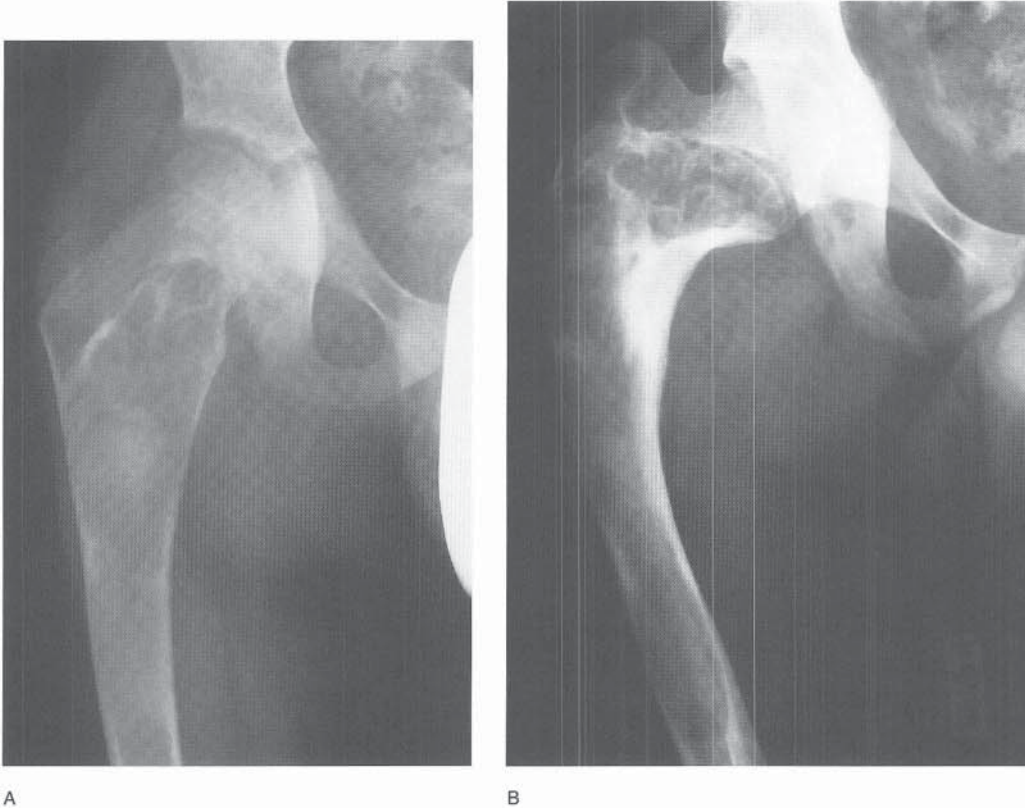


FIGURE 37-13 Imaging findings in a 9-year-old boy with polyostotic disease. **A**, Radiograph obtained at presentation showing fibrous dysplasia of the femur. **B**, Six years later, at age 15 years, a shepherd's crook deformity had developed as a result of repetitive microfractures of the proximal femur.

graphic features, and clinical course. The lesion is slightly more common in males. The symptoms almost always appear in the first decade of life. Nearly two-thirds of the lesions are noted before 5 years of age,⁴⁵ and the disorder has been noted in infants.^{14,147} The tibia is almost always involved and the ipsilateral fibula may be affected. Bilateral involvement has been reported,²⁷¹ as has involvement of the radius and ulna.²⁹³ The diaphysis is mainly affected, with localization to the middle third in the tibia. Extension into the proximal or distal metaphysis is seen sometimes. On rare occasions there is diffuse involvement of the entire shaft of the tibia. When the disorder is limited to the fibula, the distal third of the bone is affected.

ETIOLOGY

The pathogenesis of osteofibrous dysplasia remains unknown³⁷; however, several theories have been proposed: (1) it results from excessive resorption of bone with fibrous repair of the defect; (2) it is a congenital lesion or a variant of fibrous dysplasia²¹²; and (3) it results from abnormal blood circulation in the periosteum.¹⁴⁷ Most recent literature has suggested either that the disorder is a reactive process secondary to adamantinoma or that it is a precursor of adamantinoma.*

PATHOLOGY

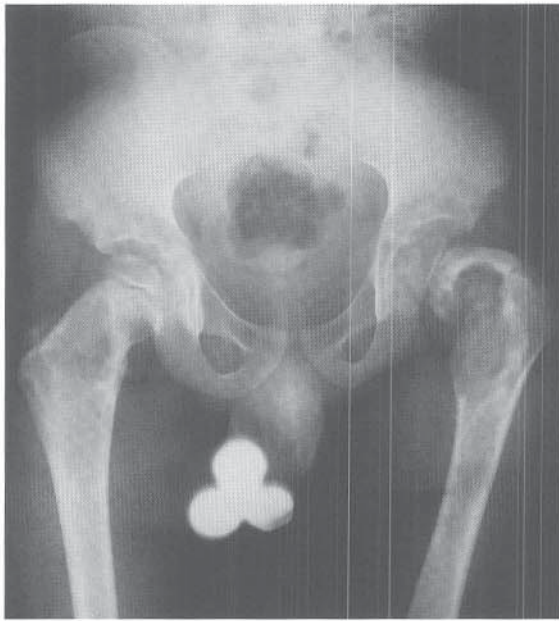
On gross inspection the periosteum is intact. The affected cortex is thinned and may be perforated. The lesion has been described as either whitish yellow or reddish.

Histologically, the tissue is similar to fibrous dysplasia, with irregular spicules of trabecular bone and fibrous or collagenous stroma. In contrast to fibrous dysplasia, the spicules are usually lined with osteoblasts (Fig. 37-15). The finding of woven bone with juxtaposed lamellar bone (from osteoblasts) is thought to be characteristic of osteofibrous dysplasia. Recent immunohistochemical studies have demonstrated isolated cytokeratin-positive cells in the stroma of osteofibrous dysplasia.^{25,37,124,285} These cells are not seen in fibrous dysplasia but are found in adamantinomas. Based on this finding, it is believed that there is a relationship between osteofibrous dysplasia and differentiated adamantinoma; however, it is not known whether osteofibrous dysplasia represents a possible precursor or is a secondary reaction to adamantinoma. Nests of epithelial cells are a consistent histologic finding in adamantinomas, but they are not found in osteofibrous dysplasia.

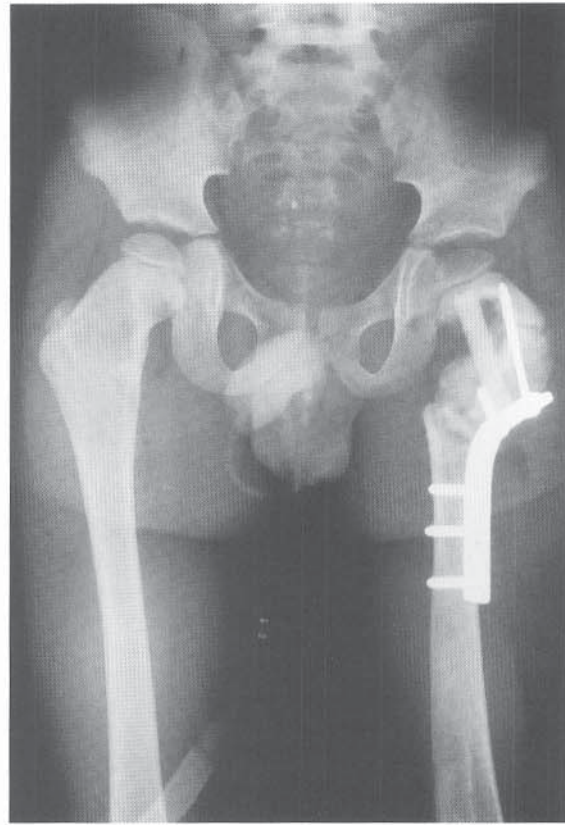CLINICAL FEATURES

The common presenting complaint is firm swelling localized over the tibia with associated mild to moderate anterior tibial bowing. Osteofibrous dysplasia is usually painless unless there is a coexisting pathologic fracture.

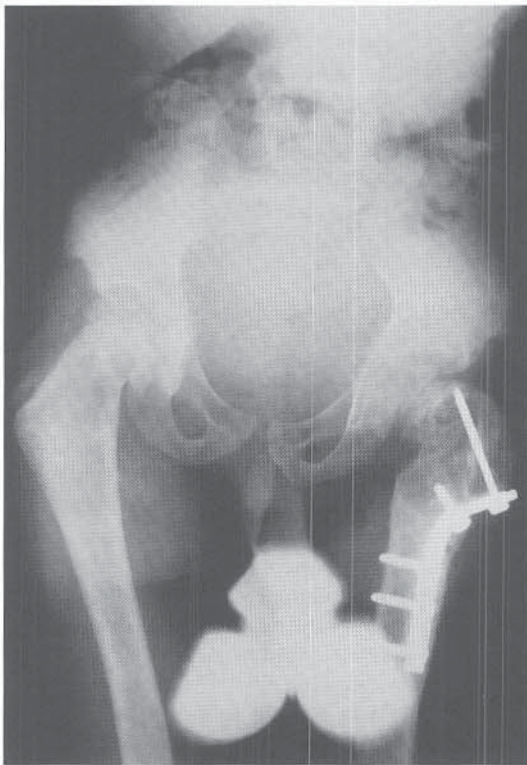
*See references 25, 37, 116, 124, 155, 265, 285.



A



B



C

FIGURE 37-14 Radiographic appearance in a 7-year-old boy with polyostotic fibrous dysplasia and a painful, progressive varus deformity. **A**, Radiographically, the left hip was found to be involved. **B**, A valgus osteotomy with allograft fibula and internal fixation was performed. **C**, Ten months later the allograft fibula had been resorbed by the dysplastic bone and varus of the proximal femur was recurring.

RADIOGRAPHIC FINDINGS

The lesion usually is extensive, involving the anterior cortex of either the diaphysis or the metaphysis of the tibia; the epiphysis usually is not affected.⁴⁰ Characteristic eccentric, intracortical osteolysis is found, with moderate or marked expansion of the cortex (Fig. 37-16). In small areas, the cortex may actually appear absent and a “bubbled” appearance may be evident. In some areas, the osteolytic areas may

have a ground-glass appearance. The tibia may be bowed anteriorly or anterolaterally. If the fibula is involved, it is usually evident in the distal third of the bone, involving nearly the entire circumference of the shaft.

DIFFERENTIAL DIAGNOSIS

The two entities that must be distinguished from osteofibrous dysplasia are monostotic fibrous dysplasia and

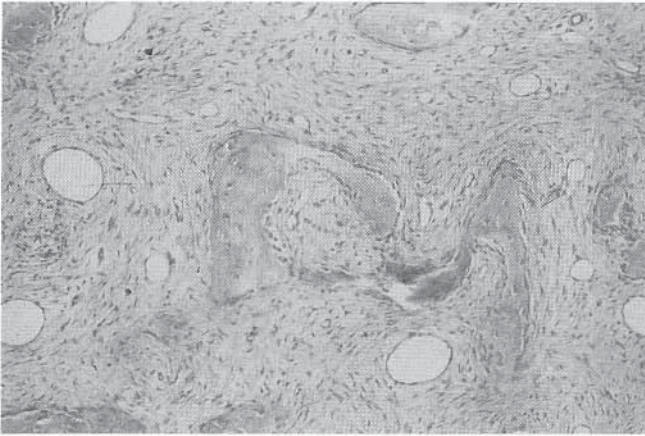


FIGURE 37-15 Histologic appearance of osteofibrous dysplasia ($\times 10$). The tissue is similar to fibrous dysplasia, with irregular spicules of woven bone. In contrast to the histologic appearance of fibrous dysplasia, the spicules are usually lined with osteoblasts.

adamantinoma. In contrast to osteofibrous dysplasia, fibrous dysplasia (1) is usually detected after age 10 years, (2) is not routinely associated with anterior or anterolateral tibial bowing, (3) is noted to be intramedullary on radiographs, with a ground-glass appearance, and (4) histologically, the bony trabeculae in the fibrous stroma are rarely ringed with osteoblasts. Adamantinomas usually occur in patients over 10 years of age and contain the epithelial components histologically. In adolescents an open biopsy is needed to differentiate osteofibrous dysplasia from adamantinoma. This tissue must be carefully evaluated because of the difficulty in distinguishing between the two entities.²⁶⁵

TREATMENT

The natural history of osteofibrous dysplasia varies. The lesion may grow slowly, it may expand rapidly into the entire diaphysis, or it may occasionally regress. The most common clinical course is one of steady growth and expansion during the first 5 to 10 years of life. Growth then slows and, after maturity, the lesion stops expanding. Treatment depends on the course of the specific lesion.

In the young child, marginal subperiosteal resection or curettage is often followed by recurrence of the lesion. A wide extraperiosteal en bloc resection will presumably achieve a cure, but such a radical procedure is rarely, if ever, indicated. Therefore, a conservative approach (observation) is recommended. Bracing, consisting of an ankle-foot orthosis with anterior shell, is indicated if the tibia shows a progressive angular deformity. Cast immobilization of a pathologic fracture is recommended unless angular deformity requires correction; if so, internal fixation may be needed.

Conservative management also is recommended in the treatment of adolescents with osteofibrous dysplasia. If the radiographic appearance is unchanging, the patient should probably be observed indefinitely. If enlargement of the lesion occurs, a marginal excision has been reported to be successful in the skeletally mature patient.

Solitary Osteochondroma

Osteochondroma is the most common benign bone tumor, reportedly accounting for 36 to 41 percent of all such tumors.^{67,240} It is characterized by a cartilage-capped osseous projection protruding from the surface of the affected bone. The exostosis is produced by progressive enchondral ossification of the hyaline cartilaginous cap, which essentially functions as a growth plate. More than 50 percent of solitary osteochondromas occur in the metaphyseal area of the distal femur, proximal tibia, and proximal humerus. Other areas in which solitary osteochondromas may be found include the distal radius, distal tibia, proximal and distal fibula, and occasionally the flat bones such as the scapulae, ilium, or ribs.

ETIOLOGY

A focal herniation of the medial or lateral component of the epiphyseal plate results in the formation of an aberrant cartilage-capped eccentric small bone. Several theories have been proposed to explain this phenomenon. Virchow in 1891 put forth the physéal theory, according to which a portion of the physéal cartilage becomes separated from the parent tissue, rotates 90 degrees, and grows in a direction transverse to the long axis of the bone.²⁹⁰ However, he did not provide an explanation for the separation and rotation of the detached physéal cartilage. In 1920, Keith proposed that the cause was a defect in the perichondral ring surrounding the physis.¹³⁹ Müller in 1913 theorized that the exostoses were produced by small nests of cartilage derived from the cambium layer of the periosteum.¹⁹¹ By producing osteochondroma using physéal cartilage transplantation, D'Ambrosia and Ferguson provided support for the physéal plate defect theory.⁶⁸ Current thought is that the cause is misdirected growth of a portion of the physéal plate, with lateral protrusions causing the development of the eccentric cartilage-capped bony prominence.

Unlike the more extensive hereditary (autosomal dominant) multiple exostoses, solitary osteochondromas do not appear to be genetically transmitted.

PATHOLOGY

Solitary osteochondromas may be sessile (broad-based) or pedunculated (narrow-based). The surface usually is lobular, with multiple bluish gray cartilaginous caps covering the irregular bony mass. The cartilaginous caps are covered by either thin or comparably thick perichondrium, which may be adherent to the underlying irregular surface and is continuous with that of the adjacent bony cortex. When this perichondrium is removed, the shiny cartilaginous cap is exposed. The cartilaginous cap is usually 1 to 3 mm thick, but in the younger patient it may be noticeably thicker. The thickness of the cartilaginous cap may be much greater if the tumor has undergone sarcomatous change. On cut section the cartilaginous cap will vary in thickness and often has an opaque yellow appearance owing to calcification within the cartilaginous matrix.

The tumor often resembles a cauliflower; however, it may also be flat, hemispheric, or tubular with a prominent end. Its base is contiguous with the normal cortical bone, and

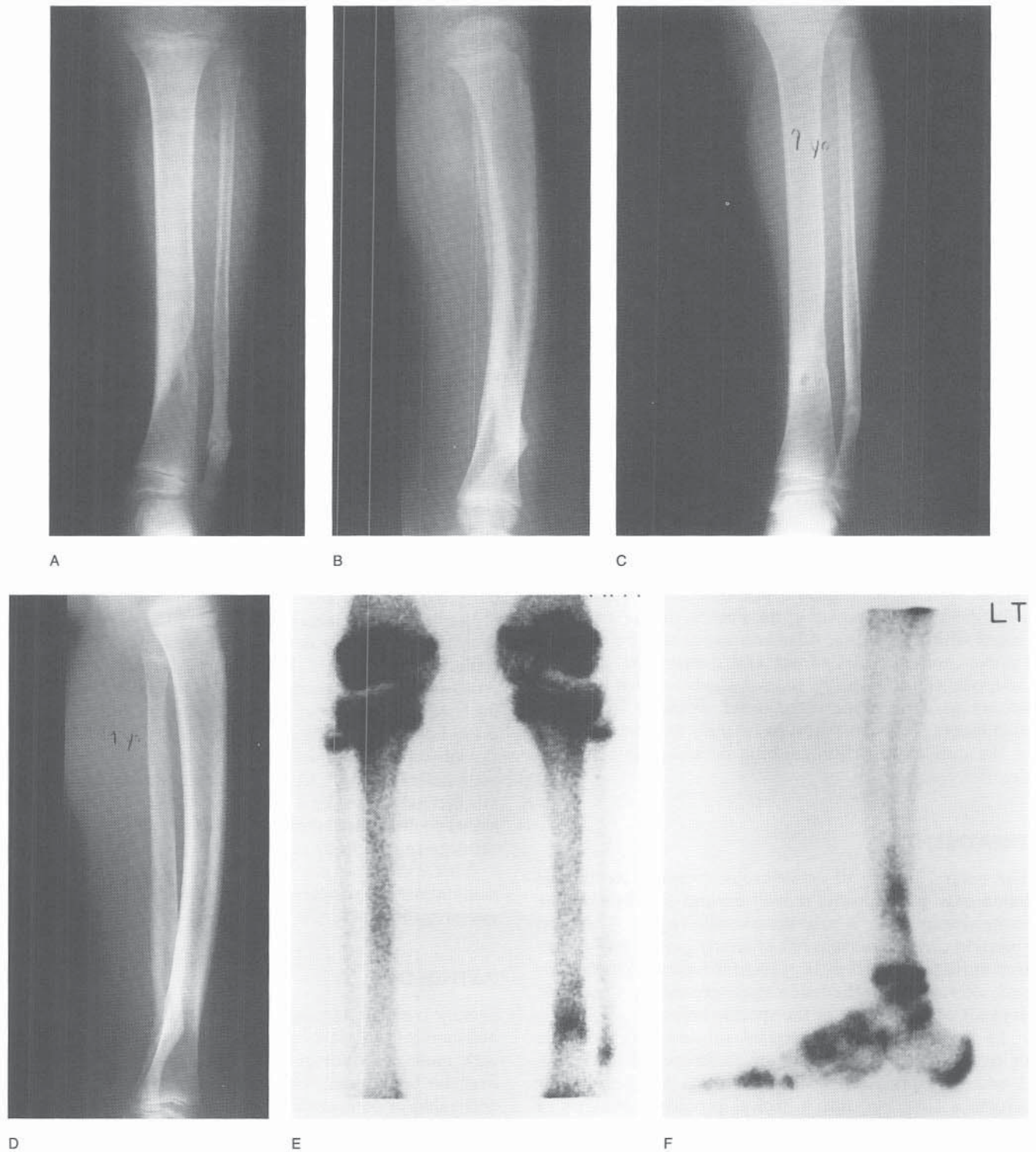


FIGURE 37-16 A and B, Osteofibrous dysplasia of the tibia/fibula in a 5-year-old girl, associated with mild anterior bowing. C and D, Radiographs obtained at age 9 years, when persistent discomfort was present. E and F, Bone scans showed increased uptake in the area of the lesion.

the interior of the lesion (spongiosa bone) blends with that of the host bone.

A bursa may develop over the osteochondroma, particularly in larger lesions, where movement of the adjacent soft tissue leads to irritation. This bursal sac may contain mucinous fluid and fibrinous rice bodies.

Histologically, the cartilaginous cap is composed of bland hyaline cartilage. Variable degrees of cellularity are seen, but anaplastic cells are not characteristically evident. Normal enchondral ossification is seen at the cartilage-bone junction. In younger patients, cartilage cores may be present within the subchondral spongiosa near the physes, and these

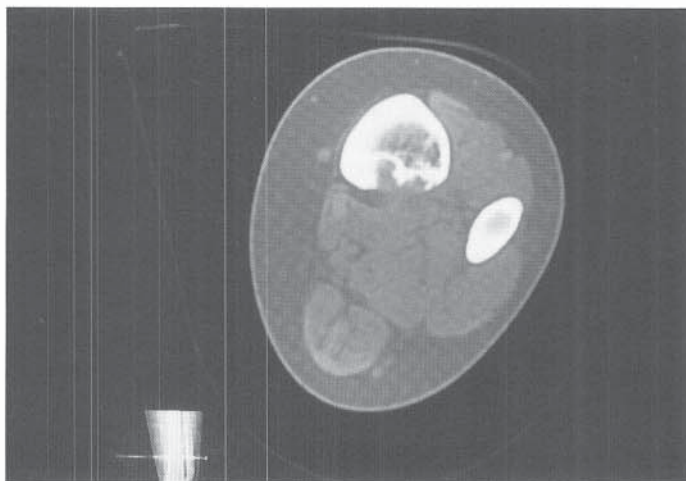


FIGURE 37–16 *Continued.* G, CT showed the intracortical osteolysis. Biopsy confirmed the diagnosis of osteofibrous dysplasia.

G

cores may be responsible for recurrence of the lesion should an incomplete resection be performed. Aside from the cartilage cores, the cancellous bone underlying the cartilaginous cap resembles that of the host, although on occasion the marrow in the interior is predominantly fatty.

The appearance of the cartilaginous cap depends on the stage of growth, becoming thinner over time. Remnants of the quiescent cap may persist well into adult life. Should increased thickness of the cartilage become evident in an adult, malignant degeneration must be considered and the lesion should be carefully examined on histologic sections.

CLINICAL FEATURES

In the majority of affected individuals, the osteochondroma becomes evident between the ages of 10 and 20 years. There is a slight male preponderance. An osteochondroma may be discovered as an incidental radiographic finding or it may be detected on palpation of a protruding bump. Other factors that often draw attention to the osteochondroma include localized pain, growth disturbance of an extremity, compromised joint motion, abnormal cosmetic appearance, or secondary impingement of soft tissues (tendon, nerves, and vessels). On occasion, a fracture may occur through a stalk of a pedunculated (narrow-based) lesion following minor trauma.

RADIOGRAPHIC FINDINGS

There are several pathognomonic radiographic findings associated with an osteochondroma (Fig. 37–17).¹⁸⁶ (1) The lesion protrudes from the host bone on either a sessile (broad-based) or pedunculated bony stalk. (2) It occurs either in the metaphysis or, as the main epiphyseal plate grows away from the lesion, in the diaphysis. It is never found in the epiphysis. (3) The cortex and cancellous bone of the osteochondroma blend with the cortex and cancellous bone of the host. This is the main radiographic finding, and any deviation from this feature should raise suspicion of a more serious lesion. (4) The lesion ranges in size from 2 to 12 cm.

There may be slight metaphyseal widening at the site of the exostosis. Although the cartilaginous cap is not radiographically visible, partial calcification of the cartilage may be seen as small areas of radiopacity.

In the flat bones, such as the ilium or scapulae, exostoses are usually sessile and are located near the cartilaginous ends of the bone. Osteochondromas rarely develop in the carpal and tarsal bones, but they may involve the phalanges. The rare osteochondroma in the spine (occurring primarily in hereditary multiple exostoses) is rarely visualized on plain

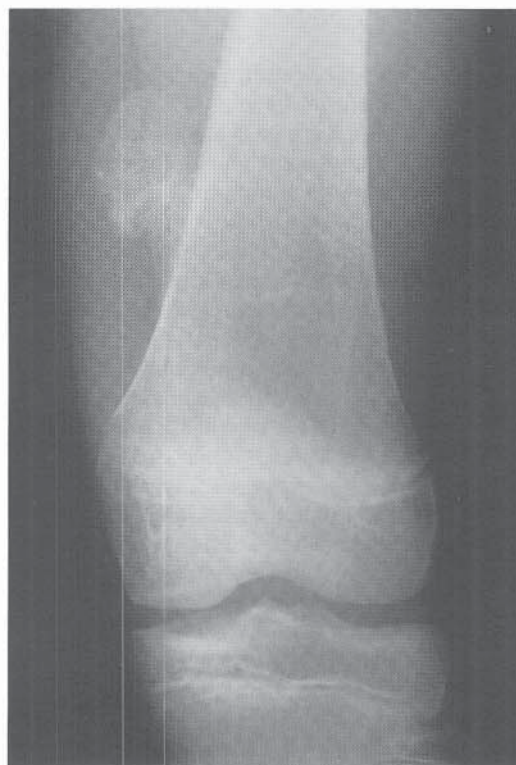

FIGURE 37–17 AP radiograph of the distal left femur in a 12-year-old boy with a solitary osteochondroma. The osteochondroma extends medially and proximally on a pedunculated bony stalk. The boy complained of discomfort when the prominence was inadvertently bumped.

radiographs. If there is evidence of cord compression, CT and MRI will clearly show the impingement.

Bursal osteochondromatosis overlying an osteochondroma of the rib has been described³⁰⁴ and, on occasion, ultrasound may help delineate the extent of the swollen bursa. If there is concern over a progressively enlarging mass, ultrasound may also help determine the thickness of the cartilaginous cap. Steady growth of the cartilaginous cap is acceptable during childhood and early adolescence, but growth should cease when skeletal maturity is reached. If the cartilaginous cap continues to grow after skeletal maturity, malignant transformation should be considered and the appropriate follow-up studies undertaken.

DIFFERENTIAL DIAGNOSIS

Because of their typically distinct radiographic appearance, solitary osteochondromas are usually easily diagnosed. On occasion, they may be confused with a juxtacortical chondroma or, less commonly, with myositis ossificans with a cartilaginous cap. Juxtacortical chondromas usually have a scalloped cortical defect with a sclerotic margin. With myositis ossificans, the apparent tumor does not blend with the cortex and cancellous bone of the host bone, even though it may be attached to the periosteum. This is usually apparent radiographically, thus distinguishing the long-standing lesion of mature myositis ossificans from an osteochondroma. In the skeletally mature individual, enlargement of a solitary osteochondroma (particularly one that is associated with progressive discomfort) must alert the physician to the possibility of malignant degeneration into a chondrosarcoma.

TREATMENT

Because a solitary osteochondroma is a benign tumor, it does not need to be surgically excised if it is asymptomatic. Excision usually is reserved for those lesions that cause pain or symptomatic impingement on neurovascular structures or that interfere with joint function. Pain usually becomes an issue when an osteochondroma is repeatedly bumped on its prominence, if a pedunculated base fractures following trauma, or if a painful bursa develops. Neurovascular impingement may include peroneal nerve compression at the knee, median nerve compression at the wrist, or, rarely, spinal cord compression from a vertebral osteochondroma. Sometimes the osteochondroma is considered cosmetically unacceptable and the adolescent will ask to have it removed, preferring a scar to a bump. Finally, surgical excision is indicated any time there is a possibility of malignant transformation of an underlying osteochondroma, as demonstrated by an increase in the size of the lesion or in symptoms following skeletal maturity.

Excision of osteochondromas should, if possible, be postponed until later adolescence, for the following reasons. First, the growth potential of osteochondromas in younger children is unknown, and the full extent of the tumor cannot be appreciated until its growth potential is recognized. Second, because there are small pockets of cartilaginous cores within the spongiosa bone of osteochondromas in young children, the risk of local recurrence following excision is significant. In this situation, if the osteochondroma is removed, the perichondrium and the periosteum along the

base of the lesion need to be excised. Finally, because of this dissection, the potential for growth arrest exists if the osteochondroma is very near a physis. In the maturing adolescent, the excision does not need to be quite as extensive, because the potential for recurrence is considerably less.

Occasionally a peripheral nerve (e.g., the peroneal nerve at the fibular head or the radial nerve along the humerus) may be in close proximity to the underlying lesion. Preliminary dissection of the nerve above the lesion can help avoid inadvertent injury to the nerve during excision of the osteochondroma. This anatomic situation, though, is more likely to occur with multiple hereditary exostoses rather than with a solitary osteochondroma.

SARCOMATOUS CHANGE

Malignant degeneration of a peripheral solitary osteochondroma leads to chondrosarcoma. However, malignant degeneration of solitary osteochondromas is rare, probably happening in less than 0.25 percent of lesions. Although Jaffe stated that 1 percent undergo malignant change¹²⁹ and Dahlin reported an incidence of 4.1 percent in solitary osteochondromas treated surgically at the Mayo Clinic,⁶⁶ these figures represent select cases referred to oncology centers. Malignant change evolves very slowly, usually occurring in adult life. When malignant changes occur, the lesions become painful and show evidence of growth.

MRI has been found useful in evaluating possible sarcomatous deterioration. The imaging modality delineates extension of the tumor mass into the adjacent soft tissues and allows proper planning of a wide resection of an underlying chondrosarcoma. Scintigraphic imaging with technetium-99m methylene diphosphonate has not been shown to qualitatively differentiate benign active exostoses from chondrosarcoma.¹²⁰ Likewise, gallium scans cannot sufficiently distinguish between benign and sarcomatous lesions.²⁵⁸ Imaging criteria differentiating osteochondroma from chondrosarcoma are provided in Table 37-1.

Biopsy prior to surgical excision of a presumed chondrosarcoma may be of limited value, as there is a significant chance of a nonrepresentative biopsy and a potential risk of seeding the biopsy tract.¹⁰⁷ The prognosis following excision of a chondrosarcoma is excellent.

Hereditary Multiple Exostoses

Hereditary multiple exostoses is an autosomal dominant condition affecting numerous areas of the skeleton that have been preformed in cartilage. The overall prevalence has recently been reported to approach one in 50,000,²⁴¹ which doubles the previously reported prevalence of one in 100,000.^{117,291} The disorder is known by a variety of terms: multiple hereditary osteochondromas, cartilaginous exostosis, diaphyseal aclasis (stressing abnormality of the modeling process), multiple osteochondromatosis, chondral osteoma, chondral osteogenic dysplasia of direction, deforming chondrodysplasia, hereditary deforming chondrodysplasia, and multiple cancellous exostoses.²¹⁶ The term most commonly used today, *hereditary multiple exostoses*, was proposed by Jaffe in 1943.¹²⁶

The median age at the time of diagnosis in affected indi-

TABLE 37-1 Criteria Differentiating Osteochondroma from Chondrosarcoma

Criterion	Osteochondroma	Chondrosarcoma
Relation to parent bone	Continuity of cortex and medullary cavity with parent bone	Gradual loss of continuity of cortex
External surface of tumor	Distinct, well demarcated	Fuzzy and indistinct
Cartilaginous cap (best visualized on MRI)	Thin, <1 cm	Thick, >3 cm, lobulated, extending into soft tissues
Matrix pattern	Dense at periphery with solid cortex Normal cancellous bone centrally	Periphery granular in appearance with small areas of rarefaction and disorganized calcification Later, blotchy areas of calcification within center of tumor with streaky densities extending peripherally
Adjacent soft tissue	Normal	Large soft tissue mass containing disorganized areas of calcification

Modified from Kenney PJ et al: The use of computed tomography to distinguish osteochondroma and chondrosarcoma. *Radiology* 1981;131:129.

viduals is approximately 3 years. Hereditary multiple exostoses has a penetrance of 50 percent by age $3\frac{1}{2}$ years. By the end of the first decade of life, 80 percent of affected persons will have exostoses. By 12 years of age, nearly all affected individuals have evidence of exostoses, as penetrance of the disorder has been found to reach 96 to 100 percent (Fig. 37-18).^{158,241,297} Although some studies have reported that incomplete penetrance preferentially affects females, other investigations have shown no such reduction.²⁴¹

ETIOLOGY

The disorder is of autosomal dominant inheritance, with penetrance approaching 96 percent. If a person whose family is affected by hereditary multiple exostoses has not had an exostosis by 12 years of age, it is unlikely that exostoses will develop later. However, there remains a small risk that a particular individual will have affected children because the gene is nonpenetrant in approximately 4 percent of carriers. Approximately 10 percent of affected individuals have no family history of hereditary multiple exostoses.

Numerous genetic studies have found anomalies on chromosomes 8, 11, and 19, making this a genetically heterogeneous disorder.* Specifically, the three loci include 8q24.1 (EXT1), 11p11-12 (EXT2), and 19p (EXT3). The EXT1 and EXT2 genes show extensive sequence homology to each other. These genes are deleted in exostoses-derived tumors, supporting the hypothesis that they encode tumor suppressors. Still another gene, EXTL (or EXT-like), has been identified that shows a striking sequence similarity to both EXT1 and EXT2. All of this information suggests that a family of related genes may be responsible for the development of hereditary multiple exostoses.

PATHOLOGY

The gross pathologic and microscopic features of hereditary multiple exostoses are similar to those described for solitary osteochondromas.

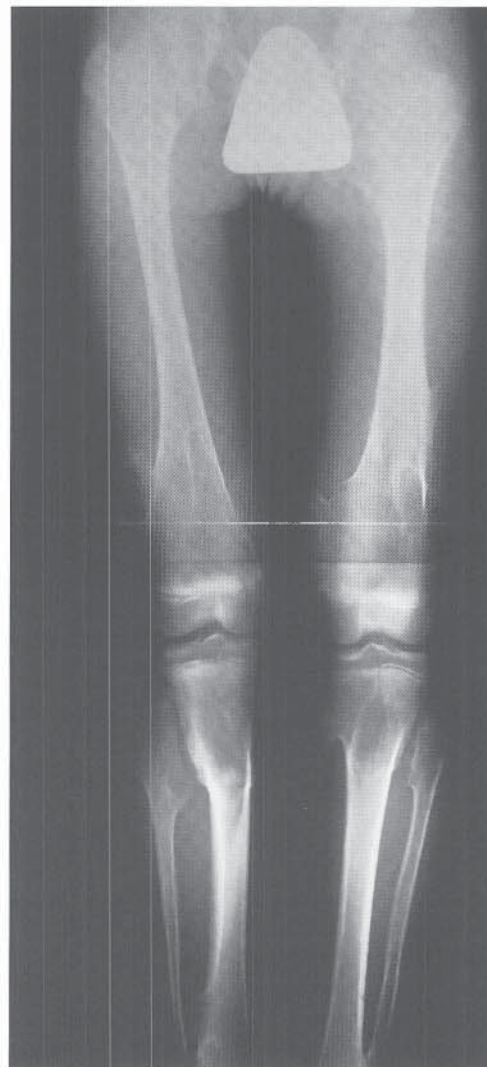

FIGURE 37-18 Hereditary multiple exostoses in a 12-year-old boy. Extensive involvement of the femurs, tibias, and fibulas was evident clinically and radiographically.

*See references 4, 29, 38, 69, 157, 164, 217, 218, 277, 296, 301, 309, 310.

CLINICAL FEATURES

Multiple exostoses usually manifest during early childhood (although rarely before 2 years of age) with several knobby, hard, subcutaneous protuberances near the joints. Numerous sites can be involved. On presentation, five or six exostoses typically may be found, involving both the upper and lower extremities. The “knobby” appearance of the child is so characteristic that one can usually make the diagnosis by clinical inspection alone. Over time, the upper and lower extremities may appear short in relationship to the trunk. Shortening of the limbs is usually disproportionate. Approximately 10 percent of affected individuals will have a lower limb length inequality. Patients are not considered dwarfs, and the trunk-limb growth difference usually does not become obvious until the pubertal growth spurt. On occasion, concerned affected parents may bring in their normal-appearing child for screening.

For those affected with hereditary multiple exostoses, 70 percent will have involvement of the distal femur, 70 percent the proximal tibia, and 30 percent the proximal fibula (Fig. 37-19). The likelihood of involvement near the knee in at least one of these three locations is approximately 94 percent. The proximal humerus is affected in 50 percent of cases, the scapula and ribs in 40 percent, the distal radius and ulna in 30 percent, the proximal femur in 30 percent, the phalanges in 30 percent, the distal fibula in 25 percent, the distal tibia in 20 percent, and the bones in the foot in 10 to 25 percent.²⁴¹ Tibia-fibular synostosis often develops from chronic apposition of osteochondromas proximally or distally but rarely causes symptoms or functional impairment. As the lesions enlarge, they may cause discomfort secondary

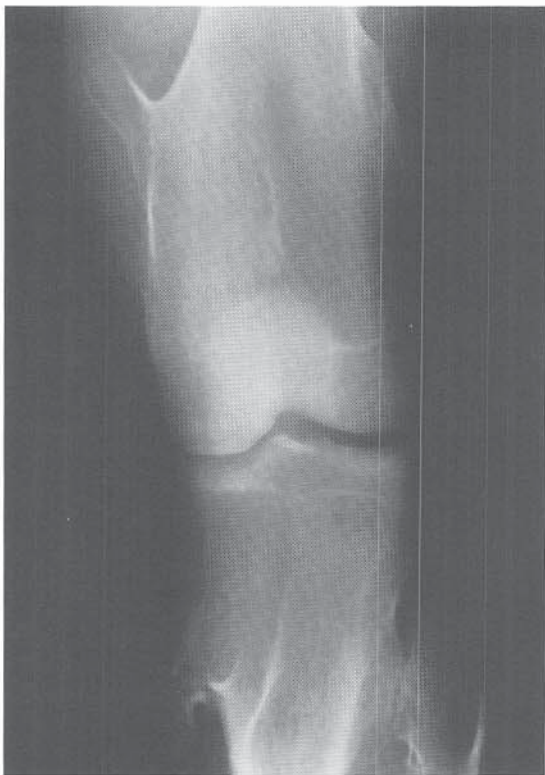

FIGURE 37-19 Osteochondromas are seen involving the femur, tibia, and fibula.

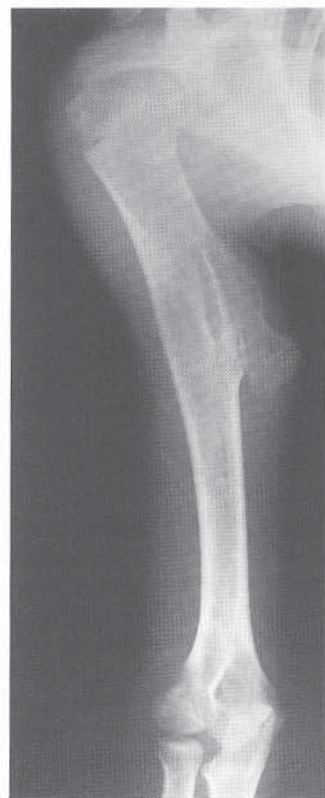

FIGURE 37-20 This exostosis on the medial aspect of the proximal humerus was minimally symptomatic.

to pressure on adjacent soft tissues, and they may hinder normal joint mobility.

Osteochondromas of the proximal humerus are often readily palpable but rarely cause neurologic dysfunction (Fig. 37-20). However, because of their proximity to major nerves, great care must be taken if resection is necessary. The scapula is involved in 40 percent of affected individuals, with osteochondromas located on the anterior or the posterior aspect of the scapula. The presence of osteochondromas on the anterior aspect of the scapula may lead to discomfort during scapulothoracic motion. Winging of the scapula due to the presence of osteochondromas has been described.⁷⁰

Obvious deformity in the forearm is seen in 39 to 60 percent of patients.^{216,241,267} The ulna is shorter than the radius and the radius is bowed laterally, with its concavity toward the short ulna (Fig. 37-21). Often the distal end of the ulna is more severely affected than the distal end of the radius, leading to this discrepancy in length. A mild flexion deformity of the elbow is usually present. Loss of forearm pronation and supination occurs with increasing age.²⁶⁷ Dislocation of the radial head occurs and is usually associated with a negative ulnar variance. The resulting forearm deformities are usually asymmetric. Often, the patient's main complaint is an undesirable cosmetic appearance. The natural history of these deformities has been described as progressive, with variable weakness, functional impairment, and worsening cosmetic deformity of the extremity. Some authors, however, report that the deformities are well tolerated and lead to little loss of function.²⁶⁷

Deformity of the hand is uncommon. The main area of involvement appears to be around the metacarpophalangeal

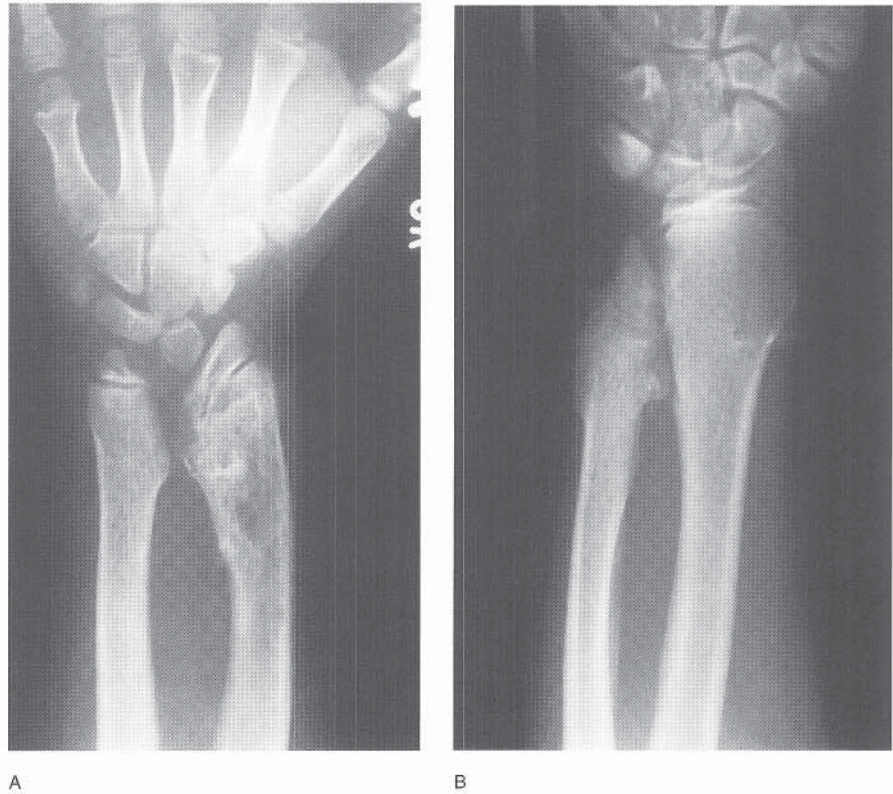


FIGURE 37-21 Two wrist deformities in a brother and sister. A, In the boy, the distal radius exhibited growth arrest on the ulnar aspect with associated compensation at the wrist joint. B, In the girl, the distal ulna was short due to growth arrest.

joint, but the proximal interphalangeal joint is the most common site of deformity. Metacarpal shortening usually does not cause functional problems and does not need to be treated. Angular deformity, although uncommon, does cause problems and requires surgical intervention. There is no evidence that deformity can be prevented by early excision of the osteochondromas.³⁰³

In the lower extremity, valgus of the proximal tibia is frequently present and is nearly always found in the proximal metaphyseal region of the tibia. The valgus progressively increases during growth spurts. Occasionally there will be some angulation distally at the femur, and there may be recurrent dislocation of the patella.¹⁹⁴

Osteochondromas of the proximal femur may lead to progressive hip dysplasia which, on occasion, will require corrective varus osteotomy (Fig. 37-22). Adverse effects on femoral growth are less with proximal involvement than with distal involvement.

Although osteochondromas near the ankle are not uncommon, the reported prevalence of ankle deformities ranges widely, from 2 percent to 54 percent.^{216,241,262} The characteristic ankle valgus deformity is often accompanied by decreased ankle motion. This deformity is caused either by retardation of the normal distal fibular growth or by deficient growth of the lateral half of the distal tibial epiphysis. The severity of the ankle valgus varies, as the distal fibular physis progressively rises in relation to the tibial-talar articular space.²⁴⁹

There have been numerous reports of spinal cord impingement by vertebral osteochondromas.^{20,85,134,184,222,250} The cervical, thoracic, or lumbar region can be affected. Lower extremity discomfort associated with decreased balance, im-

paired coordination, or other central neurologic dysfunction should raise the consideration of a vertebral osteochondroma. The presence and extent of the lesion are best delineated with CT, while MRI of the spinal cord demonstrates the area of spinal cord impingement.

RADIOGRAPHIC FINDINGS

Unlike solitary osteochondromas, hereditary multiple exostoses involve a significantly greater portion of the metaphysis or diaphysis and are generally more irregular in shape. Over time, lesions that begin in the metaphyseal region migrate into the diaphysis of the long bones. The exostoses vary in number, size, and configuration. Like solitary osteochondromas, they may be sessile or pedunculated, cauliflower-like, or even narrow with a pointed end. They nearly always point away from the physis. In nearly 95 percent of cases, evidence of the osteochondroma will be found around the knee. Thus, the disorder can often be confirmed with radiographs of the knee. Irregular zones of calcification may be present, particularly in the cartilaginous cap. In older individuals, however, extensive calcification with changes in the shape of the cartilaginous caps suggests possible malignant degeneration.

DIFFERENTIAL DIAGNOSIS

The numerous lesions associated with hereditary multiple exostoses make the radiographic findings pathognomonic of the disorder. If painful growth of an osteochondroma becomes evident in a mature individual with hereditary

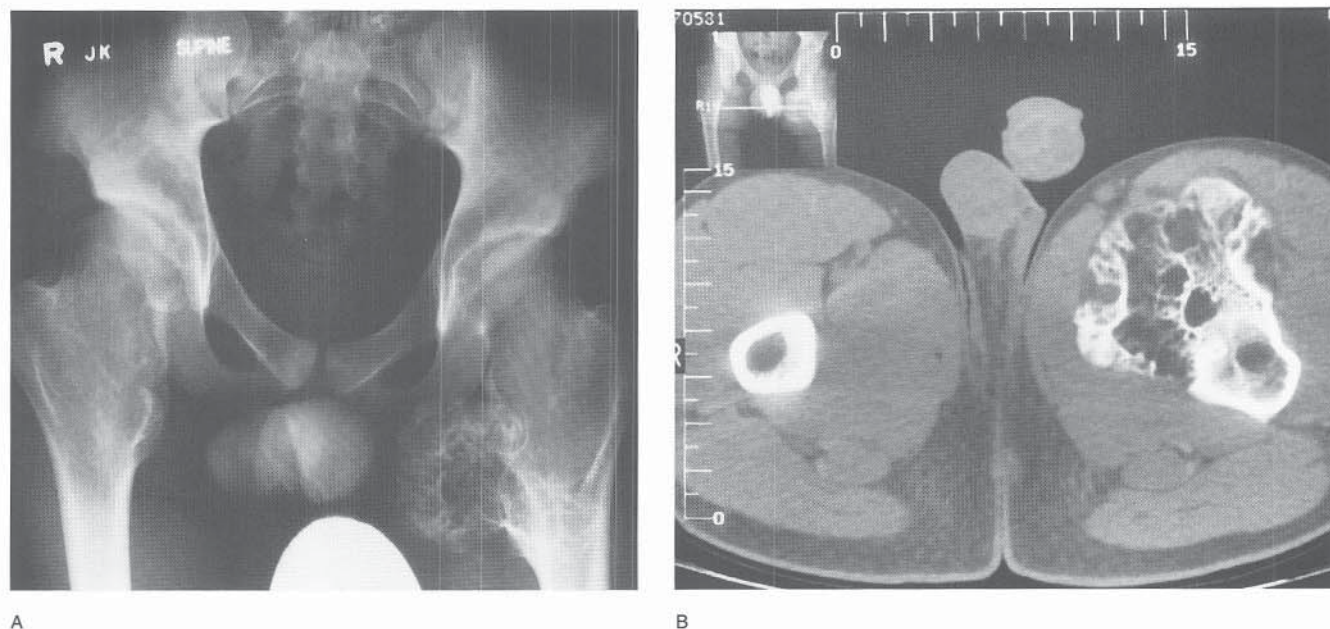


FIGURE 37-22 A, AP pelvic radiograph showing abnormal proximal femora due to hereditary multiple exostoses. B, CT scans of the hip region clearly demonstrated the 10-cm sessile osteochondroma on the left femur.

multiple exostoses, chondrosarcomatous transformation must be ruled out.

TREATMENT

The only treatment for hereditary multiple exostoses is surgery. However, because the exostoses are numerous and many are asymptomatic, a cautious approach is called for. The mere presence of an osteochondroma is not an indication for surgery. Reasonable indications include (1) pain from external trauma or irritation of surrounding soft tissues, (2) growth disturbance leading to angular deformity or limb length discrepancy, (3) joint motion compromised by juxta-articular lesions, (4) soft tissue (tendon, nerve, or vessel) impingement or tethering, (5) spinal cord compression, (6) false aneurysm produced by an osteochondroma, (7) painful bursa formation, (8) obvious cosmetic deformity, and (9) a rapid increase in the size of a lesion.²¹⁶ During childhood, numerous operations may be necessary, and this prospect should be discussed in detail with the parents soon after the disorder is diagnosed. Life expectancy is normal unless malignant degeneration of an osteochondroma has occurred and metastases have developed.

Osteochondromas involving the forearm frequently lead to surgical intervention. Early excision of the lesions on the radius and ulna does not alter or correct existing deformity, but it may delay progression of the deformity.²¹⁵ If ulnar shortening has occurred with bowing of the radius, lengthening of the ulna combined with distal radial hemiepiphyseal stapling has been found effective in correcting the deformity. Ulnar lengthening is best done gradually by distraction osteogenesis.⁶⁵ Creation of a “one-bone forearm” has been successful as a salvage procedure for severely affected forearms.²³⁰ Deformities of the forearm should be treated early and aggressively in an effort to prevent further progression and to reduce disability. A prominent, symptomatic, dislo-

cated radial head can be safely excised following skeletal maturity.¹⁹

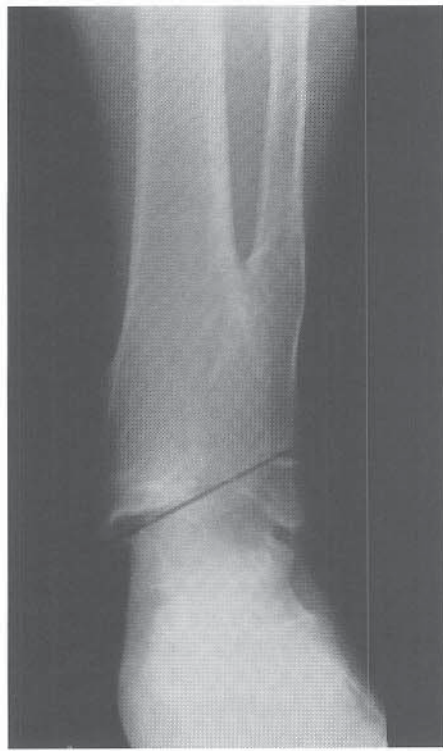Marked shortening of the humerus may result from a proximal physal growth disturbance. If the discrepancy is significant, distraction osteogenesis has been successful in increasing the length of the humerus.

For skeletally mature individuals with significant genu valgum, varus osteotomy of the proximal tibia can result in an improved appearance. However, if an osteochondroma is present in the proximal fibula, any osteotomy of the proximal tibia or fibula carries a significant risk of peroneal nerve palsy.³⁰⁰ In the skeletally immature patient, stapling along the medial side of the proximal tibial physis or distal femoral physis may be sufficient to correct the valgus. If correction is achieved by this method, the staples should be left in longer (slight overcorrection) to prevent recurrence of the deformity following staple removal.

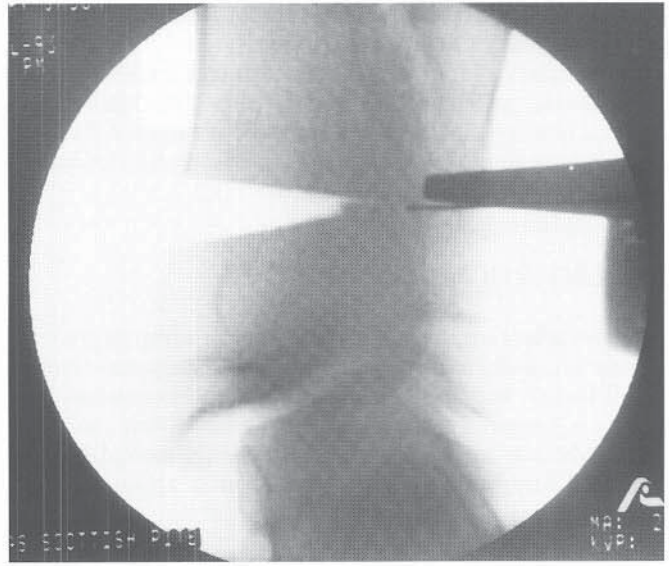
Ankle valgus is treated either by medial distal tibial physal arrest in the skeletally immature patient or by a varus corrective osteotomy in the more mature individual (Fig. 37-23).²⁶² Tibia-fibular synostoses frequently occur distally, but there usually are no symptoms or functional impairment from this occurrence and the condition does not need to be surgically treated.

SARCOMATOUS CHANGE

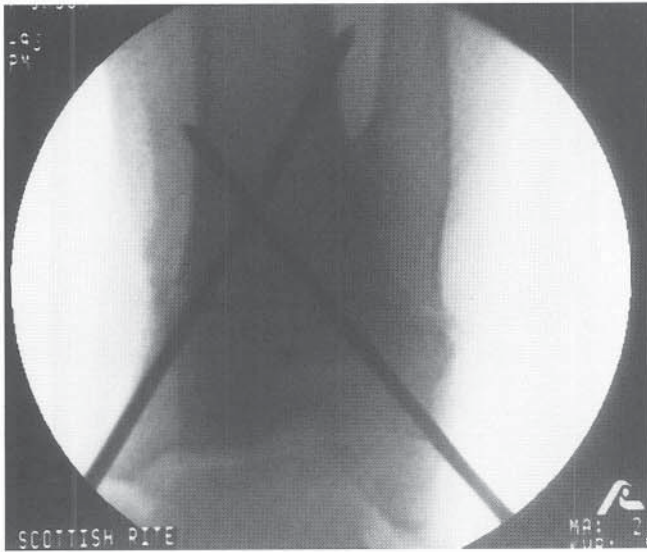
Transformation of a lesion in hereditary multiple exostoses to chondrosarcoma during childhood is exceedingly rare.²¹⁶ In general, transformation in adulthood remains uncommon, with current reports indicating the risk to be 0.9 to 5 percent.^{102,217,241,297} The apparent risk of malignant degeneration may become greater as the duration of follow-up increases. In Schmale and associates' 1994 study, two-thirds of the individuals with transformations were younger than 40 years when the authors reported an incidence of 0.9



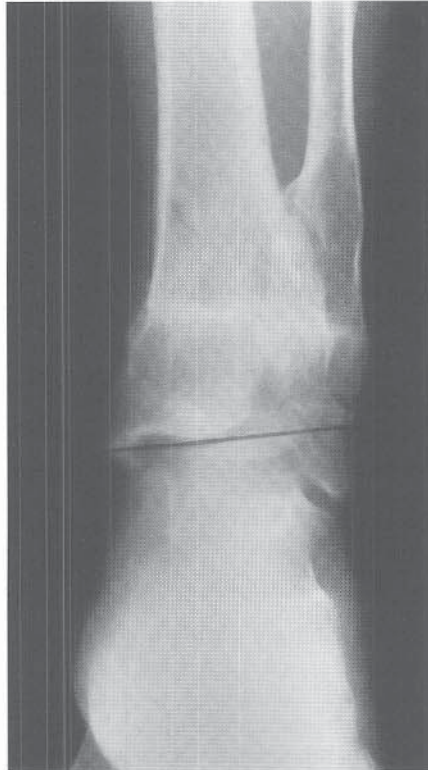
A



B



C



D

FIGURE 37-23 A, Excessive ankle valgus accompanied by a distal tibiofibular synostosis led to discomfort. B to D, A varus closing wedge osteotomy in the distal tibial/fibular region resulted in improved alignment and resolution of the patient's discomfort.

percent.²⁴¹ At this time, the lifetime risk of chondrosarcoma is estimated to be approximately 1 to 2 percent. The genetic abnormalities found on chromosomes 8, 11, and 19 (tumor suppressor genes) may play a role in the development of chondrosarcomas.²²⁵

The most frequent sign of sarcomatous change is a painful, enlarging mass, usually one of long duration.¹⁸¹ The relative frequency of chondrosarcomas is reported to be highest with osteochondromas of the pelvis or shoulder girdle.¹⁴⁴ The clinical course of the tumor is slow and metastasis occurs late, usually to the lungs.

If the cartilaginous cap of the exostoses exceeds 1 cm in thickness, malignancy should be suspected. Inadequate surgical removal almost always results in recurrence. Patient prognosis is good if metastasis has not occurred. Radiation therapy has no effect on the tumor.

Solitary Enchondroma

Intramedullary cartilaginous solitary enchondromas are relatively common, accounting for approximately one-fourth of all benign tumors. Unlike multiple enchondromatosis, which is frequently diagnosed during childhood, solitary enchondromas are usually diagnosed after the second decade of life.¹⁰⁶ The peak age of presentation is approximately 35 years.

PATHOLOGY

Enchondromas appear as glistening white, grayish white, or pearly tissues that have a gritty feel on palpation, owing to the intrinsic calcification.²⁷⁶ The tumor is easily cut with a knife, as if it were soft chalk.

Histologically, enchondromas are proliferating nests of cartilage cells that lack obvious atypia.⁴⁰ Foci of calcification are present. Plates of lamellar bone surround the lobules of cartilage in a partial to complete circumferential manner.¹⁸⁶ Invasive infiltration of the bone marrow spaces is not characteristic of benign solitary enchondromas.

Although mitotic figures within the dysplastic cartilaginous lesions may be found in specimens from growing children, the likelihood of malignancy is low. In the adult, however, it may be difficult to differentiate an enchondroma from a low-grade sarcoma. In general, small peripheral cartilage tumors are usually benign, whereas the large axial tumors in the adult are more likely to be malignant. A malignant change of a solitary enchondroma in childhood or adolescent would be a rare event.

CLINICAL FEATURES

Nearly 50 percent of diagnosed solitary enchondromas occur in the hand, involving the phalanges in particular. The carpal bones are occasionally affected.²²⁷ Of the long tubular bones, the femur and humerus are frequent sites of localization. Occasionally the ribs, sternum, innominate bones, and vertebral columns may also be affected.

Clinically, enchondromas in the fingers are generally diagnosed following local trauma. Some patients, however, present with a firm, local swelling in the region of the affected

phalanx or metacarpal without a fracture or local pain. Nearly 75 percent of patients with enchondromas involving the hands or feet have a solitary lesion. The remaining patients have multiple enchondromatosis. When the solitary enchondroma involves the femur or humerus, it is usually quiescent, with no clinical signs evident until adulthood.

RADIOGRAPHIC FINDINGS

Solitary enchondromas usually appear as well-delineated lucent defects in the metaphyseal region of long bones. In the phalanges of the hand or foot, the entire shaft may be involved. The cortical rim is generally intact unless a fracture has occurred through the weakened bone (Fig. 37-24). Calcification is usually present within the lesion and appears as fine punctate stippling. In the larger long bones, calcification may be more pronounced, which can make the differentiation between enchondroma and bone infarct difficult.⁴⁰ Most lesions are 3 to 4 cm in size, with a range of 1 to 8 cm.¹⁸⁵ Generally there is no evidence of focal cortical erosion, scalloping of the cortex, significant cortical thickening, or bone expansion. In the older symptomatic adolescent, cortical thinning and expansion in the larger long bones can be troubling because these radiographic findings may represent features of low-grade chondrosarcoma.

CT is useful for evaluating cartilaginous tumors, especially in the long bones, pelvis, and spine. Technetium bone

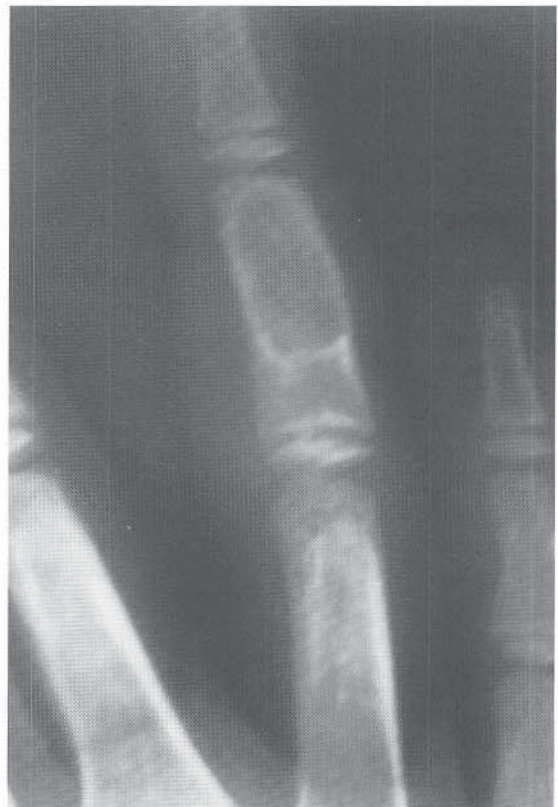

FIGURE 37-24 A solitary enchondroma in the middle phalanx of the ring finger. Radiographs showed a well-delineated lucent lesion with an intact cortical rim. It was noticed because of mild painless swelling of the digit.

scanning generally is not necessary when evaluating a child with presumed enchondroma.

DIFFERENTIAL DIAGNOSIS

Confusion between an enchondroma and a bone infarct may occur when the radiolucent lesion has a significant amount of calcification. However, in general, the calcification seen with bone infarcts is more peripherally located. In the phalanges of the hand and foot, solitary enchondromas may be difficult to differentiate from epithelial inclusion cysts. In a metacarpal, it may be difficult to distinguish a solitary enchondroma from a small solitary bone cyst, a nonossifying fibroma, or a focus of fibrous dysplasia.

TREATMENT

For solitary enchondromas in the hand, complete curettage followed by autogenous bone grafting usually results in cure. Similar treatment is undertaken for solitary enchondromas in the long bones, where the recurrence rate remains low. If an en bloc wide excision were performed, the recurrence rate would be even lower. However, the possibly unacceptable postoperative functional deficit makes this more aggressive approach unnecessary.

The risk of malignant degeneration of an isolated enchondroma is rare in childhood. However, these lesions should be followed over time. Enchondromas in the pelvis, scapulae, sternum, vertebrae, and proximal area of the large long bones have a greater likelihood of malignant transformation in adulthood.

Multiple Enchondromatosis (Ollier's Disease) and Maffucci's Syndrome

Ollier in 1889 described a condition of multiple, typically unilateral enchondromas associated with deformity of the extremity.²⁰² He referred to the condition as dyschondroplasia, implying that it resulted from a developmental defect related to abnormal growth of cartilage.¹⁸⁵

PATHOLOGY

On gross inspection of the lesions, the bones show numerous islands of glistening cartilage, which are generally located in the diaphyseal and metaphyseal regions. Infrequently, abnormal cartilage may also be seen in the epiphyseal region. This close proximity of the tumor to the physis can lead to profound inhibition of growth, resulting in severe limb length discrepancies or angular deformities. As longitudinal growth continues, the abnormal enchondroma cartilage derived near the epiphyseal plate will form long linear masses within the shaft. This phenomenon is seen only in Ollier's disease and explains the pathognomonic "fanlike" metaphyseal septation seen on radiographs. The dense lines represent bone formed by normal enchondral ossification and the intervening columns of lucency represent the epiphyseally derived areas of abnormal cartilage.¹⁸⁶

The histologic features in multiple enchondromatosis generally resemble those of a solitary enchondroma. However, in multiple enchondromatosis the appearance might be that of a highly cellular lesion with ominous nuclei mimicking a low-grade chondrosarcoma. Eventual malignant transformation into chondrosarcomas has been reported to occur in 20 to 33 percent of those affected. Therefore, communication between the surgeon, pathologist, and radiologist is imperative when making the diagnosis in the older adolescent or adult. In general, aggressive histologic findings are still likely to represent a benign lesion if the biopsy site is the hand rather than the long bones or the pelvis. Conversely, if the biopsy site is the pelvis or larger bones, suspicion of low-grade sarcomas is higher. The atypical cellular features in Ollier's disease may explain the relatively high incidence of chondrosarcomatous transformation in older individuals who are moderately or severely affected.

CLINICAL FEATURES

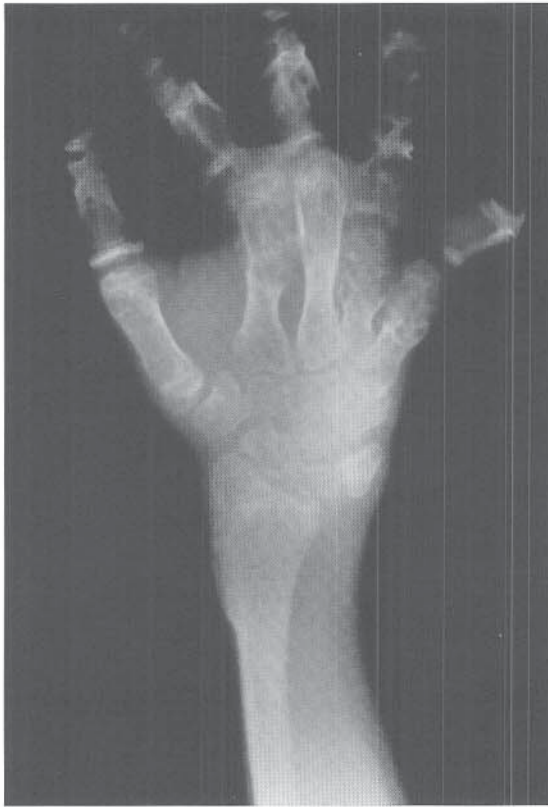Multiple enchondromatosis is an uncommon, nonhereditary disorder. The physical signs related to this condition commonly begin in childhood and vary with the extent of the lesions and their effect on the weakened bones. The number of bones affected can vary greatly, with the phalanges, femur, and tibia most commonly affected (Fig. 37–25). Because of the tendency toward unilateral involvement, severe lower limb length discrepancies and angular deformities (most commonly genu valgum) result. Discrepancies may be in the range of 10 to 25 cm by maturity. Deformity and enlargement of fingers may impair normal function. Forearm abnormalities such as bowing, limited rotation, and ulnar deviation of the hand may be evident.

Maffucci's syndrome is a condition of enchondromatosis associated with multiple hemangiomas involving soft tissue.^{111,135} They may be associated with superficial phleboliths, which can appear on radiographs as roundish opacities in the soft tissues. Hemangiomas have also been noted to occur within internal organs. Multiple pigmented nevi and vitiligo are other occasional nonskeletal manifestations. An abnormality in neuropeptides has been identified, and their presence appears to stimulate growth of abnormal blood vessels.²²⁹

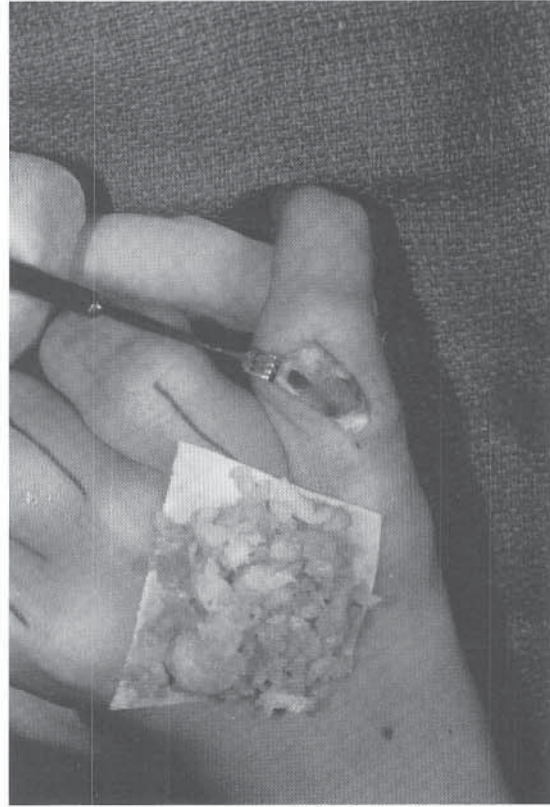Another related entity, *generalized enchondromatosis*, represents a more severe expression of the disorder. Nearly all of the metaphyseal regions in all of the long and short tubular bones are affected.²¹⁴

RADIOGRAPHIC FINDINGS

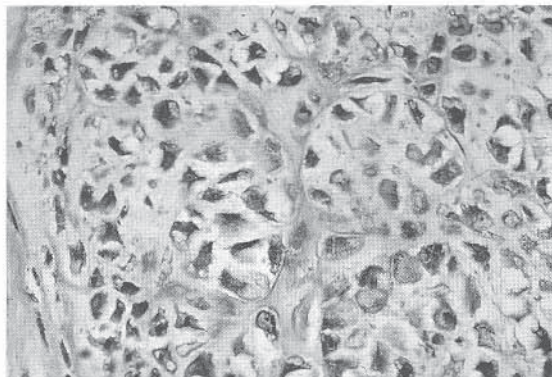
Bone abnormalities are usually more extensive than the physical examination would suggest. In the long bones, enchondromatosis is recognized as radiolucent longitudinal streaks that involve the metaphysis and extend down into the diaphysis. Epiphyses are usually not affected but, as reported recently, may be involved.⁹⁹ The cortex overlying the enchondroma is usually thin, and calcification within the lesion is common. Significant shortening and angular deformity are frequently noted in the involved long bones, whether in the hands, feet, or limbs.



A



B



C

FIGURE 37-25 A young boy with Ollier's disease. A, AP radiograph. All of the metacarpals and phalanges in the hand were affected. B, Following curettage of the proximal phalanx of the little finger, glistening white tumor was evident. C, Histologic examination demonstrated the proliferative nests of cartilage cells.

CT is useful for evaluating multiple enchondromatosis, particularly in the long bones and pelvis. CT clarifies cortical and osteal scalloping better than plain radiography and allows precise comparisons to be made over time.

TREATMENT

Because of the extent of the disease, multiple enchondromatosis cannot be cured by curettage and bone grafting. The numerous deformities that often accompany multiple enchondromatosis require repeated operative interventions over several years to correct the angular deformities and achieve similar limb lengths at maturity.^{57,208,248} These procedures include osteotomies, limb lengthenings, and epiphysi-

odeses (Fig. 37-26). In the older child, use of the Ilizarov apparatus is the best method to achieve both angular correction and equalization of limb lengths.⁶³ Use of multiple wires or half-pins allows sufficient purchase in the enchondromatous bone so that lengthenings can be successfully achieved.

MALIGNANT POTENTIAL WITH ENCHONDROMATOSIS

The incidence of secondary chondrosarcoma in patients with Ollier's disease is approximately 25 to 30 percent by age 40 years.^{47,165,245,270} Those patients with Maffucci's syndrome have a similar or higher likelihood of developing malignant de-

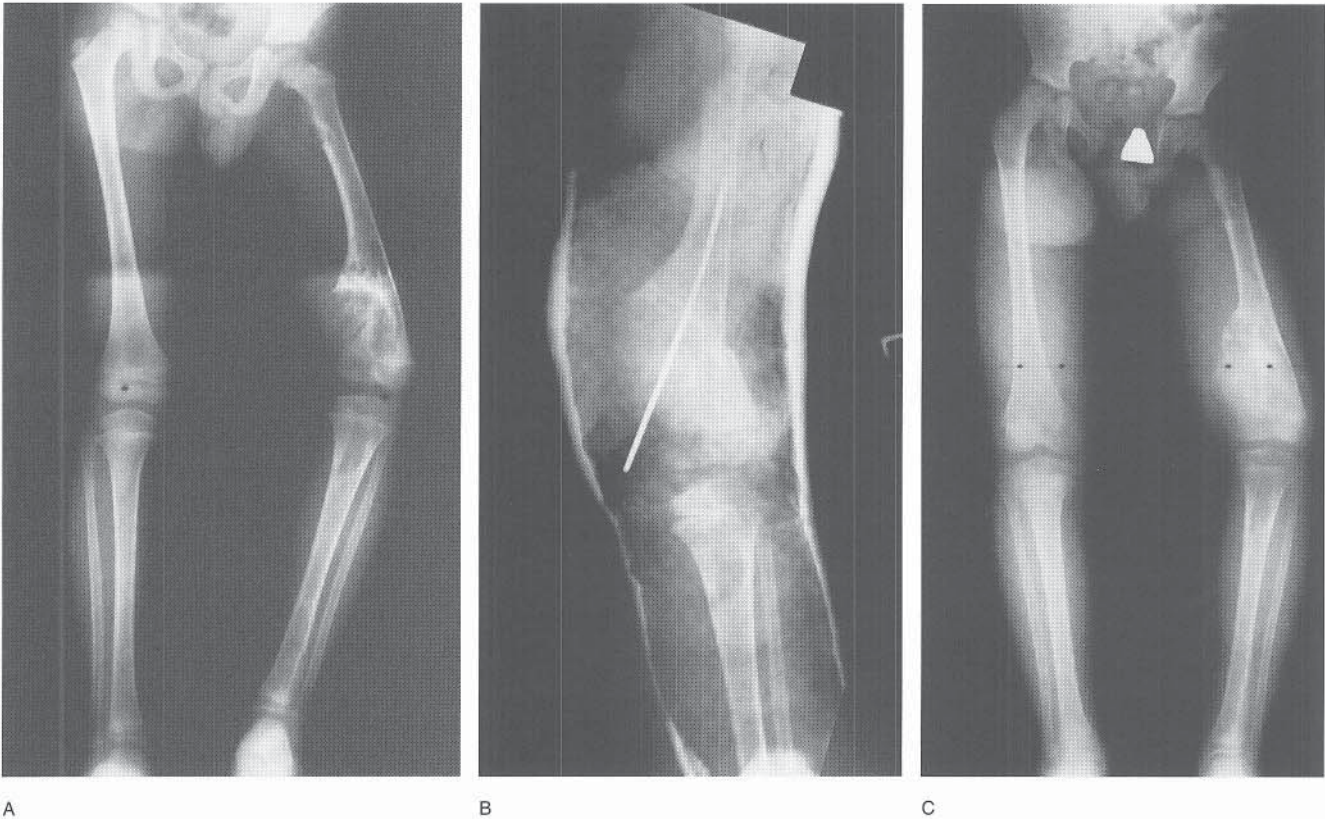


FIGURE 37–26 Findings in a 4-year-old boy with Ollier’s disease. **A**, Radiograph demonstrating unilateral left lower extremity involvement. **B**, A valgus osteotomy of the distal femur was performed to correct the notable genu varum. **C**, Two years later, the genu varum recurred, owing to the abnormal growth at the distal femoral physis. Another osteotomy was planned; future limb lengthening will be needed.

generation,^{7,26} with Schwartz and associates reporting nearly 100 percent expectation.²⁴⁵ Over the long term, periodic surveillance of the brain and abdomen for occult malignant lesions is indicated in patients who have enchondromatosis.^{122,180,223} Increased localized growth of a lesion in an extremity accompanied by pain is the hallmark of possible malignancy. In such a situation, biopsy of the lesion is indicated. Hematopoietic malignancies (acute lymphoid leukemia) have been described in association with Maffucci’s syndrome.²²⁶

Chondroblastoma

Chondroblastomas are uncommon benign cellular cartilage tumors that are most often located in the epiphyses of the long bone of the extremities.^{153,154} Chondroblastomas are twice as common in males as in females. The peak age of occurrence is in the second decade, the majority of patients presenting before age 30 years.

Chondroblastoma was first described in detail by Codman in 1931.⁶⁰ He called the lesion an epiphyseal chondromatous giant-cell tumor. Prior to his description, the tumors were often thought to represent chondrosarcomas. Today, chondroblastomas are still occasionally referred to as Codman’s tumor.

ETIOLOGY

Jaffe and Lichtenstein conjectured that the lesion arises from cartilage “germ cells” or cells of the epiphyseal cartilage.¹²⁹ However, because of reports of the lesion involving the skull or rib (where cartilage “germ cells” would not likely be found), this hypothesis is difficult to confirm.

Abnormalities in chromosomes 5 and 8 have been reported in chondroblastoma; however, specific locations have not been clearly identified.²⁷³

PATHOLOGY

Gross specimens obtained at the time of curettage are often characterized by pieces of gray-pink or hemorrhagic tissues intermixed with gritty, calcified, cholesterol-laden tissues. There may be small islands of bluish to white chondroid. Because chondroblastomas are often found to contain cystic or degenerative areas, the amount of tissue removed may be less than expected based on the radiographic appearance.

Histologically, the tumor is characterized by polygonal cells (chondroblasts), giant cells, islands of chondroid or hyaline cartilage, “chicken wire” calcification, and nodules of calcification in the stroma (Fig. 37–27).^{86,98,219} The “chicken wire” calcification results when lacelike deposits of calcium are intermixed on the intercellular chondroid matrix.

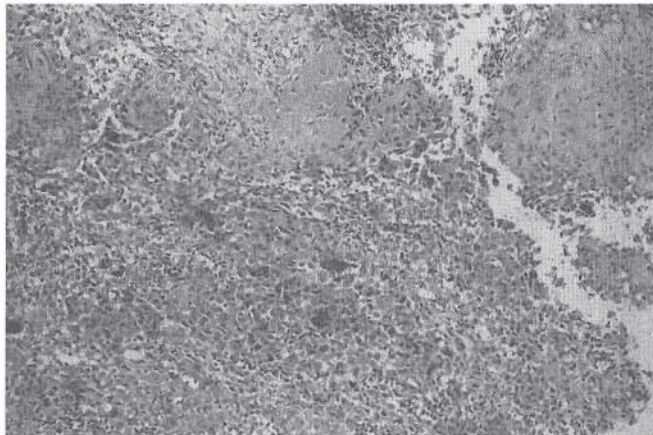


FIGURE 37–27 Histologic evaluation of chondroblastoma shows polygonal cells (chondroblasts), giant cells, islands of chondroid or hyaline cartilage, and “chicken wire” calcification.

A small percentage of chondroblastomas may be primarily cystic or hemorrhagic, making differentiation from aneurysmal bone cysts difficult histologically. Another more worrisome tumor, clear cell chondrosarcoma, may histologically resemble chondroblastoma. However, clear cell chondrosarcomas occur in adults with closed physes, and their radiographic appearance and clinical presentation would not be consistent with chondroblastomas.

CLINICAL FEATURES

The most common locations are the proximal humerus, distal femur, and proximal tibia. Chondroblastomas have also been found in the skull, maxilla, spine, ribs, pelvis, hands, patella, talus, and calcaneus.^{30,90,220,276,302,315} Multifocal, benign chondroblastomas have been reported. Nonepiphyseal locations in the long bones have been described.³⁹

Symptoms usually are mild, consisting of pain and localized tenderness. The discomfort is often present for 6 months to several years prior to diagnosis. Because the lesion is epiphyseal, the adjacent joint may be swollen and may have limited range of motion. If tumor is present in a lower extremity, an antalgic limp may be evident. Pathologic fractures are uncommon.

RADIOGRAPHIC FINDINGS

Chondroblastomas are usually located in the epiphyses, but they may extend into the metaphyseal region (Fig. 37–28). They are usually eccentric, involving less than one-half of the entire epiphysis. The lesion is rimmed by a border of host bone sclerosis, and small punctate calcifications are present within the tumor. Commonly, the physis adjacent to the lesion is present at the time of diagnosis. If all of these features are present, this radiographic appearance is pathognomonic for chondroblastoma.¹⁸⁵

CT will clearly demonstrate the extent of the lesion within the epiphyseal region and its proximity to the physis or subarticular surface.

MRI findings associated with chondroblastoma have been reported.^{204,295,313} Adjacent bone marrow and soft tissue edema, as well as periosteal reactions, are more dramatically

demonstrated on MRI than on plain radiographs. Bone marrow edema is common. Knowledge of the MRI findings of chondroblastoma may allow for more accurate diagnosis and help to avoid confusion with infection or aggressive neoplasms.

Fine-needle aspiration yields satisfactory material for interpretation and confirming the diagnosis.^{88,115,143}

DIFFERENTIAL DIAGNOSIS

The differential diagnosis includes giant-cell tumors, enchondromas, synovial lesions (e.g., pigmented villonodular synovitis, rheumatoid arthritis), and atypically located eosinophilic granuloma.

TREATMENT

Complete curettage and excision of the lesion is often successful. The surgeon should avoid interfering with the joint surface or disturbing the physes in the immature skeleton. The defect is filled with either autogenous or allograft bone. Although there is a definite risk of recurrence following intracapsular curettage, a recent study reported local control in approximately 80 percent of cases.²⁸² Preservation of the physis should be considered a secondary concern compared to complete and thorough excision of the chondroblastoma.⁵⁴ If the tumor is beneath articular cartilage, adequate excision may occasionally require removal of some of the joint cartilage. Arthroscopy has been used as an adjunct in the excision of lesions in the proximal tibia and proximal femur.^{61,278}

Occasional chondroblastomas require wide marginal resection, especially those that have recurred locally. Reconstruction after marginal or wide en bloc resection usually requires a partial or full osteoarticular allograft.

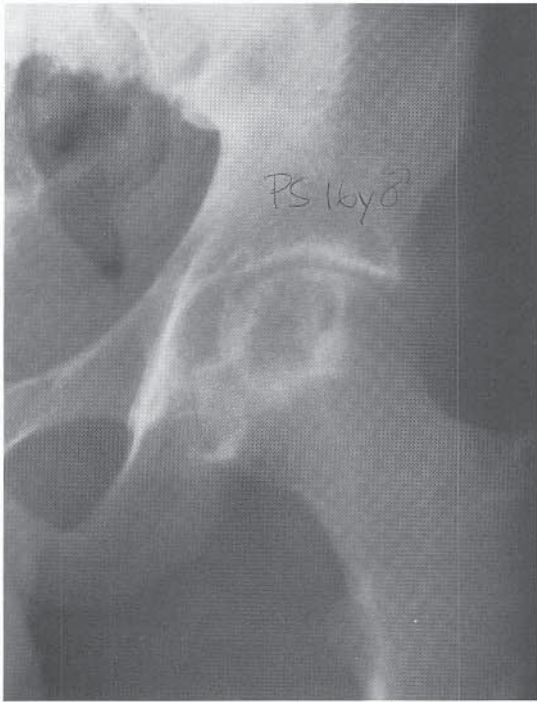
Chondroblastomas have been known to undergo benign pulmonary metastasis.¹³² When found in the lung, these metastases are usually rimmed with bone. When identified, these lesions should be surgically removed to ensure proper diagnosis.

Chondromyxoid Fibroma

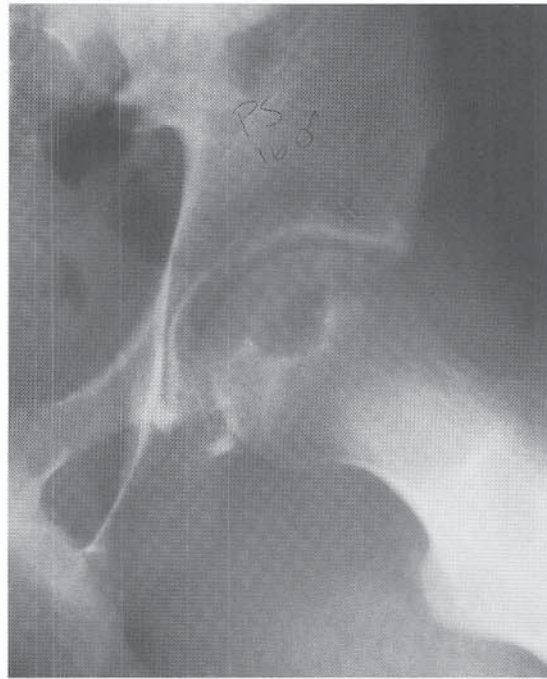
Chondromyxoid fibromas are rare, benign tumors representing less than 0.4 percent of biopsied primary bone tumors.^{185,197} They consist mainly of cartilaginous tissue intermixed with areas of myxomatous and fibrous elements. The myxomatous components are most probably due to degeneration of chondroid tissue, while the fibrous component may result from repair of the degenerated areas.

ETIOLOGY

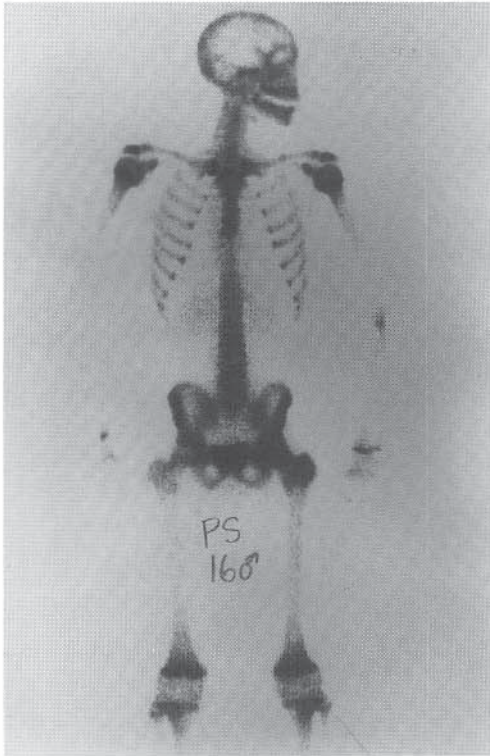
Cytogenetic analysis of chondromyxoid fibromas has found an unbalanced reciprocal translocation between the short arm of chromosome 3 and the long arm of chromosome 6. Two known cartilage-related genes are located in the regions affected by this unbalanced rearrangement. These genes function to control growth and maturation of endochondral bone, the site of origin of cartilaginous tumors.¹¹³



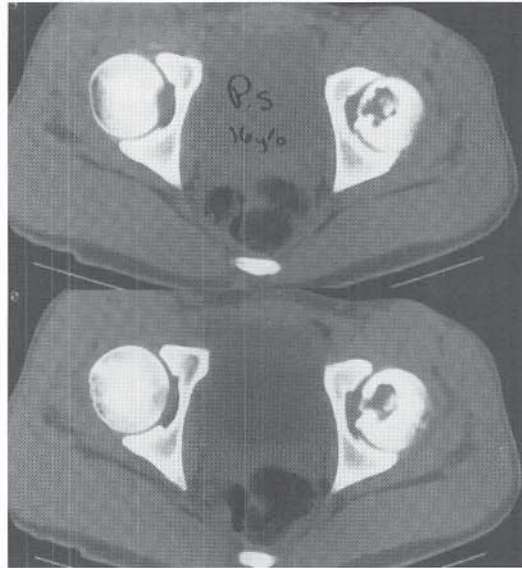
A



B



C



D

FIGURE 37–28 Chondroblastoma. **A** and **B**, AP and lateral radiographs of the left hip in a 16-year-old girl showing a subchondral radiolucent lesion in the femoral head (epiphyseal region) that is rimmed by a border of host bone sclerosis. **C**, Bone scan shows significant uptake in the left femoral head. **D**, CT of the hips shows calcification within the lesion.

PATHOLOGY

Most chondromyxoid fibromas are less than 5 cm in size. The tissue is firm, grayish white, and often covered on the outer surface with a thin rim of bone or periosteum. Cysts or areas of hemorrhage may be found within the lesion (Fig. 37–29). Histologically, chondromyxoid fibromas have a lobulated pattern, with some of these lobules sparsely cellular and others more cellular. Those lobules that have few cells are composed of a myxoid or chondroid matrix.^{40,316} Microscopic areas of cystic degeneration may contribute to the myxoid appearance. Other features of a chondromyxoid

fibroma include osteoclast-like giant cells, intermixed fibrous tissue, and occasionally cholesterol, hemosiderin, and lymphocytes. Distinct calcification is rare.

CLINICAL FEATURES

Chondromyxoid fibromas usually occur in older children and young adults, with individuals most commonly presenting for treatment in the second and third decades of life. Although most of the lesions are found in the tibia, other sites of predilection include the femur, fibula, metatar-

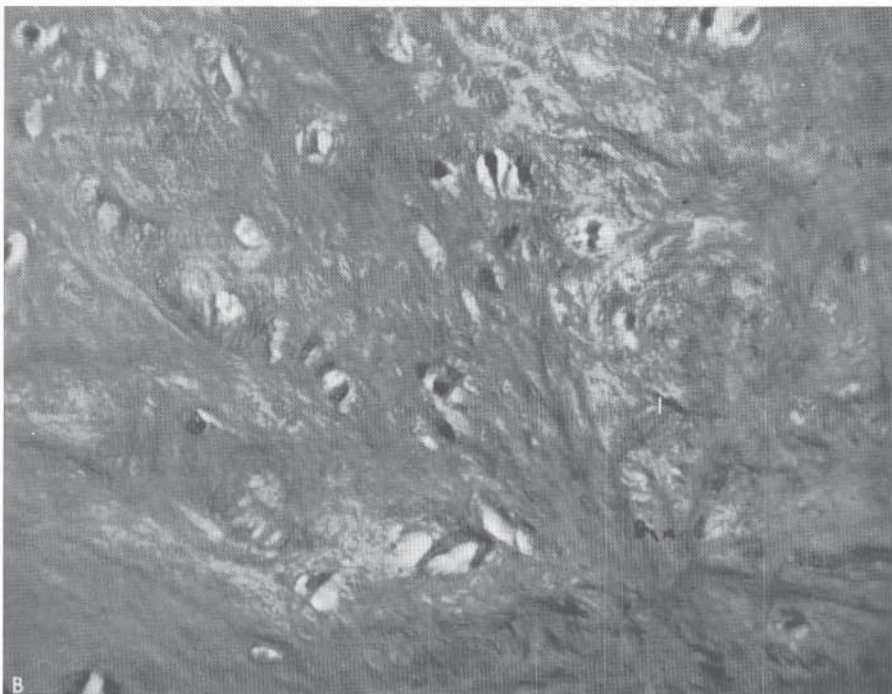



FIGURE 37–29 Chondromyxoid fibroma in the neck of the right femur. **A** and **B**, Photomicrographs showing the characteristic histologic picture. Note the ovoid and moderate-sized nuclei of the cells, which are widely separated by myxoid and chondroid matrix.

sals, and calcaneus.^{182,200,306} The upper extremities are rarely involved. Males and females are equally affected.

As with other benign bone tumors, it is not uncommon for a chondromyxoid fibroma to be discovered incidentally on a radiograph obtained for an unrelated reason. If symptoms are present from the lesion, the local discomfort usually is mild and intermittent. Swelling of the area and tenderness on palpation are occasionally noted.

RADIOGRAPHIC FINDINGS

Chondromyxoid fibromas are usually ovoid or round. They are slow-growing and usually evoke a border of reactive host bone sclerosis.²⁹⁹ This sclerotic border, most commonly seen in patients less than 20 years old, is a useful sign for determining the lesion's benign nature. Many of the tumors will have a trabeculated or bubbly appearance, but it is uncommon for calcification of the cartilage to be evident on radiographs. Chondromyxoid fibromas appear in the metaphyseal region of the long bones. They are usually eccentric and juxtacortical or even periosteal in location. It may be difficult to differentiate periosteal chondromyxoid fibromas from an aneurysmal bone cyst. In younger children, chondromyxoid fibromas may appear next to the physis, but with growth, the lesions tend to migrate away from the physis.

DIFFERENTIAL DIAGNOSIS

The radiographic appearance of a chondromyxoid fibroma can be very similar to that of a nonossifying fibroma. Both lesions are usually metaphyseal, eccentric, surrounded by a border of sclerosis, and trabeculated. Unlike nonossifying fibromas, chondromyxoid fibromas may bulge from the original bony contour. When the chondromyxoid fibroma is notably eccentric and associated with periosteal expansion, differentiation from aneurysmal bone cysts may be difficult. Other lesions to consider include solitary eosinophilic granuloma, enchondroma, simple bone cyst, and, in the older individual, worrisome entities such as chondrosarcoma or myeloma.

TREATMENT

Fine-needle aspiration cytology can be used to diagnose chondromyxoid fibroma.¹¹⁵ Many of these lesions have been effectively treated by simple curettage. In younger patients, however, incomplete removal may lead to recurrence, which is estimated to occur in as many as one-fourth of patients.³⁰⁵ Therefore, en bloc excision should be considered. Because of the benign nature of this tumor, the surgeon should avoid radical procedures. If the lesion is next to the physis, consideration should be given to delaying surgical intervention until the tumor has grown away from the physeal area. Radiation therapy and chemotherapy are not considered in the management of chondromyxoid fibromas. Chondrosarcomatous transformation is rare.

Osteoid Osteoma

Osteoid osteomas were described as a distinct entity by Jaffe in 1935.¹²⁷ Earlier reports referred to this entity as “sclerosing

nonsuppurative osteomyelitis,” osteomyelitis of Garré, or “localized or cortical bone abscess.”

Osteoid osteomas are solitary, benign, painful lesions of the bone. They have a nidus, 1.5 to 2.0 cm in size, that consists of osteoid, osteoblasts, and variable amounts of fibrovascular stroma.¹⁸⁵ This nidus is surrounded by an area of reactive, dense bone. Osteoid osteomas are relatively common, benign bone lesions, exceeded in incidence only by osteochondromas and nonossifying fibromas.⁹⁵ Osteoid osteomas account for approximately 10 to 11 percent of benign bone tumors and 2 to 3 percent of all primary biopsied bone neoplasms. They are characteristically seen in children and adolescents. The male-female ratio is approximately 2:1.

ETIOLOGY

The etiology of osteoid osteomas remains unknown.

PATHOLOGY

At the time of surgery, the cortical bone overlying the osteoid osteoma may be mildly pink compared with the surrounding cortex because of the increased local vascularity. The lesion itself is often a small, round or oval, cherry-red or reddish brown tumor 1.0 cm or less in diameter. Differentiation between osteoid osteoma and osteoblastoma depends on the size of the lesion: lesions less than 2.0 cm in diameter are technically classified as osteoid osteomas. The nidus may have a very dense, gritty texture if a significant amount of calcification is present, or it may be quite soft and granular if it is predominantly vascular with little calcification.

Histologically, osteoid osteomas are characterized by small spicules of immature trabeculae, most often lined by prominent osteoblasts and osteoclasts (Fig. 37–30).⁴⁰ In mature lesions, the intervening stroma is sparsely cellular with readily apparent vascular spaces. Cartilage is not present. The demarcation between reactive surrounding bone and nidus is readily apparent microscopically. The pain associated with osteoid osteoma is thought to be caused by the numerous nonmyelinated axons that are present within the nidus.

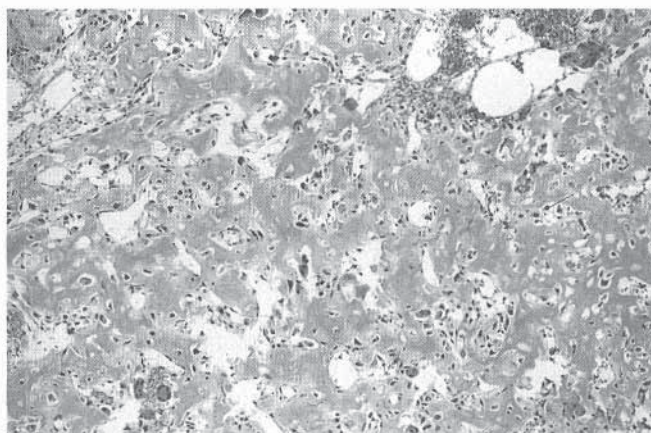


FIGURE 37–30 Osteoid osteoma, histologic appearance. The immature bone in the nidus of osteoid osteomas is lined by prominent osteoblasts and osteoclasts.

CLINICAL FEATURES

The patient with osteoid osteoma typically presents with a history of dull, aching pain in the region overlying the affected long bone. The pain may have been present for several months before presentation, tends to be worse at night, and is relieved significantly by salicylates or nonsteroidal anti-inflammatory drugs (NSAIDs).

The most commonly involved site is the lower extremity, particularly the metaphyseal or diaphyseal region of the femur and tibia. Occasionally the tumor is periarticular in location. Less frequent sites of involvement include the humerus, spine, foot (talus, calcaneus, and metatarsals), calvarium, maxilla, mandible, clavicle, scapula, ribs, pelvis, and patella.

A limp is often noted during evaluation of the patient's gait. Muscle atrophy may be apparent if the lesion has been present for several months. However, direct tenderness, erythema, or swelling is uncommon. If the lesion is in the vertebral column (most commonly in the posterior elements), a secondary painful scoliosis may be evident.²²⁴ The concavity of the curvature is usually on the side of the lesion and is attributed to spasm of the paravertebral muscles.²³⁶ Excision of the nidus in the vertebral column will often result in complete resolution of the scoliosis.

RADIOGRAPHIC FINDINGS

The radiographic appearance depends on the location of the osteoid osteoma within the bone. Most of the tumors are intracortical, with the nidus appearing as a radiolucent lesion. This nidus rarely exceeds 1.0 cm in diameter but may be as large as 2.0 cm. The dense surrounding reactive sclerotic bone may extend for several centimeters away from the nidus. Less commonly, the osteoid osteoma may be intramedullary, subperiosteal, or periarticular in location.¹³⁷ These atypical sites usually do not provoke reactive bone formation around the nidus. Calcification in the central portion of the nidus may be evident on radiographs.

Other radiologic studies may be needed to make a correct diagnosis if the typical radiographic findings are not present or if the lesion is in an atypical location and lacks the associated reactive sclerosis. Technetium-99 bone scan is useful if osteoid osteoma is suspected but the lesion is not clearly demonstrated on plain radiographs. Technetium-99 bone scan nearly always demonstrates an intense focal increase in uptake of the technetium in the nidus and is of considerable value in evaluating the spine, pelvis, and long bones.^{77,228}

Once the general area of the lesion has been localized with bone scan, cross-sectional imaging with CT will best demonstrate the well-circumscribed area representing the nidus (Fig. 37–31). Thin sections (1.0 to 2.0 mm) may be needed for optimal detail.

MRI will demonstrate the soft tissue and bone marrow edema that accompanies osteoid osteomas.³¹⁴ However, MRI is rarely needed because CT both better demonstrates the nidus and aids in differentiating between the nidus and reactive bone.

NATURAL HISTORY

Osteoid osteomas are described as self-limiting lesions that may mature spontaneously over the course of several years.

The nidus will gradually calcify, then ossify, and finally blend into the sclerotic surrounding bone. During the maturation period, the local pain gradually diminishes. Knowing this, some clinicians advocate conservative management of osteoid osteomas, with NSAIDs or aspirin recommended for those patients choosing not to undergo operative intervention. In reality, though, very few patients are willing to continue with conservative management because of the intensity of the pain and the favorable outcomes likely with surgery.

DIFFERENTIAL DIAGNOSIS

The differential diagnosis includes subacute osteomyelitis and osteoblastoma. On radiographs, a quiescent bone abscess may appear very similar to osteoid osteoma.¹⁷⁸ Laboratory studies further assist in distinguishing between the two entities. Local aspiration of subacute osteomyelitis will confirm the diagnosis.

Osteoid osteomas are generally differentiated from osteoblastomas by size (osteoblastomas are larger, usually exceeding 2 cm in diameter), degree of sclerosis (osteoid osteomas, in general, have a greater degree of surrounding dense bone), and natural history (osteoblastomas can be more aggressive).

TREATMENT

Salicylate and NSAIDs are effective in relieving symptoms of pain associated with osteoid osteoma. If the symptoms are moderate and controlled by this treatment program, observation alone is sufficient. The possibility of spontaneous improvement over the course of several years may make medical management feasible for some patients. However, it is not possible on an individual basis to conclusively determine the ultimate outcome with medical management. Most families understand this and elect a surgical approach to this benign lesion.

The purpose of surgery is to eradicate the pain-producing nidus. Surgical excision has proved extremely effective in accomplishing this goal.⁹⁵ More recently, less invasive maneuvers utilizing pinpoint CT-guided localization have become popular. With either approach, once the nidus is removed, the surrounding sclerotic bone will usually remodel. Relief from the pain is immediate, dramatic, and permanent unless the nidus has been incompletely excised. Patients often remark that the incisional pain is far different from the pain of the osteoid osteoma itself.

Accurate intraoperative localization of the nidus is crucial for the success of surgical intervention. Radiography, CT, tetracycline labeling, and bone scintigraphy have all been used for this purpose. Conventional intraoperative radiographs of the excised specimen may help confirm the presence of the nidus. CT-guided exploration, performed under anesthesia in the radiology suite, is helpful in localizing the nidus itself but will be inconclusive regarding the excision of the nidus.¹⁷⁰ Tetracycline labeling can be used in children more than 8 years old.²¹ The risk of permanent staining of the dentin may preclude use of this technique in younger children.¹¹⁸ A dental consultation may be useful in determining the maturity of the teeth if the use of tetracycline is considered in younger children. Tetracycline, which is avidly taken up by the nidus, is administered orally 1 to 2 days

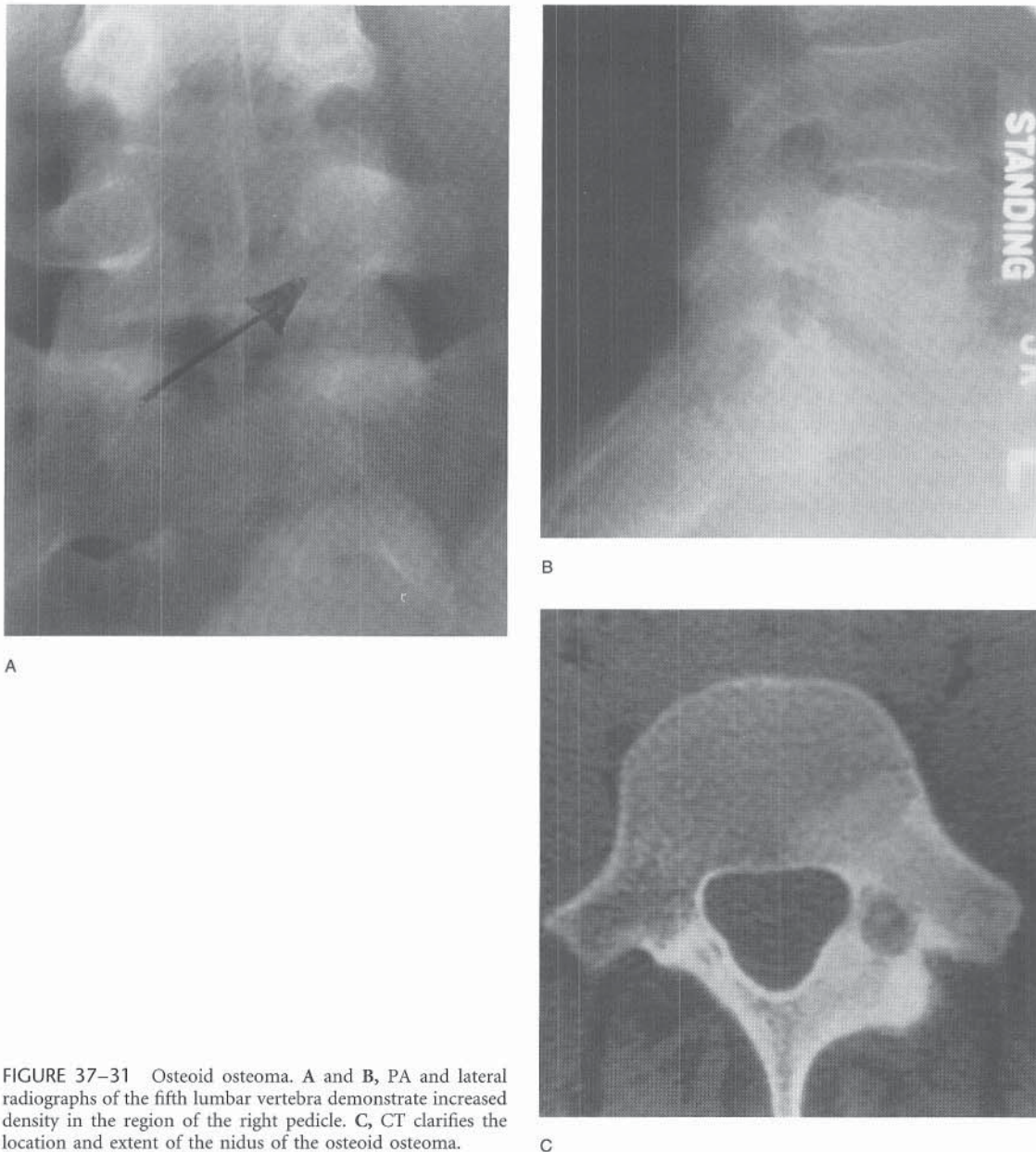


FIGURE 37-31 Osteoid osteoma. A and B, PA and lateral radiographs of the fifth lumbar vertebra demonstrate increased density in the region of the right pedicle. C, CT clarifies the location and extent of the nidus of the osteoid osteoma.

preoperatively. Tetracycline fluoresces under ultraviolet light, thus providing an intraoperative method of determining whether the nidus has been removed. With the operating room lights dimmed and a Wood's lamp emitting the ultraviolet light, the nidus can be readily identified in the resected portion.

In a similar fashion, radioactive isotope can be used intraoperatively to assist in identifying the osteoid osteoma.¹⁰⁵ The isotope is administered preoperatively and a scintillation probe is used intraoperatively to detect the increased counts per minute in the area of the lesion. However, few centers use this method because of the expense involved and the sometimes equivocal results. We have no experience with this technique.

The two most common surgical methods for removing the nidus are en bloc resection and the bur-down technique.¹⁰⁷ En bloc resection is performed by placing drill bits around the lesion and confirming their placement with

fluoroscopy in the operating room. The lesion is then removed en bloc with the margin of reactive bone. This requires a larger resection of bone than the bur-down technique, and therefore either bone grafting or internal fixation may be necessary. With the bur-down technique, the sclerotic reactive bone is burred until the nidus is visible. The nidus is then curetted and the specimen is sent to pathology. The cavity of the lesion is then thoroughly burred. This technique has even been applied arthroscopically in the talus.²⁸⁴ The advantages of this procedure over en bloc resection include removal of less reactive bone (thus reducing the need for bone grafting) and a decrease in the risk of a postoperative pathologic fracture.

Newer techniques are showing favorable results. These include CT-guided percutaneous excision using a trephine and CT-guided percutaneous radiofrequency coagulation.*

*See references 80, 156, 192, 213, 231–233, 280.

A radiofrequency probe is placed in the center of the lesion and a 1-cm area around the bone is heated to destroy the nidus itself. Reports by those who have used this technique indicate its results are equivalent to those obtained with surgical excision. Its advantages include the fact that it is an outpatient procedure, there is a lower risk of pathologic fracture, and convalescence is rapid.

Osteoblastoma

Osteoblastomas have a histologic pattern very similar to that of osteoid osteomas, but they are usually much larger (2 to 10 cm). They are one-fifth as common as osteoid osteomas and represent approximately 0.5 percent of biopsied primary tumors.¹⁸⁵ Most osteoblastomas occur in persons ages 10 to 25 years, with the peak incidence noted at around 20 years.¹⁶⁸ More than 80 percent of patients are younger than 30 years at the time of diagnosis. Affected males outnumber females by a ratio of 2:1.

PATHOLOGY

On gross pathology, osteoblastomas vary in size from 2 to 10 cm. At surgery, an osteoblastoma is found to consist of hemorrhagic, granular, friable, and calcified tissue.⁴⁰ The lesions are gritty on palpation, usually deep red to reddish brown or pink (reflecting their vascularity), and, if removed intact, often well circumscribed and surrounded by a shell of cortical bone or thickened periosteum.

Histologically, osteoblastomas are identical to osteoid osteomas, consisting of vascular spindle-cell stroma with abundant irregular spicules of mineralized bone and osteoid.⁷³

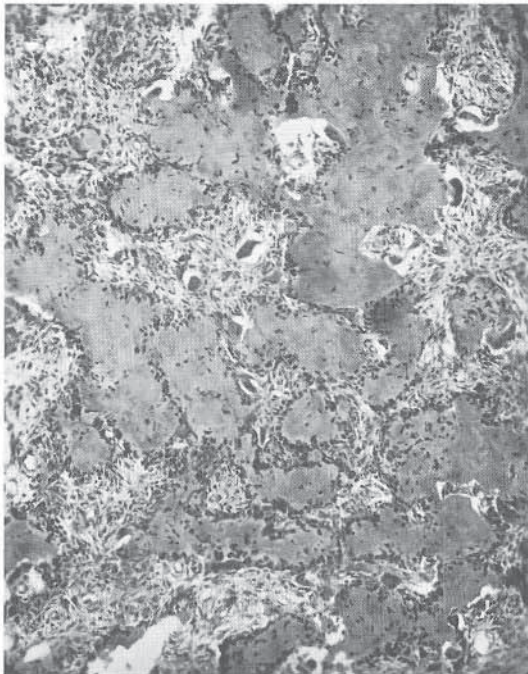


FIGURE 37–32 Benign osteoblastoma, histologic appearance. Note the highly vascularized connective tissue matrix and the trabeculae of osteoid and new bone, with layers of osteoblasts lined against them.

Osteoblasts and osteoclasts are readily evident on the edges of the bone spicules (Fig. 37–32). Cartilage is distinctly absent. Because of their similar histologic pattern, osteoblastomas have sometimes been referred to as giant osteoid osteomas.

Occasional osteoblastomas appear aggressive on radiographs, with bone destruction and extension into soft tissues (Fig. 37–33).^{23,168} Microscopically, these infrequent lesions may reveal notable cellular atypia with large plump osteoblasts, making it difficult to differentiate an aggressive osteoblastoma from a low-grade osteosarcoma histologically. Osteoblastomas do not metastasize.⁴⁰

CLINICAL FEATURES

Unlike osteoid osteomas, approximately 30 to 40 percent of osteoblastomas are found in the spine, where they most often affect the posterior elements, including the spinous and transverse processes, lamina, and pedicles.* Osteoblastomas exceed several centimeters in size, and spinal lesions may extend into the vertebral body. On occasion, the lesion appears to originate from within the vertebral body. All areas of the spine may be involved, from the upper cervical region to the sacrum.²⁴³ The clinical presentation may include myelopathic or radicular symptoms.²⁰⁷ Progressive painful scoliosis may develop. If the cervical spine is affected, torticollis may be evident.

Other common sites include the long bones, especially the femur and tibia. In the long bones, the osteoblastoma involves the metaphyseal or diaphyseal region. The lesions are centered in the medullary portions of the shaft, unlike osteoid osteomas, which tend to be located within the cortex or subperiosteally.^{151,185} Less often the mandible, foot, calvarium, pelvis, scapula, patella, ribs, clavicle, or hands may be affected. In these nonvertebral locations, pain is usually the prominent complaint. Symptoms may be present for a few months to a year. The pain is less localized than the pain of osteoid osteomas and much less likely to be relieved by salicylates.

Because osteoblastomas are several centimeters in size, physical examination may reveal a palpable mass. Tenderness over the area of the tumor is the most consistent physical finding. If the lesion is located near a joint, there may be some loss of joint motion.

RADIOGRAPHIC FINDINGS

Osteoblastomas usually result in a uniform fusiform expansion of the bone. The borders of the lesion are well delineated from the surrounding host bone, and often there is a thin rim of reactive intramedullary bone sclerosis.¹⁵¹ Most lesions are 3 to 6 cm in size, although the range is 2 to 10 cm. The reactive bone formation is noticeably less intense and the margins are less defined than those of osteoid osteomas. Although most lesions are metaphyseal or diaphyseal in location, epiphyseal lesions may be seen in the long bones of the hand or foot. The center of the lesion varies: it may be lucent, mixed lucent and blastic, or predominantly blastic.

In the spine, the posterior elements are predominantly affected. Cortical expansion is common and is similar to

*See references 35, 40, 95, 168, 187, 236, 253.

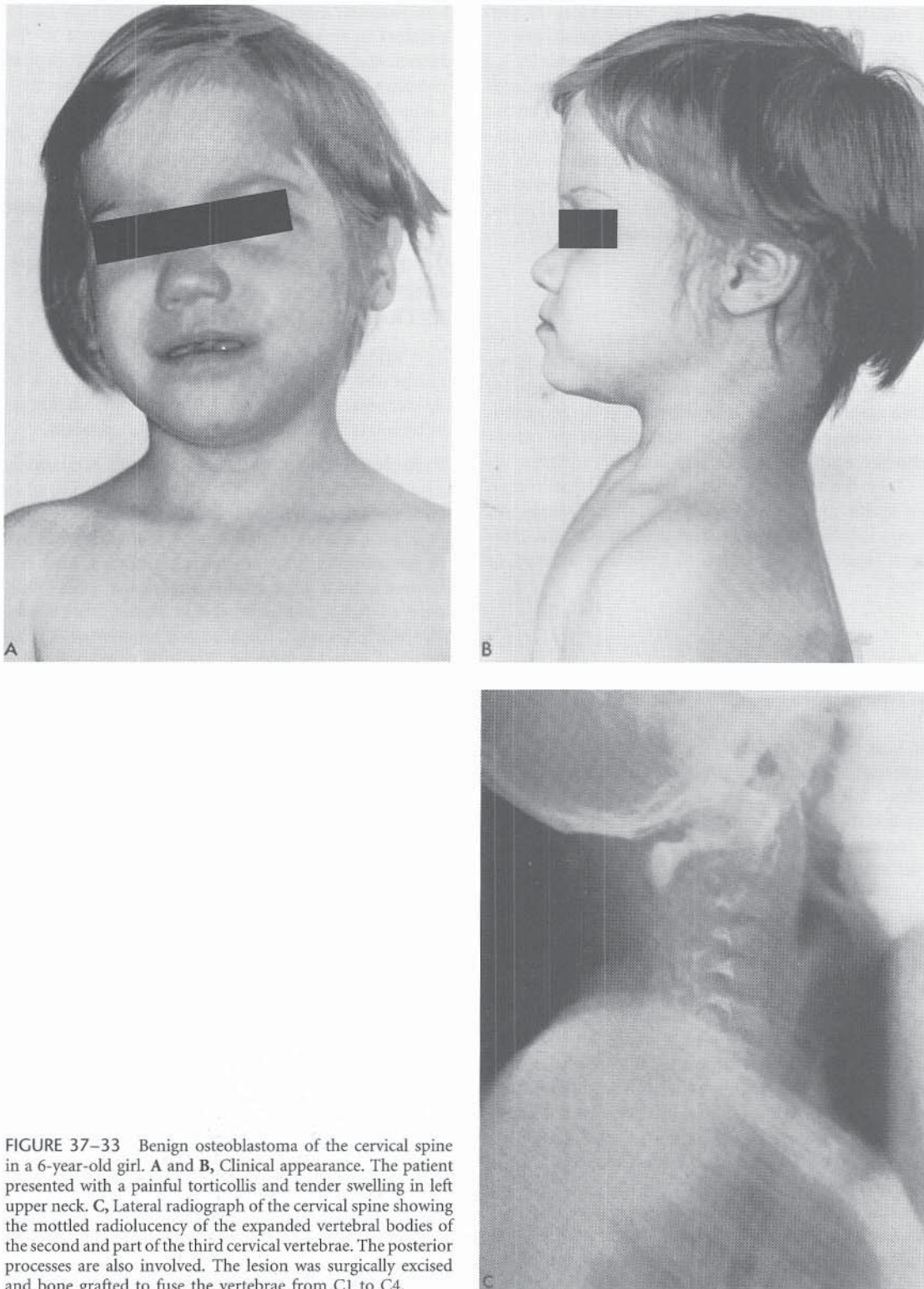


FIGURE 37-33 Benign osteoblastoma of the cervical spine in a 6-year-old girl. **A** and **B**, Clinical appearance. The patient presented with a painful torticollis and tender swelling in left upper neck. **C**, Lateral radiograph of the cervical spine showing the mottled radiolucency of the expanded vertebral bodies of the second and part of the third cervical vertebrae. The posterior processes are also involved. The lesion was surgically excised and bone grafted to fuse the vertebrae from C1 to C4.

that seen with aneurysmal bone cysts. Osteoblastomas, however, are usually more radiodense than aneurysmal bone cysts.

Because of the size of the lesion, osteoblastomas can usually be seen on plain radiographs. CT better delineates the extent of involvement, particularly with vertebral lesions. Radionuclide bone scintigraphy may be helpful in localizing

smaller osteoblastomas that are not readily apparent on plain radiographs.

DIFFERENTIAL DIAGNOSIS

Expansile osteoblastomas may be difficult to differentiate radiographically from aneurysmal bone cysts. Clarification,

however, is usually obtained with CT. Differences in the size and location of the lesions usually distinguish osteoblastomas from osteoid osteomas.

Up to 10 percent of low-grade osteosarcomas may have radiographic features that suggest osteoblastoma. As mentioned, an aggressive osteoblastoma may be difficult to differentiate histologically from a low-grade osteosarcoma. In a benign osteoblastoma, however, there is an absence of sarcomatous large, plump connective tissue stromal cells, sarcoma giant cells, and tumor cartilage and bone.

TREATMENT

Treatment consists of curettage or local excision. The risk of recurrence after such treatment is approximately 10 to 20 percent. If a spinal osteoblastoma impinges on the spinal cord or nerve roots, surgical decompression is required. Unlike osteoid osteoma, soft tissue extension of an osteoblastoma into the epidural space may become adherent to the dura.²²⁴ Once the tumor is excised, internal fixation of the unstable spine and bone grafting may be necessary. Osteoblastomas located in sites inaccessible to surgical excision have been reported to respond to radiation therapy or chemotherapy.⁴¹

Histiocytosis X (Langerhans' Cell Histiocytosis)

Histiocytosis X, a term introduced by Lichtenstein in 1953, is a syndrome that consists of a group of clinical pathologic entities: eosinophilic granuloma of bone, Hand-Schüller-Christian disease, and Letterer-Siwe disease.¹⁶¹ Because these entities are the result of proliferation and dissemination of pathologic histiocyte cells or Langerhans'-like cells, the term *Langerhans' cell histiocytosis* was introduced as an alternative to histiocytosis X by Nezelof and associates in 1973.¹⁹⁶

The disseminated forms of the disease (Hand-Schüller-Christian disease and Letterer-Siwe disease) were reported prior to our understanding of the pathologic entity of eosinophilic granuloma of bone.²⁸⁸ Alfred Hand, in 1893, Arthur Schüller, in 1915, and Henry Christian, in 1920, independently described the complex of polyuria, exophthalmos, and defects found in membranous bones. Their descriptions were combined to form what is currently known as Hand-Schüller-Christian disease. Erich Letterer in 1924 and Sture Siwe in 1933 described a generalized disease process with multisystem involvement, including bone. Present in younger children, Letterer-Siwe disease has a poor prognosis. The term *eosinophilic granuloma* was introduced in 1940 and was used to describe solitary bone destruction by large histiocytic cells intermingled with eosinophilic leukocytes.^{162,203} Approximately 80 percent of cases of histiocytosis X are solitary eosinophilic granulomas, 6 percent are multiple eosinophilic granulomas, 9 percent are Hand-Schüller-Christian disease, and 1.2 percent are Letterer-Siwe disease.¹⁰⁷

The etiology of histiocytosis X is poorly understood.²⁷⁶ There is speculation that immunologic stimulation of a normal presenting cell, the Langerhans' cell, continues in an uncontrolled manner, resulting in these cells' proliferation and accumulation. This may not truly represent a neoplasm

but, instead, a proliferative lesion that may be secondary to a defect in immunoregulation. In contrast to this theory, a recent study reported that histiocytosis X is probably a clonal neoplastic disorder with highly variable biologic behavior.²⁹⁸ Langerhans' histiocyte is the cell of origin for this spectrum of the disease. There is no hereditary pattern described.

Langerhans' cell histiocytosis can present at any age, from birth to old age. The incidence in children has been estimated at three to four per million, with a 2:1 male-female ratio.

EOSINOPHILIC GRANULOMA: SOLITARY AND MULTIPLE WITHOUT EXTRASKELETAL INVOLVEMENT

The mildest, most favorable form of histiocytosis X is an eosinophilic granuloma that is confined to a single bone, or occasionally to several bones, without extraskeletal involvement.¹⁸⁵ The lesion is a benign process.

Pathology. Eosinophilic granulomas are usually soft, reddish brown material. They often show areas of hemorrhage and, occasionally, cysts.

Histologically the tissue is characterized by a mixture of eosinophils, plasma cells, histiocytes, and peculiar large mononuclear giant cells (Langerhans' cells) with abundant pale-staining cytoplasm and indented or cleaved nuclei (Fig. 37-34).⁴⁰ Necrosis, fibrosis, and reactive cells (foamy macrophages) may be evident. There is minimal mitotic activity. The lesions may consist primarily of the histiocytic infiltrates or there may be a mixture of histiocytes and eosinophils.

Electron microscopy can be used to confirm the diagnosis; the specific pathologic finding is the presence of Birbeck granules in the cell cytoplasm near the nucleus. These granules are rod-shaped structures characterized by central striation and a vesicular expansion resembling the strings of a tennis racket. The origin and function of Birbeck granules are still uncertain;²⁸⁸ however, when present, these structures are pathognomonic of *Langerhans' cell histiocytosis*.

Clinical Features. About two-thirds of cases are diagnosed in individuals less than 20 years old, with most diagnoses made in the 5- to 10-year-old age group. The first symptom is localizing pain, occasionally accompanied by swelling and low-grade fever. The sedimentation rate may be elevated.

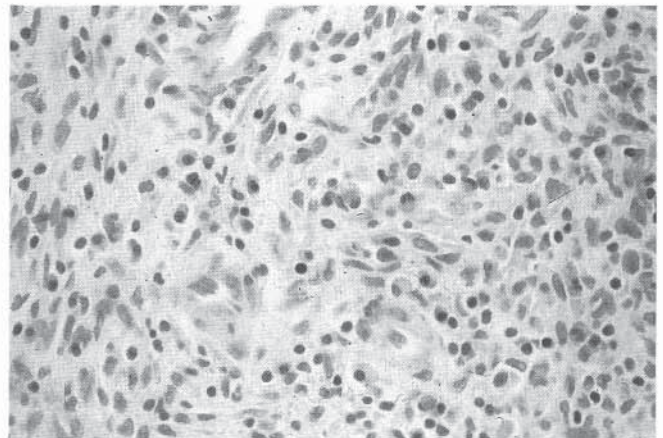
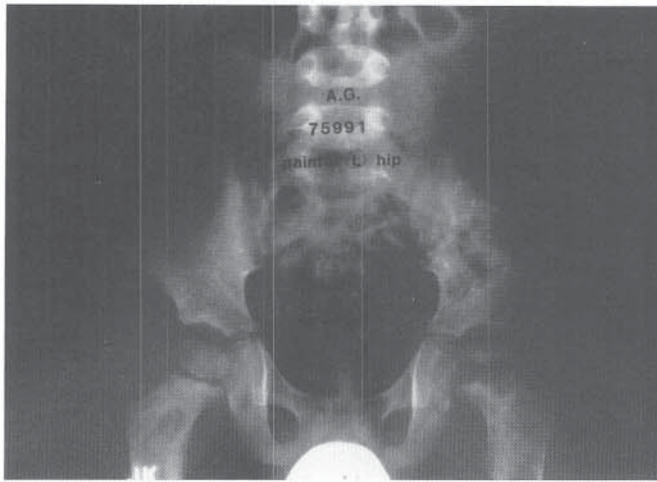
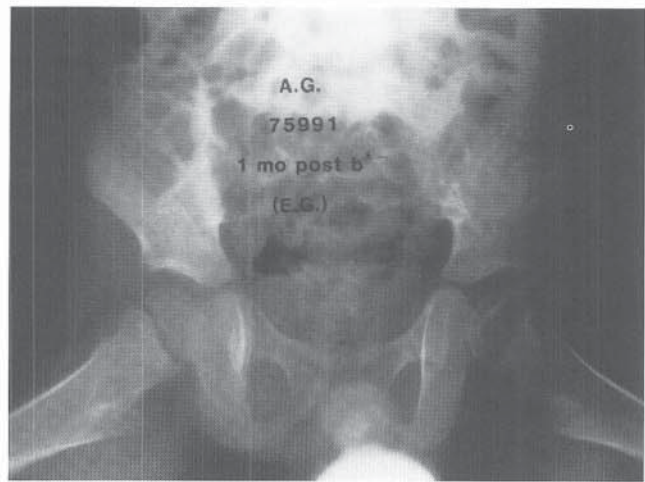


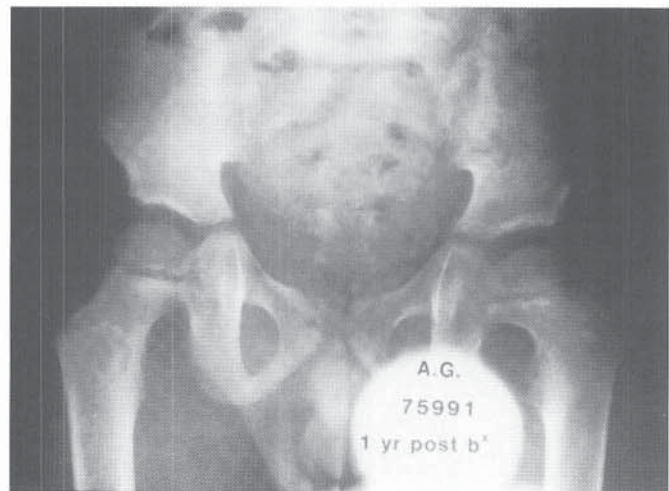
FIGURE 37-34 Eosinophilic granuloma ($\times 40$). The histologic picture is characterized by a mixture of eosinophils, histiocytes, and Langerhans' cells (large mononuclear giant cells with pale-staining cytoplasm).



A



B



C

FIGURE 37–35 Eosinophilic granuloma. A and B, Radiographs of a 4-year-old boy showing lucencies involving the proximal right femoral metaphysis, left femoral periphyseal region, and left iliac bone. Biopsy confirmed the diagnosis of eosinophilic granuloma. C, One year later, the multiple lesions had healed.

The skull is the most common site of involvement, followed by the femur. About 40 percent of solitary eosinophilic granulomas are found at one of these two sites. In the case of multiple lesions, the skull and femur again are most commonly affected. Other sites of involvement include the pelvis, ribs, and spine. The tarsal and carpal bones are rarely affected. In the long bones, the lesions are usually intramedullary and most commonly located in the diaphysis.

Radiographic Findings. A rapidly destructive lytic process occurs in the bone, producing a “punched-out” appearance on radiographs. In the early phases the lesion may be poorly delineated, show a “moth-eaten” pattern of destruction, and exhibit erosions of the cortices. The periosteum may be stimulated, showing some periosteal elevation.^{91,185} It is in this phase that the condition most closely mimics osteomyelitis or Ewing’s sarcoma. Later the borders of the lesion become sharp and the contours become round or oval. During the early radiographic phase of the solitary lesion, a biopsy is often necessary to rule out a malignant process (Fig. 37–35). In the skull, the lesion is oval or round, with several satellite lesions sometimes present, making this particular radiographic appearance almost pathognomonic for

eosinophilic granuloma. Periosteal new bone formation usually does not occur in the flat bones of the skull or pelvis. Marginal sclerosis during healing can be secondary to treatment or can occur spontaneously.

Another nearly pathognomonic sign of eosinophilic granuloma is the presence of *vertebra plana* in the spine (Fig. 37–36). This occurs with insidious collapse of the vertebral body, which is eventually compressed into a thin wafer.²⁸⁹ The patient’s neurologic status usually remains intact, although spinal cord or nerve root compression may occur on rare occasions as a result of severe vertebral body destruction.^{142,274} With healing, a variable degree of vertebral height is restored in these spinal lesions.

Approximately 10 percent of patients who initially present with a solitary eosinophilic granuloma develop multifocal lesions with extraskeletal involvement (Hand-Schüller-Christian disease). Nearly any bone other than those in the hands and feet may be affected. Chest radiographs should always be obtained to rule out pulmonary involvement.

CT is used to delineate the extent of the lytic lesions, particularly in the pelvis, spine, and skull. MRI is superior to both radiography and CT in delineating the medullary

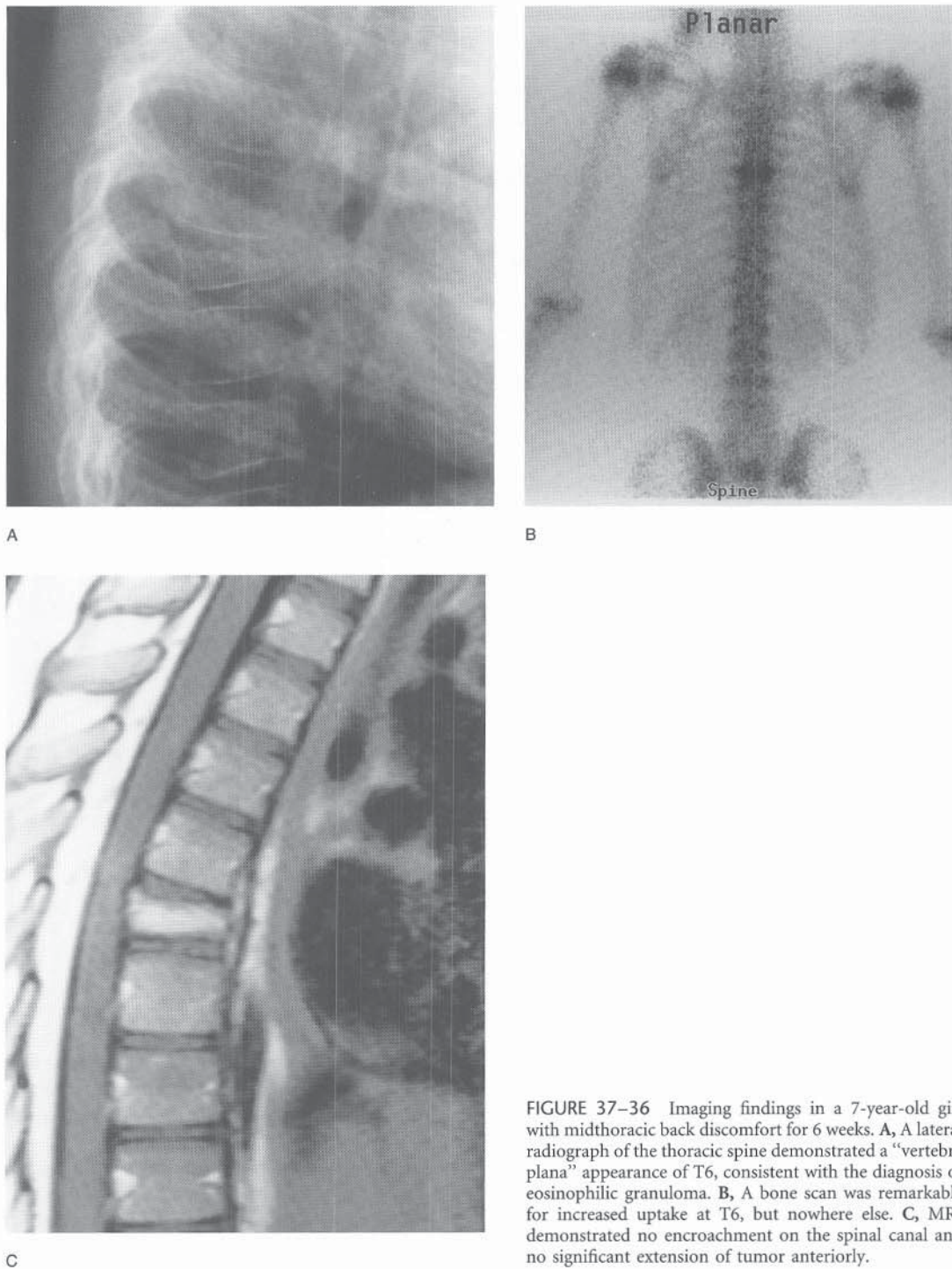


FIGURE 37-36 Imaging findings in a 7-year-old girl with midthoracic back discomfort for 6 weeks. **A**, A lateral radiograph of the thoracic spine demonstrated a “vertebra plana” appearance of T6, consistent with the diagnosis of eosinophilic granuloma. **B**, A bone scan was remarkable for increased uptake at T6, but nowhere else. **C**, MRI demonstrated no encroachment on the spinal canal and no significant extension of tumor anteriorly.

extent of eosinophilic granulomas and surrounding soft tissue changes (Fig. 37-37).^{24,71,79,188} The degree of peritumoral edema accompanying an eosinophilic granuloma is less extensive than that seen with Ewing’s sarcoma or osteomyelitis.

Radionuclide bone scintigraphy does not consistently demonstrate eosinophilic granulomas. The scans may be completely normal in patients with radiographic evidence of extensive bone involvement. A plain radiographic skeletal survey is superior to scintigraphy for the diagnosis of multiple lesions.

Differential Diagnosis. The differential diagnosis includes osteomyelitis, Ewing’s sarcoma, malignant lymphoma, metastatic disease, and, in the long bones, aneurysmal bone cyst and solitary bone cyst. Unless pathognomonic findings, such as multiple skull lucencies or vertebra plana, are found on radiographic evaluation, biopsy is needed to differentiate the more serious lesions. Fine-needle aspiration yields sufficient material to confirm the diagnosis.^{6,83} In osteomyelitis, the fine-needle aspirate will contain pus, neutrophils, or organisms. Another benign musculoskeletal tumor, nonossifying

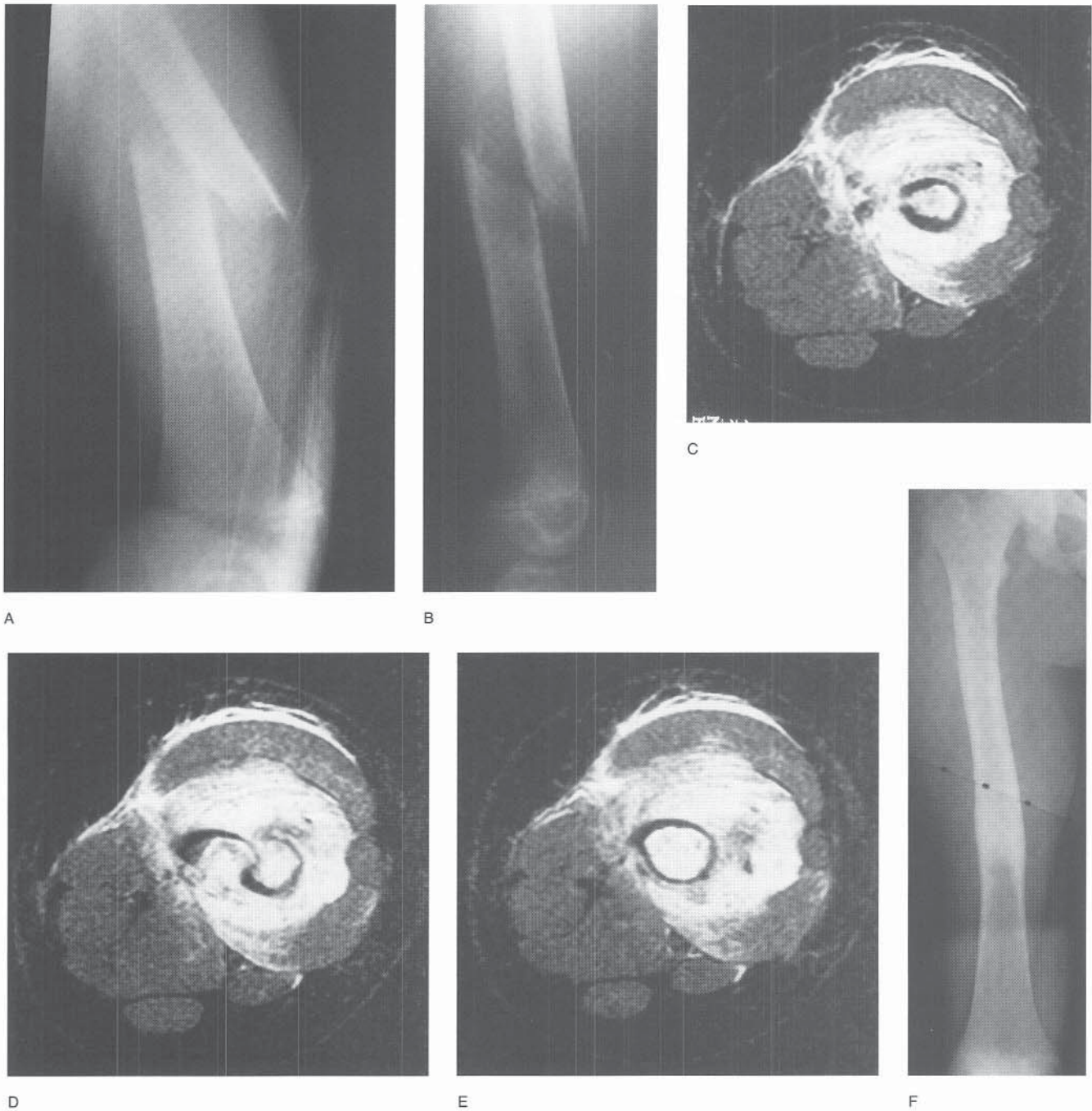


FIGURE 37-37 A and B, AP and lateral radiographs demonstrating a displaced pathologic diaphyseal femur fracture through a lucent lesion in a teenage boy. C to E, MRI showed diffuse soft tissue and intramedullary changes near the fracture site. F, Eighteen months later the fracture and the eosinophilic granuloma had healed.

fibroma, may also resemble the late healing phase of eosinophilic granuloma. Unlike nonossifying fibromas, though, eosinophilic granulomas usually are diaphyseal and are not distinctly eccentric.

Treatment. Patients with solitary eosinophilic granulomas generally have a benign clinical course. They have a good chance of spontaneous remission and a favorable outcome over a period of months to years. The single bony lesion usually does not require treatment other than a biopsy to

confirm the diagnosis.³² At that time, curettage may be performed.²⁴⁶ Curettage may require augmentation with bone grafting when performed on lesions in weightbearing bones of the lower extremities that are at risk for spontaneous fracture or on lesions where curettage alone could result in unacceptable deformity. If vertebral plana is identified but the associated back discomfort has resolved, observation alone is sufficient.⁹²

Intralesional infiltration with steroids has been reported to be safe and effective.²⁷⁶ Although this is a minimally

invasive procedure, injections are not needed if the diagnosis is clear.

Lesions can occur in areas where they threaten neurologic function (e.g., the spinal cord or optic nerve) and where local steroid infiltration or surgical resection may not be possible. In these cases, treatment with low-dose radiation may be a good alternative.^{175,237} The use of radiation therapy to manage localized bone lesions has decreased considerably, however, because of the favorable natural history (spontaneous remission) and the risk (though low) of developing a secondary malignancy. Chemotherapy has been used with some success in cases of diffuse eosinophilic granuloma and in patients with systemic disease and multiple organ involvement (Letterer-Siwe disease).²⁸⁸

HAND-SCHÜLLER-CHRISTIAN DISEASE: MULTIFOCAL EOSINOPHILIC GRANULOMA WITH EXTRASKELETAL INVOLVEMENT (CHRONIC DISSEMINATED TYPE)

The classic description of Hand-Schüller-Christian disease includes multiple eosinophilic granulomas involving bone, diabetes insipidus (due to pituitary gland involvement), and exophthalmos (due to the presence of retro-orbital granulomas). This term is now used to include instances of more chronic evolution, even without the classic findings, that generally occur in children more than 3 years old with involvement of other systems. In fact, the triad of calvarial defects, exophthalmos, and diabetes insipidus is present in only 10 percent of cases.^{185,276} More than 70 percent of patients with Hand-Schüller-Christian disease are diagnosed before age 5 years. In addition to the features just mentioned, fever, hepatosplenomegaly, lymphadenopathy, anemia, and abnormal liver chemistries may be evident. In contrast to solitary eosinophilic granulomas, the bones of the hands and feet may also be affected in Hand-Schüller-Christian disease. Pathologic fractures may occur, particularly in the spine.

In the early phases of the disease, the histologic picture is similar to that of a solitary eosinophilic granuloma. The later phases are characterized by a greater proportion of lipid-laden macrophages and scarring. Significant morbidity is associated with this disorder.

Treatment consists of a combination of low-dose irradiation and corticosteroids. Surgical curettage is occasionally indicated. Chemotherapy, consisting of a combination of prednisolone and then vinblastine, has been used primarily in cases with evidence of fever, pain, severe involvement of the skin, failure to thrive, or dysfunction of vital organs.

LETTERER-SIWE DISEASE: MULTIFOCAL EOSINOPHILIC GRANULOMA (ACUTE DISSEMINATED OR INFANTILE FORM)

This acute, disseminated, progressive form of histiocytosis is rare. Characteristically it occurs during the first year of life. All patients are identified before age 2 years. Visceral involvement is diffuse and severe. The patient may present with fever and debilitating infection secondary to marrow failure. Hepatosplenomegaly, lymphadenopathy, papular rash, bleeding diathesis, anemia, and occasionally exophthal-

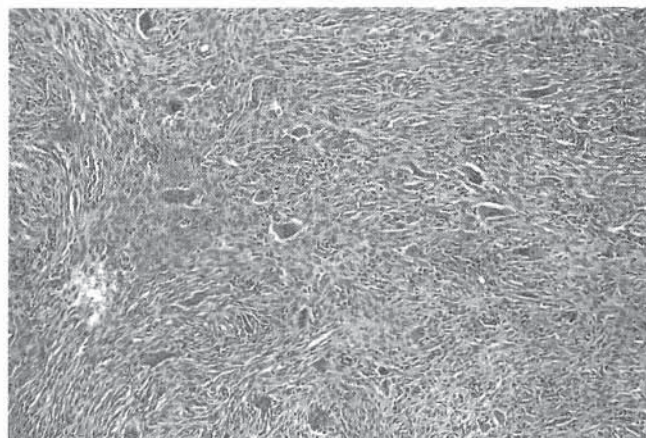


FIGURE 37-38 Nonossifying fibroma ($\times 10$). The two basic components are fibroblastic tissue and osteoclast-like giant cells.

mos and diabetes insipidus may be present. The pulmonary parenchyma may have a granular appearance on chest radiographs. The destructive "punched-out" lesions of the bones, although not a major source of complaints, are identifiable on radiographs.

In the past, Letterer-Siwe disease was considered to be invariably progressive and fatal, with death caused by marrow failure, asphyxia, or septicemia. Today, appropriate treatment with chemotherapy, steroids, and high-dose antibiotics may lead to survival.

Nonossifying Fibroma and Fibrous Cortical Defect

Fibrous defects in bone are common lesions in childhood. They are found in the metaphyseal regions of the long bones, particularly the femur and the tibia. Often they are cortical in location, but they can also be found in the cancellous area of bone. In 1942, Jaffe and Lichtenstein reported that when biopsied, these lesions contained fibrous tissue.¹³⁰ They coined the terms *fibrous cortical defect* and *nonosteogenic (nonossifying) fibroma*. Other terms used to describe these fibrous lesions include fibrous metaphyseal defect and fibrous endosteal defects.

The histologic appearance of all of these lesions is similar. They differ in size and in radiographic appearance, which reflects the varying phases of the development of the same lesion.

PATHOLOGY

Surgical curettage usually reveals soft, friable, yellow or brown tissue. Hemosiderin pigment contributes to the brownish color. The tumor is usually surrounded by ridges of bone septa, which gives it the trabeculated radiographic appearance.

Histologically, the two basic components are fibroblastic tissue and osteoclast-like giant cells (Fig. 37-38). Foamy pale histiocytes, focal hemorrhage, and hemosiderin pigment may also be extensively present. These microscopic findings may cause some confusion with other lesions that contain giant cells, such as solid aneurysmal bone cysts.

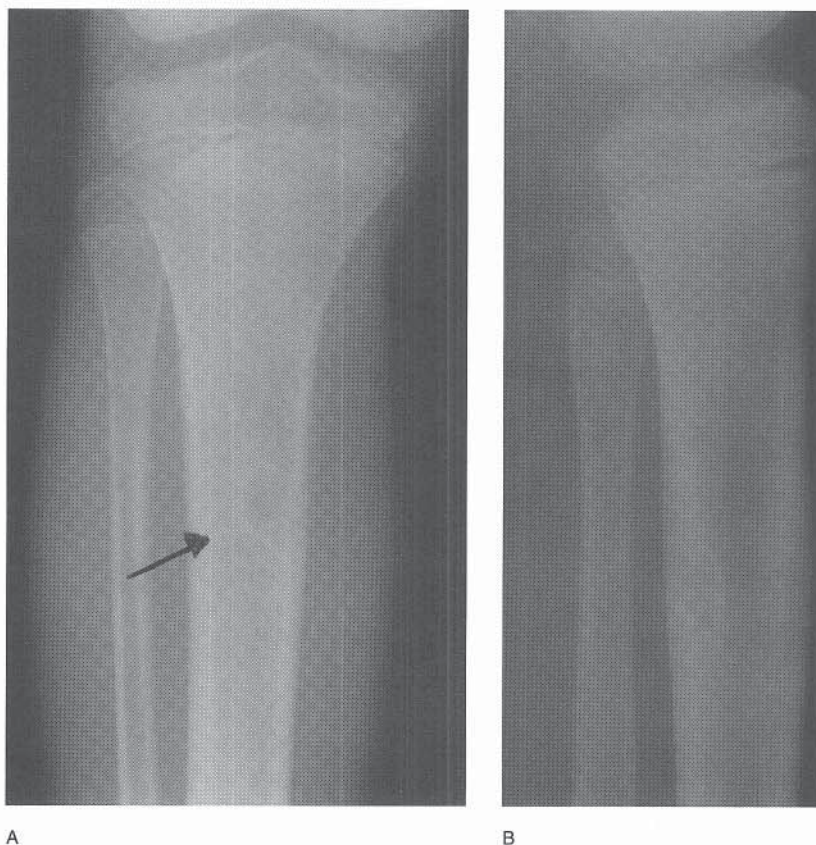


FIGURE 37-39 A and B, This classic-appearing non-ossifying fibroma is sharply delineated, radiolucent, eccentric, and outlined by a sclerotic border. It requires no treatment.

CLINICAL FEATURES

The term *fibrous cortical defect* refers to the small fibrous lesions that occur in young children. These fibrous lesions appear to be developmental defects due to a localized disturbance of bone growth and may not be representative of true neoplasms. Most fibrous cortical defects are eventually obliterated by reparative ossification or by gradual extrusion from the cortex during remodeling at the metaphyseal (growing) end of the bone. In a small percentage of cases, these fibrous cortical defects not only persist but increase in size, penetrate into the medullary canal, and may become symptomatic, producing a pathologic fracture. Jaffe and Lichtenstein considered this to be an evolutionary process by which fibrous cortical defects matured into nonossifying fibromas.¹³⁰

RADIOGRAPHIC FINDINGS

Both lesions are sharply delineated, radiolucent, multiloculated, eccentric, and outlined by a sclerotic border (Fig. 37-39).⁹⁷ They are usually metaphyseal in location, but on rare occasions they are found in the epiphyseal region. Nonossifying fibromas have greater extension into the medullary cavity.

The radiographic findings are usually so characteristic of fibrous cortical defect or nonossifying fibroma that further radiologic studies are unnecessary. For those lesions that appear painful but lack evidence of pathologic fracture, better clarification will be obtained with CT. Bone scans may show mild uptake in this isolated lesion and help in differ-

entiating it from other multifocal abnormalities, such as eosinophilic granuloma.

MRI is rarely needed. The MRI features of nonossifying fibroma include either hypo- or hyperintensity signals on T2-weighted images.^{17,133} Signal intensity on T1- and T2-weighted MR images and the patterns of contrast enhancement depend on the amounts of hypercellular fibrous tissue, hemosiderin, foamy histiocytes, and bone trabeculae.

DIFFERENTIAL DIAGNOSIS

Unicameral bone cysts radiographically resemble nonossifying fibromas more than any other lesions. Other similar benign bone tumors include aneurysmal bone cyst, chondromyxoid fibroma, and eosinophilic granuloma.

NATURAL HISTORY

The fibrous cortical defect usually appears near the physis and then migrates away during its growth. Usually the lesion regresses spontaneously, becoming smaller and less distinct and eventually disappearing. Occasionally the fibrous cortical defect proliferates and increases in size, extending into the endosteum or medullary cavity and involving a greater portion of the width of the bone. At this stage the diagnosis of nonossifying fibroma is made.

TREATMENT

Fibrous cortical defects do not require treatment. They usually regress over time. Larger, nonossifying fibromas may

lead to some discomfort and possible pathologic fractures.¹⁸ Even so, the majority of patients with nonossifying fibromas can be monitored without surgical intervention, and if fractures do occur, they can be successfully managed nonoperatively.^{82,121,174} Occasionally, discomfort or repeated fractures may require intralesional excision by curettage down to normal bone, with the defect filled with autogenous or allograft bone (Fig. 37–40). Local recurrence is rare with this type of treatment, and there is little to no risk of malignant degeneration.

Primary Synovial Chondromatosis

Synovial chondromatosis is characterized by the formation of metaplastic and multiple foci of cartilage in the intimal layer of the synovial membrane of a joint.^{72,276} The lesion also occurs in bursae and tendon sheaths.²⁷² The term *synovial osteochondromatosis* is used when the cartilage is ossified.

This benign neoplasm is very rare. It usually occurs in persons more than 40 years old but occasionally occurs in adolescents. It is twice as common in men as in women.

ETIOLOGY

The etiology of primary synovial chondromatosis is unknown, although cytogenetic findings strongly suggest that it is a clonal proliferation.¹⁸³ Trauma has been postulated as a possible stimulus of metaplasia of the synovial cells into chondrocytes.²⁶⁴

PATHOLOGY

Arthrotomy reveals the synovium to be thickened and studded with innumerable small, firm, flat or slightly raised, grayish white nodules. These cartilaginous or osteocartilaginous foci may become pedunculated and detached from the affected membrane, entering the joint cavity as loose bodies. Histologic studies disclose numerous foci of cartilaginous metaplasia of the synovium, which may be calcified or ossified (Fig. 37–41).

CLINICAL FEATURES

Clinical complaints consist of pain, swelling, and stiffness of the affected joint; joint locking may also be a symptom when there are loose bodies. Months or years may elapse before a patient seeks treatment. On examination the synovial membrane is noted to be thickened and the joint is limited in its range of motion. Other physical signs that can be elicited are crepitus and palpable loose bodies.

RADIOGRAPHIC FINDINGS

Radiographs reveal multiple areas of stippled calcification in and around the affected joint when the lesion is cartilaginous (Fig. 37–42). In such cases the findings are those of capsular distention and synovial thickening.

TREATMENT

Treatment consists of simple removal of the loose bodies and partial synovectomy, often performed arthroscopi-

cally.^{145,201,257} Extensive and complete synovectomy is impractical and usually not necessary. The condition has a definite tendency to resolve eventually. Malignant transformation into chondrosarcoma is unusual.^{140,308}

Pigmented Villonodular Synovitis and Giant-Cell Tumor of the Tendon Sheath

Pigmented villonodular synovitis (PVNS) is a benign lesion that develops in joint linings. Giant-cell tumor of the tendon sheath (histologically identical to PVNS) develops in the fibrous sheath of tendons.¹⁸⁵

PATHOLOGY

During arthroscopic or open synovectomy, the synovial membrane is found to be diffusely thickened and tan or brownish red in color. Sessile or pedunculated nodules may cover the surface of the synovium. The synovial texture may vary in firmness, depending on how much fibrous tissue is present.⁴⁰ Extensive hemosiderin deposition may be evident. In the tendon sheaths of the fingers, the lesion is usually solitary and well circumscribed.

Histologically, the villous nodular appearance of the synovium is characteristic, with tightly packed histiocytes filling the subsynovial tissue (Fig. 37–43). Some of the histiocytes are laden with hemosiderin. Multinucleated giant cells and lipid-laden macrophages are seen in varying numbers. There are few mononuclear cells, lymphocytes, or plasma cells. Histologically, PVNS is similar to the hemosiderotic synovitis that results from multiple episodes of bleeding into a joint, such as seen in hemophilia. Abundant production of collagen may be evident in patients with long-standing disease. Occasionally, cellularity of the lesion may produce a pseudo-sarcomatous appearance.

CLINICAL FEATURES

PVNS is locally aggressive and almost always monarticular. Most patients are young to middle-aged adults. The most common sites of involvement are the knee and the tenosynovial region in the hand and wrist.^{40,276} Other areas that may be affected include the foot, ankle, hip, and shoulder. Multifocal involvement, although rare, has been reported in children.^{136,287} In these patients, genitourinary and other congenital anomalies may be noted. Multiple sites are involved in less than 1 percent in reported series of PVNS. The disorder has a slight male predilection.

Patient complaints consist of localized pain and swelling of the affected joint. The proliferated synovial membrane may become caught between the articular ends of the bone, creating a locking within the joint. Range of motion may be limited. Joint aspiration yields a dark brown or serosanguineous fluid. In the absence of trauma to the joint, this finding is of diagnostic significance.

RADIOGRAPHIC FINDINGS

Radiographic findings that are highly suggestive of PVNS include soft tissue (synovial) swelling within the joint and

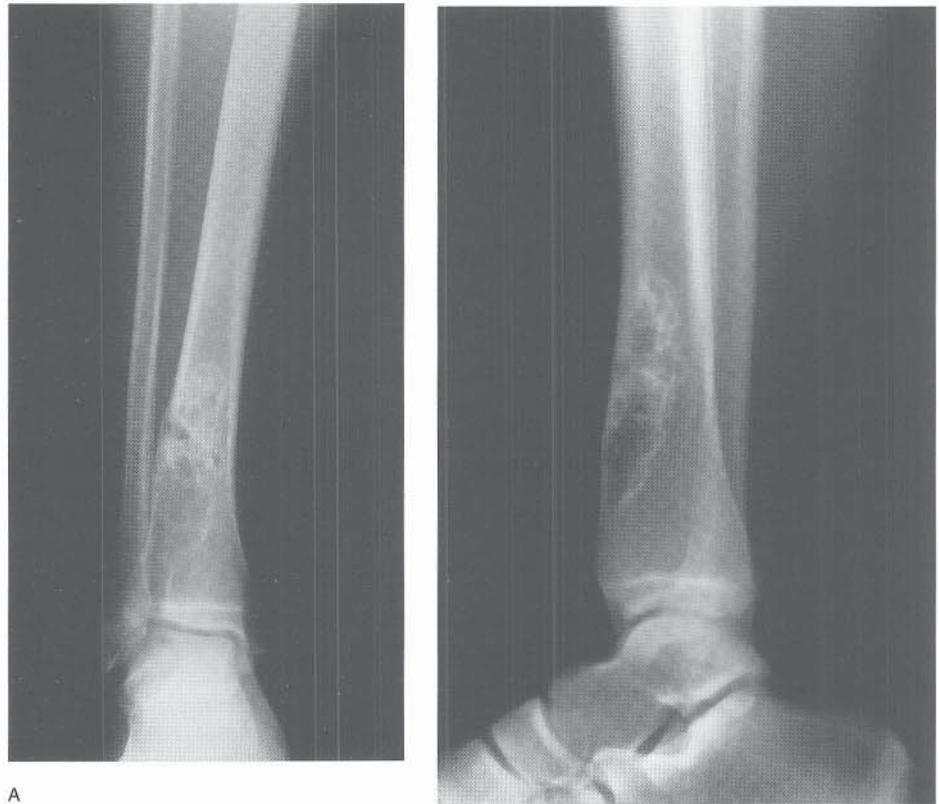
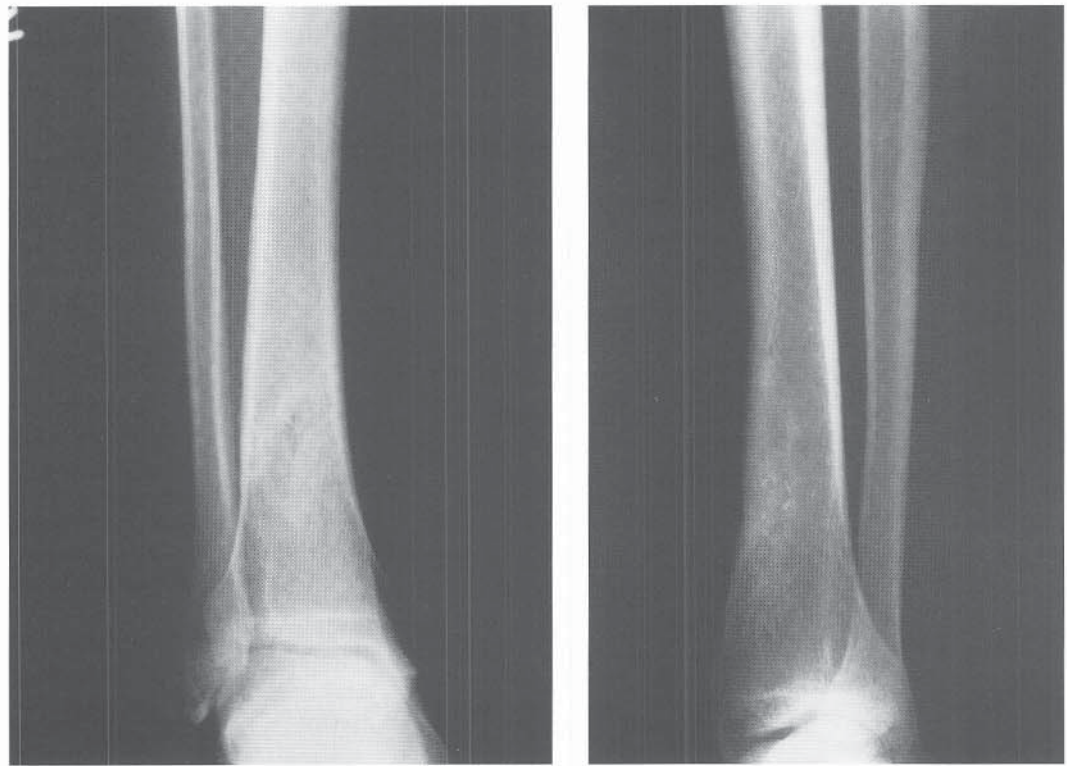


FIGURE 37-40 Imaging findings in a 15-year-old boy with persistent discomfort. A and B, Radiographs showed a persistent distal tibial nonossifying fibroma. C and D, Two years after curettage and bone grafting, the lesion had healed.



C

D

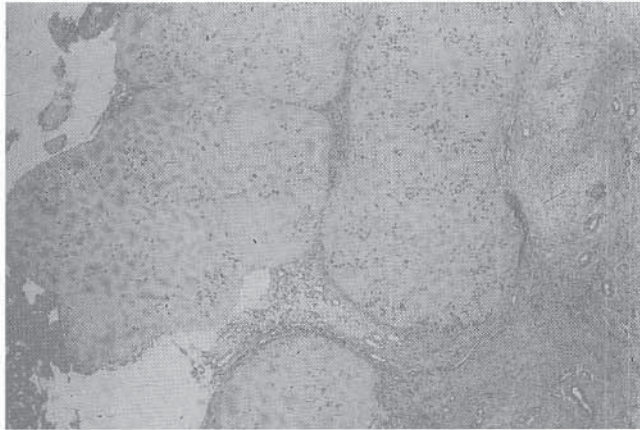


FIGURE 37-41 Synovial chondromatosis. Histologically, the lesion is composed of numerous foci of cartilaginous metaplasia, some of which may be ossified.

lucent areas involving the epiphyseal (and/or metaphyseal) ends of two continuous bones across a joint. These radiolucencies may have a border of benign sclerosis. The lytic bone lesions may appear very aggressive, particularly in the femoral head and acetabulum. CT will further clarify involvement on both sides of the joint. A marked narrowing of the joint may be present (Fig. 37-44).

MRI findings include scattered areas of low signal intensity that represent hemosiderin deposits in hypertrophied synovium on T2-weighted images and dotted areas of low signal intensity, presumably due to fibrous components of the lesion, on T1-weighted images.¹⁶

Following aspiration of the joint (dark brown or serosanguineous fluid is usually obtained), contrast arthrography will reveal multiple filling defects due to the abundant hypertrophic synovium.

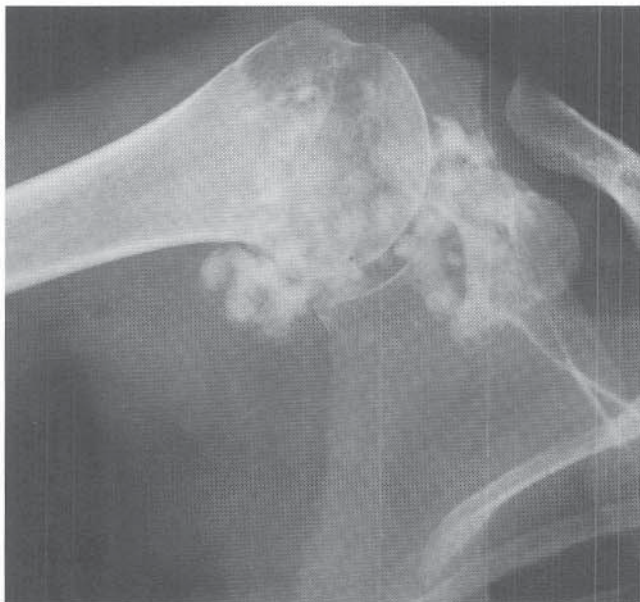


FIGURE 37-42 Synovial chondromatosis of the shoulder. Note the multiple areas of stippled calcification in and around the joint.

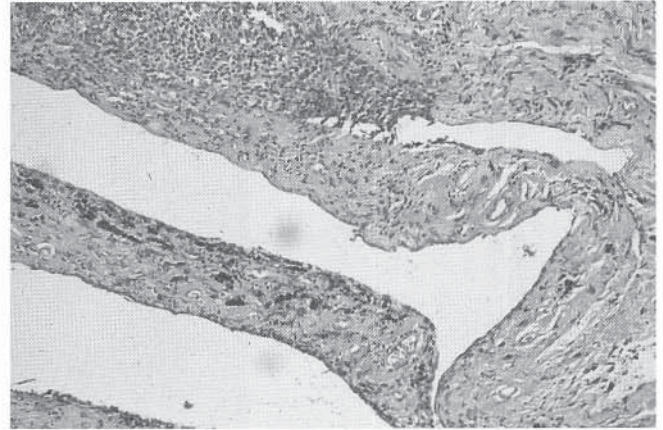


FIGURE 37-43 Pigmented villonodular synovitis ($\times 10$). The villous nodular appearance of the synovium is characteristic, with tightly packed histiocytes filling the subsynovial tissue.

DIFFERENTIAL DIAGNOSIS

Abnormalities that may affect both sides of a joint are most often considered in the differential diagnosis of PVNS. These abnormalities include chronic monarticular rheumatoid arthritis, synovial hemangiomas, low-grade infection, and, rarely, other inflammatory joint conditions such as tuberculosis. Hemophilia usually is readily diagnosed from its accompanying clinical symptoms, although the histologic findings are similar to those of PVNS.

TREATMENT

The treatment for PVNS consists of total synovectomy. In the knee, this is best performed arthroscopically. Recurrence of PVNS following synovectomy is common, and the patient and family should be made aware of this probability.²⁴⁴

Radiation therapy has been found useful in recurrent cases with extensive bone involvement and joint destruction in the adult patient.

Dysplasia Epiphysealis Hemimelica (Trevor's Disease)

Dysplasia epiphysealis hemimelica is a rare developmental disorder of epiphyseal osteocartilaginous growth in children, usually in the lower limbs. The lesion consists of osteocartilaginous tissue arising from the epiphysis and usually is hemimelic (either the lateral or the medial part of the ossification centers is involved). Although the incidence has been reported as one per million, it is likely higher than that.

Mouchet and Belot in 1926 first described this as a tarsal bone disorder and used the term *tarsomegalie*.¹⁹⁰ In 1950 Trevor used the term *tarso-epiphyseal aclasis*.²⁸¹ In 1956 Fairbank used the now common term *dysplasia epiphysealis hemimelica*.⁸⁷

ETIOLOGY

The etiology of dysplasia epiphysealis hemimelica is unknown.^{141,152,276} There is no strong evidence to suggest a he-

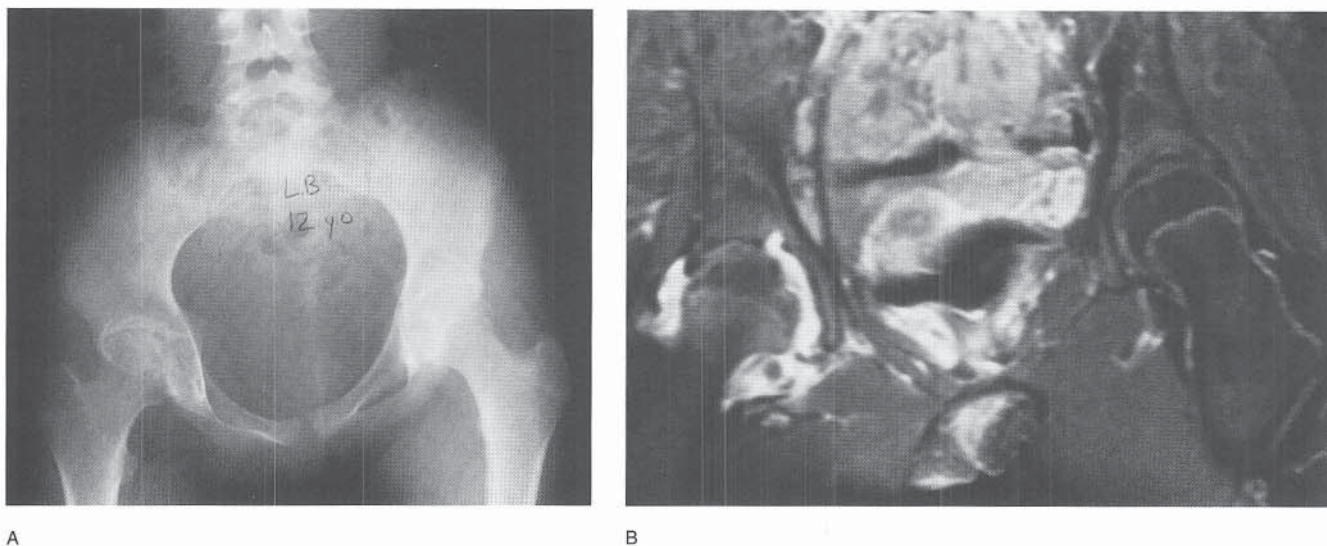


FIGURE 37-44 Imaging findings in a 12-year-old girl with a painful right hip and limited joint range of motion. **A**, Narrowing of the joint space and radiolucencies on the medial aspect of the femoral head and acetabulum are evident. **B**, MRI demonstrates an effusion and defect within the acetabulum.

editary component. It has been hypothesized that this condition represents a fundamental defect in the regulation of cartilage proliferation in the affected epiphyses, tarsal, or carpal bones.

PATHOLOGY

The findings are similar to those described for solitary osteochondromas. The lesion may be a pedunculated mass with a cartilaginous cap, or it may be seen only as an enlarged irregularity of the articular surface.⁴⁰ Histologically, the lesion appears similar to benign osteochondromas.

CLINICAL FEATURES

The most common sites of involvement are the distal femur, proximal tibia, talus, and tarsal navicular (Fig. 37-45). Other affected areas have included the hip, first cuneiform, scapula, and, infrequently, the upper extremity. The presenting complaint usually is not discomfort but instead deformity and limited range of motion in the affected joint. Other symptoms include a limp, muscle wasting, and, if long standing, limb length discrepancy. Angular malalignment of the knee (valgum or varum), ankle, and hindfoot (valgus) may be evident. The affected portion of the epiphysis is enlarged and a mass may be palpable. Articular surface irregularity may lead to early secondary osteoarthritis.

The male-female ratio is reported as 3:1, with patients commonly diagnosed between 2 and 14 years of age.

RADIOGRAPHIC FINDINGS

The radiographic findings depend on the patient's age at presentation. With infants or toddlers, radiographs may be normal or may demonstrate minimal metaphyseal widening. As the affected bone matures, a multicentric radiodensity develops adjacent to the epiphysis or tarsal bone (Fig. 37-46). In adolescents or adults, the lesion appears as an irregu-

lar bony mass, similar to an exostosis. The mass arises from one side of the affected epiphysis, may be single or multiple, and is associated with joint deformity. As the lesion matures and ossifies, it becomes confluent with the underlying bone. Premature physeal closure may occur, with secondary angular deformity and limb length discrepancy.

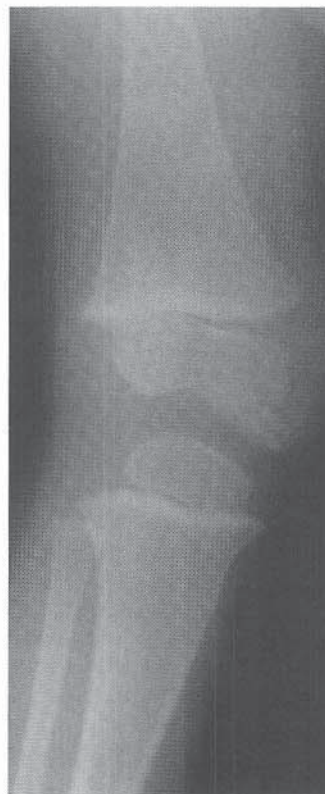

FIGURE 37-45 Dysplasia epiphysealis hemimelica. The lesion on the medial aspect of the distal femur in this 2-year-old boy led to an asymptomatic valgus malalignment.

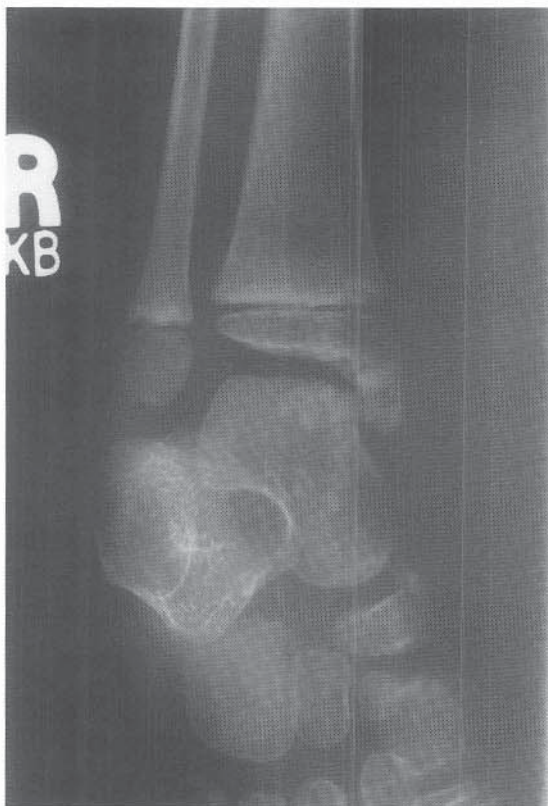

FIGURE 37–46 Dysplasia epiphysealis hemimelica. Multicentric radiodensities are evident along the medial malleolus, talar dome, and tarsal navicular in this radiograph of a 5-year-old boy's foot and ankle.

CT has been useful in accurately demonstrating the relationship between the normal bone and abnormal ossification, particularly at the articular surface. The use of MRI has allowed better imaging of the soft tissue component of the lesion. Most of the recent MRI literature reports a distinct plane of separation between the lesion and the normal epiphyseal bone.^{141,152} However, this plane is much more difficult to define during surgery.

NATURAL HISTORY

Dysplasia epiphysealis hemimelica usually stops growing once maturity is reached. Incongruity that occurs in the joint will lead to subsequent osteoarthritis. This condition remains benign; malignant transformation has not been reported in dysplasia epiphysealis hemimelica.

TREATMENT

Observation is warranted if the condition is asymptomatic and has not led to angular deformity or caused significant limitation of joint range of motion. Surgical excision should be undertaken if the lesion is painful, deformity is occurring, or joint function is limited. Recurrence is common, and repeated local excision is often required. Any angular deformities can be treated with corrective osteotomy at the time of lesion excision. Generally, the results are very good following excision of lesions that are juxta-articular. Unfortunately, less successful outcomes are achieved with excision of intra-articular lesions.¹⁵²

REFERENCES

1. Aarskog D, Tveteraas E: McCune-Albright's syndrome following adrenalectomy for Cushing's syndrome in infancy. *J Pediatr* 1968;73:89.
2. Abdelwahab IF, Hermann G, Norton KI, et al: Simple bone cysts of the pelvis in adolescents: a report of four cases [see comments]. *J Bone Joint Surg* 1991;73-A:1090.
3. Abdelwahab IF, Lewis MM, Klein MJ, et al: Case report 515. Simple (solitary) bone cyst of the calcaneus. *Skeletal Radiol* 1989;17:607.
4. Ahn J, Ludecke HJ, Lindow S, et al: Cloning of the putative tumour suppressor gene for hereditary multiple exostoses (EXT1). *Nat Genet* 1995;11:137.
5. Ahn JI, Park JS: Pathological fractures secondary to unicameral bone cysts. *Int Orthop* 1994;18:20.
6. Akhtar M, Ali MA, Bakry M, et al: Fine-needle aspiration biopsy of Langerhans histiocytosis (histiocytosis-X). *Diagn Cytopathol* 1993;9:527.
7. Albrechts AE, Rapini RP: Malignancy in Maffucci's syndrome. *Dermatol Clin* 1995;13:73.
8. Albright F: Polyostotic fibrous dysplasia: a defense of the entity. *J Med Endocrinol* 1947;7:307.
9. Albright F, Scoville WB, Slulkowitch HW: Syndrome characterized by osteitis fibrosa disseminata, areas of pigmentation, and a gonadal dysfunction. *Endocrinology* 1938;22:411.
10. Alguacil-Garcia A, Alonso A, Pettigrew NM: Osteofibrous dysplasia (ossifying fibroma) of the tibia and fibula and adamantinoma: a case report. *Am J Clin Pathol* 1984;82:470.
11. Alman BA, Greel DA, Wolfe HJ: Activating mutations of Gs protein in monostotic fibrous lesions of bone. *J Orthop Res* 1996;14:311.
12. Altermatt S, Schwobel M, Pochon JP: Operative treatment of solitary bone cysts with tricalcium phosphate ceramic: a 1 to 7 year follow-up. *Eur J Pediatr Surg* 1992;2:180.
13. Amin R, Ling R: Case report: malignant fibrous histiocytoma following radiation therapy of fibrous dysplasia. *Br J Radiol* 1995;68:1119.
14. Anderson MJ, Townsend DR, Johnston JO, et al: Osteofibrous dysplasia in the newborn: report of a case. *J Bone Joint Surg Am* 1993;75:265.
15. Andrisano A, Soncini G, Calderoni PP, et al: Critical review of infantile fibrous dysplasia: surgical treatment. *J Pediatr Orthop* 1991;11:478.
16. Araki Y, Tanaka H, Yamamoto H, et al: MR imaging of pigmented villonodular synovitis of the knee. *Radiat Med* 1994;12:11.
17. Araki Y, Tanaka H, Yamamoto H, et al: MRI of fibrous cortical defect of the femur. *Radiat Med* 1994;12:93.
18. Arata MA, Peterson HA, Dahlin DC: Pathological fractures through non-ossifying fibromas: review of the Mayo Clinic experience. *J Bone Joint Surg* 1981;63-A:980.
19. Arms DM, Strecker WB, Manske PR, et al: Management of forearm deformity in multiple hereditary osteochondromatosis. *J Pediatr Orthop* 1997;17:450.
20. Atabay H, Kuyucu Y, Korkmaz O, et al: Myelopathy due to hereditary multiple exostoses: CT and MR studies. *Clin Neurol Neurosurg* 1996;98:186.
21. Ayala AG, Murray JA, Erling MA, et al: Osteoid-osteoma: intraoperative tetracycline-fluorescence demonstration of the nidus. *J Bone Joint Surg* 1986;68-A:747.
22. Balci P, Obuz F, Gore O, et al: Aneurysmal bone cyst secondary to infantile cartilaginous hamartoma of rib. *Pediatr Radiol* 1997;27:767.
23. Beauchamp CP, Duncan CP, Dzus AK, et al: Osteoblastoma: experience with 23 patients. *Can J Surg* 1992;35:199.
24. Beltran J, Aparisi F, Bonmati LM, et al: Eosinophilic granuloma: MRI manifestations. *Skeletal Radiol* 1993;22:157.
25. Benassi MS, Campanacci L, Gamberi G, et al: Cytokeratin expression and distribution in adamantinoma of the long bones and osteofibrous dysplasia of tibia and fibula: an immunohistochemical study correlated to histogenesis. *Histopathology* 1994;25:71.
26. Ben-Itzhak I, Denolf FA, Versfeld GA, et al: The Maffucci syndrome. *J Pediatr Orthop* 1988;8:345.
27. Bertoni F, Bacchini P, Capanna R, et al: Solid variant of aneurysmal bone cyst. *Cancer* 1993;71:729.
28. Bianco P, Kuznetsov SA, Rimmucci M, et al: Reproduction of human fibrous dysplasia of bone in immunocompromised mice by transplanted mosaics of normal and Galpha-mutated skeletal progenitor cells. *J Clin Invest* 1998;101:1737.
29. Blanton SH, Hogue D, Wagner M, et al: Hereditary multiple exostoses: confirmation of linkage to chromosomes 8 and 11. *Am J Med Genet* 1996;62:150.

30. Blitch E, Mendicino RW: Chondroblastoma of the calcaneus: literature review and case presentation. *J Foot Ankle Surg* 1996;35:250.
31. Bloem JL, van der Heul RO, Schuttevaer HM, et al: Fibrous dysplasia vs adamantinoma of the tibia: differentiation based on discriminant analysis of clinical and plain film findings. *AJR Am J Roentgenol* 1991;156:1017.
32. Bollini G, Jouve JL, Gentet JC, et al: Bone lesions in histiocytosis X. *J Pediatr Orthop* 1991;11:469.
33. Bonakdarpour A, Levy WM, Aegerter E: Primary and secondary aneurysmal bone cyst: a radiological study of 75 cases. *Radiology* 1978;126:75.
34. Bongioanni F, Assadurian E, Polivka M, et al: Aneurysmal bone cyst of the atlas: operative removal through an anterolateral approach: a case report. *J Bone Joint Surg* 1996;78-A:1574.
35. Boriani S, Capanna R, Donati D, et al: Osteoblastoma of the spine. *Clin Orthop* 1992;278:37.
36. Bovill DF, Skinner HB: Unicameral bone cysts: a comparison of treatment options. *Orthop Rev* 1989;18:420.
37. Bridge JA, Dembinski A, De Boer J, et al: Clonal chromosomal abnormalities in osteofibrous dysplasia: implications for histopathogenesis and its relationship with adamantinoma. *Cancer* 1994;73:1746.
38. Bridge JA, Nelson M, Orndal C, et al: Clonal karyotypic abnormalities of the hereditary multiple exostoses chromosomal loci 8q24.1 (EXT1) and 11p11-12 (EXT2) in patients with sporadic and hereditary osteochondromas. *Cancer* 1998;82:1657.
39. Brien EW, Mirra JM, Ippolito V: Chondroblastoma arising from a nonepiphyseal site. *Skeletal Radiol* 1995;24:220.
40. Bullough P: *Orthopaedic Pathology*. London: Mosby-Wolfe, 1997.
41. Camitta B, Wells R, Segura A, et al: Osteoblastoma response to chemotherapy. *Cancer* 1991;68:999.
42. Campanacci M: *Bone and Soft Tissue Tumors*. Vienna: Springer-Verlag, 1990.
43. Campanacci M: Osteofibrous dysplasia of long bones: a new clinical entity. *Ital J Orthop Traumatol* 1976;2:221.
44. Campanacci M, Capanna R, Picci P: Unicameral and aneurysmal bone cysts. *Clin Orthop* 1986:25.
45. Campanacci M, Laus M: Osteofibrous dysplasia of the tibia and fibula. *J Bone Joint Surg* 1981;63-A:367.
46. Candelieri GA, Roughley PJ, Glorieux FH: Polymerase chain reaction-based technique for the selective enrichment and analysis of mosaic arg201 mutations in G alpha s from patients with fibrous dysplasia of bone. *Bone* 1997;21:201.
47. Cannon SR, Sweetnam DR: Multiple chondrosarcomas in dyschondroplasia (Ollier's disease). *Cancer* 1985;55:836.
48. Capanna R, Albinini U, Caroli GC, et al: Contrast examination as a prognostic factor in the treatment of solitary bone cyst by cortisone injection. *Skeletal Radiol* 1984;12:97.
49. Capanna R, Albinini U, Picci P, et al: Aneurysmal bone cyst of the spine. *J Bone Joint Surg* 1985; 67-A:527.
50. Capanna R, Campanacci DA, Manfrini M: Unicameral and aneurysmal bone cysts. *Orthop Clin North Am* 1996;27:605.
51. Capanna R, Dal Monte A, Gitelis S, et al: The natural history of unicameral bone cyst after steroid injection. *Clin Orthop* 1982;166:204.
52. Capanna R, Springfield DS, Biagini R, et al: Juxtaepiphyseal aneurysmal bone cyst. *Skeletal Radiol* 1985;13:21.
53. Capanna R, Van Horn JR, Biagini R, et al: Aneurysmal bone cyst of the sacrum. *Skeletal Radiol* 1989;18:109.
54. Caterini R, Manili M, Spinelli M, et al: Epiphyseal chondroblastoma of bone: long-term effects on skeletal growth and articular function in 15 cases treated surgically. *Arch Orthop Trauma Surg* 1992;111:327.
55. Chanson P, Dib A, Visot A, et al: McCune-Albright syndrome and acromegaly: clinical studies and responses to treatment in five cases. *Eur J Endocrinol* 1994;131:229.
56. Cheng MH, Chen YR: Malignant fibrous histiocytoma degeneration in a patient with facial fibrous dysplasia. *Ann Plast Surg* 1997;39:638.
57. Chew DK, Menelaus MB, Richardson MD: Ollier's disease: varus angulation at the lower femur and its management. *J Pediatr Orthop* 1998;18:202.
58. Chigira M, Maehara S, Arita S, et al: The aetiology and treatment of simple bone cysts. *J Bone Joint Surg* 1983;65-B:633.
59. Cigala F, Sadile F: Arterial embolization of aneurysmal bone cysts in children. *Bull Hosp Jt Dis* 1996;54:261.
60. Codman E: Epiphyseal chondromatous giant cell tumors of the upper end of the humerus. *Surg Gynecol Obstet* 1931;52:543.
61. Cohen J: Etiology of simple bone cyst. *J Bone Joint Surg* 1970;52-A:1493.
62. Cohen J: Unicameral bone cysts: a current synthesis of reported cases. *Orthop Clin North Am* 1977;8:715.
63. Cook A, Raskind W, Blanton SH, et al: Genetic heterogeneity in families with hereditary multiple exostoses. *Am J Hum Genet* 1993;53:71.
64. Dabska M, Buraczewski J: On malignant transformation in fibrous dysplasia of bone. *Oncology* 1972;26:369.
65. Dahl MT: The gradual correction of forearm deformities in multiple hereditary exostoses. *Hand Clin* 1993;9:707.
66. Dahlin D: *Bone Tumors*. Springfield, IL, Charles C Thomas, 1978.
67. Dahlin DC, Unni KK: *Bone Tumors: General Aspects and Data on 8542 Cases*. Springfield, IL, Charles C Thomas, 1986.
68. D'Ambrosia R, Ferguson FA: The formation of osteochondroma by epiphyseal cartilage transplantation. *Clin Orth Rel Res* 1968;61:103.
69. D'Angelo G, Petas N, Donzelli O: Lengthening of the lower limbs in Ollier's disease: problems related to surgery. *Chir Organi Mov* 1996;81:279.
70. Danielsson LG, el-Haddad I: Winged scapula due to osteochondroma: report of 3 children. *Acta Orthop Scand* 1989;60:728.
71. Davies AM, Pikoulas C, Griffith J: MRI of eosinophilic granuloma. *Eur J Radiol* 1994;18:205.
72. Davis RI, Foster H, Arthur K, et al: Cell proliferation studies in primary synovial chondromatosis. *J Pathol* 1998;184:18.
73. Della Rocca C, Huvos AG: Osteoblastoma: varied histological presentations with a benign clinical course: an analysis of 55 cases. *Am J Surg Pathol* 1996;20:841.
74. De Palma AF, Ahmad I: Fibrous dysplasia associated with shepherd's crook deformity of the humerus. *Clin Orthop* 1973;97:38.
75. De Palma AF, Dodd PM: Reconstructive surgery in fibrous dysplasia of bone. *Clin Orthop* 1962;19:132.
76. De Palma AF, Smythe VL: Recurrent fibrous dysplasia in a cortical bone graft. *Clin Orthop* 1963;26:136.
77. DePraeter MP, Vermeersch DG, Seynaeve PC, et al: Occipital pain in osteoid osteoma of the atlas. *Spine* 1999;24:912.
78. De Rosa GP, Graziano GP, Scott J: Arterial embolization of aneurysmal bone cyst of the lumbar spine: a report of two cases. *J Bone Joint Surg* 1990;72-A:777.
79. De Schepper AM, Ramon F, Van Marck E: MR imaging of eosinophilic granuloma: report of 11 cases. *Skeletal Radiol* 1993;22:163.
80. Dussaussois L, Stelmazyk J, Golzarian J: [Percutaneous treatment of an osteoid osteoma of the scapula using a laser under scanner control]. *Acta Orthop Belg* 1998;64:88.
81. Dysart SH, Swengel RM, van Dam BE: Aneurysmal bone cyst of a thoracic vertebra: treatment by selective arterial embolization and excision. *Spine* 1992;17:846.
82. Easley ME, Kneisl JS: Pathologic fractures through nonossifying fibromas: is prophylactic treatment warranted? *J Pediatr Orthop* 1997;17:808.
83. Elsheikh T, Silverman JF, Wakely PE Jr, et al: Fine-needle aspiration cytology of Langerhans' cell histiocytosis (eosinophilic granuloma) of bone in children. *Diagn Cytopathol* 1991;7:261.
84. Enneking WF, Gearen PF: Fibrous dysplasia of the femoral neck: treatment by cortical bone-grafting. *J Bone Joint Surg* 1986;68-A:1415.
85. Ergun R, Okten AI, Beskonakli E, et al: Cervical laminar exostosis in multiple hereditary osteochondromatosis: anterior stabilization and fusion technique for preventing instability. *Eur Spine J* 1997;6:267.
86. Fadda M, Manunta A, Rinonapoli G, et al: Ultrastructural appearance of chondroblastoma. *Int Orthop* 1994;18:389.
87. Fairbank T: Dysplasia epiphysealis hemimelica (tarsoepiphyseal aclasis). *J Bone Joint Surg* 1956;38-B:237.
88. Fanning CV, Sneige NS, Carrasco CH, et al: Fine needle aspiration cytology of chondroblastoma of bone. *Cancer* 1990;65:1847.
89. Farber JM, Stanton RP: Treatment options in unicameral bone cysts. *Orthopedics* 1990;13:25.
90. Fink BR, Temple HT, Chiricosta FM, et al: Chondroblastoma of the foot. *Foot Ankle Int* 1997;18:236.
91. Fisher AJ, Reinus WR, Friedland JA, et al: Quantitative analysis of the plain radiographic appearance of eosinophilic granuloma. *Invest Radiol* 1995;30:466.
92. Floman Y, Bar-On E, Mosheiff R, et al: Eosinophilic granuloma of the spine. *J Pediatr Orthop B* 1997;6:260.
93. Frangenheim P: Angeborene Ostitis Fibrosa als Ursache einer intrauterinen Unterschenkel Fraktur. *Arch Klin Chir* 1921;117:22.

94. Fraser RK, Coates CJ, Cole WG: An angiostatic agent in treatment of a recurrent aneurysmal bone cyst. *J Pediatr Orthop* 1993;13:668.
95. Frassica FJ, Waltrip RL, Sponseller PD, et al: Clinicopathologic features and treatment of osteoid osteoma and osteoblastoma in children and adolescents. *Orthop Clin North Am* 1996;27:559.
96. Freiberg AA, Loder RT, Heidelberger KP, et al: Aneurysmal bone cysts in young children. *J Pediatr Orthop* 1994;14:86.
97. Friedland JA, Reinus WR, Fisher AJ, et al: Quantitative analysis of the plain radiographic appearance of nonossifying fibroma. *Invest Radiol* 1995;30:474.
98. Fukuda T, Saito M, Nakajima T: Imprint cytology of chondroblastoma of bone: a case report. *Acta Cytol* 1998;42:403.
99. Gabos PG, Bowen JR: Epiphyseal-metaphyseal enchondromatosis: a new clinical entity. *J Bone Joint Surg* 1998;80-A:782.
100. Galasko CS: The fate of simple bone cysts which fracture [letter]. *Clin Orthop* 1974;101:302.
101. Gallacher SJ, Wilson R, Boyle IT, et al: The hyperthyroidism of polyostotic fibrous dysplasia: a possible autoimmune aetiology. *Scott Med J* 1989;34:529.
102. Garrison RC, Unni KK, McLeod RA, et al: Chondrosarcoma arising in osteochondroma. *Cancer* 1982;49:1890.
103. Gebhart M, Blaimont P: Contribution to the vascular origin of the unicameral bone cyst. *Acta Orthop Belg* 1996;62:137.
104. Gerasimov AM, Toporova SM, Furtseva LN, et al: The role of lysosomes in the pathogenesis of unicameral bone cysts. *Clin Orthop* 1991:53.
105. Ghelman B, Thompson FM, Arnold WD: Intraoperative radioactive localization of an osteoid-osteoma: case report. *J Bone Joint Surg* 1981;63-A:826.
106. Gitelis S, Wilkins R, Conrad EU II: Benign bone tumors. *Instr Course Lect* 1996;45:425.
107. Gitelis S, McDonald DJ: Common benign bone tumors and usual treatment. In Simon MA, Springfield D II (eds): *Surgery for Bone and Soft Tissue Tumors*, p 181. Philadelphia, Lippincott-Raven, 1998.
108. Green JA, Bellemore MC, Marsden FW: Embolization in the treatment of aneurysmal bone cysts. *J Pediatr Orthop* 1997;17:440.
109. Guille JT, Kumar SJ, MacEwen GD: Fibrous dysplasia of the proximal part of the femur: long-term results of curettage and bone-grafting and mechanical realignment. *J Bone Joint Surg* 1998;80-A:648.
110. Gupta AK, Crawford AH: Solitary bone cyst with epiphyseal involvement: confirmation with magnetic resonance imaging. A case report and review of the literature. *J Bone Joint Surg* 1996;78-A:911.
111. Haga N, Nakamura K, Taniguchi K, et al: Enchondromatosis with features of dyspondyloenchondromatosis and Maffucci syndrome. *Clin Dysmorphol* 1998;7:65.
112. Haims AH, Desai P, Present D, et al: Epiphyseal extension of a unicameral bone cyst. *Skeletal Radiol* 1997;26:51.
113. Halbert AR, Harrison WR, Hicks MJ, et al: Cytogenetic analysis of a scapular chondromyxoid fibroma. *Cancer Genet Cytogenet* 1998;104:52.
114. Hashemi-Nejad A, Cole WG: Incomplete healing of simple bone cysts after steroid injections. *J Bone Joint Surg* 1997;79-B:727.
115. Hazarika D, Kumar RV, Rao CR, et al: Fine needle aspiration cytology of chondroblastoma and chondromyxoid fibroma: a report of two cases. *Acta Cytol* 1994;38:592.
116. Hazelbag HM, Wessels JW, Mollevangers P, et al: Cytogenetic analysis of adamantinoma of long bones: further indications for a common histogenesis with osteofibrous dysplasia. *Cancer Genet Cytogenet* 1997;97:5.
117. Hennekam RC: Hereditary multiple exostoses. *J Med Genet* 1991;28:262.
118. Herzenberg JE, Phillips WA, Hensinger RN, et al: Osteoid-osteoma: intraoperative tetracycline-fluorescence demonstration of the nidus [letter]. *J Bone Joint Surg* 1987;69-A:310.
119. Hsissen MA, Kadiri F, Zamiaty S, et al: [A case of facial fibrous dysplasia in brothers]. *Rev Stomatol Chir Maxillofac* 1997;98:96.
120. Hudson TM, Chew FS, Manaster BJ: Scintigraphy of benign exostoses and exostotic chondrosarcomas. *AJR Am J Roentgenol* 1983;140:581.
121. Hudson TM, Stiles RG, Monson DK: Fibrous lesions of bone. *Radiol Clin North Am* 1993;31:279.
122. Hyde GE, Yarrington CT Jr, Chu FW: Head and neck manifestations of Maffucci's syndrome: chondrosarcoma of the nasal septum. *Am J Otolaryngol* 1995;16:272.
123. Inoue O, Ibaraki K, Shimabukuro H, et al: Packing with high-porosity hydroxyapatite cubes alone for the treatment of simple bone cyst. *Clin Orthop* 1993;293:287.
124. Ishida T, Iijima T, Kikuchi F, et al: A clinicopathological and immunohistochemical study of osteofibrous dysplasia, differentiated adamantinoma, and adamantinoma of long bones. *Skeletal Radiol* 1992;21:493.
125. Jaffe H: Aneurysmal bone cyst. *Bull Hosp Jt Dis* 1950;11:3.
126. Jaffe H: Hereditary multiple exostoses. *Ann Pathol* 1943;36:335.
127. Jaffe H: Osteoid-osteoma: a benign osteoblastic tumor composed of osteoid and atypical bone. *Arch Surg* 1935;31:709.
128. Jaffe H: *Tumors and Tumorlike Conditions of the Bones and Joints*. Philadelphia: Lea & Febiger, 1958.
129. Jaffe HL, Lichtenstein LL: Benign chondroblastoma of bone: a reinterpretation of the so-called calcifying or chondromatous giant cell tumor. *Am J Pathol* 1942;18:969.
130. Jaffe HL, Lichtenstein LL: Non-osteogenic fibroma of bone. *Am J Pathol* 1942;18:205.
131. Jaffe HL, Lichtenstein LL: Solitary unicameral bone cyst: with emphasis on the roentgen picture, the pathologic appearance and the pathogenesis. *Arch Surg* 1942;44:1004.
132. Jambhekar NA, Desai PB, Chitale DA, et al: Benign metastasizing chondroblastoma: a case report. *Cancer* 1998;82:675.
133. Jee WH, Choe BY, Kang HS, et al: Nonossifying fibroma: characteristics at MR imaging with pathologic correlation. *Radiology* 1998;209:197.
134. Johnston CE II, Sklar F: Multiple hereditary exostoses with spinal cord compression. *Orthopedics* 1988;11:1213.
135. Kaplan RP, Wang JT, Amron DM, et al: Maffucci's syndrome: two case reports with a literature review. *J Am Acad Dermatol* 1993;29:894.
136. Kay RM, Eckardt JJ, Mirra JM: Multifocal pigmented villonodular synovitis in a child: a case report. *Clin Orthop* 1996;322:194.
137. Kayser F, Resnick D, Haghighi P, et al: Evidence of the subperiosteal origin of osteoid osteomas in tubular bones: analysis by CT and MR imaging. *AJR Am J Roentgenol* 1998;170:609.
138. Kearns D, McGill T, Potsic W: Fibrous dysplasia. *Head Neck* 1992;14:510.
139. Keith A: Studies on the anatomical changes which accompany certain growth disorders of the human body. *J Anat* 1920;54:101.
140. Kenan S, Abdelwahab IF, Klein MJ, et al: Case report 817. Synovial chondrosarcoma secondary to synovial chondromatosis. *Skeletal Radiol* 1993;22:623.
141. Keret D, Spatz DK, Caro PA, et al: Dysplasia epiphysealis hemimelica: diagnosis and treatment. *J Pediatr Orthop* 1992;12:365.
142. Kerr R: Eosinophilic granuloma of the spine causing neurologic deficit [Radiologic Case Study]. *Orthopedics* 1989;12:309.
143. Kilpatrick SE, Pike EJ, Geisinger KR, et al: Chondroblastoma of bone: use of fine-needle aspiration biopsy and potential diagnostic pitfalls. *Diagn Cytopathol* 1997;16:65.
144. Kilpatrick SE, Pike EJ, Ward WG, et al: Dedifferentiated chondrosarcoma in patients with multiple osteochondromatosis: report of a case and review of the literature. *Skeletal Radiol* 1997;26:370.
145. Kistler W: Synovial chondromatosis of the knee joint: a rarity during childhood. *Eur J Pediatr Surg* 1991;1:237.
146. Koci TM, Mehlinger CM, Yamagata N, et al: Aneurysmal bone cyst of the thoracic spine: evolution after particulate embolization. *AJNR Am J Neuroradiol* 1995;16:857.
147. Komiya S, Inoue A: Aggressive bone tumorous lesion in infancy: osteofibrous dysplasia of the tibia and fibula. *J Pediatr Orthop* 1993;13:577.
148. Komiya S, Minamitani K, Sasaguri Y, et al: Simple bone cyst: treatment by trepanation and studies on bone resorptive factors in cyst fluid with a theory of its pathogenesis. *Clin Orthop* 1993;287:204.
149. Komiya S, Tsuzuki K, Mangham DC, et al: Oxygen scavengers in simple bone cysts. *Clin Orthop* 1994;308:199.
150. Kransdorf MJ, Sweet DE: Aneurysmal bone cyst: concept, controversy, clinical presentation, and imaging. *AJR Am J Roentgenol* 1995;164:573.
151. Kroon HM, Schurmans J: Osteoblastoma: clinical and radiologic findings in 98 new cases. *Radiology* 1990;175:783.
152. Kuo RS, Bellemore MC, Monsell FP, et al: Dysplasia epiphysealis hemimelica: clinical features and management. *J Pediatr Orthop* 1998;18:543.
153. Kurt AM, Turcotte RE, McLeod RA, et al: Chondroblastoma of bone. *Orthopedics* 1990;13:787.

154. Kurt AM, Unni KK, Sim FH, et al: Chondroblastoma of bone. *Hum Pathol* 1989;20:965.
155. Kuruvilla G, Steiner GC: Osteofibrous dysplasia-like adamantinoma of bone: a report of five cases with immunohistochemical and ultrastructural studies. *Hum Pathol* 1998;29:809.
156. Labbe JL, Clement JL, Duparc B, et al: Percutaneous extraction of vertebral osteoid osteoma under computed tomography guidance. *Eur Spine J* 1995;4:368.
157. Le Merrer M, Legeai-Mallet L, Jeannin PM, et al: A gene for hereditary multiple exostoses maps to chromosome 19p. *Hum Mol Genet* 1994;3:717.
158. Legeai-Mallet L, Munnich A, Maroteaux P, et al: Incomplete penetrance and expressivity skewing in hereditary multiple exostoses. *Clin Genet* 1997;52:12.
159. Levy WM, Miller AS, Bonakdarpour A, et al: Aneurysmal bone cyst secondary to other osseous lesions: report of 57 cases. *Am J Clin Pathol* 1975;63:1.
160. Lichtenstein L: Polyostotic fibrous dysplasia. *Arch Surg* 1938;36:874.
161. Lichtenstein L: Histiocytosis X: integration of eosinophilic granuloma of the bone, Letterer-Siwe disease, and Schüller-Christian disease as related manifestations of a single nosologic entity. *Arch Pathol* 1953;56:86.
162. Lichtenstein L, Jaffe HL: Eosinophilic granuloma of bone with report of a case. *Am J Pathol* 1940;16:959.
163. Lichtenstein L, Jaffe HL: Fibrous dysplasia of bone. *Arch Pathol* 1942;33:777.
164. Lin X, Wells D: Isolation of the mouse cDNA homologous to the human EXT1 gene responsible for hereditary multiple exostoses. *DNA Seq* 1997;7:199.
165. Liu J, Hudkins PG, Swee RG, et al: Bone sarcomas associated with Ollier's disease. *Cancer* 1987;59:1376.
166. Logrono R, Kurtycz DF, Wojtowycz M, et al: Fine needle aspiration cytology of fibrous dysplasia: a case report. *Acta Cytol* 1998;42:1172.
167. Lokiec F, Ezra E, Khermish O, et al: Simple bone cysts treated by percutaneous autologous marrow grafting: a preliminary report [see comments]. *J Bone Joint Surg* 1996;78-B:934.
168. Lucas DR, Unni KK, McLeod RA, et al: Osteoblastoma: clinicopathologic study of 306 cases. *Hum Pathol* 1994;25:117.
169. Madhavan P, Ogilvie C: Premature closure of upper humeral physis after fracture through simple bone cyst. *J Pediatr Orthop B* 1998;7:83.
170. Magre GR, Menendez LR: Preoperative CT localization and marking of osteoid osteoma: description of a new technique. *J Comput Assist Tomogr* 1996;20:526.
171. Malchoff CD, Reardon G, MacGillivray DC, et al: An unusual presentation of McCune-Albright syndrome confirmed by an activating mutation of the Gs alpha-subunit from a bone lesion. *J Clin Endocrinol Metab* 1994;78:803.
172. Malghem J, Maldague B, Esselinckx W, et al: Spontaneous healing of aneurysmal bone cysts: a report of three cases. *J Bone Joint Surg* 1989;71-B:645.
173. Marcove RC, Sheth DS, Takemoto S, et al: The treatment of aneurysmal bone cyst. *Clin Orthop* 1995;311:157.
174. Marks KE, Bauer TW: Fibrous tumors of bone. *Orthop Clin North Am* 1989;20:377.
175. Martinez-Lage JF, Poza M, Cartagena J, et al: Solitary eosinophilic granuloma of the pediatric skull and spine: the role of surgery. *Childs Nerv Syst* 1991;7:448.
176. Matsumoto K, Fujii S, Mochizuki T, et al: Solitary bone cyst of a lumbar vertebra: a case report and review of literature. *Spine* 1990;15:605.
177. McCune DJ, Brunch H: *Am J Dis Child* 1937;54:807.
178. McGrath BE, Bush CH, Nelson TE, et al: Evaluation of suspected osteoid osteoma. *Clin Orthop* 1996;327:247.
179. Mehdian H, Weatherley C: Combined anterior and posterior resection and spinal stabilization for aneurysmal bone cyst. *Eur Spine J* 1995;4:123.
180. Mellon CD, Carter JE, Owen DB: Ollier's disease and Maffucci's syndrome: distinct entities or a continuum? Case report: enchondromatosis complicated by an intracranial glioma. *J Neurol* 1988;235:376.
181. Merchan EC, Sanchez-Herrera S, Gonzalez JM: Secondary chondrosarcoma: four cases and review of the literature. *Acta Orthop Belg* 1993;59:76.
182. Merine D, Fishman EK, Rosengard A, et al: Chondromyxoid fibroma of the fibula. *J Pediatr Orthop* 1989;9:468.
183. Mertens F, Jonsson K, Willen H, et al: Chromosome rearrangements in synovial chondromatous lesions. *Br J Cancer* 1996;74:251.
184. Mikawa Y, Watanabe R, Nakashima Y, et al: Cervical spinal cord compression in hereditary multiple exostoses: report of a case and a review of the literature. *Arch Orthop Trauma Surg* 1997;116:112.
185. Mirra JM: *Bone Tumors: Diagnosis and Treatment*. Philadelphia: JB Lippincott, 1980.
186. Mirra JM, Gold R, Downs J, et al: A new histologic approach to the differentiation of enchondroma and chondrosarcoma of the bones: a clinicopathologic analysis of 51 cases. *Clin Orthop* 1985;201:214.
187. Mohan V, Sabri T, Marklund T, et al: Clinicoradiological diagnosis of benign osteoblastoma of the spine in children. *Arch Orthop Trauma Surg* 1991;110:260.
188. Monroc M, Ducou le Pointe H, Haddad S, et al: Soft tissue signal abnormality associated with eosinophilic granuloma: correlation of MR imaging with pathologic findings. *Pediatr Radiol* 1994;24:328.
189. Moreau G, Letts M: Unicameral bone cyst of the calcaneus in children. *J Pediatr Orthop* 1994;14:101.
190. Mouchet A, Belot J: Tarsomegalie. *J Radiol Electrol* 1926;10:289.
191. Müller E: Über hereditäre multiple cartilagineux Exostosen und Enchondrosen. *Beitr Pathol Anat* 1913;57:232.
192. Muscolo DL, Velan O, Pineda Acero G, et al: Osteoid osteoma of the hip: Percutaneous resection guided by computed tomography [see comments]. *Clin Orthop* 1995;310:170.
193. Mylle J, Burssens A, Fabry G: Simple bone cysts: a review of 59 cases with special reference to their treatment. *Arch Orthop Trauma Surg* 1992;111:297.
194. Nawata K, Teshima R, Minamizaki T, et al: Knee deformities in multiple hereditary exostoses: a longitudinal radiographic study. *Clin Orthop* 1995;313:194.
195. Neer CS, Francis KC, Johnston AD, et al: Current concepts on the treatment of solitary unicameral bone cyst. *Clin Orthop* 1973;97:40.
196. Nezelof C, Basset F, Rousseau MF: Histiogenic arguments for a Langerhans' cell origin. *Biomedicine* 1973;18:365.
197. Nimityongskul P, Anderson LD, Dowling EA: Chondromyxoid fibroma. *Orthop Rev* 1992;21:863.
198. Nixon GW, Condon VR: Epiphyseal involvement in polyostotic fibrous dysplasia: a report of two cases. *Radiology* 1973;106:167.
199. Oba M, Nakagami W, Maeda M, et al: Symptomatic monostotic fibrous dysplasia of the thoracic spine. *Spine* 1998;23:741.
200. O'Connor P, Gibbon WW, Hardy G, Butt WP: Chondromyxoid fibroma of the foot. *Skeletal Radiol (Germany)* 1996;25(2):143.
201. Ogilvie-Harris DJ, Saleh K: Generalized synovial chondromatosis of the knee: a comparison of removal of the loose bodies alone with arthroscopic synovectomy. *Arthroscopy* 1994;10:166.
202. Ollier L: De la dyschondroplasié. *Bull Soc Chir Lyon* 1900;3:22.
203. Otani S, Ehrlich J: Solitary eosinophilic granuloma of bone simulating primary neoplasm. *Am J Pathol* 1940;16:479.
204. Oxtoby JW, Davies AM: MRI characteristics of chondroblastoma. *Clin Radiol* 1996;51:22.
205. Ozaki T, Hillmann A, Lindner N, et al: Aneurysmal bone cysts in children. *J Cancer Res Clin Oncol* 1996;122:767.
206. Ozaki T, Hillmann A, Lindner N, et al: Cementation of primary aneurysmal bone cysts. *Clin Orthop* 1997;337:240.
207. Paige ML, Michael AS, Brodin A: Case report 647. Benign osteoblastoma causing spinal cord compression and spastic paresis. *Skeletal Radiol* 1991;20:54.
208. Pandey R, White SH, Kenwright J: Callus distraction in Ollier's disease. *Acta Orthop Scand* 1995;66:479.
209. Papagelopoulos PJ, Currier BL, Shaughnessy WJ, et al: Aneurysmal bone cyst of the spine: management and outcome. *Spine* 1998;23:621.
210. Papavasiliou VA, Sferopoulos NK: Aneurysmal bone cyst: a preliminary report on a new surgical approach. *J Pediatr Orthop* 1990;10:362.
211. Park CK, Cho KK, Lee SW, et al: Simple bone cyst of the axis. *Childs Nerv Syst* 1997;13:171.
212. Park YK, Unni KK, McLeod RA, et al: Osteofibrous dysplasia: clinicopathologic study of 80 cases. *Hum Pathol* 1993;24:1339.
213. Parlier-Cuau C, Champsaur P, Nizard R, et al: Percutaneous removal of osteoid osteoma. *Radiol Clin North Am* 1998;36:559.
214. Paterson DC, Morris LL, Binns GF, et al: Generalized enchondromatosis: a case report. *J Bone Joint Surg* 1989;71-A:133.
215. Peterson HA: Deformities and problems of the forearm in children with multiple hereditary osteochondromata. *J Pediatr Orthop* 1994;14:92.

216. Peterson HA: Multiple hereditary osteochondromata. *Clin Orthop* 1989;239:222.
217. Philippe C, Porter DE, Emerton ME, et al: Mutation screening of the EXT1 and EXT2 genes in patients with hereditary multiple exostoses. *Am J Hum Genet* 1997;61:520.
218. Potocki L, Shaffer LG: Interstitial deletion of 11(p11.2p12): a newly described contiguous gene deletion syndrome involving the gene for hereditary multiple exostoses (EXT2). *Am J Med Genet* 1996;62:319.
219. Povysil C, Tomanova R, Matejovsky Z: Muscle-specific actin expression in chondroblastomas. *Hum Pathol* 1997;28:316.
220. Prohaska DJ, Kneidel TW: Chondroblastoma in a metatarsal. *J Foot Ankle Surg* 1998;37:63.
221. Przybylski GJ, Pollack IF, Ward WT: Monostotic fibrous dysplasia of the thoracic spine: a case report. *Spine* 1996;21:860.
222. Quirini GE, Meyer JR, Herman M, et al: Osteochondroma of the thoracic spine: an unusual cause of spinal cord compression. *AJNR Am J Neuroradiol* 1996;17:961.
223. Ramina R, Coelho Neto M, Meneses MS, et al: Maffucci's syndrome associated with a cranial base chondrosarcoma: case report and literature review. *Neurosurgery* 1997;41:269.
224. Raskas DS, Graziano GP, Herzenberg JE, et al: Osteoid osteoma and osteoblastoma of the spine. *J Spinal Disord* 1992;5:204.
225. Raskind WH, Conrad EU, Chansky H, et al: Loss of heterozygosity in chondrosarcomas for markers linked to hereditary multiple exostoses loci on chromosomes 8 and 11. *Am J Hum Genet* 1995;56:1132.
226. Rector JT, Gray CL, Sharpe RW, et al: Acute lymphoid leukemia associated with Maffucci's syndrome. *Am J Pediatr Hematol Oncol* 1993;15:427.
227. Redfern DR, Forester AJ, Evans MJ, et al: Enchondroma of the scaphoid. *J Hand Surg* 1997;22-B:235.
228. Roach PJ, Connolly LP, Zurakowski D, et al: Osteoid osteoma: comparative utility of high-resolution planar and pinhole magnification scintigraphy. *Pediatr Radiol* 1996;26:222.
229. Robinson D, Tieder M, Halperin N, et al: Maffucci's syndrome—the result of neural abnormalities? Evidence of mitogenic neurotransmitters present in enchondromas and soft tissue hemangiomas. *Cancer* 1994;74:949.
230. Rodgers WB, Hall JE: One-bone forearm as a salvage procedure for recalcitrant forearm deformity in hereditary multiple exostoses. *J Pediatr Orthop* 1993;13:587.
231. Roger B, Bellin MF, Wioland M, et al: Osteoid osteoma: CT-guided percutaneous excision confirmed with immediate follow-up scintigraphy in 16 outpatients. *Radiology* 1996;201:239.
232. Rosenthal DI, Hornicek FJ, Wolfe MW, et al: Percutaneous radiofrequency coagulation of osteoid osteoma compared with operative treatment. *J Bone Joint Surg* 1998;80-A:815.
233. Rosenthal DI, Springfield DS, Gebhardt MC, et al: Osteoid osteoma: percutaneous radio-frequency ablation. *Radiology* 1995;197:451.
234. Rud B, Pedersen NW, Thomsen PB: Simple bone cysts in children treated with methylprednisolone acetate. *Orthopedics* 1991;14:185.
235. Ruggieri P, Sim FH, Bond JR, et al: Malignancies in fibrous dysplasia. *Cancer* 1994;73:1411.
236. Saifuddin A, White J, Sherazi Z, et al: Osteoid osteoma and osteoblastoma of the spine: factors associated with the presence of scoliosis. *Spine* 1998;23:47.
237. el-Sayed S, Brewin TB: Histiocytosis X: does radiotherapy still have a role? *Clin Oncol (R Coll Radiol)* 1992;4:27.
238. Scaglietti O, Marchetti PG, Bartolozzi P: The effects of methylprednisolone acetate in the treatment of bone cysts: results of three years follow-up. *J Bone Joint Surg* 1979;61-B:200.
239. Scaglietti O, Marchetti PG, Bartolozzi P: Final results obtained in the treatment of bone cysts with methylprednisolone acetate (Depo-Medrol) and a discussion of results achieved in other bone lesions. *Clin Orthop* 1982;165:33.
240. Schajowicz F: *Tumors and Tumorlike Lesions of Bone and Joints*. New York, Springer-Verlag, 1981.
241. Schmale GA, Conrad EU 3rd, Raskind WH: The natural history of hereditary multiple exostoses. *J Bone Joint Surg* 1994;76-A:986.
242. Schreuder HW, Veth RP, Pruszczynski M, et al: Aneurysmal bone cysts treated by curettage, cryotherapy and bone grafting. *J Bone Joint Surg* 1997;79-B:20.
243. Schwartz HS, Pinto M: Osteoblastomas of the cervical spine. *J Spinal Disord* 1990;3:179.
244. Schwartz HS, Unni KK, Pritchard DJ: Pigmented villonodular synovitis: a retrospective review of affected large joints. *Clin Orthop* 1989;243.
245. Schwartz HS, Zimmerman NB, Simon MA, et al: The malignant potential of enchondromatosis. *J Bone Joint Surg* 1987;69-A:269.
246. Sessa S, Sommelet D, Lascombes P, et al: Treatment of Langerhans-cell histiocytosis in children: Experience at the Children's Hospital of Nancy [see comments]. *J Bone Joint Surg* 1994;76-A:1513.
247. Sethi A, Agarwal K, Sethi S, et al: Allograft in the treatment of benign cystic lesions of bone. *Arch Orthop Trauma Surg* 1993;112:167.
248. Shapiro F: Ollier's disease: an assessment of angular deformity, shortening, and pathological fracture in twenty-one patients. *J Bone Joint Surg* 1982;64-A:95.
249. Shapiro F, Simon S, Glimcher MJ: Hereditary multiple exostoses: anthropometric, roentgenographic, and clinical aspects. *J Bone Joint Surg* 1979;61-A:815.
250. Shapiro SA, Javid T, Putty T: Osteochondroma with cervical cord compression in hereditary multiple exostoses. *Spine* 1990;15:600.
251. Shen Q, Jia L, Li Y: Solitary bone cyst in the odontoid process and body of the axis: a case report and review of literature. *J Bone Joint Surg* 1998;80-B:30.
252. Shenker A, Weinstein LS, Sweet DE, et al: An activating Gs alpha mutation is present in fibrous dysplasia of bone in the McCune-Albright syndrome. *J Clin Endocrinol Metab* 1994;79:750.
253. Sherazi Z, Saifuddin A, Shaikh MI, et al: Unusual imaging findings in association with spinal osteoblastoma. *Clin Radiol* 1996;51:644.
254. Shih HN, Cheng CY, Chen YJ, et al: Treatment of the femoral neck and trochanteric benign lesions. *Clin Orthop* 1996;328:220.
255. Shindell R, Huerman WW, Lippiello L, et al: Prostaglandin levels in unicameral bone cysts treated by intralesional steroid injection. *J Pediatr Orthop* 1989;9:516.
256. Shinozaki T, Arita S, Watanabe H, et al: Simple bone cysts treated by multiple drill-holes: 23 cysts followed 2–10 years [see comments]. *Acta Orthop Scand* 1996;67:288.
257. Shpitzer T, Ganel A, Engelberg S: Surgery for synovial chondromatosis: 26 cases followed up for 6 years. *Acta Orthop Scand* 1990;61:567.
258. Simon MA, Kirchner PT: Scintigraphic evaluation of primary bone tumors: comparison of technetium-99m phosphonate and gallium citrate imaging. *J Bone Joint Surg* 1980;62-A:758.
259. Simovic S, Klapan I, Bumber Z, et al: Fibrous dysplasia in paranasal cavities. *ORL J Otorhinolaryngol Relat Spec* 1996;58:55.
260. Sisayan R, Lorberboym M, Hermann G: Polyostotic fibrous dysplasia in McCune-Albright syndrome diagnosed by bone scintigraphy. *Clin Nucl Med* 1997;22:410.
261. Smith SB, Shane HS: Simple bone cyst of the calcaneus: a case report and literature review. *J Am Podiatr Med Assoc* 1994;84:127.
262. Snearly WN, Peterson HA: Management of ankle deformities in multiple hereditary osteochondromata. *J Pediatr Orthop* 1989;9:427.
263. Snetkov AI: [Surgical treatment of the polyostotic form of fibrous dysplasia in children and adolescents]. *Vestn Khir* 1988;140:85.
264. Springer KR: Synovial chondromatosis. *J Foot Surg* 1991;30:446.
265. Springfield DS, Rosenberg AE, Mankin HJ, et al: Relationship between osteofibrous dysplasia and adamantinoma. *Clin Orthop* 1994;309:234.
266. Stanton RP, Abdel-Mota'al MM: Growth arrest resulting from unicameral bone cyst. *J Pediatr Orthop* 1998;18:198.
267. Stanton RP, Hansen MO: Function of the upper extremities in hereditary multiple exostoses. *J Bone Joint Surg* 1996;78-A:568.
268. Stanton RP, Montgomery BE: Fibrous dysplasia. *Orthopedics* 1996;19:679.
269. Struhl S, Edelson C, Pritzker H, et al: Solitary (unicameral) bone cyst: the fallen fragment sign revisited. *Skeletal Radiol* 1989;18:261.
270. Sun TC, Swee RG, Shives TC, et al: Chondrosarcoma in Maffucci's syndrome. *J Bone Joint Surg* 1985;67-A:1214.
271. Sunkara UK, Sponseller PD, Hadley Miller N, et al: Bilateral osteofibrous dysplasia: a report of two cases and review of the literature. *Iowa Orthop J* 1997;17:47.
272. Sviland L, Malcolm AJ: Synovial chondromatosis presenting as painless soft tissue mass: a report of 19 cases. *Histopathology* 1995;27:275.
273. Swarts SJ, Neff JR, Johansson SL, et al: Significance of abnormalities of chromosomes 5 and 8 in chondroblastoma. *Clin Orthop* 1998;349:189.
274. Sweasey TA, Dauser RC: Eosinophilic granuloma of the cervicothoracic junction: case report. *J Neurosurg* 1989;71:942.
275. Sweet DE, Vinh TN, Devaney K: Cortical osteofibrous dysplasia of long bone and its relationship to adamantinoma: a clinicopathologic study of 30 cases. *Am J Surg Pathol* 1992;16:282.

276. Tachdjian M: *Pediatric Orthopedics*. 2nd ed. Philadelphia: WB Saunders Co, 1990.
277. Tang Y, Xia JH, Zhou JN, et al: [Localization of the gene for 4 hereditary multiple exostoses families]. *I Chuan Hsueh Pao* 1998;25:1.
278. Thompson MS, Woodward JS Jr: The use of the arthroscope as an adjunct in the resection of a chondroblastoma of the femoral head. *Arthroscopy* 1995;11:106.
279. Tokunaga Y, Hirabayashi K, Toyama Y, et al: Aneurysmal bone cyst of the axis treated by laminoplasty with autogenous iliac bone. *Spine* 1992;17:S57.
280. Towbin R, Kaye R, Meza MP, et al: Osteoid osteoma: percutaneous excision using a CT-guided coaxial technique. *AJR Am J Roentgenol* 1995;164:945.
281. Trevor D: Tarso-epiphysial aclasis: a congenital error of epiphysial development. *J Bone Joint Surg* 1950;32-B:204.
282. Turcotte RE, Kurt AM, Sim FH, et al: Chondroblastoma. *Hum Pathol* 1993;24:944.
283. Turker RJ, Mardjetko S, Lubicky J: Aneurysmal bone cysts of the spine: excision and stabilization. *J Pediatr Orthop* 1998;18:209.
284. Tuzuner S, Aydin AT: Arthroscopic removal of an osteoid osteoma at the talar neck. *Arthroscopy* 1998;14:405.
285. Ueda Y, Blasius S, Edel G, et al: Osteofibrous dysplasia of long bones: a reactive process to adamantinomatous tissue [published erratum appears in *J Cancer Res Clin Oncol* 1992;118(5):400]. *J Cancer Res Clin Oncol* 1992;118:152.
286. Vedantam R, Crawford AH, Kuwajima SS: Aneurysmal bone cyst of the clavicle in a child. *Br J Clin Pract* 1996;50:474.
287. Vedantam R, Strecker WB, Schoenecker PL, et al: Polyarticular pigmented villonodular synovitis in a child. *Clin Orthop* 1998;348:208.
288. Velez-Yanguas MC, Warriar RP: Langerhans' cell histiocytosis. *Orthop Clin North Am* 1996;27:615.
289. Villas C, Martinez-Peric R, Barrios RH, et al: Eosinophilic granuloma of the spine with and without vertebra plana: long-term follow-up of six cases. *J Spinal Disord* 1993;6:260.
290. Virchow R: Ueber multiple Exostosen, mit Vorlegung von Präparaten. *Klin Wochenschr* 1891;28:1082.
291. Voutsinas S, Wynne-Davies R: The infrequency of malignant disease in diaphyseal aclasis and neurofibromatosis. *J Med Genet* 1983;20:345.
292. Voytek TM, Ro JY, Edeiken J, et al: Fibrous dysplasia and cemento-ossifying fibroma: a histologic spectrum [see comments]. *Am J Surg Pathol* 1995;19:775.
293. Wang JW, Shih CH, Chen WJ: Osteofibrous dysplasia (ossifying fibroma of long bones): a report of four cases and review of the literature. *Clin Orthop* 1992;278:235.
294. Watanabe H, Arita S, Chigira M: Aetiology of a simple bone cyst: a case report. *Int Orthop* 1994;18:16.
295. Weatherall PT, Maale GE, Mendelsohn DB, et al: Chondroblastoma: classic and confusing appearance at MR imaging. *Radiology* 1994;190:467.
296. Wells DE, Hill A, Lin X, et al: Identification of novel mutations in the human EXT1 tumor suppressor gene. *Hum Genet* 1997;99:612.
297. Wicklund CL, Pauli RM, Johnston D, et al: Natural history study of hereditary multiple exostoses. *Am J Med Genet* 1995;55:43.
298. Willman CL, Busque L, Griffith BB, et al: Langerhans'-cell histiocytosis (histiocytosis X): a clonal proliferative disease [see comments]. *N Engl J Med* 1994;331:154.
299. Wilson AJ, Kyriakos M, Ackerman LV: Chondromyxoid fibroma: radiographic appearance in 38 cases and in a review of the literature [published erratum appears in *Radiology* 1991;180(2):586]. *Radiology* 1991;179:513.
300. Wirganowicz PZ, Watts HG: Surgical risk for elective excision of benign exostoses. *J Pediatr Orthop* 1997;17:455.
301. Wise CA, Clines GA, Massa H, et al: Identification and localization of the gene for EXT1, a third member of the multiple exostoses gene family. *Genome Res* 1997;7:10.
302. Wolfe MW, Halvorson TL, Bennett JT, et al: Chondroblastoma of the patella presenting as knee pain in an adolescent. *Am J Orthop* 1995;24:61.
303. Wood VE, Molitor C, Mudge MK: Hand involvement in multiple hereditary exostosis. *Hand Clin* 1990;6:685.
304. Wright JM, Matayoshi E, Goldstein AP: Bursal osteochondromatosis overlying an osteochondroma of a rib: a case report. *J Bone Joint Surg* 1997;79-A:1085.
305. Wu CT, Inwards CY, O'Laughlin S, et al: Chondromyxoid fibroma of bone: a clinicopathologic review of 278 cases. *Hum Pathol* 1998;29:438.
306. Wu KK: Chondromyxoid fibroma of the foot bones. *J Foot Ankle Surg* 1995;34:513.
307. Wu KK: A surgically treated unicameral (solitary) bone cyst of the talus with a 15-year follow-up. *J Foot Ankle Surg* 1993;32:242.
308. Wuisman PJ, Noorda RJ, Jutte PC: Chondrosarcoma secondary to synovial chondromatosis: report of two cases and a review of the literature. *Arch Orthop Trauma Surg* 1997;116:307.
309. Wuyts W, Van Hul W, De Boule K, et al: Mutations in the EXT1 and EXT2 genes in hereditary multiple exostoses. *Am J Hum Genet* 1998;62:346.
310. Wuyts W, Van Hul W, Wauters J, et al: Positional cloning of a gene involved in hereditary multiple exostoses. *Hum Mol Genet* 1996;5:1547.
311. Yabut SM Jr, Kenan S, Sissions HA, et al: Malignant transformation of fibrous dysplasia: a case report and review of the literature. *Clin Orthop* 1988;228:281.
312. Yalniz E, Er T, Ozyilmaz F: Fibrous dysplasia of the spine with sarcomatous transformation: a case report and review of the literature. *Eur Spine J* 1995;4:372.
313. Yamamura S, Sato K, Sugiura H, et al: Inflammatory reaction in chondroblastoma. *Skeletal Radiol* 1996;25:371.
314. Youssef BA, Haddad MC, Zahrani A, et al: Osteoid osteoma and osteoblastoma: MRI appearances and the significance of ring enhancement. *Eur Radiol* 1996;6:291.
315. Yu GV, Sellers CS: Chondroblastoma of the talus. *J Foot Ankle Surg* 1996;35:72.
316. Zillmer DA, Dorfman HD: Chondromyxoid fibroma of bone: thirty-six cases with clinicopathologic correlation. *Hum Pathol* 1989;20:952.