

Embryology and Genetics of Limb Development, 1745	Congenital Upper Limb Deficiencies, 1782
Classifying Limb Deficiencies, 1747	Acquired Limb Absences, 1790
General Treatment Concepts, 1750	Multilimb Deficiencies, 1796
Congenital Absence of Limbs, 1751	Concepts of Prosthetic Management, 1799
Congenital Lower Limb Deficiencies, 1756	Prosthetic Management of Specific Deficiencies, 1802

## Embryology and Genetics of Limb Development

### NORMAL EMBRYOLOGY

Normal development of the limbs begins at the end of the fourth week after fertilization, with buds forming in the mesoderm along the flank of the embryo (Fig. 32-1).<sup>272</sup> The limbs develop in a proximodistal direction from the limb girdle to the digits. The proximal bones of the limb girdle and the humerus/femur form prior to the differentiation of ridge ectoderm, while development of the remaining bones and digits depends upon the apical ectodermal ridge (AER).<sup>246,276</sup>

The AER, formed by thickening of lateral plate mesoderm, which signals the overlying ectoderm to thicken and establish a ridge over the tip of the limb bud, regulates the proximodistal growth of the limbs (Fig. 32-2). The underlying mesenchyme stimulates and preserves the AER, which maintains the mesenchyme in the distal portion of the limb in an undifferentiated, rapidly proliferating state. The AER causes outgrowth of the limbs, but the mesenchyme determines the type of limb that will develop.<sup>118,320</sup>

The bones and connective tissues of the limbs are formed by lateral plate mesoderm, while the muscles originate from myotome regions of the somitic mesoderm.<sup>243</sup> Forelimb and hindlimb development occurs via similar mechanisms, with upper limb growth preceding lower limb growth by 1 to 2 days. By 6 weeks, as the buds extend distally, the terminal parts of the limbs flatten to form hand- and footplates, complete with distal rays, and cartilage begins to appear in the proximal portions of the limbs. During the seventh week the limbs begin to rotate, with the forelimb turning 90 degrees laterally (positioning the thumb laterally) and the hindlimb turning 90 degrees medially (positioning the big toe medially). Digital rays appear in the hand- and footplates. By the eighth week the limbs have rotated to their final position and all segments are complete, including the digits. During this time, ossification starts. By 12 weeks, ossification centers are present in all of the long bones.<sup>243</sup>

### GENETIC REGULATION OF LIMB DEVELOPMENT

Our present understanding of the genetics involved in the development of human limbs is based primarily on research performed on three experimental models—the fruit fly, the mouse, and the chick.<sup>182</sup>

Fibroblast growth factors (FGFs) play a critical role in limb outgrowth. Recent research has shown that application of FGFs to the flank of chick embryos can stimulate the complete development of extra limbs.<sup>45,104,213</sup> FGFs, which are created by at least eight related genes, act via specific membrane-bound receptors (FGFRs) to transmit their signals. FGF-4 and FGF-8, both of which are present in the AER,<sup>120,302</sup> can substitute for an intact ridge when they are applied exogenously to the mesoderm of limb buds.<sup>185,207</sup> However, overexpression of FGF-8 in chick embryos has resulted in limb abnormalities such as truncations, deletions, and extra digits.<sup>302</sup> In some instances a phenotype similar to achondroplasia was produced in which limb reductions were associated with shortening of all skeletal elements.

The function of the zone of polarizing activity (ZPA), a small block of mesoderm near the posterior edge of the limb close to the body wall, is well known (Fig. 32-3).<sup>243</sup> In normal limbs, as the AER controls distal growth, the ZPA also moves distally as the limb develops, thus maintaining its posterior position near the posterior border of the AER. AER signals promote gene expression in the ZPA. The ZPA is involved in the anteroposterior patterning of the limbs and digits, as was demonstrated when an extra ZPA transplanted to the anterior portion of a normal chick limb resulted in a mirror-image duplication of the digits.<sup>247,277,286</sup>

The polarizing action of the ZPA apparently is mediated by protein produced by the *sonic hedgehog* gene (*Shh*).<sup>231</sup> Hedgehog genes, originally described in *Drosophila*, are a multigene family with diverse signaling functions in higher vertebrates.<sup>113</sup> *Shh* acts as an inductive signal in the development of several tissues; in the limb bud, it is first seen in the ZPA. The ZPA-inductive signal is encoded by *Shh*, which is expressed in the ZPA. *Shh* induces the expression of a cascade of downstream genes (e.g., homeobox genes, bone morphogenetic proteins, *Wnt* genes, *Gli* transcription factors) by binding to its specific receptor, called *patched*.<sup>235</sup>

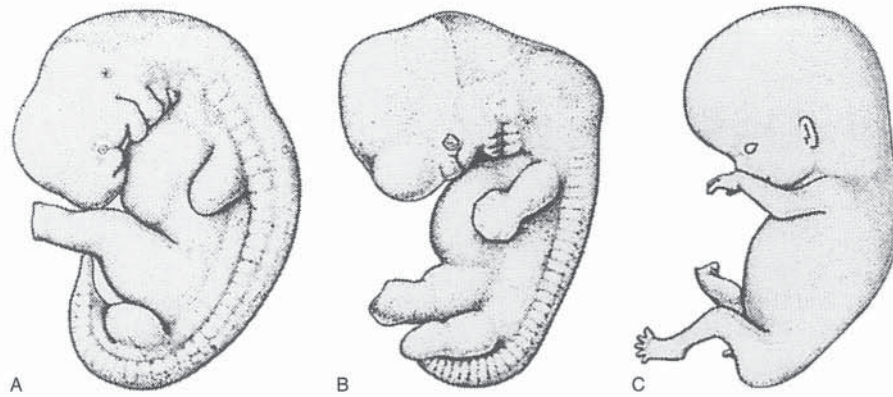


FIGURE 32-1 Limb bud development. A, The limb buds appear at the end of the fourth week post fertilization as mesodermal outpouchings on the flank of the embryo. B, During the sixth week, the terminal portion of each bud flattens to form the hand- and footplates, complete with digital rays. C, By the 12th week, cartilage appears in proximal segments and ossification centers are present in the long bones. (From Sadler TW: Skeletal development. In Langman's Medical Embryology, 7th ed. Baltimore, Williams & Wilkins, 1995.)

FIGURE 32-2 Limb development. *Top left:* Cross section through an embryo. The intermediate mesoderm signals the lateral plate mesoderm to initiate limb development (Am, amnion; YS, yolk sac). *Top right:* The early limb bud. Asterisks indicate the location of the apical ectodermal ridge, which regulates proximodistal growth of the limb bud (F, flank). *Bottom left:* Longitudinal section of the limb bud showing the ectoderm (E) surrounding a core of undifferentiated mesoderm (M). *Bottom right:* Digits are forming following programmed cell death in the AER in the spaces between the digits. Each digit then continues to grow under the influence of its own AER. More tissue between the digits will be removed by programmed cell death. (Images on left from Sadler TW: Skeletal development. In Langman's Medical Embryology, 7th ed. Baltimore, Williams & Wilkins, 1995. Images on right from Sadler TW: Embryology and gene regulation of limb development. In Herring JA, Birch JG (eds): The Child with a Limb Deficiency. Rosemont, IL, American Academy of Orthopaedic Surgeons, 1998.)

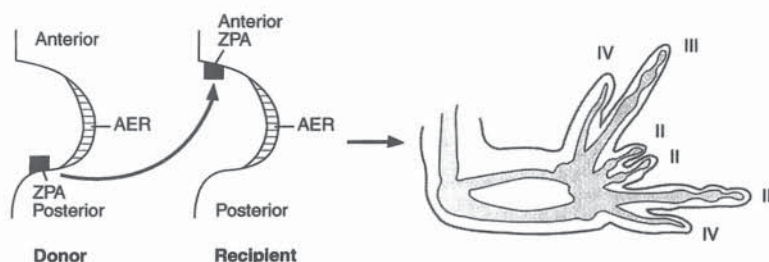
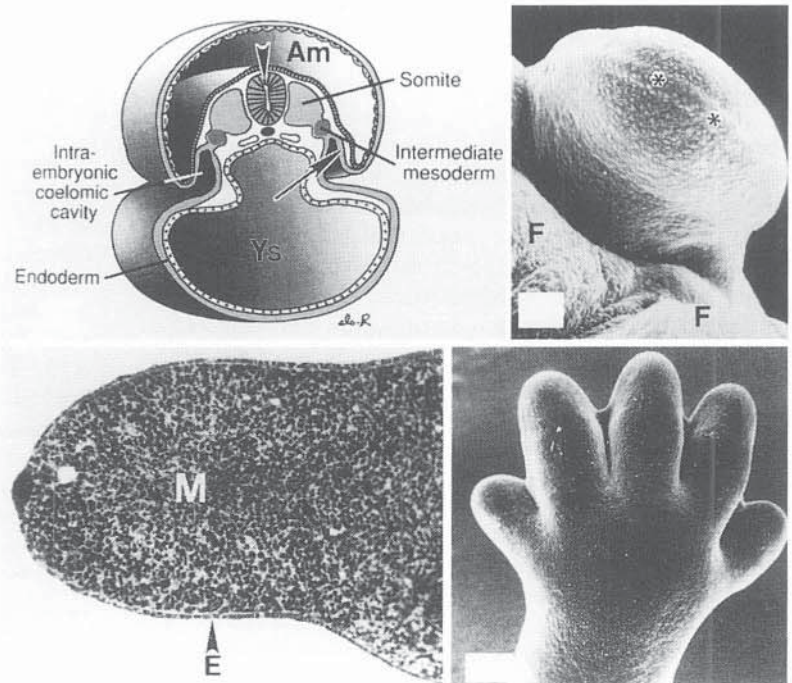


FIGURE 32-3 Regulation of anteroposterior limb development by the zone of polarizing activity (ZPA). The ZPA is a small block of mesoderm near the posterior border of the limb that regulates the anteroposterior patterning of the limb. One of its functions is to cause the digits to appear in proper order. If the ZPA is transplanted into the anterior margin of a normal limb, it will produce a mirror-image duplication of the digits, as shown in the diagram of a chick limb that would normally have three digits. (From Sadler TW: Embryology and gene regulation of limb development. In Herring JA, Birch JG (eds): The Child with a Limb Deficiency. Rosemont, IL, American Academy of Orthopaedic Surgeons, 1998.)

When retinoic acid is placed in the anterior limb mesoderm, it induces expression of *Shh*, and a new ZPA is created.<sup>305</sup> A decrease in *Shh* activity results in the absence of ulnar and posterior digits, while a complete absence of *Shh* results in loss of distal limb structures. Mutations in the human *Shh* gene cause holoprosencephaly (a pleiotropic genetic disorder),<sup>236</sup> an indication of how greatly the gene is involved in the myriad stages of human development. Other hedgehog genes play crucial roles during the later stages of limb development,<sup>113</sup> including the *Indian hedgehog* (*Ihh*) gene, which mediates the rate of cartilage differentiation.<sup>304</sup>

*Homeobox* (*Hox*) genes, which are present in all species, act as transcription factors. In the development of the limbs, *HoxA* genes may contribute to proximodistal patterning,<sup>317</sup> while *HoxD* genes may play a role in anteroposterior patterning.<sup>61</sup>

In research using the rat model, bone morphogenetic proteins (BMPs) were found to have the property of forming ectopic bone after implantation under the skin or muscle.<sup>129,306</sup> The products of BMPs, which are related to the transforming growth factor-beta (TGF- $\beta$ ) family of proteins, take part in fracture healing and in the patterning of joint placement. Three BMP genes—*Bmp-2*, *Bmp-4*, and *Bmp-7*—are expressed within the AER and mesenchyme of developing limb buds.<sup>74,75,166</sup> The role of BMPs in the very early developmental stages of limb buds is uncertain; however, the proteins do seem to have a function in ensuing digit development.<sup>182</sup>

From what is currently known of the genetic control of limb development, a relatively small set of genes and gene

families appears to be involved in the early stages of formation. The developmental programs differ at the morphological level from flies to humans<sup>256</sup>; however, there is extraordinary preservation of the molecular pathways in the various animal groups. In general, humans have more genes in a specific gene family, and these genes are utilized to play variations on a common theme (sometimes in overlapping pathways).<sup>182</sup> The important point is that the molecular theme is maintained from species to species. Continued research on *Drosophila* and transgenic mice will undoubtedly provide further information on this intricate and fascinating process of limb development.

## Classifying Limb Deficiencies

### FRANTZ AND O'RAHILLY CLASSIFICATION SYSTEM

The classification system proposed by Frantz and O'Rahilly in 1961 continues to be a widely used method of grouping congenital skeletal limb deficiencies (Fig. 32–4).<sup>80,107</sup> Extremity anomalies are categorized as either terminal or intercalary deficiencies. *Terminal deficiencies* are those in which the entire segment of a limb distal to and in line with the deficit is absent. *Intercalary deficiencies* are those in which the middle part of a limb is absent but the portions proximal and distal to the affected segment are present. Terminal and intercalary deficiencies may be *transverse*, in which the entire width of the limb is affected (Fig. 32–5), or *paraxial*, in

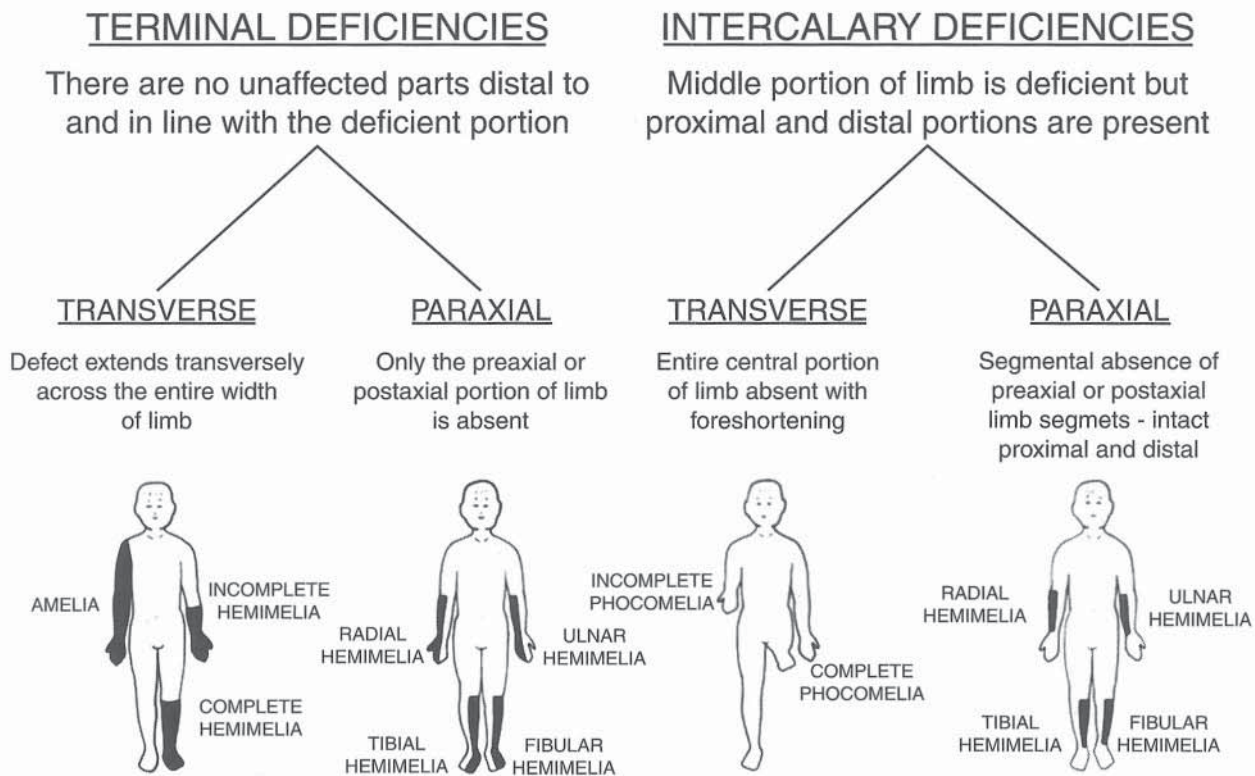


FIGURE 32–4 Frantz and O'Rahilly classification of congenital limb deficiencies. (From Herring JA, Cummings DR: The limb-deficient child. In Morrissy RT, Weinstein SL (eds): Lovell and Winter's Pediatric Orthopaedics, 4th ed, vol 2. Philadelphia, Lippincott-Raven, 1996.)

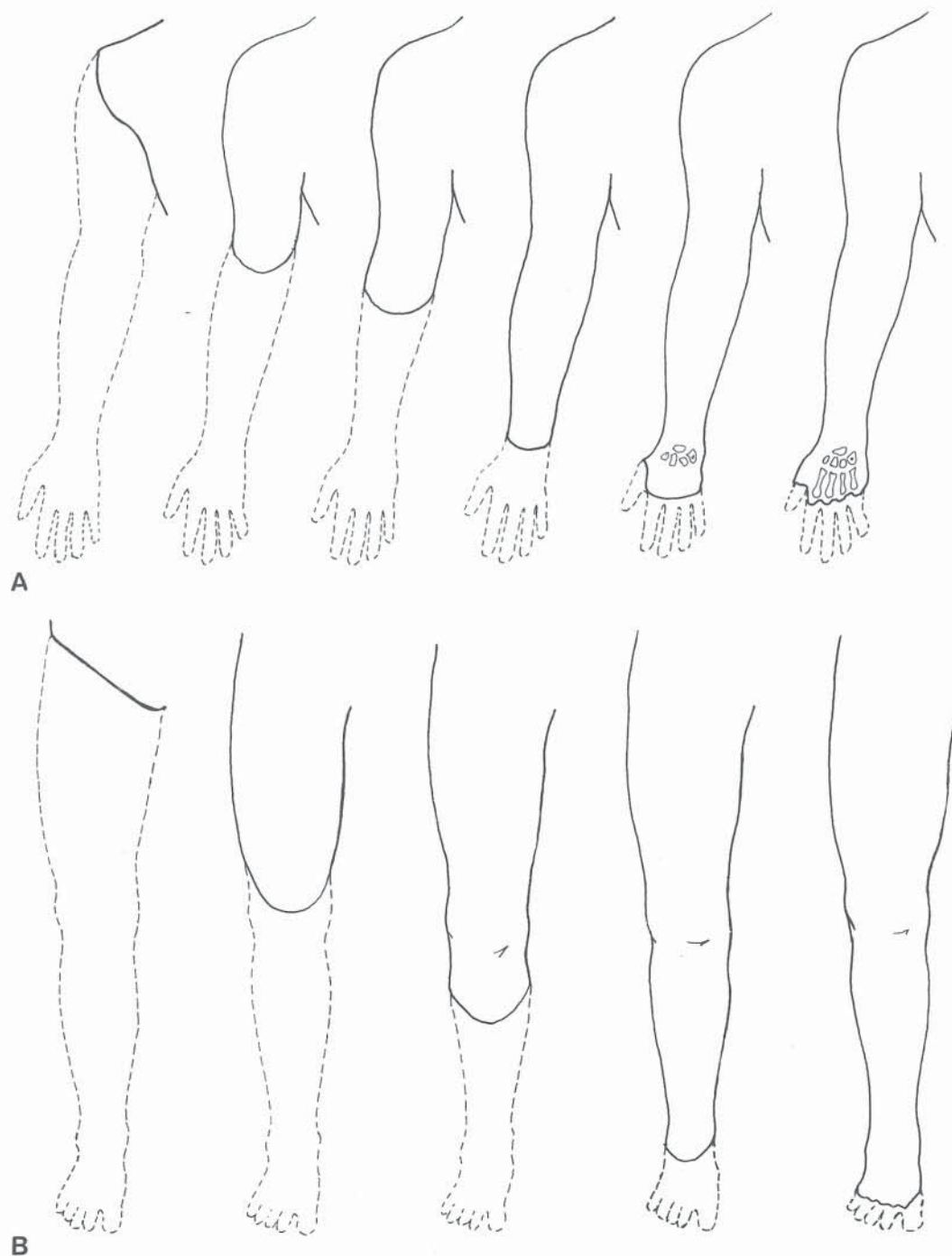


FIGURE 32-5 Spectrum of terminal transverse deficiencies in the upper limb (A) and lower limb (B).

which only the preaxial or postaxial part of the limb is involved (Figs. 32-6 and 32-7).

With *transverse terminal deficiencies*, the defect extends transversely across the entire width of the limb, whereas with *paraxial terminal deficiencies*, only the preaxial or postaxial part of the limb is missing. With *transverse intercalary deficiencies*, the entire middle part of the limb is absent, with foreshortening, whereas with *paraxial intercalary deficiencies*, only segmental portions of the preaxial or postaxial part of the limb are absent, while the proximal and distal portions are present.

### IDENTIFYING SPECIFIC DEFICIENCIES

A glossary of terms associated with limb deficiencies is provided in Table 32-1. *Amelia* is the complete absence of a limb. *Hemimelia*, which means half a limb, is used when one of the paired bones of the upper or lower extremity is absent. The terms *complete* and *incomplete* are applied to hemimelias to indicate absence of all or only part of the affected bone.

Deficiencies are designated according to the anatomic part that is absent. For example, when only the tibia is

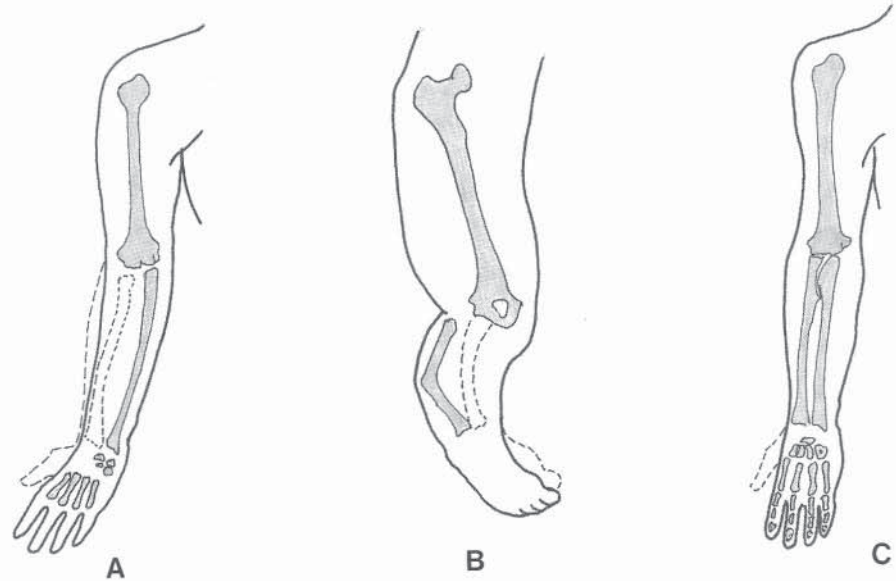


FIGURE 32-6 Preaxial longitudinal deficiencies of the radius (A), tibia (B), and thumb (C).

absent, the deficiency is termed *tibial hemimelia* and is a paraxial defect (rather than transverse) because only the tibial portion of the limb is affected. If the rays of the foot are also absent, the defect is a terminal deficiency, whereas if the foot is present and normal, the defect is an intercalary deficiency.

### ISO/ISPO INTERNATIONAL CLASSIFICATION SYSTEM

An international classification system proposed in 1991 attempts to improve communication among researchers in different countries by standardizing the terminology for congenital deficiencies (Tables 32-2 and 32-3).<sup>56</sup> In the international system, all limb deficiencies are classified as

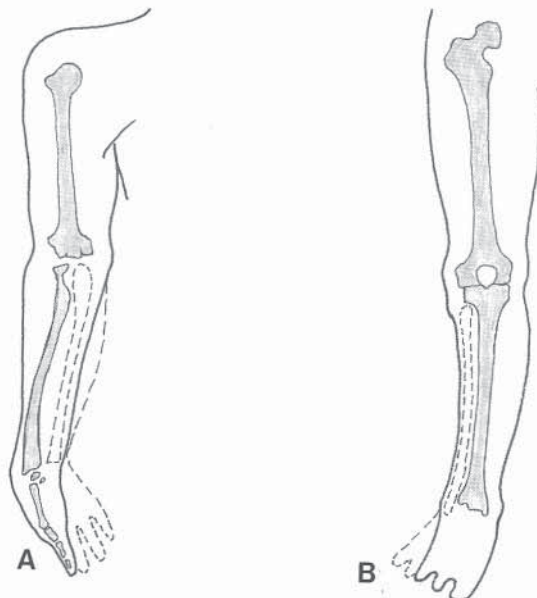


FIGURE 32-7 Postaxial longitudinal deficiencies of the ulna (A) and fibula (B).

TABLE 32-1 Glossary of Terms Used to Define Limb Deficiencies

<b>Acheiria (achiria):</b> Absence of the hand
<b>Acheriopodia:</b> Absence of hands and feet
<b>Adactyly (adactyly):</b> Absence of the fingers or toes
<b>Agensis:</b> Absence or no development
<b>Amelia:</b> Complete absence of a limb
<b>Amelia totalis:</b> Complete absence of all four limbs
<b>Amputation:</b> Absence of a distal part of a limb
<b>Aphalangia:</b> Absence of phalanges
<b>Aplasia:</b> Absence of a specific bone or bones
<b>Apodia:</b> Absence of the foot
<b>Ectrocheiria:</b> Total or partial absence of the hand
<b>Ectrodactyly:</b> Total or partial absence of the fingers or hand
<b>Ectromelia:</b> Total or partial absence of the fingers or hand
<b>Ectrophalangia:</b> Absence of one or more phalanges
<b>Ectropodia:</b> Total or partial absence of the foot
<b>Hemimelia:</b> Absence of one of the paired bones of the limbs
<b>Hypophalangia:</b> Fewer than normal number of phalanges
<b>Intercalary deficiency:</b> Absence of middle portion of limb, while proximal and distal portions are present
<b>Longitudinal deficiency:</b> Absence of limb extending parallel to the long axis (may be preaxial, postaxial, or central)
<b>Meromelia:</b> Partial absence of a limb
<b>Oligodactyly:</b> Absence of some of the fingers
<b>Paraxial deficiency:</b> Only the preaxial or postaxial portion of the limb is affected.
<b>Peromelia:</b> Hemimelia, especially for hands ending in a stump
<b>Phocomelia:</b> In the complete form, the arm and forearm are absent in the upper limb and the thigh and leg are absent in the lower limb (the hands and feet sprout directly from the trunk). The deficiency may be proximal (arms and thighs missing) or distal (forearms and legs missing).
<b>Postaxial:</b> Pertaining to the ulnar side of the upper limb, and the fibular side of the lower limb
<b>Preaxial:</b> Pertaining to the radial side of the upper limb, and the tibial side of the lower limb
<b>Terminal deficiency:</b> Absence of limb with all portions in line with and distal to defect involved
<b>Transverse deficiency:</b> Entire width of the limb is affected.

TABLE 32-2 ISO/ISPO Classification of Congenital Limb Deficiency

**Transverse Deficiencies**

- Limb has developed normally to a particular level beyond which no skeletal elements are present, although there may be digital buds.
- The deficiency is described by naming the segment at which the limb terminates and the level within the segment beyond which no skeletal elements exist.

**Longitudinal Deficiencies**

- Reduction or absence of an element or elements within the long axis of the limb in which there may be normal skeletal elements distal to the affected bone(s).
- The deficiency is described by naming the bones affected in a proximal-distal sequence. Any bone not named is present and normal.
- The affected bone is described as totally or partially absent.
- For partial deficiencies, the approximate fraction and position of the absent part may be stated.
- Number of the digit is stated in relation to a metacarpal, metatarsal, and phalanges, with numbering beginning from preaxial, radial, or tibial side.
- Term *ray* may be used to refer to a metacarpal or metatarsal and its corresponding phalanges.

either *transverse* or *longitudinal*. Missing bones are named and described as either *complete* or *partial* in their absence. These authors of the system theorize that there are no true intercalary deficits, treating such deficits as variable degrees of longitudinal deficiencies.

In the ISO/ISPO classification system transverse deficiencies are named according to the level of absence (Table 32-4). Thus, a short congenital below-elbow absence is termed transverse right Fo (forearm), upper, whereas an elbow disarticulation level is a transverse deficiency, right Fo, complete. Longitudinal deficiencies are named for the missing parts, and parts not named are assumed to be present (Table 32-5). For example a fibular hemimelia is described as a complete deficiency, Fi (fibula), implying a

TABLE 32-4 Identification of Transverse Limb Deficiencies (Congenital Amputations)

Upper Limb (UL)	Lower Limb (LL)	Level of Absence
Arm (Ar) or forearm (Fo)	Thigh (Th) or leg (Le)	Complete, upper $\frac{1}{3}$ , middle $\frac{1}{3}$ , or lower $\frac{1}{3}$
Carpal (Ca), metacarpal (MC) Phalangeal (Ph)	Tarsal (Ta), metatarsal (MT) Phalangeal (Ph)	Complete or partial

normal foot. If the lateral two rays are also missing, one adds MT (metatarsal) 4, 5, Ph (phalanges) 4, 5 to designate such a condition. Although the terminology is laudable for its anatomic accuracy, the lengthy designations have limited its general acceptance.

## General Treatment Concepts

### TIMING OF TREATMENT

The timing of nonsurgical and surgical corrections of limb deficiencies should accord with the child's developmental milestones. For example, at about 6 months of age, most children are able to sit well, put both hands together in the midline, and begin performing two-handed maneuvers. This is the best time to fit a child with a prosthesis for an upper limb deficiency. The child's ability to adapt to the prosthesis is enhanced because he or she can start using it in apposition with the other hand at an early stage.

For many lower limb deficiencies, surgical interventions should be planned early and completed, if possible, before the child starts to walk. This allows time for the wound to heal properly and for a prosthesis to be fitted when the child starts to walk, which is normally at about 12 months of age.

TABLE 32-3 Comparison of Standard and ISO/ISPO Terminology

Standard	ISO/ISPO
Congenital "Chopart" amputation	Transverse, tarsal, partial
Congenital absence of forefoot	Transverse, metatarsal, complete
Congenital "Symes"	Transverse, tarsal, complete
Congenital below-knee, long	Transverse, leg, lower third
Congenital below-knee, short	Transverse, leg, upper third
Congenital knee disarticulation	Transverse, leg, complete
Congenital above-knee, short	Transverse, thigh, upper third
Congenital hip disarticulation	Transverse, thigh, complete
Upper limb amelia, no scapula	Transverse, shoulder, complete
Upper limb amelia, scapula present	Transverse, forearm, upper third
Congenital below-elbow, long	Transverse, forearm, lower third
Congenital wrist disarticulation	Transverse, carpal, complete
Congenital partial hand (with carpals)	Transverse, carpal, partial
Congenital partial hand (with metatarsals)	Transverse, phalangeal, complete
Fibular hemimelia (foot unaffected)	Longitudinal, fibular, complete
Partial fibular hemimelia	Longitudinal, fibular, partial
Tibial hemimelia	Longitudinal, tibial, complete
Absent tibia and first two toes	Longitudinal, tibial, complete; rays 1, 2
Absent radius, ulna (index finger present)	Longitudinal, radius and ulna, complete; carpals, complete; rays 1, 3, 4, and 5, complete
Upper limb phocomelia (hand intact, scapula present)	Longitudinal, humerus, complete; radius and ulna, complete
Clavicle absent, humerus short, radius short, ulna absent, carpals absent, fifth finger absent	Longitudinal, clavicle, complete; humerus, partial; radius, partial; ulna, complete; ray 5

**TABLE 32–5 Identification of Partial or Complete Longitudinal Deficiencies**

<b>Upper Limb (UL)</b>	
Proximal:	Humeral (Hu)
Distal:	Radial (Ra); central (Ce); ulnar (Ul); carpal (Ca); metacarpal (MC) 1, 2, 3, 4, 5; phalangeal (Ph) 1, 2, 3, 4, 5
Combined:	Radial (Ra); humeral (Hu); ulnar (Ul); carpal (Ca); metacarpal (MC) 1, 2, 3, 4, 5; phalangeal (Ph) 1, 2, 3, 4, 5
<b>Lower Limb (LL)</b>	
Proximal:	Femoral (Fe)
Distal:	Tibial (Ti); central (Ce); fibular (Fi); tarsal (Ta); metatarsal (MT) 1, 2, 3, 4, 5; phalangeal (Ph) 1, 2, 3, 4, 5
Combined:	Tibial (Ti); femoral (Fe); fibular (Fi); tarsal (Ta); metatarsal (MT) 1, 2, 3, 4, 5; phalangeal (Ph) 1, 2, 3, 4, 5

For example, a Syme amputation for fibular hemimelia is best performed at about age 10 months, when the child is beginning to stand.

The child's developing anatomy is another important factor influencing the timing of surgical interventions. The correction of some lower limb deficiencies is best maintained with weightbearing, and the surgery should be performed after the child has started walking. An amputation to correct a proximal focal femoral deficiency (PFFD) may be performed when the child is young, but knee fusion is more easily performed when the femoral condyles and proximal tibia have sufficiently ossified (at about 4 to 5 years). Alternatively, the child may be treated initially with an equinus prosthesis to allow ambulation, followed by amputation and knee fusion at 3 to 4 years of age. In a patient with a partial tibial hemimelia, fusion of the proximal tibia to the fibula is more easily achieved after the tibial anlage has adequately ossified than while it is still primarily cartilaginous in nature.

## **SOCIAL FACTORS**

For children and adolescents, many important social factors also come into play when deciding on intervention to treat limb deficiencies. For example, a young child may discard an upper extremity prosthesis and later request one when starting school. When planning surgery, the surgeon should allow sufficient recovery time after the operation so that the child does not have to enter a new school still walking on crutches. For the adolescent, every attempt should be made to minimize any embarrassments, such as having to go to school without a prosthesis.

## **LONG-TERM PLANNING**

Difficult decisions often have to be made regarding the best long-term plans for the child. This is especially true when there is a choice between a prolonged course of multiple corrective procedures and a less involved, early, single intervention such as amputation. Such a dilemma typically arises in the child with fibular hemimelia.<sup>39</sup>

If a Syme amputation is performed just before the patient starts walking, the child will most likely not face any additional operations or hospitalizations for the deformity and

will be able to function at a nearly normal level in sports activities. However, the child will have to deal with wearing a prosthesis in place of a foot.

An alternative approach is to use modern limb lengthening techniques to correct the deformity, which will maintain the limb and minimize or eliminate the need for a prosthesis.<sup>310</sup> However, limb lengthening requires that the child endure two or three future periods in an external apparatus (each of which may last 6 months or longer) for a successful outcome, the procedures are often difficult and painful, and the social and psychological costs of these interventions can be substantial.<sup>88,125,84,202</sup> Of 56 patients treated by limb lengthening procedures at Texas Scottish Rite Hospital for Children between 1989 and 1996, almost 50 percent experienced deterioration in mental status, with most suffering from depression.<sup>202</sup> Almost half of the patients experienced moderate to severe pain at some time during the lengthening process. The medical outcome was compromised in approximately one-fifth of patients because of a psychological or behavioral factor, particularly noncompliance with exercise and a decline in mental status. In addition to arranging for psychological counseling, the orthopaedist should aggressively treat any pain, sleep, or appetite problems a patient experiences during lengthening and reconstruction.<sup>202</sup>

Although the anatomic results of lengthening procedures are well known, long-term functional assessments of patients who have undergone such procedures are not available. Thus, Damsin and associates make a good point when they state that “surgeons should remain humble and wise during decision making” and “not yield to the temptation offered by a brilliant equalization procedure.”<sup>52</sup> Whenever a choice must be made between amputation and lengthening, the role of the orthopaedist is to make sure that the patient and the parents are fully aware of the risks and benefits of the different choices available. In that way, informed decisions can be made based on knowledge and realistic expectations, not ignorance or wishful thinking. This may be best accomplished by introducing the child and family to another child and family who have had to make similar decisions.

## **Congenital Absence of Limbs**

### **TIMING OF LIMB MALFORMATIONS AND DEFORMATIONS**

By 7 weeks of embryonic life, all parts of the upper and lower limbs are essentially completely formed. Most limb deficiencies occur early in the period of limb morphogenesis, when there is rapid proliferation and differentiation of cells and tissues. This “sensitive period” of limb formation peaks during the fifth and sixth weeks after fertilization.<sup>243</sup> Thus, major malformations (such as absence of a long bone) appear by 7 weeks of fetal development. Major upper limb deficiencies occur at 28 days, major lower limb deficiencies at 31 days, distal upper abnormalities on the 35th day, and distal lower limb deformities on the 37th day.<sup>85</sup> Depending on the timing and severity of the insult, abnormalities develop in a predictable manner.<sup>122</sup> On the other hand, deformations—changes in formed structures due to external forces—may, unlike malformations, occur at any time during fetal development. Distal deformity secondary to a con-

stricting amniotic band is an example of a deformation (Fig. 32–8).

### ETIOLOGY OF LIMB ABSENCES

Advances in molecular biology have provided new information on the genes and gene products responsible for coordinating normal limb development. This knowledge has enabled scientists to better identify genes that might be responsible directly for limb defects or indirectly through the effects of teratogens.

At this time, however, the specific cause of congenital limb deficiencies is unknown in most cases. Although there are a few limb abnormalities with genetic bases, most limb deformities develop sporadically, with no identifiable environmental factors, trauma, or familial incidence. Most single-limb anomalies have a very small chance of recurring in subsequent children of the same parents or in the children of the affected person. The incidence of recurrence of the same anomaly—1 to 3 percent—is only slightly greater than in the general population.

In a population-based review of birth defects in Norway, Lie and associates reported that in families in which children had limb abnormalities, a second child had a significantly greater chance of being born with a similar anomaly compared with the expected rate in the general population.<sup>173</sup> However, they also noted that the risk of a birth defect in subsequent children decreased when the mother moved to another part of the country after the first child was born, which suggests an environmental influence.

Many drugs are known teratogens; however, the only drug specifically identified with a large number of limb abnormalities is thalidomide.<sup>77,78,123,190,200</sup> If the mother took drugs or was exposed to potential teratogens during her pregnancy, a complete history should be obtained to help determine the developmental stage of the fetus during the time of exposure.

Amniotic bands (Streeter band syndrome or congenital constriction band syndrome) are another potential cause of

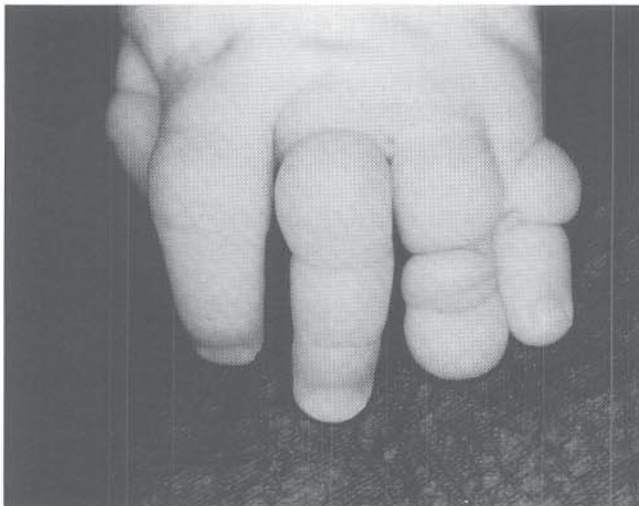


FIGURE 32–8 Amniotic bands caused the ringlike constrictions in this child's hand. (From Herring JA, Cummings DR: *The limb-deficient child*. In Morrissy RT, Weinstein SL (eds): *Lovell and Winter's Pediatric Orthopaedics*, 4th ed, vol 2. Philadelphia, Lippincott-Raven, 1996.)

prenatal limb amputations (see Fig. 32–8). Early compression of the embryo is believed to cause early rupture of the amniotic membrane, with subsequent formation of aberrant amnion bands (strands) that can disrupt structures in the craniofacial area, abdominal wall, or limbs.<sup>142</sup> When these bands of tissue form constriction rings around different parts of the limbs, they can impede venous drainage (resulting in edema), remain as deep clefts in the soft tissue, or completely amputate parts of the limb distal to the band. It is uncommon for only one limb to be affected. In most cases, early intrauterine disturbance of the limb bud results in failure of the limbs to develop further.<sup>95</sup> It has been estimated that this syndrome usually occurs at about 6 weeks of fetal development.<sup>147</sup>

### HERITABLE LIMB DEFICIENCIES AND ASSOCIATED ANOMALIES

Upper limb deficiencies are more likely to have associated abnormalities (particularly in patients with genetic disorders), with humeral defects the most predictive of concomitant anomalies.<sup>315</sup>

*Poland's syndrome* consists of unilateral absence of the pectoralis minor and the sternal portion of the pectoralis major muscles with some type of coexisting ipsilateral hand abnormalities, including hypoplasia of the hand and digits with syndactyly, brachydactyly, and reduction deformities.<sup>183</sup>

Patients with *thrombocytopenia-absent radius (TAR) syndrome* usually have unilateral or bilateral absence or hypoplasia of the radius, along with a radially clubbed hand, deformed or absent thumb, and hypoplasia of the ulna (Fig. 32–9).<sup>110</sup> Associated anomalies include short stature, strabismus, micrognathia, dislocated hip, clubfoot, congenital heart disease, foreshortened humeri and hypoplastic shoulder girdles, and occasionally lower limb deformities. This syndrome requires prompt diagnosis and treatment in the neonatal period, as hematologic problems may cause central nervous system damage secondary to intraventricular bleeding. Platelet transfusion is often necessary.

In *Fanconi's pancytopenia syndrome*, dysmorphic and limb reduction defects vary considerably, with skeletal abnormalities including absent or hypoplastic thumbs, hypoplastic radius, and developmental dysplasia of the hip (DDH).<sup>94</sup> The patient is born with the limb defects, is relatively small at birth, and usually has patchy brown discoloration of the skin. Some infants may only have hematologic disorders (e.g., bleeding, pallor, recurrent infections), which usually manifest between ages 5 and 10 years and can be treated with testosterone and hydrocortisone analog therapy.<sup>254</sup> Associated anomalies include cardiac, urogenital, and eye abnormalities and a predisposition to leukemia.

*Holt-Oram (hand-heart) syndrome* consists of upper limb deformities ranging from partial or complete absence of the thumb or radial aplasia, to a radially clubbed hand with or without elbow function, to severe hypoplasia of the forearm and defects of the humerus, clavicle, scapula, or sternum.<sup>130</sup> Associated anomalies include cardiac defects (e.g., atrial septal defect, ventricular septal defects, tetralogy of Fallot) and vertebral defects (e.g., scoliosis, pectus excavatum). The syndrome usually is bilateral but asymmetric.

Anomalies associated with the *VATER association* include vertebral defects, imperforate anus, tracheoesophageal fis-



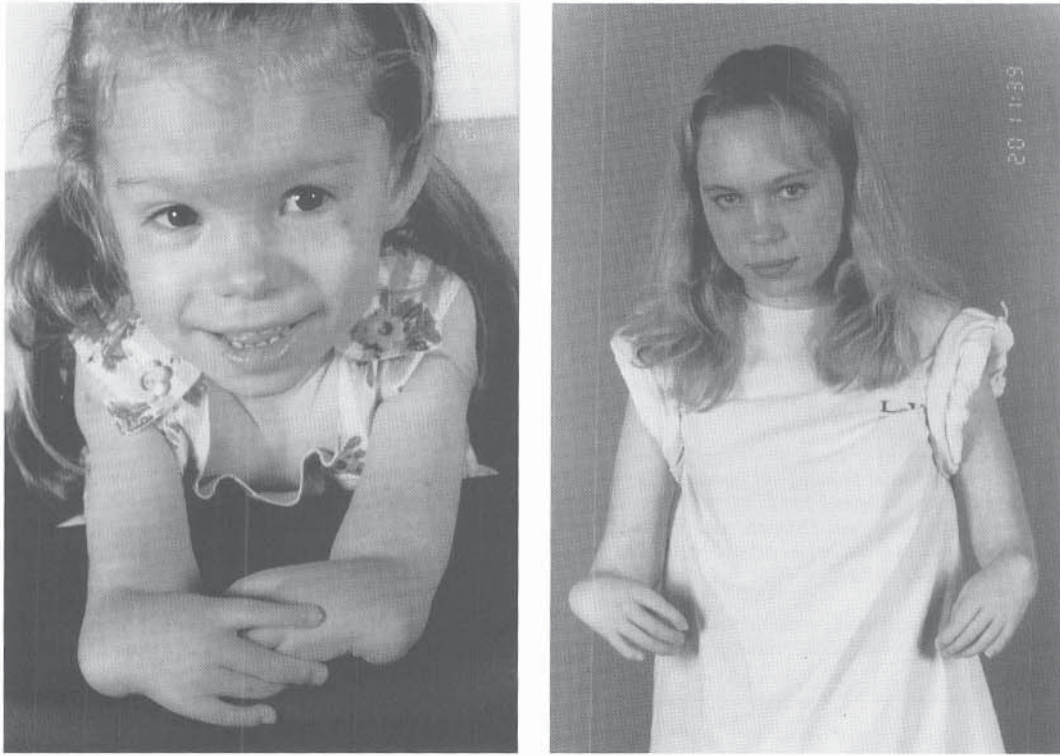

FIGURE 32-9 Patients with thrombocytopenia-absent radius (TAR) syndrome.

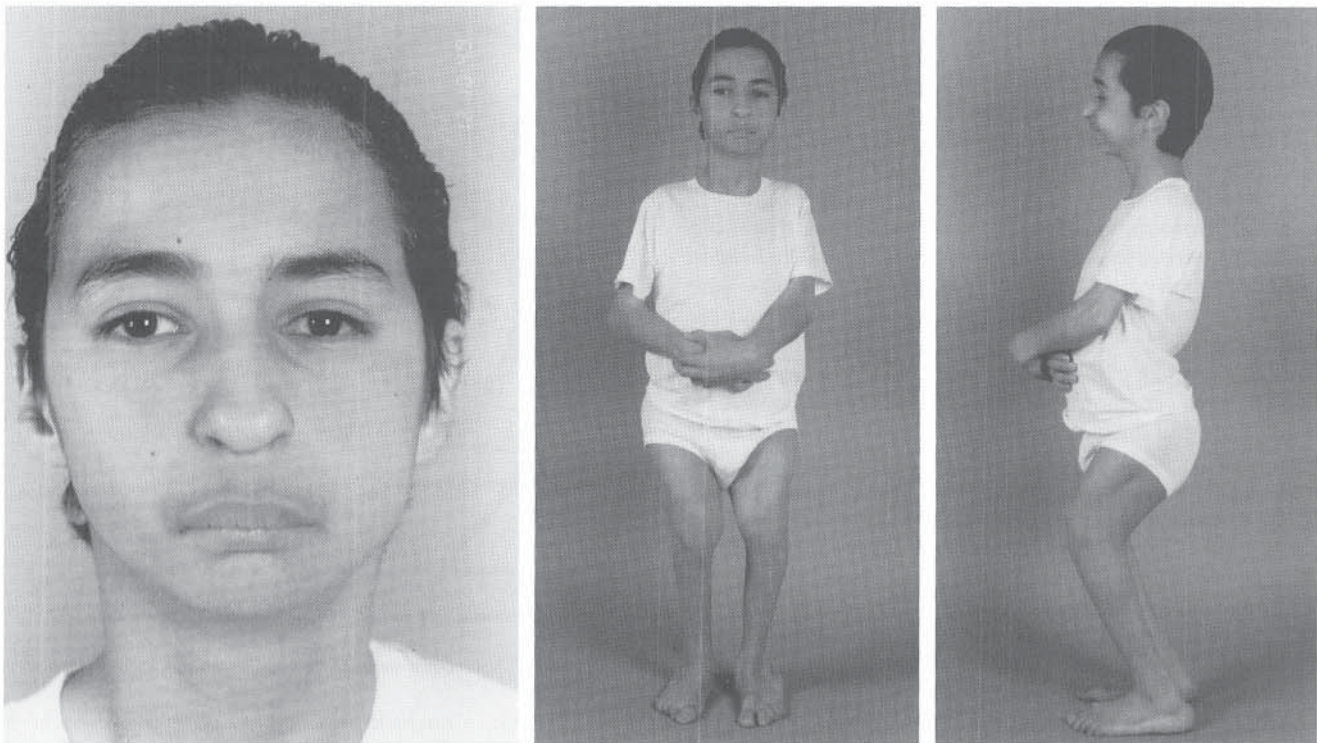


FIGURE 32-10 Patient with femoral hypoplasia-unusual facies syndrome.

TABLE 32-6 Heritable Limb Deficiencies

- Longitudinal deficiencies—preaxial, radial, and tibial
  - Fanconi's pancytopenia syndrome (autosomal recessive)—upper limb deficiencies of thumb and radius, with occasional developmental dysplasia of the hip (DDH). Associated anomalies include cardiac, urogenital, and eye abnormalities, and predisposition to leukemia.
  - Thrombocytopenia-absent radius (TAR) syndrome (autosomal recessive)—radial aplasia or hypoplasia with radially clubbed hand, deformed or absent thumb, and hypoplasia of the ulna. Associated anomalies include short stature, congenital heart disease, foreshortened humeri and hypoplastic shoulder girdles, strabismus, micrognathia, dislocated hip, clubfoot, and occasional lower limb deficiency.
- Longitudinal deficiencies—postaxial, ulnar, and fibular
  - Isolated ectrodactyly (autosomal dominant)—deficiency of central rays of both hands and feet. May be difficult to differentiate from autosomal recessive ectrodactyly because of incomplete penetrance.
- Longitudinal deficiencies—intercalary, sometimes phocomelic; middle segment
  - Holt-Oram syndrome (autosomal dominant)—upper limb deficiencies ranging from partial or complete absence of the thumb, radial aplasia, radially clubbed hand with or without elbow function to severe hypoplasia of entire forearm and defects of humerus, clavicle, scapula, or sternum. Associated anomalies include cardiac and vertebral defects.
- Tibial aplasias
  - Tibial absence with polydactyly (autosomal dominant)—tibial deficiency with duplications of radial ray. Associated anomalies include cardiac defects.

tula with esophageal atresia, and radial and renal dysplasia.<sup>225</sup> The more current nomenclature, *VACTERL*, includes cardiac anomalies and separates renal and limb abnormalities.<sup>254</sup> Patients may also have deficient prenatal growth, a single umbilical artery, and defects of the external genitalia. The cause of this condition is not known, and malformation patterns tend to be sporadic, but a greater frequency has been noted in children of diabetic mothers.<sup>254</sup>

Amelia has been associated with omphalocele and diaphragmatic hernia, and radial ray deficiencies have been associated with cardiac anomalies and imperforate anus.<sup>82-84</sup>

*Tibial hemimelia* is one of the few lower limb deficiencies in which a heritable pattern is often seen.<sup>151,241</sup> In the *femoral hypoplasia-unusual facies syndrome* (Fig. 32-10), the limb deficiencies can range from a hypoplastic femur to an absent femur and fibula.<sup>263</sup> The humerus may also be affected, producing restricted elbow motion, and deformities may be seen in the lower spine and pelvis. Defects can be unilateral or bilateral. The distinct facial characteristics include a short nose with hypoplastic alae nasi, long philtrum and thin upper lip, micrognathia, cleft palate, and upward slanting of the palpebral fissures. The *ulnar-femoral syndrome* (a combination of femoral deficiency and ulnar abnormalities) also may be inherited. Some of the more common heritable limb deficiencies are listed in Table 32-6.

Whenever a child has a limb deficiency, the physician should carefully assess the craniofacial, cardiac, gastrointestinal, genitourinary, integumentary, and nervous systems. Peripheral blood cell counts, urinalysis, skeletal radiographs, hearing, visual acuity, and growth should be monitored regularly during infancy and early childhood until it is obvious that the limb deficiency is an isolated event.<sup>315</sup> If there is a family history of an abnormality and the disorder resem-

bles that known to have a genetic cause, the parents should be provided with appropriate genetic counseling.

### THE SUBCLAVIAN ARTERY SUPPLY DISRUPTION SEQUENCE HYPOTHESIS

A vascular etiology has been proposed for patients with Poland's, Klippel-Feil, and Möbius syndromes, terminal transverse limb defects, and Sprengel's anomaly.<sup>20</sup> According to this hypothesis, these conditions are caused by interruption of the early embryonic blood supply in the subclavian or vertebral arteries or their branches during the fifth through eighth weeks of fetal development (Figs. 32-11 and 32-12). Vascular disruption in the subclavian artery could be due to internal obstruction of the vessel from edema, thrombi, or emboli or to obstruction secondary to external pressure on the vessel from tissue edema, local hemorrhage, a cervical rib, an aberrant muscle, an amniotic band, tumor, or embryonic intrauterine compression.<sup>20</sup> Exogenous factors (e.g., drugs, chemicals, generalized hypoxia, hyperthermia) could cause premature regression of vessels or a delay in vessel development.<sup>20</sup>

The specific anomaly seen depends on the blockage site, the extent and timing of the blockage, and the length of time of the interruption. Disruptions of specific arteries and their likely subsequent effects are listed in Table 32-7.

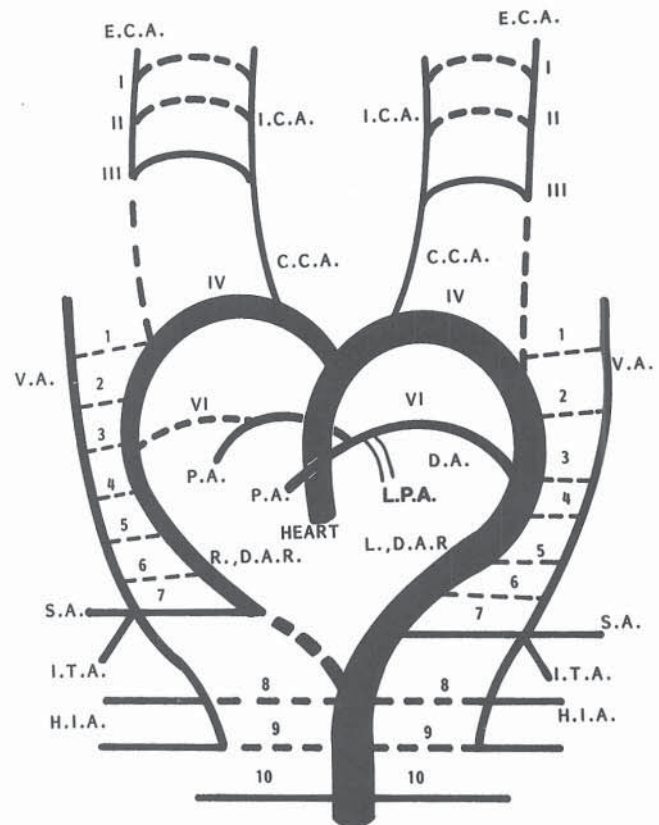


FIGURE 32-11 A schematic diagram of the many components of the aortic arch complex. The dotted lines represent vessels that do not persist in the adult. (From Bavink JN, Weaver DD: Subclavian artery supply disruption sequence: hypothesis of a vascular etiology for Poland, Klippel-Feil, and Möbius anomalies. *Am J Med Genet* 1986;23:903. Reprinted by permission of Wiley-Liss Inc, a subsidiary of John Wiley & Sons, Inc.)

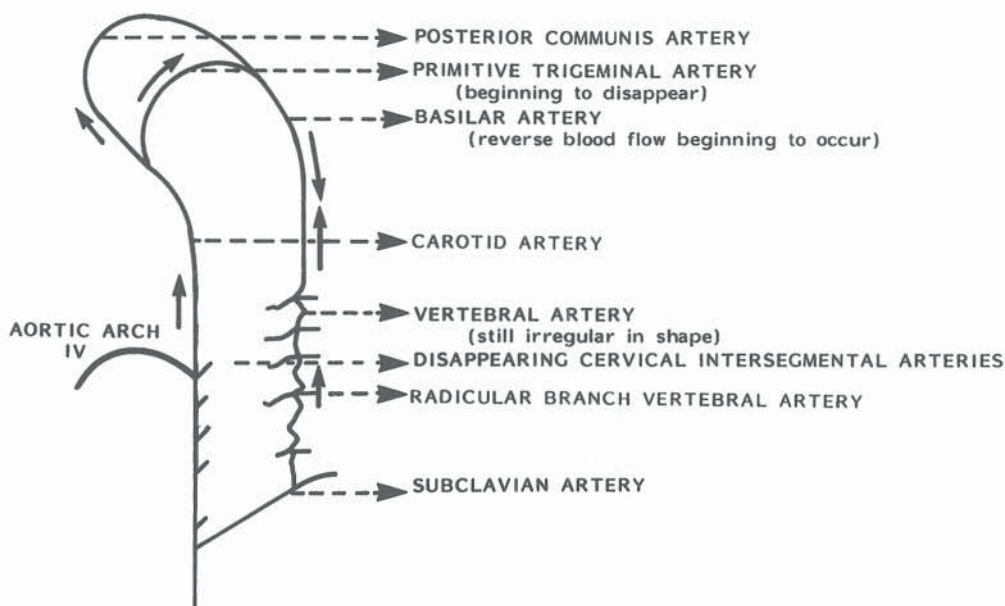


FIGURE 32–12 Major blood supply to the head and neck at 42 days of fetal development. The proximal portions of the first six cervical intersegmental arteries have regressed and disappeared. The subclavian artery has developed from the seven intersegmental arteries. (From Bavincck JN, Weaver DD: Subclavian artery supply disruption sequence: hypothesis of a vascular etiology for Poland, Klippel-Feil, and Möbius anomalies. *Am J Med Genet* 1986;23:903. Reprinted by permission of Wiley-Liss Inc, a subsidiary of John Wiley & Sons, Inc.)

Various combinations of obstructions of the subclavian and/or branch arteries could account for the overlapping clinical features seen in patients with Poland's, Möbius, and Klippel-Feil syndromes, terminal transverse limb defects, and Sprengel's anomalies (Fig. 32–13).<sup>311</sup> The different patterns of vertebral abnormalities associated with Klippel-Feil syndrome may be due to variations in the location and extent of arterial interruption. The pathologic changes seen in Möbius syndrome may result from ischemia secondary to premature regression of early brain vessels or transient blockage of the basilar and/or vertebral arteries.<sup>174,267</sup> Interruption of the blood supply from one or more of the internal thoracic arteries during embryonic development could result

in the absence or hypoplasia of structures in the upper chest area.

The degree of upper limb deficiency seen in patients with terminal transverse limb defects (as an isolated defect or in association with Klippel-Feil, Poland's, or Möbius syndromes) can vary from very mild (e.g., a slightly smaller hand, with no disability) to severe (e.g., a significant reduction in the size of the hand and forearm, with no functional hand). The severity of the defect depends on the timing of the vascular interruption—the earlier the occurrence, the more severe is the abnormality.<sup>311</sup> Chorionic villous sampling (CVS) is typically performed 8 to 12 weeks following the last menstrual period, the same time that limb and hand development takes place. Limb defects related to CVS trauma may be due to interruption of the subclavian or other arteries or to some other vascular event.<sup>313</sup> Poland's syndrome may affect either side but usually is not bilateral, which might lead to death in utero. When the left side is affected, there is about a 10 percent likelihood of concomitant dextrocardia,<sup>44</sup> which supports the premise that abnormal vascular development is the cause of Poland's syndrome.<sup>311</sup>

TABLE 32–7 Subclavian Artery Supply Disruption Sequence

Obstructed Artery	Subsequent Anomaly
Internal thoracic artery	Ipsilateral absence of costosternal heads of pectoralis major, and hypoplasia or aplasia of breast
Subclavian artery (distal to origin of internal thoracic artery)	Isolated terminal transverse limb defects
Subclavian artery (proximal to internal thoracic artery but distal to vertebral artery)	Poland's syndrome
At origin or at any segment along developing vertebral artery and/or radicular branches	Klippel-Feil syndrome
One or more early arteries of brain, and/or basilar or vertebral arteries	Möbius syndrome
Subclavian, internal thoracic, and/or suprascapular artery	Sprengel's anomaly—hypoplasia of scapula and lack of development of upper portion of serratus anterior

## PSYCHOSOCIAL ISSUES

When a child is born with a significant abnormality, such as absence of one or more limbs, the event represents a profound loss to the family and normally requires a time of grieving. During this period the orthopaedist must deal sympathetically with family members and encourage them to work through their feelings of disappointment.<sup>99,239,282,293</sup> In many cases these early “wounds” are best healed by the child with the abnormality.

Children with limb abnormalities are just as responsive and interactive as other children, and most have normal

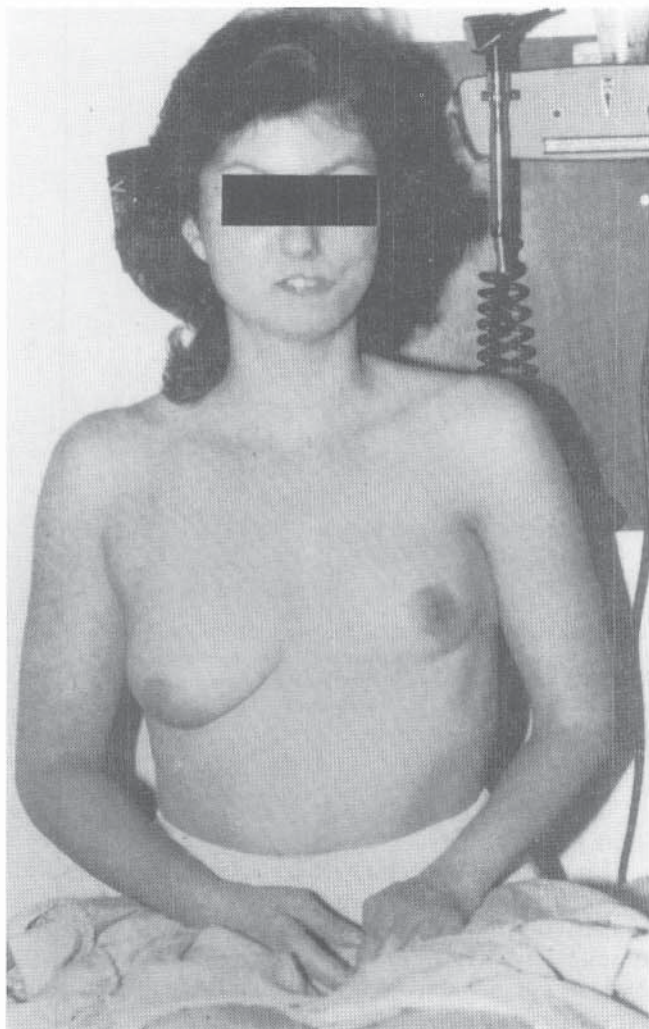


FIGURE 32–13 Woman with Poland's and Möbius syndromes, probably secondary to a subclavian artery disruption sequence. (From Weaver DD: Vascular etiology of limb defects: the subclavian artery supply disruption sequence. In Herring JA, Birch JG (eds): *The Child with a Limb Deficiency*. Rosemont, IL, American Academy of Orthopaedic Surgeons, 1998.)

intellects. The degree of limb deficiency has not been found to be associated with depressive symptoms, anxiety, or behavioral problems in children and adolescents with limb absences.<sup>292,294,296</sup> The degree of limb loss also does not affect the general self-esteem of children<sup>291,293</sup>; however, it can adversely affect adolescents' self-esteem.<sup>292,295</sup>

The child's achievement of early developmental milestones helps the family direct its attention to the positive aspects of the child's future. Children with congenital abnormalities do not have a feeling of loss and thus do not require an adjustment period. They are able to make extraordinary adaptations to achieve milestones and perform normal daily activities.<sup>238</sup> Their development of gross motor skills may not follow the "normal" expected pattern—for example, they may roll early, sit late, and never crawl—but individual modifications should not be misconstrued as evidence of developmental delay.<sup>42</sup> Even those with multiple congenital limb deficiencies may achieve nearly normal physical function by using whatever limb components they have in place of those that are missing (Fig. 32–14).

It is important for the clinician to explain to the parents early on what can and cannot be done to improve the child's situation. The parents' primary concerns often are not the same as those of the medical team. Usually the parents are most anxious about the child's appearance and how others perceive the abnormality, whereas the medical team is concerned with the functional capabilities of the patient.

The possibility of medical breakthroughs in the future that might be of benefit to the child should be discussed with parents. The physician needs to help parents distinguish between probable medical advances that hold promise and those that clearly represent impossible hopes. Undoubtedly, nonoperative and operative treatment methods will improve dramatically over the child's lifetime, but fundamental biologic principles will likely remain the same.

In all cases, the long-term interests of the child must be the primary concern. If the child has a moderate abnormality, such as a partial fibular hemimelia, the foot should be saved and any corrections should be done when the child is older, even though the condition may present a challenge prior to treatment. However, if there is complete absence of the tibia with the usual concomitant unstable knee and ankle, trying to save the foot because someday it may be possible to implant a tibial allograft will result in significant developmental delay. In this case, the consequence of delaying appropriate treatment carries too high a price for the child.

## Congenital Lower Limb Deficiencies

### PROXIMAL FOCAL FEMORAL DEFICIENCY

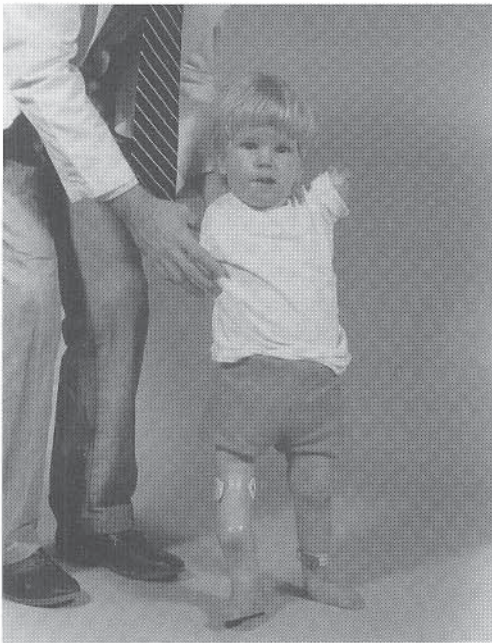
Proximal focal femoral deficiency is one of several terms used to describe a deformity in which the femur is shorter than normal and there is apparent discontinuity between the femoral neck and shaft. In many cases the defect in the proximal femur will ossify as the child grows older. A congenitally short femur without radiographic evidence of an ossification defect is most likely a less severe form of femoral deficiency.<sup>111</sup> In most cases the cause of the femoral deficiency is unknown. The disorder normally does not have a genetic link, although the combination of femoral deficiency and abnormal facies (femoral hypoplasia-unusual facies syndrome) is believed to be an autosomal dominant malformation.<sup>141</sup>

### Classifications of Femoral Deficiency

**AITKEN CLASSIFICATION.** The Aitken classification system has some clinical relevance and is the most widely used system for classifying femoral deficiencies.<sup>10</sup> PFFDs are categorized as type A, B, C, or D (Figs. 32–15 to 32–17).

In type A PFFD, radiographs of the young child reveal a defect in the upper femur that ossifies as the child matures. The femoral head is present and the acetabulum is well formed. A pseudarthrosis in the subtrochanteric area normally resolves by the time the patient reaches skeletal maturity. A varus deformity of the upper segment of the femur, which can vary in severity, usually is present, and the shaft of the femur may be positioned above the femoral head.

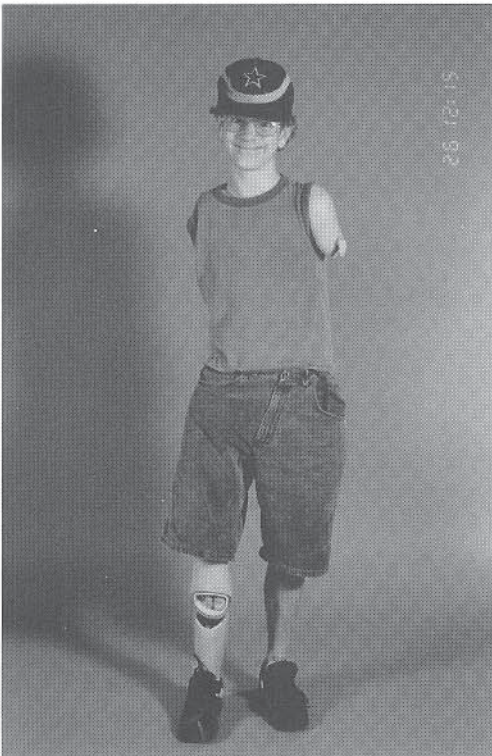
In type B deficiencies, the femoral portion of the limb is shorter than in type A, a tuft is often present at the



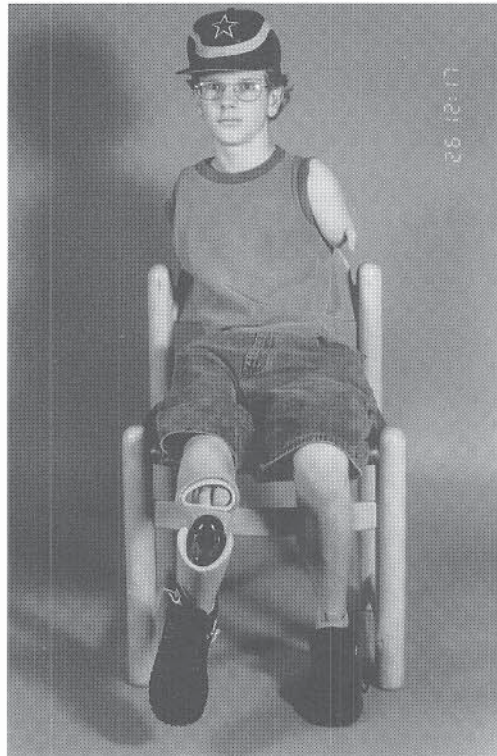
A



B

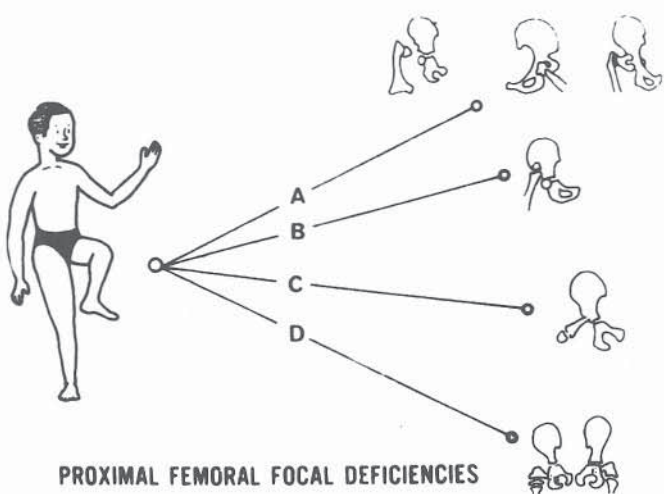


C



D

**FIGURE 32-14** Child with bilateral upper amelia and right proximal focal femoral deficiency. No ablation surgery should ever be considered for such a person. **A**, The boy is able to ambulate at age 2 years with an easily removable prosthesis. **B**, He is ahead of his peers in manual dexterity using his feet at age 2 years. **C**, At age 14, he is using an easily removable equinus prosthesis. **D**, In sitting, the position of the foot is evident.



**PROXIMAL FEMORAL FOCAL DEFICIENCIES**

FIGURE 32-15 Schematic illustration of the Aitken classification of proximal focal femoral deficiency.

proximal end of the femur, and the acetabulum is well formed. At birth, the upper portion of the femur may not be ossified, but as the child matures, the femoral head develops. The proximal end of the femur usually is positioned above the acetabulum, and at maturity there is no ossific continuity between the femoral shaft and head (a definitive feature of Aitken's type B deformity).

In type C defects, the femoral segment is short and there is a tuft at the proximal end. There is no ossification of the upper portion of the femur, and the femoral head is missing. The acetabulum is poorly developed or absent. In cases where there is no acetabulum, the flat, lateral segment of the pelvic wall is seen in its place.

In type D deficiencies, the shaft of the femur is extremely short or absent, there is no femoral head, and the acetabulum is either poorly developed or not present.

**HAMANISHI CLASSIFICATION.** The Hamanishi classification system of PFFDs is more comprehensive than the Aitken system, comprising six primary groups and ten subgroups of femoral malformation. There is a category for almost any

TYPE		FEMORAL HEAD	ACETABULUM	FEMORAL SEGMENT	RELATIONSHIP AMONG COMPONENTS OF FEMUR AND ACETABULUM AT SKELETAL MATURITY
A		Present	Normal	Short	Bony connection between components of femur Femoral head in acetabulum Subtrochanteric varus angulation, often with pseudarthrosis
B		Present	Adequate or moderately dysplastic	Short, usually proximally bony tuft	No osseous connection between head and shaft Femoral head in acetabulum
C		Absent or represented by ossicle	Severely dysplastic	Short, usually proximally tapered	May be osseous connection between shaft and proximal ossicle No articular relation between femur and acetabulum
D		Absent	Absent Obturator foramen enlarged Pelvis squared in bilateral cases	Short, deformed	(none)

FIGURE 32-16 Description and illustration of the Aitken classification of proximal focal femoral deficiency.

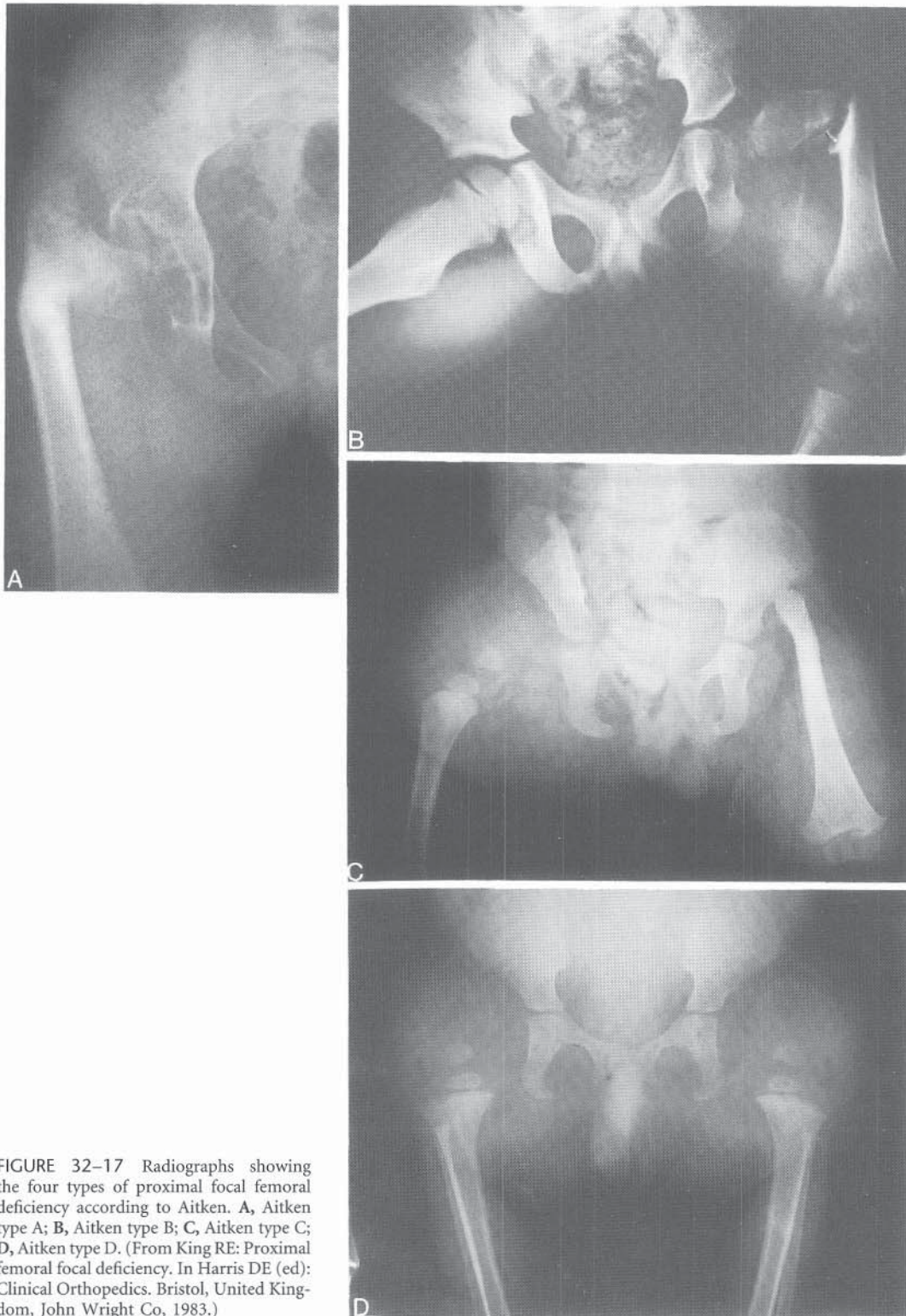


FIGURE 32-17 Radiographs showing the four types of proximal focal femoral deficiency according to Aitken. A, Aitken type A; B, Aitken type B; C, Aitken type C; D, Aitken type D. (From King RE: Proximal femoral focal deficiency. In Harris DE (ed): *Clinical Orthopedics*. Bristol, United Kingdom, John Wright Co, 1983.)

deformity. The mildest form is a shortened femur with no radiographic defect (grade Ia); the most severe is complete absence of the femur (grade V) (Fig. 32-18).<sup>18</sup> This system supports the premise that the deficiency is a continuous spectrum representing varying degrees of response to an insult, rather than being a group of distinct clinical entities. The severity of the malformation depends on the degree

to which growth and development are inhibited. In this classification, isolated congenital coxa vara is considered a separate condition that is not associated with PFFD.

**GILLESPIE AND TORODE CLASSIFICATION.** In this clinically based, treatment-oriented classification system, patients are placed in one of two groups.<sup>92</sup> In group I the femur is 40 to 60

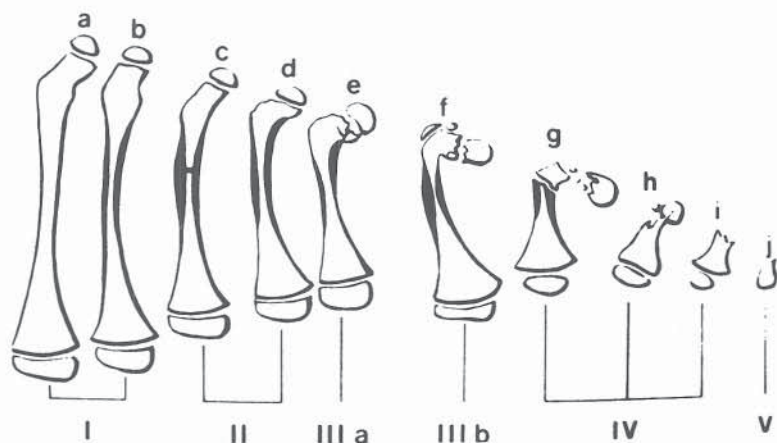


FIGURE 32-18 The Hamanishi classification of femoral deficiency. (From Hamanishi C: Congenital short femur: clinical, genetic, and epidemiological comparison of the naturally occurring condition with that caused by thalidomide. *J Bone Joint Surg* 1980;62-B:307.)

percent shorter than the normal femur and the hips and knees can be made functional. With the legs extended, the foot on the affected side reaches the midtibia on the normal side, or lower. These patients are considered suitable candidates for limb lengthening procedures. Group II comprises those patients with more severely shortened femora in which the foot on the affected side reaches above the midtibia on the normal side, often being at the level of the normal knee. These patients are best treated with amputation or rotationplasty and prosthetic management.

**GILLESPIE CLASSIFICATION.** Gillespie has since proposed a modified clinical classification system that categorizes femoral deficiencies into three groups (Fig. 32-19).<sup>90</sup> Group A con-

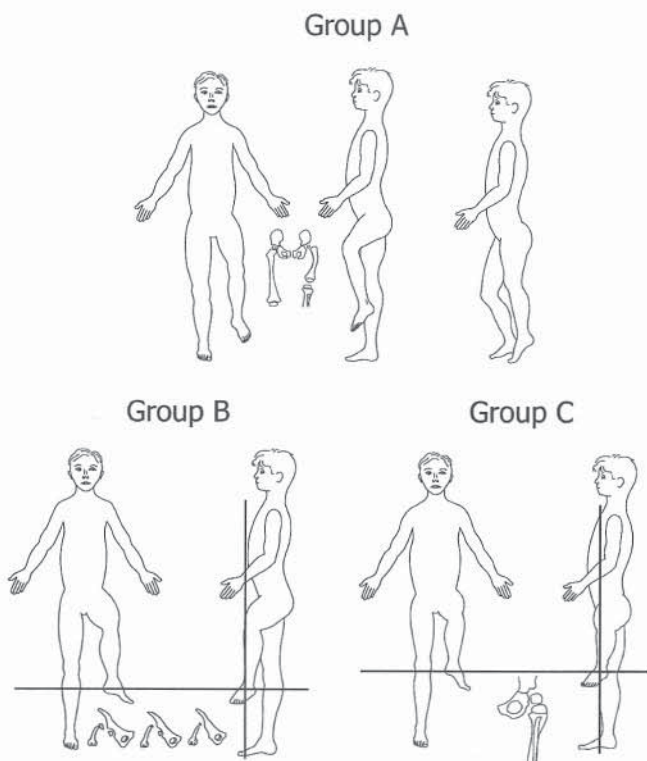


FIGURE 32-19 The Gillespie classification of femoral deficiency. (From Gillespie R: Classification of congenital abnormalities of the femur. In Herring JA, Birch JG (eds): *The Child with a Limb Deficiency*. Rosemont, IL, American Academy of Orthopaedic Surgeons, 1998.)

sists of cases previously termed *congenital short femur* in which, when the infant's feet are gently pulled down, the foot of the affected limb will be positioned opposite the midpoint of the contralateral tibia or lower (indicating that the overall limb length discrepancy is 20 percent or less). If the femur is at least 60 percent the length of the normal femur, the patient is considered a candidate for limb lengthening. If the length of the affected femur is 50 percent or less the length of the contralateral femur, Gillespie recommends a van Ness rotationplasty and prosthetic fitting.<sup>90</sup> The deficiencies in group B would be categorized as Aitken's types A, B, and C with a true PFFD. When the feet are pulled down, the affected foot is positioned at the level of the contralateral knee or above, with the overall limb length discrepancy approximately 40 percent. These patients are best managed with prostheses after surgical conversion (knee fusion, rotationplasty, and so forth). In group C, there is a subtotal absence of the femur, similar to Aitken's type D classification. Arthrodesis of the knee is not indicated in group C cases, and the patients should be managed prosthetically. If the femur is extremely short, it may be preferable to retain the foot within the socket to improve suspension and control.<sup>90</sup>

**FIXSEN AND LLOYD-ROBERTS CLASSIFICATION.** This system categorizes PFFDs according to the radiographic appearance of the proximal portion of the shaft of the femur.<sup>71</sup> There are three types of maldevelopment. In type I the proximal femur is bulbous and there is continuity between the femoral head, neck, and greater trochanter. A pseudarthrosis may form distal to the greater trochanter. In type II there is a tuft or cap of ossification at the proximal end of the femur that is separated from a blunt upper femoral shaft by an area of lucency. A pseudarthrosis is often present, and, if it heals, the femoral neck has a varus deformity. The hip is usually unstable. In type III the femur is blunt or pointed in shape (not bulbous), there is no tuft at the proximal end of the shaft, and all have unstable pseudarthrosis. The authors recommended surgical stabilization of all unstable pseudarthroses (i.e., types II and III), but recent experience does not support the need to operate on the pseudarthritic area except in unusual progressive deformities.

**Clinical Presentation.** Patients with PFFD present with a characteristic appearance. The affected thigh is extremely short, the hip is flexed and abducted, the limb is externally



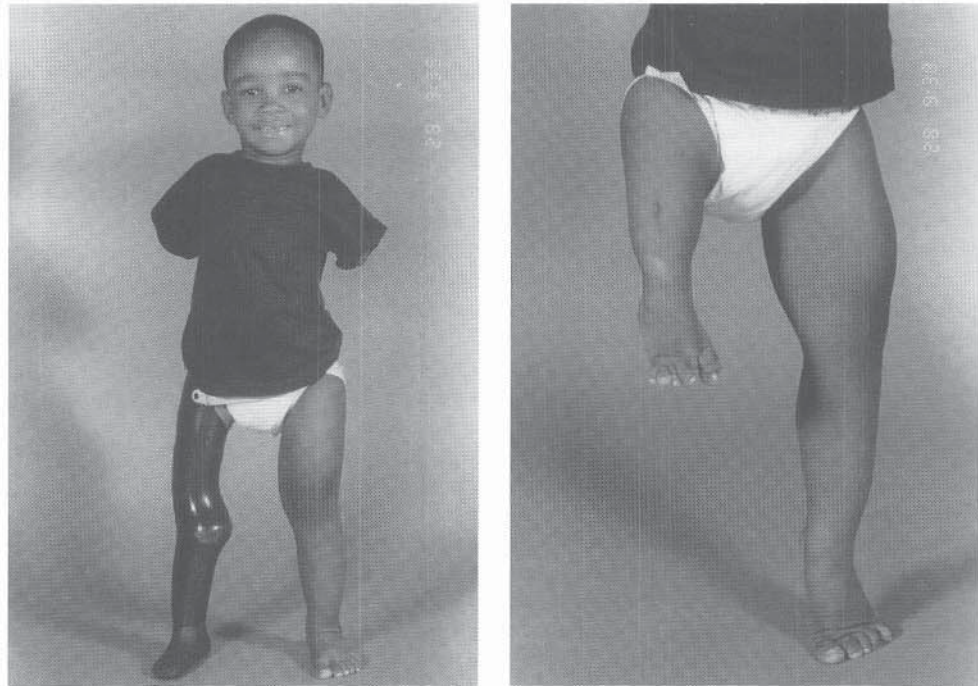


FIGURE 32-20 Typical “ship’s funnel” thigh in proximal focal femoral deficiency. The equinus prosthesis offers good cosmesis.

rotated, there often is flexion contracture of the knee, and the foot usually is at the level of the contralateral knee (Fig. 32-20). Flexion contractures of the hip and knee will make the limb appear shorter than it actually is anatomically. The actual discrepancy can be better determined by comparing the length of the two limbs while the patient is sitting. Although the hip abductors and extensors are present, they are foreshortened and unable to function properly because of the abnormal anatomy of the proximal femur. The knee joint is positioned in the groin and acts as an unstable intercalary segment.<sup>10</sup> In approximately 45 percent of cases, the patient will also have an ipsilateral fibular hemimelia of the affected limb, with a short tibia and an equinovalgus deformity of the foot.<sup>149</sup> Lateral rays of the foot may be missing.

In patients with congenital shortening of the femur, a disorder related to PFFD, the clinical presentation is more subtle. The affected thigh is shorter than the contralateral thigh and the lower leg may also be shorter. There is an associated anterolateral femoral bow, along with valgus deformity and external rotation of the knee. Patients often lack the anterior cruciate ligament of the knee, resulting in anteroposterior laxity of the joint. Some patients have shortened hamstrings, which restricts straight-leg raising.<sup>137</sup> Patients with congenital shortening of the femur will frequently have an associated ipsilateral fibular hemimelia.

Most children with a femoral deficiency are able to compensate for their deformity and do not experience delay in achieving developmental milestones. A child who has significant shortening of one lower limb will walk by bearing weight on the knee of the normal limb and the foot of the affected leg to equalize the limb length discrepancy (Fig. 32-21). A child with a congenitally short femur will walk with the hip and knee of the normal limb flexed and with equinus on the shortened limb to accomplish the same goal. These children usually start walking at the expected age.

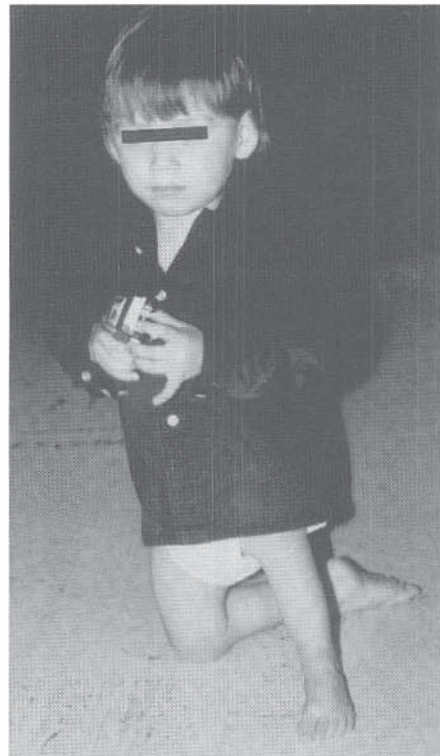


FIGURE 32-21 A child with proximal femoral deficiency walking on the knee of the sound side and the foot of the short extremity. He was treated with a Syme amputation, knee fusion, and a prosthesis. (From Herring JA, Cummings DR: *The limb-deficient child*. In Morrissy RT, Weinstein SL (eds): *Lovell and Winter’s Pediatric Orthopaedics*, 4th ed, vol 2. Philadelphia, Lippincott-Raven, 1996.)

**Treatment.** To establish an appropriate treatment plan, the orthopaedist first must determine the child's present limb length discrepancy. The percentage of discrepancy is calculated from measured radiographs. Then, based on the fact that the relative shortening of the limb will remain consistent throughout the child's growth,<sup>14</sup> the probable discrepancy at maturity is estimated by multiplying the average length of the adult femur by the percentage of the existing discrepancy. The final discrepancy can also be determined by applying the standard methods of Anderson, Green, and Messner<sup>16,17,102</sup> or Moseley<sup>203,204</sup> with measurements obtained from longitudinal radiographs.

There are at least 6 current treatment options for the child with PFFD with shortening of the limb greater than 50 percent. These children have a predicted final discrepancy of greater than 20 cm and are classified as group II in Gillespie and Torode's classification, or group B of the new Gillespie classification.<sup>90,92</sup> The current options are (1) equinus prosthesis only, (2) ankle disarticulation and prosthetic fitting, (3) ankle disarticulation and knee arthrodesis, (4) ankle disarticulation and femoral-pelvic arthrodesis, (5) rotationplasty and knee arthrodesis, (6) rotationplasty and femoral-pelvic arthrodesis. Limb lengthening and reconstruction may occasionally be an achievable option and is discussed in other chapters.

The choice of treatment is made by the parents and the medical team, and many factors must be considered. Modern prosthetics have made the equinus prosthesis (option 1) a feasible option especially for patients with close to 50 percent of femoral length. Option 2, ankle disarticulation, is a simple alternative, but the gait may be substantially improved by adding a knee arthrodesis (option 3). Options

4 and 6 include fusion of the femur to the pelvis to reduce the abductor lurch in the gait. The degree of improvement from such arthrodeses remains controversial. While options 5 and 6, rotationplasty, offer significant gait improvements, the cosmetic disadvantages must be understood and accepted by the family.

If the final predicted discrepancy at maturity is less than 20 cm (which is typical in patients with congenitally short femurs), the child may be a suitable candidate for a limb lengthening procedure. These patients would fall into group A of the new Gillespie classification system, in which the affected femur is at least 60 percent the length of the contralateral femur.<sup>90</sup> For femoral lengthening to be successful, the hip and femoral segment must be stabilized.

**AMPUTATION.** Amputation of the foot, combined with a knee arthrodesis, is a well-documented means of treating significant femoral shortening (Fig. 32-22). Before the knee is fused, the orthopaedist should consider fusing the femur to the pelvis to improve hip stability. Either a modified Syme amputation or a Boyd amputation can be performed; both techniques create a residual limb well suited to prosthetic management and end weightbearing.<sup>10,145,195,314</sup> However, because migration of the heel pad is rarely a problem following a Syme amputation, the more difficult Boyd technique is usually not necessary. After the procedure the child is able to walk either by using a Syme-type prosthesis or by bearing weight on the end of the amputated limb and the contralateral knee (i.e., "knee-walking") and equalizing the limb length discrepancy without using a prosthesis.

As the child grows and the femoral segment is short, the knee (which is at the upper brim of the prosthesis) flexes with

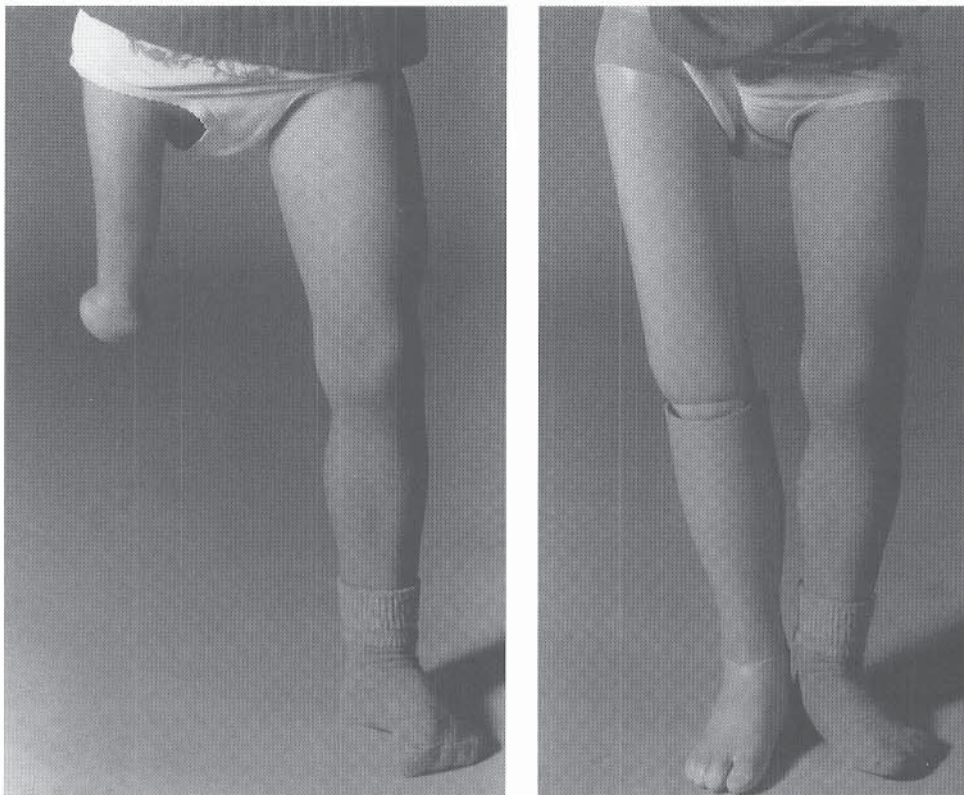


FIGURE 32-22 Proximal focal femoral deficiency, which was treated with a Syme amputation and knee fusion.

weightbearing, allowing the prosthesis to displace proximally and anteriorly. This instability causes the child to lurch forward and to the side in gait. This problem can be addressed by performing a knee arthrodesis so that the residual limb is straight and the prosthesis is positioned directly below the acetabulum. This surgical approach converts the affected limb to a functional above-knee amputation, usually with the additional advantage of distal loading tolerance. Opinion varies as to when the procedures should be done. Some orthopaedists elect to perform the amputation just before the child starts walking and wait to do the knee arthrodesis until the patient is 3 to 4 years old. Others perform both procedures simultaneously when the child is 2 to 3 years old and use an equinus prosthesis in the interim.

Ideally, after a Syme amputation and knee arthrodesis, the proximal end of the residual limb should lie at least 5 cm (2 inches) above the contralateral knee at skeletal maturity to allow for proper placement of the prosthetic knee. Often, however, the end of the residual limb will be at or below the level of the contralateral knee, and the tibial part of the prosthesis has to be shortened to accommodate the mechanism of the prosthetic knee, resulting in a discrepancy in knee heights. This length discrepancy can be minimized by excising the epiphysis of the distal femur at the same time the knee arthrodesis is performed, followed by fusion of the proximal tibial epiphysis to the distal femoral metaphysis (Plate 32-1). If this procedure is performed when the child is 3 to 4 years old, a satisfactory final length discrepancy can usually be achieved. The final discrepancy can be estimated from established growth charts; however, hip and knee flexion contractures prior to fusion reduce the accuracy of these predictions.

**ROTATIONPLASTY.** Rotationplasty was first described in 1930 by Borggreve, who used the procedure as a substitute treatment for a knee severely damaged by tuberculosis.<sup>30</sup> In 1950, van Ness described his technique of treating congenital femoral deficiencies by rotating the foot of the affected limb 180 degrees so that the toes pointed posteriorly and the ankle and foot were able to control the prosthetic knee (Fig. 32-23).<sup>289</sup>

The goal of the van Ness rotationplasty is to convert the affected limb to a functional “below-knee” amputation in which the rotated foot serves as a knee joint.<sup>145</sup> For optimum prosthetic function, it is essential that the ankle joint of the affected limb be normal and be capable of at least a 60-degree arc of motion after surgery.<sup>284</sup> The ankle should be at the same level as the knee of the contralateral limb, and the ankle joint should be rotated a full 180 degrees.<sup>153</sup> After a van Ness rotationplasty, the gastrocsoleus muscle provides primary motor control to the ankle, which in essence is now the “knee” extensor. The sensory feedback from the ankle also allows the patient better proprioceptive control of the prosthetic knee (Fig. 32-24).<sup>109,151,155,289</sup>

In a study comparing the gait mechanics of patients who had undergone a van Ness procedure with those who had undergone a Syme amputation, patients who had undergone the van Ness procedure demonstrated better prosthetic limb function and fewer compensations with the contralateral normal limb.<sup>214</sup> Data from the van Ness group were closer to normative data for ground reaction forces, forward pro-

pulsion, and active knee control. Oxygen cost was lower and walking speed was higher in the van Ness group.<sup>73</sup> The difference in oxygen cost (0.12 mL/kg/min) was comparable to the differences reported between below-knee and above-knee amputees.<sup>308</sup>

Despite good initial functional results with the original van Ness procedure,<sup>92</sup> often the feet gradually derotate as the limb grows, making repeated rotationplasties necessary.<sup>92,151</sup> Because of this problem, other techniques have been developed.

In a technique described by Gillespie and Torode, the tibia is rotated on the femur at the same time the knee arthrodesis is performed to achieve most of the rotation (approximately 120 degrees), and then a tibial osteotomy is done to gain additional rotation.<sup>288</sup> Krajchich has further modified the Gillespie-Torode approach such that all of the rotation is obtained through the knee, with simultaneous knee arthrodesis.<sup>12,152,154</sup> To prevent late derotation, all of the muscles crossing the knee joint are detached (i.e., the medial hamstrings, gracilis, and sartorius from their insertion on the tibia, and the medial head of the gastrocnemius from its origin on the distal femur) and moved into a new position so that they all pull in a straight line across the rotated, arthrodesed knee. The popliteus is divided at the level of the knee joint. Osteotomy is performed about 0.5 to 1.0 cm proximal to the distal femoral growth plate, with the length of the removed segment based on making the limb equal to or slightly longer than the contralateral thigh. The distal femoral growth plate is removed in almost every case to prevent the operated limb from growing too long and to obtain adequate shortening so that rotation can be performed without excessive tension on the neurovascular bundle. Adductor tendon insertion division is recommended so that the popliteal vessels can move freely medially and anteriorly. Appropriate prosthetic management follows the surgery.<sup>154</sup>

Although initial results with these modified procedures have been good, longer follow-up is necessary to determine whether there is long-term rotational stability. If there is rotational malalignment following the van Ness rotationplasty, limb function deteriorates and prosthetic management is particularly difficult.

**FEMORAL PSEUDARTHROSIS STABILIZATION.** The need to stabilize the upper femoral defect is controversial. Although some authors recommend an osteosynthesis when the child is between 3 and 6 years of age,<sup>157,160</sup> most leave the defect alone unless there is progressive deformity or instability. Most upper femoral defects are stable, and surgical intervention is not necessary. An osteosynthesis of the defect is performed only if there is proof of progressive deformity (Fig. 32-25).

**HIP STABILIZATION.** Children with major femoral deficiencies who are managed with either amputation or rotationplasty usually have good results and, in most cases, are able to enjoy an active lifestyle. They can walk without aids and, when running, tend to hop twice on the unaffected limb. The primary problem encountered with gait is that of hip instability.<sup>66</sup> Because of the deformities of the proximal femur (i.e., a short, varus femoral neck combined with abnormalities of the acetabulum), the abductor muscles are not able to support the patient's body weight during the stance

*Text continued on page 1768*

### **Knee Fusion for Prosthetic Conversion in Proximal Focal Femoral Deficiency (King)**

King's method converts the proximal focal femoral deficient limb into a single skeletal lever arm by arthrodesis of the knee in extension and Syme ankle disarticulation.

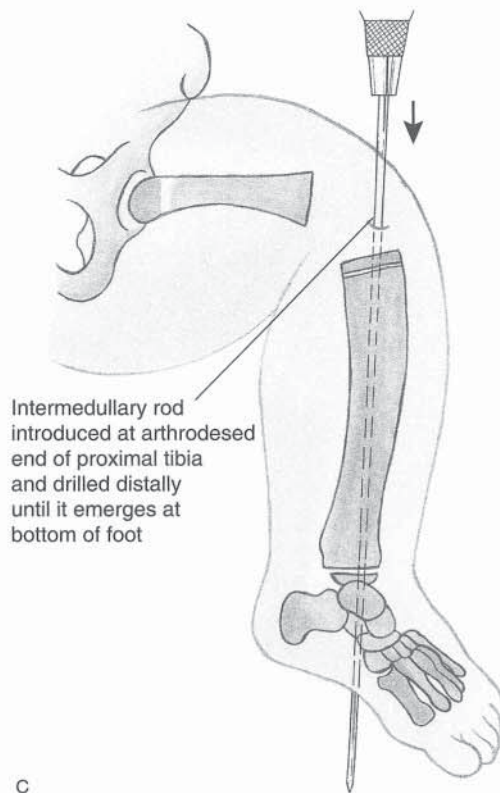
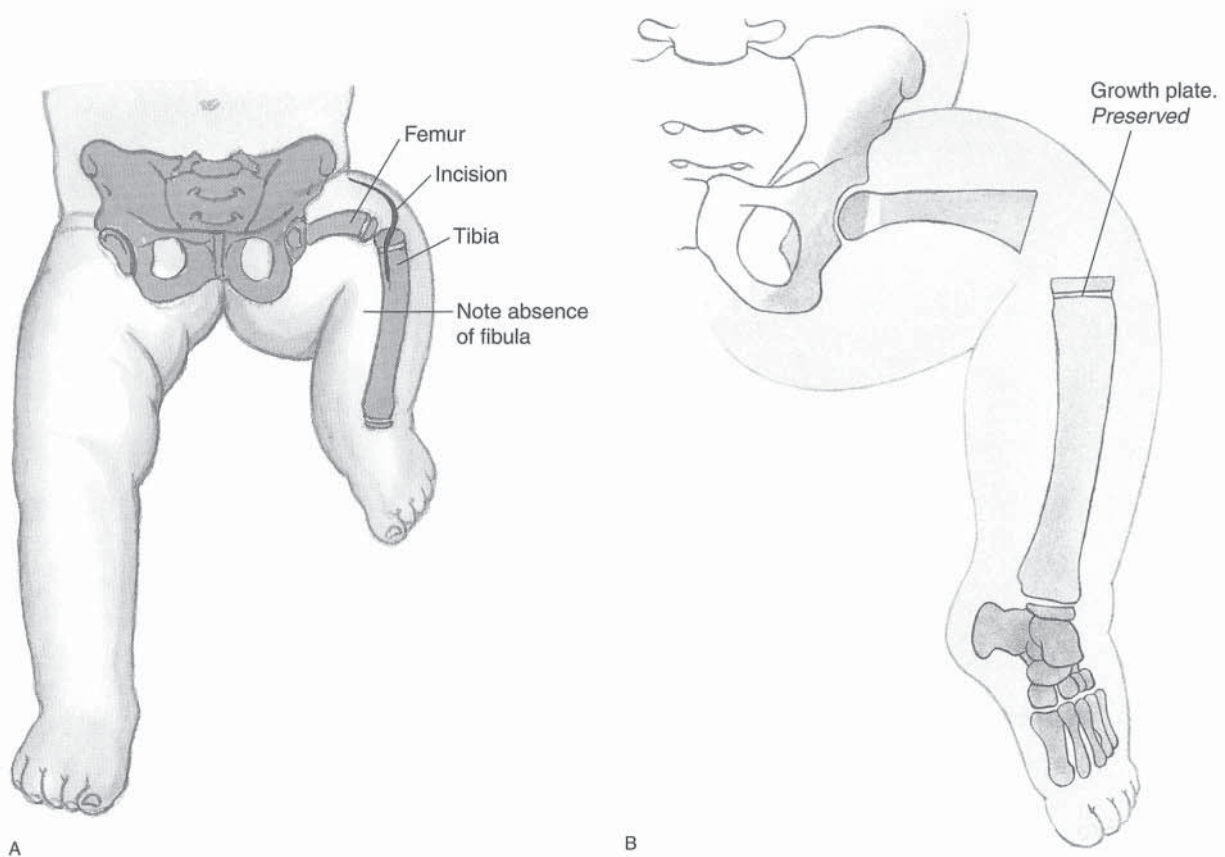
#### **OPERATIVE TECHNIQUE**

A, With the patient supine, an anterior S-shaped incision is made to expose the anterior aspect of the lower femur and upper tibia. Proximally, the incision is extended laterally to expose the lateral aspect of the upper femur.

B, The capsule and synovium of the knee joint are opened, and the articular cartilage of the upper end of the tibia is excised with an oscillating electric saw until the ossific nucleus of the epiphysis is seen. The distal femoral epiphysis is completely removed.

C, Next, an 8-mm Küntscher or similar nail is inserted retrograde. First it is inserted distally into the tibia, exiting from the sole of the foot.

# PLATE 32-1. Knee Fusion for Prosthetic Conversion in Proximal Focal Femoral Deficiency (King)



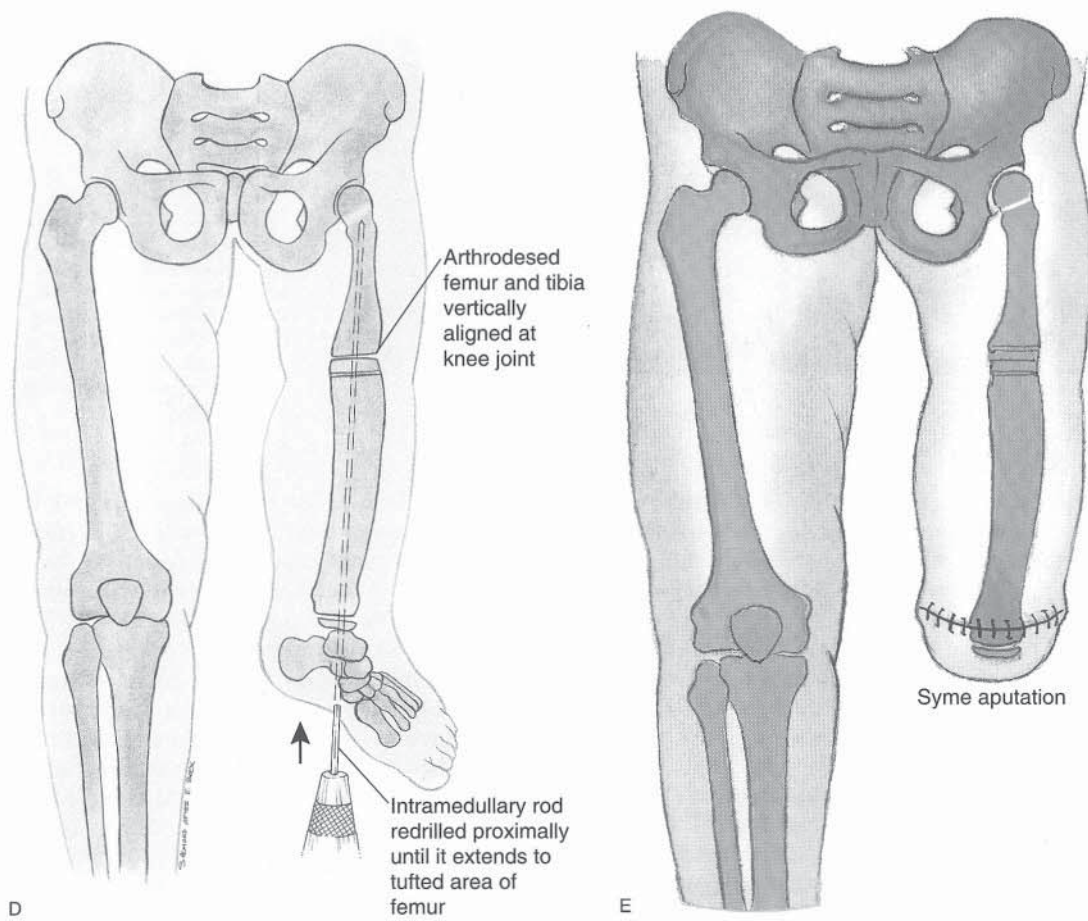
### **Knee Fusion for Prosthetic Conversion in Proximal Focal Femoral Deficiency (King) *Continued***

D, The nail is then passed proximally into the femur, impacting the lower end of the femur and the upper epiphysis of the tibia in extension. Care is taken to provide proper rotational alignment of the lower limb and ensure that the fused knee is not in flexion. The intramedullary nail should be in the center of the physes of the distal femur and the proximal tibia to avoid growth retardation.

The wound is closed in routine fashion. A one-and-one-half spica cast is applied for immobilization.

E, Six weeks postoperatively, when the intramedullary nail is removed, a Syme amputation is performed.

# PLATE 32-1. Knee Fusion for Prosthetic Conversion in Proximal Focal Femoral Deficiency (King)



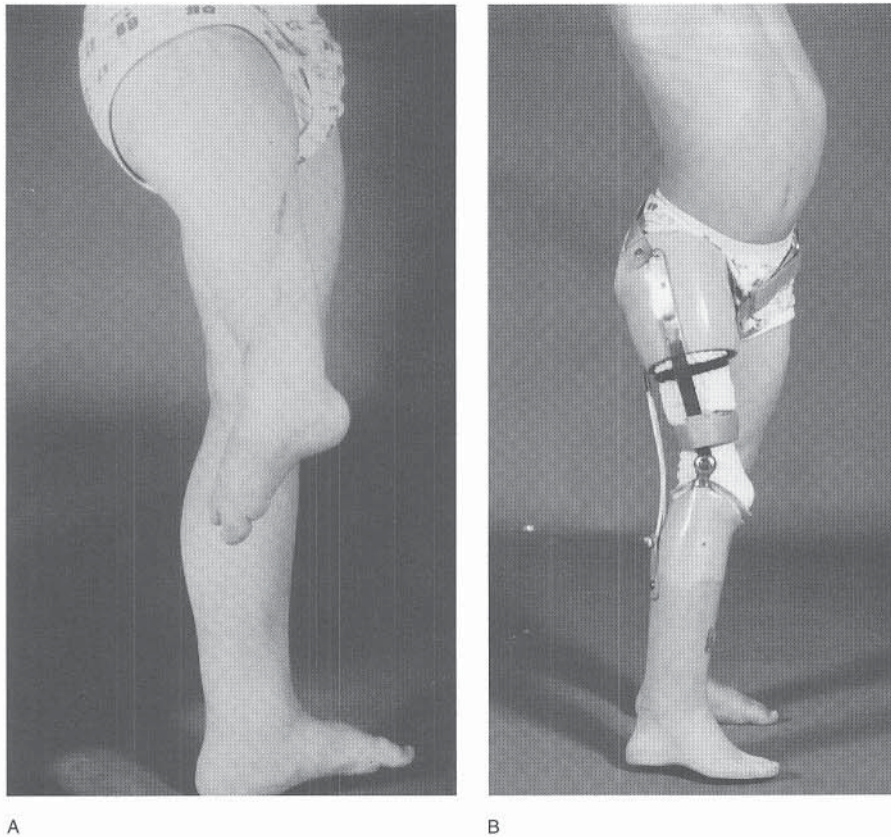


FIGURE 32-23 A, Proximal focal femoral deficiency, which was treated with a van Ness rotationplasty. B, The ankle provides motor and sensory control of the prosthetic knee. (From Herring JA, Cummings DR: The limb-deficient child. In Morrissy RT, Weinstein SL (eds): *Lovell and Winter's Pediatric Orthopaedics*, 4th ed, vol 2. Philadelphia, Lippincott-Raven, 1996.)

phase of gait, resulting in an abductor lurch. In the young child, this condition often is barely discernible and not a major inconvenience. As the child grows older, though, the abductor lurch can become a significant functional and cosmetic problem.

A number of different surgical techniques have been developed to try and eliminate the lurch. In one approach, developed by Steel and associates, the femoral segment is fused to the pelvis (iliofemoral fusion) in a flexed position, and the knee functions as a hip joint (Fig. 32-26).<sup>271</sup> This procedure can be done at the same time as a Syme amputation or a van Ness rotationplasty (Fig. 32-27). Steel described the surgical approach as “a great adventure in the abnormalities of surgical anatomy; ie, nothing was put together in a normal fashion.”<sup>270</sup> The femur needs to be shortened and the femoral epiphysis arrested to ensure that the limb is maintained in line with the patient's body mass. When this technique was developed, all of the patients subsequently underwent revisions because of overgrowth of the femoral segment.<sup>271</sup> Since then, Steel has found that the outcome is greatly improved when femoral growth is stopped at the time of fusion.<sup>270</sup> To avoid the problem of overgrowth, we fuse the femoral condyles to the pelvis after excising the remaining femoral metaphysis and physis. Steel's long-term follow-up of 22 patients found a reduced abductor lurch and improved gait, with only two children having Trendelenburg gaits.<sup>270</sup> After a Steel arthrodesis, there usually is little active hip flexion power, which may cause functional problems.

Another method of preventing derotation and eliminating the abductor lurch in patients with PFFD was developed

by K. L. B. Brown.<sup>34</sup> In this variant of a limb salvage procedure, the femur is rotated externally 180 degrees and brought as far proximal as possible for fusion to the pelvis. Excess soft tissue is excised before the femoral segment is fused in a reversed, extended position (Fig. 32-28). The rotated leg is attached in neutral to slight abduction and neutral to slight external rotation. The medial hamstrings are attached to the anterior or lateral muscles of the rotated limb. The gastrocnemius soleus acts both as a hip flexor and as a knee extensor, with the reversed knee joint functioning as a hinged hip joint. As in the van Ness rotationplasty, the retained ankle and foot serve as a knee joint. In Brown's series, at 7-month follow-up passive range of hip motion was 90 degrees and active hip flexion was 60 degrees.<sup>34</sup> Longer follow-up is needed to establish the outcome of this approach.

**SURGICAL CONSIDERATIONS.** The primary considerations when deciding on a surgical treatment plan for patients with significant femoral deficiencies are whether the foot should be saved, rotated, or amputated and whether the knee should be fused or the hip stabilized by fusing the femur to the pelvis (Table 32-8). When the hip is *stable* and the upper femoral anatomy is relatively normal, the two treatment options are knee arthrodesis with either a Syme amputation or a rotationplasty. When the hip is *unstable*, the current treatment options are a Steel fusion of the femur to the pelvis with either a Syme amputation or a rotationplasty, or a Brown iliofemoral fusion with rotationplasty.

The Syme amputation has the advantage of being a single procedure that produces satisfactory cosmetic and func-



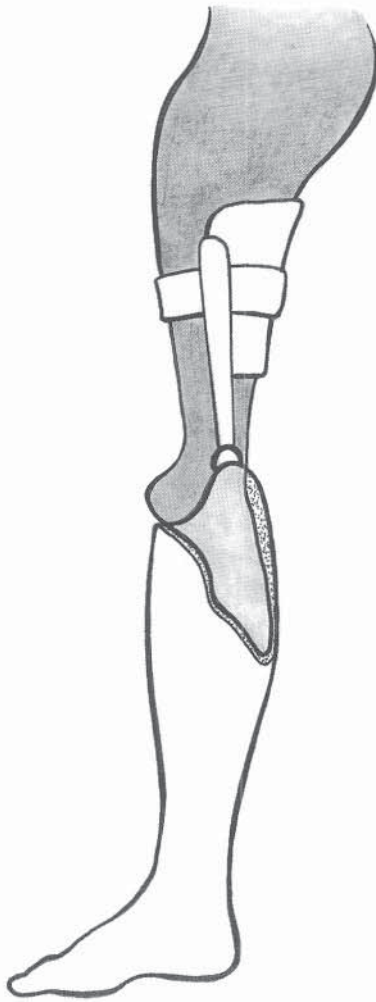


FIGURE 32–24 Rotationplasty for proximal focal femoral deficiency. The ankle and foot are turned 180 degrees to activate the knee of the prosthesis.

tional results. A rotationplasty has significant functional advantages in that the patient can actively control the prosthetic knee with the gastrocnemius, and can have proprioception as to knee position.<sup>91</sup> The disadvantages of rotationplasty are (1) the backward foot is a significant cosmetic hurdle for the patient to overcome, and (2) the rotated segment tends to derotate as the patient grows.

Bilateral PFFD is uncommon (Fig. 32–29). The primary functional problems of patients with bilateral PFFD are short stature and a waddling gait. Surgical treatment such as amputation is contraindicated for this condition. Treatment usually is limited to the use of a pair of extension, equinus prostheses to enhance the child's height and enable him or her to participate in certain physical activities.<sup>153</sup>

**LIMB LENGTHENING.** In some patients with PFFD and in the majority of patients with congenital shortening of the femur, the projected final discrepancy will be less than 20 cm. The affected femur is at least 40 to 60 percent of the length of the contralateral femur, and the patients are classified in group I of the Gillespie and Torode system<sup>92</sup> or in group A of Gillespie's modified classification system.<sup>90</sup> The foot of the shortened limb usually is at the same level as the midtibia

of the opposite limb. In these cases, limb lengthening often is the ideal treatment.

The goals of limb lengthening procedures are to correct the existing deformity and to eliminate the length discrepancy. Some patients need only a single lengthening of the femur, combined with an epiphysiodesis of the opposite limb.<sup>92</sup> Other patients may need to undergo two or more femoral lengthening procedures. In some cases it is also necessary to perform tibial lengthening. Because limb lengthening procedures for congenital shortening of the femur and PFFD are technically demanding and subject to myriad complications, they must not be undertaken lightly.<sup>149,195,206,297,314</sup> Current indications for limb lengthening of the congenital short femur include a limb that is predicted to be at least 50 percent as long as the normal limb at maturity, a predicted discrepancy of less than 17 to 20 cm, and a condition that can be corrected in three or fewer separate limb length equalization procedures.<sup>128</sup>

The anatomy of the child's hip must be almost normal before limb lengthening can be performed. Preexisting deformities that compromise stability should be corrected well before beginning lengthening (Fig. 32–30). There often is mild dysplasia of the acetabulum. If the dysplasia is not corrected, the muscle forces created by femoral lengthening will cause the dysplastic hip to dislocate. To prevent this complication from occurring, a pelvic osteotomy may be performed, with the specific type of procedure dependent on the nature of the acetabular deficiency. A Salter osteotomy is done if the deficiency is anterolateral, and a Dega osteotomy is performed if there is posterior acetabular insufficiency.

Deformity of the proximal femur, which often is in varus and retroverted, also needs to be treated before limb lengthening is done. The femoral neck-shaft angle should be corrected to normal (approximately 135 degrees); however, the femur should not be positioned in valgus, since this predisposes the hip to dislocation.<sup>39,177</sup> This osteotomy should be well healed and hardware should be removed before beginning lengthening. The iliotibial band usually is contracted, and it should be released prior to lengthening.

Price and Noonan recommend the use of a monolateral fixator for limb lengthening when the congenital short femur has a projected discrepancy of less than 17 cm and the patient has a stable hip and knee and an intact posterior cruciate ligament.<sup>223</sup> If the projected discrepancy is greater than 7 cm, multiple, staged lengthening procedures are planned, with the goal of achieving a 15 to 20 percent gain at each stage (Fig. 32–31). Spanning the knee joint prophylactically may prevent articular cartilage damage during major lengthening<sup>268,269</sup>; however, Price and Noonan prefer to avoid spanning the knee by staging the lengthening with a maximum gain of 20 percent per stage. Although bi-level lengthening may reduce the total time for osteogenesis, the authors advise against this approach, as muscles and nerves appear to respond better to slower rates of distraction.<sup>134,223,244,260,261</sup>

For the same reason, ipsilateral lengthening of the femur and tibia is discouraged in most cases. To prevent translation during lengthening, fixator alignment should be parallel to the mechanical axis. Osteotomies usually are made distal to the midshaft of the femur because of better bone healing at that level. The iliotibial band is released distally when the distal pin is inserted. If contractures start to develop, addi-

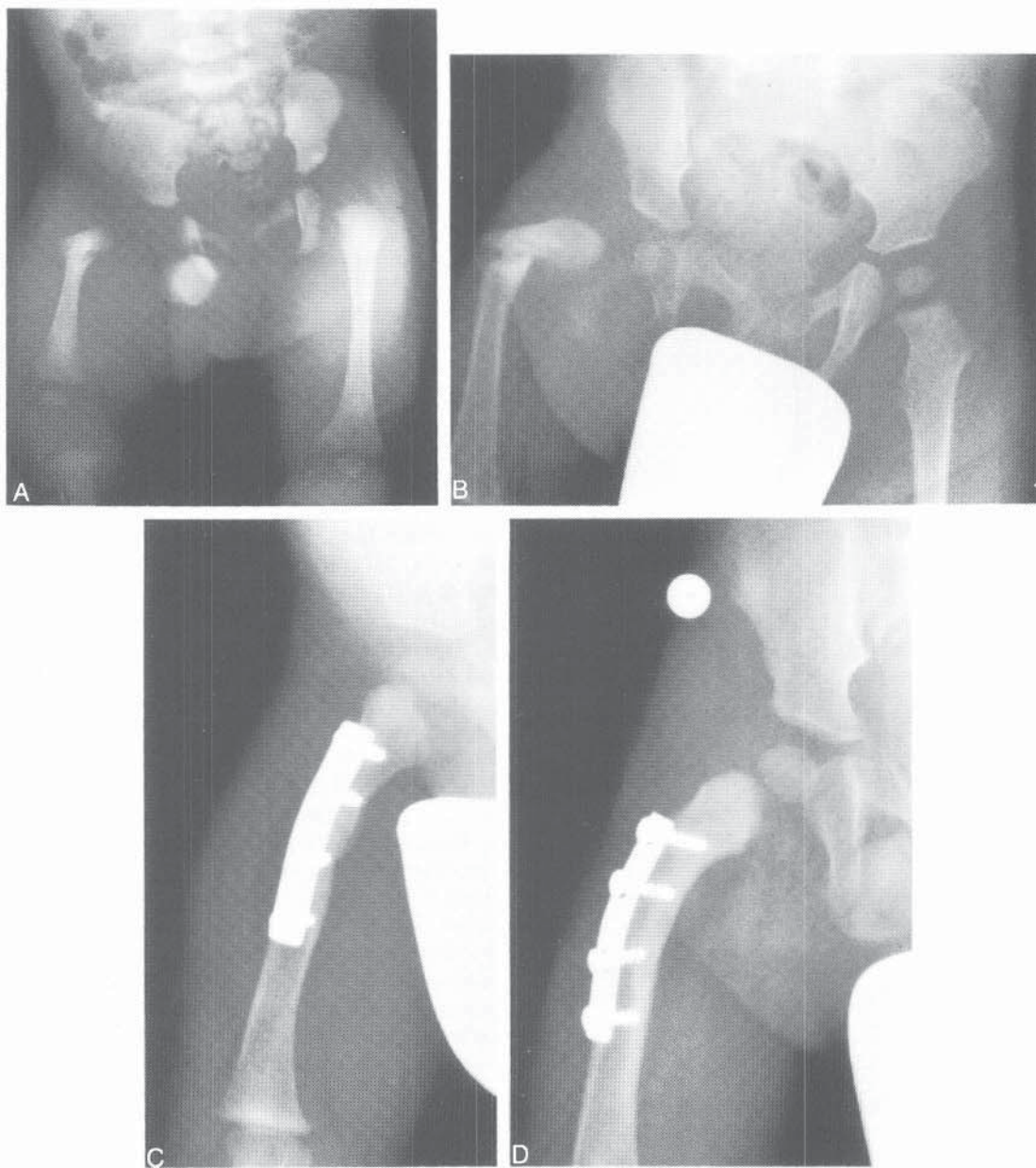


FIGURE 32-25 Proximal focal femoral deficiency (PFFD) type A. **A**, AP radiograph of a 1-month-old boy. Note the coxa vara deformity of about 110 degrees, the marked shortening of the femur, and the delay in ossification of the upper end of the femur. **B**, At age 10 months, the coxa vara deformity remained uncorrected. **C** and **D**, AP and lateral radiographs after valgus osteotomy.

tional soft tissue releases can be performed.<sup>96</sup> If the adductor magnus is tight, it can be released at the adductor hiatus. The chances of subsequent knee subluxation are minimized by distal pin placement, avoidance of knee flexion movements, and extension splinting for at least 12 hours each day. If knee subluxation occurs, it should be promptly treated by hamstring lengthening or traction and immobilization in extension. Hip subluxation or dislocation should be treated by appropriate soft tissue releases, femoral shortening, extension of fixation across the hip joint, open reduction, or a combination of these procedures.<sup>223</sup>

Paley has proposed a classification of femoral deficiencies to aid in planning reconstructive lengthening procedures

(Fig. 32-32).<sup>215</sup> His group I, which corresponds to congenitally short femur in other classification systems, is the best group for lengthening. He recommends correction of femoral neck varus and acetabular dysplasia prior to lengthening. He also outlines reconstructive approaches for patellar instability and instability of the knee joint. Paley's group IIa is defined by a mobile pseudarthrosis of the upper femur and a femoral head that is mobile in the acetabulum. The first step in reconstructing these hips is obtaining union of the pseudarthrosis, with subsequent lengthening. Group IIb is defined by a located, immobile femoral head or a dislocated hip; these hips require a pelvic support osteotomy prior to lengthening. These more typical femoral deficiency patients

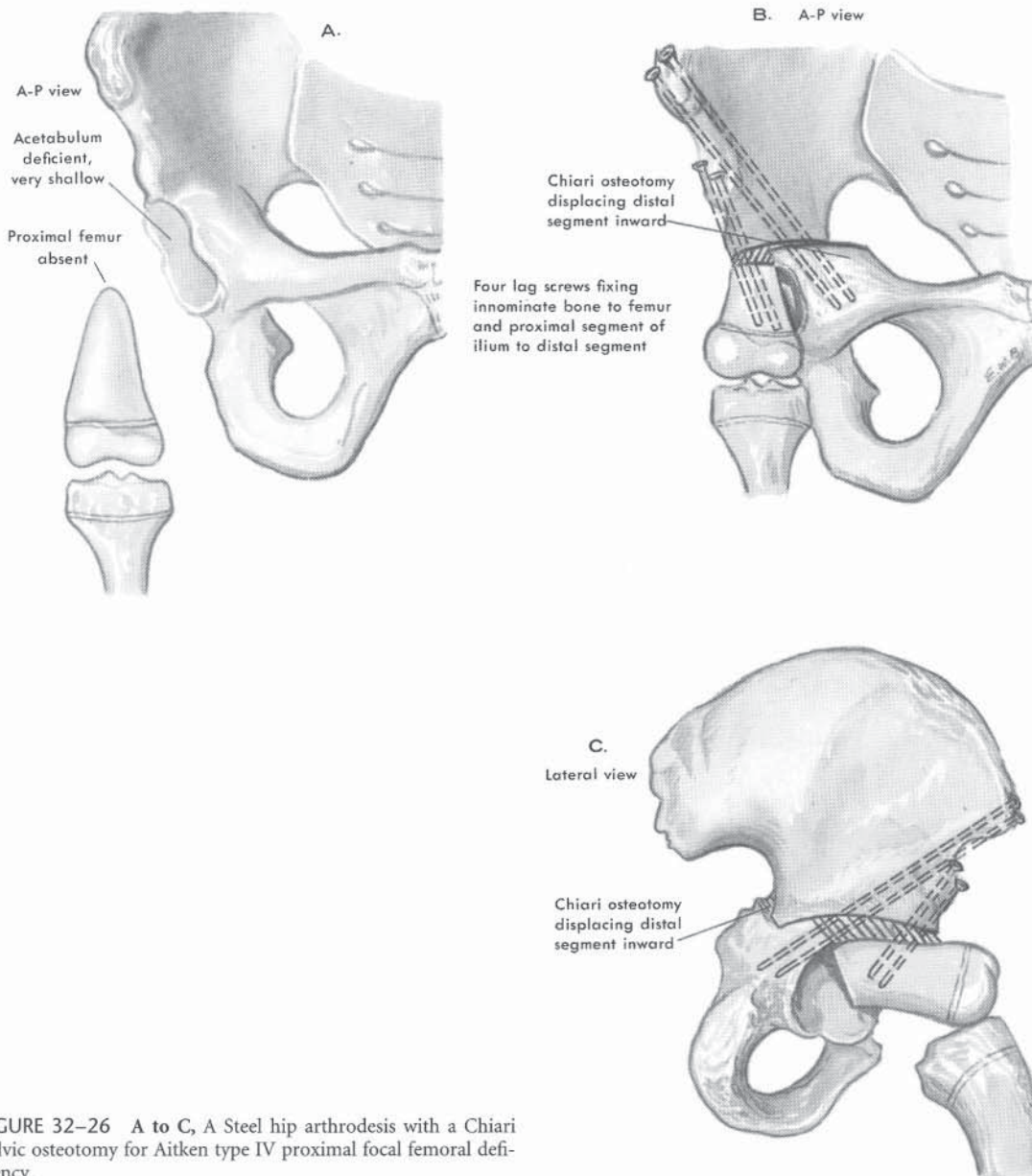


FIGURE 32–26 A to C, A Steel hip arthrodesis with a Chiari pelvic osteotomy for Aitken type IV proximal focal femoral deficiency.

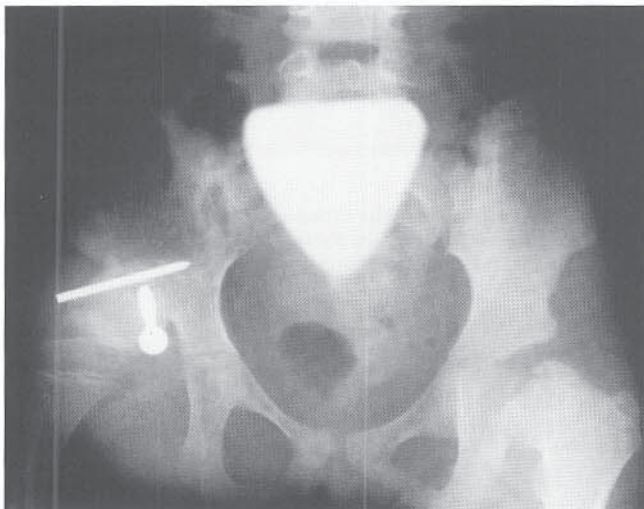
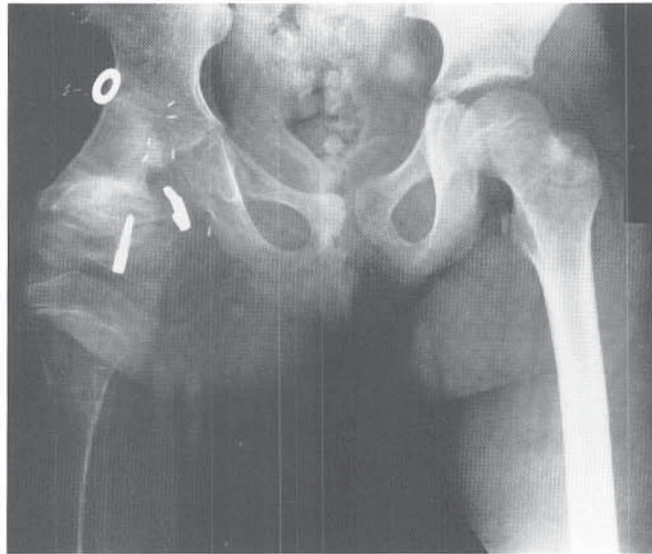
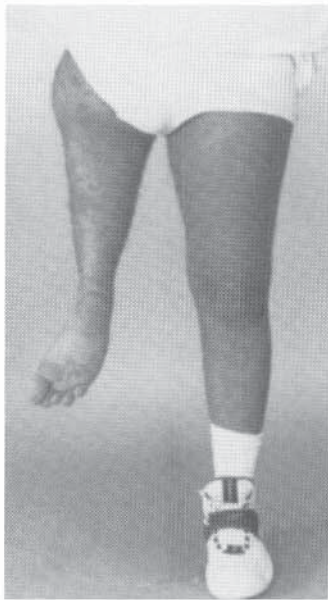

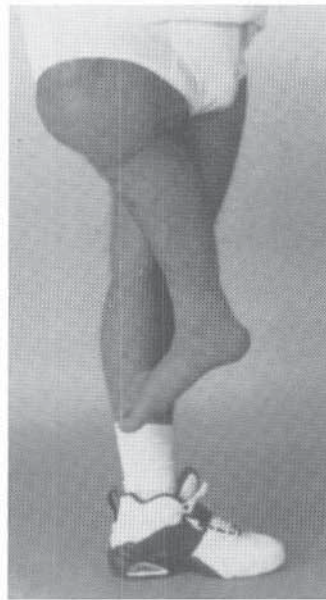FIGURE 32–27 Proximal focal femoral deformity following fusion of the femoral segment to the pelvis as described by Steel. (From Herring JA, Cummings DR: *The limb-deficient child*. In Morrissy RT, Weinstein SL (eds): *Lovell and Winter's Pediatric Orthopaedics*, 4th ed, vol 2. Philadelphia, Lippincott-Raven, 1996.)



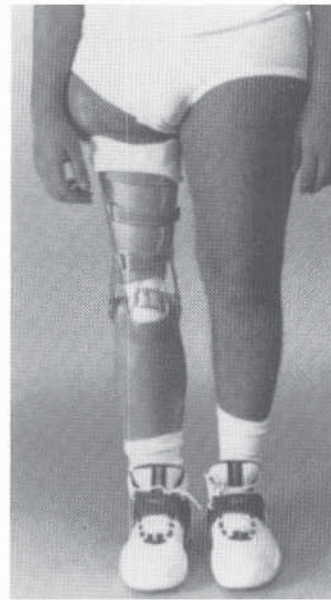A



B



C



D

**FIGURE 32-28** A, The Brown fusion procedure. B, The femur was rotated 180 degrees prior to fusion to the pelvis. (From Brown KLB: Rotationplasty with hip stabilization in congenital femoral deficiency. In Herring JA, Birch JG (eds): *The Child with a Limb Deficiency*. Rosemont, IL, American Academy of Orthopaedic Surgeons, 1998.)

**TABLE 32-8 Surgical Management of Patients with Femoral Deficiencies****Stable Hip**

*Predicted length of affected limb at maturity < 50% of contralateral limb*

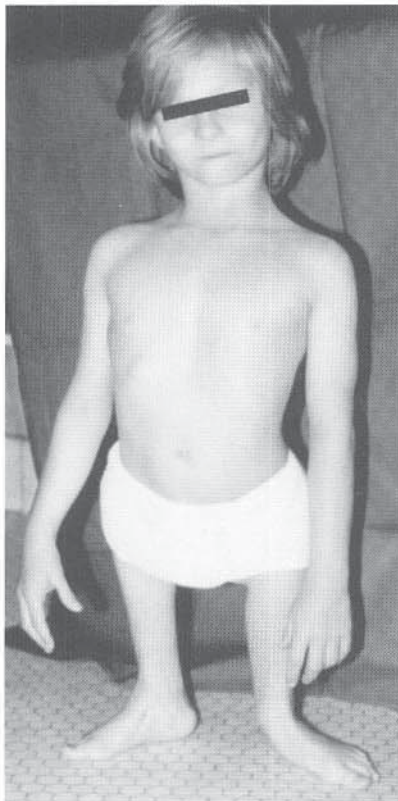
- Knee fusion and Syme's amputation: Primarily indicated when the hip is stable and there is a relatively normal relationship between the greater trochanter and the femoral head, and the patient does not wish to have a rotated foot.
- Knee fusion and rotationplasty: Indicated when the hip is stable with a good femoral head to greater trochanter relationship, and the patient appreciates the value of the rotated foot.

*Predicted length of affected limb at maturity > 50% of contralateral limb*

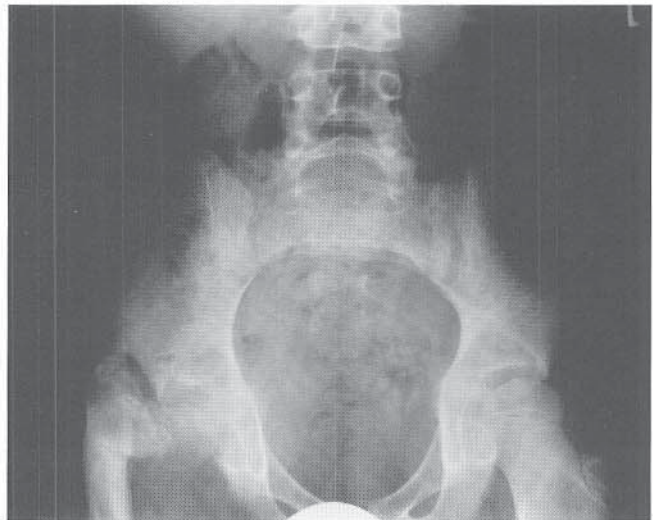
- Limb lengthening: Additional criteria for lengthening are a predicted discrepancy of less than 17 to 20 cm, and a condition that can be corrected with three or fewer separate limb length equalization procedures.

**Unstable Hip**

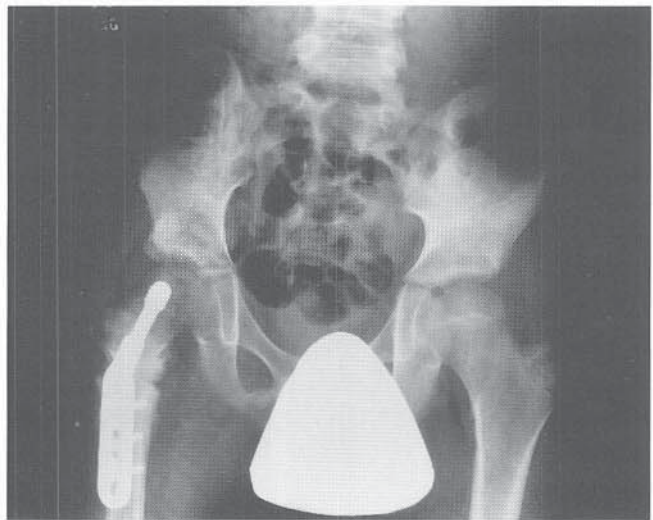
- Steel's fusion and Syme's amputation: Indicated when the hip is unstable and the patient does not desire a rotationplasty.
- Steel's fusion and rotationplasty: Indicated when the hip is unstable and the patient desires the improved function of a rotationplasty.
- Brown's fusion of femur to pelvis with rotationplasty: Indicated as an alternative to the Steel procedure for an unstable hip and for improved knee control and proprioception.



**FIGURE 32-29** Girl with bilateral femoral deficiency. Prostheses to increase her height are the only appropriate treatment measures. (From Herring JA, Cummings DR: *The limb-deficient child*. In Morrissy RT, Weinstein SL (eds): *Lovell and Winter's Pediatric Orthopaedics*, 4th ed, vol 2. Philadelphia, Lippincott-Raven, 1996.)



A

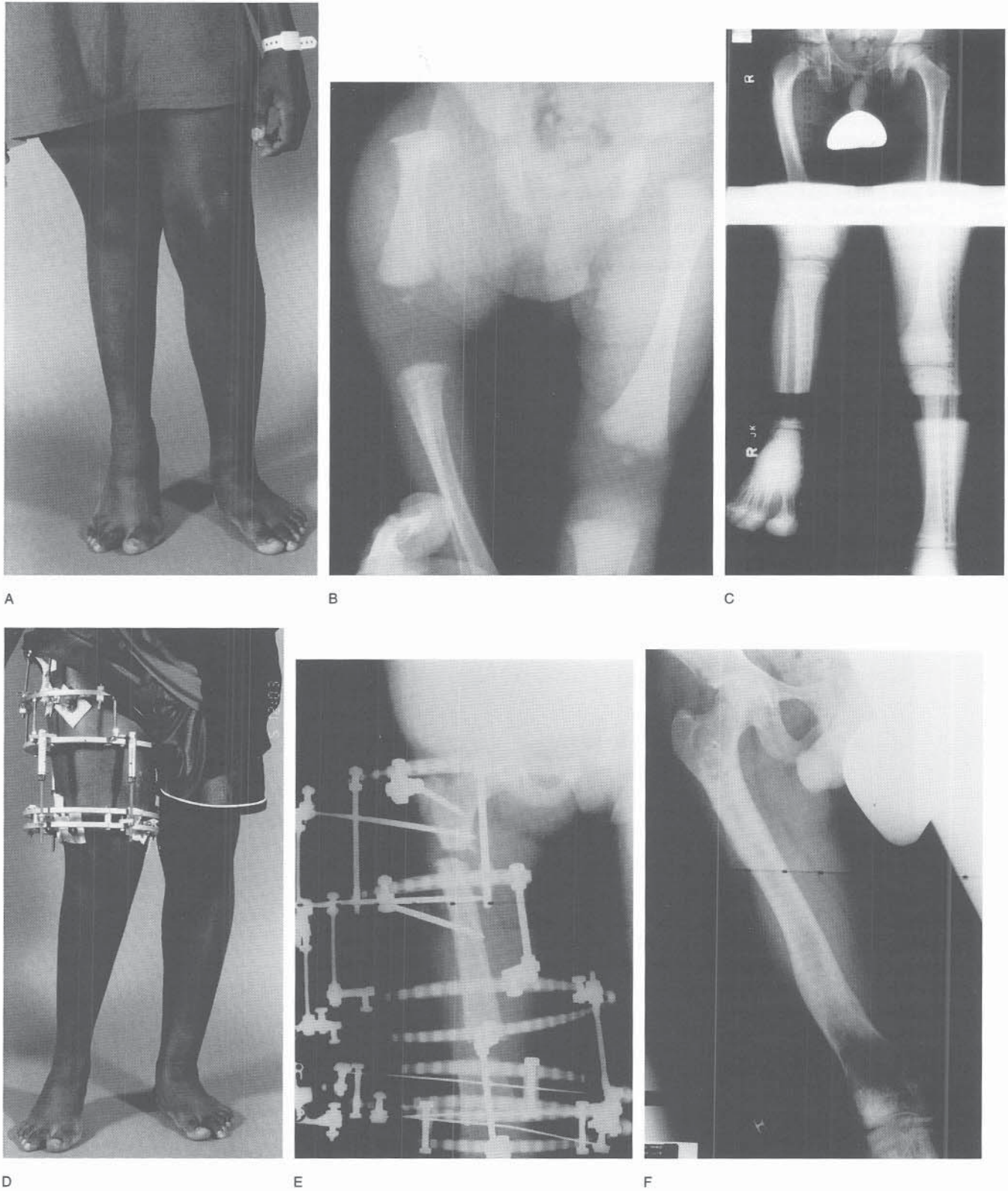


B

**FIGURE 32-30** A, Radiograph of a child with a short femur and varus femoral neck with a deficient acetabulum. B, The neck-shaft angle of the femur has been corrected and the acetabulum improved with a Dega osteotomy. The hip is now better able to withstand the forces that will be imposed by the upcoming femoral lengthening. (From Herring JA, Cummings DR: *The limb-deficient child*. In Morrissy RT, Weinstein SL (eds): *Lovell and Winter's Pediatric Orthopaedics*, 4th ed, vol 2. Philadelphia, Lippincott-Raven, 1996.)

need to undergo multiple staged lengthenings. Specific indications for reconstruction await further studies that consider function as well as length, and also take into consideration the hardships involved.

Normally, femoral lengthening is not performed when the child is young. This means that the orthopaedist must manage the patient so that the child can participate in normal, everyday childhood activities. In very young children, the shorter limb can be treated with simple extension prostheses or large shoe lifts. In older children these devices are unattractive. For these patients, an equinus prosthesis, which is more cosmetically pleasing than a large shoe lift, will effectively equalize limb lengths and allow the child full



**FIGURE 32-31** Child with a Gillespie type A proximal femoral deficiency. **A**, Front view showing shortened right femur with lateral rotation of the femur and mild genu valgus. **B**, Radiograph obtained at 1 month of age showing varus of the femoral neck, lateralization of the hip, and shortening of the femur. Note that the femur is half as long as the contralateral femur. **C**, An orthoentgenogram obtained at 6 years of age showing a 12.5-cm limb length discrepancy. The hip appears reduced without treatment. **D**, Patient at age 14 years with a circular fixator in place for femoral lengthening. **E**, Radiograph showing placement of circular fixator. **F**, Radiograph obtained after femoral lengthening, in which the femur gained 9 cm. The patient also underwent a contralateral epiphysiodesis.

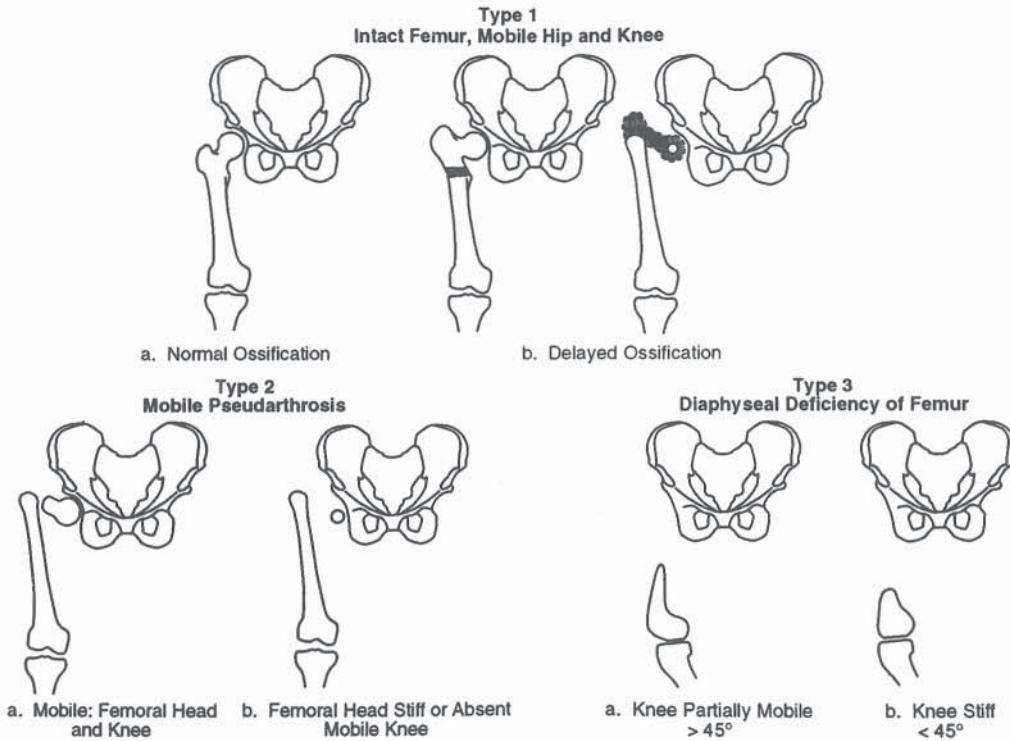


FIGURE 32-32 The Paley classification of congenital short femur syndrome, types 1-3. (From Gillespie R: Classification of congenital abnormalities of the femur. In Herring JA, Birch JG (eds): *The Child with a Limb Deficiency*. Rosemont, IL, American Academy of Orthopaedic Surgeons, 1998.)

function (Fig. 32-33). For milder discrepancies, small to moderate shoe lifts can be used.

### FIBULAR DEFICIENCY

The term *fibular deficiency* implies a congenital absence of all or part of the fibula. The syndrome of fibular deficiency encompasses a spectrum of abnormalities affecting the femur, knee, tibia, ankle, and foot. In one form, mild shortening of the fibula, valgus of the knee, anteroposterior instability of the knee, and shortening of the femur are present. In another presentation the fibula is absent, the tibia is shortened, with a sharp anteromedial bow distally, and the foot is small, with missing rays and a marked equinovalgus deformity.

The precise cause of fibular hemimelia is unknown in most cases, and the deformity normally occurs sporadically. Although 15 percent of all patients with congenital absence of the fibula have associated deficiencies of the femur,<sup>13</sup> Kruger and Talbott noted that all of their fibula-deficient patients with five-rayed feet and 50 percent of those with fewer rays had shortened femurs.<sup>159</sup>

#### Classification of Fibular Deficiency

**FRANTZ AND O'RAHILLY CLASSIFICATION.** Fibular hemimelia may be an intercalary deficiency with a normal foot or a terminal deficiency with absent rays of the foot. The deficiency is always paraxial (i.e., longitudinal).

**COVENTRY AND JOHNSTON CLASSIFICATION.** This system classifies patients into 3 groups.<sup>48</sup> Partial absence of the fibula is classified as type I and complete fibular absence as type II.

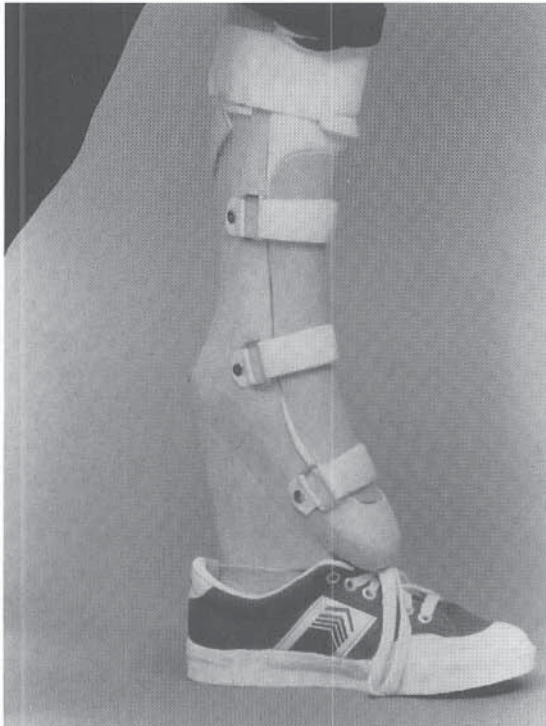


FIGURE 32-33 An equinus prosthesis for equalizing leg lengths in a child with a short femur.

Type III includes bilateral absence of the fibulae and cases of other skeletal abnormalities associated with unilateral fibular absence.

**ACHTERMAN AND KALAMCHI CLASSIFICATION.** This system, which is more clinically useful, classifies fibular hemimelia based on the degree of fibular deficiency present (Fig. 32–34).<sup>2</sup> If any portion of the fibula is present, it is classified as type I, and further subclassified as either type IA or IB. In type IA the epiphysis of the proximal fibula is distal to the level of the tibial growth plate and the physis of the distal fibula is proximal to the dome of the talus. In type IB the fibula is shorter by 30 to 50 percent, and distally the fibula does not provide any support at the ankle joint. The authors reported that tibial discrepancy was 6 percent in type IA and 17 percent in IB, and that total limb length discrepancy at maturity was 12 percent in type IA and 18 percent in IB. If the fibula is completely absent, the deformity is classified as type II. Tibial discrepancy was 25 percent and total limb length discrepancy at maturity was 19 percent in type II cases.

**BIRCH CLASSIFICATION.** This system was developed because the existing classifications of fibular deficiency did not provide satisfactory guidelines for managing the deformities.<sup>24</sup> A major shortcoming of other classifications is that they do not deal with shortening of the total limb, one of the most significant factors that orthopaedists must consider when making management decisions.

In a review of children treated for fibular deficiency at Texas Scottish Rite Hospital for Children between 1957 and 1996, approximately 50 percent of the patients had concomitant shortening of the femur. This study found no direct correlation between fibular length and the severity of the deformity, as implied by other classifications. For example, more than 50 percent of patients with complete absence of the fibula had a salvageable lower limb with a functional foot. A functional foot was defined as a foot that was or can be made plantigrade and had three or more rays. A direct correlation was found between the number of rays and the chances of preserving the foot. It was possible to preserve all five-rayed feet, whereas no foot with two or fewer rays was salvageable. Birch's functional classification of fibular deficiency with general treatment guidelines for each group is provided in Table 32–9.

**Clinical Presentation.** Children with partial absence of the fibula present with varying degrees of femoral shortening, valgus of the knee, anterior cruciate ligament deficiency with absence of the tibial spine, and a tarsal coalition (Fig. 32–35). The lateral malleolus is proximal in the ankle mortise, and there is a slight valgus of the ankle. Because the deformity affects the entire lower limb, the final limb length discrepancy is due to shortening of both the femur and the tibia, with ranges from 12 to 18 percent of the length of the limb.<sup>2</sup>

Children with complete fibular hemimelia present with anterolateral bowing of the tibia, equinovalgus deformity of the foot, and a tarsal coalition. The affected limb is always significantly shorter than the contralateral limb, and there often is additional shortening of the ipsilateral femur (Figs. 32–36 and 32–37).<sup>13,159,316</sup> The articular surface of the distal tibia faces posteriorly and laterally. The flat upper surface of the fused talocalcaneus articulates with the tibia in a valgus and equinus position. The foot may be missing one,

two, or more lateral rays. In milder variants of this type, there is some fibular remnant present and lesser degrees of shortening and foot deformity.

## Treatment

### PARTIAL FIBULAR HEMIMELIA

**Amputation or Limb Lengthening.** The decision to treat patients with partial fibular hemimelia by amputation or limb lengthening depends on the degree of predicted shortening at maturity and the condition of the foot and ankle of the affected limb.<sup>128</sup> If the predicted discrepancy at maturity is 25 cm or more and there is severe valgus of the ankle with a deformed foot, the patient should be treated with a Syme or Boyd amputation and prosthetic management. On the other hand, the patient with a predicted shortening of 8 cm or less, a functional, plantigrade foot with four or more rays, and a stable, mobile ankle is a good candidate for a lengthening procedure with or without epiphysiodesis.

Johnston and Haideri compared the function of patients with fibular hemimelia after lengthening with the function of patients who had undergone a Syme amputation.<sup>139</sup> The lengthened limbs had better power generation at the ankle than the Syme amputation limbs but had significant loss of dorsiflexion. The Syme patients were able to generate power similar to that on their normal side by increasing hip power to compensate for decreased ankle power. Actual functional comparisons were difficult to make because the patients who had undergone a Syme amputation had more severely deficient extremities.

The choice of amputation or lengthening for children who fall in between the criteria identified above must be made on an individual basis. The number of lengthening procedures deemed necessary, the degree of reconstructive difficulty, and the expected functional outcome need to be considered. Lengthening procedures have recently been developed, but long-term results are not yet available to aid the orthopaedist in making the appropriate decision. It is helpful for parents to consult surgeons experienced in both amputation and lengthening treatment of fibular deficiency, and to meet children and families who have undergone the procedures.

For those patients who qualify, single or staged lengthen-

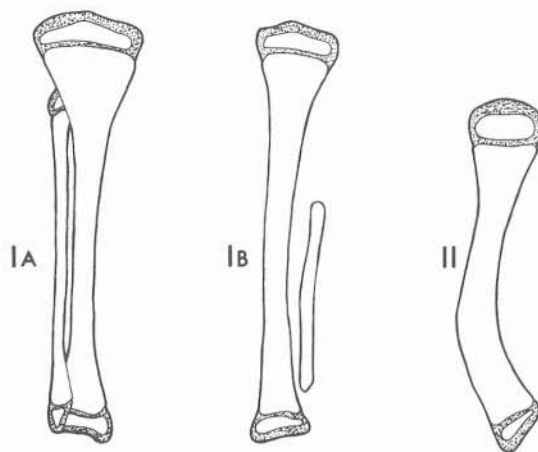


FIGURE 32–34 Achterman and Kalamchi classification of fibular hemimelia. (From Herring JA, Cummings DR: *The limb-deficient child*. In Morrissy RT, Weinstein SL (eds): *Lovell and Winter's Pediatric Orthopaedics*, 4th ed, vol 2. Philadelphia, Lippincott-Raven, 1996.)



**TABLE 32–9 Fibular Deficiency: Birch's Functional Classification with Treatment Guidelines**

Classification	Treatment
Type I—Functional foot	
• IA 0%–5% inequality	Orthosis/epiphysiodesis
• IB 6%–10% inequality	Epiphysiodesis ± limb lengthening
• IC 11%–30% inequality	One to two limb lengthening or amputation
• ID >30% inequality	More than two limb lengthening versus amputation
Type II—Nonfunctional foot	
• IIA Functional upper limb	Early amputation
• IIB Nonfunctional upper limb	Consider limb salvage procedure

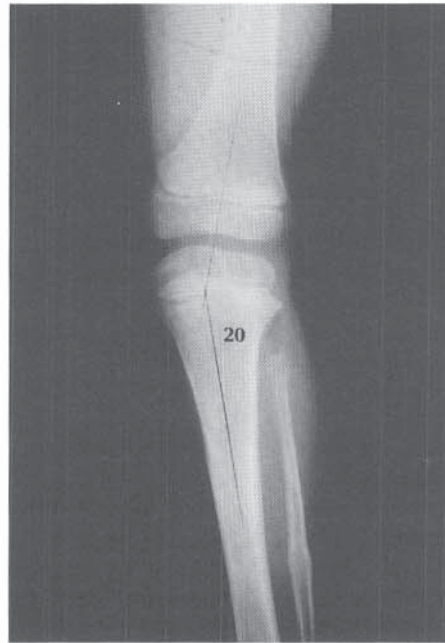
ing with repositioning of the foot may be successful, and the short fibula may be differentially lengthened relative to the tibia to reestablish a more normal tibial-fibular relation. Most of these patients, though, have a tarsal coalition and an abnormal talotibial articulation, and it is difficult to predict the long-term function of the retained foot and ankle. The frequency of complications of lengthening procedures is directly related to the amount of discrepancy present.

Regardless of which treatment method is used, some of these patients develop gradually progressive valgus of the knee. This condition should not be treated until 1 to 2 years before the patient reaches skeletal maturity, at which time a partial growth arrest procedure or a tibial osteotomy may be done. If the degree of valgus is greater than 15 degrees and there is at least 2 cm of remaining growth, a medial epiphysiodesis of the proximal tibia or distal femur (based on the site of the valgus) can be performed to gradually correct the deformity.<sup>89</sup>

Good outcomes have been reported with the use of medial distal femoral physal stapling to correct the valgus deformity.<sup>26</sup> We prefer not to use staples, though, because they are poorly tolerated under a prosthesis, and the outcome is unpredictable, owing to rebound growth after staple removal. Because the deformity may overcorrect into varus following a partial epiphysal arrest, angular deformity needs to be closely monitored during the first year after the arrest. When the limb reaches neutral alignment after the procedure and the lateral portion of the physis of the proximal tibia remains open, a lateral epiphysiodesis should be performed to prevent overcorrection.

#### COMPLETE FIBULAR HEMIMELIA

**Amputation.** In the past, different surgical procedures were performed in an attempt to centralize the patient's foot and lengthen the limb. Today there is general consensus that ankle disarticulation, pioneered by Badgley in the early 1940s, is the best treatment for complete fibular hemimelia.<sup>4,13,68,159,316</sup> The procedure should be done in early childhood and the patient fitted with a Syme-type prosthesis afterward. Most series in which the modified Syme amputation was performed have reported good results. Some surgeons prefer the Boyd amputation, in which the retained calcaneus can be used to stabilize the heel pad, especially for older boys.<sup>157,160</sup> Others have reported good results with both procedures and have found that the best outcomes correlated with central placement of the heel pad.<sup>64</sup> We have found that although migration of the heel pad occasionally

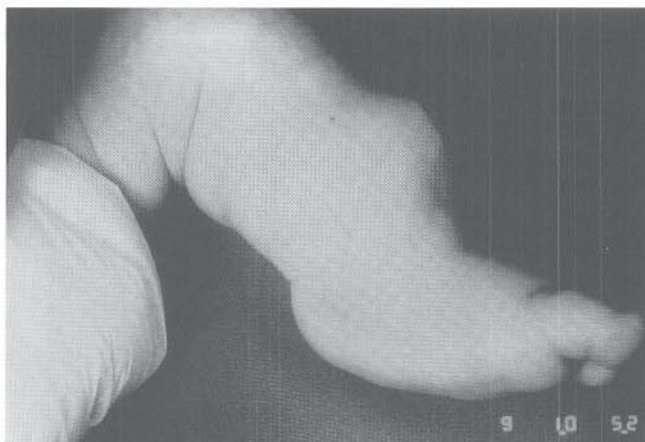

**FIGURE 32–35** Typical radiographic appearance of partial fibular hemimelia. (From Herring JA, Cummings DR: *The limb-deficient child*. In Morrissy RT, Weinstein SL (eds): *Lovell and Winter's Pediatric Orthopaedics*, 4th ed, vol 2. Philadelphia, Lippincott-Raven, 1996.)

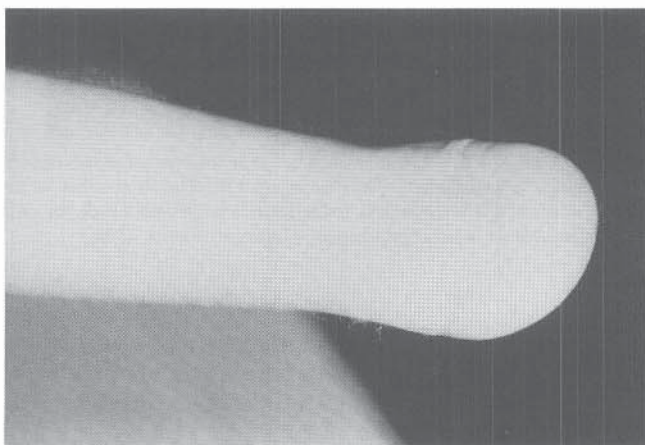
occurs following a Syme amputation, this usually does not create significant problems for the patient or the prosthetist (see Fig. 32–37).<sup>125</sup> Thus, we prefer the Syme procedure to the Boyd amputation.

The optimum time to perform the amputation is when the child is just starting to pull to stand up (normally at 9 to 10 months). If the operation is done at this time, the child will be able to ambulate in a prosthesis at approximately 1 year and will be able to function at a nearly normal level, running and playing all sports.<sup>125</sup> Mild tibial bowing is usually well tolerated and corrective osteotomy is not necessary. However, if the bowing is marked and there is too great an anterior prominence, the surgeon can perform a tibial osteotomy at the same time the amputation is performed. Distal tibial bowing may recur and occasionally requires osteotomy as the child grows.

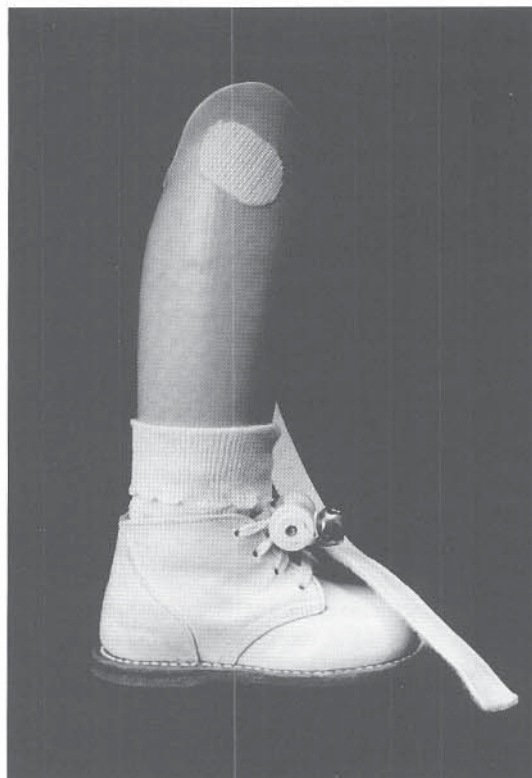
**Limb Lengthening.** Because of improved techniques, there has been renewed interest in using limb lengthening procedures to treat deformities and limb length inequality in children with complete fibular hemimelia (Figs. 32–38 and 32–39).<sup>37,76</sup> Patients whose discrepancies are less than 5 cm at birth and who do not have significant foot deformities may be suitable candidates; however, the specific indications and long-term outcomes of limb lengthening are not well defined at this time. These patients usually must undergo several lengthening procedures and may end up with significant functional deficits because of foot and ankle deformities. Although limb lengthening allows the patient to maintain the foot of the affected limb, this benefit must be weighed against the drawbacks of lengthening procedures.<sup>127</sup> For patients whose limb length discrepancies at birth are greater than 5 cm and for those who have notable foot deformities, we concur with Kruger that the most appro-



A



B



C

FIGURE 32–36 A child with fibular hemimelia treated with a Syme amputation. A, Appearance of the extremity before surgery. B, Appearance of the limb after Syme amputation. C, Typical Syme's prosthesis. (From Herring JA, Cummings DR: *The limb-deficient child*. In Morrissy RT, Weinstein SL (eds): *Lovell and Winter's Pediatric Orthopaedics*, 4th ed, vol 2. Philadelphia, Lippincott-Raven, 1996.)

appropriate treatment is amputation and prosthetic management.<sup>157,158,160,161</sup>

#### BILATERAL FIBULAR HEMIMELIA

**Amputation.** Children with bilateral fibular hemimelia usually have very little length discrepancy between the two lower limbs; however, a major problem is the disproportion between the lengths of the legs and the rest of the body. In the young child this discrepancy may be acceptable, but as the child matures, the difference in femoral and tibial lengths results in an unbecoming "dwarfism" because of the short tibiae. If there is significant shortening of the tibiae, and if the feet and ankles are malformed, the recommended treatment is ankle disarticulation. Bilateral lengthening may at times be appropriate for these individuals.

**Limb Lengthening.** If tibial shortening is not significant and if the feet are well aligned, the feet should be preserved and lengthening of the tibiae may be considered. Kruger concluded that 50 percent of his patients with bilateral fibular hemimelia should have undergone amputation instead of limb-salvage procedures.<sup>159</sup> However, this study was conducted before the development of more sophisticated limb lengthening techniques.

#### TIBIAL DEFICIENCY

Tibial deficiency, or tibial hemimelia, is a syndrome of partial to complete absence of the tibia at birth. For most children born with tibial hemimelia, the cause is unknown. However, there are a number of heritable forms of the condition that have an autosomal dominant pattern.<sup>41,163,241</sup> In these types, the deformity usually involves both limbs, there is duplication of the toes, and the patient may have coexisting anomalies of the hands. Four distinct autosomal dominant syndromes have also been identified: (1) tibial hemimelia-foot polydactyly-triphalangeal thumbs syndrome (Warner's syndrome), (2) tibial hemimelia diplopodia syndrome, (3) tibial hemimelia-split hand and foot syndrome, and (4) tibial hemimelia-micromelia-trigonobrachycephaly syndrome. In some children with tibial hemimelia, the disorder may have an autosomal recessive inheritance pattern.<sup>230</sup>

Many associated abnormalities are seen in these patients, including syndactyly, polydactyly, foot oligodactyly, split hand and foot, five-fingered hand, onychia, bifid femurs, ulnar and fibular reduplication, radioulnar synostosis, radial ray agenesis, micromelia, trigonomacrocephaly, diplopodia, joint hyperextensibility, and deafness. In a retrospective review of patients seen with tibial deficiency over a 22-year period (1961 to 1983), 34 children had associated congenital

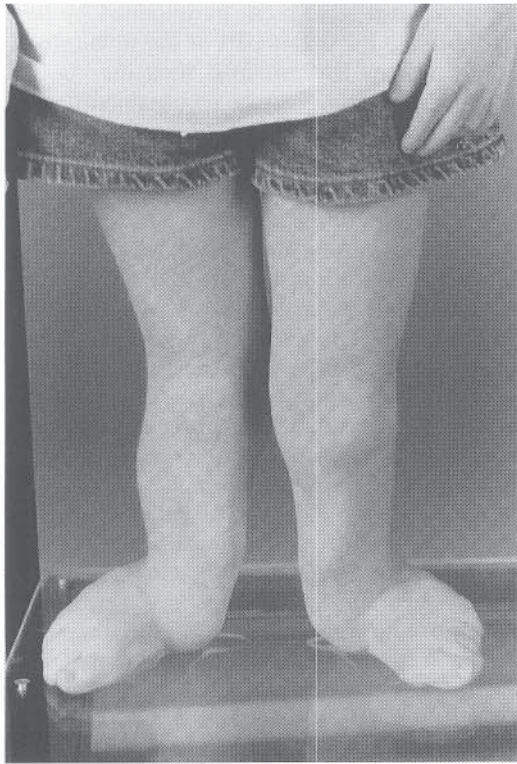

FIGURE 32-37 Another clinical presentation of complete, bilateral fibular hemimelia.

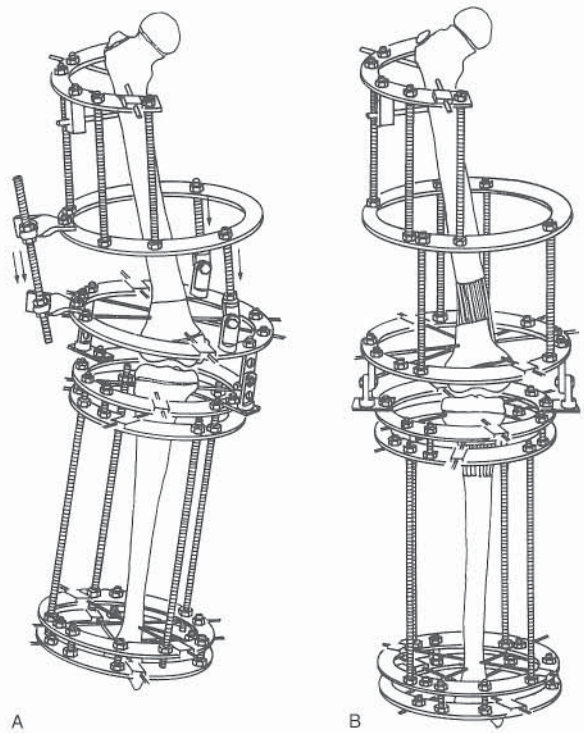


FIGURE 32-39 A femoral-tibial Ilizarov frame for lengthening and deformity correction in a patient with fibular hemimelia and femoral shortening. **A**, Frame placement. **B**, Position after lengthening of the distal femur and proximal tibia, and correction of femoral valgus. (From Catagni MA: Management of fibular hemimelia using the Ilizarov method. Instr Course Lect 1992;41:431. Reprinted with permission from the American Academy of Orthopaedic Surgeons.)

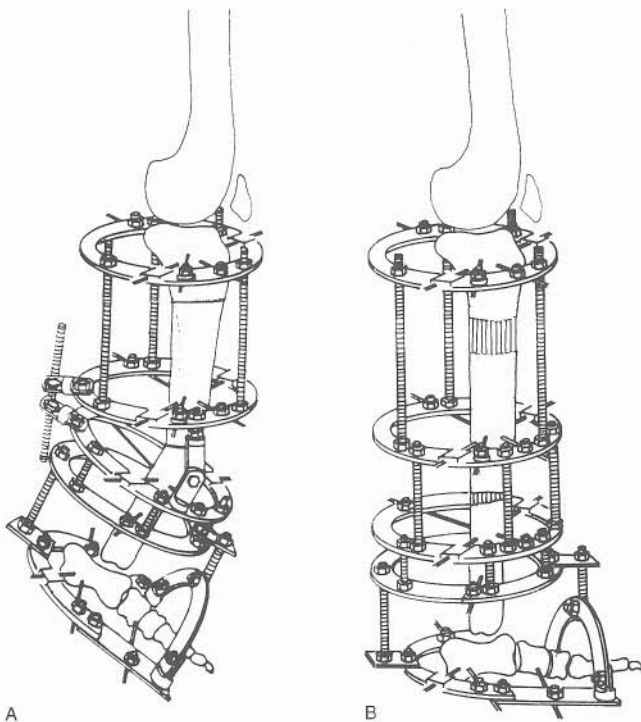


FIGURE 32-38 Ilizarov frame technique for treating fibular hemimelia. **A**, Placement of the frame and osteotomies proximally and at the apex of the deformity. **B**, Position after lengthening and deformity correction. (From Catagni MA: Management of fibular hemimelia using the Ilizarov method. Instr Course Lect 1992;41:431. Reprinted with permission from the American Academy of Orthopaedic Surgeons.)

anomalies, with abnormalities of the hip, hand, or spine occurring alone or in various combinations.<sup>250</sup>

**Jones Classification of Tibial Deficiency.** The Jones system classifies tibial hemimelia into four types, based on radiographic features present during infancy (Fig. 32-40).<sup>140</sup> In type 1 the tibia cannot be seen on radiographs at birth. In subtype 1a the tibia is completely absent. In this type the ossific nucleus of the distal femoral epiphysis is small or has not appeared at birth. In subtype 1b the proximal part of the tibia is present, but because it is not ossified at birth, it appears to be absent. In this type there is normal ossification of the distal femoral epiphysis.

In type 2 the proximal part of the tibia is ossified and visible on radiographs at birth, but the distal tibia is not seen (Fig. 32-41). In type 3 the distal part of the tibia is ossified and visible, but the proximal portion of the tibia is absent. Often a unique, amorphous osseous structure forms (representative of the shaft of the tibia), and eventually a rudimentary surrogate knee-ankle articulation develops.<sup>249</sup> This is the least common form of tibial hemimelia.

In type 4 the tibia is short and there is distal tibiofibular diastasis (Fig. 32-42). In these cases (previously referred to as congenital diastasis of the ankle), the distal tibial articular surface is absent, there is proximal displacement of the talus, and the tibia and fibula separate at the ankle.

**Clinical Presentation.** Patients with complete absence of the tibia (Jones type 1a) will have a knee flexion contracture, with the knee positioned proximal and lateral to the femoral condyles (Fig. 32-43). When the tibia is not visible on






Type	Radiological Description	No. of limbs
1	 <ul style="list-style-type: none"> <li>• Tibia not seen</li> <li>• Hypoplastic lower femoral epiphysis</li> </ul>	6
	 <ul style="list-style-type: none"> <li>• Tibia not seen</li> <li>• Normal lower femoral epiphysis</li> </ul>	12
2	 <ul style="list-style-type: none"> <li>• Distal tibia not seen</li> </ul>	5
3	 <ul style="list-style-type: none"> <li>• Proximal tibia not seen</li> </ul>	2
4	 <ul style="list-style-type: none"> <li>• Diastasis</li> </ul>	4

FIGURE 32–40 Jones classification of tibial deficiency. (From Herring JA, Cummings DR: The limb-deficient child. In Morrissy RT, Weinstein SL (eds): Lovell and Winter's Pediatric Orthopaedics, 4th ed, vol 2. Philadelphia, Lippincott-Raven, 1996.)

radiographs, careful examination of the proximal part of the patient's limb may reveal a palpable tibial segment that has not yet ossified. This clinical finding can often be better appreciated on ultrasound or magnetic resonance imaging (MRI).<sup>103</sup> When there is complete absence of the tibia, the child normally has hamstring function but not quadriceps function, the patella is typically absent, and the foot, which is fixed in severe varus, has minimal functional movement.

In patients with Jones types 1b and 2 deformities, in which the proximal part of the tibia is present but the distal portion is absent, hamstring and quadriceps function is normal and the knee moves normally. The fibular head will be displaced proximally and laterally, and the limb will be in a varus position, with significant varus instability. At the ankle joint, the foot is displaced medially relative to the fibula, and will also be in varus.

In Jones type 3 deformity, the knee is unstable and there are extra digits distally. The tibial shaft is palpable, and there is a severe varus deformity of the leg.

In patients with a Jones type 4 deformity, in which there is a diastasis of the distal tibia and fibula, the limb is moderately short and the foot is in a severe, rigid varus, positioned between the tibia and fibula.

### Treatment

**PARTIAL TIBIAL HEMIMELIA.** For Jones types 1b and 2 deformities, in which the proximal part of the tibia is present,

excellent functional results can be obtained by fusing the proximal fibula to the upper part of the tibia (see Fig. 32–41).<sup>8,114,140</sup> In infants the proximal tibia may be primarily cartilaginous, and fusion cannot be obtained until there is sufficient ossification of the upper tibia to allow for successful synostosis with the fibula. Fusion of the fibula to the tibia may be done in an end-to-end position with intramedullary pin fixation or in a side-to-side position using a screw for fixation. When joining the fibula to the tibia, the surgeon should consider resecting the proximal protruding fibula because, if left intact, it can adversely affect prosthetic fit and function.<sup>249</sup> A Syme amputation with subsequent prosthetic management is the best treatment for the distal part of the limb because of the severe foot and ankle instability. After the synostosis has healed, these children are able to function as well as other Syme-level amputees, and participation in normal sports activities is the norm.

For a Jones type 4 deformity, in which there is diastasis of the distal tibia and fibula (see Fig. 32–42), the best treatment is a modified Syme ankle disarticulation performed when the child reaches walking age. Functional results following the procedure are usually excellent. Other techniques, such as tibial lengthening and foot repositioning, may make it possible to retain a plantigrade foot, but functional reconstruction is difficult because of talus and calcaneus deformities and the absence of a distal tibial articular surface.<sup>140</sup> New limb lengthening procedures may enable the orthopaedist to treat the diastasis abnormality in other ways; however, the long-term results of these techniques are not known.

For the rare Jones type 3 deformity, the limited data available show that these patients function relatively well as below-knee amputees following a Syme or Chopart amputation.<sup>249</sup> Some of these patients may be candidates for tibial lengthening, depending on the anatomy of the ankle joint.

**COMPLETE TIBIAL HEMIMELIA.** Most patients with complete tibial hemimelia (Jones type 1a) require a knee disarticulation, which usually provides good functional results. In a gait analysis of six children who underwent knee disarticulation, gait velocity averaged 81 percent of normal, the time for a single gait cycle was 131 percent of normal, and energy expenditure was within the normal range.<sup>178</sup> As expected, the patients' ability to run was significantly decreased (time for the 50-yard dash was below the fifth percentile for age group). However, the prosthetic knee demonstrated good flexion during the swing phase of gait and no flexion in stance phase, which allowed the patients a stable, extended knee with weightbearing. No residual limb problems developed.

Centralization of the fibula combined with a Syme amputation (i.e., the Brown procedure) has frequently been used to treat this deformity (see Fig. 32–43)<sup>32,33</sup>; however, this approach is prone to failure and the patient often requires a subsequent knee disarticulation.<sup>144,178,217,250</sup> Most failures are due to marked knee instability and the progressive development of knee flexion contracture because of unopposed hamstring pull.<sup>250</sup> In one study, 53 of 55 patients with Jones type 1a tibial hemimelia who were treated by the Brown procedure developed flexion contractures that resulted in poor outcomes.<sup>179</sup> Anterior transfer of the hamstrings for active knee extension is impeded because there is no patella or femoral condylar notch. All of these factors also make prosthetic management of these patients very difficult.

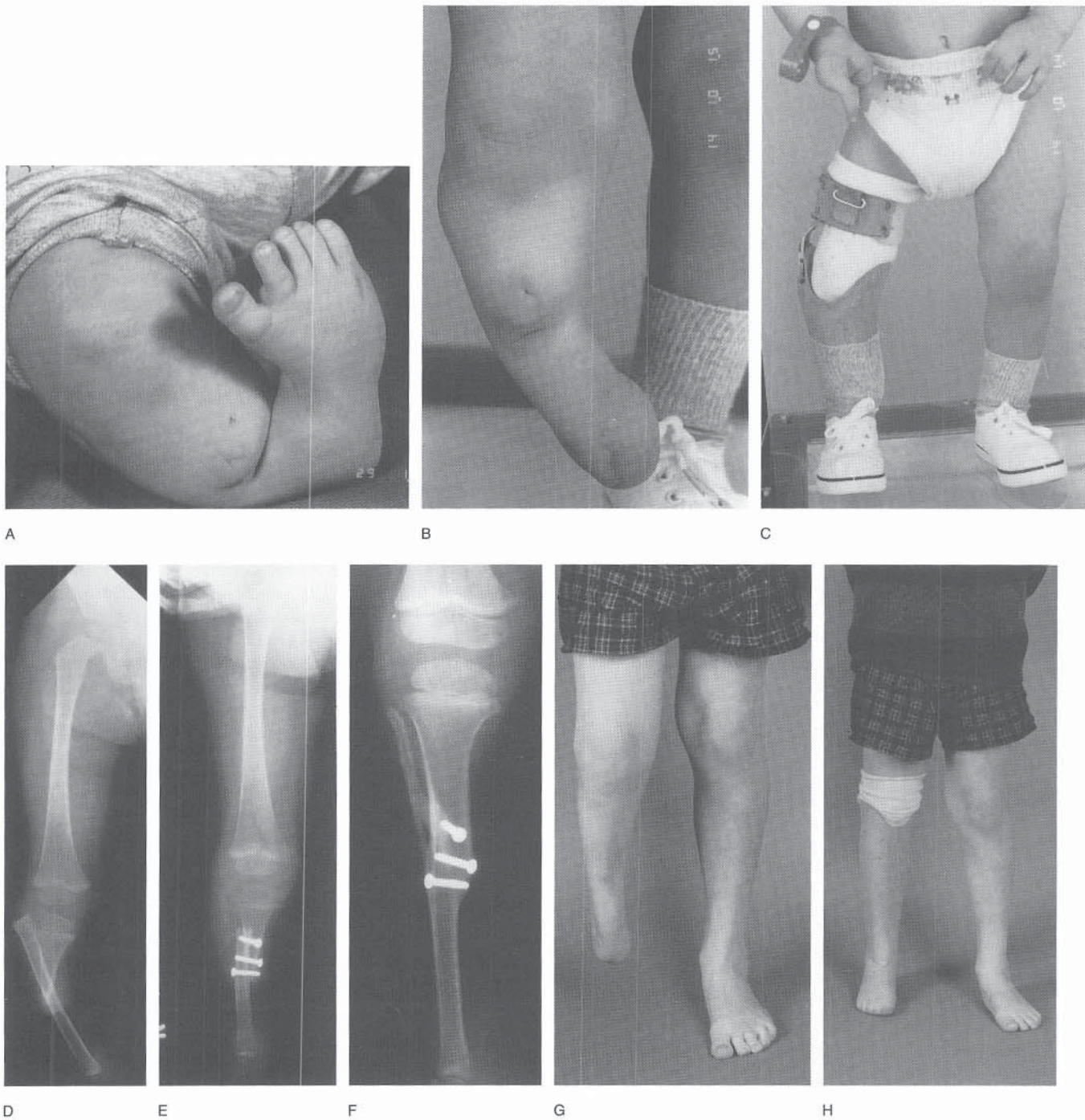

FIGURE 32-41 A child with partial tibial hemimelia, Jones type 2. **A**, In infancy, there was marked varus of the foot. The proximal portion of the tibia could be seen and palpated beneath the dimple. **B**, Appearance after Syme amputation. The tibial segment was not sufficiently ossified at this age for a synostosis procedure to be performed. **C**, Appearance in a prosthesis with a thigh support to control the varus of the lower segment. **D**, AP radiograph obtained at age 5 showing absence of the tibia below the upper third. **E**, AP radiograph after excision of the upper fibula and synostosis of the fibula to the tibia. **F**, AP radiograph obtained at age 10 showing solid arthrodesis between the tibia and fibula. **G**, The limb after the synostosis procedure, with excellent alignment and end weightbearing capabilities. **H**, The prosthesis now is a simple Syme-type prosthesis, which gives excellent functional and cosmetic results.

Hall has stated that the Brown procedure is primarily indicated only if the patient has a well-developed distal femoral segment, a functioning quadriceps mechanism, preferably a patella, and no evidence of a proximal tibia (by present imaging techniques).<sup>108,258</sup> When these criteria are met preoperatively, the procedure has been reported to be

successful<sup>40</sup>; however, patients with type 1 tibial hemimelia rarely have active knee extension. In most cases there is a gradual decline in knee function, and recurrent deformity often requires repeated surgical revisions, with eventual amputation necessary.<sup>157,160</sup> Thus, the Brown procedure is rarely indicated for patients with complete tibial hemimelia. As

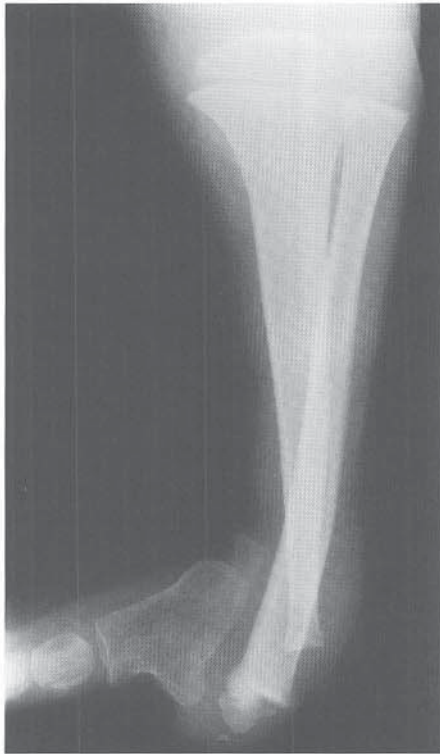

FIGURE 32-42 Tibial hemimelia type 4, with diastasis of the tibia and fibula. Note the severe displacement of the foot.

succinctly stated by Loder, "It is clear from this literature review that the Brown procedure uniformly fails in the treatment of Jones type 1a tibial deficiency. I believe it should not be attempted in the 'hopes that it might work,' because it will always end in failure at long-term follow-up."<sup>179</sup>

### CONGENITAL FOOT DEFICIENCIES

Congenital foot deficiencies are most commonly caused by constriction band formation (Streeter bands) (Fig. 32-44). Congenital absence of the complete foot is a very rare abnormality. Children with congenital partial foot absences usually do not need surgical intervention, do not develop contractures, and have minimal, if any, functional limitations.<sup>25</sup> A slipper-type prosthesis can allow for normal shoe wear and function (Fig. 32-45).

## Congenital Upper Limb Deficiencies

### TRANSVERSE DEFICIENCIES

**Etiology.** The etiology of most transverse upper limb deficiencies is unknown. The subclavian artery disruption sequence has been proposed as a common pathway but remains speculative.<sup>20</sup> The resultant vascular insult would explain the pattern of limb abnormalities seen in symbrachydactyly, Poland's and Möbius syndromes, and transverse deficiencies in which there are small "nubbins." The presence of ectoderm-derived tissues (skin, nails, and distal pha-

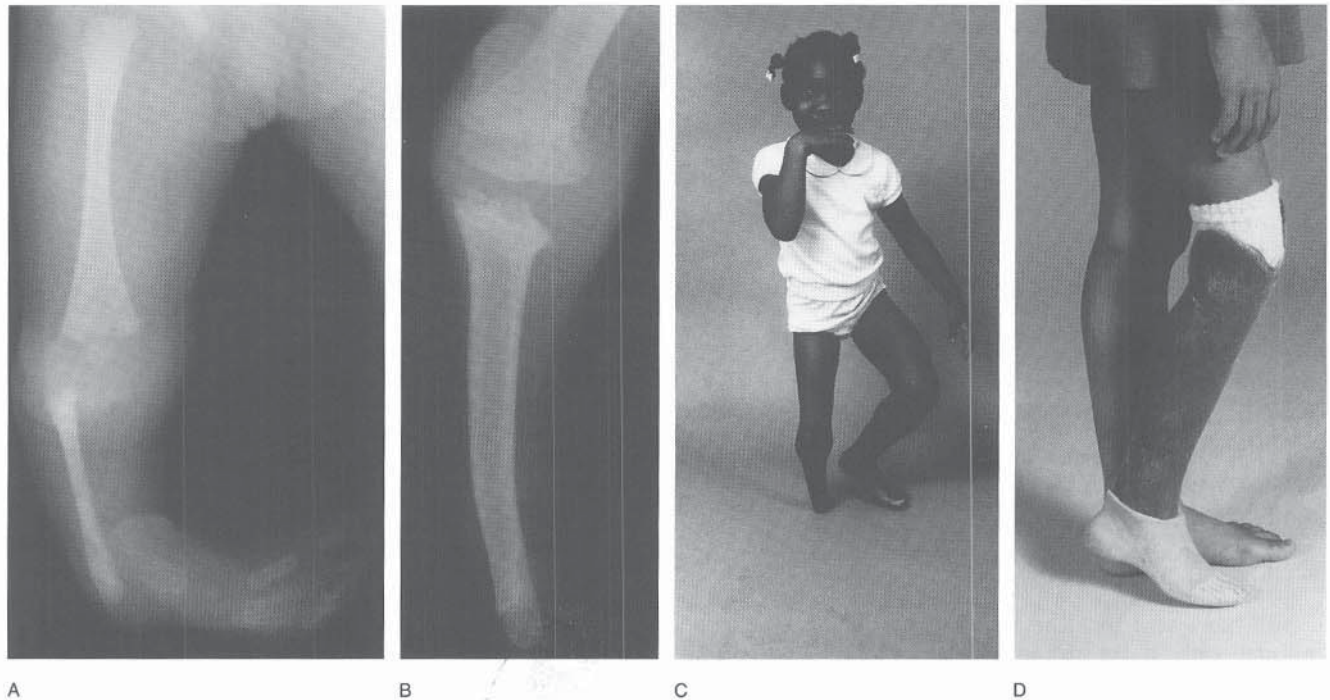


FIGURE 32-43 Girl with complete tibial hemimelia, type 1. A, Radiograph obtained at age 1 month. B, Radiograph of limb obtained following Brown centralization procedure. C, Clinical appearance after Brown procedure. D, Appearance in the prosthesis. The subsequent development of knee flexion deformity reduced the function of the extremity, and amputation is likely.

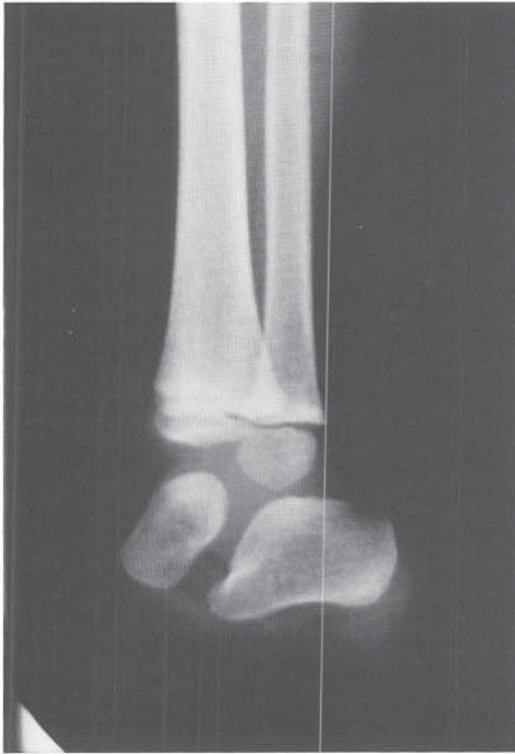

FIGURE 32-44 Congenital absence of the foot distal to the talonavicular calcaneocuboid level. (From Herring JA, Cummings DR: *The limb-deficient child*. In Morrissy RT, Weinstein SL (eds): *Lovell and Winter's Pediatric Orthopaedics*, 4th ed, vol 2. Philadelphia, Lippincott-Raven, 1996.)

langeal tuft) supports the concept of failure of normal mesodermal proliferation. Limb anomalies range from minimal shortening to proximal level of absence.

**Classification of Symbrachydactyly.** There are four classes of symbrachydactyly in the spectrum of presentation. The short-fingered type is most likely to be associated with Poland's anomaly (absence of the sternal head of the pectoralis

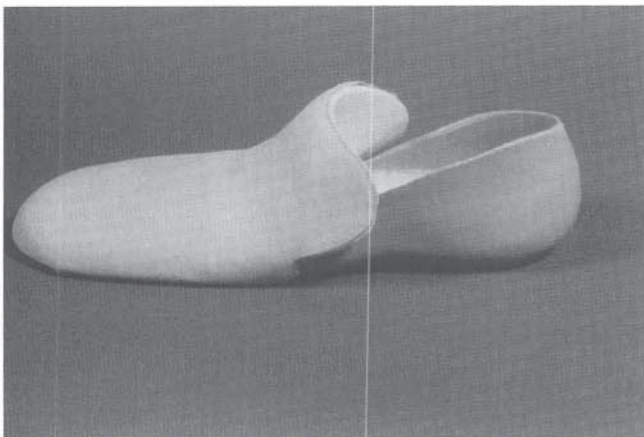


FIGURE 32-45 Slipper-type prosthesis for partial foot absence. (From Herring JA, Cummings DR: *The limb-deficient child*. In Morrissy RT, Weinstein SL (eds): *Lovell and Winter's Pediatric Orthopaedics*, 4th ed, vol 2. Philadelphia, Lippincott-Raven, 1996.)

major muscle) (Fig. 32-46). The other forms are the central defect or split hand type, the monodactylous type, in which the thumb is always preserved, and the peromelic form, which may be quite proximal.

**Treatment of Symbrachydactyly.** The surgeon must first decide how to treat any existing nubbins, as their presence can result in a number of problems. They may become entangled in hair or strands of thread and become excoriated or dysvascular. Small nails that grow abnormally may become irritated, infected, or difficult to trim. In the split hand form of symbrachydactyly, nubbins may develop on the ridge in the central part of the hand and be easily traumatized (Fig. 32-47). In this situation, local skin rearrangement and removal of the nubbins will deepen the web and smooth the residual commissure. Some clinicians, though, rarely amputate nubbins (Fig. 32-48). They report that many children find these small digits make them feel less abnormal and are quite fond of their nubbins. It is important to keep in mind that some nubbins are functional. Those that are under volitional control or are large enough for possible subsequent soft tissue and bony augmentation should not be removed.<sup>67</sup>

After the nubbins have been appropriately treated, reconstructive surgery to improve limb function is the next treatment step. Children who have some structures distal to the carpus may be candidates for digital reconstruction.

If the digital remnants do not have any bony support and are large enough to permit bone grafting, they can be augmented by the transplantation of nonvascularized toe phalanges (Fig. 32-49). Transplantation needs to include periosteum and ligamentous support tissue to ensure ready revascularization. To enhance bone stability in the soft tissue sleeve, the surgeon can suture the ligamentous attachments of the phalanx to adjoining bony elements in the finger. The timing of the procedure is debatable. Some believe that if the transplantation is performed when the child is young, the epiphysis of the toe (with its periosteum) has a better survival rate and will continue to grow.<sup>35</sup> Others report that if the transfer is done later, the toe phalanges will grow normally on the foot, and there is minimal risk of loss of "potential" growth after transfer.<sup>67</sup> In either case, the donor toe phalanx will be short and telescoped, similar to the original appearance of the involved finger.

In some patients, digital reconstruction can be performed by repositioning the available bony elements so that they are more functional. For example, an index metacarpal or ray might be transferred to the middle digit position to close a defect. Another option is to transfer metacarpal remnants so that enough bone is "stacked" at a border position in preparation for subsequent lengthening.<sup>67</sup>

Distraction lengthening, however, plays a limited role in treating digital deficiencies. Although the procedure may improve cosmetic appearance by making the digits longer, there is a risk of functional loss if the digits are thinner, stiffer, and more scarred. Distraction lengthening against atrophic soft tissue will cause ulcerations, and the surgeon will need to augment soft tissue coverage or shorten the digits back to an acceptable length. Lengthening in the hand is best done at an intercalary level when there is a normal digit tip (Fig. 32-50).<sup>67</sup>

An option for functional reconstruction of the adactylous

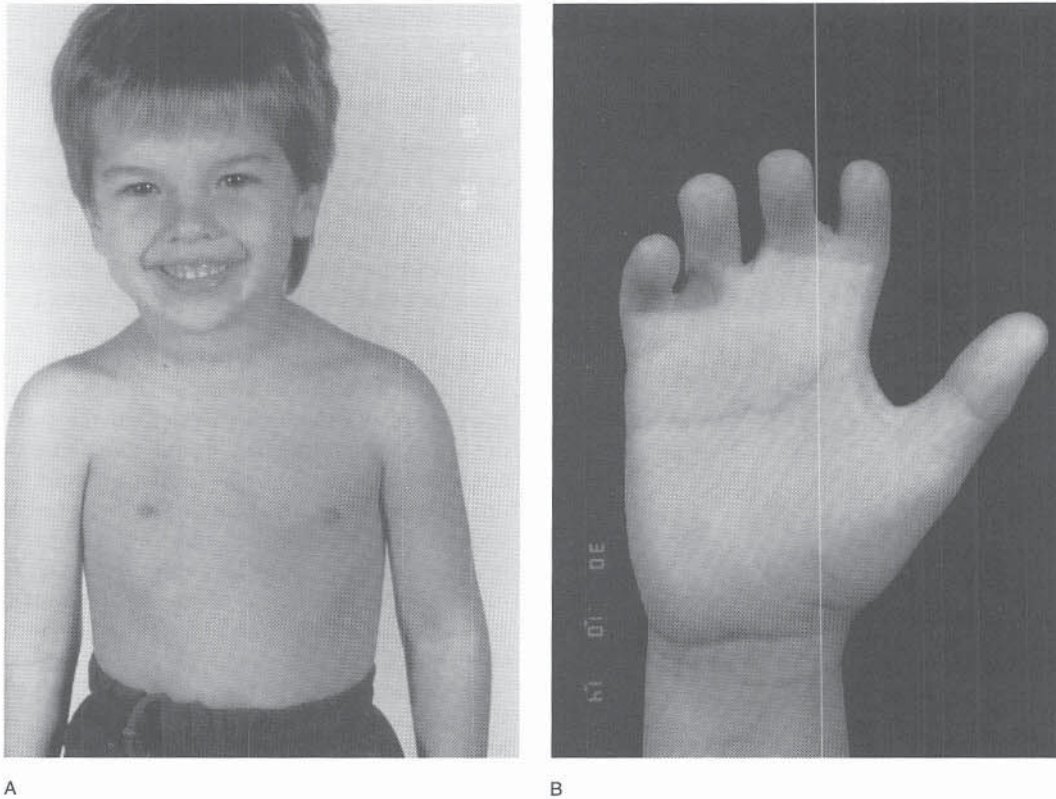


FIGURE 32-46 A and B, Child with short-fingered type of symbrachydactyly and Poland's anomaly.

hand is microsurgical free toe transfers.<sup>175,298</sup> Most patients with adactylous hands have proximal structures (muscles and tendons for motor function, and nerves for sensation) that permit successful transplantation of toes to the hand. This can improve function significantly; however, the toes will continue to look like toes despite their new position.

**Amnion Disruption Sequence.** Transverse deficiencies may also be caused by the *early amnion disruption sequence*.<sup>147</sup> Disruption of upper limb growth is due to the breakdown

of the amnion and to traumatic lesions of the limbs secondary to constriction by strands of amnion (abnormal amnion bands) (Fig. 32-51).<sup>95,142</sup> The digits of the limbs are most often affected, with “fenestrated syndactyly” (Fig. 32-52) the hallmark of limb involvement (Fig. 32-53). Deep bands can cause a number of problems, including distal edema, injury to nerves, impaired sensation, impeded limb development, amputation of digits or proximal limbs, and bony overgrowth. Late complications associated with band ampu-

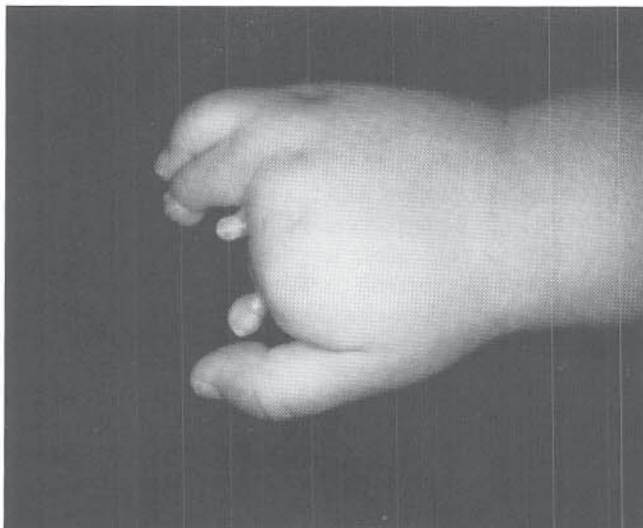


FIGURE 32-47 The split hand form of symbrachydactyly.

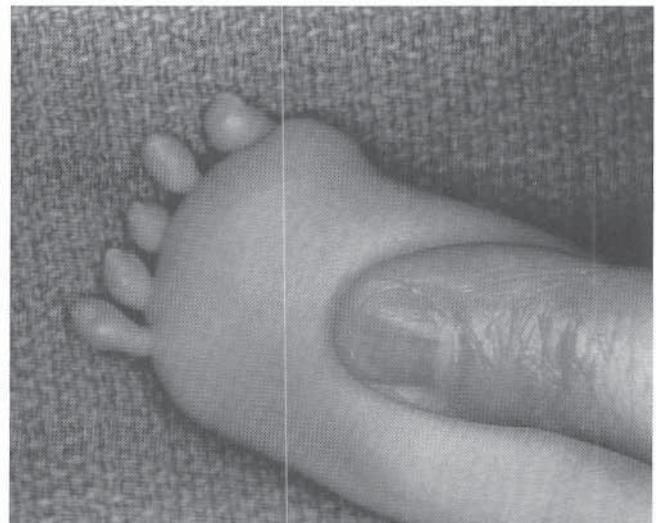

FIGURE 32-48 Residual nubbins in symbrachydactyly, which most surgeons prefer to leave alone.



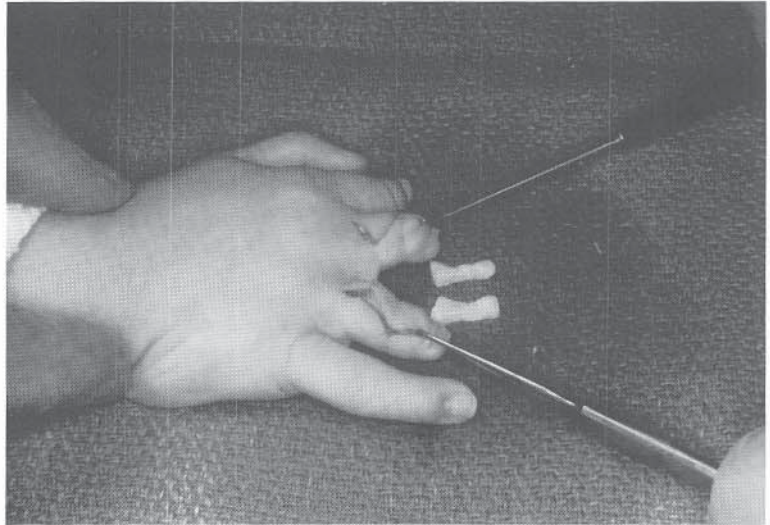


FIGURE 32-49 Augmentation of finger length by the transplantation of nonvascularized phalanges from the patient's toes.

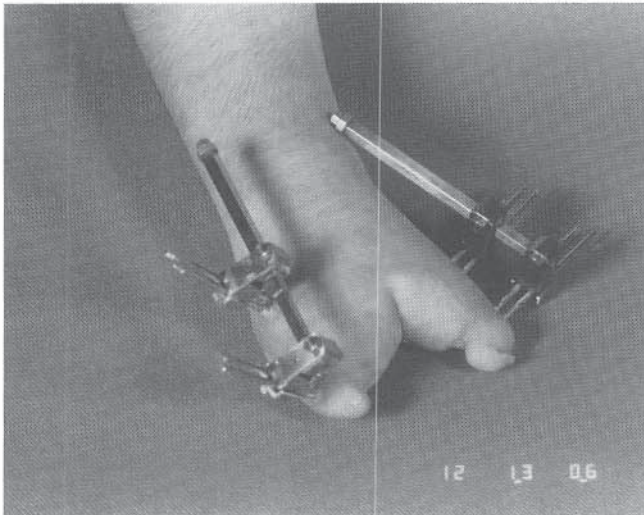


FIGURE 32-50 Lengthening of the hand using external fixators.

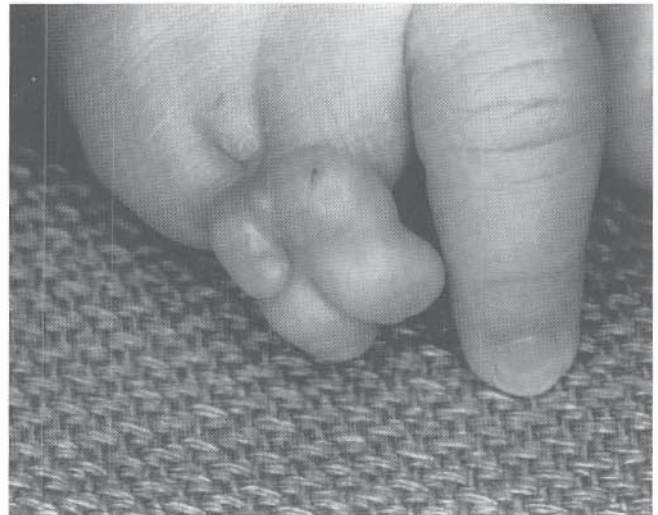

FIGURE 32-52 Fenestrated syndactyly, a hallmark of constriction band formation.

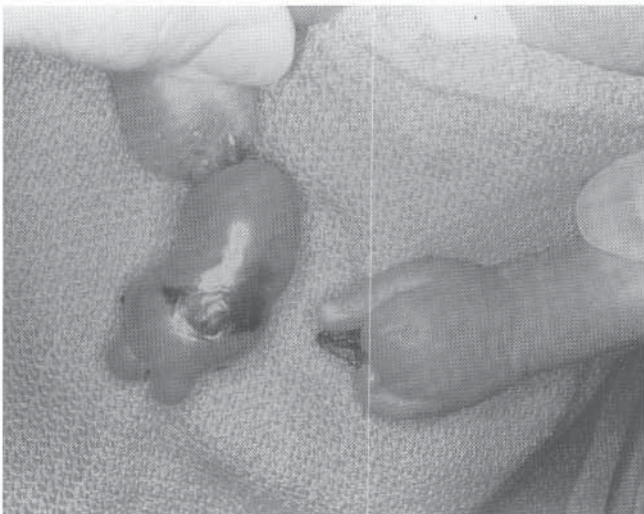


FIGURE 32-51 Near auto-amputation due to constriction bands.

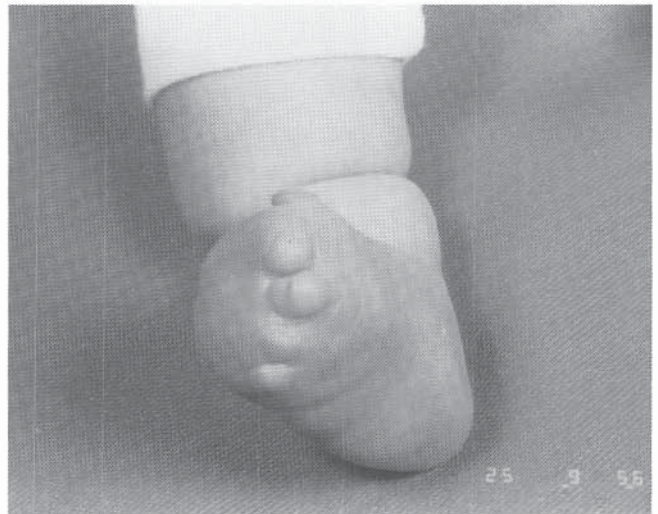


FIGURE 32-53 Severe foot deformity as a result of a constriction band.

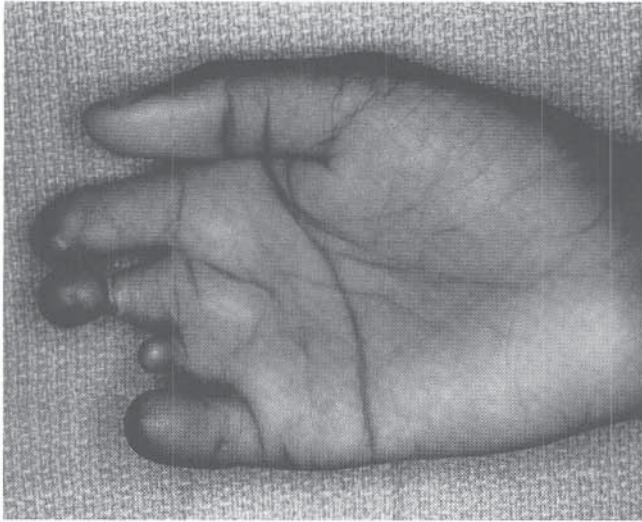
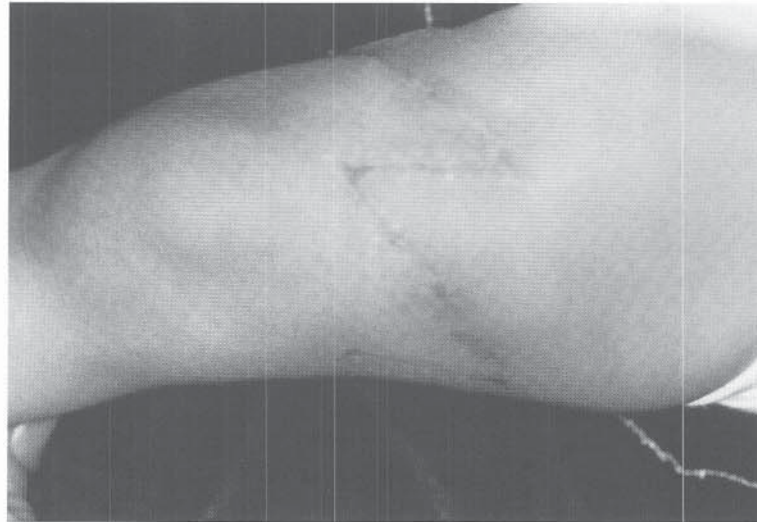


FIGURE 32-54 Late complications of band amputation.

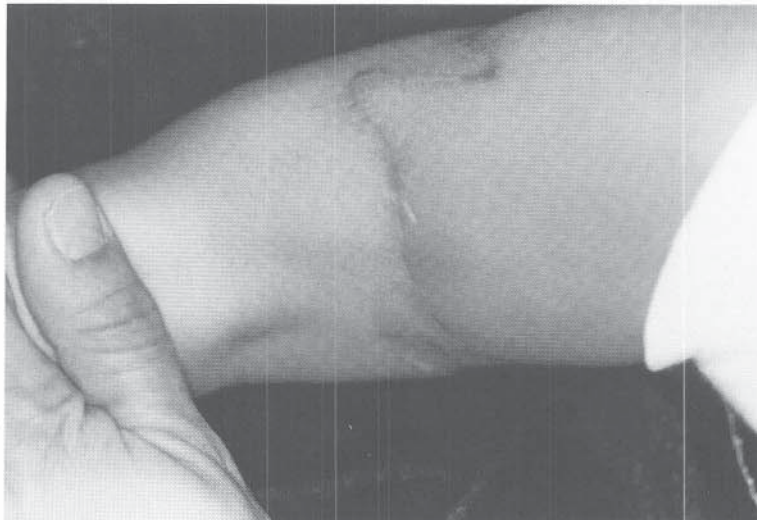
tations include diaphyseal overgrowth, unstable soft tissue at the proximal end of the residual limb or digit, formation of inclusion cysts at the tip of the limb, and increased susceptibility to infection distal to the band (Fig. 32-54).

**Treatment of Constriction Bands.** For limb deficiencies secondary to amnion disruption, early surgery to release the constriction bands is indicated only if there is the emergency of impending tissue death.<sup>67</sup> For most patients, elective release and Z-plasty of the bands can be performed when the child is older than 6 months and better able to tolerate surgery and anesthesia. The surgeon can circumferentially recontour the constricting defect in one operation by carefully preserving any vessels that are present and releasing impeding fascia (Fig. 32-55).

Digital reconstruction may be performed by syndactyly separation and grafting, augmentation of digits with local skeletal rearrangements, free toe transfer, or digital lengthening.<sup>67</sup> Reconstruction of band syndactyly may be restricted by the presence of epithelialized tracts within the fenestrations, a complex deformity of the bone with fused, entangled



A



B

FIGURE 32-55 A and B, Good cosmetic results after Z-plasty reconstruction of constriction bands.

digits, or poor tissue quality in the hand. Short digits can be made to appear slightly longer by releasing the transverse intermetacarpal ligament and deepening the interdigital web. During these procedures, the surgeon should be careful to preserve the normal expanse of palmar skin and its sensation.

Free toe transfer (if normal donor toes are available) is indicated in selected cases of band amputation of the digits, especially if the thumb is involved. Because all structures proximal to the constricting band are normal, it is possible to reestablish motor and sensory function as well as length with toe transplantation. The digits can also be made longer by distraction lengthening; however, results are poor if there is an inadequate digital tip.<sup>67</sup>

## RADIAL DEFICIENCIES

**Etiology.** Radial deficiency, a relatively common upper limb abnormality, is associated with numerous known genetic and chromosomal conditions as well as with coexisting skeletal, visceral, cardiac, hematologic, renal, and metabolic disorders. This indicates that the regulation of radial development is influenced by a variety of factors. The syndromes of thrombocytopenia-absent radius (TAR), VATER, Holt-Oram, and Fanconi present with radial dysplasia.<sup>283</sup> Thus, this anomaly must trigger a search for other significant, potentially life-threatening conditions. Segmentation anomalies of the spine may be associated with tethered cord or other spinal dysraphism.<sup>38</sup>

Treatment decisions for radial deficiencies must take into account the prognosis of any coexisting conditions the patient may have. In many patients, these associated disorders (e.g., cardiac abnormalities) are successfully treated early on, leaving the deformity caused by the radial anomaly the major concern of the patient and parents.

**Classification.** The classification of radial deficiency is based on the amount of residual radius present (Fig. 32–56). In type I there is a short distal radius. Type II, which is uncommon, consists of a small radius with proximal and distal growth plates. In type III there is a small proximal radius. Type IV, which is the most common form of radial deficiency, is complete absence of the radius.

**Treatment.** The more severe and common radial deficiencies are first treated by stretching and splinting the hand of the affected limb. The next step often is centralization of the carpus on the ulna, with tendon balancing or “radialization” of the ulna under the carpus. Tendons and muscles across the ulnocarpal articulation are released and transferred so that their forces are rebalanced, and capsulorrhaphy is also performed. Postoperatively, prolonged splinting is necessary. The purpose of centralization procedures is to stiffen the ulnocarpal junction and enhance the reach and stability of the musculotendinous units that cross the patient’s wrist. However, it is very difficult to maintain functional motion at this new “joint” and still provide sufficient stability and tendon balance that the limb does not become deformed during the child’s growth.

A crucial factor when deciding whether or not to centralize the carpus is the range of motion of the patient’s elbow. If the elbow joint is stiff in extension, any surgery that further restricts a patient’s ability to reach the face with

the hand should not be performed. When a radiocarpal arthrodesis is performed, compensatory motion takes place with rotation of the radioulnar joint. Because patients with radial deficiencies do not have a radioulnar joint, they are not able to rotate their forearm, and compensatory motion is restricted. Their limb strength (and deforming force) is derived from flexion and radial deviation. With current treatment options, it is not possible to reestablish “normal” alignment and still maintain functional motion in these patients. Realignment results in loss of motion, while preservation of motion results in persistence of deformity.<sup>67</sup>

Distraction lengthening of soft tissue may be applicable for radial deficiencies. Lengthening may precede any centralization procedures and would not preclude the performance of other surgical interventions. Factors that may limit the use of lengthening in a particular patient include limb size, the proximity of neurovascular structures, the risk of infection, and scarring.

A new surgical technique for treating radial clubhand is to restore support on the radial side of the carpus through the use of free metatarsophalangeal joint transfer.<sup>299,300</sup> This procedure is promising but technically demanding.

Late complications associated with radial deficiency include an inherent reduction in the growth capacity of the ulna, an increased risk of injury to the physis of the distal ulna (with resulting growth disruption), and the substantial risk of recurrent deformity. Patients frequently experience tendon adhesion and subluxation, resulting in decreased dexterity. The risk of recurrence of the deformity is inversely related to the stiffness of the wrist: the stiffer the wrist, the less likely it is that the deformity will recur. To increase wrist stiffness, the surgeon may need to perform an ulnocarpal arthrodesis as a final salvage procedure.<sup>67</sup>

Thumb hypoplasia and marked stiffness and deformity of all of the fingers are often associated with radial deficiency. Thumb deformity ranges from mild hypoplasia to complete absence of the digit. Treatment of the thumb depends on the condition of the forearm and the adjoining fingers and on the patient’s overall prognosis. If the thumb has a stable carpometacarpal joint, the surgeon can augment the deficient segments by rearranging adjacent tissue, transferring tendons, and reconstructing ligaments. If the thumb has an inadequate basal joint or if the patient has a “floating” or absent thumb, pollicization is the recommended treatment.<sup>67</sup> An index finger that is not used will not function in a pollicized position. Currently, no prosthesis exists that can function as an adequate substitute for a thumb.

## ULNAR DEFICIENCIES

**Etiology.** Congenital ulnar deficiencies primarily involve the postaxial or ulnar border of the upper limb. The precise role of genetics or environmental factors in the development of these deformities remains unclear. A recessive inheritance, or X-linked recessive trait, has been reported.<sup>283</sup> A deficient gene at 6q21 may be responsible for some ulnar anomalies.<sup>106,229</sup> Congenital syndromes associated with ulnar deficiency include Cornelia de Lange syndrome, Schinzel’s syndrome, Weyer’s ulnar ray oligodactyly syndrome, ulnar mammary syndrome, femoral-fibular-ulnar deficiency syndrome, and ulnar fibula dysplasia.<sup>98,283</sup> Associated cardiovascular abnormalities have also been noted,<sup>57,133</sup> but they are

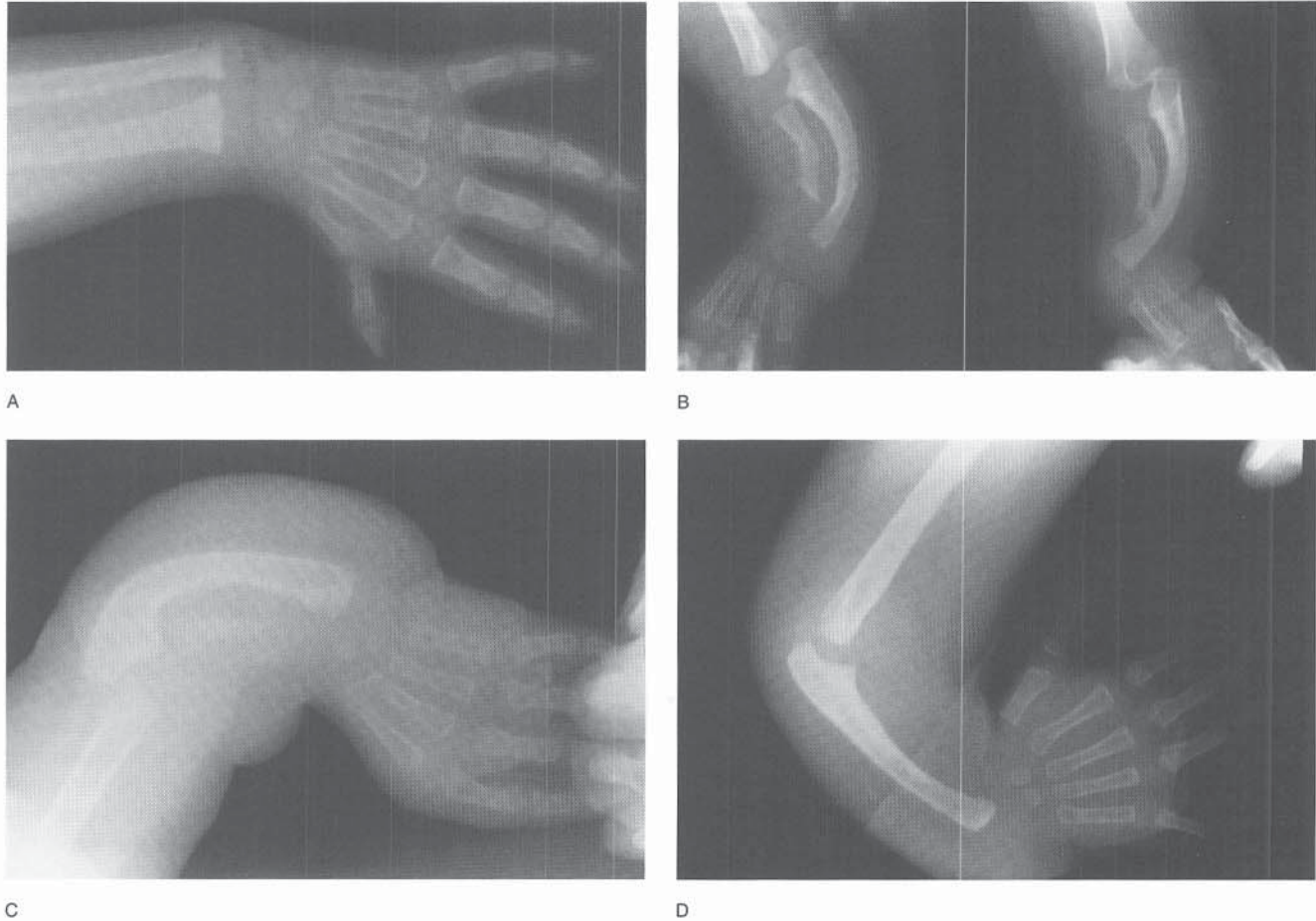


FIGURE 32-56 Classification of radial deficiency. A, Type I deficiency, in which there is a short, residual distal radius. B, Type II deficiency, in which there is a small radius with proximal and distal growth plates. C, Type III deficiency, in which there is a small proximal radius. D, Type IV deficiency, in which there is complete absence of the radius.

not as frequent as with radial dysplasia. Ulnar deficiencies have been produced in pregnant rats with the administration of busulfan teratologic agents<sup>211</sup> and acetazolamide.<sup>209</sup> Disturbance of the C8 sclerotomes may result in ulnar anomalies.<sup>193</sup> The cause of isolated ulnar hemimelia is not known, with cases apparently sporadic and not genetically induced.

**Classification.** All of the classification systems for ulnar deficiency take into account ulnar and elbow involvement,\* with some also addressing hand abnormalities.<sup>46,167,211</sup> The most commonly used classification is the Bayne system (Fig. 32-57), in which ulnar hypoplasia is classified as type I, partial ulnar aplasia is type II, total ulnar aplasia is type III, and radiohumeral synostosis is type IV. However, this classification system does not address hand or shoulder involvement, nor does it help predict evolution of the deformity or the outcome of surgical reconstruction.<sup>22</sup>

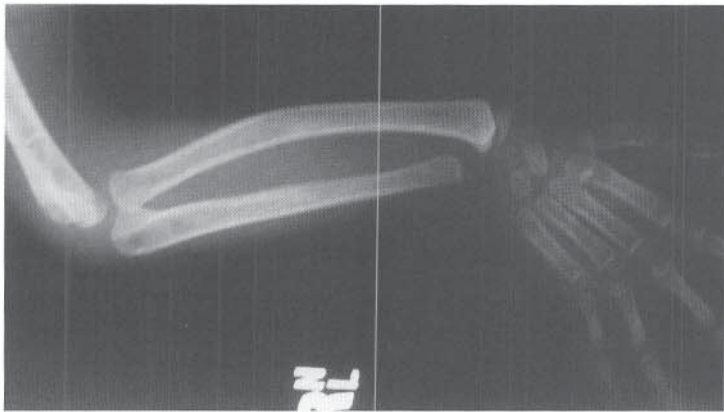**Clinical Presentation.** Longitudinal formation of the ulna is either impaired or completely absent (Fig. 32-58). Patients may have congenital absence of the ulna, longitudinal arrest of ulnar development, paraxial ulnar hemimelia, postaxial deficiency, ulnar dysmelia, ulnar clubhand, or ulnar ray

deficiency. With ulnar hemimelia, the radius bows toward the ulnar aspect of the forearm with the apex of the bow directed radially, creating an apparent ulnar deviation of the hand. Lack of bony development creates a rigid fibrocartilaginous anlage that tethers to the radius and the ulnar carpus.<sup>22</sup> This anlage has been implicated as the underlying cause of significant ulnar deviation of the hand.<sup>233</sup>

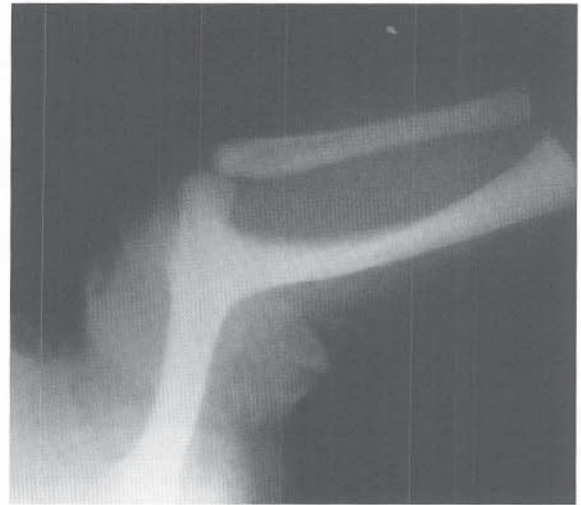
If the ulnar deficiency is severe, the patient may have a short proximal ulna, with a dislocated radial head and an unstable elbow. Elbow synostosis may affect humeral, radiohumeral, or ulnohumeral elbow segments. The extent of involvement at the level of the elbow correlates directly with the amount of functional deficit. Proximal limb involvement may produce functional shoulder deficiency.<sup>22</sup> Deformity of the forearm, elbow, and shoulder is aesthetically unappealing and associated with some weakness and loss of dexterity; however, if prehension is possible, good function is often noted in these patients. The anatomic condition of the deformed limb may mislead the clinician into underestimating its functional capabilities.<sup>264</sup>

Some of the anomalies that may be seen include ectrodactyly, carpal hypoplasia, ulnar deviation of the hand, shortening of the forearm with radial bowing, dysplasia of the elbow, and hypoplasia of the entire limb.<sup>72,138,232,233</sup> Support and sta-

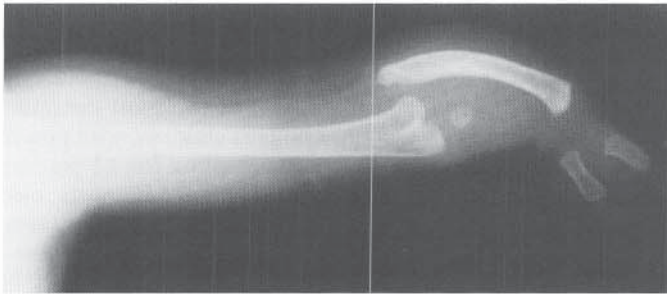
\*See references 46, 59, 167, 199, 210, 211, 233, 279.



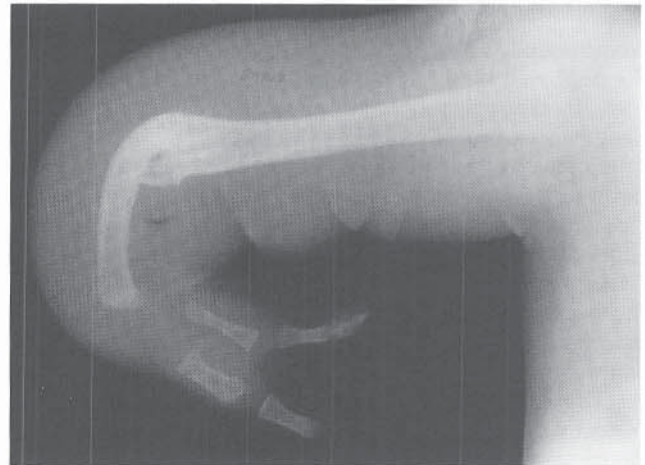
A



B



C



D

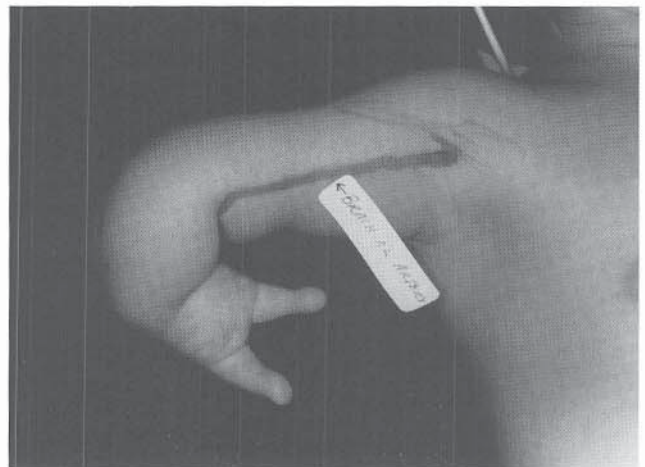


FIGURE 32-57 Classification of ulnar deficiency. **A**, Type I ulnar dysplasia, with a short ulna and ulnar deviation of the hand. **B**, Type II ulnar dysplasia, with a short ulna and a radiohumeral synostosis. **C**, Type III ulnar dysplasia, with complete absence of the ulna. A tethering ulnar anlage may be present. **D**, Type IV ulnar dysplasia, with a radiohumeral synostosis.

bility to the carpus in the hand are provided by the radius, whose slope at the distal end tends to flatten to maintain support as the ulnar deformity increases. The entire hand may be involved, and there may be abnormal or absent digits, malrotation of the hand, or symphalangism and syndactyly with abnormality of the thumb and first web.<sup>46</sup> Hand

deformities may interfere with prehension, dexterity, and hand strength.

**Treatment.** The primary goal of treatment is to improve functional use of the affected limb. Early casting and splinting (applied at birth and continued until surgery) have been

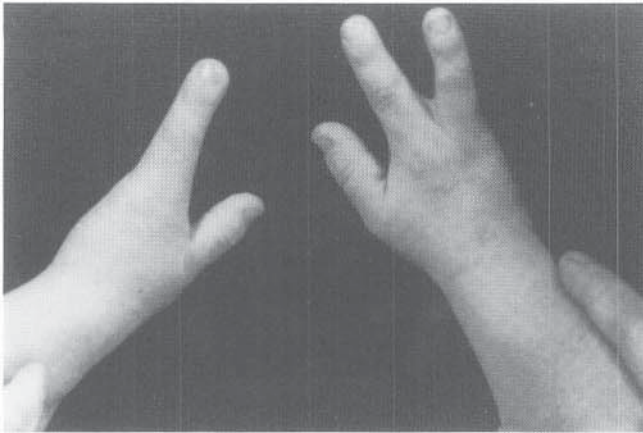


FIGURE 32-58 Bilateral ulnar hemimelia with absence of ulnar digits. (From Bennett JB, Riordan DC: Ulnar hemimelia. In Herring JA, Birch JG (eds): *The Child with a Limb Deficiency*. Rosemont, IL, American Academy of Orthopaedic Surgeons, 1998.)

recommended but not found effective.<sup>22</sup> Hand function can be improved by surgical release of syndactyly, web deepening, metacarpal rotational osteotomy, pollicization, and lengthening procedures.<sup>232,279</sup>

Corrective or rotational osteotomies performed at the level of the forearm or the humerus can effectively position the hand in space for function. However, because of dislocation, elbow arthroplasties have not been found effective in restoring elbow function or correcting radial bowing. Radial head excision may cause further instability of the elbow. Pterygium correction also has not been found beneficial in improving function or appearance.<sup>22</sup>

The establishment of a surgically created single-bone forearm may be helpful in improving stability in unstable forearms<sup>148,220</sup> and elbows.<sup>148,176,232,266,301</sup> However, nonunion and other postoperative complications can be significant, and the results of the procedure may not be as predictable as indicated in the literature.<sup>22</sup>

Early resection of the fibrocartilaginous anlage at the distal ulna to prevent ulnar deviation of the hand is controversial, with some authors maintaining that the anlage does not create a deviation force.<sup>186,233,309</sup> Resection may be indicated if deviation of the ulna is greater than 30 degrees<sup>186</sup>

or if forearm or elbow surgery is being performed at the same time.<sup>22</sup>

Distraction lengthening of the forearm (using the Ilizarov soft tissue and callus-distraction procedures) is being used in cases of unilateral ulnar deficiency.<sup>262</sup> Although cosmetic improvement has been noted, long-term follow-up is required to determine whether functional improvement is achieved.

Researchers are also studying the benefits of using free vascularized epiphyseal transfers from the proximal fibula to correct ulnar deficiencies, but this treatment method is still in the experimental stage, and longitudinal growth results are not yet known.<sup>22</sup>

## Acquired Limb Absences

### PRIMARY CAUSES AND TREATMENT PRINCIPLES OF ACQUIRED AMPUTATIONS

**Trauma.** Injuries to children are a major public health problem in North America, insofar as more than 70 percent of catastrophic injuries resulting in significant morbidity or death are preventable.<sup>168</sup> Trauma is the most common cause of acquired limb amputations in children, with power lawn mowers the main culprit, accounting for 42 percent of all amputations in children less than 10 years old. The resulting injury is usually extremely severe and very contaminated, making reimplantation impossible. Amputation of a portion of the foot is most commonly seen.<sup>18,63,172</sup> In most cases the child is riding on the power mower with a parent or grandparent and falls off. These amputations can be prevented with commonsense measures, and public education is important. Another very common cause of traumatic amputation in children is farm machinery accidents.<sup>43,169,171,234,275</sup>

Other causes of traumatic amputation include motor vehicle accidents,<sup>60,170,219</sup> gunshot wounds,<sup>274</sup> explosions,<sup>150</sup> and railroad injuries (Fig. 32-59).<sup>255,285,287</sup> Gunshot wounds most commonly involve the fingers and toes. Explosive injuries from fireworks usually cause amputation of the fingers or hands, although higher-level amputations can occur, depending on the power of the explosion. Land mine explosions in countries previously ravaged by war are a major

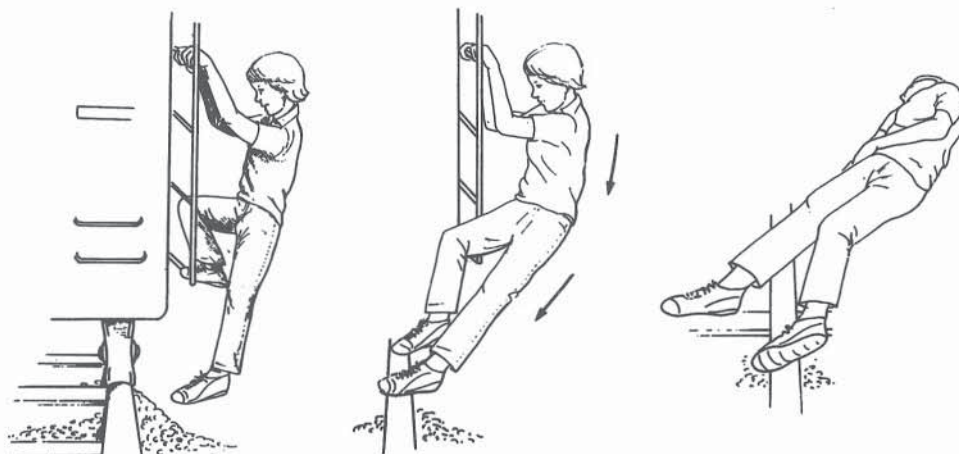


FIGURE 32-59 The mechanism of amputation when a child tries to "hop a freight train." The momentum of the train pulls the legs under the train, often resulting in bilateral amputation. (From Thompson GH, Balourdas GM, Marcus RE: *Railyard amputations in children*. *J Pediatr Orthop* 1983;3[4]: 443-48.)

cause of limb loss in children worldwide.<sup>47,273</sup> Males suffer traumatic amputations approximately twice as often as females.<sup>168</sup>

When children require amputation of a severely injured limb, the surgeon needs to take into account the future growth potential of the child (i.e., the physis), the problem of subsequent overgrowth of the residual limb, the superior healing properties of children (versus adults), and the particular psychosocial issues that affect the rehabilitation of children and adolescents.<sup>62</sup>

In the field, the amputated segment should be wrapped in a sponge slightly moistened with sterile saline, placed in a sterile container (such as a plastic Zip-lock bag) in ice (not dry ice), and transported as soon as possible with the patient to the hospital.<sup>36</sup> These measures will improve the chances of successful reimplantation. The longer the warm ischemic time (the period from injury to initial cooling of the amputated part), the poorer the prognosis for reimplantation.<sup>36</sup> A warm ischemic time of more than 4 hours for a limb and 10 hours for a digit increases the failure rate of reimplantation. In addition, traumatic amputations that are sharp and clean are more successfully reimplanted than those that have crushed or stretched sections. The residual limb is covered with bulky sterile dressings, as are other injured areas. A pressure dressing is used if there is significant bleeding. Clamping or tying vessels or using a tourniquet should be avoided in the field.

In the hospital emergency department, other surgical specialists (plastic, hand, vascular) should be consulted to deal with particular surgical situations. For medical and legal reasons, photographs should be taken to document the extent of the injury.

All open wounds should be properly debrided and irrigated to minimize the chances of early wound infection. Traumatic amputations should be debrided under tourniquet control. After debridement, the tourniquet is removed and the wound is thoroughly irrigated with sterile normal saline solution or Ringer's lactate solution. Early, aggressive wound excision (a term some believe should replace "debridement")<sup>105</sup> and flap coverage within 72 hours of injury results in a significantly lower infection rate compared with delayed reconstruction.<sup>97</sup>

Because of the dynamic healing capabilities of children, it often is possible to try more aggressive limb-salvage procedures than would be attempted in an adult patient. The Mangled Extremity Severity Score (MESS) system is considered the most valid method of scoring and the simplest to apply when trying to predict the success of limb salvage versus amputation (Table 32-10).<sup>58,136</sup> Trials have shown that a MESS score of less than 7 at the time of initial evaluation is highly predictive of successful salvage, whereas a MESS score of 7 or higher indicates the need for amputation.<sup>121,136</sup>

The first priority of the orthopaedist when treating these injuries is to preserve as much limb length as possible, consistent with the appropriate treatment for the particular injury. The epiphyses and growth plate should be maintained whenever possible so that the limb can grow normally, preventing subsequent limb length discrepancies. For example, 80 percent of femoral growth comes from the distal epiphysis of the femur. Premature loss of that vital growth center will result in a very short femur. To assist in preserving limb length, skin grafts may be used successfully without compro-

TABLE 32-10 The Mangled Extremity Severity Score (MESS) System

Factor	Score
Skeletal/soft tissue injury	
• Low energy (stab, fracture, civilian gunshot wound)	1
• Medium energy (open or multiple fracture)	2
• High energy (shotgun or military gunshot wound, crush)	3
• Very high energy (above plus gross contamination)	4
Limb ischemia*	
• Pulse reduced or absent but perfusion normal	1
• Pulseless, diminished capillary refill	2
• Patient is cool, paralyzed, insensate, numb	3
Shock	
• Systolic blood pressure always > 90 mm Hg	0
• Systolic blood pressure transiently < 90 mm Hg	1
• Systolic blood pressure persistently < 90 mm Hg	2
Age (yr)	
• <30	0
• 30-50	1
• >50	2

\*Double the value if the duration of ischemia is more than 6 hours. Adapted from Johansen K, Daines M, Howey T, et al: Objective criteria accurately predict amputation following lower extremity trauma. *J Trauma* 1990;30:568.

mising wound healing or causing subsequent problems with prosthetic management.<sup>7</sup>

It is also very important to retain a cartilaginous surface (epiphysis and articular surface) at the distal end of the residual limb to help prevent overgrowth (Fig. 32-60). Traditionally, bony overgrowth has been managed by surgical resection revision.<sup>1,79,143,164,165,237</sup> Although resection revision is technically simple and can be done quickly, the procedure sacrifices the length of the residual limb, and overgrowth frequently recurs within several years.

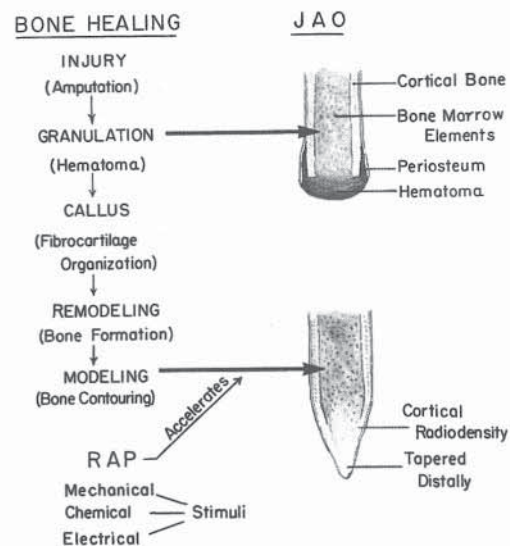


FIGURE 32-60 The mechanism of overgrowth of amputation stumps. (From Davids JR: Terminal bony overgrowth of the residual limb: current management strategies. In Herring JA, Birch JG (eds): *The Child with a Limb Deficiency*. Rosemont, IL, American Academy of Orthopaedic Surgeons, 1998.)

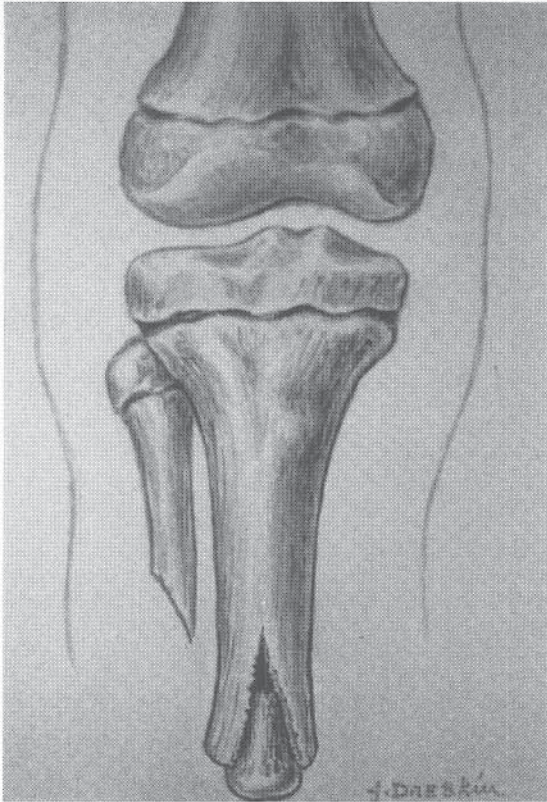


FIGURE 32-61 Use of a bone plug with a cartilage cap to prevent overgrowth of amputation stumps. (From Davids JR, Meyer LC, Blackhurst DW: Operative treatment of bone overgrowth in children who have an acquired or congenital amputation. *J Bone Joint Surg* 1995;77-A:1490.)

To prevent periosteal overgrowth from occurring, disarticulation is preferred whenever possible in the growing child.<sup>5-7,9</sup> If bony transection is required, prophylactic “biologic capping” (placing a cartilage surface from the amputated segment over the bony stump) (Fig. 32-61) may be helpful, particularly in children younger than 12 years of age.<sup>54</sup>

Based on results from the Ertl procedure, which improves end bearing by increasing the area of the distal bony surface via a broad distal synostosis,<sup>201,303</sup> the use of distal tibiofibular synostosis for transdiaphyseal amputations has been reconsidered by some authors (Fig. 32-62).<sup>54</sup> The tibia is shortened so that it is 1 to 2 cm proximal to the distal end of the fibula, and a longitudinal osteotomy of the tibia is performed, producing two pillars. A greenstick fracture of the fibula is created, and the distal fibula is displaced medially between the tibial pillars. The fibula is stabilized to the tibia, when necessary, with a nonabsorbable suture. This procedure results in a wide synostosis between the fibula and tibia and creates a biologic cap for the tibia. Early promising outcomes have been reported, but further long-term results are needed to determine the efficacy of this approach.<sup>54</sup>

When it is possible to maintain the femoral condyles or the distal tibial articular surfaces, full weightbearing usually is possible, even on hard surfaces. In the child’s ankle, the medial and lateral malleoli usually are not prominent and the surgeon should excise them only in patients who are near skeletal maturity when the amputation occurred.<sup>11,79,125</sup>

Traumatic partial foot amputations are commonly seen when children are injured by power lawn mowers. Most children are injured while playing near the lawn mower or by falling off a riding lawn mower, and being run over by the blades.<sup>18,63,172</sup> These amputations are often transverse in nature and are classified based on their level. They can be either transmetatarsal, tarsometatarsal (Liffranc), or midtarsal (Chopart).

**Malignant Tumors.** Malignant musculoskeletal tumors are the second leading cause of acquired amputations in children and adolescents. Surgically, a decision must be made between limb-salvage procedures and amputation. The success of chemotherapy in controlling local growth, along with improvements in surgical techniques, has made limb-salvage surgery more feasible than in the past.<sup>87</sup> Long-term follow-up comparing survival outcome of patients treated by limb salvage with those treated by amputation showed no disadvantage with limb salvage, as long as wide margins were achieved.<sup>240</sup> The authors also found no difference in the psychosocial outcomes in these two patient treatment groups for distal femoral tumors.

There are a number of specific contraindications to limb salvage. These include the inability to obtain adequate wide excision margins for tumor control, a projected significant limb length inequality, an extremely active patient, and inadequate soft tissue coverage. A displaced pathologic fracture may also be a contraindication, but current adjuvant treatments may make limb salvage an acceptable option. In addition, limb salvage should only be performed if the residual limb will be able to function as well as or better than an amputated limb fitted with a well-made prosthesis.<sup>259</sup> Tumors located in the distal two-thirds of the tibia often are better treated by amputation than by limb salvage.

Although limb-salvage surgery is possible and preferable to amputation when patient survival is not compromised (particularly for upper limbs versus lower limbs), the procedure is involved and subsequent complications often occur. When deciding between limb salvage and amputation, it is critical not to forget that the primary goal of surgical treatment is patient survival.

**Purpura Fulminans.** Purpura fulminans, a devastating thromboembolic condition usually caused by meningococcal septicemia, results in high rates of limb gangrene and amputation (Fig. 32-63).<sup>124</sup> Septicemia from other bacteria (e.g., *Hemophilus influenzae*), Kawasaki’s disease, toxic shock syndrome, or frostbite may also cause gangrene of the extremities. Intravascular coagulation due to protein S or C deficiency may result in tissue loss.<sup>222</sup> One or all of the upper and lower limbs may be affected.

These patients frequently have a distinct level of demarcation of gangrene at the middle of the limb. Vascularized, viable tissue may extend well distal to the proximal edge of the gangrenous skin and subcutaneous tissue eschar. Often a dense, black eschar suggests a high level of gangrene. Because there often is viable muscle and bone beneath the eschar, the surgeon should amputate the limb at the level of deep gangrene, not at the edge of the eschar.

This operative approach frequently enables the surgeon to save the patient’s knee joint and sometimes the elbow joint. The wound may then be covered with skin grafts, which usually function quite well, even in weightbearing



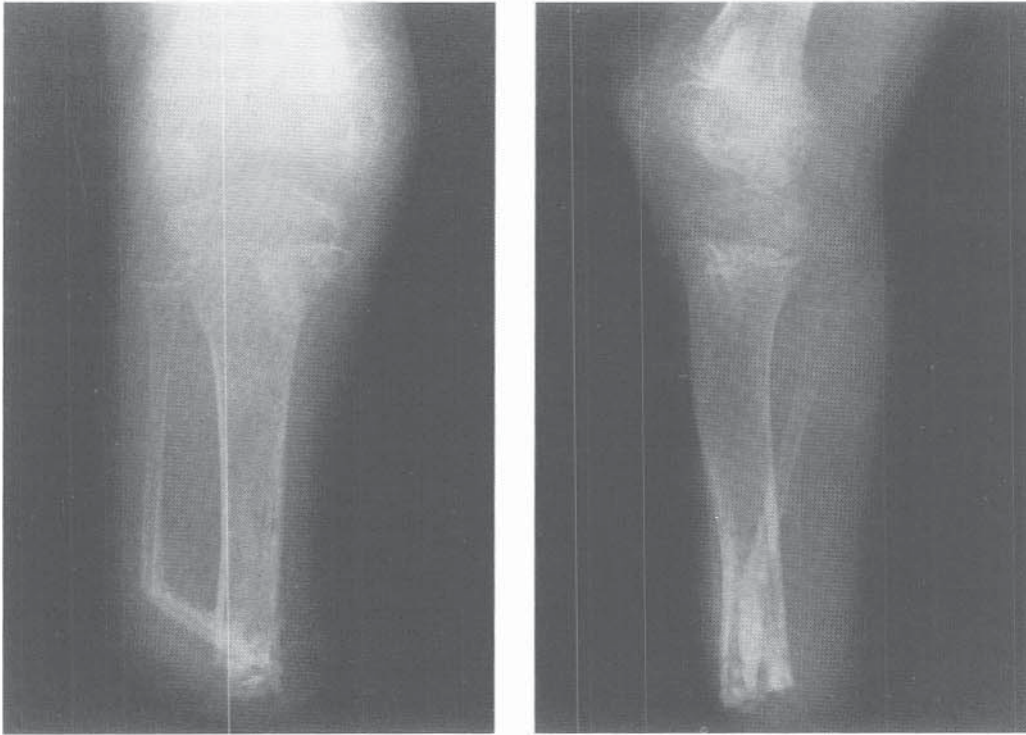


FIGURE 32-62 The Ertl procedure to create a distal synostosis between the fibula and tibia. (From Davids JR: Terminal bony overgrowth of the residual limb: current management strategies. In Herring JA, Birch JG (eds): *The Child with a Limb Deficiency*. Rosemont, IL, American Academy of Orthopaedic Surgeons, 1998.)

areas. Skin grafts and local, regional, and free flaps are used in an appropriate fashion for reconstruction. Skin grafts are used to cover all well-vascularized areas. Extremely well-vascularized tissue is used to cover any exposed bone or joints; local random or pedicled axial subcutaneous or fasciocutaneous flaps are not recommended.<sup>3</sup> Free tissue transfer can be highly beneficial. Microvascular free flaps provide good wound control and have been successfully used to preserve limb length and joints.<sup>3</sup>

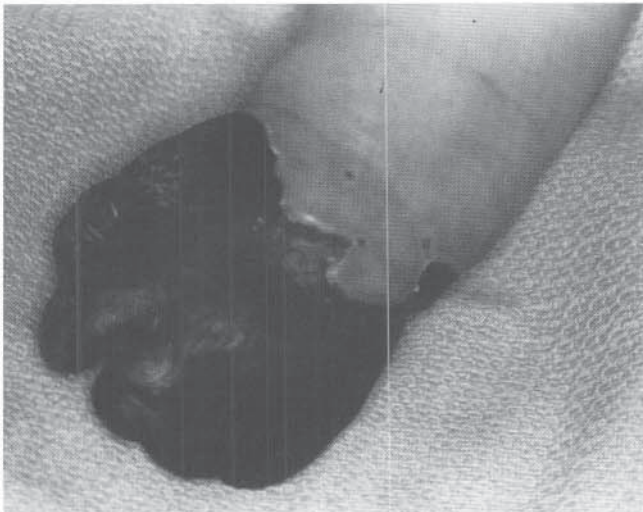


FIGURE 32-63 Necrosis of the feet due to purpura fulminans from meningococemia.

## SURGICAL AMPUTATIONS

**Upper Limb Amputation.** With all upper limb amputations, the surgeon should try to maintain the maximum amount of bone length possible. When small residual carpals and metacarpals are present and successfully lengthened, the patient is provided the ability to pinch, a dexterity skill that would otherwise be lost. Periosteal overgrowth is very common after transhumeral amputations and frequently requires multiple surgical revisions to treat. Split-thickness skin grafts are usually adequate for initial coverage since weightbearing normally is not required of the upper limb.

**Above-Knee Amputation.** There are some aspects of above-knee amputations that are unique to children. The surgeon should retain as long a femoral segment as possible, keeping in mind that there needs to be sufficient soft tissue coverage at the distal end of the limb. Even extremely short femora should be maintained, as it may be possible to lengthen them in the future.

During the stance phase of gait, the patient's abductor muscles support the rest of the body, and the source of support for the abductors is the femur and its contact with the prosthesis. The longer the femur, the greater its surface contact with the prosthesis. This provides a stable base for abductor function, and the child will have minimal abductor lurch. A child with a short femur and a fatty thigh will ambulate with an abductor limp because the femoral segment is unable to counteract the abduction forces of the abductor muscles.

With transfemoral amputations, the surgeon should shorten the femoral segment just enough that a muscle flap

can be drawn over the distal end. It may be helpful to attach the muscles to the bone. Periosteal bony overgrowth is a common complication after above-knee amputations, particularly in young children, and it may be necessary to perform numerous surgical revisions to correct the problem as the patient matures.

**Knee Disarticulation.** A knee disarticulation (through-knee amputation) creates a very good functional level for child amputees.<sup>180</sup> The distal femoral epiphysis is preserved, bony overgrowth is avoided, a strong femoral lever arm and load-tolerant distal end are maintained, excellent prosthetic suspension and rotational control are provided through the wide femoral condyles and patella (if present), and there is a lower energy cost when walking.<sup>221</sup> Children with bilateral disarticulation usually are able to ambulate with full weightbearing at the knees in a prosthesis or when knee-walking.<sup>50</sup>

During amputation, the surgeon should attach the hamstrings to the stump of the cruciate ligaments to provide the patient with better hip extension power.<sup>226</sup> The femur of the amputated limb will grow at a nearly normal rate and will be approximately the same length as the opposite femur, which creates a small problem in the prosthetic management of these patients. Specifically, when the knee mechanism is attached to the prosthesis below the residual limb, the tibial portion of the prosthesis will be shorter than the opposite tibia. To preclude this from occurring, the orthopaedist can perform a distal femoral epiphysiodesis several years before the child reaches skeletal maturity so that the femur of the residual limb is 5 to 6 cm shorter than the contralateral femur, thereby providing sufficient room for a prosthesis with a knee.

**Below-Knee Amputation.** Whenever below-knee amputations are performed, any viable part of the upper tibia should be preserved if the knee joint is intact and soft tissue coverage is possible. Split-thickness skin grafts can be used initially to cover the proximal tibia, and replaced later with free tissue transfer if necessary.<sup>157,160</sup> The problems of skin breakdown with prosthetic wear have also been reduced with the availability of newer materials and methods for managing shear forces and pressure within the prosthetic socket.

The Ilizarov and other lengthening techniques have been used to successfully treat extremely short below-knee amputation stumps.<sup>318</sup> These procedures can be difficult for both the surgeon and the patient, but the functional gain achieved from a below-knee amputation compared with a knee disarticulation makes the undertaking well worth the effort (Fig. 32–64). Advantages associated with below-knee amputation include control of the knee, proprioception of knee position, decreased energy expenditure during gait, and less complicated prosthetic devices. For a satisfactory prosthetic fitting, the residual limb should be at least 6 cm long below the knee when the patient is skeletally mature.

Children who undergo below-knee amputations may face some unique problems as they mature. Bony overgrowth of the distal tibia and fibula is common and often requires surgical revision to correct.<sup>4</sup> Recurrent overgrowth of the fibula can be treated by creating a surgical synostosis between the distal fibula and tibia. As the patient gets older, the knee may gradually develop a valgus deformity. This usually can be managed by modifying the prosthesis. Patients may also

experience periodic dislocation of the patella, which may be partially associated with the valgus deformity. They can also develop patella alta, which lends to instability of the patella.<sup>205</sup> During physical activity, the prosthesis may become twisted, and the medial edge of the prosthesis may cause the patella to dislocate.

## COMPLICATIONS ASSOCIATED WITH AMPUTATIONS

### Overgrowth After Amputations Through Long Bones.

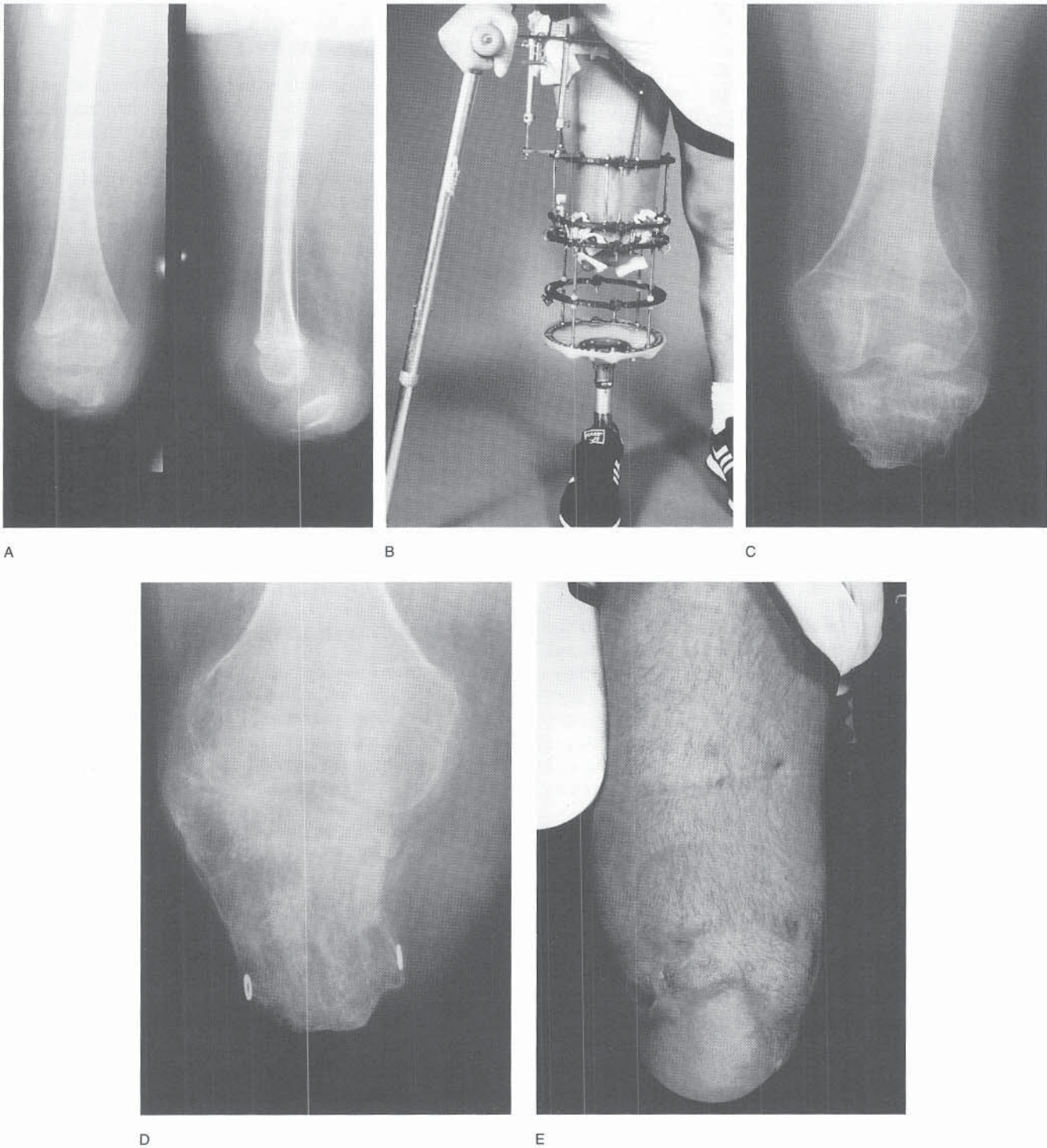
Although amputation through long bone is frequently required, the outcome may be compromised by bony overgrowth of the residual limb,<sup>1</sup> which is primarily a consequence of a local biologic phenomenon occurring at the distal portion of the bone.<sup>5,6</sup> The normal wound contracture mechanism may initiate overgrowth by pulling the periosteum into the medullary canal, placing it in contact with the endosteum.<sup>265</sup> However, if the medullary canal is occluded with muscle or bone, the local sealing mechanism of the canal is impeded and the subsequent development of overgrowth is prevented.<sup>115, 116</sup> Overgrowth occurs only in skeletally immature patients, and the only stage of normal bone healing unique to children is the eventual modeling phase, which is characterized by the resorption and development of mature lamellar bone, which changes the micro- and macroscopic contours of the bone.

Overgrowth of bony spicules tends to occur at the distal part of the bone because of periosteal bone formation (not epiphyseal growth), and surgical revision often is necessary to remove the overgrowth. The most common bones in which this occurs are the humerus, fibula, tibia, and femur, in that order.<sup>5,6,265</sup> Over time, a painful bursa develops, and the bone will eventually grow through the skin.

Different procedures have been tried to prevent overgrowth (e.g., putting silicone sleeves over the end of the bone or capping the transected bone with autologous cartilage-bone graft); however, but these attempts have usually failed.<sup>187,194,278</sup> Repeated surgical revisions, sometimes as often as every 2 to 3 years as the child is growing, are frequently required.

The concept of using a biologic cap to treat overgrowth is based on the fact that overgrowth does not occur following disarticulation (see Fig. 32–61).<sup>23,188,189,191</sup> Wang and Zaleske transferred proximal fibular physis or iliac apophysis to the end of the limb to prevent overgrowth, believing that there would be growth of the transferred tissue.<sup>307,319</sup> When it was later recognized that there was little growth potential of the transfer, Davids and associates used a tricortical iliac crest graft to plug the end of the amputated bone.<sup>55</sup> In a comparison of resection revision, synthetic capping with a high-density polyethylene implant, and biologic capping with an autologous iliac crest bone graft, the authors found that biologic capping was the most efficacious procedure.<sup>55</sup>

A number of authors have recommended a proactive, prophylactic surgical approach for children at risk for overgrowth after an acquired amputation.<sup>21,23,55,189</sup> Biologic capping is performed on the tibia or fibula and humerus during the initial amputation. The ipsilateral fibular head, the dome or head of the talus, or the base of the great toe metatarsal can be used as bone graft donor sites.<sup>54</sup>



**FIGURE 32-64** A boy with a very short residual tibial segment that was lengthened using the Ilizarov device. **A**, Radiograph of the limb with only a proximal tibial epiphysis present. **B**, Patient walking with the lengthening device in place. **C**, Appearance of the limb after the initial lengthening procedure. Because skin coverage was poor, a free flap coverage procedure was performed. **D**, Appearance of the limb after the second lengthening procedure. **E**, Final appearance of the limb. (From Herring JA, Cummings DR: The limb-deficient child. In Morrissy RT, Weinstein SL (eds): *Lovell and Winter's Pediatric Orthopaedics*, 4th ed, vol 2. Philadelphia, Lippincott-Raven, 1996.)

**Complications Following Burns or Purpura Fulminans.** If a patient undergoes amputation because of burns or purpura fulminans, the residual limb often is covered with a split-thickness skin graft (Fig. 32–65). These grafts are often surprisingly resilient for weightbearing in a prosthesis.<sup>7</sup> With some patients, though, a free tissue transfer must be substituted for the split-thickness skin graft. Free tissue transfers provide excellent coverage of amputated limbs; however, they take time to develop protective sensation and may break down if weightbearing is started before they become sensitized. Soft tissue involvement of the legs and arms is often extensive, and multiple soft tissue debridements and skin grafts are usually necessary for patients who survive the initial onset of meningococcal disease. Careful and meticulous care to maximize limb length and joint function will greatly enhance patient outcome.<sup>3</sup> Neuromas are frequent, owing to extensive loss of overlying skin and subcutaneous tissue.

**Immediate Fitting of Prostheses in Young Children.** In young children, immediate fitting of a prosthesis after amputation can be unsafe and may cause wound dehiscence if the child begins full weightbearing prematurely. Because the residual limb rapidly loses size postoperatively, casts tend to fall off. Thus, we elect to use soft elastic bandages to help shape the residual limb after amputation.

**Phantom Pain.** Phantom pain does not occur in children with congenital limb absences and is uncommon in younger children with acquired amputations. Although older children with acquired amputations may experience phantom pain, the phenomenon usually is not incapacitating. If the condition is painful, the patient can be treated with tactile stimulation, physical therapy, or drug therapy (with tricyclic antidepressants such as amitriptyline). The symptoms normally lessen over time. To prevent neuromas from subsequently forming, the surgeon should tension the nerves, cut them sharply, and allow them to retract away from the end of the limb during the amputation. Any persistent neuromas

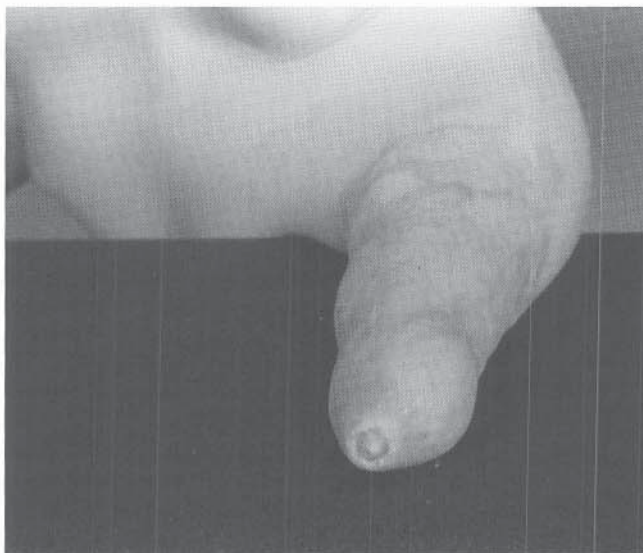


FIGURE 32–65 A limb covered with well-healed split-thickness skin grafts.

may need to be excised and the severed nerve replaced into healthy tissue.

## PSYCHOSOCIAL ASPECTS OF ACQUIRED AMPUTATIONS

Very young children with acquired amputations of one or more limbs because of injury or disease often respond in the same manner as children with congenital limb deficiencies. They will experience minimal or no sense of loss, the adjustment period will be short, and necessary adaptations will be made to meet developmental milestones and participate in activities with their peers. However, older children with acquired amputations will experience a feeling of loss, and they must be allowed to go through a grieving process as part of the natural course of accepting what has occurred. Limb loss can have a significantly adverse affect on the self-esteem of adolescents.<sup>294,295</sup> A deep-seated wish to be as they were before the amputation may interfere with constructive adaptations.<sup>70</sup> Thus, older children often need more encouragement and positive reinforcement to enable them to adjust to the reality of their situation. The goal of treatment, as with all limb-deficient patients, is to eventually maximize the individual's functional independence and minimize the psychological impact of the condition.

## Multilimb Deficiencies

### BILATERAL UPPER LIMB ABSENCES

Children who have partial or complete absence of both upper limbs adapt in predictable ways. They may use prostheses at times, but they usually forgo the use of prosthetics for major functional activities, discovering that most of these activities can be better performed using the natural sensory surfaces still available to them.<sup>42</sup> Oddly, it has been found that even though functional need increases as the level of limb absence increases, these patients are the least likely to tolerate prosthetic devices. In most cases they will use the prostheses as tools to assist them in meeting specific functions, and then remove the devices.

There are three primary reasons why children with bilateral upper limb deficiency do not use prostheses.<sup>126</sup> First, the prostheses encase and impede the natural sensory surfaces of the arms. Second, present devices provide only very simple and limited functions and are inadequate replacements for the functional sophistication of the hand. Third, and most important, because most of the child's motor and sensory pathways are formed postnatally, they develop the most efficient adaptations for that individual's anatomy. Often the sensory and motor functions of the residual limbs are almost as sophisticated as those of normal hands and arms. Current prosthetic devices are not able to improve on these results.

Children with absent hands but mobile wrists will use the wrists together for most prehension. Those with bilateral wrist disarticulations have elbows and often movable carpals that have prehensile function. Patients with bilateral below-elbow absences usually function well by using their elbows for prehension and by using their residual arms for holding

larger objects (Figs. 32–66 and 32–67). Even those with very short forearms have good elbow prehension. The Krukenberg procedure has been recommended for patients with unilateral, long below-elbow absences<sup>280</sup>; however, we have no personal experience with the procedure.

Children with bilateral above-elbow absences will use the arms together in midline if the residual limbs are long enough to hold large objects (Fig. 32–68). Children with absence of the limb at the transhumeral level will also hold objects against the body with the residual limb, whereas if the limb is very short, the object may be held against the cheek (Fig. 32–69).

If a child has one limb with a functional elbow and the other limb is absent at the distal level of the humerus, the limb with the elbow will become the dominant extremity. Elbow prehension will be used for major functional activities (e.g., writing) and for other fine motor activities, while both limbs used together (if possible) will be used to maneuver large objects.

If the humeri are extremely short or if there is complete absence of both upper limbs, children will usually use their feet to perform most manual and physical activities (Fig. 32–70), including brushing their teeth, writing, and using eating utensils. Most children become very adept at using their feet in this manner and are often able to reach just above their heads with their feet. Teenagers are able to drive automobiles with automatic shifts. Although toileting can present difficulties, specific bathroom adaptations usually enable the child to successfully meet these challenges.<sup>81</sup>

For this patient population, prosthetic usage should be viewed as task specific; that is, the devices are worn intermit-

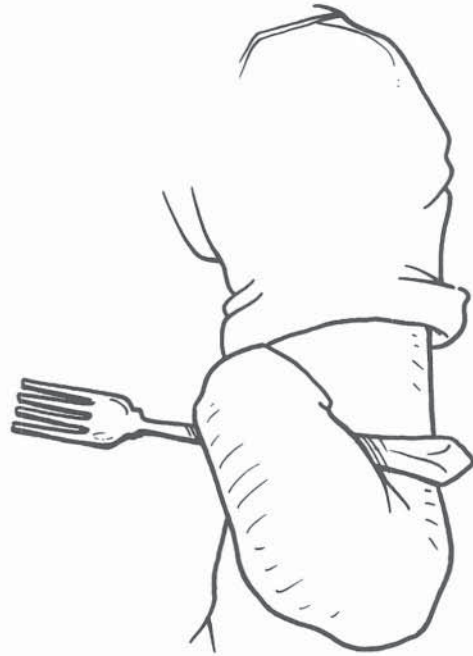


FIGURE 32–67 A child with either unilateral or bilateral below-elbow absences can achieve good prehensile function using the elbow. (From Herring JA: Functional assessment and management of multilimb deficiency. In Herring JA, Birch JG (eds): *The Child with a Limb Deficiency*. Rosemont, IL, American Academy of Orthopaedic Surgeons, 1998.)

tently, when they can better assist the child with a specific function. Prosthetic choices include body-powered and externally powered devices, and hybrid systems that combine body and external power.<sup>42</sup> Hybrid prostheses often provide the best option because they are lightweight and allow the patient some degree of proprioceptive feedback via cable-

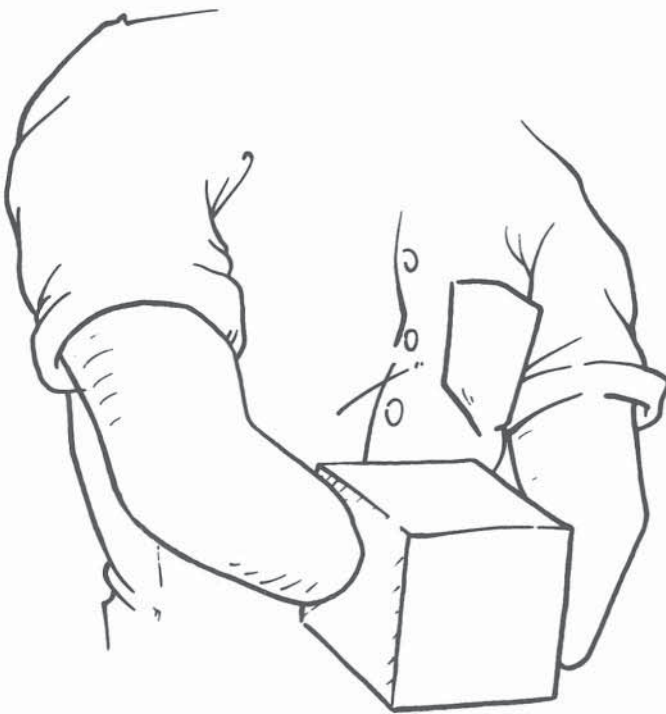


FIGURE 32–66 A child with bilateral below-elbow absences can hold objects very effectively between the two arms. (From Herring JA: Functional assessment and management of multilimb deficiency. In Herring JA, Birch JG (eds): *The Child with a Limb Deficiency*. Rosemont, IL, American Academy of Orthopaedic Surgeons, 1998.)

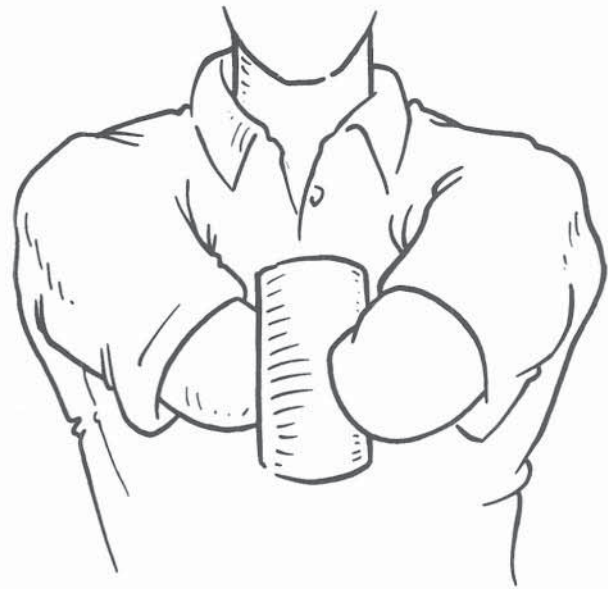


FIGURE 32–68 A child with bilateral above-elbow absences can hold objects with both arms if they are long enough. (From Herring JA: Functional assessment and management of multilimb deficiency. In Herring JA, Birch JG (eds): *The Child with a Limb Deficiency*. Rosemont, IL, American Academy of Orthopaedic Surgeons, 1998.)




FIGURE 32-69 A child with above-elbow absence will use the extremity against the face to write and hold objects. (From Herring JA: Functional assessment and management of multilimb deficiency. In Herring JA, Birch JG (eds): *The Child with a Limb Deficiency*. Rosemont, IL, American Academy of Orthopaedic Surgeons, 1998.)

controlled terminal devices or elbows. Components will vary depending on the patient's age and developmental status.

### BILATERAL LOWER LIMB ABSENCES

Children with bilateral lower limb deficiencies usually try to stand on the ends of the residual limb when they are developmentally ready. If the level of absence is below the knee, prosthetic management is similar to that of patients with unilateral limb deficiencies.<sup>50</sup> However, at the beginning, it may be helpful to have the first pair of prostheses 1 or 2 inches short to assist the child in balancing.

Patients face special problems if the level of the bilateral disarticulation is at the knee. To maintain knee stability after a bilateral knee disarticulation, the patient must be able to achieve a strong knee extension at heel strike. Walking on an upward incline or on uneven ground can prove challenging. Patients who undergo bilateral above-knee amputations

encounter the same compensatory needs and ambulatory difficulties. The ability of the child to ambulate depends on the length of the residual limbs. The shorter the limbs, the greater the energy consumption during gait.<sup>308</sup>

In the prosthetic management of these patients, particular attention is paid to a gradual progression in prosthetic height and complexity. The child is first fitted with short "stubby" prostheses, which include feet or blocks positioned directly beneath the prosthetic sockets. These prostheses provide the child with a very low center of gravity, which helps the child to stand. When the child starts to walk, the stubbies can be gradually lengthened as needed.<sup>112</sup> In addition, the patient is usually fitted with nonarticulated knees first, and as the child matures, one or both knees may be articulated. Children are often able to function better on the playground with locked knees; however, adolescents usually prefer articulated knees. In these cases, some type of locking knee or stance-phase stabilizer may still be required.

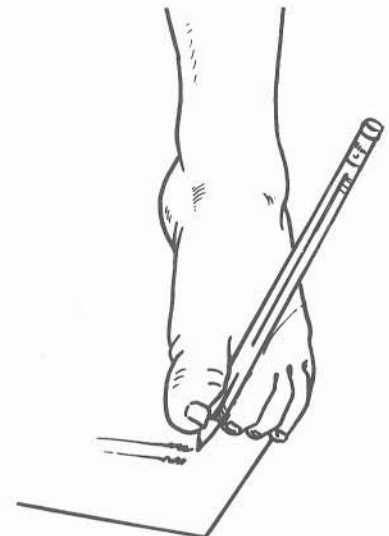
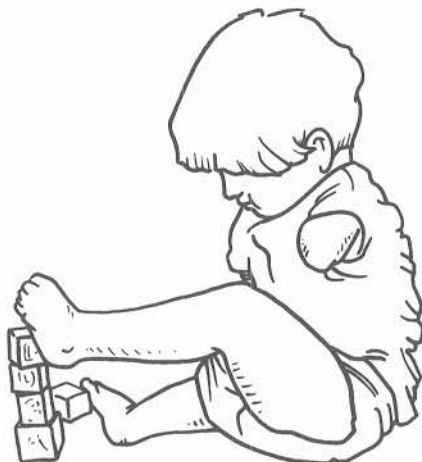

FIGURE 32-70 A child with short or absent upper extremities will use the feet for all manual tasks. (From Herring JA: Functional assessment and management of multilimb deficiency. In Herring JA, Birch JG (eds): *The Child with a Limb Deficiency*. Rosemont, IL, American Academy of Orthopaedic Surgeons, 1998.)

If the limbs are extremely short, walking with full-length legs and articulated knees may be difficult or impossible for the patient. Devices that may enable children to use longer prostheses include manually locking knees, knees with stance-phase braking, polycentric knees, and knee spring-extension assists. Patients with short bilateral above-knee levels may require external support, such as a walker, canes, or crutches, to walk. As bilateral higher-level patients get older, they may opt for wheelchair ambulation, particularly when participating in sports activities, or other means of locomotion.

### **BILATERAL UPPER AND LOWER LIMB ABSENCES (QUADRIMELIC LIMB DEFICIENCY)**

When a child has bilateral upper and lower limb deficiencies (quadrimelia), the problems naturally are increased. The degree of functional capability will depend on the length of the residual limbs. If the level of amputation is below-elbow and below-knee for all limbs, the child should be able to achieve independent ambulation with the use of lower limb prostheses. For young children, a very short prosthesis (“stubby”) is appropriate, whereas for older children, longer prostheses can be used.

If the patient has long above-elbow residual limbs and knee disarticulation or long above-knee limbs, ambulation is usually possible. For young children, very short prostheses are used. As the child matures, longer, nonarticulated devices are employed. The use of articulated knees depends on the patient’s level of limb absence and his or her body size and motivation. Some patients choose to stay with nonarticulated prostheses because of the greater stability provided by the rigid knees.

In cases of above-knee-level amputations of the lower limbs and absent upper limbs, getting up from a seated position is extremely difficult and using crutches is impossible because the patient lacks forearms to push up with and quadriceps to extend the knees. If the quadrimelic child has below-elbow deficiencies, prosthetic management may be achieved by attaching prosthetic sockets to crutches or a walker. The shorter the upper limbs, the more difficult it is for the child to walk. For these patients, ambulation may be possible only with very short lower limb prostheses.<sup>158</sup> Many of these children choose to use a motorized wheelchair for mobility.

### **ONE UPPER LIMB AND ONE LOWER LIMB ABSENCES**

If the child lacks one upper limb and one lower limb, the deficiencies can usually be managed in the same way as for a single limb absence, with some minor modifications. In some cases a walking support will be needed in conjunction with a lower limb prosthesis. When learning to use the prosthesis, the patient may require a crutch specially adapted to the abnormal upper limb or upper limb prosthesis, if one is being used. Many of these patients, though, will forgo the use of an upper limb prosthesis.

### **BILATERAL UPPER LIMB AND ONE LOWER LIMB ABSENCES**

Children who lack both upper limbs and also have one deficient lower limb present particularly difficult problems

when it comes to managing their lower limbs. Because the lower limb functions as both a hand and a limb for walking, conventional treatments (e.g., amputation for fibular deficiency) are contraindicated. Prosthetic management of the lower limb must maximize function, with the realization that “hand” function takes priority over lower limb function. If both upper limbs and one lower limb are completely absent, the use of a prosthetic leg is extremely difficult because of the lack of support normally provided by the upper limbs. In addition, it will be difficult to remove the prosthesis, because the foot is the only functional “hand.” Some of these children will use a prosthesis, but others will choose to ambulate by hopping on the normal leg.

## **Concepts of Prosthetic Management**

### **GENERAL GUIDELINES**

For children with congenital limb deficiencies, the timing of prosthetic management usually is based on the patient’s developmental readiness for the prosthesis.<sup>196</sup> Children with upper limb deficiencies usually are fitted with a passive prosthesis when they start to acquire independent sitting balance.<sup>218</sup> Children with lower limb deficiencies usually are fitted when they start trying to stand (normally between 9 and 16 months of age).<sup>27,157,159</sup> Training, prosthetic design, and prosthetic replacement are all matched with the child’s developmental state, increasing in complexity as the child matures. A toddler’s first transfemoral prosthesis may be nonarticulated or have a lockable knee joint. With proper training, children may be able to use a prosthesis with an articulated knee by 3 to 4 years of age, when they are more physically and intellectually ready to learn how to use it.<sup>212</sup>

During the child’s first appointment with the prosthetist, the residual limb is evaluated and measured and a cast is made. This model is made either by hand casting or with the use of computer-aided design and manufacture (CAD-CAM) equipment.<sup>197</sup> A clear plastic “test” socket is then fabricated over the model and used for initial evaluation of socket fit. During the patient’s next visit(s), the prosthetist ensures that the prototype socket fits properly and can be adjusted as the child grows. After a suitable socket and suspension system have been made, dynamic alignment of the prosthesis is accomplished. For very young children or recent amputees, alignment changes may be made over several days, whereas older, more experienced patients may need only a single visit. Final fabrication of the prosthesis occurs after appropriate alignment and design have been determined. Some patients may require additional physical therapy after receiving their prosthesis.

Nonstandard prostheses, often hybrids between a prosthesis and an orthosis, are used with a limb abnormality that has not been amputated. These prostheses may be used for a variety of reasons, such as when surgical correction of the abnormality has been refused or delayed, during early observation of longitudinal limb deficiencies, or when lower limb abnormalities normally treated by amputation are combined with upper limb deficiencies that require the child to use the feet for hand function.<sup>192</sup> Because of the myriad, diverse anatomic differences among children with congenital

deficiencies, many pediatric prostheses could be categorized as “nonstandard.”

An equinus, or extension, prosthesis is a common example of a nonstandard prosthesis used for children with congenital deficiencies. To compensate for lower limb length discrepancy, this system incorporates the child’s anatomic foot in a position of comfortable equinus above an appropriately aligned prosthetic foot. The socket may be designed similar to an ankle-foot orthosis (AFO), with either an anterior or a posterior opening. If the patient’s proximal joints are weak or unstable, the equinus prosthesis may include metal knee joints as well as a plastic thigh cuff. In some cases, ischial weightbearing may be incorporated in the design. An equinus, or extension, prosthesis enables the prosthetist to make up for significant length discrepancy, avoids the need for a large shoe lift, allows the child to wear conventional shoes and long pants, and enables the child to benefit from the dynamic capabilities of a prosthetic foot.

As the child grows, the prosthesis may need to be replaced every 12 to 24 months.<sup>70</sup> Growing children usually are seen every 3 to 6 months for follow-up examination to ensure that the prosthesis continues to fit and function properly and to make any necessary adjustments. There are some common methods for dealing with changing size and length of residual limbs because of growth. Easily altered socket liners that allow revisions for changes in shape and size can be used. A lower limb prosthesis can initially be fitted over extra socks, which can be reduced to accommodate growth. Layered sockets, in which a thin inner socket can be removed as growth occurs, may be employed.<sup>86</sup> Removable distal end pads can be replaced with smaller pads as the limb grows. Silicone sockets or other flexible sockets are especially advantageous for patients whose limb volume may fluctuate (Fig. 32–71).<sup>50</sup>

## UPPER LIMB PROSTHESES

Children born with partial upper limb deficiencies will adapt the residual portion of the limb, combined with other, often remarkable compensatory strategies, to efficiently meet their functional needs. Because of this adaptation, they often view an upper limb prosthesis as more of an imposition than a benefit. Children with partial transverse amputation of the upper limb generally do not need prostheses for balance, crawling, or achieving other developmental milestones. If they have bilateral involvement (particularly at more proximal levels), they may alter their order of gross motor development in a highly individual way to meet their unique needs. For example, the child may learn to roll early or develop sitting balance late.<sup>42</sup>

In most cases, a prosthesis is a tool that can provide the patient with the ability to pinch or grasp an object, and then manipulate the object with the intact upper limb. However, the fine manipulative, proprioceptive, and sensory functions of the hand cannot be duplicated by any of today’s prostheses, regardless of their sophistication. The reported rates of rejection of upper limb myoelectrical prostheses range from zero to 50 percent.<sup>51,119,216,257,312</sup> Often the child (or parents) will seek a prosthesis more for cosmetic purposes than functional need.

Prosthetic management should be harmonious with the child’s normal developmental milestones.<sup>128</sup> Normally, a pas-

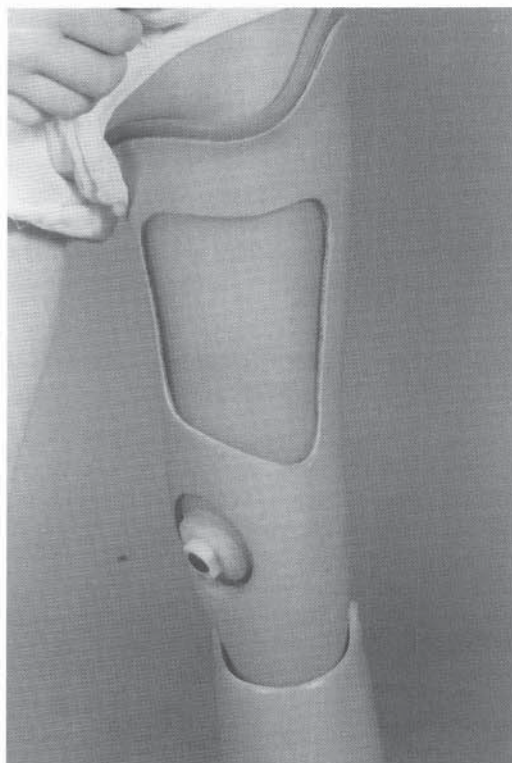


FIGURE 32–71 An open-frame flexible socket for use in amputees when volume changes are anticipated because of chemotherapy or other factors. (From Herring JA, Cummings DR: The limb-deficient child. In Morrissy RT, Weinstein SL (eds): *Lovell and Winter’s Pediatric Orthopaedics*, 4th ed, vol 2. Philadelphia, Lippincott-Raven, 1996.)

sive prosthesis is fitted at about ages 6 to 9 months, when the child has learned to sit independently and is starting two-handed activities. Between 12 and 24 months, a prosthesis with an active terminal device is prescribed. The options include the CAPP terminal device, body-powered hooks and hands, and myoelectrical hands.

Children with below-elbow absences learn to use their elbow for prehensile activities and usually have little functional need for a prosthesis. Most children use a prosthesis for specific purposes or occasions. Myoelectric hands are popular because of their “handlike” appearance and because they minimize or eliminate harnessing.<sup>131,252</sup> Children as young as 3 years can be taught to control a hand with a two-site electrode system.<sup>19</sup> As newer, smaller hands and single-site electrode control systems have become available, some centers have begun routinely training children to use their myoelectrical prostheses as young as 20 months of age, and other centers report success as early as 12 to 18 months.<sup>53,252</sup> Cable-operated (or body-powered) hooks can be fitted successfully as soon as the child is amenable to training, which generally is around 24 months. Among these, the CAPP terminal device, whose design allows for easy visual control, is adapted specifically for younger children. Voluntary opening, as well as voluntary closing, hook terminal devices remain among the most functional because of their durability, simplicity, and provision of a clear view of the object. However, because of poor grip and high operating forces, currently available pediatric voluntary opening cable-operated hands do not appear appropriate for young children with limb deficiencies.



There are numerous combinations of prosthetic components available for patients with above-elbow limb absences. A passive friction elbow that can be positioned with the other hand is often used first. Later, a body-powered myoelectrical, or switch-activated, elbow may be tried.<sup>131,252</sup> These complex devices, however, often are not used by children with congenital absence of the upper limb because they find it easier to function with their residual limb (or, in the case of bilateral upper limb deficiency, with their feet). With shoulder disarticulation prostheses, the child may not have the excursion or strength needed for a body-powered elbow. For such levels, electrical elbows, combined with body-powered or electrical terminal devices, may be employed, but often they are not successfully used on a long-term basis.

## LOWER LIMB PROSTHESES

Because many children with lower limb deficiencies are active and healthy, they can place extreme demands on their prostheses, wearing them out or destroying them during play or sports activities. In addition, as children grow, the close fit of the socket is lost, and periodic adjustments are needed to keep the prosthesis functioning properly. The prosthesis may need to be lengthened every 6 months, and children often outgrow their socket in a year. Thus, prostheses must fit snugly but be easily modified to accommodate growth, be lightweight yet strong, and be durable but reasonably cosmetic. Adolescents often prefer soft, cosmetic covers over modular endoskeletal components, while others prefer to wear exposed components with no cover at all. Still others request patterns, cartoon characters, or other self-expressive designs on their prosthetic covers.

There are a number of different types of prosthetic feet that can be used with lower limb prostheses. The SACH (solid ankle-cushioned heel) foot is most often used with younger children. Older children and adolescents may prefer dynamic response feet that have a flexible keel, aid propulsion, and enhance the person's running skills and athletic performance. Although multiple-axis ankles are available, they are not recommended for young children because of their complexity, added weight, and lack of durability.

## GAIT PROBLEMS ASSOCIATED WITH LOWER LIMB PROSTHESES

The gait of a person with a lower limb prosthesis is asymmetric, with the degree of asymmetry directly related to the level of the deficiency—the higher the level of loss, the greater the asymmetry.<sup>65</sup> The gait of below-knee amputees is characterized by a longer double-limb support time on the prosthetic side, a longer stance phase on the nonprosthetic side, significantly greater limb loading on the nonprosthetic side, and dominance by the nonprosthetic limb during the gait cycle.<sup>65</sup> With above-knee amputees, comfortable walking speed is reduced, swing phase is longer on the prosthetic side, energy consumption is greater than in able-bodied subjects, and there is no specific relationship between prosthetic socket designs and energy expenditure.<sup>29</sup> Age, general health, fitness, and activity level all play a role in the gait characteristics of amputees.<sup>117</sup>

Some of the primary problems associated with gait abnormalities in children who require lower limb prostheses are

increased energy expenditure, “whips,” lateral bending of the trunk, excessive adduction of the prosthesis, vaulting, and circumduction.<sup>15,31,228,245</sup>

*Increased energy expenditure* is seen whenever there is an abnormal gait. It has been estimated that below-knee amputees expend about 60 percent more energy and above-knee amputees about 100 percent more energy than normal at comfortable walking speed.<sup>49</sup> Energy expenditure during walking normally is reduced by minimizing the excursion of the center of gravity, by controlling momentum, and by active transfer of energy between limb segments. In amputees, the center of gravity excursion can be minimized by a well-fitted prosthesis, and control over momentum can be maximized by good muscle strength and control of the residual limb. However, transfer of energy between segments of the lower limb prosthesis is not the same as energy transfer in a normal limb.<sup>93,117,248</sup> As a result, child amputees expend more energy to walk or run than able-bodied children.

A *whip* is a gait abnormality seen during swing phase in patients with above-knee prostheses. It usually is caused by malorientation of the axis of the knee relative to the line of progression. The prosthetic knee normally is rotated externally by 2 to 5 degrees. If the knee axis is excessively rotated internally, the prosthetic shank and foot will whip laterally; if the knee is excessively rotated laterally, there will be a medial whip. The direction of the whip is always in the opposite direction of the malrotation of the prosthetic knee. The physician can best observe these swing-phase whips from behind during the very beginning of swing phase on the prosthetic side. Whips may also be caused by poor socket fit (either too loose or too tight), or they may develop as the residual limb outgrows the socket. Whips can usually be corrected through prosthetic adjustment or gait training. Exceptions are whips due to hip joint pathology, congenital deformities, or muscular abnormalities.

*Lateral trunk bending* to the prosthetic side during stance phase (Trendelenburg lurch) usually occurs when the prosthesis (above- or below-knee) is too short, a situation that can be corrected by simply lengthening the prosthesis. With transfemoral amputees, lateral bending of the trunk may also occur if the lateral socket wall does not comfortably or adequately stabilize the shaft of the femur, when there is excessive pressure on the distal end of the femur, or if there is excess tissue bulging uncomfortably over the upper medial edge of the socket. Patients with weak hip abductors, an unstable hip, or an extremely short residual femoral segment (resulting in a decrease in lateral stabilization) may need to compensate by leaning laterally over the prosthesis. By leaning the trunk laterally, body weight is shifted over the prosthesis, the hip abductors are required to do less work, lateral forces against the femur are minimized, and the patient is better able to balance over the prosthesis. A proper transfemoral amputation (including myodesis of the adductors to maintain anatomic alignment of the femur) may play a greater role in influencing the amputee's ability to stabilize the femur in the prosthesis than the actual design of the socket.<sup>100</sup> If the child has a short residual limb or weak abductors, additional support and stability can be provided by adding a pelvic band and hip joint to the prosthesis.

Excessive adduction of the prosthesis is usually due to developmental changes rather than incorrect prosthetic alignment.<sup>112</sup> When children start to walk, they tend to have

a wide-based gait with flexed hip and knees. As the child matures, the base becomes narrower. Thus, a prosthesis fitted before or at the beginning of the child's walking stage will be improperly aligned as the child's gait changes. Because of this, a young child's first prostheses will have to be changed sooner than subsequent ones.

*Vaulting* on the normal limb or *circumduction* of the prosthesis can be seen in children who develop compensatory habits as they learn to use a prosthesis. This is particularly true with new prostheses or above-knee prostheses with knee joint mechanisms. Children quickly adapt their gait patterns to accommodate the prosthesis, often with little regard for gait appearance. Vaulting is characterized by the child's rising on the toe of the normal foot to permit him or her to swing the prosthesis through with minimal knee flexion. In a circumducted gait, there is a swinging of the prosthesis laterally in a wide arc during swing phase. Vaulting and circumduction may develop because the prosthesis is too long or there is limited knee flexion, the child has an abduction contracture of the residual limb, or the child is afraid to flex the prosthetic knee because of muscle weakness or fear of falling.<sup>117</sup> Physical therapy may be helpful in correcting undesirable gait pattern habits.

## GUIDELINES FOR REPLACING PROSTHESES

Prostheses need to be replaced when they wear out or are essentially destroyed, a common occurrence with lower limb prostheses used by active children. Other less obvious indications for replacement are (1) when continued prosthetic adjustments cannot reestablish a satisfactory socket fit, (2) if weightbearing surfaces or relief areas in the socket do not conform to the child's anatomy, (3) when the patient's weight or activity level is approaching or greater than the maximum values specified for the prosthetic components, (4) if developmental changes in gait or posture cannot be accommodated by the prosthesis, and (5) when the prosthesis cannot accommodate angular changes of the limb.

## Prosthetic Management of Specific Deficiencies

### PROXIMAL FEMORAL FOCAL DEFICIENCY

There are a number of different prosthetic management options for patients with PFFDs. The first is to do no surgery, and simply provide the child with a prosthesis. This approach addresses the common problem of a weak, unstable hip and an extremely proximal knee and foot. The prosthetic socket usually provides the patient with ischial or gluteal weightbearing to offset the piston action of the unstable hip. The knee normally is included in the socket, and the foot is positioned in equinus (mainly for cosmetic purposes). The prosthesis may be suspended by a heel strap or waist belt. As the child matures and approaches adolescence, the limb discrepancy may be great enough to allow for a prosthetic knee joint below the foot. If the discrepancy is not so severe, the child may simply be fitted with an extension prosthesis, with a prosthetic foot placed below the plantar-flexed foot. When they are not wearing their prostheses,

most of these children are able to tolerate walking in equinus on the affected limb.

Another option is the conventional fitting of a Syme prosthesis following a Syme amputation. This is appropriate when the femoral segment is long enough to permit the knee to function. The patient usually can bear weight distally, and the prosthesis can be self-suspended over the prominent malleoli. This allows for a good gait. However, the patient may have a Trendelenburg lurch if there is an abnormal hip or a short femoral neck. One drawback to this management approach is that a relatively long prosthesis and high knee joint are required because the affected femoral segment is markedly shorter than the contralateral femur and the knee joint is more proximal. Maintaining the anatomic knee provides the child with better function, but the poor cosmesis of the long prosthesis becomes more evident as the child reaches adult proportions.

When a Syme amputation is combined with knee fusion, a single, straight lever arm is created so that an "above-knee" prosthesis can be fitted and hip flexion contracture can be eliminated or reduced.<sup>145,146</sup> The prosthesis can be fitted when the wound is healed and the patient is developmentally ready to use a prosthesis. To counteract pistoning of the unstable hip, the prosthetic socket usually provides ischial or gluteal weightbearing or containment. In most cases, the prosthesis for younger children is suspended by a waist belt; however, if the malleoli and heel pad are sufficiently bulbous, they may be able to "self-suspend" the prosthesis. Self-suspension can also be achieved by using an expandable inner "bladder" secured above the malleoli that permits the flared distal portion of the limb to pass in or out of the prosthesis.<sup>281</sup> Another approach is to position a compressible suspension pad directly over the residual limb distally. When it is time to add a prosthetic knee joint to the prosthesis, a polycentric "knee-disarticulation" four-bar knee provides good stability and cosmetic appearance.

After a van Ness rotationplasty, the prosthesis typically accommodates the foot in a comfortable equinus position within the socket. Weightbearing is on the plantar (now anterior) part of the foot and calcaneus.<sup>28</sup> Room is provided distally for growth of the toes, and a removable socket liner is fitted between the limb and prosthesis. Mediolateral stability of the ankle is achieved by extending single-axis joints from the socket up to a rigid, bivalved shell or a leather or plastic cuff around the patient's thigh. If the patient's hip is unstable, the thigh portion of the prosthesis is extended proximally to provide ischial-gluteal weightbearing. If the hip is stable, weightbearing may be through the foot rather than the ischium. A heel strap or waist belt is usually used to suspend the prosthesis. Specific components and alignment are individualized based on the particular needs of the patient. In most cases, it is not possible to achieve a normal gait; the deficient hip joint and musculature usually cause the patient to have a Trendelenburg gait. The degree of functional "knee" control depends on the strength, range of motion, and correct orientation of the rotated ankle.

### FIBULAR DEFICIENCY

Prosthetic management following amputation is relatively easy because the limb takes on a cylindrical shape, with only mild enlargement of the distal portion of the leg. Even

though the lateral malleolus usually is absent after ankle disarticulation, the child is usually capable of full weight-bearing on the heel pad. The prosthesis consists of a firm distal pad for protection, combined with a total-contact patellar tendon-bearing (PTB) socket. If there is anterior tibial bowing, special padding or relief in the socket may be necessary. Soft liners and foam shell designs have eliminated the need for a window in the prosthesis.

The length discrepancy associated with fibular hemimelia often allows for more space in the prosthesis distal to the residual limb in which to place a prosthetic foot, and the prosthetist is not limited to feet specifically designed for a Syme amputee. For a child who is just beginning to ambulate, the prosthesis usually must be suspended by a cuff above the femoral condyles, a waist belt, or a neoprene sleeve. After their second or third prosthesis, many children are able to keep the device on by actively contracting their heel pad against the contoured inner wall of the socket. Self-suspension may also be attained by using pads or an expandable inner socket liner.<sup>50</sup> The proximal brim of the socket should extend high on either side of the knee to provide rotational control and some mediolateral stability. If knee valgus is present, the prosthesis can be adjusted to allow for medial displacement of the prosthetic foot.

### TIBIAL DEFICIENCY

Prosthetic management depends on the type of surgery performed. For a Jones type 2 deformity, in which the proximal tibia has been fused to the upper tibia and a Syme amputation has been performed distally, a conventional Syme prosthesis is appropriate. This also holds true for a Jones type 4 deformity treated with a modified Syme ankle disarticulation. If the child's knee is stable and there is good hamstring and quadriceps function, joints and thigh corsets are not necessary.

After a knee disarticulation for complete tibial hemimelia, the patient is fitted with an end-bearing above-knee prosthesis when the child is attempting to walk. With the first prosthesis, the knee joint usually has a manual lock or is nonarticulated. When the child is approximately 3 years old, he or she can usually manage well with an articulated knee and should eventually be able to perform at a normal activity level, including running.<sup>178</sup>

For complete tibial hemimelia in which a Brown procedure has been performed (i.e., centralization of the fibula combined with a Syme amputation), a below-knee prosthesis with knee joints and a thigh corset is used to provide mediolateral knee stability. Prosthetic management is difficult with these patients, however, because the knee usually is extremely unstable (often lacking quadriceps function) and there is a tendency toward progressive knee flexion contracture.

### FOOT DEFICIENCIES

The prosthetic management of foot deficiencies is usually simple and depends on the degree of congenital deficiency. Some patients may need only a padded toe-filler device to preclude shoe distortion, or a slipper-type prosthesis (a modified plastic shoe insert) may work well. These systems

provide excellent cosmesis and are less restrictive than an AFO. Adequate padding combined with frequent modifications for growth should prevent pressure problems over rudimentary toes. If the residual foot is not long enough to suspend a prosthesis, the child can be fitted with a modified AFO with a partial prosthetic foot. Patients with congenital partial foot deficiencies usually do not have problems with equinus deformity.

### FOOT AMPUTATION

The prosthetic management of foot amputations is similar to that for congenital partial foot absence. A patient with a transmetatarsal amputation may need only a toe-filler device. In some cases, however, it may be necessary during the early postoperative period to use a modified AFO to prevent an equinus contracture. The addition of a padded cosmetic toe-filler to a polypropylene AFO affords the patient maximum ankle stability, good rotational control, and an extended toe "lever arm." If there is no tendency to contracture, a less restrictive, flexible slipper-style prosthesis may be fitted a year or so later. If periosteal overgrowth occurs, the orthopaedist may need to perform revision surgery to excise the sharp ends of the metatarsals. However, this problem may be averted if biologic capping is performed during the initial amputation.<sup>54</sup> Patients with tarsometatarsal and midtarsal amputations function well with a slipper-type prosthesis. After a tarsometatarsal amputation, the foot usually remains in a neutral position if the tibialis anterior and toe extensor tendons are sutured to the talus at the time of the amputation to offset the pull of the Achilles tendon.

### AMPUTATION BECAUSE OF MALIGNANT TUMORS

The prosthetic management of patients who have undergone amputations because of malignancy often is dramatically different from the management of patients with traumatic amputations and is influenced by a number of unique factors. Children with malignancies frequently must be fitted with a prosthesis while they are dealing with the emotional trauma of a life-threatening illness and the physical distress caused by chemotherapy and radiation therapy.

Because the child's life span may be attenuated, periods of medical intervention should be minimized and the child should be mobilized as rapidly as possible. It is important to fit the child with a prosthesis early on to improve his or her body image, realizing, however, that the residual limb will change quickly in size and shape. As the residual limb is maturing, a temporary, easily replaced prosthesis or socket should be used. When patients are receiving chemotherapy, they frequently experience intermittent periods of weight loss that will affect the fit of a prosthesis. If limb volume changes are anticipated, a socket that can be adapted to meet these fluctuations should be used (e.g., a flexible above-knee socket with a windowed outer frame or some other mechanism for adjusting for volumetric changes). If the child has multiple tumor sites, prosthetic management becomes even more difficult (e.g., the child with a secondary tumor in the upper limb may not be able to use crutches effectively).

## ABOVE-KNEE AMPUTATION

The most commonly used sockets for above-knee prostheses are the quadrilateral socket and the newer ischial containment socket.<sup>181,224,227,242</sup> Ischial containment sockets may provide more control in younger patients without creating uncomfortable pressure as the child grows. This socket may also be preferred by active persons.<sup>251</sup>

For young children, a transfemoral prosthesis is most often suspended by a Silesian belt or a total elastic suspension (TES) belt.<sup>253</sup> In most cases, suction suspension should be reserved for patients 6 years old or older.<sup>284</sup> If the patient has an extremely short residual limb, weak abductor muscles, an unstable or painful hip, or is obese, the prosthesis may be suspended by a hip joint with a pelvic band and belt.<sup>101</sup> A variety of prosthetic knees are now available for children, including manual-locking knees, constant-friction knees, stance-control or weight-activated friction knees, polycentric or four-bar knees, and fluid-controlled knees.<sup>197,198</sup>

## KNEE DISARTICULATION

A variety of prosthetic sockets and knee mechanisms have been specifically designed to take advantage of the supracondylar suspension capacity, long lever arm, and end weight-bearing tolerance provided by through-knee amputations.<sup>132</sup> Socket design often is determined by the amount of distal weightbearing the patient can tolerate and the size of the femoral condyles relative to the thigh. If the distal femur is underdeveloped and not able to provide adequate prosthetic suspension, the prosthesis may need to be suspended by suction, or by a Silesian or TES belt. Almost any knee mechanism can be used with a knee disarticulation prosthesis, but because of the long femoral segment, only a few specifically designed polycentric knees will enable the prosthetist to match the knee centers. The choice should be based on the individual patient's goals and needs. If an epiphysiodesis is performed to provide room for the knee, 3 cm should be sufficient for a polycentric knee, and 6 cm will accommodate practically any knee.<sup>208</sup>

## BELOW-KNEE AMPUTATION

Socket designs for below-knee prostheses employ some degree of patellar tendon weightbearing, with additional support through the medial flare of the tibia and through total contact. This relieves pressure on the anterior distal tibia and the fibular head. If additional mediolateral stability of the knee is required, the supracondylar design may be used; however, if the collateral ligaments are damaged or absent, greater stability is provided by joints and a thigh corset. Suspension straps are used with young children who have not started walking, and later replaced with the PTS socket or with neoprene sleeves. Silicone suspension methods not only suspend the prosthesis, they may also reduce shear along the socket interface. The most common silicone below-knee device is a pliable silicone sleeve with a ribbed stainless steel pin protruding distally from the sleeve. Silicone suction systems provide excellent suspension and minimize shear as well as up-and-down pistoning of the prosthesis. Replaceable, soft distal pads are used to accommodate

longitudinal growth and protect against bony overgrowth.<sup>50</sup> Relative contraindications to silicone suction include fluctuating limb volume, bony overgrowth, neuromas, significant adhesive scar tissue, long residual limbs (such as with a Syme amputation), frequent kneeling or crawling, and physical or mental inability to operate the lock mechanism.<sup>69</sup>

## REFERENCES

1. Abraham E, Pellicore RJ, Hamilton RC, et al: Stump overgrowth in juvenile amputees. *J Pediatr Orthop* 1986;6:66.
2. Achterman C, Kalamchi A: Congenital deficiency of the fibula. *J Bone Joint Surg* 1979;61-B:133.
3. Adams WP Jr, Hobar PC: Surgical treatment of meningococcal-induced purpura fulminans. In Herring JA, Birch JG (eds): *The Child With a Limb Deficiency*, p 447. Rosemont, IL, American Academy of Orthopaedic Surgeons, 1998.
4. Aitken G: Osseous overgrowth in amputations in children. In Swinyard C (ed): *Limb Development and Deformity: Problems of Evaluation and Rehabilitation*. Springfield, IL, Charles C Thomas, 1969.
5. Aitken G: Overgrowth of the amputation stump. *J Assoc Child Prosthet Orthot Clin* 1962;1:1.
6. Aitken G: Overgrowth of the amputation stump. *Interclin Information Bull* 1962;1:1.
7. Aitken G: Surgical amputation in children. *J Bone Joint Surg* 1963;45-A:1735.
8. Aitken G: Tibial hemimelia. In: *A Symposium on Selected Lower Limb Anomalies: Surgical and Prosthetic Management*, p 1. Washington, DC, National Academy of Sciences, 1971.
9. Aitken GT: The child amputee: an overview. *Orthop Clin North Am* 1972;3:447.
10. Aitken GT: Proximal femoral focal deficiency: a congenital anomaly. In Aitken GT (ed): *A Symposium on Proximal Femoral Focal Deficiency: A Congenital Anomaly*, p 1. Washington, DC, National Academy of Sciences, 1969.
11. Aitken GT, Frantz CH: Management of the child amputee. *Instr Course Lect* 1960;17:246.
12. Alman BA, Krajchich JI, Hubbard S: Proximal femoral focal deficiency: results of rotationplasty and Syme amputation. *J Bone Joint Surg* 1995;77-A:1876.
13. Amstutz HC: Histiocytosis X: Natural history and treatment of congenital absence of the fibula (abstract). *J Bone Joint Surg* 1972;54-A:1349.
14. Amstutz HC: The morphology, natural history, and treatment of proximal femoral focal deficiency. In Aitken GT (ed): *A Symposium on Proximal Femoral Focal Deficiency: A Congenital Anomaly*, p 50. Washington, DC, National Academy of Sciences, 1969.
15. Anderson M, Bray J, Hennessy C: *Prosthetic Principles: Above Knee Amputations*. Springfield, IL, Charles C Thomas, 1960.
16. Anderson M, Green WT, Messner MB: The classic: growth and predictions of growth in the lower extremities. *Clin Orthop* 1978;136:7.
17. Anderson M, Green WT, Messner MB: Growth and predictions of growth in the lower extremities. *J Bone Joint Surg* 1963;45-A:1.
18. Anger DM, Ledbetter BR, Stasikelis PJ: Injuries of the foot related to the use of lawn mowers. *J Bone Joint Surg* 1995;77-A:719.
19. Baron E, Clarke S, Solomon C: The two stage myoelectric hand for children and young adults. *Orthot Prosthet* 1983;37:11.
20. Bavinck JN, Weaver DD: Subclavian artery supply disruption sequence: hypothesis of a vascular etiology for Poland, Klippel-Feil, and Möbius anomalies. *Am J Med Genet* 1986;23:903.
21. Benevenia J, Makley JT, Leeson MC, et al: Primary epiphyseal transplants and bone overgrowth in childhood amputations. *J Pediatr Orthop* 1992;12:746.
22. Bennett JB, Riordan DC: Ulnar hemimelia. In Herring JA, Birch JG (eds): *The Child With a Limb Deficiency*, p 387. Rosemont, IL, American Academy of Orthopaedic Surgeons, 1998.
23. Bernd L, Blasius K, Lukoschek M, et al: The autologous stump plasty: treatment for bony overgrowth in juvenile amputees. *J Bone Joint Surg* 1991;73-B:203.
24. Birch JG, Lincoln TL, Mack PW: Functional classification of fibular deficiency. In Herring JA, Birch JG (eds): *The Child With a Limb*

- Deficiency, p 161. Rosemont, IL, American Academy of Orthopaedic Surgeons, 1998.
25. Blanco J, Herring J: Congenital Chopart amputation: a functional assessment. *J Assoc Child Prosthet Orthot Clin* 1989;24:27.
  26. Boakes JL, Stevens PM, Moseley RF: Treatment of genu valgus deformity in congenital absence of the fibula. *J Pediatr Orthop* 1991;11:721.
  27. Bochmann D: Prostheses for the limb-deficient child. In Kostuik J, Gillespie R (eds): *Amputation Surgery and Rehabilitation: The Toronto Experience*, p 293. New York, Churchill Livingstone, 1981.
  28. Bochmann D: Prosthetic devices for the management of proximal femoral focal deficiency. *Orthot Prosthet* 1980;12:4.
  29. Boonstra AM, Schrama J, Fidler V, et al: The gait of unilateral transfemoral amputees. *Scand J Rehabil Med* 1994;26:217.
  30. Borggreve J: Kniegelenkseratz durch das in der Beinlängsachse um 180 degree gedrehte Fussgelenk. *Arch Orthop* 1930;28:175.
  31. Bowker J, Michael J: *Atlas of Limb Prosthetics: Surgical, Prosthetic, and Rehabilitation Principles*, 2nd ed. St. Louis, Mosby-Year Book, 1992.
  32. Brown F: Construction of a knee joint in congenital total absence of the tibia (paraxial hemimelia tibia). *J Bone Joint Surg* 1965;47-A:695.
  33. Brown F, Pohnert W: Construction of a knee joint in meromelia tibia (congenital absence of the tibia): a 15-year follow-up study. *J Bone Joint Surg* 1972;54-A:1333.
  34. Brown KLB: Rotationplasty with hip stabilization in congenital femoral deficiency. In Herring JA, Birch JG (eds): *The Child With a Limb Deficiency*, p 103. Rosemont, IL, American Academy of Orthopaedic Surgeons, 1998.
  35. Buck-Gramcko D: The role of nonvascularized toe phalanx transplantation. *Hand Clin* 1990;6:643.
  36. Buncke HJ (ed): *Microsurgery: Transplantation-Replantation: An Atlas-Text*, p 587. Philadelphia, Lea & Febiger, 1991.
  37. Catagni M: Management of fibular hemimelia using the Ilizarov method. *Instr Course Lect* 1992;61:431.
  38. Chestnut R, James HE, Jones KL: The VATER association and spinal dysraphia. *Pediatr Neurosurg* 1992;18:144.
  39. Choi IH, Kumar SJ, Bowen JR: Amputation or limb-lengthening for partial or total absence of the fibula. *J Bone Joint Surg* 1990;72-A:1391.
  40. Christini D, Kumar SJ: Fibular transfer in tibial hemimelia: a follow-up study. *J Assoc Child Prosthet Orthot Clin* 1991;26:8.
  41. Clark M: Autosomal dominant inheritance of tibial meromelia. *J Bone Joint Surg* 1975;57-A:262.
  42. Clark MW, Atkins DJ, Hubbard SA, et al: Prosthetic devices for children with bilateral upper limb deficiencies: when and if, pros and cons. In Herring JA, Birch JG (eds): *The Child With a Limb Deficiency*, p 397. Rosemont, IL, American Academy of Orthopaedic Surgeons, 1998.
  43. Cogbill H, Steenlage ES, Landercasper J, et al: Death and disability from agricultural injuries in Wisconsin: a 12-year experience with 739 patients. *J Trauma* 1991;31:1632.
  44. Cohen MM Jr (ed): *The Child with Multiple Birth Defects*, 2nd ed, p 15. New York, Oxford University Press, 1997.
  45. Cohn MJ, Izpisua-Belmonte JC, Abud H, et al: Fibroblast growth factors induce additional limb development from the flank of chick embryos. *Cell* 1995;80:739.
  46. Cole RJ, Manske PR: Classification of ulnar deficiency according to the thumb and first web. *J Hand Surg* 1997;22-A:479.
  47. Coupland RM, Krover A: Injuries from antipersonnel mines: the experience of the International Committee of the Red Cross. *Br Med J* 1991;303:1509.
  48. Coventry M, Johnston E: Congenital absence of the fibula. *J Bone Joint Surg* 1952;34-A:941.
  49. Crouse SF, Lessard CS, Rhodes J, et al: Oxygen consumption and cardiac response of short-leg and long-leg prosthetic ambulation in a patient with bilateral above-knee amputations: comparisons with able-bodied men. *Arch Phys Med Rehabil* 1990;71:313.
  50. Cummings DR, Kapp SL: Lower-limb pediatric prosthetics: general considerations and philosophy. *J Prosthet Orthot* 1992;4:196.
  51. Dalsey R, Gomez W, Seitz W, et al: Myoelectrical prosthetic replacement in the upper extremity amputee. *Orthop Rev* 1989;18:697.
  52. Damsin JP, Pous JG, Ghanem I: Therapeutic approach to severe congenital lower limb length discrepancies: surgical treatment versus prosthetic management. *J Pediatr Orthop* 1995;4:164.
  53. Datta D, Ibbotson V: Powered prosthetic hands in very young children. *Prosthet Orthot Int* 1998;22:150.
  54. Davids JR: Terminal bony overgrowth of the residual limb: current management strategies. In Herring JA, Birch JG (eds): *The Child With a Limb Deficiency*, p 269. Rosemont, IL, American Academy of Orthopaedic Surgeons, 1998.
  55. Davids JR, Meyer LC, Blackhurst DW: Operative treatment of bone overgrowth in children who have an acquired or congenital amputation. *J Bone Joint Surg* 1995;77-A:1490.
  56. Day HJ: The ISO/ISPO classification of congenital limb deficiency. *Prosthet Orthot Int* 1991;15:67.
  57. Di Bella D, Di Stefano G, Romeo MG, et al: Upper limb cardiovascular syndrome with ulna agenesis (abstract). *Pediatr Radiol* 1984;14:259.
  58. Dirschl DR, Dahners LE: The mangled extremity: when should it be amputated? *J Am Acad Orthop Surg* 1996;4:182.
  59. Dobyns JH, Wood VE, Bayne LG, et al: Congenital hand deformities. In Green DP (ed): *Operative Hand Surgery*, p 213. New York, Churchill Livingstone, 1982.
  60. Dolan MA, Knapp JF, Andres J: Three-wheel and four-wheel all-terrain vehicle injuries in children. *Pediatrics* 1989;84:694.
  61. Dolle P, Izpisua-Belmonte JC, Falkenstein H, et al: Coordinate expression of the murine Hox-5 complex homeobox-containing genes during limb pattern formation. *Nature* 1989;342:767.
  62. Dormans JP: Management of pediatric mutilating extremity injuries and traumatic amputations. In Herring JA, Birch JG (eds): *The Child With a Limb Deficiency*, p 253. Rosemont, IL, American Academy of Orthopaedic Surgeons, 1998.
  63. Dormans JP, Azzoni M, Davidson RS, et al: Major lower extremity lawn mower injuries in children. *J Pediatr Orthop* 1995;15:78.
  64. Eilert R, Jayakumar S, Boyd and Syme ankle amputations in children. *J Bone Joint Surg* 1976;58-A:1138.
  65. Engsberg JR, Lee AG, Tedford KG, et al: Normative ground reaction force data for able-bodied and below-knee amputee children during walking. *J Pediatr Orthop* 1993;13:169.
  66. Epps C: Current concepts review: proximal femoral focal deficiency. *J Bone Joint Surg* 1983;65-A:867.
  67. Ezaki M: Upper extremity deficiencies. In Herring JA, Birch JG (eds): *The Child With a Limb Deficiency*, p 381. Rosemont, IL, American Academy of Orthopaedic Surgeons, 1998.
  68. Farmer A, Laurin C: Congenital absence of the fibula. *J Bone Joint Surg* 1960;42-A:1.
  69. Fillauer C, Pritham C, Fillauer K: Evolution and development of the silicone suction socket (3S) for below-knee prostheses. *J Pediatr Orthop* 1989;1:92.
  70. Fisk J: Introduction to the child amputee. In Bowker J, Michael J (eds): *Atlas of Limb Prosthetics: Surgical, Prosthetic, and Rehabilitation Principles*, p 731. St. Louis, Mosby-Year Book, 1992.
  71. Fixsen J, Lloyd-Roberts G: The natural history and early treatment of proximal femoral dysplasia. *J Bone Joint Surg* 1974;56-B:86.
  72. Flatt AE: Ulnar deficiencies. In Flatt AE (ed): *The Care of Congenital Hand Anomalies*, 2nd ed, p 411. St. Louis, Quality Medical Publishing, 1994.
  73. Fowler E, Zernicke R, Setoguchi Y, et al: Energy expenditure during walking by children who have proximal femoral focal deficiency. *J Bone Joint Surg* 1996;78-A:1857.
  74. Francis PH, Richardson MK, Brickell PM, et al: Bone morphogenetic proteins and a signaling pathway that controls patterning in the developing chick limb. *Development* 1994;120:209.
  75. Francis-West PH, Robertson KE, Ede DA, et al: Expression of genes encoding bone morphogenetic proteins and sonic hedgehog in talpid (ta3) limb buds: their relationship in the signaling cascade involved in limb patterning. *Dev Dyn* 1995;203:187.
  76. Frankel V, Gold S, Golyakhovsky V: The Ilizarov technique. *Bull Hosp Jt Dis Orthop Inst* 1988;48:17.
  77. Frantz C: The increase in the incidence of malformed babies in the German Federal Republic during the years 1959–1962. *J Assoc Child Prosthet Orthot Clin* 1994;28:62.
  78. Frantz C: The upsurge in phocomelic congenital anomalies. *J Assoc Child Prosthet Orthot Clin* 1994;28:38.
  79. Frantz C, Aitken G: Management of the juvenile amputee. *Clin Orthop* 1959;9:30.
  80. Frantz CH, O'Rahilly R: Congenital skeletal limb deficiencies. *J Bone Joint Surg* 1961;43-A:1202.
  81. Friedmann L: Toileting self-care methods for bilateral high level upper limb amputees. *Prosthet Orthot Int* 1980;4:29.
  82. Froster UG, Baird PA: Congenital defects of lower limbs and associated

- malformations: a population-based study. *Am J Med Genet* 1993;45:60.
83. Froster UG, Baird PA: Upper limb deficiencies and associated malformations: a population-based study. *Am J Med Genet* 1992;44:767.
  84. Froster-Iskenius UG, Baird PA: Limb reduction defects in over one million consecutive livebirths. *Teratology* 1989;39:127.
  85. Fuller D, Duthie R: The timed appearance of some congenital malformations and orthopaedic abnormalities. *Instr Course Lect* 1974;23:53.
  86. Gazely W, Ey M, Sampson W: Use of triple wall sockets for juvenile amputees. *Interclin Information Bull* 1964;4:1.
  87. Gherlinzoni F, Picci P, Bacchi G, et al: Limb sparing versus amputations in osteosarcoma: correlations between local control, surgical margins, and tumor necrosis. *Ann Oncol* 1992;3(suppl 2):S23.
  88. Ghoneem HF, Wright JG, Cole WG, et al: The Ilizarov method for correction of complex deformities: psychological and functional outcomes. *J Bone Joint Surg* 1996;78-A:1480.
  89. Gibson D: Child and juvenile amputees. In Banjerjee S, Khan N (eds): *Rehabilitation Management of Amputees*. Baltimore, Williams & Wilkins, 1982.
  90. Gillespie R: Classification of congenital abnormalities of the femur. In Herring JA, Birch JG (eds): *The Child With a Limb Deficiency*, p 63. Rosemont, IL, American Academy of Orthopaedic Surgeons, 1998.
  91. Gillespie R: Principles of amputation surgery in children with longitudinal deficiencies of the femur. *Clin Orthop* 1990;256:29.
  92. Gillespie R, Torode IP: Classification and management of congenital abnormalities of the femur. *J Bone Joint Surg* 1983;65-B:557.
  93. Gitter A, Czerniecki JM, DeGroot DM: Biomechanical analysis of the influence of prosthetic feet on below-knee amputee walking. *Am J Phys Med Rehabil* 1991;70:142.
  94. Glanz A, Fraser FC: Spectrum of anomalies in Fanconi anaemia. *J Med Genet* 1982;19:412.
  95. Glessner J: Spontaneous intra-uterine amputation. *J Bone Joint Surg* 1963;45-A:351.
  96. Glorion C, Pouliquen JC, Langlais J, et al: Femoral lengthening using the callotaxis method: study of the complications in a series of 70 cases in children and adolescents. *J Pediatr Orthop* 1996;16:161.
  97. Godina M: Early microsurgical reconstruction of complex trauma of the extremities. *Plast Reconstr Surg* 1986;78:285.
  98. Goldberg MJ: *The Dysmorphic Child: An Orthopedic Perspective*. New York, Raven Press, 1987.
  99. Gonin-Decarie T: The mental and emotional development of the thalidomide children and the psychological reactions of the mothers. *J Assoc Child Prosthet Orthot Clin* 1994;28:79.
  100. Gottschalk F, Sohrab K, Stills M, et al: Does socket configuration influence the position of the femur in above-knee amputation? *J Prosthet Orthot* 1989;2:94.
  101. Gottschalk F, Stills M: The biomechanics of trans-femoral amputation. *Prosthet Orthot Int* 1994;18:12.
  102. Green WT, Anderson M: Skeletal age and the control of bone growth. In Reynolds FC (ed): *Instructional Course Lectures XVII*, p 199. St. Louis, CV Mosby, 1960.
  103. Grissom L, Harcke H, Kumar S: Sonography in the management of tibial hemimelia. *Clin Orthop* 1990;251:266.
  104. Grossley PH, Minowada G, MacArthur CA, et al: Roles for FGF8 in the induction, initiation, and maintenance of chick limb development. *Cell* 1996;84:127.
  105. Gupta A, Wolff TW: Management of the mangled hand and forearm. *J Am Acad Orthop Surg* 1995;3:226.
  106. Gurrieri F, Cammarata M, Avarello RM, et al: Ulnar ray defect in an infant with a 6q21;7q31.2 translocation: further evidence for the existence of a limb defect gene in 621. *Am J Med Genet* 1995;55:315.
  107. Hall CB, Brooks MB, Dennis JF: Congenital skeletal deficiencies of the extremities: classification and fundamentals of treatment. *JAMA* 1962;181:110.
  108. Hall JE: Brown's fibula-femur transfer for congenital absence of the tibia. In Herring JA, Birch JG (eds): *The Child With a Limb Deficiency*, p 219. Rosemont, IL, American Academy of Orthopaedic Surgeons, 1998.
  109. Hall JE: Rotation of congenitally hypoplastic lower limbs to use the ankle joint as a knee. *J Assoc Child Prosthet Orthot Clin* 1966;6:3.
  110. Hall JG, Levin J, Kuhn JP, et al: Thrombocytopenia with absent radius (TAR). *Medicine* 1969;48:411.
  111. Hamanishi C: Congenital short femur. *J Bone Joint Surg* 1980;62-B:307.
  112. Hamilton E: Gait training. Part 2. Children. In Kostuik J (ed): *Amputation Surgery and Rehabilitation: The Toronto Experience*, p 331. New York, Churchill Livingstone, 1981.
  113. Hammerschmidt M, Brook A, McMahon AP: The world according to hedgehog. *Trends Genet* 1997;13:14.
  114. Hancock CI, King RE: The one-bone leg. *J Assoc Child Prosthet Orthot Clin* 1967;7:11.
  115. Hansen-Leth C: Bone vascularization and bone healing in the amputation stump: an experimental study. *Acta Orthop Scand* 1979;50:39.
  116. Hansen-Leth C: Muscle blood flow after amputation with special reference to the influence of osseous plugging of the medullary cavity: assessed by 133 xenon and histamine. An animal experiment. *Acta Orthop Scand* 1976;47:613.
  117. Harder JA: Gait analysis of the child with a lower limb deficiency. In Herring JA, Birch JG (eds): *The Child With a Limb Deficiency*, p 331. Rosemont, IL, American Academy of Orthopaedic Surgeons, 1998.
  118. Harrison RG: Experiments on the development of the forelimb of *Amblystoma*, a self-differentiating equipotential system. *J Exp Zool* 1918;25:413.
  119. Heger H, Millstein S, Hunter G: Electrically powered prostheses for the adult with an upper limb amputation. *J Bone Joint Surg* 1985;67-B:278.
  120. Heikinheimo M, Lawshé A, Shackleford GM, et al: FGF-8 expression in the post-gastrulation mouse suggests roles in the development of the face, limbs and central nervous system. *Mech Dev* 1994;48:129.
  121. Helfet DL, Howey T, Sanders R, et al: Limb salvage versus amputation: preliminary results of the Mangled Extremity Severity Score. *Clin Orthop* 1990;256:80.
  122. Henkel L, Willert H-G: Dysmelia: a classification and a pattern of malformation in a group of congenital defects of the limbs. *J Bone Joint Surg* 1969;51-B:399.
  123. Hepp O: Frequency of congenital defect-anomalies of the extremities in the Federal Republic of Germany. *J Assoc Child Prosthet Orthot Clin* 1994;28:40.
  124. Herrera R, Hobar PC, Ginsburg CM: Surgical intervention for the complications of meningococcal-induced purpura fulminans. *Pediatr Infect Dis J* 1994;13:734.
  125. Herring J, Barnhill B, Gaffney C: Syme amputation: an evaluation of the physical and psychosocial function in young patients. *J Bone Joint Surg* 1986;68-A:573.
  126. Herring JA: Functional assessment and management of multilimb deficiency. In Herring JA, Birch JG (eds): *The Child With a Limb Deficiency*, p 437. Rosemont, IL, American Academy of Orthopaedic Surgeons, 1998.
  127. Herring JA: Symes amputation for fibular hemimelia: a second look in the Ilizarov era. *Instr Course Lect* 1992;41:435.
  128. Herring JA, Birch JG (eds): *The Child With a Limb Deficiency*. Rosemont, IL, Academy of Orthopaedic Surgeons, 1998.
  129. Hogan BL: Bone morphogenetic proteins in development. *Curr Opin Genet Dev* 1996;6:432.
  130. Holt M, Oram S: Familial heart disease with skeletal malformations. *Br Heart J* 1960;22:236.
  131. Hubbard S, Kurtz I, Heim W, et al: Powered prosthetic intervention in upper extremity deficiency. In Herring JA, Birch JG (eds): *The Child With a Limb Deficiency*, p 417. Rosemont, IL, American Academy of Orthopaedic Surgeons, 1998.
  132. Hughes J: Biomechanics of the through-knee prosthesis. *Prosthet Orthot Int* 1983;7:96.
  133. Inoue G, Miura T: Arteriographic findings in radial and ulnar deficiencies. *J Hand Surg* 1991;16-Br:409.
  134. Ippolito E, Peretti G, Bellocchi M, et al: Histology and ultrastructure of arteries, veins, and peripheral nerves during limb lengthening. *Clin Orthop* 1994;308:54.
  135. Jayakumar SS, Eilert RE: Fibular transfer for congenital absence of the tibia. *Clin Orthop* 1979;139:97.
  136. Johansen K, Daines M, Howey T, et al: Objective criteria accurately predict amputation following lower extremity trauma. *J Trauma* 1990;30:568.
  137. Johansson E, Aparisi T: Missing cruciate ligament in congenital short femur. *J Bone Joint Surg* 1983;65-A:1109.
  138. Johnson J, Omar CE II Jr: Congenital ulnar deficiency: natural history and therapeutic implications. *Hand Clin* 1985;1:499.
  139. Johnston CE II, Haideri NF: Comparison of functional outcome in fibular deficiency treated by limb salvage versus Syme's amputation. In Herring JA, Birch JG (eds): *The Child With a Limb Deficiency*, p 173. Rosemont, IL, American Academy of Orthopaedic Surgeons, 1998.

140. Jones D, Barnes J, Lloyd-Roberts G: Congenital aplasia and dysplasia of the tibia with intact fibula: classification and management. *J Bone Joint Surg* 1978;60-B:31.
141. Jones K: Femoral hypoplasia-unusual facies syndrome. In Jones K (ed): *Smith's Recognizable Patterns of Human Malformation*, p 268. Philadelphia, WB Saunders Co, 1988.
142. Jones KL, Smith DW, Hall BD, et al: A pattern of craniofacial and limb defects secondary to aberrant tissue bands. *J Pediatr* 1974;84:90.
143. Jorring K: Amputations in children: a follow-up of 74 children whose lower extremities were amputated. *Acta Orthop Scand* 1971;42:178.
144. Kalamchi A, Dawe RV: Congenital deficiency of the tibia. *J Bone Joint Surg* 1985;67-B:581.
145. King R: Providing a single lever in proximal femoral focal deficiency: a preliminary report. *J Assoc Child Prosthet Orthot Clin* 1966;6:23.
146. King R, Marks T: Follow-up findings on the skeletal lever in the surgical management of proximal femoral focal deficiency. *Interclin Information Bull* 1971;11:1.
147. Kino Y: Clinical and experimental studies of the congenital constriction band syndrome with an emphasis on its etiology. *J Bone Joint Surg* 1969;57-A:636.
148. Kitano K, Tada K: One-bone forearm procedure for partial defect of the ulnar. *J Pediatr Orthop* 1985;5:290.
149. Koman L, Meyer L, Warren F: Proximal femoral focal deficiency: a 50-year experience. *Dev Med Child Neurol* 1982;24:344.
150. Kon M: Firework injuries to the hand. *Ann Chir Main Memb Supp* 1991;10:443.
151. Kostuik J, Gillespie R, Hall J: Van Ness rotational osteotomy for treatment of proximal femoral focal deficiency and congenital short femur. *J Bone Joint Surg* 1975;57-A:1039.
152. Krajbich I: Proximal femoral focal deficiency. In Kalamchi A (ed): *Congenital Lower Limb Deficiencies*, p 108. New York, Springer-Verlag, 1989.
153. Krajbich I, Bochmann D: Van Ness rotation-plasty in tumor surgery. In Bowker J, Michael J (eds): *Atlas of Limb Prosthetics: Surgical, Prosthetic, and Rehabilitation Principles*, p 885. St. Louis, Mosby—Year Book, 1992.
154. Krajbich JI: Rotationplasty in the management of proximal femoral focal deficiency. In Herring JA, Birch JG (eds): *The Child With a Limb Deficiency*, p 87. Rosemont, IL, American Academy of Orthopaedic Surgeons, 1998.
155. Kritter A: Tibial rotation-plasty for proximal femoral focal deficiency. *J Bone Joint Surg* 1977;59-A:927.
156. Kruger L: Congenital limb deficiencies. Part II. Lower limb deficiencies. In Bowker J, Michael J (eds): *Atlas of Limb Prosthetics: Surgical and Prosthetic Principles*, p 522. St. Louis, CV Mosby, 1981.
157. Kruger L: Lower limb deficiencies. In Bowker J, Michael J (eds): *Atlas of Limb Prosthetics: Surgical, Prosthetic, and Rehabilitation Principles*, p 802. St. Louis, CV Mosby, 1992.
158. Kruger L: The use of stubbies for the child with bilateral lower-limb deficiencies. *J Assoc Child Prosthet Orthot Clin* 1973;12:7.
159. Kruger L, Talbott R: Amputation and prosthesis as definitive treatment in congenital absence of the fibula. *J Bone Joint Surg* 1961;43-A:625.
160. Kruger LM: Congenital limb deficiencies. Section II. Lower limb deficiencies. In Bowker JH, Michael JW (eds): *Atlas of Limb Prosthetics: Surgical, Prosthetic, and Rehabilitation Principles*, 2nd ed, p 522. St. Louis, Mosby—Year Book, 1992.
161. Kruger LM: Fibula deficiencies. In Herring JA, Birch JG (eds): *The Child With a Limb Deficiency*, p 151. Rosemont, IL, American Academy of Orthopaedic Surgeons, 1998.
162. Kruger LM: Recent advances in surgery of lower limb deficiencies. *Clin Orthop* 1980;148:97.
163. Kruger LM, Abdo RB, Schwartz AM: Tibial deficiency: a genetic problem. *J Assoc Child Prosthet Orthot Clin* 1985;20:41.
164. Kurtz AD, Hand RC: Bone growth following amputation in childhood. *Am J Surg* 1939;43:773.
165. Lambert CN: Amputation surgery in the child. *Orthop Clin North Am* 1972;3:473.
166. Laufer E, Nelson CE, Johnson RL, et al: Sonic Hedgehog and FGF-4 act through a signaling cascade and feedback loop to integrate growth and patterning of the developing limb bud. *Cell* 1994;79:993.
167. Lausecker H: Der angeborene Defekt der Ulna. *Virchows Arch Pathol Anat Physiol Klin Med* 1954;325:211.
168. Letts M, Davidson D: Epidemiology and prevention of traumatic amputations in children. In Herring JA, Birch JG (eds): *The Child With a Limb Deficiency*, p 235. Rosemont, IL, American Academy of Orthopaedic Surgeons, 1998.
169. Letts RM: Farm machinery accidents in children. In Dosman JA, Cockcroft DW (eds): *Principles of Health and Safety in Agriculture*, p 357. Boca Raton, FL, CRC Press, 1986.
170. Letts RM, Cleary J: The child and the snowmobile. *Can Med Assoc J* 1975;113:1061.
171. Letts RM, Gammon WA: Auger injuries in children. *Can Med Assoc J* 1978;118:519.
172. Letts RM, Mardirosian A: Lawnmower injuries in children. *Can Med Assoc J* 1977;116:1151.
173. Lie R, Wilcox A, Skjaevren R: A population based study of the risk of recurrence of birth defects. *N Engl J Med* 1994;331:1.
174. Lipson AH, Webster WS, Brown-Woodman PD, et al: Moebius syndrome: animal model-human correlations and evidence for a brainstem vascular etiology. *Teratology* 1989;40:339.
175. Lister GD: Toes to the hand. In Flatt AE (ed): *The Care of Congenital Hand Anomalies*, 2nd ed, p 180. St. Louis, Quality Medical Publishing, 1994.
176. Lloyd-Roberts GC: Treatment of defects of the ulna in children by establishing cross-union with the radius. *J Bone Joint Surg* 1973;55-B:327.
177. Lloyd-Roberts GC, Stone KH: Congenital hypoplasia of the upper femur. *J Bone Joint Surg* 1963;45-B:557.
178. Loder R, Herring J: Fibular transfer for congenital absence of the tibia: a reassessment. *J Pediatr Orthop* 1987;7:8.
179. Loder RT: Fibular transfer for congenital absence of the tibia (Brown procedure). In Herring JA, Birch JG (eds): *The Child With a Limb Deficiency*, p 223. Rosemont, IL, American Academy of Orthopaedic Surgeons, 1998.
180. Loder RT, Herring JA: Disarticulation of the knee in children: a functional assessment. *J Bone Joint Surg* 1987;69-A:1155.
181. Long I: Normal shape-normal alignment (NSNA) above-knee prostheses. *Clin Prosthet Orthot* 1985;9:9.
182. Lovett M, Clines G, Wise CA: Genetic control of limb development. In Herring JA, Birch JG (eds): *The Child With a Limb Deficiency*, p 13. Rosemont, IL, American Academy of Orthopaedic Surgeons, 1998.
183. Mace JW, Kaplan JM, Schanberger JE, et al: Poland's syndrome: report of seven cases and review of the literature. *Clin Pediatr* 1972;11:98.
184. Maffulli N, Fixsen JA: Distraction osteogenesis in congenital limb length discrepancy: a review. *J R Coll Surg Edinb* 1996;41:258.
185. Mahmood R, Bresnick J, Hornbruch A, et al: A role for FGF-8 in the initiation and maintenance of vertebrate limb bud outgrowth. *Curr Biol* 1995;114:755.
186. Marcus NA, Omar GE Jr: Carpal deviation in congenital ulnar deficiency. *J Bone Joint Surg* 1984;66-A:1003.
187. Marquardt E: The multiple limb-deficient child. In Committee on Prosthetics and Orthotics (eds): *Atlas of Limb Prosthesis*, p 595. St. Louis, CV Mosby, 1982.
188. Marquardt E: The multiple limb-deficient child. In Bowker JH, Michael JW (eds): *Atlas of Limb Prosthetics and Rehabilitation Principles*, 2nd ed, p 839. St. Louis, Mosby—Year Book, 1992.
189. Marquardt E, Correll J: Amputations and prostheses for the lower limbs. *Int Orthop* 1984;8:139.
190. Marquardt E, Fisk JR: Thalidomide children: thirty years later. *J Assoc Child Prosthet Orthot Clin* 1992;27:3.
191. Martini AK, Marquardt E: Stump plasty on congenital amputations. *Garyounis Med J* 1980;3(suppl):83.
192. McCoullough N, Trout A, Caldwell J: Non-standard prosthetic applications for juvenile amputations. *J Assoc Child Prosthet Orthot Clin* 1963;2:7.
193. McCredie J: Neural crest defects: a neuroanatomic basis for classification of multiple malformations related to phocomelia. *J Neurol Sci* 1975;28:373.
194. Meyer L, Sauer B: The use of porous high-density polyethylene caps in the prevention of appositional bone growth in the juvenile-amputee: a preliminary report. *J Assoc Child Prosthet Orthot Clin* 1975;14:1.
195. Meyer LC, Sauer BW: Problems of treating and fitting the patient with proximal femoral focal deficiency. *J Assoc Child Prosthet Orthot Clin* 1971;10:1.
196. Michael J: Pediatric prosthetics and orthotics. *Phys Occup Ther Pediatr* 1990;10:123.
197. Michael J: Reflections on CAD/CAM in prosthetics and orthotics. *J Pediatr Orthop* 1989;1:116.

198. Michael JW: Prosthetic knee mechanisms. *Phys Med Rehabil* 1994; 8:147.
199. Miller JK, Wenner SM, Kruger LM: Ulnar deficiency. *J Hand Surg* 1986;11-A:822.
200. Minnes PM, Stack DM: Research and practice with congenital amputees: making the whole greater than the sum of its parts. *Int J Rehabil Res* 1990;13:151.
201. Moll JH: More on the Ertl osteotomy. *Amputee Clin* 1970;2:7.
202. Morton AA: Psychological considerations in the planning of staged reconstruction in limb deficiencies. In Herring JA, Birch JG (eds): *The Child With a Limb Deficiency*, p 195. Rosemont, IL, American Academy of Orthopaedic Surgeons, 1998.
203. Moseley CF: A straight-line graph for leg-length discrepancies. *J Bone Joint Surg* 1977;59-A:174.
204. Moseley CF: A straight line graph for leg length discrepancies. *Clin Orthop* 1978;136:33.
205. Mowery C, Herring J, Jackson D: Dislocated patella associated with below-knee amputation. *J Pediatr Orthop* 1986;6:299.
206. Murray D, Kambouroglou G, Kenwright J: One-stage lengthening for femoral shortening with associated deformity. *J Bone Joint Surg* 1993;75-B:566.
207. Niswander L, Martin GR: FgF-4 and BMP-2 have opposite effects on limb growth. *Nature* 1993;361:68.
208. Oberg K: Knee mechanisms for through-knee prostheses. *Prosthet Orthot Int* 1983;7:107.
209. Ogden JA, Vickers TH, Tauber JE, et al: A model for ulnar dysmelia. *Yale J Biol Med* 1978;51:193.
210. Ogden JA, Watson HK, Bohne W: Ulnar dysmelia. *J Bone Joint Surg* 1996;58-A:467.
211. Ogino T, Kato H: Clinical and experimental studies on ulnar ray deficiency. *Handchir Mikrochir Plast Chir* 1988;20:330.
212. Oglesby DG Jr, Tablada C: Prosthetic and orthotic management. In Bowker JH, Michael JW (eds): *Atlas of Limb Prosthetics: Surgical, Prosthetic, and Rehabilitation Principles*, 2nd ed, p 835. St. Louis, Mosby-Year Book, 1992.
213. Ohuchi H, Nakagawa T, Yamauchi M, et al: An additional limb can be induced from the flank of the chick embryo by FGF-4. *Biochem Biophys Res Commun* 1995;209:809.
214. Oppenheim WL, Setoguchi Y, Fowler E: Overview and comparison of Syme's amputation and knee fusion with the van Ness rotationplasty procedure in proximal femoral focal deficiency. In Herring JA, Birch JG (eds): *The Child With a Limb Deficiency*, p 73. Rosemont, IL, American Academy of Orthopaedic Surgeons, 1998.
215. Paley D: Lengthening reconstruction surgery for congenital femoral deficiency. In Herring JA, Birch JG (eds): *The Child With a Limb Deficiency*, p 113. Rosemont, IL, American Academy of Orthopaedic Surgeons, 1998.
216. Patterson DB, McMillian PM, Rodriguez RP: Acceptance rate of myoelectric prosthesis. *J Assoc Child Prosthet Orthot Clin* 1990;25:73.
217. Pattinson RC, Fixsen JA: Management and outcome in tibial dysplasia. *J Bone Joint Surg* 1992;74-B:893.
218. Patton J: Developmental approach to pediatric prosthetic evaluation and training. In Atkins D, Meier R (eds): *Comprehensive Management of the Upper-Limb Amputee*, p 137. New York, Springer-Verlag, 1989.
219. Paulson JA: The epidemiology of injuries in adolescents. *Pediatr Ann* 1988;17:84.
220. Peterson CA II, Maki S, Wood MB: Clinical results of the one-bone forearm. *J Hand Surg* 1995;20-A:609.
221. Pinzur MS: Knee disarticulation. In Bowker JH, Michael JW (eds): *Atlas of Limb Prosthetics: Surgical, Prosthetic, and Rehabilitation Principles*, 2nd ed, p 479. St. Louis, Mosby-Year Book, 1992.
222. Powars D, Larsen R, Johnson J, et al: Epidemic meningococemia and purpura fulminans with induced protein C deficiency. *Clin Infect Dis* 1993;17:254.
223. Price CT, Noonan KJ: Femoral lengthening with monolateral half-pin devices. In Herring JA, Birch JG (eds): *The Child With a Limb Deficiency*, p 133. Rosemont, IL, American Academy of Orthopaedic Surgeons, 1998.
224. Pritham C: Biomechanics and shape of the above-knee socket considered in light of the ischial containment concept. *Prosthet Orthot Int* 1990;14:9.
225. Quan L, Smith DW: The VATER association: vertebral defects, anal atresia, T-E fistula with esophageal atresia, radial and renal dysplasia: a spectrum of associated defects. *J Pediatr* 1973;82:104.
226. Rab G: Principles of amputation in children. In Chapman M (ed): *Operative Orthopaedics*, p 2469. Philadelphia, JB Lippincott, 1993.
227. Radcliffe C: Functional considerations in the fitting of above knee prostheses. *Orthot Prosthet* 1955;2:35.
228. Radcliffe C: Prosthetics. In Rose J, Gamble J (eds): *Human Walking*, 2nd ed, p 165. Baltimore, Williams & Wilkins, 1994.
229. Reynolds JF, Wyandt HE, Kelly TE: De novo 21q interstitial deletion in a retarded boy with ulno-fibular dysostosis. *Am J Med Genet* 1985;20:173.
230. Richieri-Costa A, Ferrareto I, Masiero D, et al: Tibial hemimelia: report on 37 new cases, clinical and genetic considerations. *Am J Med Genet* 1987;27:867.
231. Riddle RD, Johnson RL, Laufer E, et al: *Sonic hedgehog* mediates the polarizing activity of the ZPA. *Cell* 1993;75:1401.
232. Riordan DC: The upper limb. In Lovell WW, Winter RB (eds): *Pediatric Orthopaedics*, p 685. Philadelphia, JB Lippincott, 1978.
233. Riordan DC, Mills EH, Alldredge RH: Congenital absence of the ulna (abstract). *J Bone Joint Surg* 1961;43-A:614.
234. Rivara FP: Fatal and non-fatal farm injuries to children and adolescents in the United States. *Pediatrics* 1985;76:567.
235. Roberts DJ, Johnson RL, Burke AC, et al: Sonic hedgehog is an endodermal signal inducing *Bmp-4* and *Hox* genes during induction and regionalization of the chick hindgut. *Development* 1995;121:3163.
236. Roessler E, Belloni E, Gaudenz K, et al: Mutations in the human sonic hedgehog gene cause holoprosencephaly. *Nat Genet* 1996;14:357.
237. Romano RL, Burgess EM: Extremity growth and overgrowth following amputations in children. *Interclin Information Bull* 1966;5:11.
238. Rosenfelder R: Infant amputees: early growth and care. *Clin Orthop* 1980;148:41.
239. Roskies E: *Abnormality and Normality: The Mothering of Thalidomide Children*. Ithaca, NY, Cornell University Press, 1972.
240. Rougraff BT, Simon MA, Kneisl JS, et al: Limb salvage compared with amputation for osteosarcoma of the distal end of the femur: a long-term oncological, functional, and quality-of-life study. *J Bone Joint Surg* 1994;76-A:649.
241. Russell JE: Tibial hemimelia: limb deficiency in siblings. *Interclin Information Bull* 1965;14:15.
242. Sabolich J: Contoured adducted trochanteric-controlled alignment method. *Clin Prosthet Orthot* 1985;9:15.
243. Sadler TW: Embryology and gene regulation of limb development. In Herring JA, Birch JG (eds): *The Child With a Limb Deficiency*, p 3. Rosemont, IL, American Academy of Orthopaedic Surgeons, 1998.
244. Saleh M, Hamer AJ: Bifocal limb lengthening: a preliminary report. *J Pediatr Orthop* 1993;2-B:42.
245. Sanders G: Static and dynamic analysis. In Sanders G (ed): *Lower Limb Amputations: A Guide to Rehabilitation*, p 415. Philadelphia, FA Davis Co, 1986.
246. Saunders JW Jr: The proximo-distal sequence of origin of the parts of the chick wing and the role of the ectoderm. *J Exp Zool* 1948;108:363.
247. Saunders JW Jr, Gasseling MT: Ectodermal-mesenchymal interactions in the origin of limb symmetry. In Fleischmajer R, Billingham RE (eds): *Epithelial-Mesenchymal Interactions*, p 78. Baltimore, Williams & Wilkins, 1968.
248. Schneider K, Hart T, Zernicke RF, et al: Dynamics of below-knee child amputee gait: SACH foot versus flex foot. *J Biomech* 1993;26:1191.
249. Schoenecker PL: Tibial deficiency. In Herring JA, Birch JG (eds): *The Child With a Limb Deficiency*, p 209. Rosemont, IL, American Academy of Orthopaedic Surgeons, 1998.
250. Schoenecker PL, Capelli AM, Millar EA, et al: Congenital longitudinal deficiency of the tibia. *J Bone Joint Surg* 1989;71-A:278.
251. Schuch CM: Modern above-knee fitting practice. *Prosthet Orthot Int* 1988;12:77.
252. Schuch CM: Prosthetic principles in fitting myoelectric prostheses in children. In Herring JA, Birch JG (eds): *The Child With a Limb Deficiency*, p 405. Rosemont, IL, American Academy of Orthopaedic Surgeons, 1998.
253. Schuch CM: Transfemoral amputation: prosthetic management. In Bowker J, Michael J (eds): *Atlas of Limb Prosthetics*, p 509. St. Louis, Mosby-Year Book, 1992.
254. Setoguchi Y: Medical conditions associated with congenital limb deficiencies. In Herring JA, Birch JG (eds): *The Child With a Limb Deficiency*, p 51. Rosemont, IL, American Academy of Orthopaedic Surgeons, 1998.
255. Shapiro MJ, Luchtefeld WB, Durham RM, et al: Traumatic train injuries. *Am J Emerg Med* 1994;12:92.



256. Shubin T, Tabin C, Carroll S: Fossils, genes and the evolution of animal limbs. *Nature* 1997;276:81.
257. Silcox D, Rooks M, Vogel R, et al: Myoelectrical prostheses. *J Bone Joint Surg* 1993;75-A:1781.
258. Simmons ED Jr, Ginsburg GM, Hall JE: Brown's procedure for congenital absence of the tibia revisited. *J Pediatr Orthop* 1996;16:85.
259. Simon MA, Aschiliman MA, Thomas N, et al: Limb-salvage treatment versus amputation for osteosarcoma of the distal end of the femur. *J Bone Joint Surg* 1986;68-A:1331.
260. Simpson AH, Cunningham JL, Kenwright J: The forces which develop in the tissues during leg lengthening: a clinical study. *J Bone Joint Surg* 1996;78-B:979.
261. Simpson AH, Williams PE, Kyberd P, et al: The response of muscle to leg lengthening. *J Bone Joint Surg* 1995;77-B:630.
262. Smith AA, Greene TL: Preliminary soft tissue distraction in congenital forearm deficiency. *J Hand Surg* 1995;20A:420.
263. Smith D: *Recognizable Patterns of Human Malformation*. Philadelphia, WB Saunders Co, 1994.
264. Southwood AR: Partial absence of the ulnar and associated structures. *J Anat* 1927;61:346.
265. Speer D: The pathogenesis of amputation stump overgrowth. *Clin Orthop* 1981;159:34.
266. Spinner M, Freundlich BD, Abeles ED: Management of moderate longitudinal arrest of development of the ulna. *Clin Orthop* 1970;69:199.
267. St. Charles S, DiMario FJ Jr, Grunnet ML: Mobius sequence: further in vivo support of the subclavian artery disruption sequence. *Am J Med Genet* 1993;47:289.
268. Stanitski DF: The effect of limb lengthening on articular cartilage: an experimental study. *Clin Orthop* 1994;301:68.
269. Stanitski DF, Rossman K, Torosian M: The effect of femoral lengthening on knee articular cartilage: the role of apparatus extension across the joint. *J Pediatr Orthop* 1996;16:151.
270. Steel HH: Iliofemoral fusion for proximal femoral focal deficiency. In Herring JA, Birch JG (eds): *The Child With a Limb Deficiency*, p 103. Rosemont, IL, American Academy of Orthopaedic Surgeons, 1998.
271. Steel HH, Lin P, Betz R, et al: Iliofemoral fusion for proximal femoral focal deficiency. *J Bone Joint Surg* 1987;69-A:837.
272. Stephens TD, Spall R, Baker WC, et al: Axial and paraxial influences on limb morphogenesis. *J Morphol* 1991;208:367.
273. Stover E, Keller AS, Cobey J, et al: The medical and social consequences of land mines in Cambodia. *JAMA* 1994;272:331.
274. Stucky W, Loder RT: Extremity gunshot wounds in children. *J Pediatr Orthop* 1991;11:64.
275. Stueland D, Layde P, Lee BC: Agricultural injuries in children in central Wisconsin. *J Trauma* 1991;31:1503.
276. Summerbell D: A quantitative analysis of the effect of excision of the AER from the chick limb-bud. *J Embryol Exp Morphol* 1974;32:651.
277. Summerbell D: The zone of polarizing activity: evidence for a role in normal chick limb morphogenesis. *J Embryol Exp Morphol* 1979;50:217.
278. Swanson AB: Bone overgrowth in the juvenile amputee and its control by the use of silicone rubber implants. *J Assoc Child Prosthet Orthot Clin* 1969;8:9.
279. Swanson AB: A classification for congenital limb malformations. *J Hand Surg* 1976;1-A:8.
280. Swanson AB: The Krukenberg procedure in the juvenile amputee. *J Bone Joint Surg* 1964;46-B:1540.
281. Tablada C: A technique for fitting converted proximal femoral focal deficiencies. *Artif Limbs* 1971;15:27.
282. Talbot D, Solomon D: The function of a parent group in the adaptation to the birth of a limb-deficient child. *Interclin Information Bull* 1979;17:9.
283. Temtamy S, McKusick VA, Bergsma D, et al: *The Genetics of Hand Malformations*, p 48. New York, Alan R Liss, 1978.
284. Thompson G, Leimkuller J: Prosthetic management. In Kalamchi A (ed): *Congenital Lower Limb Deficiencies*, p 210. New York, Springer-Verlag, 1989.
285. Thompson GH, Balourdas GM, Marcus RE: Railyard amputations in children. *J Pediatr Orthop* 1983;3:443.
286. Tickle C, Summerbell D, Wolpert L: Positional signaling and specification of digits in chick limb morphogenesis. *Nature* 1975;254:199.
287. Tooms R: Acquired amputations in children. In Bowker J, Michael J (eds): *Atlas of Limb Prosthetics: Surgical, Prosthetic, and Rehabilitation Principles*, p 735. St. Louis, Mosby-Year Book, 1992.
288. Torode I, Gillespie R: Rotationplasty of the lower limb for congenital defects of the femur. *J Bone Joint Surg* 1983;65-B:569.
289. van Ness CP: Rotation-plasty for congenital defects of the femur: making use of the ankle of the shortened limb to control the knee joint of a prosthesis. *J Bone Joint Surg* 1950;32-B:12.
290. Varni JW, Rubinfeld LA, Talbot D, et al: Determinants of self-esteem in children with congenital/acquired limb deficiencies. *J Dev Behav Pediatr* 1989;10:13.
291. Varni JW, Setoguichi Y: Correlates of perceived physical appearance in children with congenital/acquired limb deficiencies. *J Dev Behav Pediatr* 1991;12:171.
292. Varni JW, Setoguichi Y: Perceived physical appearance and adjustment of adolescent with congenital/acquired limb deficiencies: a path-analytic model. *J Clin Child Psychol* 1996;25:201.
293. Varni JW, Setoguichi Y: Psychological factors in the management of children with limb deficiencies. *Phys Med Rehabil Clin North Am* 1991;2:395.
294. Varni JW, Setoguichi Y: Screening for behavioral and emotional problems in children and adolescents with congenital or acquired limb deficiencies. *Am J Dis Child* 1992;146:103.
295. Varni JW, Setoguichi Y: Self-perceived physical appearance in children and adolescents with congenital/acquired limb deficiencies. *J Assoc Child Prosthet Orthop Clin* 1991;26:56.
296. Varni JW, Setoguichi Y, Rappaport LR, et al: Effects of stress, social support, and self-esteem on depression in children with limb deficiencies. *Arch Phys Med Rehabil* 1991;72:1053.
297. Velasquez R, Bell D, Armstrong P, et al: Complications of the use of the Ilizarov technique in the correction of limb deformities in children. *J Bone Joint Surg* 1993;75-A:1148.
298. Vilkki SK: Advances in microsurgical reconstruction of the congenitally adactylous hand. *Clin Orthop* 1995;314:45.
299. Vilkki SK: Distraction and microvascular epiphysis transfer for radial club hand. *J Hand Surg* 1998;23-B:445.
300. Vilkki SK: Vascularized joint transfer for radial club hand. *Techn Hand Upper Extremity Surg* 1998;2:126.
301. Vitale CC: Reconstructive surgery for defects in the shaft of the ulna in children. *J Bone Joint Surg* 1952;34-A:804.
302. Vogel A, Rodriguez C, Izpisua-Belmonte JC: Involvement of FGF-8 in initiation, outgrowth and patterning of the vertebrate limb. *Development* 1996;122:1737.
303. von Ertl JW: The care of amputation stumps by osteomyeloplastic according to v Ertl. *Z Plast Chir* 1981;5:184.
304. Vortkamp A, Lee K, Lanske B, et al: Regulation of rate of cartilage differentiation by Indian hedgehog and PTH-related protein. *Science* 1996;273:613.
305. Wanek N, Gardiner DM, Muneoka K, et al: Conversion by retinoic acid of anterior cells into ZPA cells in the chick wing bud. *Nature* 1991;350:81.
306. Wang EA, Rosen V, D'Alessandro JS, et al: Recombinant human bone morphogenetic protein induces bone formation. *Proc Natl Acad Sci USA* 1990;87:2220.
307. Wang G-J, Baugher VM, Stamp WG: Epiphyseal transplant in amputations: effects on overgrowth in a rabbit model. *Clin Orthop* 1978;130:285.
308. Waters RL, Perry J, Antonelli D, et al: Energy cost of walking of amputees: the influence of level of amputation. *J Bone Joint Surg* 1976;58-A:42.
309. Watson HK, Bohne WH: The role of the fibrous band in ulnar deficient extremities (abstract). *J Bone Joint Surg* 1971;53-A:816.
310. Watts HG: Lengthening of short residual limbs in children. In Herring JA, Birch JG (eds): *The Child With a Limb Deficiency*, p 281. Rosemont, IL, American Academy of Orthopaedic Surgeons, 1998.
311. Weaver DD: Vascular etiology of limb defects: the subclavian artery supply disruption sequence. In Herring JA, Birch JG (eds): *The Child With a Limb Deficiency*, p 25. Rosemont, IL, American Academy of Orthopaedic Surgeons, 1998.
312. Weaver S: Comparison of myoelectric and conventional prostheses for adolescent amputees. *Am J Occup Ther* 1988;42:78.
313. Webster WS, Lipson AH, Brown-Woodman PD: Uterine trauma and limb defects. *Teratology* 1987;35:253.
314. Westin GW, Gunderson GO: Proximal femoral focal deficiency: a

- review of treatment experiences. In Aitken GT (ed): *A Symposium on Proximal Femoral Focal Deficiency: A Congenital Anomaly*, p 100. Washington, DC, National Academy of Sciences, 1969.
315. Wilson GN: Heritable limb deficiencies. In Herring JA, Birch JG (eds): *The Child With a Limb Deficiency*, p 39. Rosemont, IL, American Academy of Orthopaedic Surgeons, 1998.
316. Wood WL, Zlotsky N, Westin G: Congenital absence of the fibula: treatment by Syme amputation. Indications and technique. *J Bone Joint Surg* 1965;47-A:1159.
317. Yokouchi Y, Sasaki H, Kuroiwa A: Homeobox gene expression correlated with the bifurcation process of limb cartilage development. *Nature* 1991;353:443.
318. Younge D, Dafniotis O: A composite bone flap to lengthen a below-knee amputation stump. *J Bone Joint Surg* 1993;75-B:330.
319. Zalesky DJ: Biology of epiphyseal transplantation. In Friedlaender GE, Goldberg VM (eds): *Bone and Cartilage Allografts: Biology and Clinical Applications*, p 27. Park Ridge, IL, American Academy of Orthopaedic Surgeons, 1991.
320. Zwilling E: Ectoderm: mesoderm relationship in the development of the chick embryo limb bud. *J Exp Zool* 1955;128:423.