

# Metabolic and Endocrine Bone Diseases

General Pathophysiology, 1685	Hypervitaminosis D, 1704
Nutritional Rickets, 1686	Scurvy, 1705
Rickets of Prematurity, 1690	Hypervitaminosis A, 1707
Drug-Induced Rickets, 1690	Hypophosphatasia, 1708
Vitamin D-Resistant Rickets, 1690	Hyperphosphatasia, 1711
Tumor-Related Hypophosphatemic Rickets, 1695	Pituitary Dwarfism, 1711
Renal Osteodystrophy, 1696	Hypothyroidism, 1712
Primary Hyperparathyroidism, 1701	Idiopathic Juvenile Osteoporosis, 1715
Idiopathic Hypoparathyroidism, 1702	Osteogenesis Imperfecta, 1717
Pseudohypoparathyroidism, 1703	

## General Pathophysiology

Metabolic bone disease is caused by disturbances in the metabolism of calcium and phosphate. The result is inadequate mineralization of bone matrix. In children, the epiphyseal ends of the bones are the most active in osteogenesis, so the disease is more evident there. A complete understanding of calcium metabolism is needed to understand this group of disorders.<sup>5</sup>

The body is extremely sensitive to serum calcium levels, and a disturbance of calcium balance leads to abnormal irritability, conductivity, and contractility of the cardiovascular and neurologic systems. Almost all of the body's calcium is stored in bone as hydroxyapatite; thus, if extra calcium is needed in the bloodstream to maintain cardiac or neurologic function, the bone is the source of the required calcium. Only a very small portion of the body's calcium is present in the bloodstream.

Serum calcium is under the regulation of vitamin D and parathyroid hormone (PTH) (Fig. 31-1).<sup>1-4,6</sup> Ergosterol (provitamin D) is ingested and absorbed from the small intestine. These precursors of vitamin D must be absorbed from the gut. Because they are fat-soluble, gastrointestinal (GI) or hepatic diseases that produce steatorrhea result in the inability to absorb vitamin D. Provitamin D then undergoes a series of hydroxylations in its transformation to the active form, 1,25-dihydroxyvitamin D. The first hydroxylation takes place in the liver. The second hydroxylation, which occurs in the kidney, is stimulated by hypocalcemia and high levels of PTH. The liver also produces 7-dehydrocholesterol (also a provitamin D). Thus, hepatic or renal diseases lead to problems with metabolic bone diseases.

The skin also plays a role in metabolic bone diseases, as it is the site of conversion of 7-dehydrocholesterol to vitamin D<sub>3</sub> (cholecalciferol). This change occurs as a result of exposure to ultraviolet light.

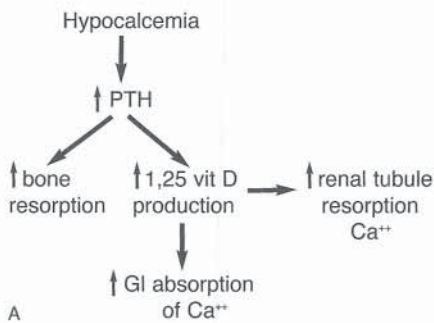
The action of 1,25-dihydroxycholecalciferol is to enable absorption of calcium from the small intestine.<sup>7</sup> In a state of vitamin D deficiency, deficient absorption of calcium leads to mild hypocalcemia, which triggers the release of PTH. PTH enables absorption of calcium from the intestines and renal tubules, and activates osteoclasts.<sup>8</sup> Calcium is leached out of the bones, and the hypocalcemia is relatively corrected; however phosphate is excreted from the kidney, leading to hypophosphatemia and poor mineralization of bones.

## REFERENCES

### General Pathophysiology

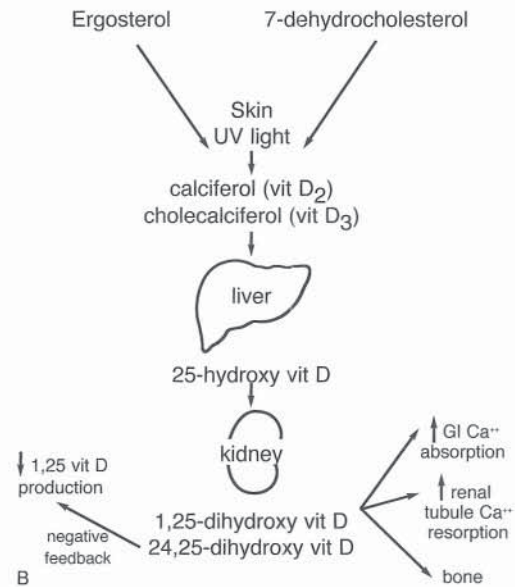
1. Boden SD, Kaplan FS: Calcium homeostasis. *Orthop Clin North Am* 1990;21:31.
2. De Luca HF: Vitamin D: new horizons. *Clin Orthop* 1971;78:4.
3. De Luca HF: The vitamin D system: a view from basic science to the clinic. *Clin Biochem* 1981;14:213.
4. Kanis JA: Vitamin D metabolism and its clinical application. *J Bone Joint Surg* 1982;64-B:542.
5. Mankin HJ: Metabolic bone disease. *Instr Course Lect* 1995;44:3.
6. Norman AW: Recent studies on vitamin D and parathyroid hormone regulation of calcium and phosphorus metabolism. *Clin Orthop* 1967;52:249.
7. Norman ME: Vitamin D in bone disease. *Pediatr Clin North Am* 1982;29:947.
8. Vaes G: Cellular biology and biochemical mechanism of bone resorption: a review of recent developments on the formation, activation, and mode of action of osteoclasts. *Clin Orthop* 1988;231:239.

## Metabolic Control of Calcium Metabolism



A

## Vitamin-D Metabolism



B

FIGURE 31-1 A, Metabolic control of calcium metabolism. B, Vitamin D metabolism.

## Nutritional Rickets

Vitamin D deficiency in the diet leads to nutritional rickets. Although this entity is rare in developed countries, it is by no means absent from these areas.<sup>1,30</sup> The dysplasia may result from prolonged breast-feeding, and occurs more frequently in children fed a vegetarian diet and in black children.<sup>3,4,8,11,27</sup> In the developed world, rickets is more commonly the result of inability to absorb vitamin D due to celiac or hepatic disease.<sup>7,10,16,17</sup> Children with either form of rickets usually present between the ages of 6 months and 3 years. Presenting findings are listlessness, periarticular swelling, or angular deformities.

Mellanby<sup>15</sup> and Park<sup>20</sup> in the mid-1920s were the first to suggest that rickets could be prevented by adequate vitamin D intake. Since that time, milk and dairy products have been fortified with vitamin D. Thus, it is only in cases of malnutrition and unusual dietary practices that vitamin D deficiency rickets is seen.

## PATHOLOGY

In rickets, the primary disturbance in bone is a failure of calcification of cartilage and osteoid tissue.<sup>9,14,19,21,33</sup> Normally the cartilage cells at the provisional zone of calcification proliferate in columns, the most mature of which are calcified, resorbed, and replaced by new bone. In rickets, there is a failure of deposition of calcium along the mature cartilage cell columns, followed by disorderly invasion of cartilage by blood vessels, lack of reabsorption at the zone of provisional calcification, and increased thickness of the epiphyseal plate (Fig. 31-2). The chondrocytes multiply normally, but the normal process of maturation of cartilage columns fails to take place.

Osteoblastic activity in both the endosteal and periosteal

tissues is normal, forming abundant osteoid. With defective mineralization, however, osteoclastic resorption of the uncalcified osteoid does not take place. Hence, the overly abundant osteoid produced by the normal osteoblasts is laid down irregularly around anything that will serve as a scaffolding. There are widened osteoid seams. The osteoid islets may even persist down into the diaphysis.

In rickets, there is an abnormality in the arrangement of

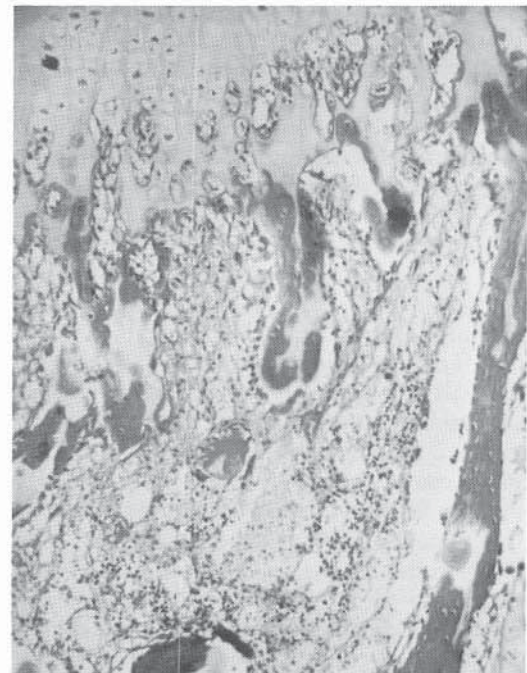


FIGURE 31-2 Histologic appearance of rickets. Photomicrograph through the epiphyseal-metaphyseal junction shows uncalcified osteoid tissue, failure of deposition of calcium along the mature cartilage cell columns, and disorderly invasion of cartilage by blood vessels (×25).

**Biochemical Abnormalities in Rickets**

	Ca	Phos	Alk Phos	PTH	25 (OH) Vit D	1,25 (OH) <sub>2</sub> Vit D
<b>Nutritional</b>	NI-↓	NI-↓	↑	↑	↓↓	↓
<b>Vit D Resistant</b> (XLH, RTA, Fanconi, Oncogenic rickets)	NI	↓	↑	NI	NI	NI
<b>Vit D Dependent Type I</b> (inability to hydroxylate)	↓	↓	↑	↑	↑↑	↓↓
<b>Vit D Dependent Type II</b> (receptor insensitivity)	↓	↓	↑	↑	NI-↑↑	↑↑↑↑
<b>Renal Osteodystrophy</b>	NI-↓	↑	↑	↑↑	NI	↓↓

FIGURE 31-3 Biochemical abnormalities in rickets.

bundles of collagen fibers in compact bone. Instead of running parallel to the haversian canals, they course perpendicularly and are biomechanically inferior.<sup>5</sup>

Grossly, the rachitic bone is soft and becomes misshapen under the forces of weightbearing. If the disease remains untreated, angular deformities of the lower extremities

and deformities of the thoracic cage and pelvis may develop.

After treatment of rickets with vitamin D, calcium absorption increases and calcification of the cartilage columns and of osteoid occurs. Osteoclasts resorb the calcified cartilage, and remodeling of bone follows.<sup>2</sup>

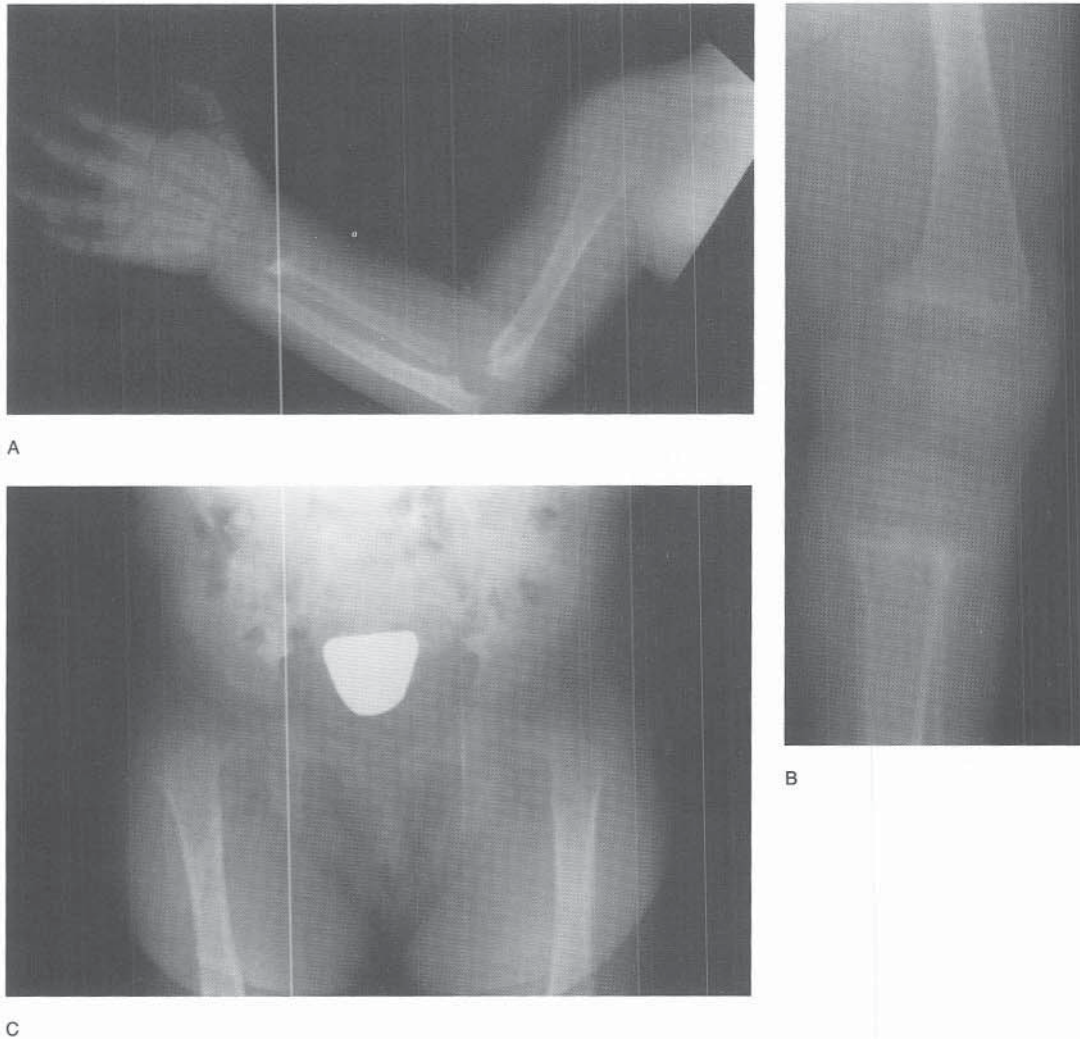
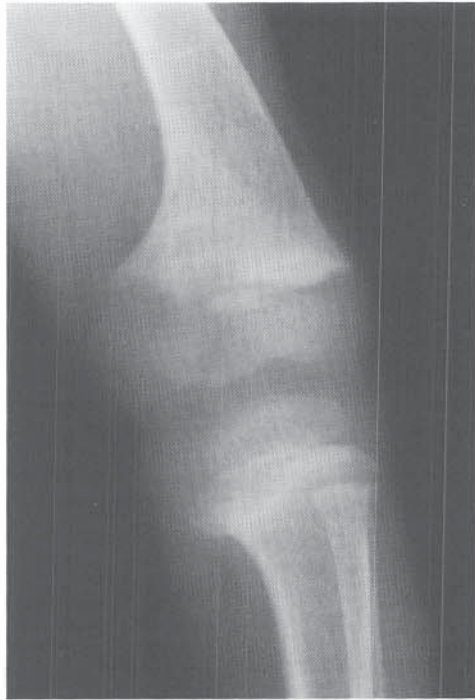
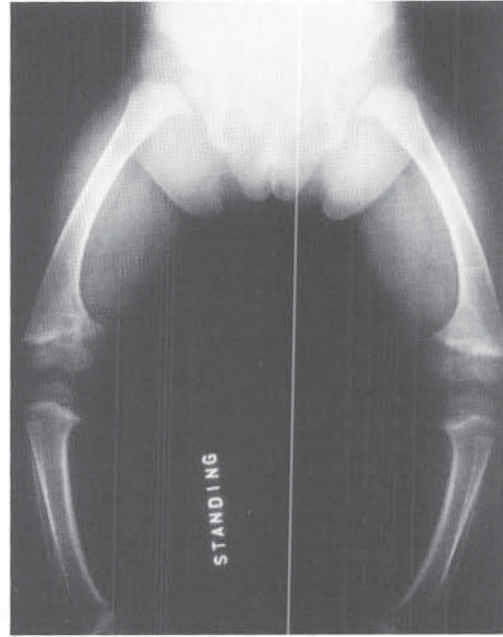


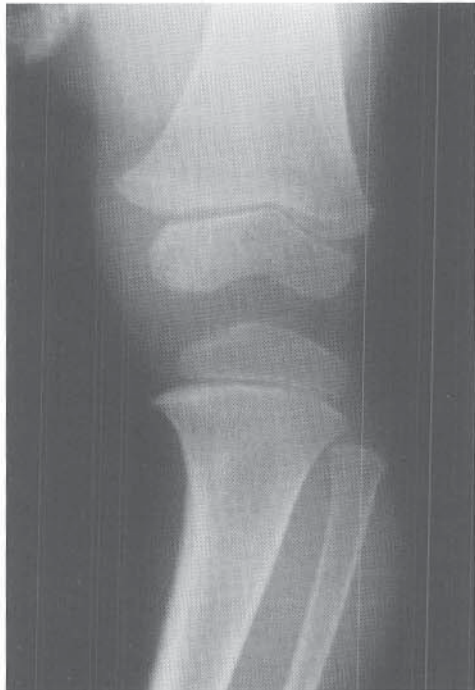
FIGURE 31-4 A to C, Radiographs obtained in a 1-year-old black girl with nutritional rickets. All physes are widened and the metaphyses are indistinct. Cupping is most prominent in the metaphysis of the distal radius and ulna and at the knee. See also Figure 31-6.



A



B



C

FIGURE 31-5 A, Hazy metaphysis with cupping in a young boy with rickets. B, Accentuated genu varum is present. C, With vitamin D replacement therapy, the bony lesions healed in 6 months.

### LABORATORY FINDINGS

Vitamin D deficiency results in inability to absorb calcium and phosphorus. PTH is released in response to hypocalcemia, which corrects the serum calcium deficit, but hypophosphatemia persists. Serum calcium levels are normal to mildly decreased, phosphate levels are low, and vitamin D levels are decreased, but PTH and alkaline phosphatase levels are high (Fig. 31-3).<sup>6,13,18,24</sup>

### CLINICAL FEATURES

The clinical features of nutritional rickets depend on the severity of the disease and may be quite subtle. Infants present with generalized muscular weakness, lethargy, and irritability.<sup>29</sup> Sitting, standing, and walking are delayed. The abdomen may appear protuberant.

Early bony manifestations include a slight thickening of the ankles, knees, and wrists. Beading of the ribs, referred

to as the “rachitic rosary,” is due to enlargement of the costochondral junctions. As the disease continues, the pull of the diaphragm on the ribs produces a horizontal depression known as Harrison’s groove. Short stature results from insufficient longitudinal growth. Pectus carinatum is caused by forward projection of the sternum. Closure of the fontanelles is delayed and the sutures are thickened, leading to a skull appearance described as resembling hot cross buns. The dentition is affected, with delays in the appearance of the teeth and defects in the enamel.

As the child begins standing and walking, the softened long bones bow, and it is at this time that the child is usually brought to the orthopaedic surgeon for a diagnosis. Genu valgum and coxa vara may result from the bowing. Stress fractures of the long bones may be present.<sup>22</sup> Later, kyphoscoliosis may develop.

### RADIOGRAPHIC FINDINGS

Failure of the physal cartilage to calcify leads to elongation of the physis and a hazy appearance of the provisional zone of calcification.<sup>23,35,36</sup> The widened growth plate is particularly suspect for rickets, differentiating this rare condition from the more common physiologic angular deformities of the lower extremities (Fig. 31–4).<sup>12</sup> The metaphysis abutting the physis is brushlike in appearance, as islands or columns of cartilage persist well into the metaphysis (Fig. 31–5). The metaphysis also appears cupped or flared. There is an osteopenic appearance to the bones overall, with thinning of the cortices.<sup>26</sup> The bony trabeculae are indistinct. Looser’s lines, radiolucent transverse bands that extend across the

axes of the long bones, are evident on radiographs in 20 percent of patients with rickets.<sup>34</sup>

As the rickets continues, deformities of the long bones, ribs, pelvis, and spine develop. Thoracolumbar kyphosis—“rachitic catback”—may be apparent on radiographs.

Although the diagnosis of nutritional rickets should be made on review of plain films, bone scintigraphy has been used in neonates to confirm the diagnosis and to pick up areas of fractures. Increased uptake is seen.<sup>28</sup>

With treatment, calcification occurs and the radiographs become normal. The physis thins and bone density increases (Fig. 31–6).<sup>31,32</sup>

### TREATMENT

Rickets is treated by the administration of vitamin D under the supervision of a pediatric specialist in metabolic bone disease. The usual course of treatment is 6 to 10 weeks. After 2 to 4 weeks, radiographs show improvement in mineralization. Tetracycline labeling shows response to therapy, with new mineralization picking up the drug. (Tetracycline should not be used in young children, however, due to staining of the teeth.<sup>25</sup>) If the child does not respond to vitamin D therapy, vitamin D-resistant rickets should be suspected. Because residual deformity is quite rare following the medical treatment of nutritional rickets, there is no specific orthopaedic treatment for nutritional rickets.

### REFERENCES

#### Nutritional Rickets

- Bachrach S, Fisher J, Parks JS: An outbreak of vitamin D deficiency rickets in a susceptible population. *Pediatrics* 1979;64:871.
- Baillie JM, Irving JT: Development and healing of rickets in intramembranous bone. *Acta Med Scand* 1955;306.
- Curtis JA, Kooh SW, Fraser D, et al: Nutritional rickets in vegetarian children. *Can Med Assoc J* 1983;128:150.
- Dwyer JT, Dietz WH Jr, Hass G, et al: Risk of nutritional rickets among vegetarian children. *Am J Dis Child* 1979;133:134.
- Engfeldt B, Zetterstrom R: Biophysical studies of the bone tissue of dogs with experimental rickets. *Biophysical studies of bone tissue, No. II. Arch Pathol* 1955;59:321.
- Goldsmith RS: Laboratory aids in the diagnosis of metabolic bone diseases. *Orthop Clin North Am* 1972;3:545.
- Heubi JE, Tsang RC, Steichen JJ, et al: 1,25-Dihydroxyvitamin D<sub>3</sub> in childhood hepatic osteodystrophy. *J Pediatr* 1979;94:977.
- Jacobsen ST, Hull CK, Crawford AH: Nutritional rickets. *J Pediatr Orthop* 1986;6:713.
- Jaworski ZF: Pathophysiology, diagnosis and treatment of osteomalacia. *Orthop Clin North Am* 1972;3:623.
- Kooh SW, Jones G, Reilly BJ, et al: Pathogenesis of rickets in chronic hepatobiliary disease in children. *J Pediatr* 1979;94:870.
- Kruger DM, Lyne ED, Kleerekoper M: Vitamin D deficiency rickets: a report on three cases. *Clin Orthop* 1987;224:277.
- Mankin HJ: Metabolic bone disease. *Instr Course Lect* 1995;44:3.
- Mankin HJ: Rickets, osteomalacia, and renal osteodystrophy. Part II. *J Bone Joint Surg* 1974;56-A:352.
- Marie PJ, Pettifor JM, Ross FP, et al: Histological osteomalacia due to dietary calcium deficiency in children. *N Engl J Med* 1982;307:584.
- Mellanby E: Experimental rickets: the effect of cereals and their interaction with other factors of diet and environment in producing rickets. *Spec Rep Ser Med Res Council (London)* 1925;93:48.
- Moss AJ, Waterhouse C, Terry R: Gluten-sensitive enteropathy with osteomalacia without steatorrhea. *N Engl J Med* 1965;272:825.
- Nordin BEC: Effect of malabsorption syndrome on calcium metabolism. *Proc R Soc Med* 1961;54:497.
- Norman AW: Recent studies on vitamin D and parathyroid hormone

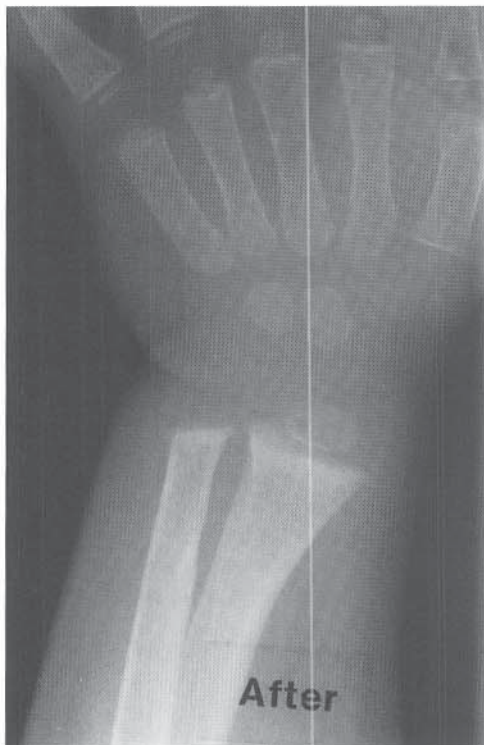

FIGURE 31–6 Radiographic appearance of the wrist of the girl whose radiographs (rickets) appear in Figure 31–4, after 4 months of treatment with vitamin D. The osteopenia has resolved and the physis is narrowed.

- regulation of calcium and phosphorus metabolism. *Clin Orthop* 1967;52:249.
19. Oppenheimer SJ, Snodgrass GJ: Neonatal rickets: histopathology and quantitative bone changes. *Arch Dis Child* 1980;55:945.
  20. Park EA: The etiology of rickets. *Physiol Rev* 1923;3:106.
  21. Park EA: Observations on the pathology of rickets with particular reference to the changes at the cartilage-shaft junction of the growing bones. *Harvey Lect* 1938-39;34:157.
  22. Paterson CR: Vitamin D deficiency rickets simulating child abuse. *J Pediatr Orthop* 1981;1:423.
  23. Pitt MJ: Rachitic and osteomalacic syndromes. *Radiol Clin North Am* 1981;19:581.
  24. Raghuramulu N, Reddy V: Serum 25-hydroxy-vitamin D levels in malnourished children with rickets. *Arch Dis Child* 1980;55:285.
  25. Raubenheimer EJ, Van Heerden WF, Potgieter D, et al: Static and dynamic bone changes in hospitalized patients suffering from rickets: a histomorphometric study. *Histopathology* 1997;31:12.
  26. Reynolds WA, Karo JJ: Radiologic diagnosis of metabolic bone disease. *Orthop Clin North Am* 1972;3:521.
  27. Rudolf M, Arulanantham K, Greenstein RM: Unsuspected nutritional rickets. *Pediatrics* 1980;66:72.
  28. Saul PD, Lloyd DJ, Smith FW: The role of bone scanning in neonatal rickets. *Pediatr Radiol* 1983;13:89.
  29. Schott GD, Wills MR: Muscle weakness in osteomalacia. *Lancet* 1976;1:626.
  30. Sills IN, Skuza KA, Horlick MN, et al: Vitamin D deficiency rickets: reports of its demise are exaggerated. *Clin Pediatr (Phila)* 1994;33:491.
  31. Simmons DJ, Kunin AS: Development and healing of rickets in rats. I. Studies with tritiated thymidine and nutritional considerations. *Clin Orthop* 1970;68:251.
  32. Simmons DJ, Kunin AS: Development and healing of rickets in rats. II. Studies with tritiated proline. *Clin Orthop* 1970;68:261.
  33. Smith R: The pathophysiology and management of rickets. *Orthop Clin North Am* 1972;3:601.
  34. Steinbach HL, Kolb FO, Gilfillan R: Mechanism and production of pseudofractures in osteomalacia (milkman's syndrome). *Radiology* 1954;62:388.
  35. Steinbach HL, Noetzli M: Roentgen appearance of the skeleton in osteomalacia and rickets. *AJR Am J Roentgenol* 1964;91:955.
  36. Swischuk LE, Hayden CK Jr: Rickets: a roentgenographic scheme for diagnosis. *Pediatr Radiol* 1979;8:203.

## Rickets of Prematurity

Very premature infants are particularly at risk for the development of nutritional rickets.<sup>1,2,4,6</sup> Risk factors include hepatobiliary disease, total parenteral nutrition, diuretic therapy, physical therapy with passive motion, and chest percussion therapy. These infants are seen with pathologic fractures in the neonatal intensive care unit. With treatment of the rickets, the fractures heal readily with minimal other treatment.<sup>3</sup> Resolution of the rachitic changes and fractures occurs as the infants gain weight.<sup>5</sup>

### REFERENCES

#### Rickets of Prematurity

1. Bosley AR, Verrier-Jones ER, Campbell MJ: Aetiological factors in rickets of prematurity. *Arch Dis Child* 1980;55:683.
2. Callenbach JC, Sheehan MB, Abramson SJ, et al: Etiologic factors in rickets of very low-birth-weight infants. *J Pediatr* 1981;98:800.
3. Dabezies EJ, Warren PD: Fractures in very low birth weight infants with rickets. *Clin Orthop* 1997;233.
4. Geftter WB, Epstein DM, Anday EK, et al: Rickets presenting as multiple fractures in premature infants on hyperalimentation. *Radiology* 1982;142:371.
5. Koo WW, Sherman R, Succop P, et al: Fractures and rickets in very low birth weight infants: conservative management and outcome. *J Pediatr Orthop* 1989;9:326.

6. Oppenheimer SJ, Snodgrass GJ: Neonatal rickets: histopathology and quantitative bone changes. *Arch Dis Child* 1980;55:945.

## Drug-Induced Rickets

Certain antiepileptic medications have been known to produce rachitic changes in children.<sup>1,2,5</sup> Seizure medications that affect the liver may induce the P450 microsomal enzyme system and decrease the levels of vitamin D. Hypocalcemia develops, which can aggravate the seizure disorder. Treatment with vitamin D is very helpful. The condition should be suspected in neurologic patients with seizures who begin sustaining frequent fractures.<sup>3,4</sup>

### REFERENCES

#### Drug-Induced Rickets

1. Aponte CJ, Petrelli MP: Anticonvulsants and vitamin D metabolism. *JAMA* 1973;225:1248.
2. Crosley CJ, Chee C, Berman PH: Rickets associated with long-term anticonvulsant therapy in a pediatric outpatient population. *Pediatrics* 1975;56:52.
3. Lee JJ, Lyne ED: Pathologic fractures in severely handicapped children and young adults. *J Pediatr Orthop* 1990;10:497.
4. Lee JJ, Lyne ED, Kleerekoper M, et al: Disorders of bone metabolism in severely handicapped children and young adults. *Clin Orthop* 1989;297.
5. Morijiri Y, Sato T: Factors causing rickets in institutionalised handicapped children on anticonvulsant therapy. *Arch Dis Child* 1981;56:446.

## Vitamin D-Resistant Rickets

Vitamin D-resistant rickets, also known as familial hypophosphatemic rickets, encompasses a group of disorders in which normal dietary intake of vitamin D is insufficient to achieve normal mineralization of bone.<sup>30</sup> There are four major forms, but the most common is inherited as an X-linked dominant trait, followed in frequency by an autosomal dominant type.<sup>5,30,32</sup>

The inherent abnormality in familial vitamin D-resistant rickets is the renal tubule's inability to retain phosphate, leading to phosphate diabetes and hypophosphatemia.<sup>20</sup> End-organ insensitivity to vitamin D is the cause of autosomal recessive vitamin D-resistant rickets.<sup>2</sup> This form is extremely hard to treat. There is a third form, characterized by failure of the kidney to perform the second hydroxylation of vitamin D.<sup>5</sup> This type rarely requires orthopaedic intervention as it is easily treated with administration of dihydroxyvitamin D. Lastly, renal tubular acidosis has traditionally been grouped with vitamin D-resistant rickets. In renal tubular acidosis, the kidney excretes fixed base and wastes bicarbonate. This leads to wasting of calcium and sodium as well. The alkaline urine results in the precipitation of calcium and severe renal calcinosis.<sup>1,19</sup>

The remainder of the discussion will address familial X-linked dominant hypophosphatemic rickets.

### LABORATORY FINDINGS

Laboratory studies reveal normal or near-normal levels of calcium. PTH and vitamin D levels are normal, but the serum phosphate concentration is significantly decreased.<sup>13-16,20</sup> Urine assays for phosphate demonstrate the increased concentration of phosphate in the urine. The se-

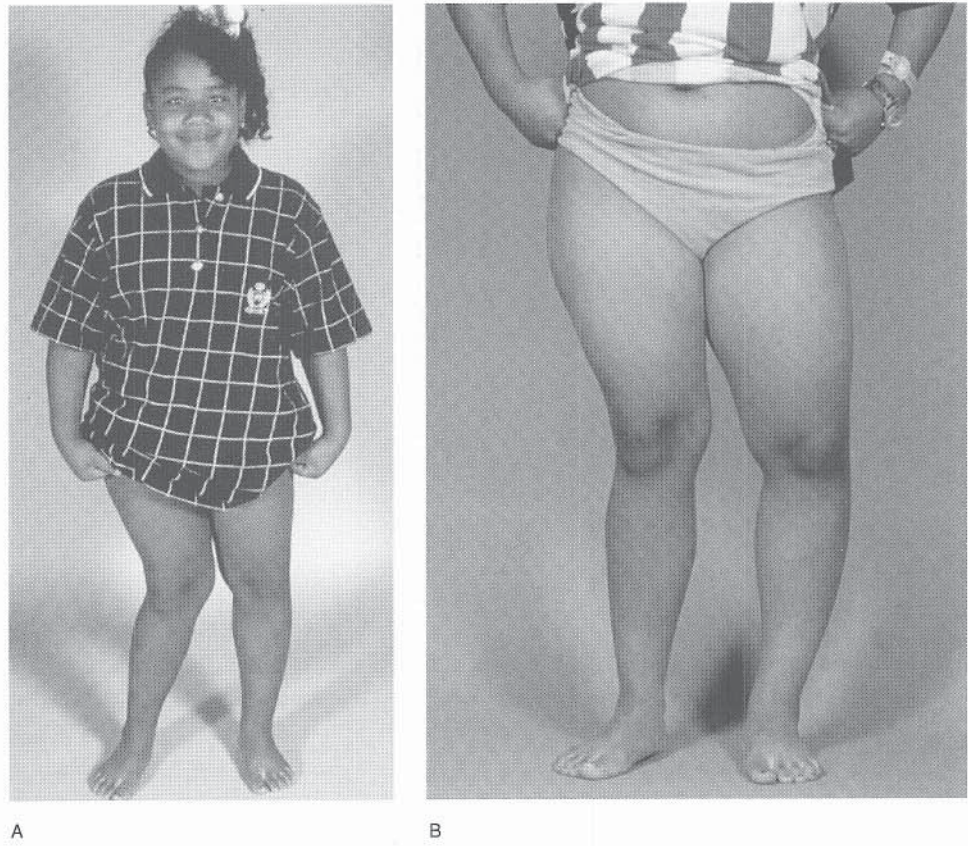


FIGURE 31-7 A, Unilateral genu valgus in a 12-year-old child with poorly controlled vitamin D-resistant rickets. B, Same child at age 15 following right medial hemiepiphyseodesis of the femur. Left genu varum is now apparent.

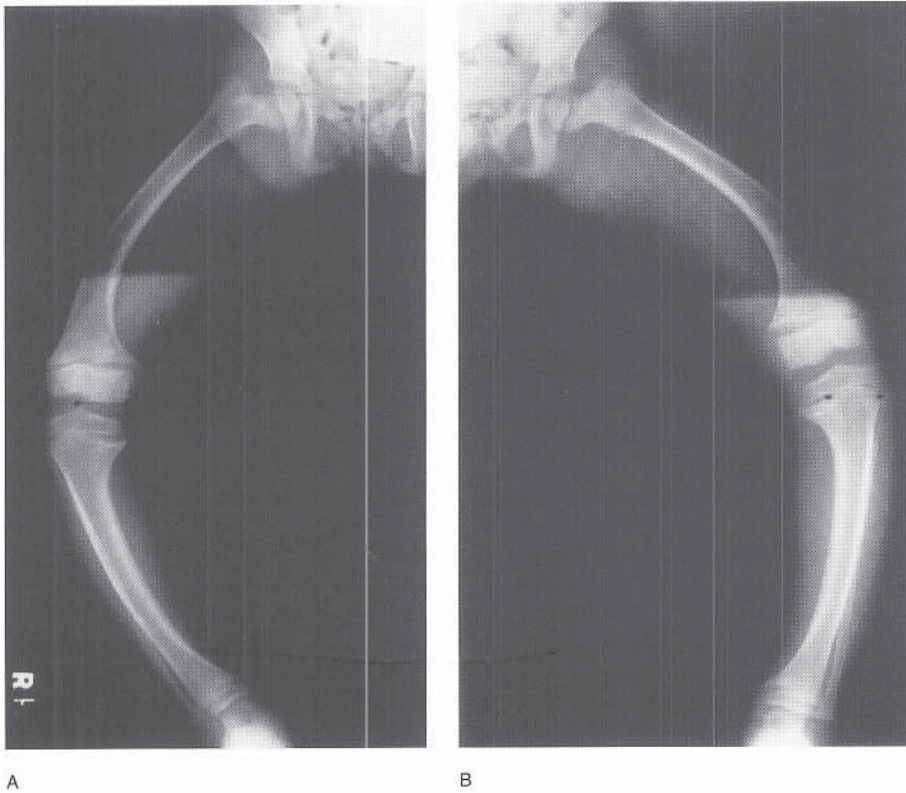


FIGURE 31-8 A and B, AP radiographs of the left and right lower extremities of a standing 7-year-old child with familial hypophosphatemic rickets. Severe genu varum and anterolateral bowing of femur are evident. The physes of the distal femur and proximal tibia are widened medially. See Figures 31-9 and 31-10.

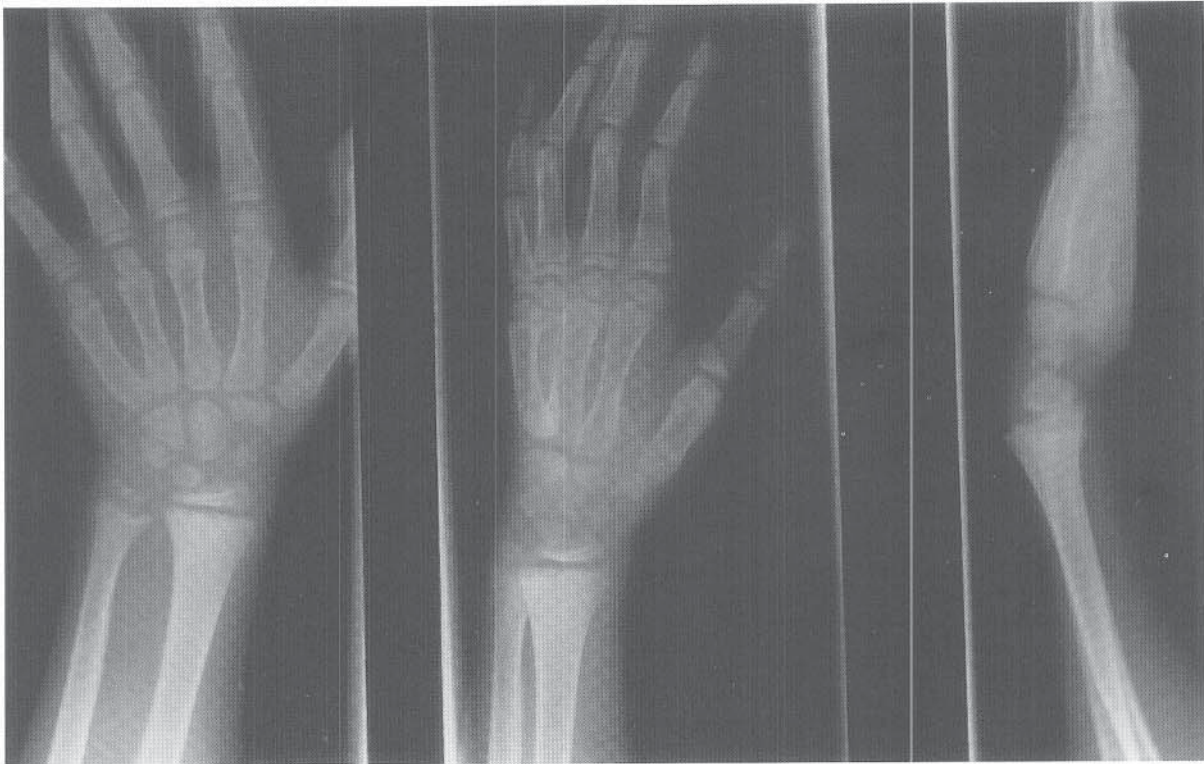


FIGURE 31-9 Physal widening and metaphyseal cupping of the distal radius and ulna in a 7-year-old child (same as in Fig. 31-8) with vitamin D-resistant rickets.

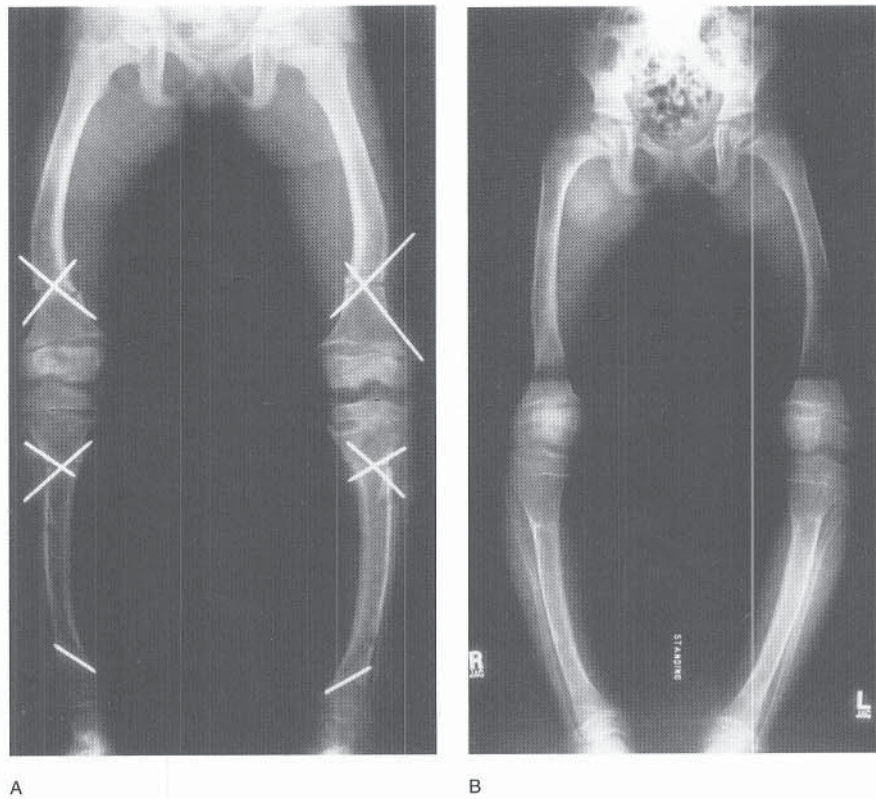


FIGURE 31-10 Postoperative radiographs of the child whose imaging findings are shown in Figures 31-8 and 31-9. A, Appearance after distal femoral, proximal tibial, and distal tibial osteotomies for treatment of the genu varum. B, Varus is recurring 1 year after surgery.



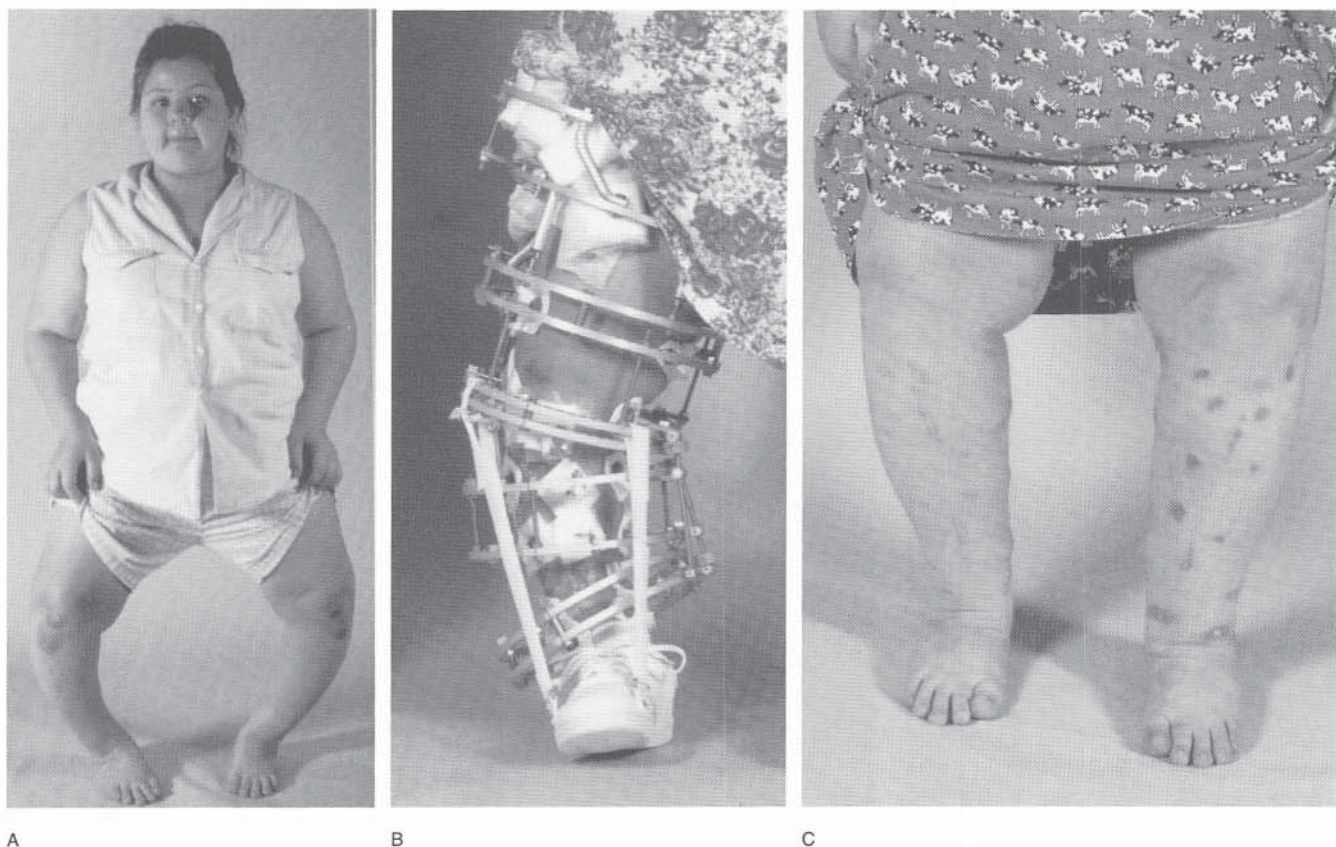


FIGURE 31-11 A, Clinical appearance of a 13-year-old girl with severe genu varum due to vitamin D-resistant rickets. Calluses on the knees were due to crawling because of knee pain. B, Treatment consisted of distal femoral, proximal tibial, and distal tibial corticotomies and gradual correction using the Ilizarov device. Surgery on the two legs was staged, due to the extent of the frame. C, Clinical appearance of the lower extremities at the end of treatment.

rum alkaline phosphatase concentration is elevated (see Fig. 31-3).

### MOLECULAR GENETICS

The gene for hypophosphatemic rickets has been localized. The X-linked dominant form of the disease is attributed to mutations in the PEX gene, located at Xp22.1.<sup>9,23</sup> The gene locus for autosomal dominant hypophosphatemic rickets has been located on chromosome 12p13.<sup>6</sup>

### CLINICAL FEATURES

The disease usually becomes apparent at a slightly older age than nutritional rickets, with most patients becoming symptomatic between 1 and 2 years of age. Severe hypophosphatemic rickets can be recognized in early infancy, and when the disease is suspected because of the family history, laboratory determination of phosphorus concentrations can lead to the diagnosis in infants as young as 3 months.<sup>18</sup> The usual presenting complaints are delayed walking and angular deformities of the lower extremities. In contrast to what is seen in nutritional rickets, systemic manifestations such as irritability and apathy are minimal.

The physical findings in hypophosphatemic rickets include skeletal deformities, which resemble those seen in nutritional rickets but, because of the chronicity of the disease, become far more severe. Once affected children begin

to walk, genu varum develops, although genu valgum may occur in some children (Fig. 31-7). There is periarticular enlargement due to widening of the physes and metaphyses. The “rachitic rosary” may also occur.

Short stature is a feature of hypophosphatemic rickets. Height is usually 2 standard deviations below the mean for age in these patients.<sup>27</sup>

### RADIOGRAPHIC FINDINGS

The radiographic changes are the same as those seen in nutritional rickets and include physeal elongation and widening, and indistinct osteopenic metaphyses. In the lower extremities, genu varum is obvious, and the distal femoral and proximal tibial physes are particularly widened medially (Fig. 31-8). Coxa vara is present, and there may be general anterior and lateral bowing of the entire femur. The varus of the tibia is also generalized, present not only proximally but also producing varus angulation of the ankle.

The upper extremities are also involved, but to a lesser degree, due to the absence of the influence of weightbearing (Fig. 31-9).

### MEDICAL TREATMENT

Medical treatment of hypophosphatemic rickets is best managed by a pediatric nephrologist with expertise in metabolic bone disease. The usual treatment consists of oral replacement of phosphorus in large doses and the administration

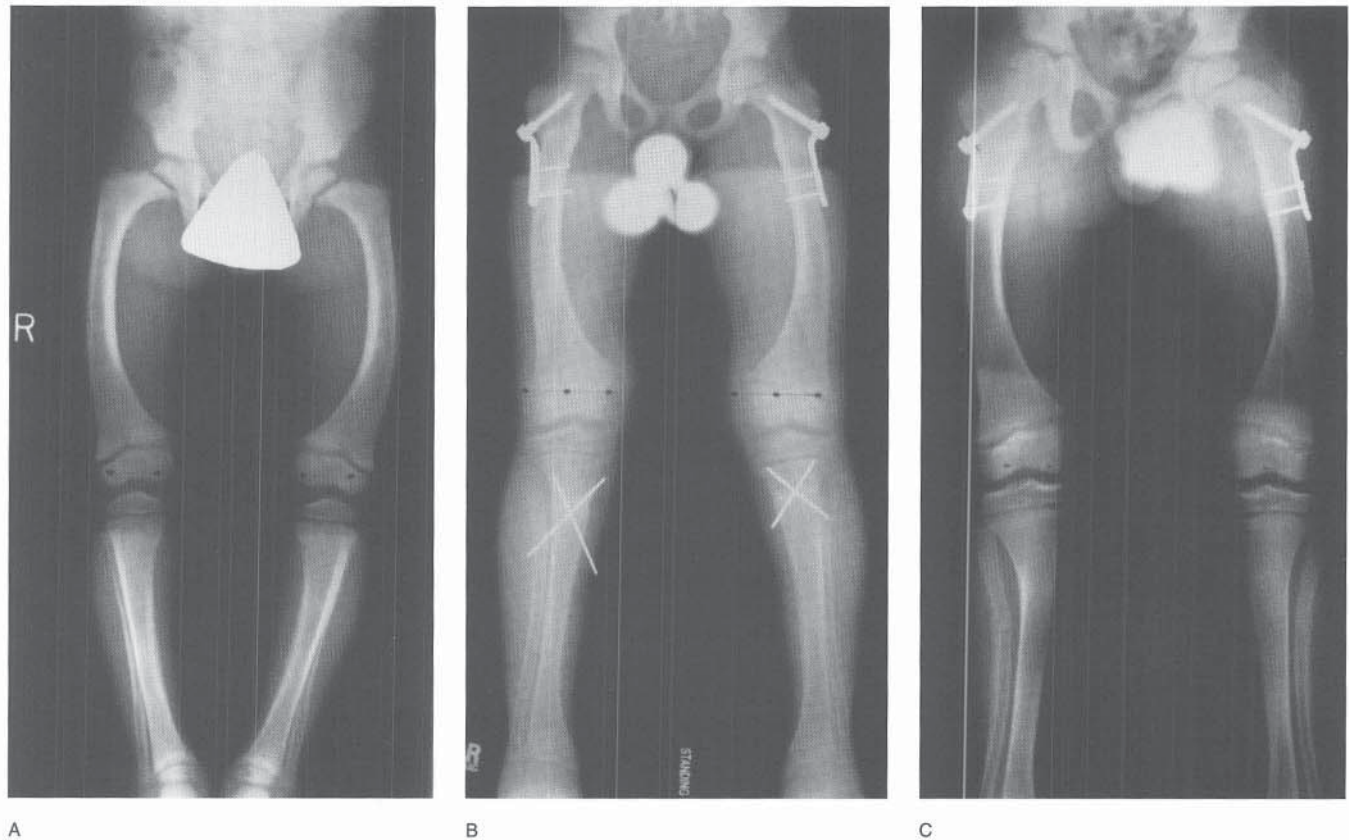


FIGURE 31-12 A, Coxa vara and genu varum in a 5-year-old boy with vitamin D-resistant rickets. B, Postoperative radiograph obtained after corrective osteotomy with plate fixation of proximal femora and osteotomy with K-wire fixation of proximal tibiae. C, Alignment remained satisfactory at 2-year follow-up.

of vitamin D.<sup>17,22,31</sup> Nephrocalcinosis is a significant complication of medical treatment.<sup>28</sup> In a recent study, renal calcinosis was present in 79 percent of treated children with hypophosphatemic rickets, and the severity of the calcinosis correlated with the dose of phosphorus.<sup>29</sup> Because nephrocalcinosis is a significant complication, the decision whether or not to offer treatment to children with hypophosphatemic rickets has become controversial.<sup>8,11</sup> Studies have shown that longitudinal growth is greater in children who undergo vitamin D treatment.<sup>12,26</sup>

Treatment of children with hypophosphatemic rickets with growth hormone has been shown to increase height and to have beneficial effects on bone density and phosphate retention.<sup>25</sup> Preliminary studies reported that the administration of growth hormone with vitamin D increased serum phosphate concentration, and it may reduce the incidence of nephrocalcinosis.<sup>21</sup>

### ORTHOPAEDIC MANAGEMENT

The orthotic management of vitamin D-resistant rickets has not been efficacious. If patients are experiencing increasing pain or difficulty walking, surgical correction of angular deformities should be performed. It is important to work closely with the nephrologist or endocrinologist managing the medical therapy, as calcium levels can suddenly climb in a patient who is immobilized after surgery. Discontinuation of vitamin D prior to surgery should be discussed.

The deformity most commonly seen in patients with hypophosphatemic rickets is a gradual anterolateral bowing of the femur combined with tibia vara. Multilevel osteotomy is usually required to satisfactorily correct the mechanical axis of the limb (Fig. 31-10). The mechanical axis should be mildly overcorrected at surgery. The suggested fixation varies among reports. External fixation allows fine-tuning of the alignment postoperatively, when the patient is able to stand (Fig. 31-11).<sup>10</sup> Others advocate using intramedullary fixation or plating (Fig. 31-12).<sup>7,24</sup> Regardless of the type of fixation used, careful preoperative planning of the surgical treatment of these multiplanar deformities is crucial to restoring alignment.

Recurrent deformity is a common sequela of osteotomies in hypophosphatemic rickets.<sup>24</sup> Younger patients have a higher risk of recurrence.<sup>12</sup> For this reason, milder deformities should not be corrected in early childhood. Some children have severe varus at a very young age, leading to a thrust during gait. When gait is compromised or symptoms or pain exist, osteotomy should be performed and the alignment monitored for recurrent deformity.

Spinal deformity may be seen in patients with hypophosphatemic rickets. Kyphoscoliosis, Arnold-Chiari malformations, and spinal stenosis have all been described in patients with vitamin D-resistant rickets.<sup>3,33</sup>

Adults with hypophosphatemic rickets develop arthritis. Degradation of articular cartilage resembling osteochondritis dissecans has been described. Joint stiffness and bony pain are common complaints.<sup>7</sup>

## REFERENCES

## Vitamin D–Resistant Rickets

- Brenner RJ, Spring DB, Sebastian A, et al: Incidence of radiographically evident bone disease, nephrocalcinosis, and nephrolithiasis in various types of renal tubular acidosis. *N Engl J Med* 1982;307:217.
- Brooks MH, Bell NH, Love L, et al: Vitamin-D-dependent rickets type II: resistance of target organs to 1,25-dihydroxyvitamin D. *N Engl J Med* 1978;298:996.
- Caldemeyer KS, Boaz JC, Wappner RS, et al: Chiari I malformation: association with hypophosphatemic rickets and MR imaging appearance [see comments]. *Radiology* 1995;195:733.
- Delvin EE, Glorieux FH, Marie PJ, et al: Vitamin D dependency: replacement therapy with calcitriol? *J Pediatr* 1981;99:26.
- Dent CE, Harris H: Hereditary forms of rickets and osteomalacia. *J Bone Joint Surg* 1956;38-B:204.
- Econs MJ, McEnery PT, Lennon F, et al: Autosomal dominant hypophosphatemic rickets is linked to chromosome 12p13. *J Clin Invest* 1997;100:2653.
- Ferris B, Walker C, Jackson A, et al: The orthopaedic management of hypophosphatemic rickets. *J Pediatr Orthop* 1991;11:367.
- Hanna JD, Niimi K, Chan JC: X-linked hypophosphatemia: genetic and clinical correlates. *Am J Dis Child* 1991;145:865.
- [HYP Consortium]: A gene (PEX) with homologies to endopeptidases is mutated in patients with X-linked hypophosphatemic rickets. The HYP Consortium. *Nat Genet* 1995;11:130.
- Kanel JS, Price CT: Unilateral external fixation for corrective osteotomies in patients with hypophosphatemic rickets. *J Pediatr Orthop* 1995;15:232.
- Latta K, Hisano S, Chan JC: Therapeutics of X-linked hypophosphatemic rickets. *Pediatr Nephrol* 1993;7:744.
- Loeffler RD Jr, Sherman FC: The effect of treatment on growth and deformity in hypophosphatemic vitamin D–resistant rickets. *Clin Orthop* 1982;162:4.
- Mankin HJ: Metabolic bone disease. *Instr Course Lect* 1995;44:3.
- Mankin HJ: Rickets, osteomalacia, and renal osteodystrophy. Part I. *J Bone Joint Surg* 1974;56-A:101.
- Mankin HJ: Rickets, osteomalacia, and renal osteodystrophy. Part II. *J Bone Joint Surg* 1974;56-A:352.
- Mankin HJ: Rickets, osteomalacia, and renal osteodystrophy: an update. *Orthop Clin North Am* 1990;21:81.
- Marie PJ, Glorieux FH: Stimulation of cortical bone mineralization and remodeling by phosphate and 1,25-dihydroxyvitamin D in vitamin D–resistant rickets. *Metab Bone Dis Relat Res* 1981;3:159.
- Minamitani K, Minagawa M, Yasuda T, et al: Early detection of infants with hypophosphatemic vitamin D resistant rickets (HDDR). *Endocr J* 1996;43:339.
- Morris RC Jr: Renal tubular acidosis: mechanisms, classification and implications. *N Engl J Med* 1969;281:1405.
- Parfitt AM: Hypophosphatemic vitamin D refractory rickets and osteomalacia. *Orthop Clin North Am* 1972;3:653.
- Patel L, Clayton PE, Brain C, et al: Acute biochemical effects of growth hormone treatment compared with conventional treatment in familial hypophosphatemic rickets. *Clin Endocrinol (Oxf)* 1996;44:687.
- Rasmussen H, Pechet M, Anast C, et al: Long-term treatment of familial hypophosphatemic rickets with oral phosphate and 1 alpha-hydroxyvitamin D. *J Pediatr* 1981;99:16.
- Rowe PS, Goulding JN, Francis F, et al: The gene for X-linked hypophosphatemic rickets maps to a 200–300kb region in Xp22.1, and is located on a single YAC containing a putative vitamin D response element (VDRE). *Hum Genet* 1996;97:345.
- Rubinovitch M, Said SE, Glorieux FH, et al: Principles and results of corrective lower limb osteotomies for patients with vitamin D–resistant hypophosphatemic rickets. *Clin Orthop* 1988;237:264.
- Saggese G, Baroncelli GI, Bertelloni S, et al: Long-term growth hormone treatment in children with renal hypophosphatemic rickets: effects on growth, mineral metabolism, and bone density. *J Pediatr* 1995;127:395.
- Seikaly MG, Browne RH, Baum M: The effect of phosphate supplementation on linear growth in children with X-linked hypophosphatemia. *Pediatrics* 1994;94:478.
- Steendijk R, Hauspie RC: The pattern of growth and growth retardation of patients with hypophosphatemic vitamin D–resistant rickets: a longitudinal study. *Eur J Pediatr* 1992;151:422.
- Stickler GB, Morgenstern BZ: Hypophosphatemic rickets: final height and clinical symptoms in adults [see comments]. *Lancet* 1989;2:902.
- Verge CF, Lam A, Simpson JM, et al: Effects of therapy in X-linked hypophosphatemic rickets [see comments]. *N Engl J Med* 1991;325:1843.
- Walton J: Familial hypophosphatemic rickets: a delineation of its subdivisions and pathogenesis. *Clin Pediatr (Phila)* 1976;15:1007.
- West CD, Blanton JC, Silverman FN, et al: Use of phosphate salts as an adjunct to vitamin D in the treatment of hypophosphatemic vitamin D refractory rickets. *J Pediatr* 1964;64:469.
- Winters RW, Graham JB, Williams TF, et al: A genetic study of familial hypophosphatemia and vitamin D resistant rickets with a review of the literature. 1958 [classical article] [see comments]. *Medicine (Baltimore)* 1991;70:215.
- Yamamoto Y, Onofrio BM: Spinal canal stenosis with hypophosphatemic vitamin D–resistant rickets: case report. *Neurosurgery* 1994;35:512.

## Tumor-Related Hypophosphatemic Rickets

An association between benign and malignant tumors and hypophosphatemic rickets has been described, termed oncogenic hypophosphatemic osteomalacia.<sup>3,4,6,8,10</sup> Conditions such as neurofibromatosis and fibrous dysplasia produce rickets on rare occasion.<sup>7,11</sup> Osteoblastomas, hemangiopericytomas of bone, and skin tumors have produced rachitic changes in bone by disrupting renal tubular resorption of phosphate.<sup>2,5</sup> Oncogenic rickets should be suspected in older children presenting with hypophosphatemic rickets, as the true genetic form generally is apparent by age 2 years. The rachitic changes resolve with excision of the tumor.<sup>1,9,11</sup>

## REFERENCES

## Tumor-Related Hypophosphatemic Rickets

- Asnes RS, Berdon WE, Bassett CA: Hypophosphatemic rickets in an adolescent cured by excision of a nonossifying fibroma. *Clin Pediatr (Phila)* 1981;20:646.
- Hanukoglu A, Chalew SA, Sun CJ, et al: Surgically curable hypophosphatemic rickets: diagnosis and management. *Clin Pediatr (Phila)* 1989;28:321.
- Kricun ME, Resnick D: Elbow abnormalities in renal osteodystrophy. *AJR Am J Roentgenol* 1983;140:577.
- Kricun ME, Resnick D: Patellofemoral abnormalities in renal osteodystrophy. *Radiology* 1982;143:667.
- Lee DY, Choi IH, Lee CK, et al: Acquired vitamin D–resistant rickets caused by aggressive osteoblastoma in the pelvis: a case report with ten years' follow-up and review of the literature. *J Pediatr Orthop* 1994;14:793.
- Malluche HH, Faugere MC: Renal osteodystrophy [editorial]. *N Engl J Med* 1989;321:317.
- McArthur RG, Hayles AB, Lambert PW: Albright's syndrome with rickets. *Mayo Clin Proc* 1979;54:313.
- Mehls O, Ritz E, Oppermann HC, et al: Femoral head necrosis in uremic children without steroid treatment or transplantation. *J Pediatr* 1981;99:926.
- Parker MS, Klein I, Haussler MR, et al: Tumor-induced osteomalacia: evidence of a surgically correctable alteration in vitamin D metabolism. *JAMA* 1981;245:492.
- Rowe PS: Molecular biology of hypophosphatemic rickets and oncogenic osteomalacia. *Hum Genet* 1994;94:457.
- Salassa RM, Jowsey J, Arnaud CD: Hypophosphatemic osteomalacia associated with "nonendocrine" tumors. *N Engl J Med* 1970;283:65.

## Renal Osteodystrophy

As the rate of successful treatment of renal failure in children with kidney transplants has increased, the prevalence of renal osteodystrophy has risen. Manifestations of renal osteodystrophy are present in 66 to 79 percent of children with renal failure.<sup>18,26</sup> Children who develop renal disease in infancy or early childhood are more likely to have osteodystrophy than those who are older at presentation.<sup>26</sup> Renal failure in children is due to such diseases as chronic pyelonephritis, congenital abnormalities, and polycystic kidney disease. Renal osteodystrophy is more common in renal disease due to congenital or hereditary conditions than in acquired renal failure. Renal osteodystrophy is distinctly different from either nutritional or hypophosphatemic rickets.<sup>34</sup> It is driven by the presence of secondary hyperparathyroidism, leading to activation of osteoclasts and resorption of bone. Thus, it is a disease both of poor mineral deposition and of increased bony turnover.<sup>9</sup>

The pathophysiology of renal osteodystrophy begins with the damaged glomerulus's inability to excrete phosphorus.<sup>33,34,49</sup> Hyperphosphatemia shuts down the production of dihydroxyvitamin D.<sup>13</sup> Calcium absorption from the small intestine is diminished in the absence of vitamin D. Hypocalcemia triggers the release of PTH, which enables the demineralization of bone to increase the serum calcium level.<sup>56</sup> The hyperphosphatemia worsens with the release of minerals from the bones, leading to a cycle of bony resorption. PTH also acts directly to stimulate osteoclast activity, worsening the bony changes and leading to osteitis fibrosa.

High levels of serum phosphate are universal in renal failure. In the setting of elevated phosphate levels, calcium

may precipitate out, leading to ectopic calcification in tissues. The usual areas for ectopic calcification are the corneas and conjunctivae, skin, blood vessels, and periarticular soft tissues.<sup>7,8,31,49</sup>

### PATHOLOGY

Features of both rickets and hyperparathyroidism are present in renal osteodystrophy (Fig. 31–13).<sup>56</sup> Rachitic changes consist of failure to replace proliferating cartilage cells by new bone. Physeal cartilage persists into the metaphysis. The physis is widened, and the zone of provisional calcification is irregular as a result of the lack of normal calcification of maturing physeal cartilage. Bony trabeculae have abundant osteoid and widened osteoid seams.

The histologic features of hyperparathyroidism include osteoclastic resorption of bone. Marrow is replaced by hyperplastic fibrous tissue. Patchy formation of new bone leads to areas of osteosclerosis, present in 20 percent of patients with renal osteodystrophy.

### LABORATORY FINDINGS

The blood urea nitrogen level is high, as is the serum creatinine concentration. Levels of serum phosphate, alkaline phosphatase, and PTH are elevated. The serum calcium concentration is almost always low, as is the albumin level. Acidosis is present, and vitamin D levels are decreased (see Fig. 31–3).

Bone biopsy may be necessary for accurate diagnosis, and can help guide treatment.<sup>19,35</sup>

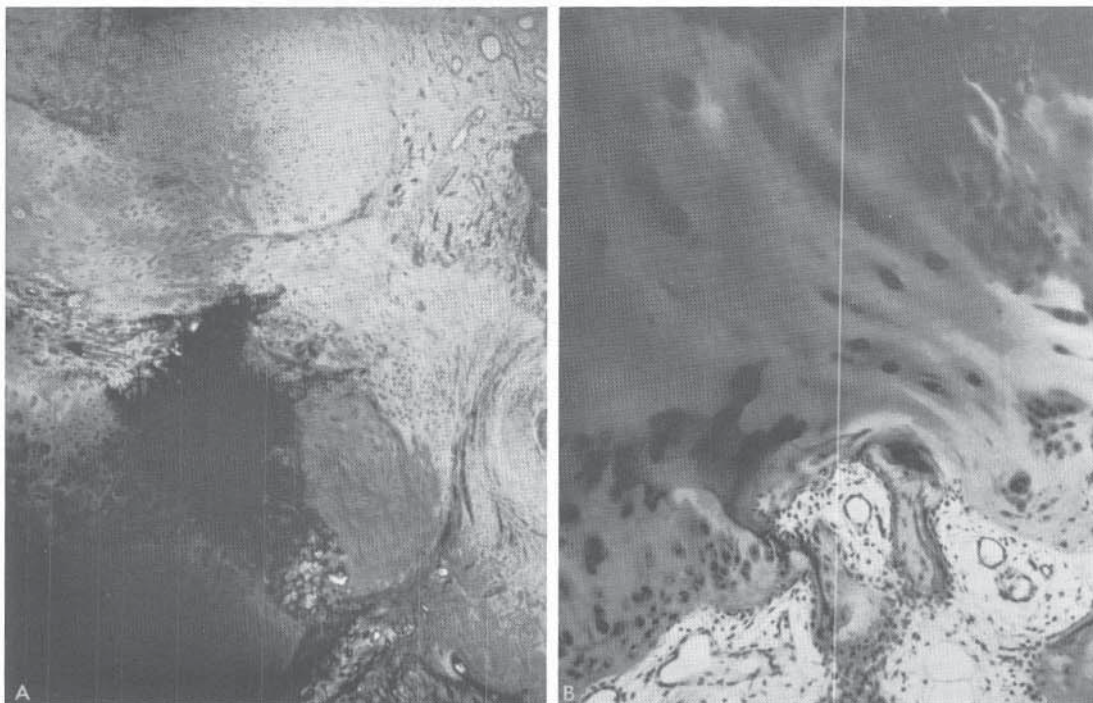


FIGURE 31–13 Histologic findings of osteodystrophy due to chronic renal insufficiency. **A**, Photomicrograph of a section through the widened physis showing extension of cartilage cells into the metaphysis ( $\times 25$ ). **B**, Higher magnification ( $\times 100$ ) of same area. Note the uncalcified osteoid tissue and replacement of the normal fatty bone marrow by hyperplastic fibrous tissue.

## CLINICAL FEATURES

Children with renal osteodystrophy resemble those with rickets.<sup>3</sup> They are short for their age,<sup>23,26</sup> and their bones are fragile.<sup>48</sup> Because of the effects of weightbearing, lower extremity involvement is more severe than upper extremity involvement. Patients may complain of bone pain, and fractures occur quite easily. Skeletal deformities may consist of genu valgum, periarticular enlargement of the long bones, and slipped capital femoral epiphysis (SCFE).<sup>6,21,24,30,38,55</sup> The gait may be abnormal due to muscular weakness, and a Trendelenburg gait is present in patients with SCFE. Enlargement of the costochondral cartilages may produce a “rachitic rosary,” as in nutritional rickets.

## RADIOGRAPHIC FINDINGS

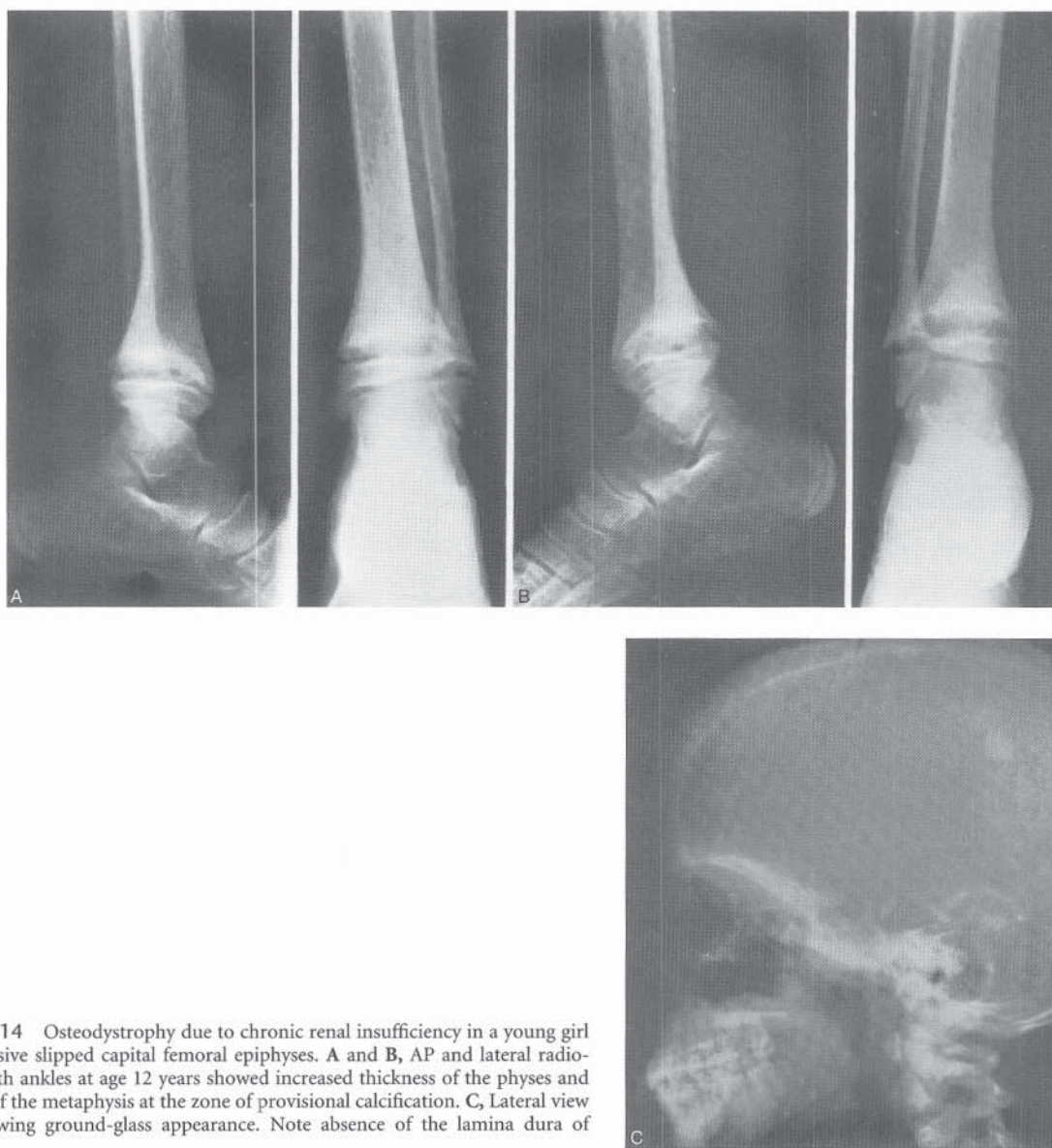
Generalized osteopenia is notable, with thinning of the cortices and indistinct bony trabeculae.<sup>1,16,37,61</sup> Overall the bone

looks blurry, like ground glass. The skull takes on a salt-and-pepper appearance because of the coarse granular pattern. The physes are increased in thickness, and the provisional zone of calcification looks uncalcified and indistinct (Fig. 31–14).<sup>22,26</sup> Cupping of the physes is not present, unlike in nutritional rickets.

Changes of hyperparathyroidism develop with time.<sup>58</sup> SCFE may be seen, even in young patients (Fig. 31–15).<sup>11</sup> The terminal tufts of the distal phalanges of the fingers resorb, as do the lateral end of the clavicle and the symphysis pubis.<sup>10,20,50,51</sup> Subperiosteal resorption is also present in the metacarpals and ulna.<sup>28</sup>

Osteosclerosis, when present, is most common at the base of the skull and in the vertebrae.<sup>25,29</sup> The horizontal striped appearance of the spine is called “rugger jersey” spine.

In severe and prolonged renal failure, peculiar aggressive-appearing lytic areas may develop within the long bones, termed brown tumors. The surrounding cortex is thinned,



**FIGURE 31–14** Osteodystrophy due to chronic renal insufficiency in a young girl with progressive slipped capital femoral epiphyses. **A** and **B**, AP and lateral radiographs of both ankles at age 12 years showed increased thickness of the physes and irregularity of the metaphysis at the zone of provisional calcification. **C**, Lateral view of skull showing ground-glass appearance. Note absence of the lamina dura of the teeth.

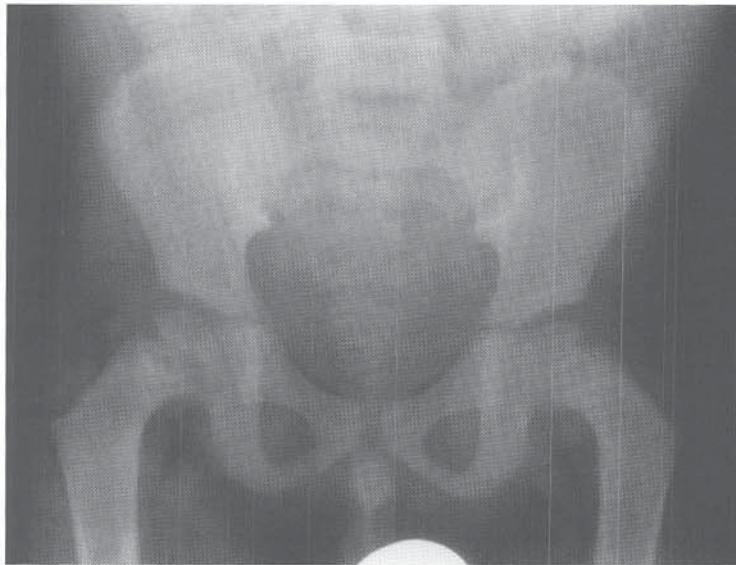
then expands. The margins of a brown tumor are not well-defined. Pathologic fracture may result. Radiographically, these lesions mimic malignancy. They are well visualized on magnetic resonance imaging (MRI).<sup>43</sup>

Because many patients with renal failure (and all patients who have undergone kidney transplantation) are treated with steroids, the typical skeletal abnormalities seen with chronic steroid use may develop. Osteonecrosis is common and is seen most frequently in the femoral heads (Fig. 31-16).

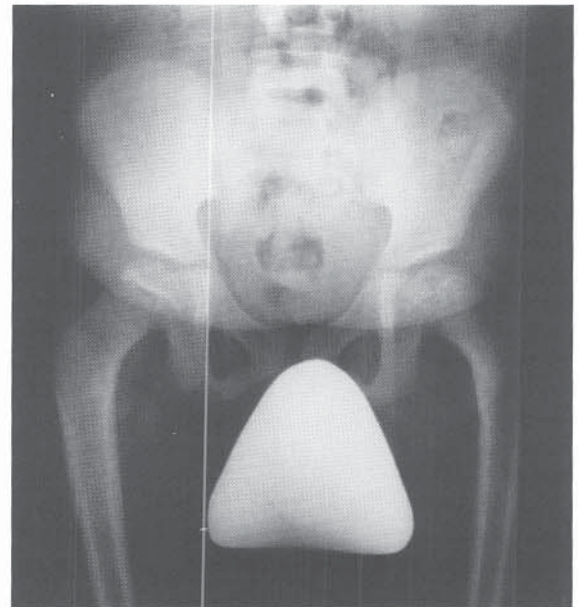
### MEDICAL TREATMENT

Treatment of the underlying renal disease is of primary importance. Dialysis and transplantation are extending the life spans of these patients. Medical treatment of the osteodystrophy starts with the prescription of vitamin D.<sup>39,52,53</sup>

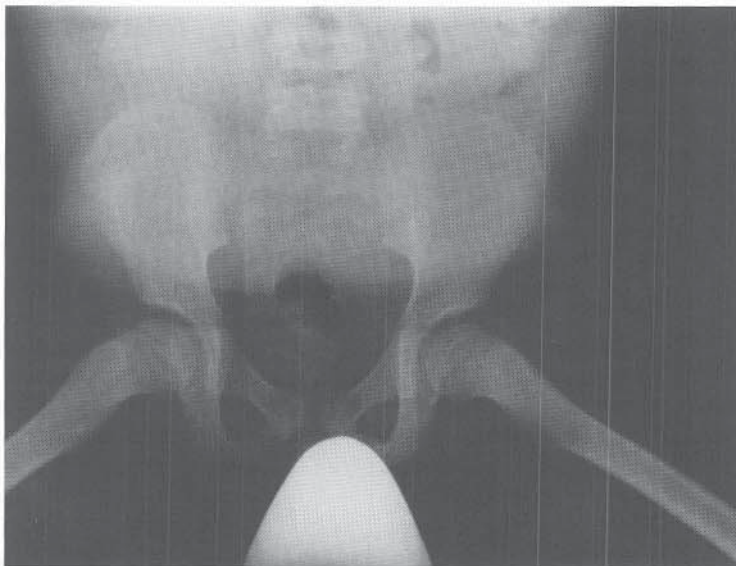
Because the abnormal kidney cannot participate in the hydroxylation of provitamin D, the 1,25-dihydroxy form is now given.<sup>41</sup> Serum calcium levels are closely monitored, as too much calcium leads to ectopic calcification. The use of high-dose pulsed intravenous, intraperitoneal, and oral calcitriol therapy has significantly decreased serum PTH levels and retarded the progression of osteitis fibrosa.<sup>2,54</sup> The treatment of acidosis with sodium bicarbonate is also important in improving the metabolic bone disease. Phosphate-binding agents have been given for management of hyperphosphatemia, but their use is falling out of favor due to problems with aluminum toxicity, which can lead to encephalopathy and worsening of the osteomalacia and osteodystrophy.<sup>5,39,45</sup> Bone biopsy is useful in monitoring response to therapy and in surveillance for such complications.<sup>32</sup> Aluminum toxicity is treated by administering aluminum-chelating agents.



A



B



C

FIGURE 31-15 A, AP radiograph of a 7-year-old boy with hip pain. Slipped capital femoral epiphysis is present, osteopenia is obvious, and the physes are wide. B and C, AP and lateral radiographs of the hips following treatment of renal failure with dialysis. The physes of the proximal femur have narrowed.

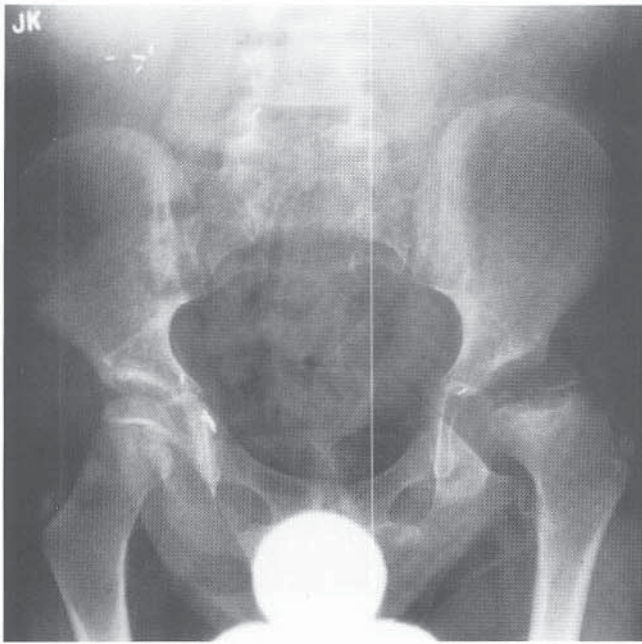


FIGURE 31-16 Avascular necrosis of the left hip in a 7-year-old boy following renal transplantation and steroid therapy.

The use of growth hormone to treat growth inhibition in children with renal osteodystrophy is currently under investigation.<sup>23,36,40</sup> Growth hormone biomechanically weakens the physis, so that vigilance on the part of the treating physician for the development of SCFE or physiolysis must be maintained.

In renal osteodystrophy that is recalcitrant to medical treatment, parathyroidectomy may play a role in the control of the bony disease.<sup>17</sup>

### ORTHOPAEDIC MANAGEMENT

Patients with renal osteodystrophy are referred to the orthopaedic surgeon for the treatment of three problems: (1) angular deformity of the lower extremities, (2) SCFE, and (3) brown tumors.<sup>12</sup>

Angular deformity occurs in renal osteodystrophy because the bone is soft, undermineralized, and prone to bend with weightbearing. Genu valgum is the most common deformity,<sup>27</sup> but genu varum may occur in some patients. It has been proposed that if the onset of renal osteodystrophy occurs before age 4 years, varus deformity may occur, as the normal alignment of the leg is in mild varus, which then is accentuated as the bone becomes weak. Likewise, older children are predisposed to the development of genu valgum, due to the normal valgus alignment of the lower extremity.<sup>15</sup> Valgus at the ankle may accompany the genu valgum.

Some milder deformities will correct with medical therapy of the renal osteodystrophy.<sup>9</sup> Deformities do not respond well to bracing. If the patient is symptomatic and has had optimal medical management of the osteodystrophy without resolution of deformity, osteotomy is performed.<sup>12</sup> Preoperative assessment of the deformity with long-leg standing radiographs will permit the surgeon to decide where the deformity is and how many osteotomies will be needed to best

correct the mechanical axis. Usually the distal femur is the site of greatest deformity, but some patients also need a proximal tibial osteotomy. Internal or external fixation may be used. Use of the Ilizarov device in metabolic bone disease has met with success, although healing was delayed.<sup>57</sup> Recurrence is common in patients with continuing metabolic disease, so medical treatment should be optimized prior to osteotomy whenever possible. Elevation of the serum alkaline phosphatase concentration above 500 U/L is a good marker of ongoing metabolic bone disease.<sup>15,44</sup> Bone biopsy may be needed to establish that the bone is metabolically healthy prior to osteotomy.<sup>15</sup> Milder deformity may respond to physal stapling.<sup>44</sup>

A subset of patients with genu valgum show evidence of a proximal tibial growth disturbance in the form of physal abnormality in the proximal lateral tibial physis. Oppenheim and associates liken the physal widening of the lateral physis to that seen in the medial physis in Blount's disease.<sup>46</sup> These patients benefit from tibial osteotomy for realignment.

SCFE is associated with renal osteodystrophy, but the clinical picture of the patient with renal slips differs from the usual clinical scenario.<sup>6,14,21,42</sup> Often the patients are younger than those with idiopathic SCFE, and obesity is not commonly seen. Bilaterality is extremely common. Radiographs show more physal widening than is usual in SCFE, and osteopenia and blurring of the metaphysis may be obvious.<sup>38</sup> The orthopaedic surgeon should be aware of the radiographic appearance of renal SCFE, since on rare occasions patients may present for treatment of hip or groin pain unaware of their renal disease. In such cases it is up to the orthopaedic surgeon to make the diagnosis of renal osteodystrophy and promptly refer the child to a nephrologist for the appropriate treatment.

There are inherent problems in the surgical treatment of SCFE in renal osteodystrophy. The goal of routine treatment of SCFE is to stop proximal femoral physal growth, and thus heal the slip. This may not be a desirable goal in the very young child with renal osteodystrophy. Additionally, physal healing may be very difficult to achieve in the presence of osteitis fibrosa and metabolic imbalance. Fortunately, in many patients the hip pain resolves and the proximal femoral physis narrows with mineral treatment of the renal osteodystrophy, so that surgery is not necessary in every patient with renal SCFE.<sup>30,55</sup> If the slip is displaced or if symptoms persist despite good medical control of the osteodystrophy, surgery may be needed. Fixation with special partially threaded screws to achieve stability and cross but not close the physis has been done in a small series of patients with renal slips.<sup>24</sup> In the adolescent with SCFE due to renal disease, epiphyseal closure with *in situ* fixation is the treatment of choice once the metabolic bone disease is under appropriate treatment (Fig. 31-17).

Physiolysis has been described in other physes in children with renal osteodystrophy.<sup>60</sup> Sites where physiolysis has occurred include the distal femur, proximal humerus, and distal radius and ulna (Fig. 31-18). Treatment consists of medical management of the metabolic bone disease and cast immobilization.<sup>4,59</sup>

Yet another orthopaedic complication seen in patients with renal failure is avascular necrosis (AVN), most commonly of the femoral head.<sup>47</sup> This may be unilateral or bilateral. Prolonged steroid use (commonly needed after

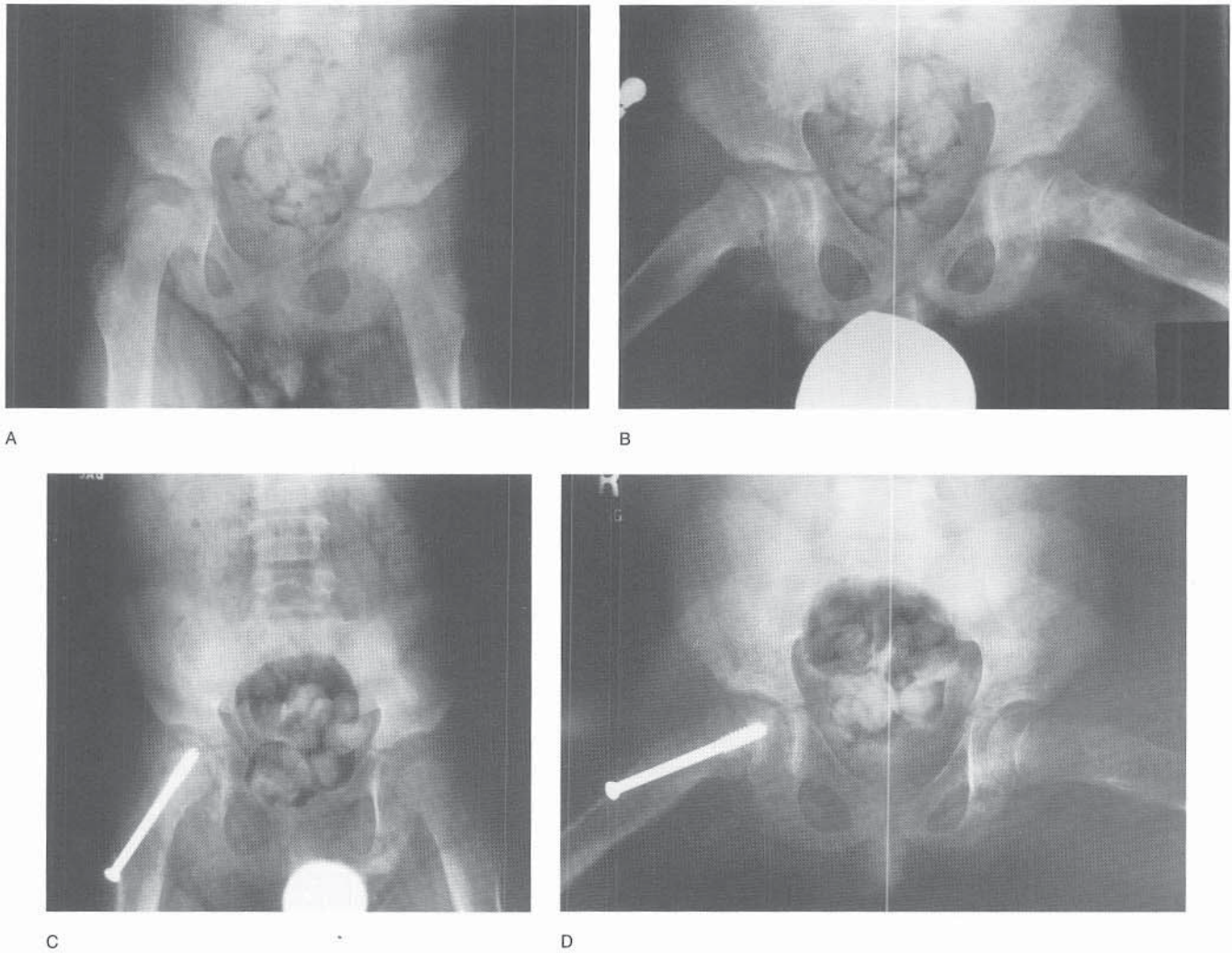


FIGURE 31-17 A and B, Valgus slipped capital femoral epiphysis in an 11-year-old child after renal transplantation and hypothyroidism. C and D, In situ fixation was performed.

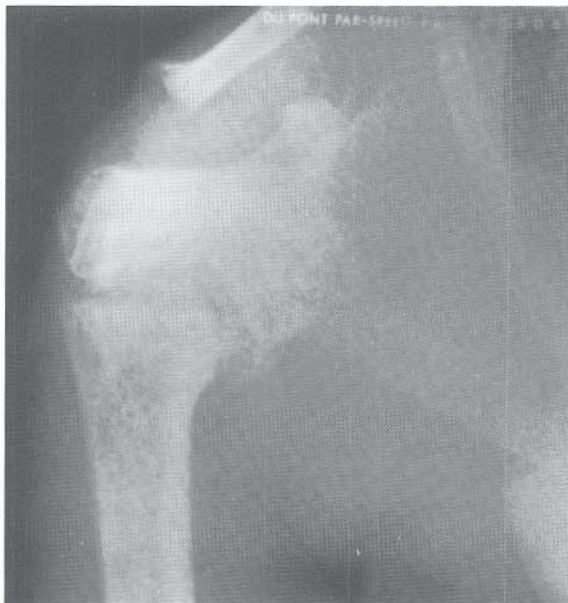


FIGURE 31-18 Osteodystrophy due to chronic renal insufficiency in a young girl. AP radiograph shows slipping of humeral head.

renal transplantation) is the probable cause in most children, although AVN has been seen in the hips of some children with renal failure who were not taking steroids. Treatment is symptomatic.

In the surgical correction of any of the orthopaedic deformities in renal osteodystrophy, the hazards and complications should be carefully weighed because of the increased risks in this patient population. Anemia, hypertension, bleeding tendencies, and electrolyte imbalances all are present in patients with renal failure. The risk of infection is also increased, particularly if the patient has received a transplant and is immunosuppressed. Despite these potential risks, with careful coordination of surgery and perioperative management with the pediatric nephrologist, osteotomy can be performed safely.

## REFERENCES

### Renal Osteodystrophy

1. Andresen J, Nielsen HE: Renal osteodystrophy in non-dialysed patients with chronic renal failure. *Acta Radiol [Diagn] (Stockh)* 1980;21: 803.
2. Andress DL, Norris KC, Coburn JW, et al: Intravenous calcitriol in



- the treatment of refractory osteitis fibrosa of chronic renal failure. *N Engl J Med* 1989;321:274.
3. Apel DM, Millar EA, Moel DI: Skeletal disorders in a pediatric renal transplant population. *J Pediatr Orthop* 1989;9:505.
  4. Arvin M, White SJ, Braunstein EM: Growth plate injury of the hand and wrist in renal osteodystrophy. *Skeletal Radiol* 1990;19:515.
  5. Bardin T: Renal osteodystrophy, disorders of vitamin D metabolism, and hypophosphatasia. *Curr Opin Rheumatol* 1992;4:389.
  6. Barrett IR, Papadimitriou DG: Skeletal disorders in children with renal failure. *J Pediatr Orthop* 1996;16:264.
  7. Berlyne GM: Microcrystalline conjunctival calcification in renal failure: a useful clinical sign. *Lancet* 1968;2:366.
  8. Berlyne GM, Ari JB, Danovitch GM, et al: Cataracts of chronic renal failure. *Lancet* 1972;1:509.
  9. Blockey NJ, Murphy AV, Mocan H: Management of rachitic deformities in children with chronic renal failure. *J Bone Joint Surg* 1986;68-B:791.
  10. Bonavita JA, Dalinka MK: Shoulder erosions in renal osteodystrophy. *Skeletal Radiol* 1980;5:105.
  11. Brailsford JF: Slipping of the epiphysis of the head of the femur: its relation to renal rickets. *Lancet* 1933;1:16.
  12. Cattell HS, Levin S, Kopits S, et al: Reconstructive surgery in children with azotemic osteodystrophy. *J Bone Joint Surg* 1971;53-A:216.
  13. Chan JC, Hsu AC: Vitamin D and renal diseases. *Adv Pediatr* 1980;27:117.
  14. Crawford AH: Slipped capital femoral epiphysis. *J Bone Joint Surg* 1988;70-A:1422.
  15. Davids JR, Fisher R, Lum G, et al: Angular deformity of the lower extremity in children with renal osteodystrophy. *J Pediatr Orthop* 1992;12:291.
  16. Debnam JW, Bates ML, Kopelman RC, et al: Radiological/pathological correlations in uremic bone disease. *Radiology* 1977;125:653.
  17. Esselstyn CB Jr, Popowniak KL: Parathyroid surgery in the treatment of renal osteodystrophy and tertiary hyperparathyroidism. *Surg Clin North Am* 1971;51:1211.
  18. Fassier F, St.-Pierre M, Robitaille P: Renal osteodystrophy in children: correlation between aetiology of the renal disease and the frequency of bone and articular lesions. *Int Orthop* 1993;17:269.
  19. Fletcher S, Jones RG, Rayner HC, et al: Assessment of renal osteodystrophy in dialysis patients: use of bone alkaline phosphatase, bone mineral density and parathyroid ultrasound in comparison with bone histology. *Nephron* 1997;75:412.
  20. Gamble JG, Simmons SC, Freedman M: The symphysis pubis: anatomic and pathologic considerations. *Clin Orthop* 1986;203:261.
  21. Goldman AB, Lane JM, Salvati E: Slipped capital femoral epiphyses complicating renal osteodystrophy: a report of three cases. *Radiology* 1978;126:333.
  22. Greenfield GB: Roentgen appearance of bone and soft tissue changes in chronic renal disease. *AJR Am J Roentgenol* 1972;116:749.
  23. Hanna JD, Krieg RJ Jr, Scheinman JJ, et al: Effects of uremia on growth in children. *Semin Nephrol* 1996;16:230.
  24. Hartjen CA, Koman LA: Treatment of slipped capital femoral epiphysis resulting from juvenile renal osteodystrophy. *J Pediatr Orthop* 1990;10:551.
  25. Haust MD, Landing BH, Holmstrand D, et al: Osteosclerosis of renal disease in children: comparative pathologic and radiographic studies. *Am J Pathol* 1964;44:141.
  26. Hsu AC, Kooh SW, Fraser D, et al: Renal osteodystrophy in children with chronic renal failure: an unexpectedly common and incapacitating complication. *Pediatrics* 1982;70:742.
  27. Kling TF Jr: Angular deformities of the lower limbs in children. *Orthop Clin North Am* 1987;18:513.
  28. Kricun ME, Resnick D: Elbow abnormalities in renal osteodystrophy. *AJR Am J Roentgenol* 1983;140:577.
  29. Lalli AF, Lapidus J: Osteosclerosis occurring in renal disease. *AJR Am J Roentgenol* 1965;93:924.
  30. Loder RT, Hensinger RN: Slipped capital femoral epiphysis associated with renal failure osteodystrophy. *J Pediatr Orthop* 1997;17:205.
  31. Mallick NP, Berlyne GM: Arterial calcification after vitamin-D therapy in hyperphosphatemic renal failure. *Lancet* 1968;2:1316.
  32. Malluche HH, Monier-Faugere MC: The role of bone biopsy in the management of patients with renal osteodystrophy [editorial]. *J Am Soc Nephrol* 1994;4:1631.
  33. Mankin HJ: Metabolic bone disease. *Instr Course Lect* 1995;44:3.
  34. Mankin HJ: Rickets, osteomalacia, and renal osteodystrophy: an update. *Orthop Clin North Am* 1990;21:81.
  35. McCarthy JT, Dayton JM, Fitzpatrick LA, et al: The importance of bone biopsy in managing renal osteodystrophy [Clinical Conference]. *Adv Ren Replace Ther* 1995;2:148.
  36. Mehls O, Broyer M: Growth response to recombinant human growth hormone in short prepubertal children with chronic renal failure with or without dialysis. The European/Australian Study Group. *Acta Paediatr Suppl* 1994;399:81.
  37. Mehls O, Ritz E, Krempien B, et al: Roentgenological signs in the skeleton of uremic children: an analysis of the anatomical principles underlying the roentgenological changes. *Pediatr Radiol* 1973;1:183.
  38. Mehls O, Ritz E, Krempien B, et al: Slipped epiphyses in renal osteodystrophy. *Arch Dis Child* 1975;50:545.
  39. Mehls O, Salusky IB: Recent advances and controversies in childhood renal osteodystrophy. *Pediatr Nephrol* 1987;1:212.
  40. Mehls O, Tonshoff B, Haffner D, et al: The use of recombinant human growth hormone in short children with chronic renal failure. *J Pediatr Endocrinol* 1994;7:107.
  41. Morii H, Ishimura E, Inoue T, et al: History of vitamin D treatment of renal osteodystrophy. *Am J Nephrol* 1997;17:382.
  42. Nixon JR, Douglas JF: Bilateral slipping of the upper femoral epiphysis in end-stage renal failure: a report of two cases. *J Bone Joint Surg* 1980;62-B:18.
  43. Olmastroni M, Seracini D, Lavoratti G, et al: Magnetic resonance imaging of renal osteodystrophy in children. *Pediatr Radiol* 1997;27:865.
  44. Oppenheim WL, Fischer SR, Salusky IB: Surgical correction of angular deformity of the knee in children with renal osteodystrophy. *J Pediatr Orthop* 1997;17:41.
  45. Oppenheim WL, Namba R, Goodman WG, et al: Aluminum toxicity complicating renal osteodystrophy: a case report. *J Bone Joint Surg* 1989;71-A:446.
  46. Oppenheim WL, Shayestehfar S, Salusky IB: Tibial physeal changes in renal osteodystrophy: lateral Blount's disease. *J Pediatr Orthop* 1992;12:774.
  47. Oppermann HC, Mehls O, Willich E, et al: [Osteonecroses in children with chronic renal diseases before and after kidney transplantation]. *Radiologe* 1981;21:175.
  48. Parfitt AM: Renal osteodystrophy. *Orthop Clin North Am* 1972;3:681.
  49. Parfitt AM: Soft-tissue calcification in uremia. *Arch Intern Med* 1969;124:544.
  50. Resnick D, Deftos LJ, Parthemore JG: Renal osteodystrophy: magnification radiography of target sites of absorption. *AJR Am J Roentgenol* 1981;136:711.
  51. Resnick D, Niwayama G: Subchondral resorption of bone in renal osteodystrophy. *Radiology* 1976;118:315.
  52. Rigden SP: The treatment of renal osteodystrophy. *Pediatr Nephrol* 1996;10:653.
  53. Salusky IB, Goodman WG: The management of renal osteodystrophy. *Pediatr Nephrol* 1996;10:651.
  54. Sanchez CP, Salusky IB: The renal bone diseases in children treated with dialysis. *Adv Ren Replace Ther* 1996;3:14.
  55. Shea D, Mankin HJ: Slipped capital femoral epiphysis in renal rickets: report of three cases. *J Bone Joint Surg* 1966;48-A:349.
  56. Stanbury SW, Lumb GA: Metabolic studies of renal osteodystrophy. I. Calcium, phosphorus and nitrogen metabolism in rickets, osteomalacia and hyperparathyroidism complicating chronic uremia and in the osteomalacia of the adult Fanconi syndrome. *Medicine* 1962;41:1.
  57. Stanitski DF: Treatment of deformity secondary to metabolic bone disease with the Ilizarov technique. *Clin Orthop* 1994;301:38.
  58. Sundaram M: Renal osteodystrophy. *Skeletal Radiol* 1989;18:415.
  59. Swierstra BA, Diepstraten AF, vd Heyden BJ: Distal femoral physiolysis in renal osteodystrophy: successful nonoperative treatment of 3 cases followed for 5 years. *Acta Orthop Scand* 1993;64:382.
  60. Tebor GB, Ehrlich MG, Herrin J: Slippage of the distal tibial epiphysis. *J Pediatr Orthop* 1983;3:211.
  61. Weller M, Edeikin J, Hodes PJ: Renal osteodystrophy. *AJR Am J Roentgenol* 1968;104:354.

## Primary Hyperparathyroidism

Primary hyperparathyroidism results from hyperplasia of the parathyroid glands, which leads to increased secretion of PTH.<sup>1,2</sup> The increased PTH stimulates osteoclastic resorp-

tion of bone, which produces hypercalcemia. The presenting symptoms of hyperparathyroidism are lethargy, bone pain, and abdominal complaints. The diagnosis is usually made late in the disease course, when the child has abdominal symptoms, toxicity, and hypercalcemic crisis.<sup>5</sup> The symptoms of hyperparathyroidism are common and nonspecific, so the diagnosis is frequently missed at initial presentation.<sup>11</sup> Prolonged hypercalcemia leads to ectopic calcification in tissues and renal calculi formation. Abdominal pain and constipation result from the decreased abdominal motility. Hypertension is commonly present. In severe cases, the patient may become obtunded.

The usual cause is an adenoma.<sup>17</sup> Patients who have undergone head and neck irradiation are particularly susceptible to the development of parathyroid adenomas.<sup>4,7</sup> Hyperparathyroidism can also be a component of the multiple endocrine neoplasia (MEN) syndromes, which are inherited and can rarely present in childhood.<sup>9,16,19,20</sup> There also exist very rare genetic forms of hyperparathyroidism,<sup>6</sup> some of which are self-limiting with medical treatment<sup>8,14</sup> while others are life-threatening.<sup>10,12</sup> Babies born to parents with familial hypocalciuric hypercalcemia are at risk for developing severe neonatal hyperparathyroidism as a result of mutations in the calcium-sensing receptor gene.<sup>3,15</sup>

The radiographic findings resemble those of renal osteodystrophy. Bony resorption is seen in the terminal tufts of the phalanges and in the clavicle. The bone appears osteopenic. Angular deformities resembling those seen in rickets can occur.<sup>13</sup>

Laboratory evaluation usually reveals hypercalcemia, hypophosphatemia, and elevated alkaline phosphatase concentration. Rarely, the calcium and phosphate concentrations are normal. PTH is elevated on direct assays.

Treatment is directed toward correcting the cause of the hyperparathyroidism. In cases of adenoma, tumor resection is performed. Adenomas are imaged with radionuclide scans. It is not uncommon for multiple glands to be involved.<sup>18</sup> Hypercalcemic crisis is treated by hydration and replacement of sodium losses.<sup>21</sup>

## REFERENCES

### Primary Hyperparathyroidism

- Anast CS: Parathyroid disorders in children. *Pediatr Ann* 1980;9:376.
- Bjernulf A, Hall K, Sjögren L, et al: Primary hyperparathyroidism in children: brief review of the literature and a case report. *Acta Paediatr Scand* 1970;59:249.
- Bornemann M: Management of primary hyperparathyroidism in children. *South Med J* 1998;91:475.
- Cohen J, Gierlowski TC, Schneider AB: A prospective study of hyperparathyroidism in individuals exposed to radiation in childhood. *JAMA* 1990;264:581.
- Cronin CS, Reeve TS, Robinson B, et al: Primary hyperparathyroidism in childhood and adolescence. *J Paediatr Child Health* 1996;32:397.
- Cutler RE, Reisse E, Ackerman LU: Familial hyperparathyroidism. *N Engl J Med* 1964;270:859.
- Gillis D, Hirsch HJ, Landau H, et al: Parathyroid adenoma after radiation in an 8-year-old boy. *J Pediatr* 1998;132:892.
- Harris SS, D'Ercole AJ: Neonatal hyperparathyroidism: the natural course in the absence of surgical intervention. *Pediatrics* 1989;83:53.
- Howe JR, Norton JA, Wells SA Jr: Prevalence of pheochromocytoma and hyperparathyroidism in multiple endocrine neoplasia type 2A: results of long-term follow-up. *Surgery* 1993;114:1070.
- Kobayashi M, Tanaka H, Tsuzuki K, et al: Two novel missense mutations in calcium-sensing receptor gene associated with neonatal severe hyperparathyroidism. *J Clin Endocrinol Metab* 1997;82:2716.

- Lawson ML, Miller SF, Ellis G, et al: Primary hyperparathyroidism in a paediatric hospital. *Q J Med* 1996;89:921.
- McHenry CR, Rosen IB, Walfish PG, et al: Parathyroid crisis of unusual features in a child. *Cancer* 1993;71:1923.
- Menon PS, Madhavi N, Mukhopadhyaya S, et al: Primary hyperparathyroidism in a 14 year old girl presenting with bone deformities. *J Paediatr Child Health* 1994;30:441.
- Nishiyama S, Tomoeda S, Inoue F, et al: Self-limited neonatal familial hyperparathyroidism associated with hypercalciuria and renal tubular acidosis in three siblings. *Pediatrics* 1990;86:421.
- Pearce SH, Trump D, Wooding C, et al: Calcium-sensing receptor mutations in familial benign hypercalcemia and neonatal hyperparathyroidism. *J Clin Invest* 1995;96:2683.
- Petty EM, Green JS, Marx SJ, et al: Mapping the gene for hereditary hyperparathyroidism and prolactinoma (MEN1/Burin) to chromosome 11q: evidence for a founder effect in patients from Newfoundland. *Am J Hum Genet* 1994;54:1060.
- Rapaport D, Ziv Y, Rubin M, et al: Primary hyperparathyroidism in children. *J Pediatr Surg* 1986;21:395.
- Ross AJ III: Parathyroid surgery in children. *Prog Pediatr Surg* 1991;26:48.
- Telander RL, Moir CR: Medullary thyroid carcinoma in children. *Semin Pediatr Surg* 1994;3:188.
- The BT, Kytola S, Farnebo F, et al: Mutation analysis of the *MEN1* gene in multiple endocrine neoplasia type 1, familial acromegaly and familial isolated hyperparathyroidism [see comments]. *J Clin Endocrinol Metab* 1998;83:2621.
- Tisell LE, Hedback G, Jansson S, et al: Management of hyperparathyroid patients with grave hypercalcemia. *World J Surg* 1991;15:730.

## Idiopathic Hypoparathyroidism

Idiopathic hypoparathyroidism is caused by failure of the parathyroid glands to produce PTH. Inherited forms of hypoparathyroidism exist. An autosomal dominant type is the result of mutations on chromosome 3q13 in the gene encoding for the G protein-coupled  $\text{Ca}^{2+}$ -sensing receptor, which regulates PTH secretion.<sup>2-4</sup> Hypoparathyroidism is also associated with deletions in chromosome 22q11, the gene responsible for DiGeorge syndrome and cardiac defects.<sup>5,13</sup> Yet another autosomal dominant syndrome consists of hypoparathyroidism, sensorineural deafness, and renal dysplasia.<sup>6</sup> Other autosomal recessive types are associated with growth retardation, seizures, and severe mental retardation.<sup>8,10,11</sup> Lastly, X-linked recessive hypothyroidism has been seen in males.<sup>15,17</sup>

Hypoparathyroidism should be distinguished from pseudohypoparathyroidism, in which production of PTH is increased but the end organs cannot respond to the hormone.

The presenting symptoms of hypoparathyroidism are those of hypocalcemia: tetany, paresthesias, and lethargy. The skin is dry, the hair brittle and scanty. The teeth erupt late and fall out early. Cataracts may be present. Papilledema may occur. Mental retardation is seen in very young children.

Laboratory evaluation reveals low serum calcium levels, and the urinary calcium concentration is diminished. Hypoproteinemia should be considered, as the serum calcium concentration is normally decreased in patients with decreased albumin concentrations. The serum phosphorus concentration is elevated. If a test dose of PTH is administered, urinary phosphate reabsorption falls and levels of plasma cyclic adenosine monophosphate (cAMP) rise.<sup>7</sup>

Radiographs may be normal or may reveal increased radiopacity of the cortices of the long bones. Soft tissue calcification can occur, including in the basal ganglia.<sup>9</sup>

Treatment is administration of vitamin D and PTH.<sup>1,12</sup> Nephrocalcinosis is a known complication of vitamin D therapy, however.<sup>16</sup> Treatment with injectable human PTH alone effectively maintains a normal serum calcium level, with less risk of nephrocalcinosis.<sup>18,19</sup> Infants with hypoparathyroidism complicated by tetany may need calcium infusion. Allograft transplantation of parathyroid cells is investigational at present.<sup>14</sup>

There is no orthopaedic treatment specific to the disease.

## REFERENCES

### Idiopathic Hyperparathyroidism

1. Avioli LV: The therapeutic approach to hypoparathyroidism. *Am J Med* 1974;57:34.
2. Baron J, Winer KK, Yanovski JA, et al: Mutations in the Ca(2+)-sensing receptor gene cause autosomal dominant and sporadic hypoparathyroidism. *Hum Mol Genet* 1996;5:601.
3. De Campo C, Piscopello L, Noacco C, et al: Primary familial hypoparathyroidism with an autosomal dominant mode of inheritance. *J Endocrinol Invest* 1988;11:91.
4. Finegold DN, Armitage MM, Galiani M, et al: Preliminary localization of a gene for autosomal dominant hypoparathyroidism to chromosome 3q13. *Pediatr Res* 1994;36:414.
5. Greig F, Paul E, Di Martino-Nardi J, et al: Transient congenital hypoparathyroidism: resolution and recurrence in chromosome 22q11 deletion. *J Pediatr* 1996;128:563.
6. Hasegawa T, Hasegawa Y, Aso T, et al: HDR syndrome (hypoparathyroidism, sensorineural deafness, renal dysplasia) associated with del(10)(p13). *Am J Med Genet* 1997;73:416.
7. Kruse K, Kracht U: A simplified diagnostic test in hypoparathyroidism and pseudohypoparathyroidism type I with synthetic 1-38 fragment of human parathyroid hormone. *Eur J Pediatr* 1987;146:373.
8. Marsden D, Nyhan WL, Sakati NO: Syndrome of hypoparathyroidism, growth hormone deficiency, and multiple minor anomalies. *Am J Med Genet* 1994;52:334.
9. McLeod DR, Hanley DA, McArthur RG: Autosomal dominant hypoparathyroidism with intracranial calcification outside the basal ganglia. *Am J Med Genet* 1989;32:32.
10. Parvari R, Hershkovitz E, Kanis A, et al: Homozygosity and linkage-disequilibrium mapping of the syndrome of congenital hypoparathyroidism, growth and mental retardation, and dysmorphism to a 1-cM interval on chromosome 1q42-43. *Am J Hum Genet* 1998;63:163.
11. Richardson RJ, Kirk JM: Short stature, mental retardation, and hypoparathyroidism: a new syndrome. *Arch Dis Child* 1990;65:1113.

12. Schilling T, Ziegler R: Current therapy of hypoparathyroidism: a survey of German endocrinology centers. *Exp Clin Endocrinol Diabetes* 1997;105:237.
13. Scire G, Dallapiccola B, Iannetti P, et al: Hypoparathyroidism as the major manifestation in two patients with 22q11 deletions. *Am J Med Genet* 1994;52:478.
14. Tolloczko T, Wozniwicz B, Gorski A, et al: Cultured parathyroid cells allotransplantation without immunosuppression for treatment of intractable hypoparathyroidism. *Ann Transplant* 1996;1:51.
15. Trump D, Dixon PH, Mumm S, et al: Localisation of X linked recessive idiopathic hypoparathyroidism to a 1.5 Mb region on Xq26-q27. *J Med Genet* 1998;35:905.
16. Weber G, Cazzuffi MA, Frisone F, et al: Nephrocalcinosis in children and adolescents: sonographic evaluation during long-term treatment with 1,25-dihydroxycholecalciferol. *Child Nephrol Urol* 1988;9:273.
17. Whyte MP, Weldon VV: Idiopathic hypoparathyroidism presenting with seizures during infancy: X-linked recessive inheritance in a large Missouri kindred. *J Pediatr* 1981;99:608.
18. Winer KK, Yanovski JA, Cutler GB Jr: Synthetic human parathyroid hormone 1-34 vs calcitriol and calcium in the treatment of hypoparathyroidism. *JAMA* 1996;276:631.
19. Winer KK, Yanovski JA, Sarani B, et al: A randomized, cross-over trial of once-daily versus twice-daily parathyroid hormone 1-34 in treatment of hypoparathyroidism. *J Clin Endocrinol Metab* 1998;83:3480.

### Pseudohypoparathyroidism

Pseudohypoparathyroidism is similar to hypoparathyroidism in its clinical and radiographic manifestations but differs in that it does not respond to exogenous PTH administration. The parathyroid glands are hyperplastic and secrete large amounts of the hormone, but the kidneys are resistant to PTH.<sup>6</sup> Bony changes consistent with hyperparathyroidism occur, as the skeleton does respond to the elevated PTH.<sup>5</sup> Thus, findings include hypocalcemia and hyperphosphatemia resembling hypoparathyroidism, and osteitis fibrosa cystica resembling hyperparathyroidism.<sup>5,8</sup> The skeletal changes seen in pseudohypoparathyroidism are also termed Albright's osteodystrophy, since Albright and his associates Burnett, Smith, and Parson were the first to describe the disease.<sup>2</sup>

The etiology is usually genetic. There are four subtypes of pseudohypoparathyroidism, specifically Ia, Ib, Ic, and II. The molecular genetics of the disease type Ia is associated

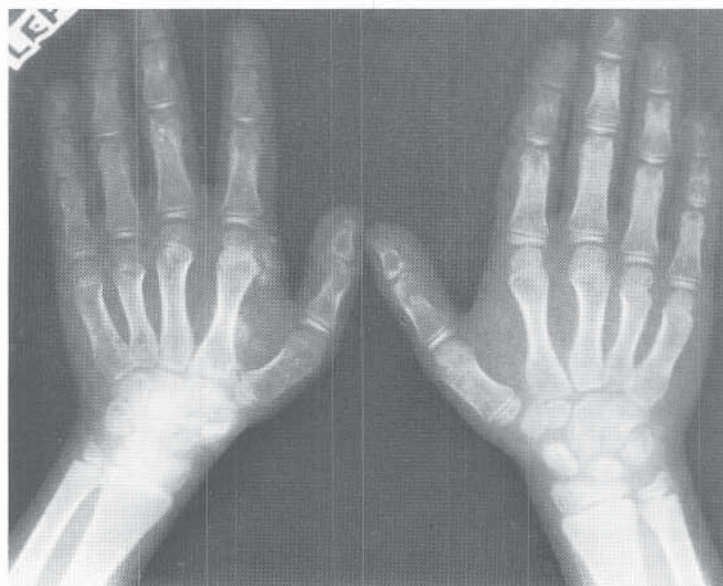


FIGURE 31-19 Pseudohypoparathyroidism. AP radiograph of the hands shows shortening (brachydactyly) of the first, fourth, and fifth metacarpals.

with deficient cellular activity of the alpha-subunit of the guanine nucleotide-binding protein ( $G_s$ , alpha) that stimulates adenylyl cyclase.<sup>1</sup> Many mutations in the  $G_s$  alpha protein gene have been identified.<sup>7,12</sup> Patients with type Ia disease have been found to suffer from multiple endocrinopathies, such as hypothyroidism and growth hormone deficiency.<sup>15</sup>

In type Ib pseudohypoparathyroidism, mutations have been found in chromosome 20q, which contains another stimulatory G protein gene.<sup>9</sup> Yet another genetic association exists between pseudohypoparathyroidism and DiGeorge syndrome, with mutations present on chromosome 22q11.<sup>4</sup>

The clinical appearance of affected infants is normal, with skeletal changes becoming gradually apparent at age 2 to 4 years. There is a characteristic shortening of the metacarpals, especially the first, fourth, and fifth, termed brachydactyly (Fig. 31–19).<sup>3</sup> When the hands are clenched into a fist, dimples are present at the sites of the knuckles of the shortened digits. Multiple exostoses may be present, and the radius may be bowed. Patients are very short, and the facies has been described as moon-shaped. Heterotopic calcifications occur, especially in the periarticular tissues.<sup>13,14</sup> Intracerebral calcifications have also been described.<sup>16</sup> Sensorineural hearing loss is common.<sup>10</sup>

Pseudohypoparathyroidism may be associated with hypothyroidism, Turner's syndrome, and diabetes. Brachydactyly may also be seen in Turner's syndrome and in myositis ossificans progressiva.

The diagnosis is made by injecting PTH. The patient with pseudohypoparathyroidism is unable to respond to the exogenous hormone, so there will not be a rise in serum calcium or urinary phosphate levels, and plasma cAMP will not rise also.<sup>11,17</sup>

Treatment has been with vitamin D, which has led to problems with nephrocalcinosis.<sup>18</sup>

## REFERENCES

### Pseudohypoparathyroidism

- Ahmed SF, Dixon PH, Bonthron DT, et al: *GNAS1* mutational analysis in pseudohypoparathyroidism. *Clin Endocrinol (Oxf)* 1998;49:525.
- Albright F, Burnett CH, Smith PH, et al: Pseudo-hypoparathyroidism, an example of "sea-bright-bantam" syndrome: report of three cases. *Endocrinology* 1942;30:922.
- Cherninkov Z, Cherninkova S: Two cases of pseudohypoparathyroidism in a family with type E brachydactyly. *Radiol Diagn (Berl)* 1989;30:57.
- Craig WJ, Lindsay EA, Bricker JT, et al: Deletion of chromosome 22q11 and pseudohypoparathyroidism. *Am J Med Genet* 1997;72:63.
- Eubanks PJ, Stabile BE: Osteitis fibrosa cystica with renal parathyroid hormone resistance: a review of pseudohypoparathyroidism with insight into calcium homeostasis. *Arch Surg* 1998;133:673.
- Farfel Z, Brickman AS, Kaslow HR, et al: Defect of receptor-cyclase coupling protein in pseudohypoparathyroidism. *N Engl J Med* 1980;303:237.
- Fischer JA, Egert F, Werder E, et al: An inherited mutation associated with functional deficiency of the alpha-subunit of the guanine nucleotide-binding protein  $G_s$  in pseudo- and pseudopseudohypoparathyroidism. *J Clin Endocrinol Metab* 1998;83:935.
- Frame B, Hanson CA, Frost HM, et al: Renal resistance to parathyroid hormone with osteitis fibrosa: "pseudohypoparathyroidism." *Am J Med* 1972;52:311.
- Juppner H, Schipani E, Bastepe M, et al: The gene responsible for pseudohypoparathyroidism type Ib is paternally imprinted and maps in four unrelated kindreds to chromosome 20q13.3. *Proc Natl Acad Sci USA* 1998;95:11798.
- Koch T, Lehnhardt E, Bottinger H, et al: Sensorineural hearing loss owing to deficient G proteins in patients with pseudohypoparathyroidism: results of a multicentre study. *Eur J Clin Invest* 1990;20:416.
- Kruse K, Kracht U: A simplified diagnostic test in hypoparathyroidism and pseudohypoparathyroidism type I with synthetic 1-38 fragment of human parathyroid hormone. *Eur J Pediatr* 1987;146:373.
- Lin CK, Hakakha MJ, Nakamoto JM, et al: Prevalence of three mutations in the  $G_s$  alpha gene among 24 families with pseudohypoparathyroidism type Ia. *Biochem Biophys Res Commun* 1992;189:343.
- Prendiville JS, Lucky AW, Mallory SB, et al: Osteoma cutis as a presenting sign of pseudohypoparathyroidism. *Pediatr Dermatol* 1992;9:11.
- Schuster V, Sandhage K: Intracardiac calcifications in a case of pseudohypoparathyroidism type Ia (PHP-Ia). *Pediatr Cardiol* 1992;13:237.
- Scott DC, Hung W: Pseudohypoparathyroidism type Ia and growth hormone deficiency in two siblings. *J Pediatr Endocrinol Metab* 1995;8:205.
- Siejka SJ, Knezevic WV, Pullan PT: Dystonia and intracerebral calcification: pseudohypoparathyroidism presenting in an eleven-year-old girl. *Aust NZ J Med* 1988;18:607.
- Stirling HF, Darling JA, Barr DG: Plasma cyclic AMP response to intravenous parathyroid hormone in pseudohypoparathyroidism. *Acta Paediatr Scand* 1991;80:333.
- Weber G, Cazzuffi MA, Frisone F, et al: Nephrocalcinosis in children and adolescents: sonographic evaluation during long-term treatment with 1,25-dihydroxycholecalciferol. *Child Nephrol Urol* 1988;9:273.

## Hypervitaminosis D

Hypervitaminosis D is the result of the ingestion of excessive doses of vitamin D.<sup>1,4,6</sup> Patients at risk are those who are taking vitamin D for the treatment of such metabolic bone diseases as vitamin D-resistant rickets and hypoparathyroidism.<sup>9</sup> The elevated vitamin D promotes intestinal absorption of calcium, leading to hypercalcemia. The optimal nutritional requirements for vitamin D in newborns and infants have been established.<sup>7</sup>

## PATHOLOGY

Histologically, wide osteoid seams are found around the trabeculae, resembling what is seen in rickets.<sup>3</sup> The physis, however, is well calcified and normal in width and length. Metastatic calcification may be found in the kidneys, arteries, thyroid, pancreas, lungs, stomach, and brain. Deposition of calcium salts in the kidneys and degenerative changes in the arteries may produce significant morbidity.

## LABORATORY FINDINGS

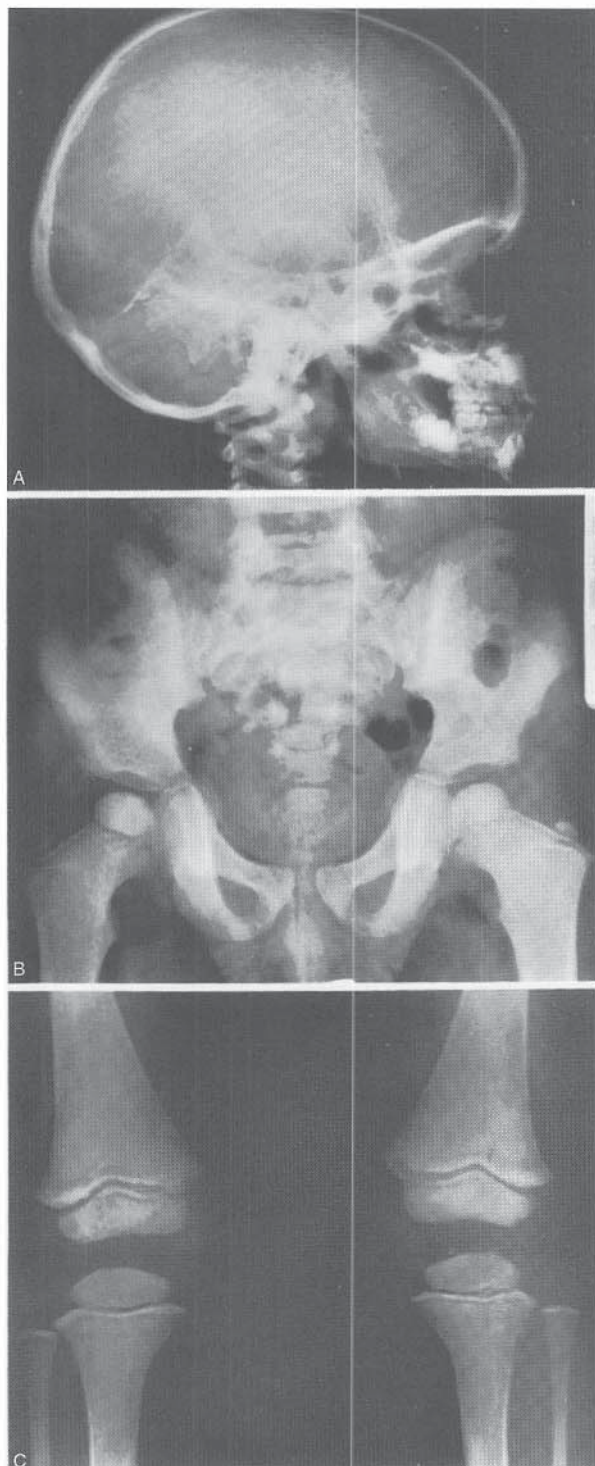
Hypercalcemia can be quite severe. The serum phosphate concentration is normal and the alkaline phosphatase concentration is diminished.<sup>8</sup>

## CLINICAL FEATURES

Anorexia, constipation, nausea and vomiting, polyuria, and thirst are the early manifestations. The child feels very tired. With progression of the intoxication, mental depression and stupor develop. Renal failure and hypertension are common.

## RADIOGRAPHIC FINDINGS

Dense metaphyseal bands are seen in the long bones and result from an increase in the proximal zone of calcification.



**FIGURE 31–20** Hypervitaminosis D in a 5-year-old boy who had taken 50,000 IU of vitamin D per day for the past 14 months. **A**, Lateral views of skull showing metastatic calcification of the cerebral and cerebellar falces. **B** and **C**, AP view of both hips and lower limbs. Note the increased radiopacity of the metaphyses.

The diaphyses show osteopenia due to demineralization. Osteosclerosis is visible at the base of the skull. There may be premature closure of the sutures. The vertebral end-plates are dense. Metastatic calcifications are seen in soft tissues (Fig. 31–20).<sup>2,5</sup>

## TREATMENT

Treatment is medical and consists of immediate cessation of vitamin D supplements. Diuretics are given, with replacement of volume with saline. Dehydration can be fatal, and serum electrolyte levels must be carefully monitored. Steroids inhibit calcium absorption in the kidney and gut and are helpful in correcting the calcium level.<sup>11</sup> Bisphosphonates inhibit bone resorption and have been helpful in treating vitamin D intoxication.<sup>10</sup> Sodium phosphate should not be given, as its administration leads to ectopic calcification.

## REFERENCES

### Hypervitaminosis D

- Blank S, Scanlon KS, Sinks TH, et al: An outbreak of hypervitaminosis D associated with the overfortification of milk from a home-delivery dairy. *Am J Public Health* 1995;85:656.
- Christensen WB, Liebman C, Sosman MC: Skeletal and periarticular manifestations of hypervitaminosis D. *AJR Am J Roentgenol* 1951; 65:27.
- Ham AW, Lewis MD: Hypervitaminosis D rickets: the action of vitamin D. *Br J Exp Pathol* 1934;15:228.
- Harris LJ: The mode of action of vitamin D: the “parathyroid” theory. *Clinical hypervitaminosis*. *Lancet* 1932;1:1031.
- Holman CB: Roentgenologic manifestations of vitamin D intoxication. *Radiology* 1952;59:805.
- Jacobus CH, Holick MF, Shao Q, et al: Hypervitaminosis D associated with drinking milk [see comments]. *N Engl J Med* 1992;326: 1173.
- Mehls O, Wolf H, Wille L: Vitamin D requirements and vitamin D intoxication in infancy. *Int J Vitam Nutr Res Suppl* 1989;30:87.
- Payne WR: The blood chemistry in idiopathic hypercalcemia. *Arch Dis Child* 1952;27:302.
- Schilling T, Ziegler R: Current therapy of hypoparathyroidism: a survey of German endocrinology centers. *Exp Clin Endocrinol Diabetes* 1997;105:237.
- Selby PL, Davies M, Marks JS, et al: Vitamin D intoxication causes hypercalcaemia by increased bone resorption which responds to pamidronate. *Clin Endocrinol* 1995;43:531.
- Winberg J, Zetterstrom R: Cortisone treatment in vitamin D intoxication. *Acta Paediatr (Uppsala)* 1956;45:96.

## Scurvy

Scurvy is caused by a nutritional deficiency of vitamin C (ascorbic acid).<sup>15</sup> The disease is quite rare and now is most commonly seen in patients who are following extreme diets, such as patients with anorexia nervosa.<sup>11,12</sup> Historically, scurvy was described in sailors whose diets lacked vitamin C during long sea voyages.<sup>19</sup>

## PATHOLOGY

When vitamin C is deficient, collagen synthesis is impaired.<sup>2,6</sup> Vitamin C is necessary for the hydroxylation of lysine and proline to hydroxylysine and hydroxyproline, two amino acids crucial to the proper cross-linking of the triple helix of collagen.<sup>15</sup> The result is primitive collagen formation, seen throughout the body, including in the blood vessels, which predisposes to hemorrhages.

The osteoblasts become dysfunctional, resulting in a failure to produce osteoid tissue and form new bone. The chondroblasts, however, continue to function normally, and

mineralization is unaffected. This leads to a persistence of cartilage cells, and calcified chondroid approaches the metaphysis. Radiographically, this is seen as an opaque white line at the junction of the physis and metaphysis, termed Fränkel's line.

Generalized osteoporosis results from lack of osteoid and new bone. Osteoclasts are normal, but osteoblasts become flattened, resembling connective tissue fibroblasts. The bone trabeculae and the cortices of the long bones are thin and fragile.

Hemorrhages and fractures are common, but the attempt at repair of these injuries is disorderly. The provisional zone of calcification is weak, leading to epiphyseal separations.

In the teeth, dentin formation is abnormal because of the defective collagen.

### CLINICAL FEATURES

Scurvy develops after 6 to 12 months of dietary deprivation of vitamin C. For this reason, it is not seen in neonates. Early manifestations consist of loss of appetite, irritability, and failure to thrive. Hemorrhage of the gums is common, and they become bluish in color and swollen. Subperiosteal hemorrhage is a distinctive sign, occurring most commonly in the distal femur and tibia and the proximal humerus.<sup>7</sup> The limbs become exquisitely tender, so much so that the baby screams on movement of the affected areas. The child lies still in the frog-leg position to minimize pain, called pseudoparalysis. The limbs are swollen and bruised. Beading of the ribs at the costochondral

junctions may occur. Hemorrhages may also develop in the soft tissues, including the joints,<sup>10</sup> the kidneys, and the gut, and petechiae may be seen.<sup>9,21</sup> The hair takes on a coiled appearance.<sup>14</sup> Anemia and impaired wound healing are common.

### RADIOGRAPHIC FINDINGS

The changes of scurvy are best seen at the knees, wrists, and proximal humeri (Fig. 31–21).<sup>3,4</sup> Osteopenia is the first change seen, with thinning of the cortices. The zone of provisional calcification increases in width and opacity (Fränkel's line) due to failure of resorption of the calcified cartilaginous matrix, and stands out compared to the severely osteopenic metaphyses. The margins of the epiphyses appear relatively sclerotic, termed "ringing of the epiphyses" or "Wimberger's sign." Lateral spur formation at the ends of the metaphysis is produced by the outward projection of the zone of provisional calcification. The "scurvy line" or "scorbutic zone" is a radiolucent transverse band adjacent to the dense provisional zone. The corner or "angle" sign of scurvy is a peripheral metaphyseal cleft due to a defect in the spongiosa and cortex adjacent to the provisional zone of calcification. Epiphyseal separation may occur.<sup>13,17,18</sup>

Subperiosteal hemorrhage occurs most commonly at the femur, tibia, or humerus and is initially seen as an increase in soft tissue density. The hemorrhages become radiodense as the scurvy is treated and the lesions calcify.

The development of a physeal bar in a patient with scurvy has been described.<sup>8</sup>

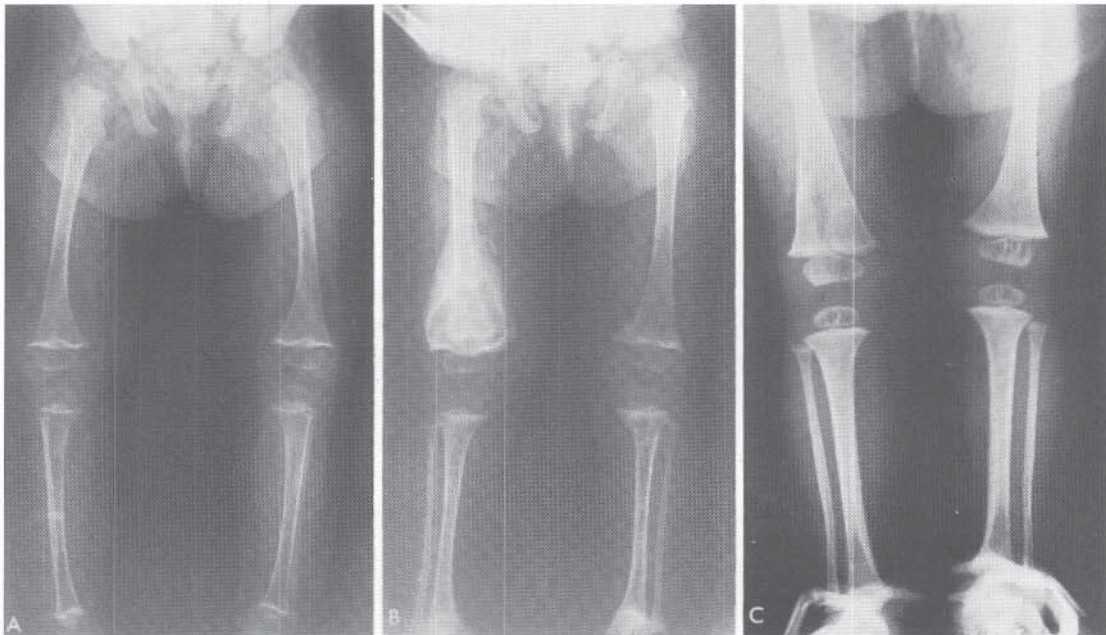


FIGURE 31–21 Scurvy in a 10-month-old infant. **A**, AP radiograph of both lower limbs demonstrates early changes in the scorbutic bones. Note the generalized osteoporosis with rarefaction of the spongiosa and atrophy of the cortex. There is relatively increased opacity of the provisional zones of calcification at the ends of the metaphyses and around the margins of the epiphyseal centers of ossification ("ringing of the epiphyses"). **B**, Two weeks after treatment with ascorbic acid, marked calcification of subperiosteal hematoma of the right femur has occurred. Such minimal calcification is also evident in the medial aspects of the distal left femoral shaft and proximal left tibia. Note the multiple metaphyseal spur formation. **C**, Three months later there are further radiographic signs of healing scurvy. The cortices have become thicker and the spongiosa are of almost normal density. Note the persistence of rarefaction in the epiphyseal centers.

## DIFFERENTIAL DIAGNOSIS

The most common entity that scurvy is mistaken for is osteomyelitis. The symptoms of pain, tenderness, subperiosteal soft tissue swelling, and pseudoparalysis resemble symptoms of infection. Because infection is common and scurvy is extremely rare, the condition can be misdiagnosed initially. The sedimentation rate, C-reactive protein level, and white blood cell count are normal in scurvy, however. Other diagnoses to be considered for this clinical picture include polio,<sup>16</sup> leukemia, and purpuric conditions such as Henoch-Schönlein purpura and thrombocytopenic purpura. Syphilis may be suspected<sup>20</sup> but usually presents earlier.

Serum levels of vitamin C may be difficult to interpret in scurvy. A more reliable test is the absence of vitamin C in the buffy coat of centrifuged blood.

## TREATMENT

Treatment is administration of vitamin C. Rapid recovery is usual, with pain and tenderness resolving.

Scurvy is prevented by an adequate intake of vitamin C, defined as 50 mg/day for infants and children and 75 to 100 mg/day for adults. Intoxication does not occur.

## REFERENCES

### Scurvy

- Baker EM, Hodges RE, Hood J, et al: Metabolism of ascorbic-1-14C acid in experimental human scurvy. 1969 [classical article]. *Nutrition* 1993;9:75. Originally published in *Am J Clin Nutr* 1969;22:549.
- Banks SW: Bone changes in acute and chronic scurvy: experimental study. *J Bone Joint Surg* 1943;25:553.
- Brailsford JW: Some radiological manifestations of early scurvy. *Arch Dis Child* 1953;28:31.
- Bromer RS: A critical analysis of the roentgen signs of infantile scurvy. *AJR Am J Roentgenol* 1943;49:575.
- Dunn PM: James Lind (1716–94) of Edinburgh and the treatment of scurvy. *Arch Dis Child Fetal Neonatal Ed* 1997;76:F64.
- Follis RH: Histochemical studies on cartilage and bone. II. Ascorbic acid deficiency. *Bull Johns Hopkins Hosp* 1951;89:9.
- Gabay C, Voskuyl AE, Cadiot G, et al: A case of scurvy presenting with cutaneous and articular signs. *Clin Rheumatol* 1993;12:278.
- Hoeffel JC, Lascombes P, Mainard L, et al: Cone epiphysis of the knee and scurvy. *Eur J Pediatr Surg* 1993;3:186.
- Kronauer CM, Buhler H: Images in clinical medicine: skin findings in a patient with scurvy. *N Engl J Med* 1995;332:1611.
- Leone J, Delhinger V, Maes D, et al: Rheumatic manifestations of scurvy: a report of two cases. *Rev Rhum Engl Ed* 1997;64:428.
- McKenna KE, Dawson JF: Scurvy occurring in a teenager. *Clin Exp Dermatol* 1993;18:75.
- Mehta CL, Cripps D, Bridges AJ: Systemic pseudovasculitis from scurvy in anorexia nervosa. *Arthritis Rheum* 1996;39:532.
- Nerubay J, Pilderwasser D: Spontaneous bilateral distal femoral physiolysis due to scurvy. *Acta Orthop Scand* 1984;55:18.
- Oeffinger KC: Scurvy: more than historical relevance. *Am Fam Physician* 1993;48:609.
- Peterkofsky B: Ascorbate requirement for hydroxylation and secretion of procollagen: relationship to inhibition of collagen synthesis in scurvy. *Am J Clin Nutr* 1991;54:1135S.
- Ramar S, Sivaramakrishnan V, Manoharan K: Scurvy: a forgotten disease. *Arch Phys Med Rehabil* 1993;74:92.
- Silverman FN: Recovery from epiphyseal invagination: sequel to an unusual complication of scurvy. *J Bone Joint Surg* 1970;52-A:384.
- Silverman FN: An unusual osseous sequel to infantile scurvy. *J Bone Joint Surg* 1953;35-A:215.
- Thomas DP: Sailors, scurvy and science. *J R Soc Med* 1997;90:50.
- Toohey JS: Skeletal presentation of congenital syphilis: case report and review of the literature. *J Pediatr Orthop* 1985;5:104.
- Wirth PB, Kalb RE: Follicular purpuric macules of the extremities. *Scurvy. Arch Dermatol* 1990;126:385.

## Hypervitaminosis A

Vitamin A is a fat-soluble vitamin whose primary biologic functions are concerned with skeletal growth, maintenance and regeneration of epithelial tissues, and preservation of visual purple in the retina. It is also necessary for membrane stability. The normal plasma level for vitamin A is 80 to 100 IU/100 mL. Hypervitaminosis A is very rare, and usually results from inappropriate use of vitamin supplements.<sup>1,8,14</sup> Retinoids used for acne also contain vitamin A and can lead to toxicity.<sup>2,12,15</sup>

## CLINICAL FEATURES

Clinically, the soft tissues overlying the hyperostotic bones are swollen and tender. Proliferation of basal cells and hyperkeratinization cause dry, itchy skin.<sup>9</sup> Anorexia, vomiting, and lethargy are caused by increased intracranial pressure.<sup>3</sup> The child fails to thrive. Hepatomegaly with cirrhosis-like liver damage or splenomegaly may be present.<sup>5</sup>

## RADIOGRAPHIC FINDINGS

The development of bony changes in patients with hypervitaminosis A is slow, so that radiographs are normal initially. For this reason, radiographs are normal in young children less than 1 year old. Once changes do occur, there is periosteal hyperostosis and thickening of the cortex of the long bones.<sup>4</sup> The ulna, radius, metacarpals, and metatarsals are particularly affected. The mandible is spared, a fact that distinguishes hypervitaminosis A from Caffey's disease. Subperiosteal new bone formation is seen (Fig. 31–22). Bone scintigraphy shows increased uptake. Premature partial or complete physal closure may be present.<sup>10,11,13</sup>

## DIAGNOSIS

The diagnosis is made by determining the plasma level of vitamin A, which will be elevated 5 to 15 times the normal value. Hypercalcemia can be present.<sup>6,7</sup> Hypervitaminosis A must be differentiated from infantile cortical hyperostosis (Caffey's disease), scurvy, and congenital syphilis.

## TREATMENT

Treatment entails total cessation of administration of vitamin A and eliminating all foods containing vitamin A from the diet. Because of the great body reserves of vitamin A, the hyperostosis will disappear only after a long period of time, although the systemic symptoms resolve quickly. Growth of the long bones should be followed, as premature physal closure may not become apparent for years following the initial insult.

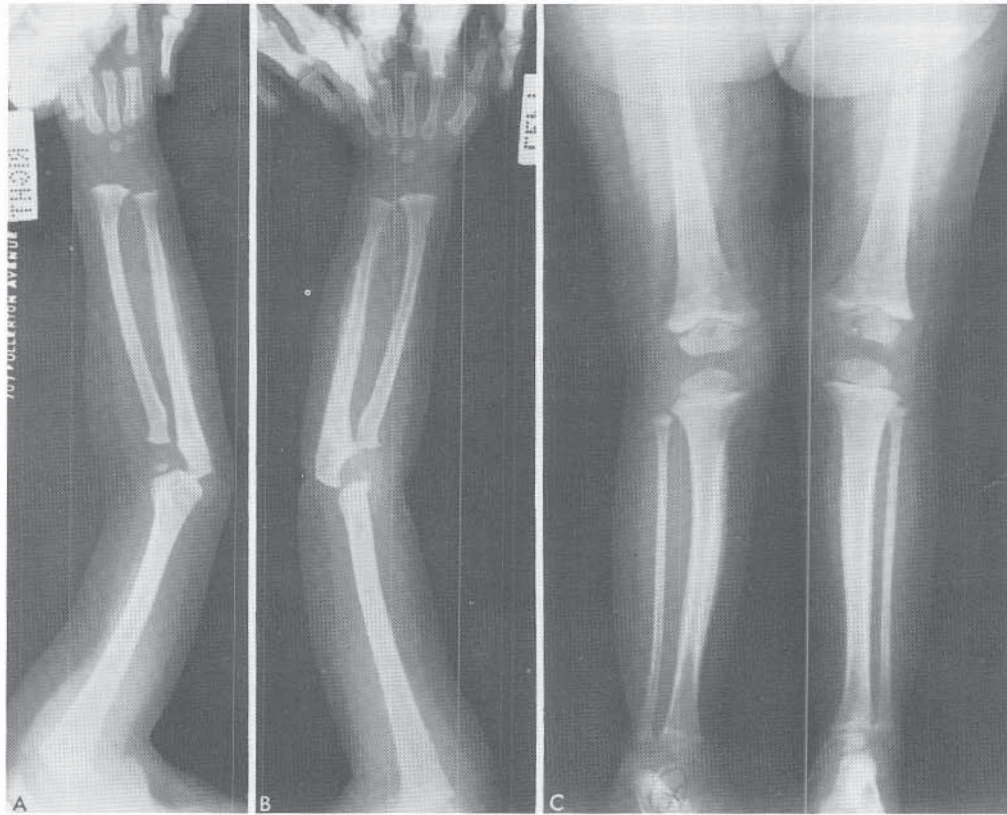


FIGURE 31-22 Hypervitaminosis A in a 2-year-old child. Note the subperiosteal new bone formation and cortical thickening of both tibiae and both ulnae. The mandible and other facial bones are not affected. A and B, Radiographs of right and left forearms. C, Radiograph of both lower limbs.

## REFERENCES

### Hypervitaminosis A

1. Bendich A, Langseth L: Safety of vitamin A. *Am J Clin Nutr* 1989;49:358.
2. Bergman SM, O'Mailia J, Krane NK, et al: Vitamin-A-induced hypercalcemia: response to corticosteroids. *Nephron* 1988;50:362.
3. Bhattay EM, Bakst CM: Hypervitaminosis A causing benign intracranial hypertension: a case report. *S Afr Med J* 1988;74:584.
4. Caffey J: Chronic poisoning due to excess of vitamin A: description of clinical and roentgen manifestations in seven infants and young children. *AJR Am J Roentgenol* 1951;65:12.
5. Fallon MB, Boyer JL: Hepatic toxicity of vitamin A and synthetic retinoids. *J Gastroenterol Hepatol* 1990;5:334.
6. Fisher G, Skillern PG: Hypercalcemia due to hypervitaminosis A. *JAMA* 1974;227:1413.
7. Frame B, Jackson CE, Reynolds WA, et al: Hypercalcemia and skeletal effects in chronic hypervitaminosis A. *Ann Intern Med* 1974;80:44.
8. Gamble JG, Ip SC: Hypervitaminosis A in a child from megadosing. *J Pediatr Orthop* 1985;5:219.
9. Goskowitz M, Eichenfield LF: Cutaneous findings of nutritional deficiencies in children. *Curr Opin Pediatr* 1993;5:441.
10. Milstone LM, McGuire J, Ablow RC: Premature epiphyseal closure in a child receiving oral 13-cis-retinoic acid. *J Am Acad Dermatol* 1982;7:663.
11. Pease CN: Focal retardation and arrestment of growth of bones due to vitamin A intoxication. *JAMA* 1962;182:980.
12. Pennes DR, Ellis CN, Madison KC, et al: Early skeletal hyperostoses secondary to 13-cis-retinoic acid. *AJR Am J Roentgenol* 1984;142:979.
13. Ruby LK, Mital MA: Skeletal deformities following chronic hypervitaminosis A: a case report. *J Bone Joint Surg* 1974;56-A:1283.
14. Scherl S, Goldberg NS, Volpe L, et al: Overdosage of vitamin A supplements in a child. *Cutis* 1992;50:209.
15. Silverman AK, Ellis CN, Voorhees JJ: Hypervitaminosis A syndrome: a paradigm of retinoid side effects. *J Am Acad Dermatol* 1987;16:1027.

## Hypophosphatasia

Hypophosphatasia is a rare, genetically determined error of metabolism in which there is a deficiency of alkaline phosphatase in the plasma and tissues, leading to abnormal mineralization of bone. There is wide variation in the severity of the disease, with the prognosis related to the age at onset. Several forms of hypophosphatasia exist—perinatal, infantile, childhood, and adult.<sup>1,10</sup>

### INHERITANCE

The gene for hypophosphatasia is the tissue-nonspecific alkaline phosphatase gene (*TNSALP*). Many different mutations have been described within the *TNSALP* gene.<sup>2,4,6</sup> Autosomal recessive inheritance seems to lead to the lethal perinatal form and the infantile type, while autosomal dominant transmission produces milder phenotypes. Heterozygous carriers for hypophosphatasia can be detected by abnormally diminished alkaline phosphatase concentrations in the plasma.

### PATHOLOGY

The pathology seen in hypophosphatasia closely resembles that seen in patients with rickets. Osteoid production proceeds unharmed, but without alkaline phosphatase, mineral-



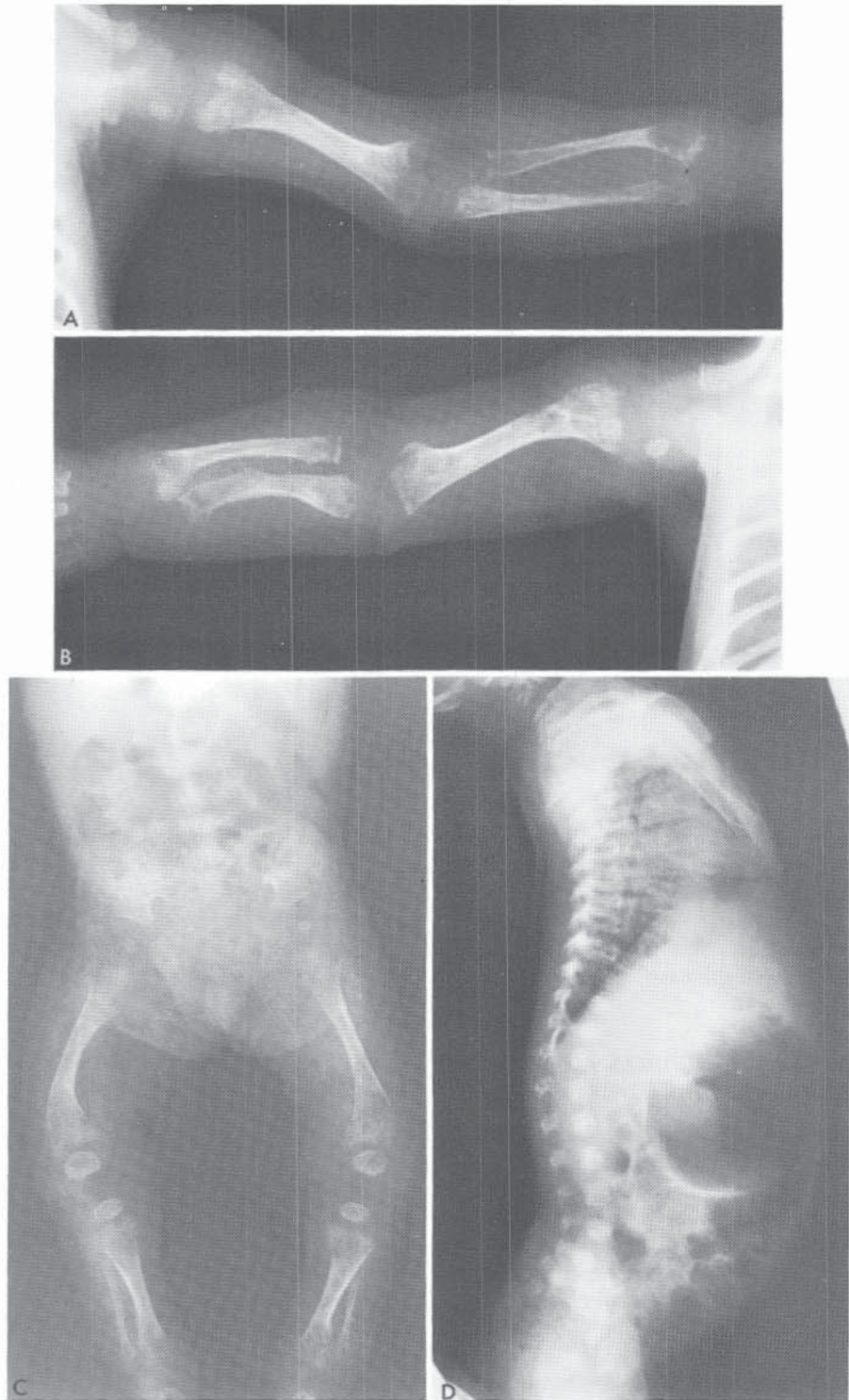


FIGURE 31-23 Typical radiographic changes of hypophosphatasia in a 4-month-old infant. A and B, Both upper limbs. C, Lower limbs. D, Spine (see text for discussion).

*Illustration continued on following page*

ization of the osteoid cannot occur.<sup>12</sup> This leads to widening of the physis, with persistence of the provisional zone of calcification (which cannot calcify) and islands of cartilage continuing down into the metaphysis. The normal columnar arrangement of the chondrocytes of the growth plate is disturbed.

If hypercalcemia is present, heterotopic calcification can occur, especially in the kidney.

#### LABORATORY FINDINGS

The hallmark of hypophosphatasia is a decrease in or lack of alkaline phosphatase. The enzyme is decreased not only in serum but also in such tissues as the kidneys, bones, leukocytes, and spleen. Serum phosphorus, vitamin D, and PTH levels are normal, but hypercalcemia may be present, especially in young children. Characteristic findings in the

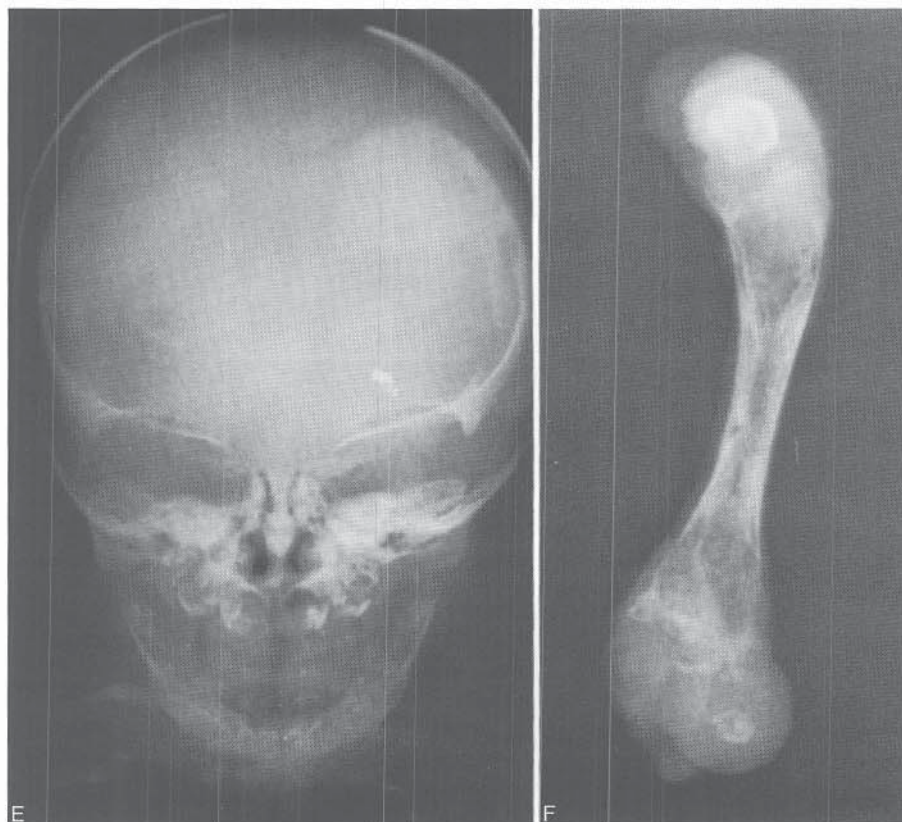


FIGURE 31–23 *Continued.* E, Skull. F, Femur, obtained at autopsy (see text for discussion).

urine are elevated levels of phosphoethanolamine (which may be elevated in other endocrinopathies) and inorganic pyrophosphate. Pyridoxal-5'-phosphate levels are also increased in hypophosphatasia in relation to disease severity.<sup>7</sup>

Disease carriers have been found to have decreased serum alkaline phosphatase levels and increased urinary pyrophosphate levels.<sup>9</sup>

### CLINICAL FEATURES AND RADIOGRAPHIC FINDINGS

**Perinatal Hypophosphatasia.** The clinical findings vary with the age at which the disease manifests. In the severe perinatal (or congenital) form, the babies may be stillborn. If they survive birth, they usually succumb to respiratory infections in early infancy.

Radiographs of babies with perinatal hypophosphatasia reveal diffuse, severe demineralization of the entire skeleton (Fig. 31–23). Ossification of the skull is incomplete, and the suture lines are very wide. The ribs are unossified at the ends and slender in the middle. The pelvis is small, soft, and poorly mineralized. The vertebral bodies are paper thin and the neural arches cannot be seen. The long bones have jagged, rarefied defects extending into the metaphysis.

**Infantile Hypophosphatasia.** The onset of symptoms in the infantile form is later in infancy, usually around 6 months of age. The children fail to thrive, experiencing anorexia, vomiting, dehydration, fever, hypotonia, and sometimes seizures.

Demineralization of the bones is still present but is not as marked as in the perinatal form. The bones look rachitic, with widened physes, bossing of the skull, bowing of the

ribs, and flaring of the metaphyses of the long bones and costochondral junctions. Lucent streaks in the metaphyses represent nests of unossified physal cartilage. Fractures and bowing of the extremities are common. The cranial sutures are initially wide but close prematurely, leading to increased intracranial pressure.

Dentition is poor, and the primary teeth fall out very early.<sup>3,11</sup> Hypercalcemia may cause renal calcinosis. Renal failure and hypertension then follow.

Children who survive early infancy tend to improve clinically with time. Stature is normal in the infant, but as the child matures, dwarfism due to lack of normal enchondral bone growth becomes noticeable.

**Adult Hypophosphatasia.** A rare adult form of hypophosphatasia exists. Clinically, the disease usually becomes apparent with a fracture. Osteomalacia is present.

### PRENATAL DIAGNOSIS

Hypophosphatasia can be diagnosed in fetuses. Ultrasound shows deficient ossification of the fetal skull.<sup>8</sup> A definitive diagnosis can be established through amniocentesis and molecular genetic testing, looking for mutations in *TNSALP* in at-risk infants.<sup>5</sup>

### DIFFERENTIAL DIAGNOSIS

Hypophosphatasia is most commonly confused with severe type II osteogenesis imperfecta because of the presence of birth fractures and the severe demineralization. Thanatophoric dwarfism and achondrogenesis can also resemble the perinatal form of hypophosphatasia.

Less severe forms of hypophosphatasia should be differentiated from the various types of rickets. In rickets, the alkaline phosphatase concentration is generally increased, whereas in hypophosphatasia it is by definition decreased or not measurable.

## TREATMENT

Currently no successful treatment is available for hypophosphatasia. If the diagnosis of rickets is mistakenly made, treatment with vitamin D can worsen the heterotopic calcification and nephrocalcinosis. Enzyme replacement therapy is not yet available.

Fractures require orthopaedic referral. Healing of fractures is generally quite delayed in hypophosphatasia. Occasionally, multiple osteotomies with intramedullary fixation, as one would do in cases of severe osteogenesis imperfecta, are needed to correct bowing and lend structural support to the long bones.

## REFERENCES

### Hypophosphatasia

- Bardin T: Renal osteodystrophy, disorders of vitamin D metabolism, and hypophosphatasia. *Curr Opin Rheumatol* 1992;4:389.
- Cai G, Michigami T, Yamamoto T, et al: Analysis of localization of mutated tissue-nonspecific alkaline phosphatase proteins associated with neonatal hypophosphatasia using green fluorescent protein chimeras. *J Clin Endocrinol Metab* 1998;83:3936.
- Chapple IL: Hypophosphatasia: dental aspects and mode of inheritance. *J Clin Periodontol* 1993;20:615.
- Greenberg CR, Taylor CL, Haworth JC, et al: A homoallelic Gly317→Asp mutation in ALPL causes the perinatal (lethal) form of hypophosphatasia in Canadian Mennonites. *Genomics* 1993;17:215.
- Henthorn PS, Whyte MP: Infantile hypophosphatasia: successful prenatal assessment by testing for tissue-nonspecific alkaline phosphatase isoenzyme gene mutations. *Prenat Diagn* 1995;15:1001.
- Henthorn PS, Whyte MP: Missense mutations of the tissue-nonspecific alkaline phosphatase gene in hypophosphatasia. *Clin Chem* 1992;38:2501.
- Iqbal SJ, Brain A, Reynolds TM, et al: Relationship between serum alkaline phosphatase and pyridoxal-5'-phosphate levels in hypophosphatasia. *Clin Sci (Colch)* 1998;94:203.
- Kleinman G, Uri M, Hull S, et al: Perinatal ultrasound casebook: antenatal findings in congenital hypophosphatasia. *J Perinatol* 1991;11:282.
- Macfarlane JD, Poorthuis BJ, Mulivor RA, et al: Raised urinary excretion of inorganic pyrophosphate in asymptomatic members of a hypophosphatasia kindred. *Clin Chim Acta* 1991;202:141.
- Ramage IJ, Howatson AJ, Beattie TJ: Hypophosphatasia. *J Clin Pathol* 1996;49:682.
- Watanabe H, Umeda M, Seki T, et al: Clinical and laboratory studies of severe periodontal disease in an adolescent associated with hypophosphatasia: a case report. *J Periodontol* 1993;64:174.
- Whyte MP: Hypophosphatasia and the role of alkaline phosphatase in skeletal mineralization. *Endocr Rev* 1994;15:439.

### Hyperphosphatasia

Hyperphosphatasia is an extremely rare bone dysplasia characterized by failure to replace immature woven bone with mature lamellar bone. Biochemically, serum levels of alkaline phosphatase are increased (hence the name hyperphosphatasia), as is the urinary excretion of hydroxyproline. The disease is transmitted as an autosomal recessive trait.

Clinically, the long bones are bowed and prone to stress fractures due to osteopenia and decreased biomechanical

strength of the bone.<sup>3</sup> The patient's head is enlarged. Presenting complaints are painful swelling of the limbs and bowing. Muscle mass appears diminished, and the limbs may be warm. Affected children are very short.

Radiographic findings include generalized diaphyseal expansion of the bones with subperiosteal new bone deposition.<sup>10</sup> Fractures are transverse and are usually nondisplaced. The spine and pelvis show patchy areas of sclerosis. The base and vault of the skull are thickened.

Pathologic studies of the bone tissue show extensive fibrosis of the marrow with cellular hyperactivity. There is evidence of both increased bone resorption and bone formation resembling fibrous dysplasia.<sup>6,9</sup> There may be a mosaic pattern of cement lines resembling what is seen in Paget's disease.<sup>5</sup>

Conditions from which hyperphosphatasia must be distinguished include Camurati-Engelmann disease, craniodiaphyseal dysplasia, and fibrous dysplasia. Hyperphosphatasia can be differentiated from all these conditions by the distinct elevation in serum alkaline phosphatase concentration.

Treatment previously consisted of administering thyrocalcitonin.<sup>14</sup> Recently, successful treatment of the disease has been described with use of bisphosphonates, such as pamidronate and etidronate.<sup>2,7-9</sup>

## REFERENCES

### Hyperphosphatasia

- Blanco O, Stivel M, Mautalen C, et al: Familial idiopathic hyperphosphatasia: a study of two young siblings treated with porcine calcitonin. *J Bone Joint Surg* 1977;59-B:421.
- Cassinelli HR, Mautalen CA, Heinrich JJ, et al: Familial idiopathic hyperphosphatasia (FIH): response to long-term treatment with pamidronate (APD). *Bone Miner* 1992;19:175.
- Dohler JR, Souter WA, Beggs I, et al: Idiopathic hyperphosphatasia with dermal pigmentation: a twenty-year follow-up. *J Bone Joint Surg* 1986;68-B:305.
- Dunn V, Condon VR, Rallison ML: Familial hyperphosphatasemia: diagnosis in early infancy and response to human thyrocalcitonin therapy. *AJR Am J Roentgenol* 1979;132:541.
- Eyring EJ, Eisenberg E: Congenital hyperphosphatasia: a clinical, pathological and biochemical study of two cases. *J Bone Joint Surg* 1968;50-A:1099.
- Pazzaglia UE, Barbieri D, Beluffi G, et al: Chronic idiopathic hyperphosphatasia and fibrous dysplasia in the same child. *J Pediatr Orthop* 1989;9:709.
- Silve C: Hereditary hypophosphatasia and hyperphosphatasia. *Curr Opin Rheumatol* 1994;6:336.
- Singer F, Siris E, Shane E, et al: Hereditary hyperphosphatasia: 20 year follow-up and response to disodium etidronate. *J Bone Miner Res* 1994;9:733.
- Spindler A, Berman A, Mautalen C, et al: Chronic idiopathic hyperphosphatasia: report of a case treated with pamidronate and a review of the literature. *J Rheumatol* 1992;19:642.
- Whalen JP, Horwith M, Krook L, et al: Calcitonin treatment in hereditary bone dysplasia with hyperphosphatasemia: a radiographic and histologic study of bone. *AJR Am J Roentgenol* 1977;129:29.

### Pituitary Dwarfism

A deficiency in the somatotrophic hormone is due to congenital hypoplasia or aplasia of the eosinophilic cells in about two-thirds of cases of hypopituitarism. It is often a hereditary disorder, and four forms exist, with autosomal recessive, autosomal dominant, and X-linked types.<sup>4,7,8</sup> In the remaining cases, cessation of growth results from destructive

lesions of the anterior pituitary, most commonly a craniopharyngeoma.

### CLINICAL FEATURES

In the congenital forms, the infant is of normal size, but diminished growth is noted around age 2 to 4 years. The limbs are of normal proportion in relation to the head and trunk. Intelligence is normal. The condition can be associated with hypogonadism and a delay in or absence of sexual maturation.<sup>2,9</sup>

In the acquired form caused by a pituitary lesion, signs of neurologic deficit such as impaired vision, ocular disturbances, and pathologic sleepiness are present.

### RADIOGRAPHIC FINDINGS

In congenital hypopituitarism, skeletal maturation is delayed. The ossification centers are late in both their appearance and closure. Osteoporosis of the long bones and the skull is present. The fontanelles close later than normal.

Where there is a lesion in the pituitary, radiographs will reveal an enlargement of the sella turcica, the home of the pituitary. Intraseellar or suprasellar calcification suggests craniopharyngeoma.

MRI is especially useful in visualizing the pituitary. Enlargement, hypoplasia, or tumor can be seen.<sup>1,6</sup>

### DIAGNOSIS

Serum levels of growth hormone will be low or absent. Because low levels are normal in healthy children, a stimulatory test is usually needed to confirm the lack of growth hormone.<sup>5</sup> Insulin or L-arginine is administered to produce hypoglycemia, which stimulates the release of growth hormone. Growth hormone levels do not increase in patients with pituitary dwarfism after administration of these agents.

### TREATMENT

Pituitary dwarfism is treated by administration of synthetic growth hormone.<sup>3,10</sup> This treatment stimulates growth and should be monitored by a pediatric endocrinologist. Patients with growth hormone deficiency following resection of craniopharyngeomas rarely have an isolated deficiency in growth hormone, so additional hormone replacement therapy is necessary, under the guidance of the endocrinologist. Some children with growth hormone deficiency have developed panhypopituitarism in adulthood, with hypothyroidism and abnormalities in antidiuretic hormone. On rare occasion, referral to the orthopaedic surgeon is needed for treatment of slipped capital femoral epiphysis.

### REFERENCES

#### Pituitary Dwarfism

- Desai MP, Mehta RU, Choksi CS, et al: Pituitary enlargement on magnetic resonance imaging in congenital hypothyroidism. *Arch Pediatr Adolesc Med* 1996;150:623.
- Goodman HG, Grumbach MB, Kaplan SL: Growth and growth hormone. II. A comparison of isolated growth hormone, hormone deficiency, and multiple pituitary hormone deficiencies in 35 patients with idiopathic hypopituitary dwarfism. *N Engl J Med* 1968;278:57.

- Henneman PH: The effect of human growth hormone on growth of patients with hypopituitarism: a combined study. *JAMA* 1968;205:828.
- Lagerstrom-Fermer M, Sundvall M, Johnsen E, et al: X-linked recessive panhypopituitarism associated with a regional duplication in Xq25-q26. *Am J Hum Genet* 1997;60:910.
- Lin T, Tucci JR: Provocative tests of growth-hormone release: a comparison of results with seven stimuli. *Ann Intern Med* 1974;80:464.
- Pellini C, di Natale B, De Angelis R, et al: Growth hormone deficiency in children: role of magnetic resonance imaging in assessing aetiopathogenesis and prognosis in idiopathic hypopituitarism [see comments]. *Eur J Pediatr* 1990;149:536.
- Perez Jurado LA, Argente J: Molecular basis of familial growth hormone deficiency. *Horm Res* 1994;42:189.
- Raskin S, Cogan JD, Summar ML, et al: Genetic mapping of the human pituitary-specific transcriptional factor gene and its analysis in familial panhypopituitary dwarfism. *Hum Genet* 1996;98:703.
- Root AW, Bongiovanni AM, Eberlein WR: Diagnosis and management of growth retardation with special reference to the problem of hypopituitarism. *J Pediatr* 1971;78:737.
- Rosenfeld RG, Kemp SF, Gaspich S, et al: In vivo modulation of somatomedin receptor sites: effects of growth hormone treatment of hypopituitary children. *J Clin Endocrinol Metab* 1981;52:759.

## Hypothyroidism

Thyroid hormone deficiency may be congenital or acquired. The degree of deficiency, age at onset, and duration of the deficiency are all factors that determine the severity of disease. Hypothyroidism is fairly common, with an incidence of one per 4,000 newborns.<sup>18</sup>

Congenital hypothyroidism, previously known as cretinism, is characterized by dwarfism and mental retardation. It is more common in girls than in boys.

### ETIOLOGY

The usual cause of congenital hypothyroidism is a structural abnormality in the thyroid gland. The abnormalities range from aplasia of the thyroid, hypoplasia, and goiter to ectopic thyroid tissue. There are familial forms of hypothyroidism, which are being delineated through molecular genetic research.<sup>1,10,21,29</sup>

### CLINICAL FEATURES

Symptoms in early infancy include prolonged jaundice, lethargy, sleepiness, feeding difficulties, and constipation. Often the babies are overweight. Other features include dry skin, scanty, coarse hair, an enlarged tongue, umbilical hernias, and an expressionless face (Fig. 31-24). Developmental delay is noted. Associated congenital malformations, especially heart defects, are more likely to occur in children with congenital hypothyroidism.<sup>23,28</sup>

In acquired hypothyroidism, which manifests later in childhood, sluggishness, slowed growth, and worsening school performance are noted.<sup>18</sup> Slipped capital femoral epiphyses may occur, leading to groin, hip, or knee pain. Hypogonadism is present, and the children are often overweight.

### RADIOGRAPHIC FINDINGS

Thyroid hormone is very important in regulating bone growth and maturation. In patients with hypothyroidism, enchondral bone formation is disturbed. The skeleton is

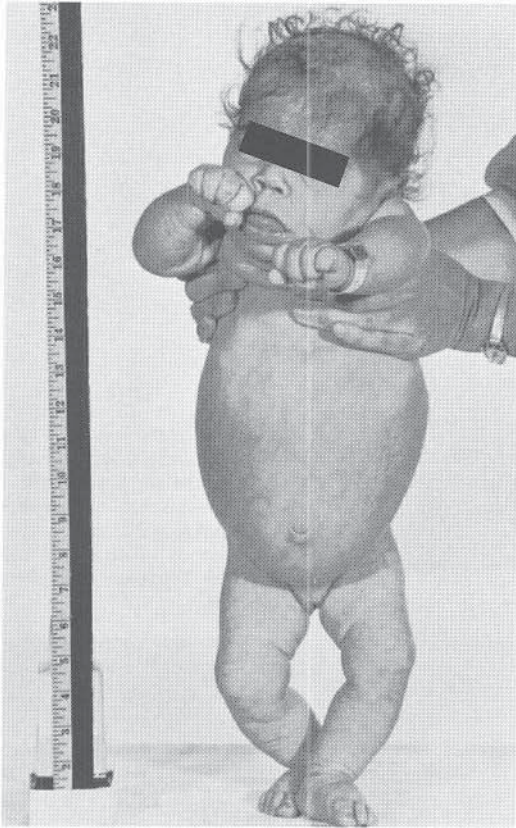


FIGURE 31–24 Typical clinical appearance of congenital hypothyroidism.

immature for the baby's chronological age. Appearance of the epiphyses is delayed, and they look irregular and fragmented, which in childhood resembles what is seen in Perthes' disease or multiple epiphyseal dysplasia.<sup>11</sup> *Epiphyseal dysgenesis* was the term used by Reilly and Smyth to describe the ossific nuclei.<sup>27</sup> The physis may be irregular and widened, resembling the radiographic picture in rickets.

The bone age of the patient is delayed. The long bones are abnormally widened as a result of normal intramembranous bone formation in the context of disturbed endochondral ossification.

The head appears large. Radiographically, ossification of the skull is retarded and the base of the skull is shortened. The sella turcica may be enlarged. Closure of the fontanelles is delayed. A delay in the development of normal dentition is common.

Spinal radiographs show a tendency toward thoracolumbar kyphosis. The vertebral body of L2 is wedge-shaped and the anterior margin is beaked. L1 and L3 may have a similar appearance. The bony end-plates are convex.

Some patients have osteosclerosis due to hypercalcemia. Radiographs in these patients show transverse radiopaque bands in the metaphyseal areas and thickened cortices. Metastatic calcification can occur.

MRI has shown enlargement of the pituitary in children with congenital hypothyroidism.<sup>8</sup>

## DIAGNOSIS

Great gains have been made in the diagnosis of congenital hypothyroidism. Screening programs are in place to measure

thyroid-stimulating hormone (TSH) in the newborn nursery.<sup>2,7,12,13,14,26</sup> An elevated TSH level is suspicious for congenital hypothyroidism.<sup>32</sup> Further laboratory evaluation of thyroid hormone levels and further imaging studies, consisting of radionuclide scintigraphy of the thyroid or thyroid ultrasound are then performed to ascertain the cause of the hormone deficiency.<sup>5,22,30</sup>

Early diagnosis is mandatory, because a delay in diagnosis can lead to irreversible mental retardation. The workup of the developmentally delayed child should include laboratory evaluation of thyroid function when the cause of the delay is unknown.<sup>25</sup>

There is an association between Down syndrome and hypothyroidism. One study found that 15 percent of babies with Down syndrome had congenital hypothyroidism.<sup>15</sup> Another found that 30 of 85 children with Down syndrome had hypothyroidism, and the authors recommended annual screening of these children.<sup>16</sup>

Other laboratory findings in children with hypothyroidism may include high serum calcium levels.<sup>31</sup> Patients with panhypopituitarism will have not only hypothyroidism but also the other hormonal deficiencies seen in this disorder, such as growth hormone deficiency.

## TREATMENT

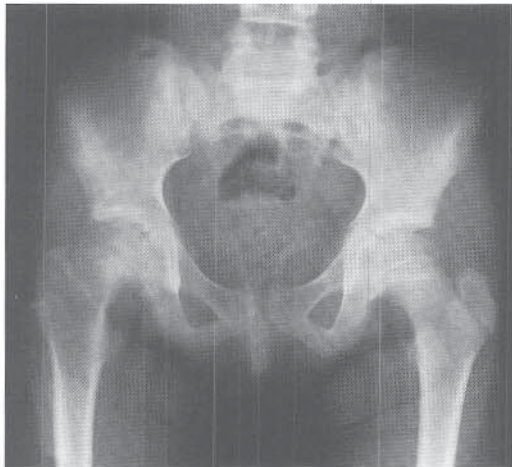
Treatment begins immediately upon diagnosis. Hormone replacement therapy with thyroxine is begun and carefully monitored. If treatment is begun by age 24 months, subsequent growth has been shown to be normal by age 5.<sup>3,6</sup> With hormonal replacement therapy, the pubertal growth spurt is normal, and adult height is within normal limits.<sup>9</sup> Long-term thyroxine replacement therapy has not been shown to decrease bone mass and lead to osteopenia.<sup>17</sup> Prompt treatment leads to normal intellectual development.<sup>19</sup>

Prenatal diagnosis through cord blood sampling has been achieved, and the prenatal treatment of hypothyroidism by means of thyroid hormone injected into the amniotic fluid has been successful in experimental settings.<sup>4,24</sup>

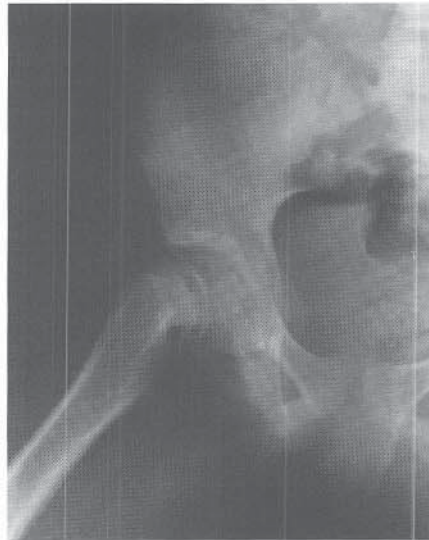If congenital hypothyroidism remains untreated, mental retardation is progressive, and most children die early of respiratory infections.

## ORTHOPAEDIC CONSIDERATIONS

In the older child, slipped capital femoral epiphysis may be the first manifestation of hypothyroidism (Fig. 31–25). Loder and associates found that the diagnosis of hypothyroidism was made *after* the patient presented for treatment of the slip.<sup>20</sup> Screening recommendations range from screening all patients with SCFE for thyroid disease<sup>33</sup> to no routine screening whatsoever. We feel that any patient who presents with a SCFE and is younger than usual (less than 11 years old), or who has a family history of thyroid abnormalities, or who is not of the typical obese body habitus should be screened for hypothyroidism with a TSH test. In patients with SCFE secondary to hypothyroidism, contralateral prophylactic pinning should be performed, as the incidence of bilateral SCFE in hypothyroidism is 61 percent.<sup>20</sup>

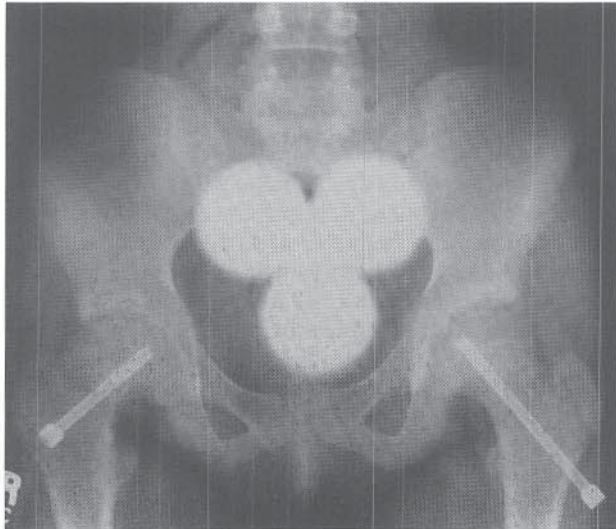


A

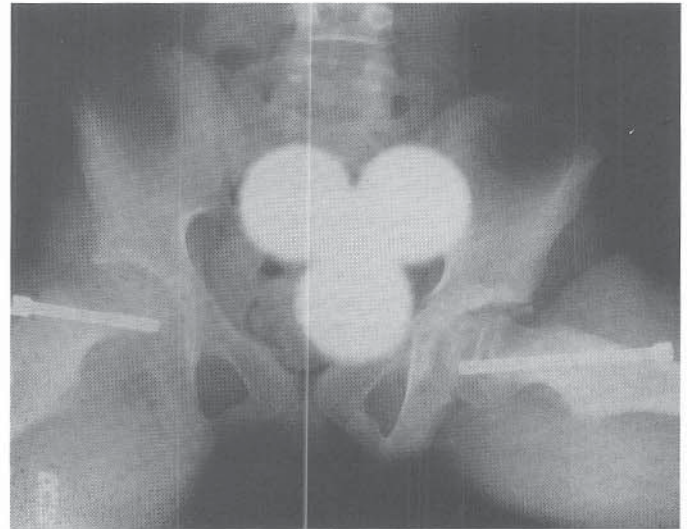


B

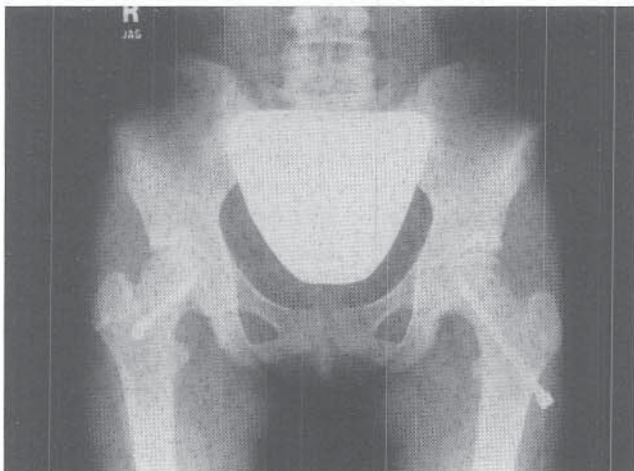
FIGURE 31-25 A and B, Right slipped capital femoral epiphysis in a 13-year-old girl. Hypothyroidism was diagnosed on presentation. Physeal widening is seen in the asymptomatic left hip. C and D, In situ fixation was performed bilaterally. E and F, At 2-year follow-up, the physes were healed.



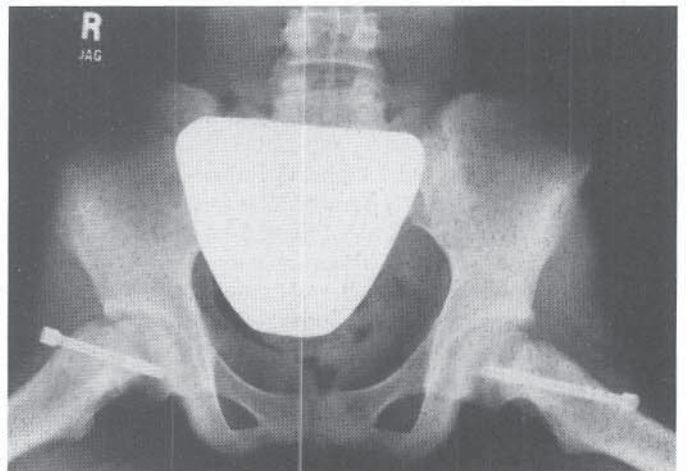
C



D



E



F

## REFERENCES

## Hypothyroidism

- Abramowicz MJ, Duprez L, Parma J, et al: Familial congenital hypothyroidism due to inactivating mutation of the thyrotropin receptor causing profound hypoplasia of the thyroid gland. *J Clin Invest* 1997; 99:3018.
- American Academy of Pediatrics Section on Endocrinology and Committee on Genetics, and American Thyroid Association Committee on Public Health: Newborn screening for congenital hypothyroidism: recommended guidelines. *Pediatrics* 1993;91:1203.
- Aronson R, Ehrlich RM, Bailey JD, et al: Growth in children with congenital hypothyroidism detected by neonatal screening. *J Pediatr* 1990;116:33.
- Bruner JP, Dellinger EH: Antenatal diagnosis and treatment of fetal hypothyroidism: a report of two cases. *Fetal Diagn Ther* 1997;12:200.
- Chanoine JP, Toppet V, Body JJ, et al: Contribution of thyroid ultrasound and serum calcitonin to the diagnosis of congenital hypothyroidism. *J Endocrinol Invest* 1990;13:103.
- Chiesa A, Gruneiro de Papendieck L, Keselman A, et al: Growth follow-up in 100 children with congenital hypothyroidism before and during treatment. *J Pediatr Endocrinol* 1994;7:211.
- Delange F: Neonatal screening for congenital hypothyroidism: results and perspectives. *Horm Res* 1997;48:51.
- Desai MP, Mehta RU, Choksi CS, et al: Pituitary enlargement on magnetic resonance imaging in congenital hypothyroidism. *Arch Pediatr Adolesc Med* 1996;150:623.
- Dickerman Z, De Vries L: Prepubertal and pubertal growth, timing and duration of puberty and attained adult height in patients with congenital hypothyroidism (CH) detected by the neonatal screening programme for CH: a longitudinal study [see comments]. *Clin Endocrinol* 1997;47:649.
- Doeker BM, Pfaffle RW, Pohlenz J, et al: Congenital central hypothyroidism due to a homozygous mutation in the thyrotropin beta-subunit gene follows an autosomal recessive inheritance. *J Clin Endocrinol Metab* 1998;83:1762.
- Eberle AJ: Congenital hypothyroidism presenting as apparent spondyloepiphyseal dysplasia [see comments]. *Am J Med Genet* 1993;47:464.
- Gruters A: Congenital hypothyroidism. *Pediatr Ann* 1992;21:15.
- Hunter MK, Mandel SH, Sesser DE, et al: Follow-up of newborns with low thyroxine and nonelevated thyroid-stimulating hormone-screening concentrations: results of the 20-year experience in the Northwest Regional Newborn Screening Program. *J Pediatr* 1998;132:70.
- Irons M: Screening for metabolic disorders: how are we doing? *Pediatr Clin North Am* 1993;40:1073.
- Jaruratanasirikul S, Patarakijvanich N, Patanapisarnsak C: The association of congenital hypothyroidism and congenital gastrointestinal anomalies in Down's syndrome infants. *J Pediatr Endocrinol Metab* 1998;11:241.
- Karlsson B, Gustafsson J, Hedov G, et al: Thyroid dysfunction in Down's syndrome: relation to age and thyroid autoimmunity. *Arch Dis Child* 1998;79:242.
- Kooh SW, Brnjac L, Ehrlich RM, et al: Bone mass in children with congenital hypothyroidism treated with thyroxine since birth. *J Pediatr Endocrinol Metab* 1996;9:59.
- La Franchi S: Diagnosis and treatment of hypothyroidism in children. *Compr Ther* 1987;13:20.
- Law WY, Bradley DM, Lazarus JH, et al: Congenital hypothyroidism in Wales (1982–1993): demographic features, clinical presentation and effects on early neurodevelopment. *Clin Endocrinol (Oxf)* 1998;48:201.
- Loder RT, Wittenberg B, De Silva G: Slipped capital femoral epiphysis associated with endocrine disorders. *J Pediatr Orthop* 1995;15:349.
- Macchia PE, Lapi P, Krude H, et al: PAX8 mutations associated with congenital hypothyroidism caused by thyroid dysgenesis. *Nat Genet* 1998;19:83.
- Muir A, Daneman D, Daneman A, et al: Thyroid scanning, ultrasound, and serum thyroglobulin in determining the origin of congenital hypothyroidism. *Am J Dis Child* 1988;142:214.
- Oakley GA, Muir T, Ray M, et al: Increased incidence of congenital malformations in children with transient thyroid-stimulating hormone elevation on neonatal screening [see comments]. *J Pediatr* 1998;132:726.
- Perelman AH, Johnson RL, Clemons RD, et al: Intrauterine diagnosis and treatment of fetal goitrous hypothyroidism. *J Clin Endocrinol Metab* 1990;71:618.
- al-Qudah AA: Screening for congenital hypothyroidism in cognitively delayed children. *Ann Trop Paediatr* 1998;18:285.
- Ray M, Muir TM, Murray GD, et al: Audit of screening programme for congenital hypothyroidism in Scotland 1979–93. *Arch Dis Child* 1997;76:411.
- Reilly WA, Smyth FS: Cretinoid epiphyseal dysgenesis. *J Pediatr* 1937;11:786.
- Siebner R, Merlob P, Kaiserman I, et al: Congenital anomalies concomitant with persistent primary congenital hypothyroidism. *Am J Med Genet* 1992;44:57.
- Tatsumi K, Miyai K, Amino N: Genetic basis of congenital hypothyroidism: abnormalities in the TSHbeta gene, the *PIT1* gene, and the *NIS* gene. *Clin Chem Lab Med* 1998;36:659.
- Ueda D, Mitamura R, Suzuki N, et al: Sonographic imaging of the thyroid gland in congenital hypothyroidism. *Pediatr Radiol* 1992; 22:102.
- Verrotti A, Greco R, Altobelli E, et al: Bone metabolism in children with congenital hypothyroidism: a longitudinal study. *J Pediatr Endocrinol Metab* 1998;11:699.
- Wang ST, Pizzolato S, Demshar HP: Diagnostic effectiveness of TSH screening and of T4 with secondary TSH screening for newborn congenital hypothyroidism. *Clin Chim Acta* 1998;274:151.
- Wells D, King JD, Roe TF, et al: Review of slipped capital femoral epiphysis associated with endocrine disease. *J Pediatr Orthop* 1993; 13:610.

## Idiopathic Juvenile Osteoporosis

Idiopathic juvenile osteoporosis is a rare metabolic bone disease of childhood that is characterized by a profound reduction in bone mass of unknown cause. The cardinal features of idiopathic juvenile osteoporosis are (1) onset before puberty, (2) compression fractures of the vertebrae and long bones, (3) formation of new but osteoporotic bone, and (4) spontaneous recovery following skeletal maturity.

## ETIOLOGY

The etiology of idiopathic juvenile osteoporosis remains unknown. The disease is not genetically transmitted. The basic mechanism of disease is an imbalance between bone formation and bone resorption. Bone histology usually shows an excess of osteocytes associated with woven bone.<sup>13</sup> In a recent study, secretion of synthesized collagen by cultured skin fibroblasts in some patients with idiopathic juvenile osteoporosis was reduced, while the range of collagen secretion in other patients with the disease overlapped the normal range.<sup>10</sup> Another study found diminished levels of the carboxy-terminal propeptide of type I procollagen in patients with juvenile osteoporosis, again indicating abnormalities in collagen metabolism.<sup>11</sup>

Biomechanical studies are conflicting. Serum calcium and phosphorus levels are normal in these patients. Calcium balance, however, is negative, with poor GI absorption of calcium.<sup>4,8</sup> Alkaline phosphatase and urinary hydroxyproline levels are usually normal as well. Although most studies report normal vitamin D levels,<sup>5</sup> two recent studies found low levels of calcitriol (1,25-dihydroxycholecalciferol). Therapy was then directed toward the vitamin deficiency, with improvement in the disease.<sup>9,12</sup> It may be that different forms of the disease exist with different biochemical profiles.

## CLINICAL FEATURES

The mean age at onset is 7 years, with cases reported in children as young as 1 year.<sup>13</sup> By definition, the disease

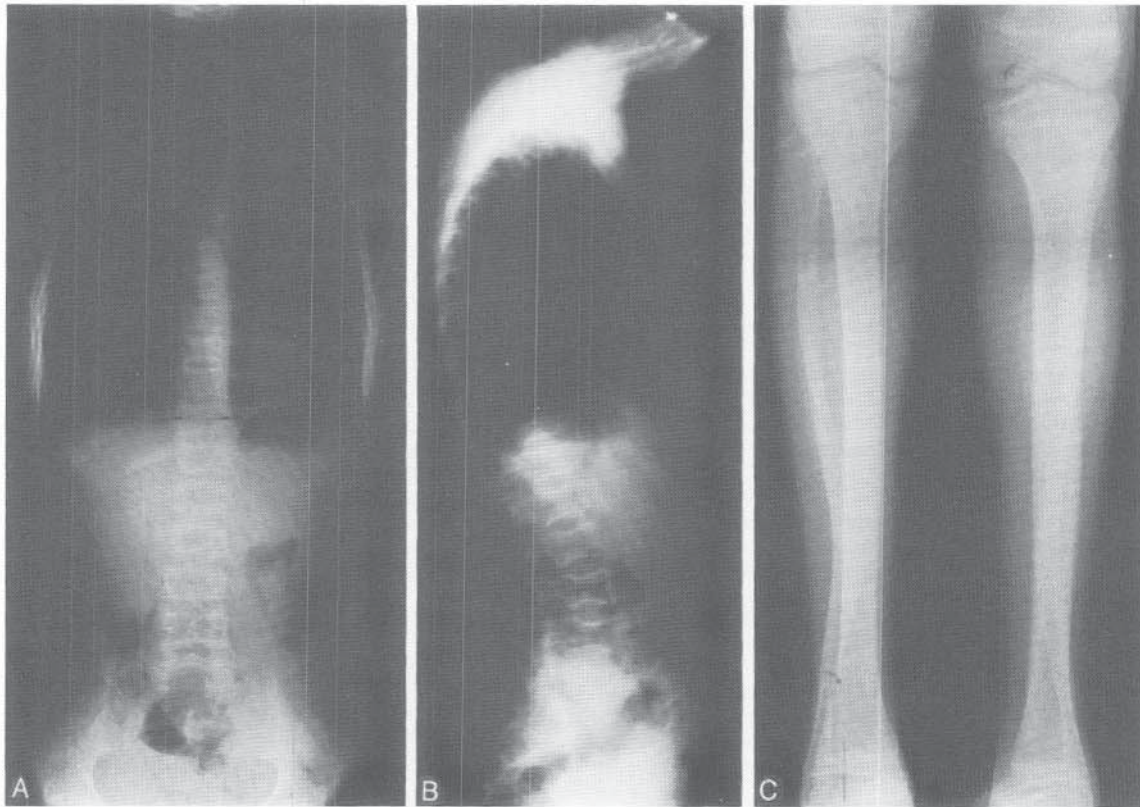


FIGURE 31-26 Idiopathic juvenile osteoporosis. A and B, AP and lateral radiographs of the spine showing the severe osteoporosis. Note the compression fractures of the vertebrae in the lumbar region. C, AP radiograph of both tibiae. Note the plastic bowing of the fibulae and marked osteoporosis.

always manifests before puberty. There is no sex predilection.

The presenting complaints in children with idiopathic juvenile osteoporosis are back pain and leg pain.<sup>2</sup> Patients may refuse to walk or may have a slow gait or limp.<sup>14</sup> The examining physician should always remember that a limp in children is a common orthopaedic dilemma, whereas idiopathic juvenile osteoporosis is extremely rare.

### RADIOGRAPHIC FINDINGS

Diffuse generalized osteoporosis is seen on radiographs of the spine and limbs (Fig. 31-26). The normal trabecular pattern is markedly decreased and the cortices of the bones are thinned. On lateral radiographs of the spine, a “codfish” appearance is present. Patients may develop increased thoracic or thoracolumbar kyphosis with anterior wedging of the vertebrae. Vertebral compression fractures may be evident, and scoliosis may be present.

Another radiographic feature is the presence of long bone fractures in various stages of healing. The fractures are usually metaphyseal and tend to occur in areas of highest stress, such as the femoral neck. Other areas in which stress fractures are common are the distal femur and proximal tibia.

The skull does not have a wormian appearance.

### DIAGNOSIS

The diagnosis is one of exclusion. The various known causes of osteoporosis in childhood are listed in Table 31-1. The

TABLE 31-1 Causes of Osteoporosis in Childhood

Endocrine disorders
Hyperthyroidism
Hyperparathyroidism
Hypogonadism
Glucocorticoid excess—Cushing’s syndrome, steroid therapy
Metabolic disorders
Homocystinuria
Gastrointestinal malabsorption
Idiopathic hypoproteinemia
Vitamin C deficiency
Rickets of any cause
Liver disease
Renal disease
Chronic tubular acidosis
Idiopathic hypercalciuria
Lowe’s syndrome
Uremia and regular hemodialysis
Bone affections
Osteogenesis imperfecta
Idiopathic juvenile osteoporosis
Idiopathic osteolysis
Turner’s syndrome (XO chromosome anomaly)
Malignant diseases
Leukemia
Lymphoma
Miscellaneous causes
Disuse osteoporosis of paralyzed limbs as in myelomeningocele
Generalized osteoporosis of Still’s disease, especially after steroid therapy
Heparin therapy
Anticonvulsant drug therapy



most difficult distinction to make is between idiopathic juvenile osteoporosis and mild osteogenesis imperfecta. Those patients with a positive family history have osteogenesis imperfecta, yet individuals with no affected relatives still may have either disease. Other distinguishing features of osteogenesis imperfecta that are not associated with idiopathic juvenile osteoporosis are blue sclerae, dentinogenesis imperfecta, ligamentous laxity, and easy bruising. Patients with juvenile osteoporosis do not sustain fractures in early infancy, and this may help differentiate the two diseases in some patients. Lastly, the fracture callus in juvenile osteoporosis is osteopenic.

Fibroblast studies may be of some help in establishing the diagnosis of osteogenesis imperfecta, but overlap of results with normal ranges and with results in idiopathic juvenile osteoporosis may occur in some children.<sup>10</sup>

Bone biopsy is usually not necessary to diagnose either osteogenesis imperfecta or idiopathic juvenile osteoporosis, but when performed, increased woven immature bone is seen in osteogenesis imperfecta, while increased osteoclastic resorption of bone is seen in idiopathic juvenile osteoporosis.<sup>7</sup>

Another very important distinction to make clinically is that between leukemia and idiopathic juvenile osteoporosis. A child with leukemia may present with osteopenia and compression fractures, so urgent referral to a pediatric hematologist is wise in the evaluation of a patient with osteoporosis. Usually a bone marrow aspirate will be required to definitively rule out leukemia.

## TREATMENT

The treatment of idiopathic juvenile osteoporosis is controversial. Isolated reports of successful medical treatment with calcitonin,<sup>5</sup> calcitriol,<sup>9,12</sup> bisphosphonates,<sup>4</sup> and estrogen<sup>15</sup> have been published. All reported improved bone mineralization and decreased fractures. It appears that when a demonstrable deficiency is found through laboratory testing, treatment aimed toward correcting that deficiency is warranted.

Orthopaedic treatment for the spine is usually conservative. Bracing may relieve back pain and treat the kyphotic deformity. The Milwaukee brace has been used for this purpose, with reported success.<sup>3,6</sup> The role of the brace in accelerating osteoporosis by stress shielding the spine is unknown. Use of the brace should be discontinued gradually as the osteoporosis resolves.

Scoliosis likewise should be managed orthotically when possible. Spinal fusion has been performed in isolated cases, but continued progression of the deformity due to bending of the fusion mass has been described.<sup>1</sup>

Long bone fractures should be managed by conventional means. Immobilization should be kept to a minimum, as prolonged immobilization leads to worsening osteoporosis and may result in a cycle of fractures.

## REFERENCES

### Idiopathic Juvenile Osteoporosis

1. Bartal E, Gage JR: Idiopathic juvenile osteoporosis and scoliosis. *J Pediatr Orthop* 1982;2:295.
2. Dimar JR II, Campbell M, Glassman SD, et al: Idiopathic juvenile

- osteoporosis: an unusual cause of back pain in an adolescent. *Am J Orthop* 1995;24:865.
3. Hensinger RN: Kyphosis secondary to skeletal dysplasias and metabolic disease. *Clin Orthop* 1977;128:113.
4. Hoekman K, Papapoulos SE, Peters AC, et al: Characteristics and bisphosphonate treatment of a patient with juvenile osteoporosis. *J Clin Endocrinol Metab* 1985;61:952.
5. Jackson EC, Strife CF, Tsang RC, et al: Effect of calcitonin replacement therapy in idiopathic juvenile osteoporosis. *Am J Dis Child* 1988;142:1237.
6. Jones ET, Hensinger RN: Spinal deformity in idiopathic juvenile osteoporosis. *Spine* 1981;6:1.
7. Jowsey J, Johnson KA: Juvenile osteoporosis: bone findings in seven patients. *J Pediatr* 1972;81:511.
8. Lachmann D, Willvonseder R, Hofer R, et al: A case-report of idiopathic juvenile osteoporosis with particular reference to 47-calcium absorption. *Eur J Pediatr* 1977;125:265.
9. Marder HK, Tsang RC, Hug G, et al: Calcitriol deficiency in idiopathic juvenile osteoporosis. *Am J Dis Child* 1982;136:914.
10. Pocock AE, Francis MJ, Smith R: Type I collagen biosynthesis by skin fibroblasts from patients with idiopathic juvenile osteoporosis. *Clin Sci (Colch)* 1995;89:69.
11. Proszynska K, Wieczorek E, Olszaniecka M, et al: Collagen peptides in osteogenesis imperfecta, idiopathic juvenile osteoporosis and Ehlers-Danlos syndrome. *Acta Paediatr* 1996;85:688.
12. Saggese G, Bertelloni S, Baroncelli GI, et al: Mineral metabolism and calcitriol therapy in idiopathic juvenile osteoporosis. *Am J Dis Child* 1991;145:457.
13. Smith R: Idiopathic juvenile osteoporosis: experience of twenty-one patients. *Br J Rheumatol* 1995;34:68.
14. Villaverde V, De Inocencio J, Merino R, et al: Difficulty walking: a presentation of idiopathic juvenile osteoporosis. *J Rheumatol* 1998;25:173.
15. Wright NM, Metzger DL, Key LL: Estrogen and diclofenac sodium therapy in a prepubertal female with idiopathic juvenile osteoporosis. *J Pediatr Endocrinol Metab* 1995;8:135.

## Osteogenesis Imperfecta

### INTRODUCTION

Osteogenesis imperfecta is a genetic disorder of connective tissue with the trademark clinical feature of bone fragility evidenced by long bone fractures. Other major clinical features may include skeletal deformity, blue sclerae, hearing loss, and fragile, opalescent teeth (dentinogenesis imperfecta). Less severe manifestations may include generalized ligamentous laxity, hernias, easy bruisability, and excessive sweating. The spectrum of the presence of the various potential manifestations, their severity, and the age at which these features manifest is very broad.\* The extent of the manifestation of bone fragility is the best example of this spectrum: fragility can be so severe that the affected infant is born with crumpled ribs, a fragile cranium, and long bone fractures incompatible with life, whereas at the opposite end of the spectrum, an older child who otherwise appears normal may sustain only a few fractures after a reasonable amount of trauma. The distinction between child abuse (nonaccidental injury) and excessive bone fragility may be difficult to make in these latter circumstances.<sup>8,52,93,135,136,176</sup> It is now known that at least 90 percent of affected individuals have an identifiable genetically determined quantitative and/or qualitative defect in type I collagen formation.† Type I collagen is the major structural protein found in bone and skeletal connective tissue. The disorder may be inherited from a parent in an

\*See references 1, 3, 4, 38, 40, 41, 42, 45, 74, 94, 109, 110, 111, 122, 125, 168, 172, 179, 181.

†See references 1, 33, 38, 40, 41, 43, 45, 56, 122, 129, 175.

autosomal dominant fashion, may occur as a spontaneous mutation, or, rarely, may be inherited as a homozygous autosomal recessive trait from both parents.<sup>40,41,122</sup>

Historical descriptions of individuals who may have been affected with osteogenesis imperfecta date from Egyptian times. The most colorful description is probably that of "Ivar the Boneless," a Scandinavian prince who led the invasion of Britain during the ninth century.<sup>91,181</sup> He was purportedly carried by his troops into battle on a shield, because his limb deformities prevented him from walking. His skeleton is not available for modern substantiation of this diagnosis, since his remains were dug up and burned at the direction of William the Conqueror. From a medical perspective, this disorder has been called by a variety of names over the years, including *fragilis ossium*, *osteopsathyrosis idiopathica*, *brittle bone disease*, *Lobstein's disease*, and *Vrolik's disease*. Lobstein<sup>104</sup> described the nonlethal variety in 1835, and Vrolik<sup>183</sup> described the lethal variety manifesting as multiple birth fractures in 1849. Vrolik was also the first to use the term osteogenesis imperfecta.

## PATHOPHYSIOLOGY

Extensive molecular genetic and collagen qualitative research has shown that the vast majority (at least 90 percent) of individuals with osteogenesis imperfecta have an identifiable defect in the genes responsible for encoding type I collagen.\* Some understanding of normal collagen formation, and of errors of that metabolic process that are seen in osteogenesis imperfecta, is essential to understanding the pathophysiology and variability of the disorder.

**Normal Collagen Metabolism.** Collagen is a connective tissue protein with a left-handed triple-helical structure that is found in abundance in many areas of the body. Many specific subtypes have been described that occur in specific parts of the body relatively frequently. The major structural collagen of the skeletal system, including bone, ligament, and tendon, is type I collagen. This type of collagen is composed of three strands of collagen protein: two  $\alpha_1$  (I) strands and one  $\alpha_2$  (I) strand. In the normal fibroblast, precursor subunits for these two types of strands (pro- $\alpha_1$  [I] and pro- $\alpha_2$  [I] polypeptide chains) are synthesized in the rough endoplasmic reticulum. These two procollagen polypeptide chains are encoded for by two separate genes, *COL1A1* (encoding for pro- $\alpha_1$  [I]), located on the long arm of chromosome 17, and *COL1A2* (encoding for pro- $\alpha_2$  [I]), located on the long arm of chromosome 7. Two pro- $\alpha_1$  (I) chains and 1 pro- $\alpha_2$  (I) chain combine to form type I procollagen molecules. The combining of these three chains into the triple helix begins at the carboxy-terminal end, propagating toward the amino-terminal end. An essential feature of the pro- $\alpha$  chains is a recurrent pattern of glycine residues at every third peptide position in the chain, for it is at these residues that cross-linking of the three chains occurs. The type I procollagen molecules are secreted from the cell and are processed extracellularly to type I collagen molecules (Fig. 31-27A).

**Collagen Metabolism in Osteogenesis Imperfecta.** In the 90 percent of patients in whom the nature of the genetic

error in type I collagen formation can be determined (to date), that error is of two basic types: qualitative or quantitative. Type I collagen can be assayed from cultures of fibroblasts taken from skin biopsies, using electrophoresis techniques. First, there can be a complete absence of an identifiable type I collagen, or a quantitative error. Such patients likely have a stop codon in the affected gene, leading to an absence of the necessary mRNA, resulting in turn in no collagen being formed under the direction of the affected gene. In this circumstance a patient who is heterozygous for the condition will secrete approximately half of the normal amount of type I collagen, with no abnormal type I collagen identifiable (Fig. 31-27B). This is the type of defect most commonly identified in type IA osteogenesis imperfecta in Sillence's classification (see below).<sup>167</sup> Cole, in a review of the molecular pathology of 200 patients with osteogenesis imperfecta,<sup>41</sup> identified rare types that had normal type I collagen, but with even more severe reductions in quantity than the typical type I patients in Sillence's classification, with levels of 20 percent or less.

Alternatively, there can be an error in substitution or deletion, usually involving a glycine peptide residue somewhere along the polypeptide chain. In such circumstances the affected patient will produce an abnormal, less effectual collagen, usually in reduced amounts. The severity of the disruption of the function of the affected collagen is in part related to the location of the glycine residue error. Substitutions located at the carboxy end of the polypeptide chains are potentially more serious, since cross-linking of the triple helix begins at the carboxy terminal of the chains. This type of defect, a both quantitative and qualitative one impairing the function of type I collagen, is the more commonly identified defect in Sillence's types II, III, and IV (discussed below) (Fig. 31-27C). Patients with the most severe or lethal varieties tend to have the coding defect at the carboxy end of either the pro- $\alpha_1$  (I) or pro- $\alpha_2$  (I) chains.

## CLASSIFICATION AND HEREDITY

The classification of osteogenesis imperfecta has proved troublesome because of variability in the nature, time of onset, and severity of the various clinical manifestations of the disorder. The different patterns of inheritance, the relatively high incidence of spontaneous mutations, and the variability in clinical severity even when the mode of inheritance is known further compromise the effectiveness of classification schemes. The identification of more than 150 specific locations of disruptions of genetic coding for type I collagen has improved our understanding of the nature and variability of the clinical manifestations but has not simplified classification. There are two classification schemes (those of Sillence and associates<sup>41,165-167</sup> and Shapiro<sup>162</sup>) with which orthopaedic surgeons attending to the needs of patients with osteogenesis imperfecta should be familiar.

Sillence and Danks delineated four distinct types of osteogenesis imperfecta, based on both clinical and genetic characteristics.<sup>167</sup> Previous classifications did not take genetic modes of transmission into account in delineating types of osteogenesis imperfecta. In the original description of Sillence and Danks, four types were described and identified as either autosomal dominant (types I and IV) or autosomal

\*See references 1, 33, 38, 40, 41, 44, 45, 56, 122, 129, 175.

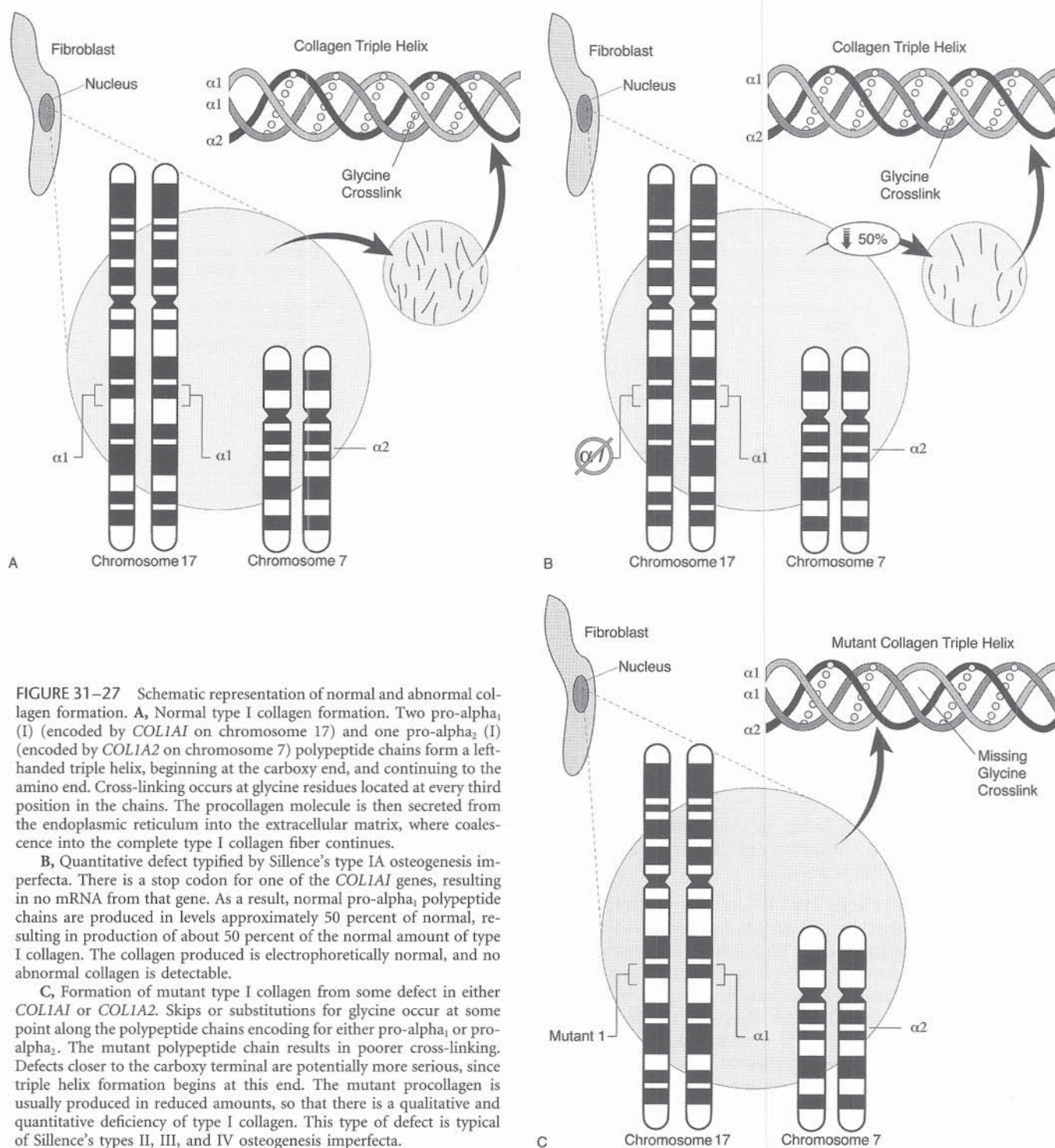


FIGURE 31–27 Schematic representation of normal and abnormal collagen formation. A, Normal type I collagen formation. Two pro-alpha<sub>1</sub>(I) (encoded by *COL1A1* on chromosome 17) and one pro-alpha<sub>2</sub>(I) (encoded by *COL1A2* on chromosome 7) polypeptide chains form a left-handed triple helix, beginning at the carboxy end, and continuing to the amino end. Cross-linking occurs at glycine residues located at every third position in the chains. The procollagen molecule is then secreted from the endoplasmic reticulum into the extracellular matrix, where coalescence into the complete type I collagen fiber continues.

B, Quantitative defect typified by Sillence's type IA osteogenesis imperfecta. There is a stop codon for one of the *COL1A1* genes, resulting in no mRNA from that gene. As a result, normal pro-alpha<sub>1</sub> polypeptide chains are produced in levels approximately 50 percent of normal, resulting in production of about 50 percent of the normal amount of type I collagen. The collagen produced is electrophoretically normal, and no abnormal collagen is detectable.

C, Formation of mutant type I collagen from some defect in either *COL1A1* or *COL1A2*. Skips or substitutions for glycine occur at some point along the polypeptide chains encoding for either pro-alpha<sub>1</sub> or pro-alpha<sub>2</sub>. The mutant polypeptide chain results in poorer cross-linking. Defects closer to the carboxy terminal are potentially more serious, since triple helix formation begins at this end. The mutant procollagen is usually produced in reduced amounts, so that there is a qualitative and quantitative deficiency of type I collagen. This type of defect is typical of Sillence's types II, III, and IV osteogenesis imperfecta.

recessive (types II and III).<sup>167</sup> According to this formulation, type I osteogenesis imperfecta was an autosomal dominant condition characterized by bone fragility and blue sclerae throughout life. This type was subdivided into type IA, without dentinogenesis imperfecta, and type IB, with dentinogenesis imperfecta. Type II was considered a lethal autosomal recessive form characterized by extreme bone fragility and perinatal death. Type III was described as a relatively rare autosomal recessive condition with relatively severe bone fragility and white sclera. Type IV was described as

an autosomal dominant disorder of intermediate severity, characterized by white sclerae in adulthood. Type IV, like type I, was subclassified into type IVA, without dentinogenesis imperfecta, and type IVB, with dentinogenesis imperfecta. More recent work on the nature of type I collagen disorders and the molecular genetic basis for these disorders, however, has elucidated the nature of the genetic defect, and, in fact, true autosomal recessive transmission is rare in this condition.<sup>41</sup> Cole has recommended modification of the original Sillence classification, based on an extensive

TABLE 31-2 Classification of Osteogenesis Imperfecta Syndromes (According to Silience)

Type	Inheritance	Teeth	Bone Fragility	Deformity of Long Bones	Growth Retardation	Presenile Hearing Loss (percent)
I A	Autosomal dominant	Normal	Variable—less severe than other types	Moderate	Short stature, 2% to 3% below mean	40
B	Autosomal dominant	Dentinogenesis imperfecta	Variable—less severe than other types	Moderate	Short, 2% to 3% below mean	40
II	Autosomal recessive	Unknown (because of perinatal death)	Very extreme	Crumbled bone (accordion femora) marked	Unknown (because of perinatal death)	
III	Autosomal recessive	Dentinogenesis imperfecta	Severe	Progressive bowing of long bones and spine	Severe—smallest of all patients with osteogenesis imperfecta	
IV A	Autosomal dominant	Normal	Moderate	Moderate	Short stature	Low frequency
B	Autosomal dominant	Dentinogenesis imperfecta	Moderate	Moderate	Short stature	Low frequency
Prognosis		Sclerae	Spine	Skull	Other	Incidence
Fair		Distinctly blue throughout life	20% scoliosis and kyphosis	Wormian bones on x-rays	Premature arcus senilis	1/30,000
Fair		Distinctly blue throughout life	20% scoliosis and kyphosis	Wormian bones on x-rays	Premature arcus senilis	1/30,000
Perinatal death		Blue		Marked absence of ossification		1/62,000 live births
Nonambulatory, wheelchair-bound May die in third decade		Bluish at birth, become less blue with age, white in adult	Kyphoscoliosis	Hypoplastic, more ossified than type II Wormian bones		Very rare
Fair		Normal	Kyphoscoliosis	Hypoplastic Wormian bones		Unknown
Fair		Normal	Kyphoscoliosis	Hypoplastic Wormian bones		Unknown

review of the collagen defect in 200 patients with osteogenesis imperfecta. The features of Silience's classification are summarized in Table 31-2.

**Osteogenesis Imperfecta Type I.** Osteogenesis imperfecta type I is characterized by generalized osteoporosis with abnormal bony fragility, distinct blue sclerae throughout life, and presenile conductive hearing loss. This is the most common type of osteogenesis imperfecta in most series, and the patients are, in general, the least affected in terms of incidence of fractures. This type is inherited as an autosomal dominant condition, although spontaneous mutations occur. Molecular genetic studies have revealed that this type is characterized by a quantitative defect in type I collagen.\* Specifically, one of the inherited *COL1A1* genes in affected patients will not produce effective mRNA for pro- $\alpha_1$  collagen, so that the amount of type I collagen is effectively reduced to approximately 50 percent of the normal amount, but that 50 percent is electrophoretically normal, and no "mutant" type I collagen is detectable by electrophoretic techniques.<sup>41</sup> Dentinogenesis imperfecta is present in some of these patients; those without dentinogenesis imperfecta are subclassified as having osteogenesis imperfecta type IA, and those with dentinogenesis imperfecta are classified as having type IB. It is likely that patients with osteogenesis

type IB have a mutant collagen present and are biochemically distinctly different from patients with osteogenesis type IA.

**Osteogenesis Imperfecta Type II.** Type II osteogenesis imperfecta is characterized by extreme bone fragility leading to death in the perinatal period or early infancy. The long bones are crumbled (accordion femora), and ossification of the skull is markedly delayed; on palpation, the cranial vault feels like numerous small plates of bone. Originally this condition was thought to be inherited as an autosomal recessive trait.<sup>160</sup> However, work on the nature of type I collagen disturbance has revealed that the defect in most cases is a severe disruption in the qualitative function of type I collagen.\* In most cases the condition is inherited as a "dominant negative" condition, often as the result of spontaneous mutation. In the words of Cole, most affected individuals have "their own private mutation," and many different ones have been described.<sup>41</sup>

This pattern of inheritance is more in keeping with the risk of recurrence in subsequent pregnancies of couples with a prior affected fetus. If the condition were inherited as an autosomal recessive trait, the risk in subsequent pregnancies should be on the order of 25 percent, or, if due to spontaneous mutations, essentially zero. In fact, the risk of having a subsequent fetus affected has been estimated at approxi-

\*See references 1, 15, 40, 41, 45, 56, 122, 175, 180, 188.

\*See references 1, 38, 40, 41, 44, 45, 56, 122, 175.

mately 7 percent. In those situations, one of the parents has been identified as being “mosaic” for the dominant negative gene, accounting for the low but present risk. For a discussion of diagnostic evaluations for identifying an affected fetus, please see the section titled Prognostication and Parental Counseling—Antenatal Diagnosis.

**Osteogenesis Imperfecta Type III.** This variety of Osteogenesis imperfecta type III also is characterized by qualitative and quantitative changes in type I collagen and may be inherited as an autosomal recessive or “dominant negative” trait.<sup>1,40,41,45,122,129</sup> It is characterized by severe bone fragility, multiple fractures and progressive marked deformity of the long bones, and severe growth retardation.<sup>40,41,165,167</sup> The sclerae are bluish at birth but become less blue with age. In the adolescent, the sclerae are of normal hue. The most severely affected surviving patients often have this type of disease.

**Osteogenesis Imperfecta Type IV.** Osteogenesis imperfecta type IV is inherited as an autosomal dominant condition, and most patients, like patients with types II and III, have qualitative and quantitative changes in type I collagen. At birth the sclerae are of normal hue; if they are bluish, they become progressively less so with maturation, and are normal in adolescence. The osteoporosis, bone fragility, and long bone deformities are of variable severity. Dentinogenesis imperfecta also occurs in some affected individuals: those with normal dentition are classified as having type IVA disease and those with dentinogenesis imperfecta are classified as having type IVB disease.

One of the problems for the orthopaedic surgeon and the families of patients with osteogenesis imperfecta is the significant variability in the severity of long bone deformity and fracture frequency within Sillence classification categories and even within families, whose members presumably share the same genetic defect. Yet these two clinical features have a significant impact on the affected individual’s mobility, morbidity, and need for orthopaedic intervention. In general, Sillence’s type I patients are the least affected individuals; Sillence’s type II patients almost invariably are stillborn or die shortly after birth; and Sillence’s types III and IV patients are more severely affected than most type I patients, constituting the majority of patients with severe deformity and frequent fractures; they may require extremity

intramedullary rodding and have more difficulty ambulating or are unable to do so. However, within a family, one sibling may have only a few fractures while another may have repeated fractures and deformity requiring intramedullary rods and difficulty ambulating without lower extremity bracing or upper extremity aid. Because of this practical problem, the clinical classifications based on the age at onset and the severity of fractures still has prognostic relevance for the orthopaedic surgeon and affected individuals.

The evolution of a useful clinical classification based on the occurrence and severity of fractures is as follows. Looser in 1906<sup>105</sup> classified osteogenesis imperfecta into two types: *osteogenesis imperfecta congenita*, characterized by the presence of numerous fractures at birth, and *osteogenesis imperfecta tarda*, in which the fracture or fractures occur after the perinatal period.<sup>105</sup> Seedorff in 1949<sup>161</sup> subclassified osteogenesis imperfecta tarda into two types: *tarda gravis*, in which the first fracture occurs in the first year of life (these children subsequently develop severe deformities of the long bones and spine), and *tarda levis*, in which the first fracture occurs after the first year of life: deformity and disability are not so severe in the latter.<sup>153</sup> Falvo and associates<sup>61</sup> noted that age does not always correlate with the severity of the disease, and therefore recommended subdivision of osteogenesis imperfecta tarda according to the presence of bowing of the long bones; those cases with bowing they subclassified as *tarda* type I, and those without bowing as *tarda* type II. Shapiro has recommended a further modification of Looser’s classification, based on the evaluation of a large number of patients with respect to prognosis for survival and ambulation.<sup>162</sup> This classification, given in Table 31–3, has excellent practical application for the orthopaedic surgeon and the families of affected individuals in regard to prognosis for survival and ambulation. The classification consists of four categories: congenita A, congenita B, *tarda* A, and *tarda* B. Shapiro classified patients as having osteogenesis imperfecta “congenita” if they had fractures in utero or at birth, whereas Looser and other later authors used “congenita” only for in utero fractures. The distinction between the two congenita types is based on the timing of fractures and radiographic features of the affected bones. Patients with *congenita A* are patients who sustain fractures in utero or at birth, with the additional radiographic features

TABLE 31–3 Shapiro’s Classification of Osteogenesis Imperfecta\*

Type	Description	Positive Family History	Deaths	Ambulatory Status
Osteogenesis imperfecta congenita A	In utero or birth fractures; short, broad, crumpled femora and ribs	0%	15/16 (94%)	One survivor wheelchair bound
Osteogenesis imperfecta congenita B	In utero or birth fractures; normal long bone contours, no chest deformity	4%	2/27 (8%)	59% wheelchair-bound; 33% at least household ambulators
Osteogenesis imperfecta tarda A	Fractures after birth but before walking	11%	0/21 (0%)	33% in wheelchair; 67% ambulatory
Osteogenesis imperfecta tarda B	Fractures after walking	76%	0/21 (0%)	100% ambulatory

\*Clinical features and prognosis in patients with osteogenesis imperfecta as described by Shapiro. Patients with osteogenesis imperfecta congenita (fractures in utero or at birth) are distinguished by the presence or absence of long bone and rib deformities. Patients with osteogenesis imperfecta tarda (fractures after birth) are distinguished by the onset of fractures prior to, or after, walking.

From Shapiro F: Consequences of an osteogenesis imperfecta diagnosis for survival and ambulation. *J Pediatr Orthop* 1985;5:456.

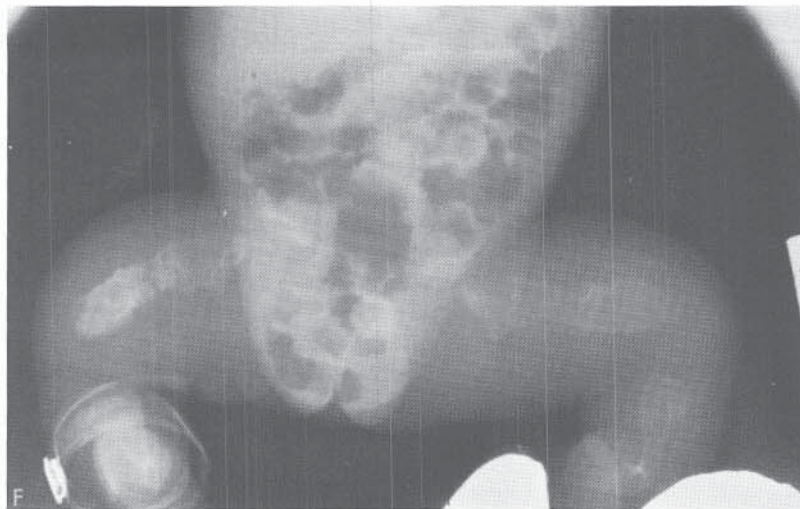

FIGURE 31–28 Radiograph showing crumpled femora and lack of normal funnelization of the long bone in a child with osteogenesis imperfecta, Sillence's type II, Shapiro's type congenita. This form is virtually universally fatal, as the child is stillborn or dies in the neonatal period from intracranial hemorrhage or respiratory insufficiency.

of crumpled long bones, crumpled ribs with rib cage deformity, and fragile skull (Fig. 31–28). These features are incompatible with life, and the patients are almost always either stillborn or die shortly after birth from intracranial hemorrhage or respiratory insufficiency. In Shapiro's series, 15 of 16 patients with congenita A died, while one survived with wheelchair mobility. Patients with *congenita B* have fractures at birth but are radiographically distinct from congenita A patients in that the long bones, as typified by the femur, are more tubular and have more normal funnelization in the metaphysis, the ribs are more normally formed (although there may be rib fractures), and there is no rib cage deformity. These patients are obviously severely affected, but this type of osteogenesis imperfecta is compatible with survival. In Shapiro's series, only two of 27 congenital B patients died, and nine were able to ambulate in some fashion. Patients with osteogenesis imperfecta tarda developed fractures only after birth. Patients with *tarda A* have onset of fractures prior to walking. In Shapiro's series, 33 percent were in wheelchairs and 67 percent were ambulatory. The age at onset of fractures was not prognostic for ambulation within this group. Patients with *tarda B* incur their first fracture after walking age; in Shapiro's series, all these patients were ambulatory.

## INCIDENCE

The exact incidence of the various types of osteogenesis imperfecta is uncertain. The population frequency of type I has been estimated as approximately 2.35 per 100,000 in Japan, 4.7 per 100,000 in Germany, and 3.4 per 100,000 in Victoria, Australia. The birth incidence of type II has been estimated at 1 per 40,000 to 1.4 per 100,000 live births.<sup>165–167</sup> At present the exact incidence of type III and type IV is unknown,<sup>181</sup> but these types are less common than type I in most clinical series. In Cole's review of the genetic defect and type I collagen anomaly in 200 patients, 28 patients had type IA (two with IB), 47 had perinatally lethal type II (Cole subdivided this group into three types), 41 had type III, and 79 had type IV.<sup>41</sup>

In Shapiro's review and classification based on clinical severity, 16 patients had congenita A (fractures in utero

or at birth, with chest deformity and crumpled ribs and extremities), 27 had congenita B (in utero or birth fractures, without chest deformity and with more normal metaphyseal funnelization), 21 had *tarda A* (fractures after birth but before walking), and 21 had *tarda B* (fractures after walking).

## PATHOLOGY

The fundamental defect in osteogenesis imperfecta is an absolute reduction in the amount of normal type I collagen in bone or its replacement with a poorly functioning mutant collagen (usually also reduced in quantity). That defect is manifested histologically in many ways.\* Formation of both enchondral and intramembranous bone is disturbed. Histologic findings vary according to the type of osteogenesis imperfecta. The morphology of the cells and of the matrix is not consistent throughout the spectrum of the syndrome. The amount of woven bone is larger than in normal controls, and histometric analyses have shown that in type II, the proportion of primitive osseous tissue with a woven or irregular collagen matrix is significantly greater than in other types.<sup>30,54</sup>

The bone trabeculae are thin and lack an organized trabecular pattern. Fractured spicules of trabeculae may be found. The spongiosa is scanty. The intracellular matrix is reduced, and as a result there is relative abundance of osteocytes (Fig. 31–29).<sup>31</sup> The osteoclasts are morphologically normal, although they seem to be numerous and have an increased number of resorption surfaces.

Osteoid seams are wide and crowded by plump osteoblasts. The mineralized chondroid lattice is surrounded by wide seams of basophilic substance.<sup>53,54</sup> This large number of osteoblasts and osteoclasts, the large size of the osteoblasts, and the plentiful osteoid tissue covering the thin bone trabeculae indicate increased bone turnover. Tetracycline labeling studies have confirmed the increased bone turnover in osteogenesis imperfecta.<sup>4,13</sup> McCarthy and associates, however, noted normal or (evidence of) decreased bone turnover in eight adult patients with Sillence's type IA osteogenesis imperfecta.<sup>116</sup>

\*See references 5, 13, 16, 30, 31, 54, 59, 116, 149.

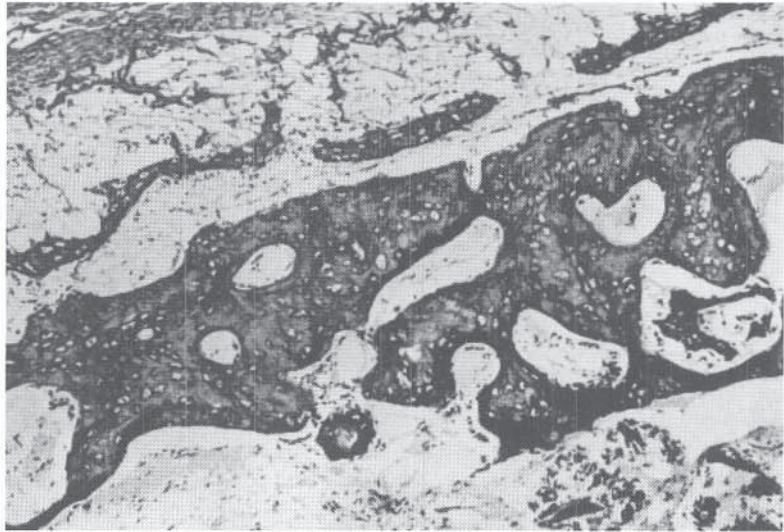


FIGURE 31–29 Histologic appearance in osteogenesis imperfecta. There is a relative abundance of osteocytes with a reduced extracellular matrix. Osteoclasts are morphologically normal and normal or increased in number, with an increased number of resorption surfaces.

The lamellae in lamellar bone are thin and tenuous. On electron microscopy the collagen fibrils do not aggregate in bundles of normal thickness; instead, they are organized into thin, loosely compacted filaments.<sup>54,173</sup> The compact bone consists of a coarse fibrillary type of immature bone without haversian systems. Periosteum and perichondrium are generally normal, but in one study the periosteum was thickened, with a defective microvascular system.<sup>132</sup> The physis is usually broad and irregular, the proliferative and hypertrophic zones are disorganized, and the typical columnar arrangement is lacking. The calcified zone of the growth plates is thinner, and metaphyseal blood vessels permeate the growth plate.<sup>30</sup> Islands of cartilage are present in the juxtaphyseal metaphyseal region. Sanguinetti and associates<sup>160</sup> observed that biopsy specimens from patients with type II osteogenesis imperfecta had a relatively normal appearance of the growth plate, but in specimens from patients with types I and III disease they noted reduced cartilage matrix calcification, thin, newly formed bony trabeculae, and decreased glycosaminoglycan staining within the growth plate.<sup>160</sup>

The primary spongiosa in the metaphysis is sparse, with the osseous tissue almost always of the woven variety. The secondary centers of ossification in the epiphysis are delayed in maturation, and residual islands of cartilage remain in the epiphysis.

When a fracture is present the endosteal fracture callus is primarily cartilaginous and the periosteal reaction is abundant, consisting mainly of woven bone.

Gross anatomic findings consist of porosis (osteopenia), diminution in size, and skeletal deformities secondary to fracture and asymmetric physal growth disturbance (Fig. 31–30), corresponding to the degree of bone fragility.<sup>31</sup> In severely affected individuals, the long bones are slender and smaller than normal and the cortices are extremely thin, with a paucity of medullary spongy bone and evidence of recent or healed fractures with varying degrees of angular or torsional deformities. The cartilaginous epiphyseal ends of the long bones in general retain a recognizable shape but are disproportionately large and have some irregularity of the articular surface.

The spine may show varying degrees of deformity, usually scoliosis, often with compression fractures and wedging of the vertebral bodies (Fig. 31–31). Kyphosis may be combined with scoliosis.

In the skull there are multiple centers of ossification, particularly in the occipital region, and wormian bones.

#### CLINICAL PICTURE

The clinical picture varies according to the variety of the disease. In the severe congenital form (Sillence's type II, or Shapiro's congenita A), multiple fractures from minimal trauma during delivery or in utero cause the limbs to be

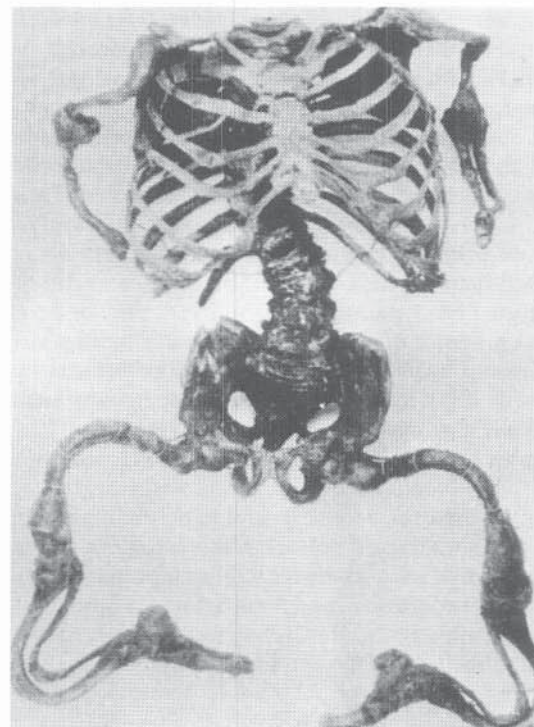


FIGURE 31–30 The skeleton in severe osteogenesis imperfecta.

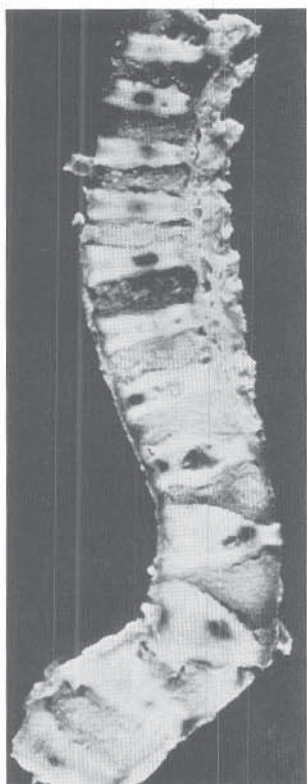


FIGURE 31–31 The spine in severe osteogenesis imperfecta. Vertebral bodies are biconcave and wedge-shaped, producing kyphoscoliosis.

deformed and short. Crepitation can be demonstrated by palpation at fracture sites. The skull is soft and membranous. This type is usually fatal, with death secondary to intracranial hemorrhage or respiratory insufficiency due to the incompetency of the rib cage; the infant is stillborn or lives only a short time.

In the nonlethal forms of the disease (Sillence's types I, III, and IV), fragility of the bones is the most outstanding feature. In severely affected patients, fractures that can occur on the slightest injury. In general, the earlier fractures that occur, the more severe is the disease, and, according to Shapiro, this has direct prognostic significance for ambulation.<sup>162</sup> Lower limbs are more frequently affected, as they are more prone to trauma. The femur is more commonly fractured than the tibia. The pattern of fracture depends on the nature of the trauma, the severity of the bone fragility, and the presence of preexisting deformity acting as a stress concentrator. Any fracture pattern may be seen in osteogenesis imperfecta, and no particular fracture pattern is specifically diagnostic of osteogenesis imperfecta.<sup>52</sup> Fractures heal at a normal rate; nonunion is relatively rare but does occur.<sup>69,123,151</sup> Fracture callus is typically wispy, but on rare occasions it may be very large and hyperplastic, resembling osteogenic sarcoma on radiographs.\* A pattern of repeated fractures can develop as the result of a combination of disuse osteopenia, progressive long bone deformity, and joint stiffness from immobilization. Growth may be arrested by multiple microfractures at the epiphyseal ends. The frequency of fractures declines sharply after adolescence, although it may

rise again in postmenopausal women. Bowing results from multiple transverse fractures of the long bones and muscle contraction across the weakened diaphysis. Typically, an anterolateral bow or proximal varus deformity; of the femur develops; an anterior or anteromedial bow of the tibia may develop. Acetabular protrusion (Otto pelvis) may be present; in one reported case, this resulted in colonic obstruction.<sup>184</sup> The humerus is usually angled laterally or anterolaterally. The forearm may be in minimal pronation; its rotation is often severely limited. Angulation is usually greater in the upper part of both bones of the forearm. The elbow joint has cubitus varus with flexion contracture.

The forehead is broad, with prominent parietal and temporal bones and an overhanging occiput. The bulging calvarium causes faciocranial disproportion, giving a triangular, elfin shape to the face. The ears are displaced downward and outward. The configuration of the skull in osteogenesis imperfecta has been likened to that of a soldier's helmet and is called "helmet head."

Severe spinal deformity may develop because of the combination of marked osteoporosis, compression fractures of the vertebrae, and ligamentous hyperlaxity.\* The resultant scoliosis and/or kyphosis may be very severe and disabling. Scoliosis is present in 20 to 40 percent of the patients. The most common type of curve is thoracic scoliosis. Some patients develop spondylolisthesis consequent on elongation of the pedicles without any actual break in the pars interarticularis. Cervical spinal fractures or instability are relatively rare but do occur,<sup>119,138,154,192</sup> including with associated cervical neurologic injury.<sup>138,192</sup> A more commonly reported cervical anomaly is basilar impression.<sup>64,80,86,95,114,141,155</sup> This condition in osteogenesis imperfecta may be due to an infolding of the margins of the foramen magnum or upward migration of the odontoid process, and results in compression of the brain stem and likely altered cerebrospinal fluid dynamics. Symptoms are highly variable but include headaches, ataxia, cranial nerve dysfunction, and paraparesis. Anterior or posterior decompression (or both) may be required.

Short stature is common. It is due to deformities of the limbs caused by angulation and overriding of fractures, growth disturbance at the physes, and the marked kyphoscoliosis. Hyperlaxity of ligaments is common, with resultant hypermobility of joints. Pes valgus is a frequent physical finding. Recurrent dislocation of the patellofemoral joint may occur. The radial head and the hip joint may occasionally be dislocated. Developmental dysplasia of the hip can occur;<sup>55</sup> unfortunately, femoral fractures resulting from screening for the condition have also been reported.<sup>134</sup> Infants suspected of having osteogenesis imperfecta must have their hips examined very gently, and physical examination should be supplemented by ultrasound examination whenever necessary. Adults may be predisposed to ruptures of the patellar ligament or Achilles tendon.<sup>51,133</sup>

The muscles are hypotonic, most probably because of the multiple fractures and deformities. The skin is thin and translucent. Subcutaneous hemorrhages may occur. As a rule, surgical scars tend to be wide.

Blue sclerae are one of the best-known manifestations of osteogenesis imperfecta<sup>37</sup> but are not present in all types. In type I, they are distinctly blue throughout life, and they are

\*See references 1, 6, 11–13, 32, 60, 92, 99, 112, 115, 148, 174, 182.

\*See references 19, 20, 47, 57, 75, 83, 87, 91, 123, 146, 190.



also blue in type II. In type III, they may be gray-blue at birth but become less blue with increasing age, and are white in the adult. In type IV they are usually normal. The blueness of the sclera is caused by the thinness of its collagen layer, due to the decreased production of type I collagen. Normal-colored sclerae in patients with osteogenesis imperfecta have a normal collagen thickness, but that collagen is, of course, abnormal. The so-called Saturn's ring, a frequent finding, is due to the white sclera immediately surrounding the cornea. Hyperopia is frequently present, but vision usually remains unaffected. An opacity in the periphery of the cornea, known as embryotoxon or arcus juvenilis, is common. Retinal detachment may occur.

The teeth are affected in patients with type IB and IVB disease as a result of a dentin deficiency.<sup>21,101</sup> The enamel is essentially normal, as it is of ectodermal, not mesenchymal, origin. Both deciduous and permanent teeth are involved. They break easily and are prone to caries, and fillings do not hold well. Yellowish brown or translucent bluish gray discoloration of the teeth is common (Fig. 31–32). The lower incisors, which erupt first, are the most severely affected. *Dentinogenesis imperfecta* (also called *hereditary opalescent dentin* or *hereditary hypoplasia of the dentin*) can exist as an isolated condition,<sup>17</sup> so that the diagnosis of osteogenesis imperfecta must be made on criteria other than the presence of affected teeth alone.

Deafness may occur in osteogenesis imperfecta, usually onset in adolescence or adulthood.<sup>163</sup> It is present in 40 percent of those with type I disease and is lower in frequency in type IV disease. Hearing loss may be either of the conduction type, due to otosclerosis, or of the nerve type, caused by pressure on the auditory nerve as it emerges from the skull. Otosclerosis results from abnormal proliferation of cartilage, which on ossification produces sclerosis of the petrous portion of the temporal bone.<sup>78</sup>

Some patients, particularly those with type III disease, complain of excessive sweating, thought to be due to a resting hypermetabolic state.<sup>48,159</sup> This is associated with heat intolerance and difficulty tolerating orthoses and can lead to chronic constipation.<sup>81</sup> A related problem is the possible susceptibility of patients to the development of malignant hyperthermia during general anesthesia. The development of increased temperature, metabolic acidosis, and cardiac arrhythmia suggesting this diagnosis has been reported.<sup>102,140,142,157</sup> Porsborg,<sup>140</sup> however, noted that the *in vitro*

contracture test for malignant hyperthermia was completely normal in muscle obtained from biopsy in one such affected patient. Both surgeon and anesthesiologist must be aware of the potential for such untoward intraoperative problems.

## RADIOGRAPHIC FINDINGS

**Severe Form.** Radiographic findings in patients with Silence's type II disease (or Shapiro's congenita A) are quite striking at birth. The long bones of the limbs are short and wide with thin cortices. The diaphyses are as wide as the metaphyses. Shapiro noted that this appearance is an important distinction from his congenita B type, in which the metaphyses of the femur have a more normal funnelization.<sup>162</sup> There are numerous fractures, some recent and others in various stages of healing. Multiple rib fractures and atrophy of the thoracic cage may simulate asphyxiating thoracic dysplasia. The presence of rib cage deformity is the other important radiographic feature distinguishing congenita A from congenita B disease.

Goldman and associates described "popcorn" calcifications in the metaphyseal and epiphyseal areas of long bones close to the growth plate, appearing as clustered collections of rounded or scalloped radiolucencies, each with a sclerotic margin and some with central radiopacities (Fig. 31–33).<sup>77</sup> These collections have been referred to in the literature as "whorls of radiodensities." They probably represent traumatic fragmentation of the cartilaginous growth plate.<sup>31,77</sup> The popcorn calcifications appear in childhood and usually resolve after completion of skeletal growth. They are more frequent in the lower than in the upper limbs and more common in the severe congenital type of disease. Their appearance parallels the development of growth plate irregularity. With a growth spurt, popcorn calcifications increase in number. In a severely affected nonambulatory child, as typified by congenita B patients, the lack of normal stress will give rise to a cystic honeycomb pattern in the long bones.

The skull has a mushroom appearance with a very thin calvarium. There is marked paucity and delay in ossification. Wormian bones (described by a Danish anatomist, Olaus Wormius, in 1643) are a salient radiographic feature of osteogenesis imperfecta.<sup>31</sup> They are detached portions of the primary ossification centers of the adjacent membrane bones. To be significant, wormian bones should be more

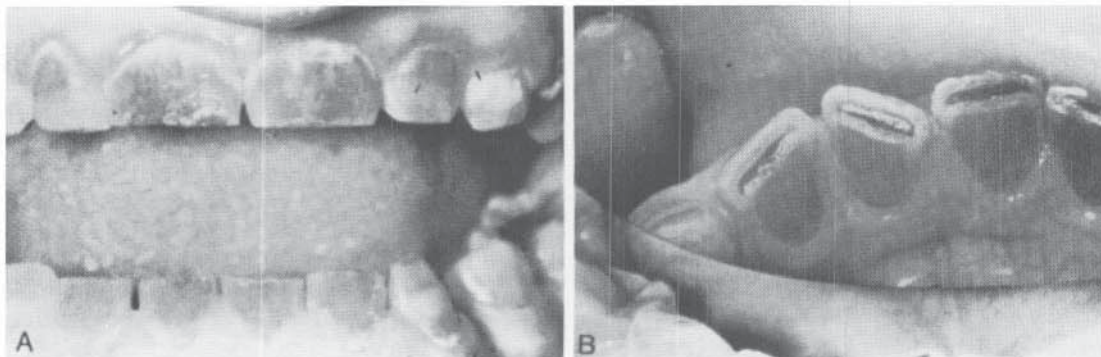


FIGURE 31–32 A and B, Dentinogenesis imperfecta. The dentin is opalescent and the teeth are fragile, prone to caries, wearing down, and fracture.

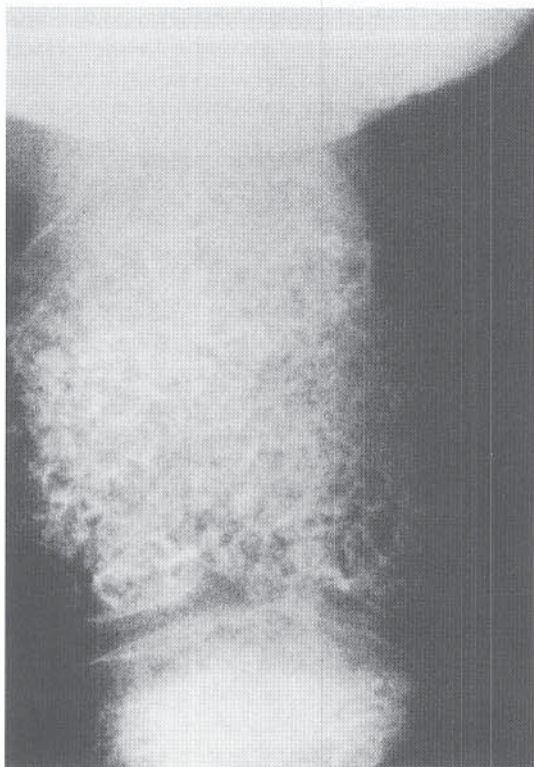


FIGURE 31–33 Appearance of “popcorn” calcifications in the distal femur, seen in severe osteogenesis imperfecta.

than 10 in number, measure at least 6 mm by 4 mm, and be arranged in a general mosaic pattern (Fig. 31–34). Cremin and associates<sup>46</sup> studied the skull radiographs of 81 patients with osteogenesis imperfecta and 500 normal children for the presence of significant wormian bones, which they found in all cases of osteogenesis imperfecta but not in the normal skulls.<sup>40</sup> Wormian bones may be present in other bone dysplasias, such as cleidocranial dysplasia, congenital hypothyroidism, pachydermoperiostosis, Menkes’ syndrome, and some trisomies,<sup>1</sup> so their presence is not pathognomonic for osteogenesis imperfecta.

The spine shows marked osteoporosis; the vertebral bodies are compressed, becoming biconcave between bulging disks (Fig. 31–35). Scoliosis and kyphosis eventually develop in the majority of congenital severe forms of osteogenesis imperfecta.

**Milder Forms.** In the milder forms of osteogenesis imperfecta the radiographic picture is that of osteoporosis: the cortices and intramedullary trabeculae are thin. Fractures vary in frequency and age of occurrence. Radiographs may show fractures in various stages of healing. Fractures tend to heal and remodel quite adequately in less severely affected patients. Plastic bowing of long bones is common and is due to microfractures and stress fractures or malunion of fractures. One lower limb may be in valgus deformation and the other in varus deviation. In the hip, coxa vara and acetabular protrusion may be found. The patellar joint, the radial head, or the hip may dislocate. Platyspondyly and biconcave vertebrae are common. Varying degrees of scoliosis and kyphosis develop in up to 40 percent of cases.

In adolescence or adult life, basilar impression of the

foramen magnum into the posterior cranial fossa may develop.\*

### HYPERPLASTIC CALLUS AND TUMORS IN OSTEOGENESIS IMPERFECTA

*Hyperplastic callus formation* in patients with osteogenesis imperfecta is a rare but clinically disturbing event.† The clinical scenario is of an acute localized inflammation, with progressive, often alarming enlargement of the involved limb over a 1- to 3-week period. Hyperplastic callus has been reported to occur as an apparently spontaneous event,<sup>60</sup> after trauma or fracture,<sup>112</sup> and after limb surgery, particularly intramedullary rodding.<sup>32,115,151</sup> The condition appears to be most common in the lower extremities of males with types III or IV osteogenesis imperfecta. The involved limb develops an enlarging mass that is painful, warm to the touch, and tender on palpation. The overlying skin is tense and translucent, with dilation of the superficial veins. Prolonged low-grade fever is commonly present. In one case, bilateral femoral hyperplastic callus formation after intramedullary rodding led to high-output cardiac failure.<sup>32</sup> Laboratory studies show an elevated erythrocyte sedimentation rate and alkaline phosphatase level. Radiographs show an enlarging, irregular, callous mass enveloping the involved bone (Fig. 31–36).

The development of hyperplastic callus is a cause for great concern, not only in managing the affected extremity but also because of diagnostic problems in distinguishing hyperplastic callus from osteogenic sarcoma. Banta and associates reported 21 cases of hyperplastic callus.<sup>12</sup> Three of the patients underwent amputation for the presumptive diagnosis of osteogenic sarcoma, which subsequently proved to be hyperplastic callus. To further complicate the picture, osteogenic sarcoma has been reported in patients with osteogenesis imperfecta,<sup>92,98,145,156</sup> so this is not an idle concern. If there is any doubt in the individual case, a confirmatory biopsy must be performed. One postoperative case was associated with initial evidence of deep wound infection,<sup>32</sup> so cultures should be performed as well. However, true deep wound infection has not generally been an inciting or intercurrent condition with hyperplastic callus formation.

Histologic examination of the callus shows fibromucoid, cartilage-like tissue, or “chondroid,” a transitional form between fibrous, mucoid, and cartilaginous tissue. In contrast, a normal callus consists of a network of woven bone trabeculae lying in fairly dense connective tissue without mucoid or chondroid.<sup>12,52</sup> The peripheral part of the mass shows undifferentiated tissue, while the central part is more differentiated, resembling normal callus.

Treatment is symptomatic. The affected extremity is splinted for comfort. Benefit from palliative radiation therapy has been reported in the literature.<sup>12,13,32,101,177</sup> Great caution must be used in pursuing this course of treatment, however, because of the risk of development of sarcomatous changes in the irradiated tissues. Diphosphonates have also been tried, but without apparent success.<sup>32</sup>

*Osteogenic sarcoma* has clearly occurred in patients with osteogenesis imperfecta.<sup>90,92,98,145,156</sup> The treating physician

\*See references 57, 64, 80, 86, 91, 95, 114, 141, 155.

†See references 6, 11, 12, 32, 60, 99, 112, 115, 148, 151, 174, 182.

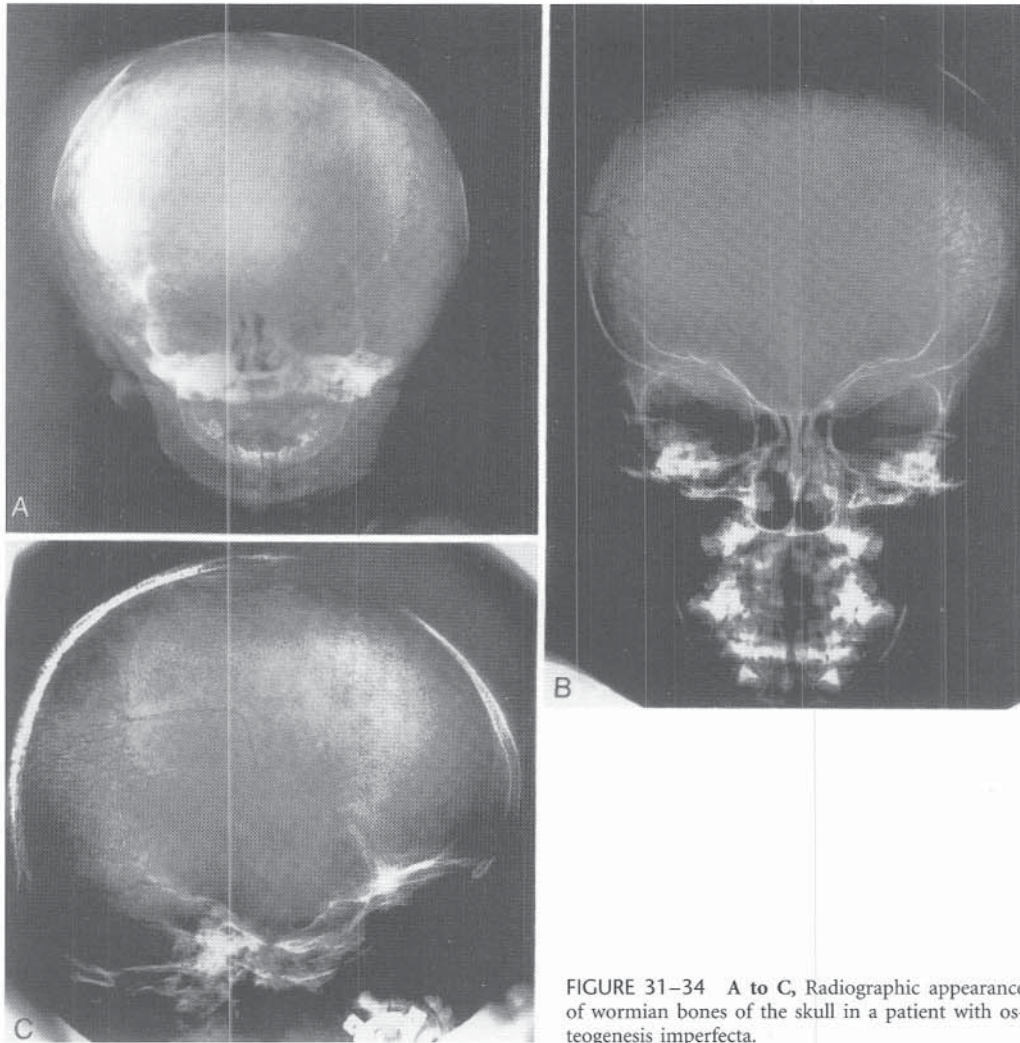


FIGURE 31-34 A to C, Radiographic appearance of wormian bones of the skull in a patient with osteogenesis imperfecta.

must not only be alert to this possibility but consider this diagnosis actively when confronted with a patient with hyperplastic callus formation. The case reported by Jewell and Lofstrom occurred in the pelvis of a 49-year-old man.<sup>90</sup> In most other reported cases the tumor arose from the femur<sup>92,98,156</sup> and the patient died of metastatic disease. Osteogenic sarcoma has been reported in all surviving Silence types.

Other rare tumor or tumorlike conditions that have been reported in patients with osteogenesis imperfecta include *aneurysmal bone cyst* in the radius of an 8-year-old girl,<sup>88</sup> and *unicameral bone cyst* of the proximal humerus in three patients.<sup>153</sup>

### LABORATORY FINDINGS

In osteogenesis imperfecta, results of routine laboratory investigations are normal. Specifically, serum calcium and phosphorus levels are normal. The alkaline phosphatase level may be elevated.

In general, the diagnosis of osteogenesis imperfecta can be made based on a positive family history and the presence of typical clinical and radiographic signs of the condition. However, spontaneous mutations in affected individuals,

especially in patients who may be mildly affected, with white sclerae, may make the diagnosis more difficult. More than 90 percent of affected individuals will have a demonstrable quantitative and/or qualitative defect in type I collagen. A very large number of genetic mutations result in these defects. As a consequence, only a few families have a sufficiently documented specific locus of mutation to allow direct or linkage analysis of the presence of the defective gene in any given individual. Much more commonly, biochemical analysis of type I collagen obtained from fibroblasts cultured from the skin biopsy specimen of the individual in whom the diagnosis is questioned will be required to confirm the diagnosis.

### DIFFERENTIAL DIAGNOSIS

In the newborn and in early infancy, Silence's type II osteogenesis imperfecta should be distinguished from *congenital hypophosphatasia*. In the latter, a lethal affection, the laboratory tests will show a low phosphatase level in the serum, a lack of alkaline phosphatase activity in the leukocytes, and excessive excretion of phosphorylethanolamine in the urine.

In the infant, osteogenesis imperfecta and *achondroplasia*

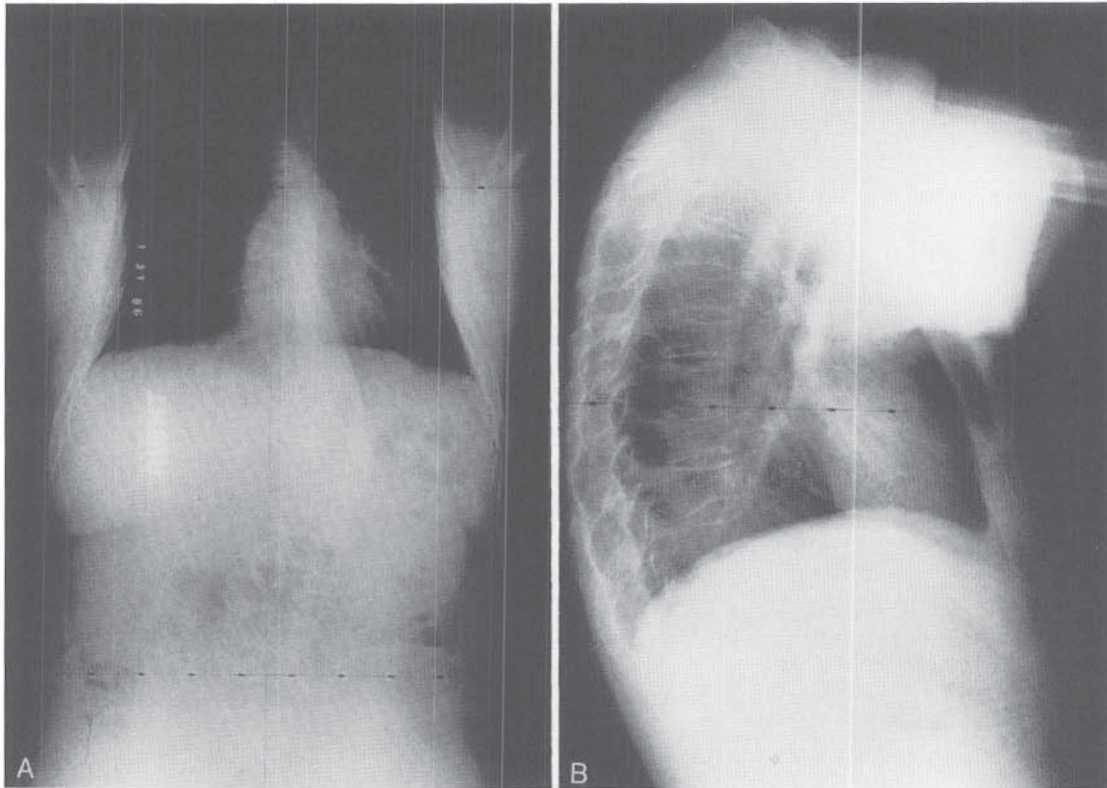


FIGURE 31-35 The spine in an adolescent with osteogenesis imperfecta. Note the structural scoliosis and the collapsed vertebrae. A, AP radiograph of the spine showing structural scoliosis. B, Lateral radiograph of dorsal spine showing osteoporosis and biconcave vertebrae.

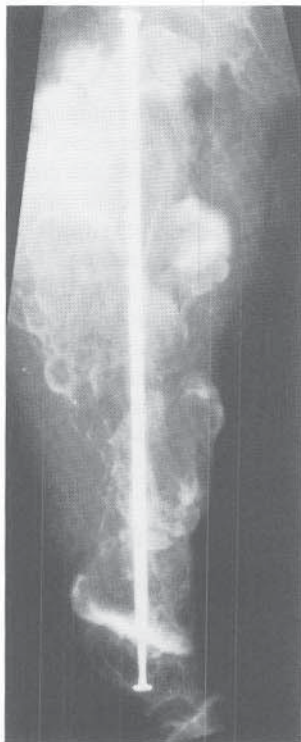


FIGURE 31-36 Hyperplastic callus formation in the femur after intramedullary fixation.

are frequently confused clinically because an enlarged head and short limbs are common to both conditions. Radiographs will easily distinguish between the two conditions.

*Camptomelic dwarfism* may be mistaken for osteogenesis imperfecta because of the congenital bowing and angulation of the long bones. Fractures, however, are not a feature of this type of dwarfism.

The presence of osteoporosis and a proclivity to fracture in *cystinosis* may suggest osteogenesis imperfecta.

Patients with *pycnodysostosis* may have a propensity to fracture. Patients with this condition will have bony sclerosis evident on radiographs, persistently wide cranial fontanelles, micrognathism with absence of the mandible, hypoplasia of the clavicles, and osteolysis of the terminal phalanges of the fingers.

The diffuse osteopenia in the early stages of *leukemia*, before the appearance of the typical blood picture, may be mistaken for osteogenesis imperfecta.

*Idiopathic juvenile osteoporosis* may be very difficult to distinguish from osteogenesis imperfecta; the former is characterized by being a self-limiting disorder and by its onset a year or so before puberty. Osteoporosis and compression fractures of the vertebrae may also be caused by prolonged intake of steroids.

An important diagnosis to be considered in patient presenting with fractures is nonaccidental injury, that is, child abuse or battered child syndrome. Accusations of nonaccidental injury in children subsequently proven to have osteogenesis imperfecta, a presumption of osteogenesis imperfecta in abused children, and nonaccidental injury in

children with osteogenesis imperfecta are all known to occur.<sup>8,52,93,135,136,176</sup> Therefore, the clinician must carefully assess each child presenting with suspicious fractures. A family history of disease, blue sclerae, or the presence of dentinogenesis imperfecta will make this distinction easy in some patients. The proper diagnosis of milder forms of osteogenesis imperfecta, especially in patients without a family history or obviously blue sclerae (Sillence's types III and IV, Shapiro's tarda A and B) may be more difficult. Other than the very severe multiple fracture patterns with or without rib and skull deformities that characterize type II osteogenesis imperfecta, no particular fracture pattern will specifically substantiate or exclude the diagnosis of osteogenesis imperfecta. Because a specific diagnosis is clinically important, skin biopsy for fibroblast culture and type I collagen analysis may be required.

## TREATMENT

There is no specific treatment to correct the basic mutant gene defect in osteogenesis imperfecta. Until recently, efforts to medically induce stronger bone less prone to fracture met with limited or no success. A rehabilitation program that includes protective bracing and physical therapy to improve muscle strength and independent function can be very beneficial for more severely affected children. The orthopaedic surgeon will be extensively involved with children with osteogenesis imperfecta in the course of managing individual fractures, repeated fractures, long bone deformity, and spinal deformity.

**Medical Treatment.** Until recently, efforts to improve bone strength by medical means were largely unsuccessful. The administration of sex hormones,<sup>36</sup> sodium fluoride,<sup>2,22</sup> calcitonin,<sup>35,131</sup> calcium, growth hormone, magnesium oxide, and vitamins D or C were all attempted in the past, usually with no or mixed results.

Recently, however, very promising studies regarding the use of a bisphosphonate, aminohydroxypropylidene (pamidronate), have been published.<sup>7,18,67,76,85</sup> This compound inhibits osteoclastic resorption of bone, an activity that appears to be increased in patients with osteogenesis imperfecta. Administration of this medication intravenously in dosages ranging from 15 mg given every 20 days<sup>18</sup> to 7 mg/kg/year given every 4 to 6 months<sup>76</sup> has resulted in subjective improvement in complaints of generalized bone pain and fracture frequency. In addition, increased bone mineral density as determined from dual-energy x-ray absorptiometry has been noted.<sup>7,18,76</sup> Transient fever and increased serum calcium levels can occur during the intravenous administration of this medication and must be watched for. No negative effect on longitudinal bone growth or fracture healing has been noted. However, these reports must be considered preliminary, as the potential long-term adverse effects of use of this medication have not yet been published.

The ideal treatment of osteogenesis imperfecta would be to correct the basic genetic defect by replacing the defective *COL1A1* or *COL1A2* gene with a normal one. That capability, of course, does not yet exist. Horwitz and associates<sup>84</sup> have published preliminary results in three severely affected patients treated with bone marrow harvested from an unaffected sibling after host marrow suppression.<sup>84</sup> Subsequent

biopsy in the recipients demonstrated exuberant new bone formation, and most hemopoietic cells were of donor origin. Correspondingly, bone density measurements improved, growth velocity increased, and there was a dramatic reduction in the incidence of fractures. However, one of the three patients also developed pulmonary insufficiency and sepsis during treatment. Thus, these promising preliminary results must be very carefully assessed in the context of the considerable morbidity and potential mortality associated with bone marrow transplantation.

**Orthopaedic Treatment.** The goal of orthopaedic treatment is to maximize the affected patient's function, prevent deformity and disability resulting from fractures, correct deformities that have developed, and monitor for potential complicating conditions associated with osteogenesis imperfecta. In addition, the orthopaedist should be able to provide realistic expectations of disability and mobility to the family of an affected infant. These goals can be analyzed according to prognostication as to future mobility and complications, nonoperative rehabilitation, and the specific management of fractures, long bone deformity, spinal deformity and basilar impression.

## PROGNOSTICATION AND PARENTAL COUNSELING

Parents will need to know the likelihood of survival of the affected infant, and, when perinatal death is unlikely, what to expect in the future with regard to ambulation and deformity. They may also want genetic counseling and prenatal screening in future pregnancies. It is important to emphasize to the parents that surviving infants, even if significantly affected by bone fragility, are typically characterized by normal intelligence, determination, and excellent social skills that allow them to compensate admirably for their skeletal disability.

**Survival.** The most important indicators of survival of an affected infant are the location and severity of the fractures and the radiographic appearance of the skeleton. As has been pointed out by Sillence<sup>167</sup> and Shapiro,<sup>162</sup> multiple birth fractures or fractures in utero associated with chest wall deformity and crumpled long bones are generally incompatible with life, and if the infant is not stillborn, early death from intracranial hemorrhage or respiratory insufficiency will ensue. On the other hand, multiple fractures at birth without rib cage deformity and with relatively normal funnelization of the femur can be compatible with long-term survival, and even walking in some cases.<sup>162</sup>

Patients who are mildly affected (particularly Sillence's type IA patients) often have a normal life span.<sup>114,137</sup> Paterson and associates<sup>137</sup> noted that Sillence's types IB and IV patients had only modestly reduced life spans.<sup>137</sup> More severely affected patients may have their life span shortened by a susceptibility to cardiac or pulmonary insufficiency related to chest wall deformity or kyphoscoliosis.<sup>114</sup> Paterson and associates noted in their review that of 26 patients with Sillence's type III disease who had died, 19 did so prior to age 10, so that those who survived beyond that age seemed to have a better outlook.<sup>137</sup> More severely affected patients are susceptible to the development of basilar impression, causing death. Finally, deaths have occurred from the consequences

of polytrauma after accidents that might otherwise be considered relatively trivial, due to the relative fragility of such patients.<sup>114</sup>

**Ambulation.** The future ambulatory ability of the affected infant is probably best predicted by Shapiro's classification into the categories of congenita A and B and tarda A and B.<sup>162</sup> Although patients with osteogenesis imperfecta congenita A are unlikely to survive, those with congenita B (fractures at birth or in utero, with normal funnelization and without rib cage deformity) are not only likely to survive, but one-third, in Shapiro's experience, achieved ambulation. Sixty-seven percent of patients who sustained fractures after birth but prior to walking (tarda A) ultimately were able to walk, by his report, while all patients whose initial fracture occurred after walking age remained ambulatory. Prognosis using this classification has been substantiated by Daly and associates, who further found that the age at which the patient achieved independent sitting was also important: 76 percent of patients who were able to sit independently by age 10 months achieved ambulation, whereas only 18 percent of those who were not sitting independently by this age were ultimately able to walk.<sup>50</sup> These authors also found that Sillence's classification was predictive of ambulation. Specifically, in their patient population, nearly all Sillence type I patients were independent ambulators, all type III patients were wheelchair dependent, and three of seven type IV patients were able to walk.

**Antenatal Diagnosis.** According to Ablin, osteogenesis imperfecta is one of the most common skeletal dysplasias to be diagnosed based on fetal ultrasonographic findings.<sup>1</sup> Most cases are Sillence's type II, and as such represent an unexpected finding because of the usual absence of a positive family history.

The ultrasonographic features of type II, usually identifiable by fetal age 16 weeks, include long bone deformity (implying fracture), severely reduced femoral length, and decreased echogenicity of the skull, with correspondingly better than usual visualization of the brain.<sup>1,28,178</sup> Rib fractures or chest wall deformity may also be detectable. The prenatal findings of the fetus affected by Sillence's type I, III, or IV disease will vary with the severity of the disease expression, and may be normal in mildly affected type I patients.

Couples with a history of a fetus affected by type II osteogenesis imperfecta have a 2 to 7 percent risk of having another similarly affected fetus owing to mosaicism in one parent. In such cases the antenatal diagnosis can be made between 13 and 14 weeks of gestation by DNA analysis of chorionic villous cells obtained by ultrasound-guided chorionic villous sampling.

## REHABILITATION

The orthopaedist will be called on to assist in the rehabilitation of infants with osteogenesis imperfecta who survive the neonatal period. Infants with birth fractures usually need only careful, supportive handling to prevent further injury. If long bone fractures are unstable, minimal external splinting may be used to stabilize the affected limb; such fractures will usually heal within a week or two. It is important to avoid immobilization of excessive extent or duration at any age, since such treatment will aggravate osteopenia and in-

duce joint stiffness, either of which in turn increases the risk of fracture.

Protective bracing to prevent fractures and aid in ambulation is a mainstay in the conservative management of patients with osteogenesis imperfecta.\* Typically, lightweight plastic and metal hip-knee-ankle-foot orthoses (HKAFOs) are required for effective lower extremity bracing in the most severely affected patients. These braces may allow patients to stand or walk, usually with the upper extremity aids of crutches or a walker. In addition, HKAFOs can reduce the incidence of lower extremity fractures compared to the incidence in unbraced patients.<sup>72,73</sup>

Lightweight air-filled fluted trouser splints have been reported to be an effective simple alternative to HKAFOs for the purpose of allowing severely affected children to stand.<sup>68,100,124</sup> These splints are lighter than conventional orthoses and easier to fit, provided the child does not have major lower extremity long bone deformity. However, they are not in common use in North America.

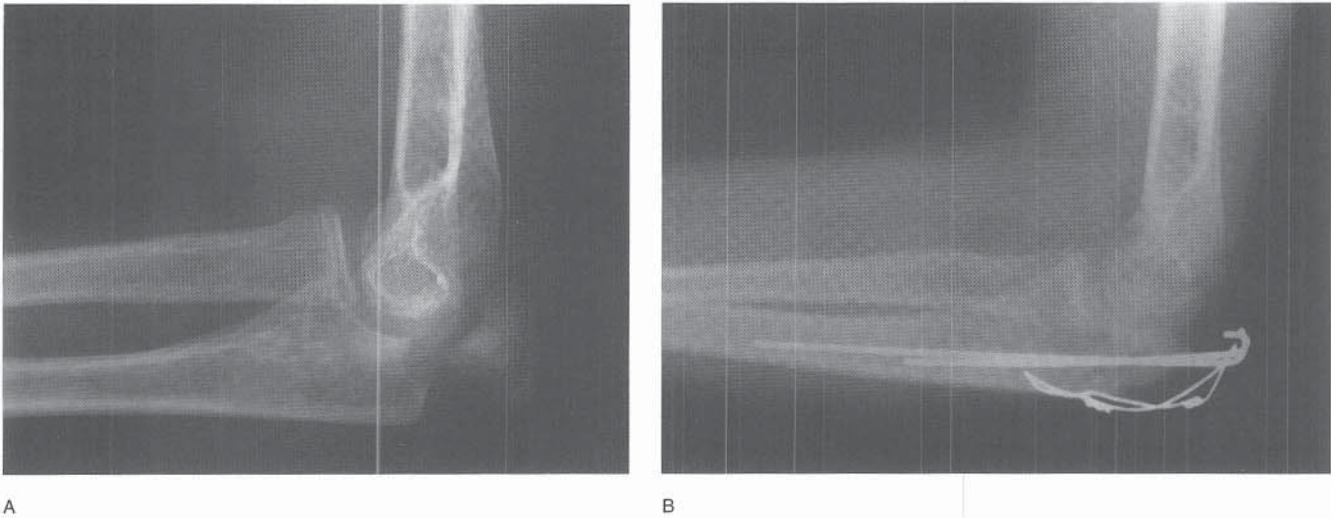
Nonambulatory osteogenesis imperfecta patients are ideal users of motorized wheelchairs, since they have the intelligence to use them effectively and often have upper extremity deformity or weakness that hinders the use of standard wheelchairs. Custom inserts may be required to support the trunk and accommodate spinal deformity. Such mobility aids should be made available to nonambulatory patients as soon as the child's intellectual development allows him or her to safely operate one.

## MANAGEMENT OF LONG BONE FRACTURES

The management of long bone fractures depends on the severity of the fracture and the age of the patient. General management principles are based on the facts that most fractures heal, recurrent fractures are common, and inherent osteopenia may be aggravated by prolonged immobilization, thus making the patient even more susceptible to fracture. For these reasons, fractures should be immobilized only until symptoms resolve, with the minimum amount of external immobilization required to provide comfort. Patients should be encouraged to return judiciously to their usual level of activity as soon as feasible. Radiographs are not always required, especially if the fracture is not grossly unstable or does not result in a new deformity. The patient's immobilization should be based on symptoms, and for minor fractures serial radiographs are not usually necessary. Frequently children present with pain suggesting a fracture but radiographs show no evidence of one. Such patients should be immobilized as if a fracture were present (which it almost certainly is). Although technitium 99 bone scan, MRI, or follow-up radiographs can demonstrate fracture, these investigations are rarely necessary and are of no help to patient or physician in the management of the fracture. Many times, the parents of a severely affected child will not even seek medical assistance for minor fractures because of the frequency of such fractures and the confidence gained by the parent in treating the infant or child symptomatically.

Fractures in the newborn, if unstable or interfering of normal handling, may be splinted with padded tongue depressors, padded aluminum splints, or plaster splints. Usu-

\*See references 23-27, 50, 68, 72, 73, 100, 124.



**FIGURE 31-37** Olecranon fracture in a patient with mild osteogenesis imperfecta type I. **A**, Preoperative radiograph showing the typical avulsion pattern of this fracture. **B**, Postoperative radiograph after open reduction and internal fixation using tension-band wiring technique.

ally only a week or two of splinting will be required until the fracture has stabilized. Fractures in the older child or adult, particularly when the patient has relatively minor involvement, should be treated by means appropriate to the fracture, including reduction and casting, percutaneous pinning, or internal fixation. The operating surgeon must exercise extreme caution in handling the patient and the fracture to prevent further fracture or fragmentation of the fracture under treatment. As a general principle, intramedullary fixation is preferable to plates and screws whenever possible because of the stress risers produced by the latter. The operating surgeon must be familiar with the techniques and pitfalls unique to the use of intramedullary fixation in patients with osteogenesis imperfecta, as discussed below under Management of Long Bone Deformity. Presumably, external fixation may also be used in these patients when indicated, and external fixation has been used to correct deformities in patients with osteogenesis imperfecta.<sup>63,96,147</sup> However, the use of external fixation for fractures in patients with osteogenesis imperfecta has not been described in the literature, and the benefits and risks of this technique must be carefully assessed by the treating surgeon.

Other than extreme fragility and the crumpled long bone deformities seen in severe cases of osteogenesis imperfecta, no specific fracture pattern is unique to these patients.<sup>52</sup> One fracture that occurs commonly, usually in more mildly affected Sillence type I patients, is a displaced fracture of the olecranon.<sup>53,113,126,173</sup> These fractures will often occur bilaterally, although not usually simultaneously.<sup>53,113,173</sup> They can be managed by tension band wiring techniques, with good restoration of function (Fig. 31-37).<sup>167</sup>

Nonunions are an uncommon sequela of fracture or surgery in osteogenesis imperfecta, but they do occur. Gamble and associates reported 12 nonunions in 10 patients; the nonunions occurred most commonly in the femur and humerus, but also in the radius, ulna, and pubis.<sup>69</sup> Nine of the 10 patients had osteogenesis imperfecta type III. Frequent fractures and deformity at the affected site were often associated with the development of nonunion. Eight of the nine

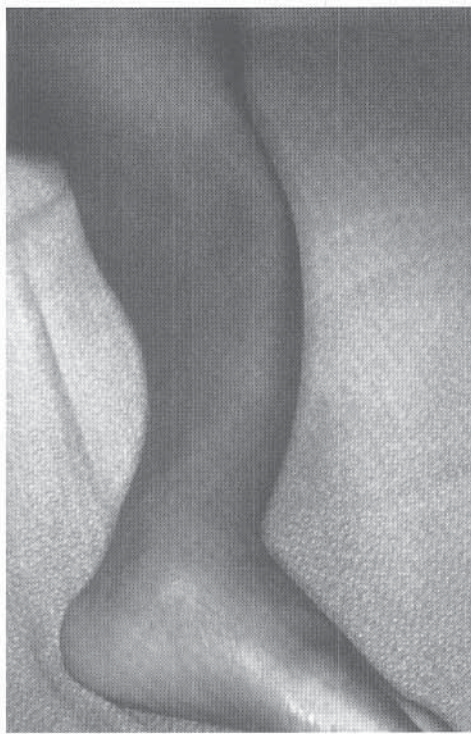
fractures that were operated on healed after intramedullary fixation and grafting. This treatment failed in one supracondylar femoral nonunion, and the patient required an amputation for pain relief.

### MANAGEMENT OF LONG BONE DEFORMITY

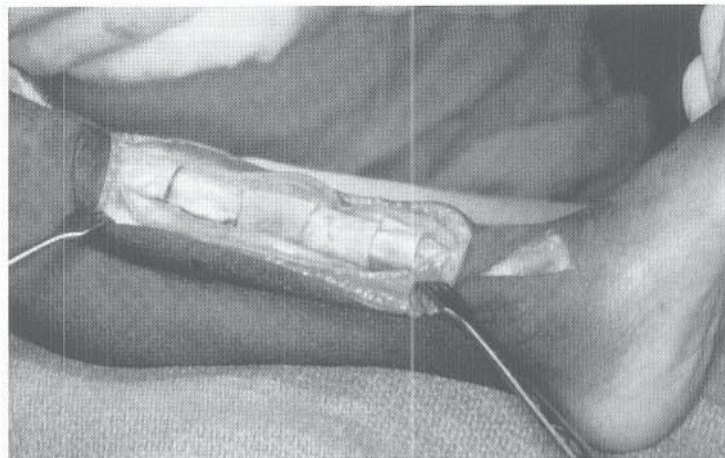
Long bone deformity is one of the most frequent conditions requiring treatment in patients with osteogenesis imperfecta. Its incidence is in general related to the severity of the underlying bone fragility, and thus it is more likely to be seen in Sillence's types III and IV, although this deformity is by no means limited to these types. Long bone bowing is induced by bone fragility, deforming muscular forces, and repeated fractures and, in turn, results in repeated fractures. Thus, the most important indication for surgical correction of long bone deformity is repeated fractures induced by the deformity. A further indication for surgery is to remove deformity to allow bracing for either protection against further fractures or to aid in ambulation. It is not clear from the literature, however, that the correction of long bone deformity alone results in long-term ambulation.<sup>50</sup> Long bone deformity in infants and children can be corrected by closed osteoclasia without intramedullary fixation,<sup>124</sup> by closed osteoclasia with percutaneous intramedullary fixation,<sup>66,117,120,121,158,164</sup> and by open osteotomy with internal fixation.\* In addition, external fixation by the Ilizarov circular fixator with wire fixation and osteotomy have been used to correct long bone deformity in young adult patients.<sup>63,96,147</sup>

**Closed Osteoclasia Without Internal Fixation.** Manual osteoclasia of long bone deformity has been described<sup>124</sup> and is generally indicated in medically fragile children who may not be able to tolerate blood loss and other physiologic stresses of a formal open operative procedure but whose deformity creates management difficulties. In essence, the treating physician gently manipulates the deformed bone

\*See references 9, 10, 29, 39, 49, 50, 58, 65, 70, 71, 89, 97, 106-108, 118, 127, 128, 130, 139, 150-152, 169, 171, 177, 185-187, 189, 191.



A



B

FIGURE 31–38 Sofield procedure of fragmentation and intramedullary fixation of long bone. A, Preoperative appearance of long bone deformity. B, Intraoperative photograph showing multiple osteotomies to allow straightening of the bone, with intramedullary fixation of the fragments on a rod (see text).

with the child under adequate sedation or anesthesia and immobilizes the limb until union. This procedure is usually followed by the application of protective bracing to help prevent further fractures and recurrent deformity. The procedure is indicated only when one of the procedures described below is not possible for any reason.

**Closed Osteoclasis with Percutaneous Intramedullary Fixation.** This procedure is essentially the same as above, except that in addition to the external manual correction of deformity, the operating surgeon attempts to “splint” the long bone by percutaneously threading a smooth rod (Kirschner wire, Steinmann pin, or Rush rod) in an intramedullary fashion.<sup>66,117,120,121,158,164</sup> This procedure is also indicated for the patient who sustains repeated fractures that interfere with care and in whom formal open fixation is not feasible due to bone fragility. The basic surgical technique is to percutaneously thread a small-diameter smooth rod within the intramedullary canal of an affected bone while simultaneously bending or breaking the bone by external compression to allow the rod to pass within the intramedullary canal. Fluoroscopy and good fortune are required. We prefer to manage patients conservatively until their age, bone size, and medical stability allow them to undergo open osteoclasis with intramedullary fixation.

**Open Osteotomy with Intramedullary Fixation (Sofield Procedure).** A procedure entailing multiple diaphyseal osteotomies (“fragmentation”) with intramedullary fixation was described for osteogenesis imperfecta by Sofield and Millar,<sup>169</sup> although Springer had earlier described this technique for correction of long bone deformity in rickets.<sup>177</sup> The indications for fragmentation and rodding are long bone deformity that interfere with the fitting of orthoses

and impair function, and repeated fractures. These indications are much more frequent in the lower extremity than in the upper extremity. The basic principle is to expose the deformed bone subperiosteally, make appropriate wedge-shaped osteotomies in the deformed metaphysis and diaphysis to allow straightening of the bone, and to fix the fragments on an intramedullary rod of some sort to maintain alignment and provide long-term internal splinting of the fragile bone (Fig. 31–38). A great deal has been written about the technique and the results achieved with different intramedullary devices.\* In general, reports are favorable in that deformity is corrected and mobility maintained or achieved.† Daly and associates, however, in a survey of adults were unable to demonstrate that intramedullary fixation had a long-term influence in respect to maintaining the ability to ambulate.<sup>50</sup> Complications of the procedure include non-union, infection, and rod migration. These complications are remarkably uncommon, however, in the context of a procedure that produces multiple devascularized segments of long bone.

Sofield used a fixed intramedullary rod (a “straight, round steel rod,” Rush rod, or Kuntscher rod) for internal fixation.<sup>169</sup> Other authors have used Rush rods<sup>106,123,139</sup> or Williams rods.<sup>186,187</sup> The technique of Williams rod insertion is described in Chapter 21, Disorders of the Leg, in the section titled Intramedullary Fixation. When a Williams rod is used in the tibia, the rod is usually left embedded within the tibia itself, and is not left across the ankle and subtalar

\*See references 9, 10, 29, 32, 34, 39, 49, 50, 58, 65, 66, 70, 71, 89, 97, 106–108, 115, 118, 120, 123, 127, 128, 130, 139, 150–152, 169, 171, 177, 185–187, 189, 191.

†See references 39, 58, 65, 89, 97, 106, 123, 128, 171, 185, 191.



joints. This procedure must be undertaken with careful preoperative planning and good communication among the orthopedic surgeon, operating room personnel, and anesthesiologist. All parties must handle the fragile child carefully. Blood pressure cuffs may not be advisable if humeral fragility is extreme. The patient's temperature will often rise during surgery, and the patient should be kept cool. The anesthesiologist must be alert to temperature elevation, metabolic acidosis, the potential for cardiac arrhythmias, and the potential development of true malignant hyperthermia (see Chapter 8, Anesthesiology). Excessive bleeding requiring transfusion is a distinct possibility and must be prepared for. Patients with osteogenesis imperfecta tend to bruise easily and may develop a bleeding diathesis. The surgeon probably will not be able to use a tourniquet during extremity surgery, extensive exposure of the deformed bone will be necessary to perform corrective osteotomies, and many trying technical challenges may arise as the surgeon attempts to thread a series of fragile, macaroni-shaped wisps of bone onto an unforgiving rod. Thus, when surgery on both femora or on all four lower limb segments is indicated, the operations may need to be staged to avoid life-threatening hemorrhage.

The operating surgeon and the operating staff must have a full assortment of lengths and breadths available of the intramedullary device to be used, and pliers and bolt cutters to modify the device as needed during insertion. Fluoroscopy should be available to help guide insertion where insertion is not done under direct vision, such as through the epiphyses.

An extensive exposure of most of the length of the involved bone is almost always required. The femur is approached anterolaterally and the tibia directly anteriorly. Care should be taken to identify the landmarks of the anterolateral approach to the femur, especially the intermuscular septum. Otherwise, excessive bleeding and damage to muscle will result. Once the curved bone is exposed, the surgeon cuts into it with a knife, rongeur, osteotome, or saw, as needed, in as many places as necessary to create a straight diaphysis. Although some authors have recommended preserving as much periosteal insertion in the bone as possible to preserve blood supply to the individual segments,<sup>171,185</sup> in fact, nonunion or infection harbored by devascularized bone is surprisingly infrequent, and such periosteal insertion preservation may not be important. Straightening the deformed limb will result in soft tissue lengthening, so portions of bone may have to be removed to avoid excessive soft tissue tension.

Intramedullary reaming is often required. The surgeon should choose the narrowest bone fragment first and ream with a drill of appropriate diameter. There may be no medullary cavity. Beginning at one metaphyseal or epiphyseal end, depending on the rod being used, the rod is then advanced toward the other metaphysis, with the bone fragments threaded on the rod as it is advanced. The rod must be carefully sized for length before it is advanced into the final segment, and cut as necessary. In most instances, rotational control of the bone is poor, and the patient should be immobilized in a long-leg or spica cast. Weightbearing in the cast should be encouraged as soon as is feasible, and the cast should be replaced with HKAF orthoses as soon as union is evident radiographically.

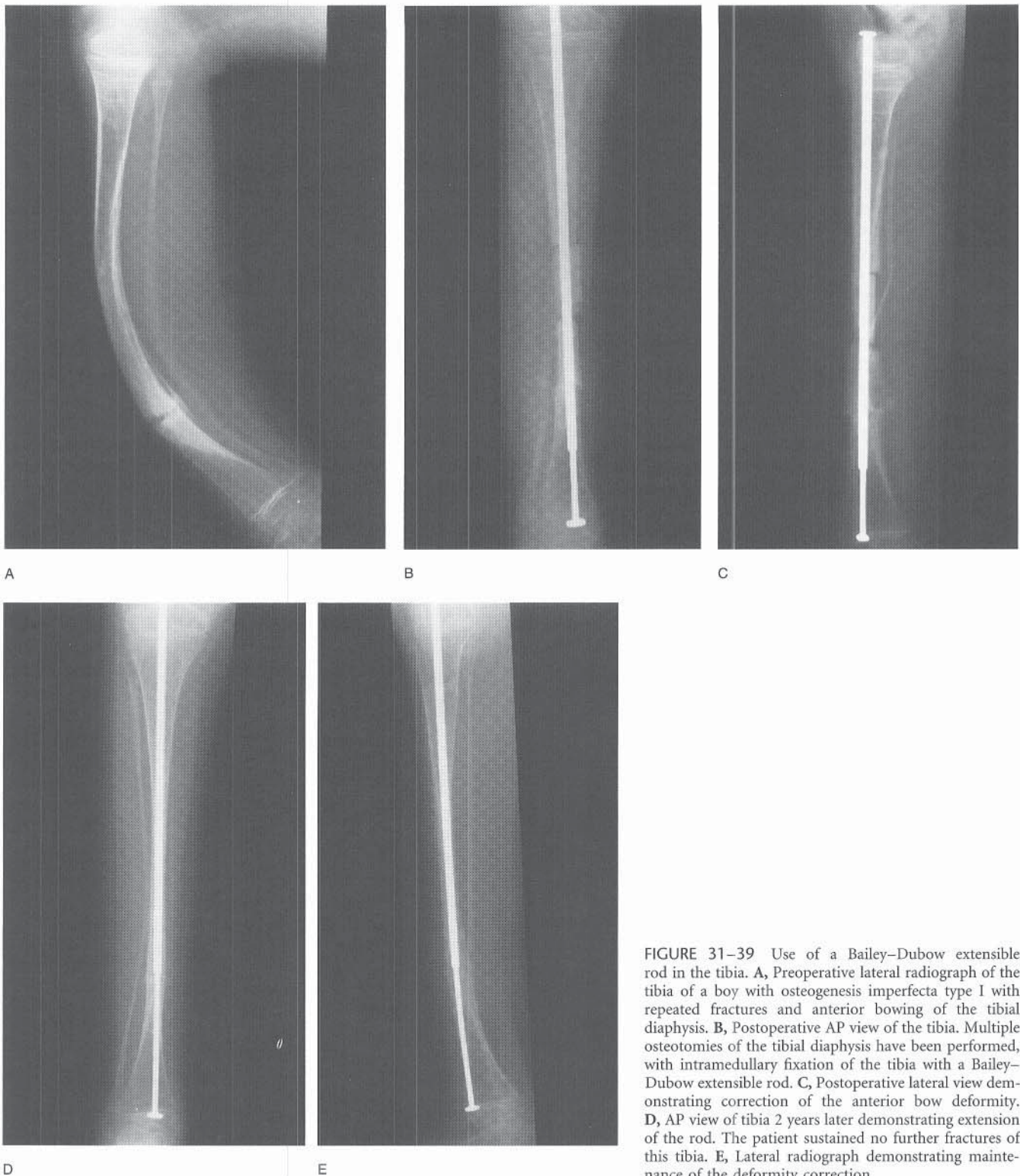
### Use of the Extensible Intramedullary (Bailey-Dubow)

**Rod.** One of the problems that can develop with the use of a fixed-length intramedullary device in children is growth of the epiphysis beyond the rod. This in turn often results in progressive deformity beyond the limits of the rod, with fracture or rod protrusion. Revision of the intramedullary fixation is thus often required, especially if the child was young when the procedure was first performed. To overcome this problem, Bailey and Dubow introduced an extensible intramedullary fixation device to reduce the need for reoperation because of bone overgrowth (Fig. 31–39).<sup>9</sup> The telescoping intramedullary rod consists of an outer tubular sleeve with a detachable T-shaped end and an inner obturator rod with a solid T-shaped end. The inner rod can be entirely telescoped into the sleeve (Fig. 31–40).

The surgical approach to the femur and tibia and the technique of fragmenting and stringing the diaphysis on the rod are similar to those of Sofield and Millar. The bowed bone is exposed subperiosteally from metaphysis to metaphysis. Additional exposure of the epiphyses is required for insertion of the T-piece for the outer rod and the inner, fixed T-ended rod. In the femur, the intercondylar notch is exposed by knee arthrotomy. Usually only minimal exposure of the upper end of the femur is required, in the region of the greater trochanter. In the tibia, the tibial plateau is exposed by knee arthrotomy. Access to the distal tibia is gained by arthrotomy and mobilization of the talus. The latter is accomplished by dividing the deltoid ligament, formally osteotomizing the medial malleolus (usually not required or feasible because of bone fragility), or detaching the deltoid ligament insertion with a sliver of medial malleolus using a knife.

The length of the outer rod must be carefully determined. The fragments may be directly measured, or the limb may be gently pulled out to length and the distance between the epiphyses measured. The outer rod should be several centimeters shorter than the total length estimated to be needed, to allow some settling after surgery and to maximize proper rod elongation. The outer rod has a detachable T-piece and a like-diameter drill bit with a threaded base. The drill bit can be threaded onto the outer rod in place of the T-piece to facilitate rod insertion during surgery. In the femur, the outer rod is usually placed proximally where the greater fracture stresses tend to occur. In addition, this T-piece can detach from the rod, and this complication is less of a problem if it occurs at the greater trochanter than in the knee.

After a rod of appropriate length and diameter has been selected, the most effective sequence of rod insertion for the femur is as follows (Fig. 31–41). (1) The drill bit is inserted into the proximal end of the outer rod. (2) Commencing from either the distal end of the lowest metaphyseal fragment (if this is close to the epiphysis) or from the intercondylar region of the distal femur, the surgeon drives the outer rod proximally, threading the segments of bone on it as the rod is advanced. (3) When the rod exits the proximal femur at the greater trochanter or base of the femoral neck, the outer rod and drill bit are driven further proximally until they tent the skin. (4) A small incision is made over the rod, the drill bit is removed, the T-piece is threaded in place, and the outer rod is crimped over the threads with a pair of pliers to help prevent the T-piece from disengaging from

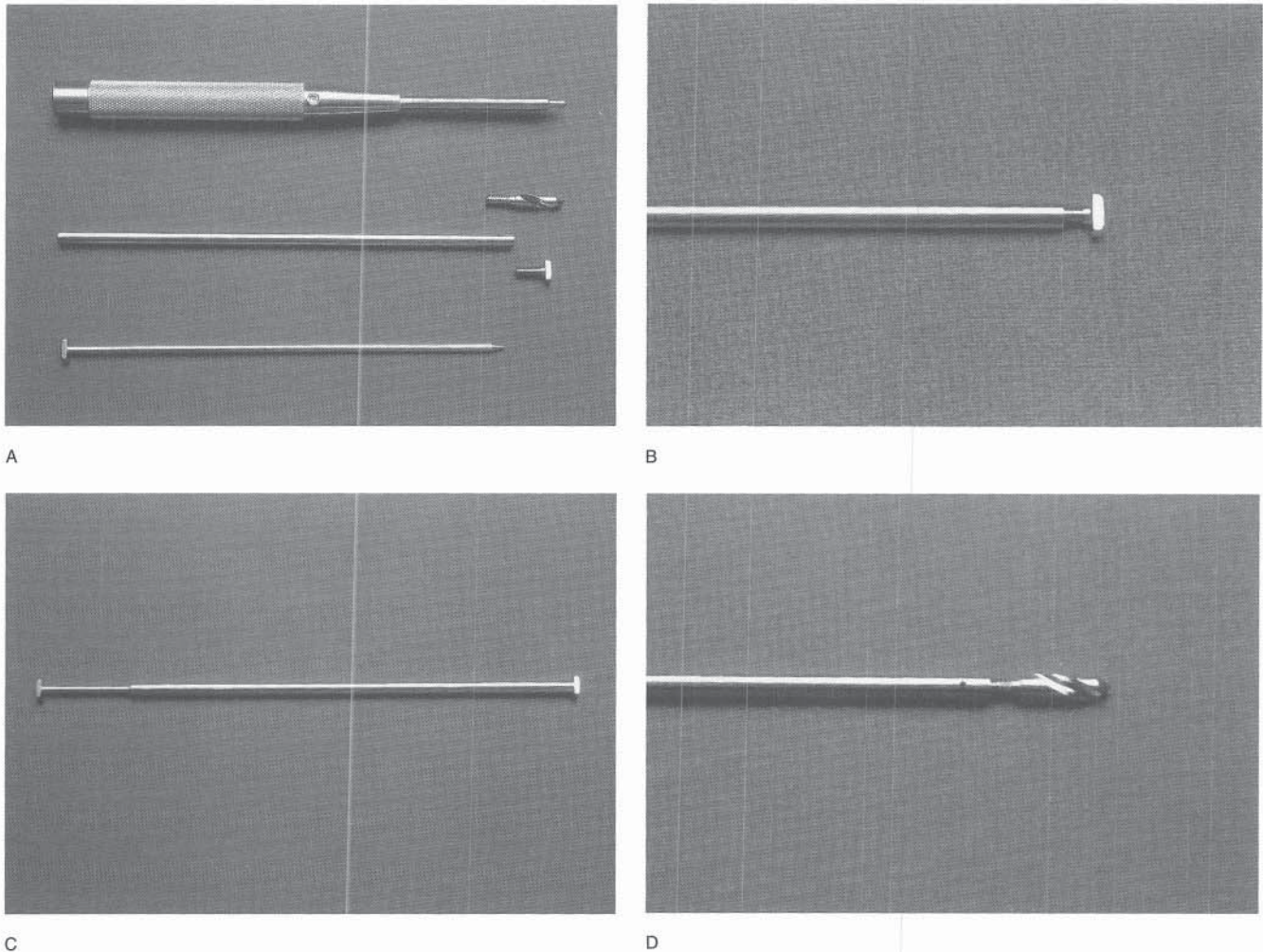


**FIGURE 31-39** Use of a Bailey-Dubow extensible rod in the tibia. **A**, Preoperative lateral radiograph of the tibia of a boy with osteogenesis imperfecta type I with repeated fractures and anterior bowing of the tibial diaphysis. **B**, Postoperative AP view of the tibia. Multiple osteotomies of the tibial diaphysis have been performed, with intramedullary fixation of the tibia with a Bailey-Dubow extensible rod. **C**, Postoperative lateral view demonstrating correction of the anterior bow deformity. **D**, AP view of tibia 2 years later demonstrating extension of the rod. The patient sustained no further fractures of this tibia. **E**, Lateral radiograph demonstrating maintenance of the deformity correction.

the rod. (5) The outer rod with the T-piece engaged is pushed back into the upper femur, where it is countersunk into the femur. The T-piece should be grasped with small pliers or a similar instrument and rotated 90 degrees to help secure the outer rod within the proximal epiphysis. (6) The obturator is then passed through the intercondylar notch into the outer rod under direct vision or fluoroscopic control. Its T-piece, which is solid on the rod, is likewise count-

ersunk under the distal femoral epiphyseal cartilage and rotated 90 degrees.

In the tibia, the sequence of steps is similar. Because the detachable T-piece of the outer rod is intra-articularly located, there is no advantageous position for it, in contradistinction to the femur. Because gaining access to the distal tibial epiphysis can be awkward, it may be a little easier to thread the outer rod from proximal to distal, remove the



**FIGURE 31-40** Bailey-Dubow extensible rod, used for intramedullary fixation of long bone. **A**, The device consists of a hollow outer rod, one end of which is threaded to receive either a like-diameter drill bit or T-piece; a narrower inner rod with a fixed T-piece; and inserters. **B**, The outer rod has a threaded end to accept the T-piece for fixation into the epiphysis. **C**, The inner rod slides into the outer rod and has a fixed T-piece end. **D**, The outer rod may be inserted by using the removable drill bit, which threads into the end of the rod. See Figure 31-41 for a description of the surgical details.

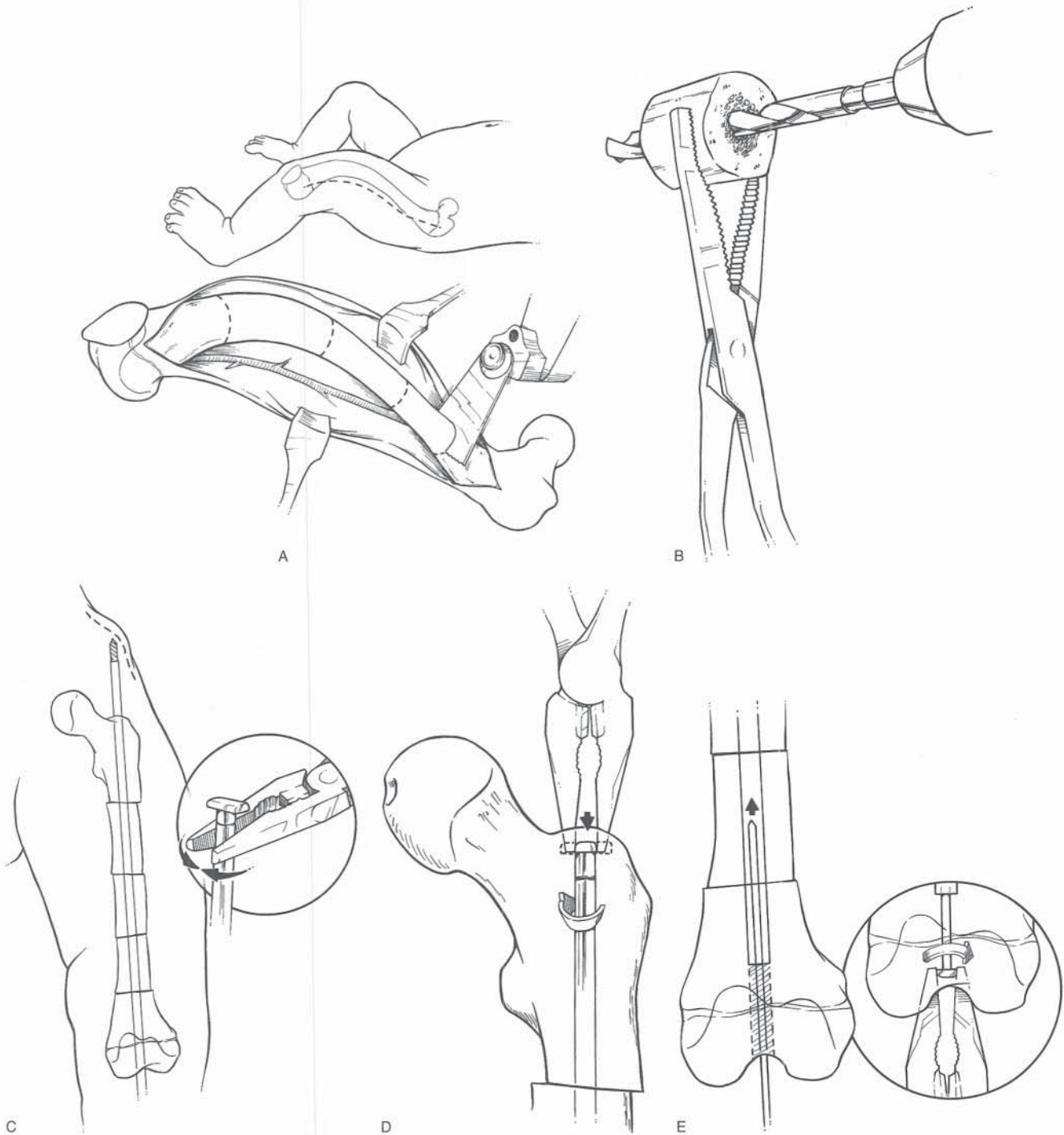
drill bit as it exits the distal tibia into the ankle joint, replace it with the T-piece, and then push the rod proximally until the T-piece can be countersunk in the distal tibial epiphysis. However, authors have described both proximal and distal insertion of the outer rod in the tibia. These rods can also be used in the humerus, although the need to correct deformity here is much less frequent than in the femur and tibia. Furthermore, complications related to intramedullary fixation are more common here than in the lower extremity.<sup>39,71,89,107</sup> When used in the humerus, the outer rod is inserted via the upper humerus, to exit at the greater tuberosity, and the inner obturator rod is inserted through the lateral epicondyle. These rods are not indicated for use in the radius or ulna.

Although most authors have described burying the T-pieces in the epiphysis and rotating them 90 degrees to help keep them in the epiphysis,\* it should be noted that the originators of the device originally described leaving the T-pieces outside the epiphysis.<sup>9,10,151</sup> We agree with the

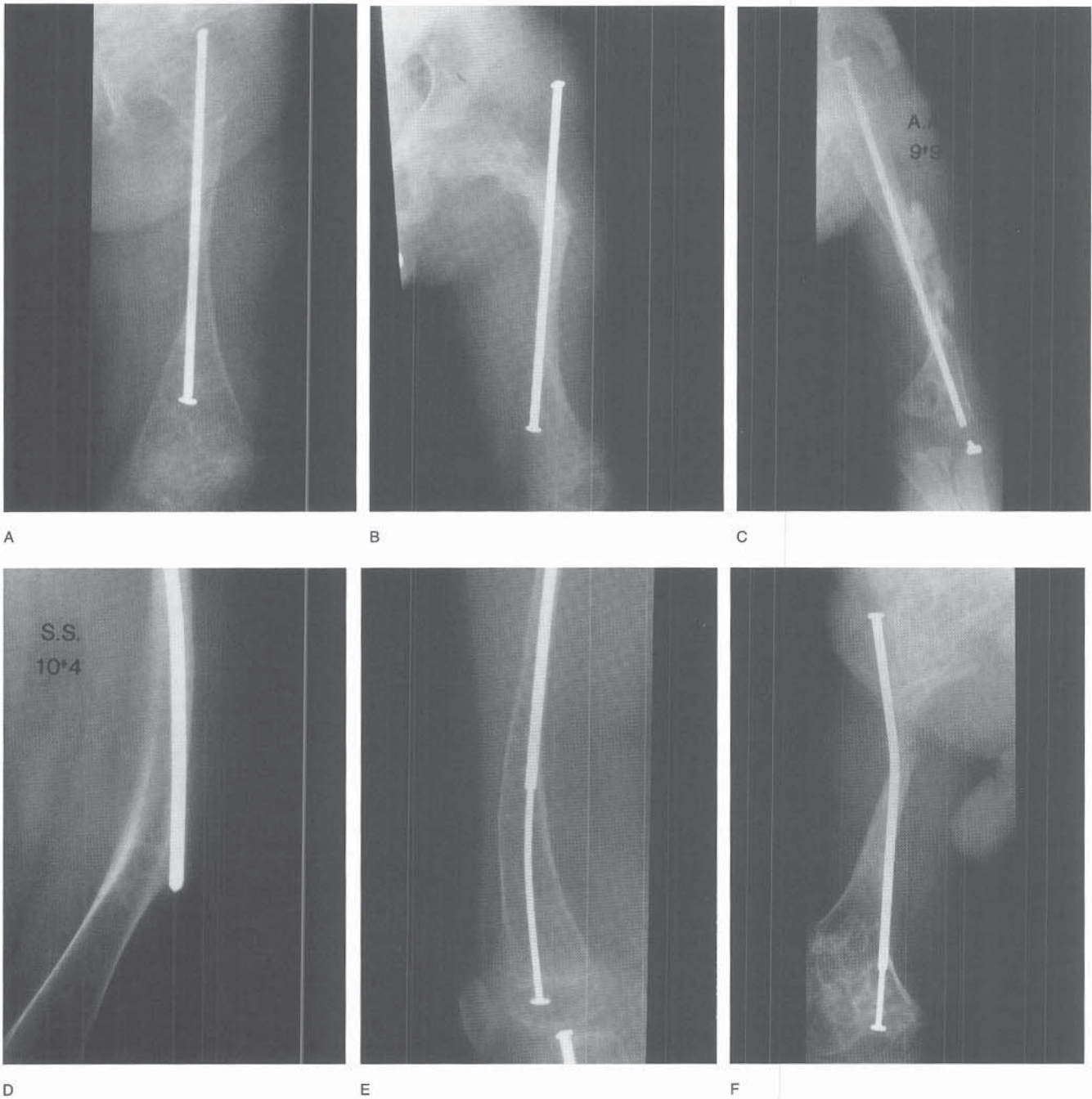
majority of authors on this topic in that we believe that the T-pieces should be buried within the epiphyseal cartilage. Stockley and associates have described a modified version of the original device.<sup>171</sup> The device comes in a broader array of lengths and diameters, the T-pieces are fixed to the end of both rods, and the T-pieces are butterfly shaped so that they can be more easily grasped for rotation during insertion into the epiphysis.<sup>171,185</sup>

Clearly, the insertion of such a rod is more complex than the insertion of fixed devices such as Kirschner wires, Steinmann pins, Williams rods, Rush rods, or other fixed-length rods. Correspondingly, the intraoperative procedure is much more complex and the opportunity for technical problems and rod failure much greater. Complications specific to this device include failure of the rod to elongate, extrusion of the rod into the soft tissues (especially the proximal thigh), disengagement of the T-piece, and bending of the rod with bone fractures at the junction of the outer and inner rods (Fig. 31-42). Other complications of the procedure include infection, nonunion, hypertrophic callus formation, and growth arrest (rarely). These complications

\*See references 58, 65, 70, 89, 97, 106, 128, 171, 185, 191.



**FIGURE 31–41** Surgical technique of extensible rod insertion into the femur. **A**, After subperiosteal exposure of the femur from metaphysis to metaphysis, an appropriate number of osteotomies are made to allow straightening of the bone and fixation on the intramedullary rod. **B**, The individual bone segments are reamed to accept the rod, and the largest-diameter rod is selected based on the reaming. An outer rod of appropriate length is selected either by direct measurement of the fragments or by gently pulling on the limb and measuring from epiphysis to epiphysis. The outer rod should be a few centimeters shorter than this measurement to permit postoperative settling of the fragments and normal telescopic action of the rods. **C**, With the drill bit attached to the proximal end of the selected outer rod, the rod is carefully driven proximally under direct vision or fluoroscopic control. The individual fragments are threaded on the rod as it is advanced. When the rod exits the proximal femur, it is advanced until it tents the skin. The skin is incised at this point, the drill bit is removed, and the T-piece is inserted into the rod. The end of the rod should be crimped over the threaded portion with a pair of pliers before the rod is reinserted, to help prevent disengagement of the T-piece. **D**, The outer rod is pushed back to the level of the proximal femur and into the bone. The T-piece is grasped with a small clamp and rotated 90 degrees under the cortex of the bone. This helps prevent proximal migration of the outer rod and keeps the rod in the proximal portion of the femur. **E**, Under direct vision or fluoroscopic guidance, the inner rod is inserted through the intercondylar drill hole into the outer rod. The T-piece of the inner rod is pushed into the distal femoral epiphysis and similarly rotated 90 degrees with a small clamp. The wounds are then closed and the patient is immobilized in a spica cast.



**FIGURE 31-42** Complications associated with the Bailey-Dubow extensible rod. **A**, Failure of the rod to elongate. This may occur because the inner rod becomes jammed in the outer rod or because of inadequate anchoring of either T-piece in the epiphysis. **B**, Rod migration into the soft tissue. This also occurs after inadequate fixation of the T-piece in the epiphysis. **C**, Disengagement of the outer rod's T-piece. This complication may be avoided by crimping the end of the rod with a pair of pliers before the T-piece is embedded in the epiphysis. **D**, Rod extrusion from the metaphyseal cortex. This complication is more common with fixed-length rods in growing children, as in this example. **E**, Resorption of the diaphysis around the rod. Note also bending of the inner rod. **F**, Fracture around a rod, with bending of the intramedullary rod.

are well documented in a number of publications,\* in which the reported complication rate varies from 7 percent to 100 percent. In addition, several authors have noted that an alarming involution of cortical bone can occur around the rod, with the original bone all but disappearing. Fortunately, no specific clinical problem has been identified with this radiographic finding. On the other hand, when the rods do perform as intended, most publications comparing telescoping rods and fixed-length rods note this advantage when the patient has enough growth remaining to warrant the more complex index procedure. Just what age corresponds to "enough growth remaining" is uncertain, but use of these rods should be strongly considered in children less than 10 years old. Rodriguez and Wickstrom reported their experience with fragmentation and use of the extensible intramedullary rod; in 13 of the 15 long bones operated on, the telescoping rod proved effective.<sup>152</sup> In the experience of Marafioti and Westin, the use of 47 Bailey-Dubow elongating rods increased the average length of time between replacement operations, yielded a lower removal rate, and showed no additional adverse effects.<sup>108</sup> Reoperation was required three and a half times less often with the telescoping rod than with the solid rod. Jerosch and associates evaluated the results of 107 rods placed in the upper and lower extremities of 29 patients.<sup>89</sup> They reported a 68 percent complication rate. The most common complication was proximal rod migration into the gluteal region or the knee. The second most common complication was T-piece loosening. In addition, there was a 5 percent infection rate and two nonunions. Additional complications reported with the extensible rod include failure to elongate as desired and bending of the obturator rod at the junction of the two after fracture. Porat and associates, however, in a 10-year follow-up comparison of 32 Bailey-Dubow rods and 24 Rush rods used in the lower extremities of 20 patients, found that the overall complication rate was 72 percent for the Bailey-Dubow rod and 50 percent for the Rush rod.<sup>139</sup> The authors found that the reoperation rate and time to revision surgery were similar for the two types of rods. Thus, they felt that the results of the Bailey-Dubow rods did not justify the burden of the additional technical challenges their insertion presents to the surgeon. We recommend the procedure, but the operating surgeon must be alert to, and warn families of, the relatively high complication rate.

### SPINAL DEFORMITY AND ITS MANAGEMENT

Involvement of the cervical spine, other than basilar impression, is a relatively uncommon feature of osteogenesis imperfecta.<sup>119,138,154,192</sup> Involvement of the thoracolumbar spine is much more common. Vertebral body fracture has been reported,<sup>62,143</sup> as has spondylolisthesis,<sup>79,144</sup> but by far the most common deformity is scoliosis with or without kyphosis.† The incidence of scoliosis has been reported in 39 percent to 100 percent of patient popula-

tions, according to Ishikawa and associates.<sup>87</sup> The incidence of scoliosis can be related to the severity of bone fragility, being more common in patients with more severe fragility, and also to vertebral body shape and strength. Specifically, both Ishikawa and associates<sup>87</sup> and Hanscom and associates<sup>79</sup> noted that patients with biconcave vertebral bodies and radiographic evidence of osteoporosis were at risk for the development and progression of scoliosis and kyphosis; Ishikawa and associates found that the development of six or more biconcave vertebrae before puberty was a strong risk factor for the development of scoliosis of more than 50 degrees. These radiographic anomalies were more likely to occur in patients with congenita B osteogenesis imperfecta, and these and other authors have found the classifications of Falvo and associates<sup>61</sup> or Shapiro<sup>162</sup> more useful in identifying risk for the development of scoliosis. In general, however, scoliosis is more prevalent in patients with Sillence's type III or IV disease.

Conservative management of scoliosis with orthosis has generally not prevented progression of the deformity, and may be detrimental.<sup>19,20,79,190</sup> External pressure applied on the rib cage in an effort to control the spinal deformity may result in secondary compressive deformity of the rib cage itself. Furthermore, the excessive sweating and heat sensitivity often observed in Sillence's type III patients usually make it impossible for the patient to tolerate a spinal orthosis. Thus, use of a corrective spinal orthosis in the management of spinal deformity in osteogenesis imperfecta is rarely indicated.

Spinal fusion has been recommended for the management of severe (greater than 40 or 50 degrees) progressive deformity in patients with osteogenesis imperfecta.\* The specific problems faced by the treating surgeon in completing this recommendation are manyfold. The patients are typically of the more fragile variety and thus are more prone to fractures and other anesthesia-related complications.<sup>170</sup> Intraoperative bleeding tends to be greater than average, presumably related to bone fragility and the bleeding diathesis noted in osteogenesis imperfecta patients in general. Spinal fragility demands very careful surgical exposure and makes instrumentation very difficult. The iliac crest will often serve as only a meager source of autologous bone graft material. Finally, the patient may not tolerate postoperative external immobilization well, for the same reasons that spinal orthoses for the prevention of progression are not tolerated well. Thus, when spinal stabilization is deemed warranted, the operating team must be prepared to handle the delicate patient carefully, must be prepared for blood transfusion, and must have allograft bone graft or other bone graft substitutes available to supplement whatever autologous bone can be obtained.

Initially, spinal fusion was performed using *in situ* techniques or Harrington instrumentation with methylmethacrylate augmentation of hook sites.† However, stable posterior segmental fixation with Luque sublaminar wires or tapes appears to be ideally suited to the instrumentation management of these difficult cases (Fig. 31–43).<sup>79</sup> It is not clear that even successful instrumentation and fusion will halt

\*See references 29, 32, 49, 57, 65, 70, 71, 89, 97, 106, 108, 115, 128, 139, 150, 151, 171, 185, 191.

†See references 14, 19, 20, 47, 57, 75, 79, 83, 87, 91, 103, 123, 146, 167, 190.

\*See references 19, 20, 57, 75, 79, 123, 146, 190.

†See references 19, 20, 47, 75, 79, 82, 83, 91, 103, 146, 190.

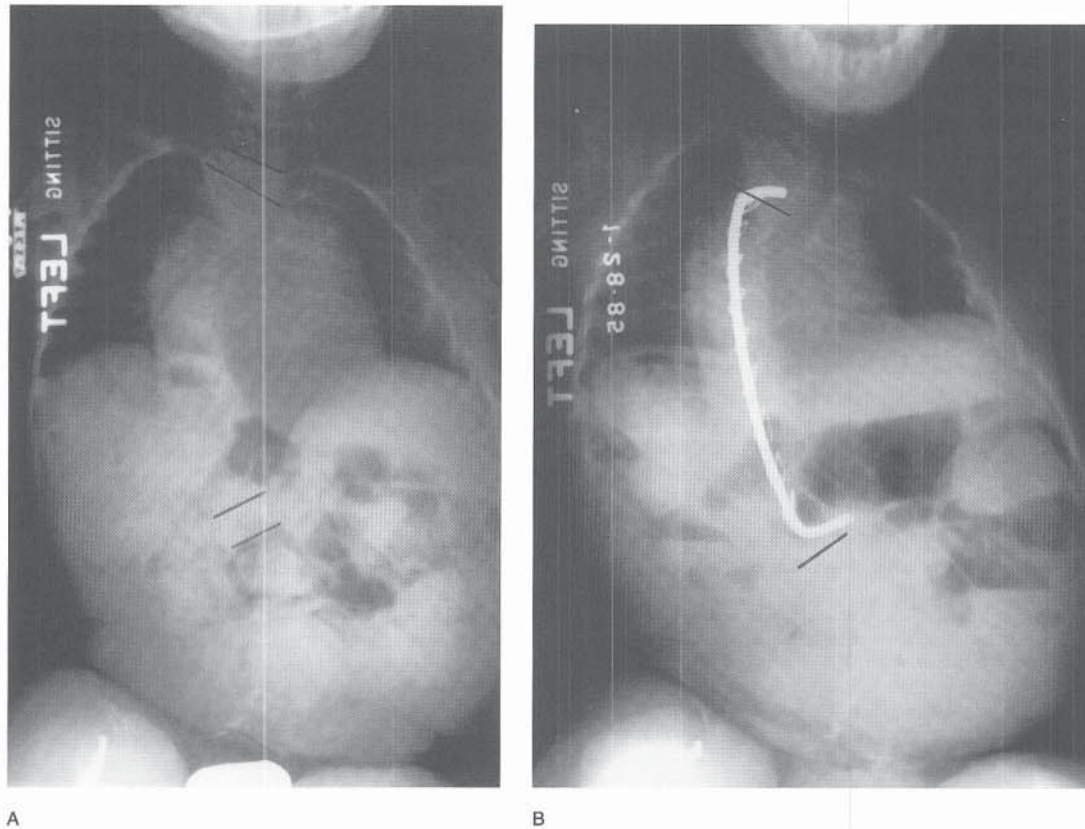


FIGURE 31-43 Scoliosis in osteogenesis imperfecta. **A**, Preoperative radiograph showing the typical deformity in a severely affected patient. **B**, Postoperative radiograph obtained after posterior fusion and instrumentation using the Luque technique. Minimal correction was noted. An allograft was required to supplement the local bone graft.

progression of the spinal deformity.<sup>20,79</sup> However, these patients are not at high risk for pseudarthrosis after posterior fusion alone, and anterior spinal growth is modest after fusion. Thus, although successful anterior spinal fusions have been described,<sup>79</sup> anterior spinal fusion would seem to be rarely required in these patients.

### BASILAR IMPRESSION

Basilar impression is an unusual but well-recognized complicating condition seen in patients with osteogenesis imperfecta.\* Although case reports and reviews of general populations of patients with osteogenesis imperfecta would suggest that this condition is relatively rare, Engelbert and associates found radiographic evidence of basilar impression in 10 of 47 patients with osteogenesis imperfecta.<sup>57</sup> Presumably due to pathologic bone softening, the foramen magnum margins invaginate into the posterior cranial fossa in the affected patient, translocating the upper cervical spine into this depression. This in turn produces direct brain stem compression and, likely, alteration in cerebrospinal fluid flow dynamics, resulting in a wide variety of symptoms. Symptoms can include headaches, facial spasm and numbness, bulbar symptoms (difficulty swallowing and speaking, and respiratory depression), and long-tract signs or weakness in the

upper and lower extremities. Basilar impression was the confirmed or suspected contributory cause of death in six patients in a study of mortality in osteogenesis imperfecta patients by McAllion and Paterson.<sup>114</sup> The condition has been reported in all Silience types except type II. Although basilar impression has been reported in a 3-year-old child,<sup>155</sup> most reported cases have occurred in adults.<sup>64,80,86,95,114,141</sup> More severely affected patients with associated dentinogenesis imperfecta may be more susceptible to the development of basilar impression, and those with ligamentous laxity may be less susceptible, but exceptions to these generalities have been reported.

Diagnosing basilar impression solely on the basis of plain radiographic findings has always been difficult, due to difficulty in identifying radiographic landmarks at the foramen magnum and variation in normal measurements in this area. CT with three-dimensional reconstruction and, even more important, MRI of the upper cervical spine and brain stem greatly simplify the clinician's investigation. These studies should be performed whenever the treating physician's suspicions of this diagnosis are raised based on the patient's complaints or on physical findings on neurologic examination.

Relatively short-term relief of symptoms and neurologic signs has been reported after posterior decompression only.<sup>64,86,95,144,155</sup> However, based on the pathophysiology of the deformity, combined transoral anterior decompression

\*See references 57, 64, 80, 86, 95, 114, 141, 155.

and posterior fusion of the occiput to the lower cervical or thoracic spine, as recommended by Harkey and associates, seems the most appropriate management of this condition.<sup>80</sup>

## REFERENCES

### Osteogenesis Imperfecta

1. Ablin DS: Osteogenesis imperfecta: a review. *Can Assoc Radiol J* 1998;49:110.
2. Aeschlimann MI, Grunt JA, Crigler JF Jr: Effects of sodium fluoride on the clinical course and metabolic balance of an infant with osteogenesis imperfecta congenita. *Metabolism* 1966;15:905.
3. Albright JA: Management overview of osteogenesis imperfecta. *Clin Orthop* 1981;159:80.
4. Albright JA, Grunt JA: Studies of patients with osteogenesis imperfecta. *J Bone Joint Surg* 1971;53-A:1415.
5. Albright JP, Albright JA, Crelin ES: Osteogenesis imperfecta tarda: the morphology of rib biopsies. *Clin Orthop* 1975;108:204.
6. Apley AG: Hyperplastic calus in osteogenesis imperfecta. *J Bone Joint Surg* 1951;33-B:591.
7. Astrom E, Soderhall S: Beneficial effect of bisphosphonate during five years of treatment of severe osteogenesis imperfecta. *Acta Paediatr* 1998;87:64.
8. Augarten A, Laufer J, Szeinberg A, et al: Child abuse, osteogenesis imperfecta and the grey zone between them. *J Med* 1993;24:171.
9. Bailey RW, Dubow HI: Evolution of the concept of an extensible nail accommodating to normal longitudinal bone growth: clinical considerations and implications. *Clin Orthop* 1981;159:157.
10. Bailey RW, Dubow HI: Studies of longitudinal bone growth resulting in an extensible nail. *Surg Forum* 1963;14:455.
11. Baker SL: Hyperplastic callus simulating sarcoma in two cases of fragilitas ossium. *J Pathol Bacteriol* 1946;58:609.
12. Banta JV, Schreiber RR, Kulik WJ: Hyperplastic callus formation in osteogenesis imperfecta simulating osteosarcoma. *J Bone Joint Surg* 1971;53-A:115.
13. Baron R, Gertner JM, Lang R, et al: Increased bone turnover with decreased bone formation by osteoblasts in children with osteogenesis imperfecta tarda. *Pediatr Res* 1983;17:204.
14. Barrack RL, Whitecloud TS III, Skinner HB: Spondylolysis after spinal instrumentation in osteogenesis imperfecta. *South Med J* 1984;77:1453.
15. Barsh GS, David KE, Byers PH: Type I osteogenesis imperfecta: a nonfunctional allele for pro alpha 1 (I) chains of type I procollagen. *Proc Natl Acad Sci USA* 1982;79:3838.
16. Bauze RJ, Smith R, Francis MJ: A new look at osteogenesis imperfecta: a clinical, radiological and biochemical study of forty-two patients. *J Bone Joint Surg* 1975;57-B:2.
17. Beighton P: Familial dentinogenesis imperfecta, blue sclerae, and wormian bones without fractures: another type of osteogenesis imperfecta? *J Med Genet* 1981;18:124.
18. Bembi B, Parma A, Bottega M, et al: Intravenous pamidronate treatment in osteogenesis imperfecta. *J Pediatr* 1997;131:622.
19. Benson DR, Donaldson DH, Millar EA: The spine in osteogenesis imperfecta. *J Bone Joint Surg* 1978;60-A:925.
20. Benson DR, Newman DC: The spine and surgical treatment in osteogenesis imperfecta. *Clin Orthop* 1981;159:147.
21. Bergman G, Engfeldt B: Studies on mineralized dental tissues. IV. Biophysical studies in osteogenesis imperfecta. *Acta Pathol Microbiol Scand* 1954;35:537.
22. Bilginturan N, Ozsoylu S, Yordam N: Further experiences with sodium fluoride treatment in osteogenesis imperfecta. *Turk J Pediatr* 1982;24:151.
23. Binder H, Conway A, Gerber LH: Rehabilitation approaches to children with osteogenesis imperfecta: a ten-year experience. *Arch Phys Med Rehabil* 1993;74:386.
24. Binder H, Conway A, Hason S, et al: Comprehensive rehabilitation of the child with osteogenesis imperfecta. *Am J Med Genet* 1993;45:265.
25. Binder H, Hawks L, Graybill G, et al: Osteogenesis imperfecta: rehabilitation approach with infants and young children. *Arch Phys Med Rehabil* 1984;65:537.
26. Bleck EE: Nonoperative treatment of osteogenesis imperfecta: orthotic and mobility management. *Clin Orthop* 1981;159:111.
27. Bossingham DH, Strange TV, Nicholls PJ: Splints in severe osteogenesis imperfecta. *BMJ* 1978;1:620.
28. Brown BS: The prenatal ultrasonographic diagnosis of osteogenesis imperfecta lethalis. *J Can Assoc Radiol* 1984;35:63.
29. Brunelli PC, Frediani P: Surgical treatment of the deformities of the long bones in severe osteogenesis imperfecta. *Ann NY Acad Sci* 1988;543:170.
30. Bullough PG, Davidson D: The morphology of the growth plate in osteogenesis imperfecta. *Clin Orthop* 1976;116:259.
31. Bullough PG, Davidson DD, Lorenzo JC: The morbid anatomy of the skeleton in osteogenesis imperfecta. *Clin Orthop* 1981;159:42.
32. Burke TE, Crerand SJ, Dowling F: Hypertrophic callus formation leading to high-output cardiac failure in a patient with osteogenesis imperfecta. *J Pediatr Orthop* 1988;8:605.
33. Byers PH, Wallis GA, Willing MC: Osteogenesis imperfecta: translation of mutation to phenotype. *J Med Genet* 1991;28:433.
34. Cassis N, Gledhill RB, Dubow H: Osteogenesis imperfecta: Its sociological and surgical implications, with a preliminary report on the use of a telescoping intramedullary nail. *J Bone Joint Surg* 1975;57-B:533.
35. Castells S, Inamdar S, Baker RK, et al: Effects of porcine calcitonin in osteogenesis imperfecta tarda. *J Pediatr* 1972;80:757.
36. Cattell HS, Clayton B: Failure of anabolic steroids in the therapy of osteogenesis imperfecta: clinical, metabolic, and biochemical study. *J Bone Joint Surg* 1968;50-A:123.
37. Chan CC, Green WR, de la Cruz ZC, et al: Ocular findings in osteogenesis imperfecta congenita. *Arch Ophthalmol* 1982;100:1458.
38. Cole DE, Cohen MM Jr: Osteogenesis imperfecta: an update [editorial]. *J Pediatr* 1991;119:73.
39. Cole WG: Early surgical management of severe forms of osteogenesis imperfecta. *Am J Med Genet* 1993;45:270.
40. Cole WG: Etiology and pathogenesis of heritable connective tissue diseases. *J Pediatr Orthop* 1993;13:392.
41. Cole WG: The Nicholas Andry Award—1996. The molecular pathology of osteogenesis imperfecta. *Clin Orthop* 1997;343:235.
42. Cole WG: Orthopaedic treatment of osteogenesis imperfecta. *Ann NY Acad Sci* 1988;543:157.
43. Cole WG, Chan D, Chow CW, et al: Disrupted growth plates and progressive deformities in osteogenesis imperfecta as a result of the substitution of glycine 585 by valine in the alpha 2 (I) chain of type I collagen. *J Med Genet* 1996;33:968.
44. Cole WG, Dalgleish R: Perinatal lethal osteogenesis imperfecta. *J Med Genet* 1995;32:284.
45. Cole WG, Jaenisch R, Bateman JF: New insights into the molecular pathology of osteogenesis imperfecta. *Q J Med* 1989;70:1.
46. Cremin B, Goodman H, Spranger J, et al: Wormian bones in osteogenesis imperfecta and other disorders. *Skeletal Radiol* 1982;8:35.
47. Cristofaro RL, Hoek KJ, Bonnett CA, et al: Operative treatment of spine deformity in osteogenesis imperfecta. *Clin Orthop* 1979;139:40.
48. Cropp GJA, Myers DN: Physiological evidence of hypermetabolism in osteogenesis imperfecta. *Pediatrics* 1972;49:375.
49. Dal Monte A, Manes E, Capanna R, et al: Osteogenesis imperfecta: results obtained with the Sofield method of surgical treatment. *Ital J Orthop Traumatol* 1982;8:43.
50. Daly K, Wisbeach A, Sanpera I Jr, et al: The prognosis for walking in osteogenesis imperfecta. *J Bone Joint Surg* 1996;78-B:477.
51. Dent CM, Graham GP: Osteogenesis imperfecta and Achilles tendon rupture. *Injury* 1991;22:239.
52. Dent JA, Paterson CR: Fractures in early childhood: osteogenesis imperfecta or child abuse? *J Pediatr Orthop* 1991;11:184.
53. Di Cesare PE, Sew-Hoy A, Krom W: Bilateral isolated olecranon fractures in an infant as presentation of osteogenesis imperfecta. *Orthopedics* 1992;15:741.
54. Doty SB, Mathews RS: Electron microscopic and histochemical investigation of osteogenesis imperfecta tarda. *Clin Orthop* 1971;80:191.
55. du Toit SN, Weiss C: Congenital dislocation of the hip associated with osteogenesis imperfecta in male siblings. *Bull Hosp Jt Dis* 1969;30:164.
56. Edwards MJ, Graham JM Jr: Studies of type I collagen in osteogenesis imperfecta. *J Pediatr* 1990;117:67.
57. Engelbert RH, Gerver WJ, Breslau-Siderius LJ, et al: Spinal complications in osteogenesis imperfecta: 47 patients 1–16 years of age. *Acta Orthop Scand* 1998;69:283.
58. Engelbert RH, Helders PJ, Keessen W, et al: Intramedullary rodding in type III osteogenesis imperfecta: effects on neuromotor development in 10 children. *Acta Orthop Scand* 1995;66:361.
59. Engfeldt B, Hjerpe A, Mengarelli S, et al: Morphological and biochemical analysis of biopsy specimens in disorders of skeletal development. *Acta Paediatr Scand* 1982;71:353.



60. Fairbank HAT: Osteogenesis imperfecta and osteogenesis imperfecta cystica. *J Bone Joint Surg* 1948;30-B:164.
61. Falvo KA, Root L, Bullough PG: Osteogenesis imperfecta: clinical evaluation and management. *J Bone Joint Surg* 1974;56-A:783.
62. Ferrera PC, Hayes ST, Triner WR: Spinal cord concussion in previously undiagnosed osteogenesis imperfecta. *Am J Emerg Med* 1995;13:424.
63. Fontanazza C, Razzano M, Mastromarino R: New outlooks in the treatment of osteogenesis imperfecta: an unusual case successfully treated by the Ilizarov method. *Ital J Orthop Traumatol* 1987;13:67.
64. Frank E, Berger T, Tew JM Jr: Basilar impression and platybasia in osteogenesis imperfecta tarda. *Surg Neurol* 1982;17:116.
65. Frediani P, Brunelli PC: Corrective femoral osteotomy and telescopic nailing in osteogenesis imperfecta. *Ital J Orthop Traumatol* 1989;15:473.
66. Frost RB, Middleton RW, Hillier LG: A stereotaxic device for the closed exchange of intramedullary rods, using image-intensified X-rays, in children with osteogenesis imperfecta. *Eng Med* 1986;15:131.
67. Fujiwara I, Ogawa E, Igarashi Y, et al: Intravenous pamidronate treatment in osteogenesis imperfecta [letter]. *Eur J Pediatr* 1998;157:261.
68. Furey JG, McNamee DC: Air splints for long-term management of osteogenesis imperfecta. *J Bone Joint Surg* 1973;55-A:645.
69. Gamble JG, Rinsky LA, Strudwick J, et al: Non-union of fractures in children who have osteogenesis imperfecta. *J Bone Joint Surg* 1988;70-A:439.
70. Gamble JG, Strudwick WJ, Rinsky LA, et al: Complications of intramedullary rods in osteogenesis imperfecta: Bailey-Dubow rods versus nonelongating rods. *J Pediatr Orthop* 1988;8:645.
71. Gargan MF, Wisbeach A, Fixsen JA: Humeral rodding in osteogenesis imperfecta [see comments]. *J Pediatr Orthop* 1996;16:719.
72. Gerber LH, Binder H, Berry R, et al: Effects of withdrawal of bracing in matched pairs of children with osteogenesis imperfecta. *Arch Phys Med Rehabil* 1998;79:46.
73. Gerber LH, Binder H, Weintrob J, et al: Rehabilitation of children and infants with osteogenesis imperfecta: a program for ambulation. *Clin Orthop* 1990;251:254.
74. Gertner JM, Root L: Osteogenesis imperfecta. *Orthop Clin North Am* 1990;21:151.
75. Gitelis S, Whiffen J, De Wald RL: The treatment of severe scoliosis in osteogenesis imperfecta: case report. *Clin Orthop* 1983;175:56.
76. Glorieux FH, Bishop NJ, Plotkin H, et al: Cyclic administration of pamidronate in children with severe osteogenesis imperfecta [see comments]. *N Engl J Med* 1998;339:947.
77. Goldman AB, Davidson D, Pavlov H, et al: "Popcorn" calcifications: a prognostic sign in osteogenesis imperfecta. *Radiology* 1980;136:351.
78. Hall JG, Rohrt T: The stapes in osteogenesis imperfecta. *Acta Otolaryngol (Stockh)* 1968;65:345.
79. Hanscom DA, Winter RB, Lutter L, et al: Osteogenesis imperfecta: radiographic classification, natural history, and treatment of spinal deformities. *J Bone Joint Surg* 1992;74-A:598.
80. Harkey HL, Crookard HA, Stevens JM, et al: The operative management of basilar impression in osteogenesis imperfecta. *Neurosurgery* 1990;27:782.
81. Hensinger RN: Gastrointestinal problems and osteogenesis imperfecta [letter]. *J Bone Joint Surg* 1996;78-A:1785.
82. Herron LD, Dawson EG: Methylmethacrylate as an adjunct in spinal instrumentation. *J Bone Joint Surg* 1977;59-A:866.
83. Hoek KJ: Scoliosis in osteogenesis imperfecta. *J Bone Joint Surg* 1975;57-A:136.
84. Horwitz EM, Prockop DJ, Fitzpatrick LA, et al: Transplantability and therapeutic effects of bone marrow-derived mesenchymal cells in children with osteogenesis imperfecta. *Nat Med* 1999;5:309.
85. Huaux JP, Lokietek W: Is APD a promising drug in the treatment of severe osteogenesis imperfecta? *J Pediatr Orthop* 1988;8:71.
86. Hurwitz LJ, McSwiney RR: Basilar impression and osteogenesis imperfecta in a family. *Brain* 1960;83:138.
87. Ishikawa S, Kumar SJ, Takahashi HE, et al: Vertebral body shape as a predictor of spinal deformity in osteogenesis imperfecta. *J Bone Joint Surg* 1996;78-A:212.
88. Jacobsen FS: Aneurysmal bone cyst in a patient with osteogenesis imperfecta. *J Pediatr Orthop* 1996;6:225.
89. Jerosch J, Mazzotti I, Tomasevic M: Complications after treatment of patients with osteogenesis imperfecta with a Bailey-Dubow rod. *Arch Orthop Trauma Surg* 1998;117:240.
90. Jewell FC, Lofstrom JE: Osteogenic sarcoma occurring in fragilitas ossium. *Radiology* 1940;34:741.
91. King JD, Bobechko WP: Osteogenesis imperfecta: an orthopaedic description and surgical review. *J Bone Joint Surg* 1971;53-B:72.
92. Klenerman L, Ockenden BG, Townsend AC: Osteosarcoma occurring in osteogenesis imperfecta: report of two cases. *J Bone Joint Surg* 1967;49-B:314.
93. Knight DJ, Bennet GC: Nonaccidental injury in osteogenesis imperfecta: a case report. *J Pediatr Orthop* 1990;10:542.
94. Kocher MS, Shapiro F: Osteogenesis imperfecta. *J Am Acad Orthop Surg* 1998;6:225.
95. Kurimoto M, Ohara S, Takaku A: Basilar impression in osteogenesis imperfecta tarda: case report. *J Neurosurg* 1991;74:136.
96. Lammens J, Mukherjee A, Van Eygen P, et al: Forearm realignment with elbow reconstruction using the Ilizarov fixator: a case report. *J Bone Joint Surg* 1991;73-B:412.
97. Lang-Stevenson AI, Sharrard WJ: Intramedullary rodding with Bailey-Dubow extensible rods in osteogenesis imperfecta: an interim report of results and complications. *J Bone Joint Surg* 1984;66-B:227.
98. Lasson U, Harms D, Wiedemann HR: Osteogenic sarcoma complicating osteogenesis imperfecta tarda. *Eur J Pediatr* 1978;129:215.
99. Laurent LE: Hyperplastic callus formation in osteogenesis imperfecta: report of a case simulating sarcoma. *Acta Orthop Scand* 1967;38:280.
100. Letts M, Monson R, Weber K: The prevention of recurrent fractures of the lower extremities in severe osteogenesis imperfecta using vacuum pants: a preliminary report in four patients. *J Pediatr Orthop* 1988;8:454.
101. Levin LS: The dentition in the osteogenesis imperfecta syndromes. *Clin Orthop* 1981;159:64.
102. Libman RH: Anesthetic considerations for the patient with osteogenesis imperfecta. *Clin Orthop* 1981;159:123.
103. Livesley PJ, Webb PJ: Spinal fusion in situ in osteogenesis imperfecta. *Int Orthop* 1996;20:43.
104. Lobstein JFGCM: *Lehrbuch der pathologischen Anatomie*, vol 2, p 179. Stuttgart, 1835.
105. Looser E: Kenntnis der Osteogenesis imperfecta congenita und tarda (sogenannte idiopathische Osteopsathyrosis). *Mitt Grenzgebiet Med Cir* 1906;15:161.
106. Luhmann SJ, Sheridan JJ, Capelli AM, et al: Management of lower-extremity deformities in osteogenesis imperfecta with extensible intramedullary rod technique: a 20-year experience. *J Pediatr Orthop* 1998;18:88.
107. Marafioti RL, Westin GW: Elongating intramedullary rods in the treatment of osteogenesis imperfecta. *J Bone Joint Surg* 1977;59-A:467.
108. Marafioti RL, Westin GW: Twenty years experience with multiple osteotomies and intramedullary fixation in osteogenesis imperfecta (including the Bailey expandable rod) at the Shriners Hospital, Los Angeles, California. *J Bone Joint Surg* 1975;57-A:136.
109. Marini JC: Osteogenesis imperfecta: comprehensive management. *Adv Pediatr* 1988;35:391.
110. Marini JC: Osteogenesis imperfecta: managing brittle bones [editorial]. *N Engl J Med* 1998;339:986.
111. Maroteaux P, Cohen-Solal L, Bonaventure J: Clinical and genetical heterogeneity of osteogenesis imperfecta. *Ann NY Acad Sci* 1988;543:16.
112. Massey T, Garst J: Compartment syndrome of the thigh with osteogenesis imperfecta: a case report. *Clin Orthop* 1991;267:202.
113. Match RM, Corrylos EV: Bilateral avulsion fracture of the triceps tendon insertion from skiing with osteogenesis imperfecta tarda: a case report. *Am J Sports Med* 1983;11:99.
114. McAllion SJ, Paterson CR: Causes of death in osteogenesis imperfecta. *J Clin Pathol* 1996;49:627.
115. McCall RE, Bax JA: Hyperplastic callus formation in osteogenesis imperfecta following intramedullary rodding. *J Pediatr Orthop* 1984;4:361.
116. McCarthy EF, Earnest K, Rossiter K, et al: Bone histomorphometry in adults with type IA osteogenesis imperfecta. *Clin Orthop* 1997;336:254.
117. McHale KA, Tenuta JJ, Tosi LL, et al: Percutaneous intramedullary fixation of long bone deformity in severe osteogenesis imperfecta. *Clin Orthop* 1994;305:242.
118. Messinger AL, Teal F: Intramedullary nailing in correction of deformity in osteogenesis imperfecta. *Clin Orthop* 1956;5:221.
119. Meyer S, Villarreal M, Ziv I: A three-level fracture of the axis in a patient with osteogenesis imperfecta: a case report. *Spine* 1986;11:505.

120. Middleton RW: Closed intramedullary rodding for osteogenesis imperfecta. *J Bone Joint Surg* 1984;66-B:652.
121. Middleton RW, Frost RB: Percutaneous intramedullary rod interchange in osteogenesis imperfecta. *J Bone Joint Surg* 1987;69-B:429.
122. Minch CM, Kruse RW: Osteogenesis imperfecta: a review of basic science and diagnosis. *Orthopedics* 1998;21:558.
123. Moorefield WG Jr, Miller GR: Aftermath of osteogenesis imperfecta: the disease in adulthood. *J Bone Joint Surg* 1980;62-A:113.
124. Morel G, Houghton GR: Pneumatic trouser splints in the treatment of severe osteogenesis imperfecta. *Acta Orthop Scand* 1982;53:547.
125. Moriwake T, Seino Y: Recent progress in diagnosis and treatment of osteogenesis imperfecta. *Acta Paediatr Jpn* 1997;39:521.
126. Mudgal CS: Olecranon fractures in osteogenesis imperfecta: a case report. *Acta Orthop Belg* 1992;58:453.
127. Murray D, Young BH: Osteogenesis imperfecta treated by fixation with intramedullary rod. *South Med J* 1960;53:1142.
128. Nicholas RW, James P: Telescoping intramedullary stabilization of the lower extremities for severe osteogenesis imperfecta. *J Pediatr Orthop* 1990;10:219.
129. Nicholls AC, Oliver J, Renouf DV, et al: Substitution of cysteine for glycine at residue 415 of one allele of the alpha 1(I) chain of type I procollagen in type III/IV osteogenesis imperfecta. *J Med Genet* 1991;28:757.
130. Niemann KM: Surgical treatment of the tibia in osteogenesis imperfecta. *Clin Orthop* 1981;159:134.
131. Nishi Y, Hamamoto K, Kajiyama M, et al: Effect of long-term calcitonin therapy by injection and nasal spray on the incidence of fractures in osteogenesis imperfecta. *J Pediatr* 1992;121:477.
132. Nogami H, Ono Y, Katoh R, et al: Microvascular and cellular defects of the periosteum of osteogenesis imperfecta. *Clin Orthop* 1993;292:358.
133. Ogilvie-Harris DJ, Khazim R: Tendon and ligament injuries in adults with osteogenesis imperfecta. *J Bone Joint Surg* 1995;77-B:155.
134. Paterson CR, Beal RJ, Dent JA: Osteogenesis imperfecta: fractures of the femur when testing for congenital dislocation of the hip [see comments]. *BMJ* 1992;305:464.
135. Paterson CR, Burns J, McAllion SJ: Osteogenesis imperfecta: the distinction from child abuse and the recognition of a variant form [see comments]. *Am J Med Genet* 1993;45:187.
136. Paterson CR, McAllion SJ: Osteogenesis imperfecta in the differential diagnosis of child abuse. *BMJ* 1989;299:1451.
137. Paterson CR, Ogston SA, Henry RM: Life expectancy in osteogenesis imperfecta. *BMJ* 1996;312:351.
138. Pauli RM, Gilbert EF: Upper cervical cord compression as cause of death in osteogenesis imperfecta type II. *J Pediatr* 1986;108:579.
139. Porat S, Heller E, Seidman DS, et al: Functional results of operation in osteogenesis imperfecta: elongating and nonelongating rods. *J Pediatr Orthop* 1991;11:200.
140. Porsborg P, Astrup G, Bendixen D, et al: Osteogenesis imperfecta and malignant hyperthermia: is there a relationship? *Anaesthesia* 1996;51:863.
141. Pozo JL, Crockard HA, Ransford AO: Basilar impression in osteogenesis imperfecta: a report of three cases in one family. *J Bone Joint Surg* 1984;66-B:233.
142. Rampton AJ, Kelly DA, Shanahan EC, et al: Occurrence of malignant hyperpyrexia in a patient with osteogenesis imperfecta. *Br J Anaesth* 1984;56:1443.
143. Rao S, Patel A, Schildhauer T: Osteogenesis imperfecta as a differential diagnosis of pathologic burst fractures of the spine: a case report. *Clin Orthop* 1993;289:113.
144. Rask MR: Spondylolisthesis resulting from osteogenesis imperfecta: report of a case. *Clin Orthop* 1979;139:164.
145. Reid BS, Hubbard JD: Osteosarcoma arising in osteogenesis imperfecta. *Pediatr Radiol* 1979;8:110.
146. Renshaw TS, Cook RS, Albright JA: Scoliosis in osteogenesis imperfecta. *Clin Orthop* 1979;145:163.
147. Ring D, Jupiter JB, Labropoulos PK, et al: Treatment of deformity of the lower limb in adults who have osteogenesis imperfecta. *J Bone Joint Surg* 1996;78-A:220.
148. Roberts JB: Bilateral hyperplastic callus formation in osteogenesis imperfecta. *J Bone Joint Surg* 1976;58-A:1164.
149. Robichon J, Germain JP: Pathogenesis of osteogenesis imperfecta. *Can Med Assoc J* 1968;99:975.
150. Rodriguez RP: Report of multiple osteotomies and intramedullary fixation by a extensible intramedullary device in children with osteogenesis imperfecta. *Clin Orthop* 1976;116:261.
151. Rodriguez RP, Bailey RW: Internal fixation of the femur in patients with osteogenesis imperfecta. *Clin Orthop* 1981;159:126.
152. Rodriguez RP Jr, Wickstrom J: Osteogenesis imperfecta: a preliminary report on resurfacing of long bones with intramedullary fixation by an extensible intramedullary device. *South Med J* 1971;64:169.
153. Root L: Upper limb surgery in osteogenesis imperfecta. *Clin Orthop* 1981;159:141.
154. Rush GA, Burke SW: Hangman's fracture in a patient with osteogenesis imperfecta: case report. *J Bone Joint Surg* 1984;66-A:778.
155. Rush PJ, Berbrayer D, Reilly BJ: Basilar impression and osteogenesis imperfecta in a three-year-old girl: CT and MRI. *Pediatr Radiol* 1989;19:142.
156. Rutkowski R, Resnick P, McMaster JH: Osteosarcoma occurring in osteogenesis imperfecta: a case report. *J Bone Joint Surg* 1979;61-A:606.
157. Ryan CA, Al-Ghamdi AS, Gayle M, et al: Osteogenesis imperfecta and hyperthermia. *Anesth Analg* 1989;68:811.
158. Ryoppy S, Alberty A, Kaitila I: Early semiclosed intramedullary stabilization in osteogenesis imperfecta. *J Pediatr Orthop* 1987;7:139.
159. Sadat-Ali M, Sankaran-Kutty M, Adu-Gyamfi Y: Metabolic acidosis in osteogenesis imperfecta. *Eur J Pediatr* 1986;145:582.
160. Sanguinetti C, Greco F, De Palma L, et al: Morphological changes in growth-plate cartilage in osteogenesis imperfecta. *J Bone Joint Surg* 1990;72-B:475.
161. Seedorff KS: Osteogenesis Imperfecta: A Study of Clinical Features and Heredity Based on 55 Danish Families Comprising 180 Affected Persons. Copenhagen, Munksgaard, 1949.
162. Shapiro F: Consequences of an osteogenesis imperfecta diagnosis for survival and ambulation. *J Pediatr Orthop* 1985;5:456.
163. Shea JJ, Postma DS: Findings and long-term surgical results in the hearing loss of osteogenesis imperfecta. *Arch Otolaryngol* 1982;108:467.
164. Sijbrandij S: Percutaneous nailing in the management of osteogenesis imperfecta. *Int Orthop* 1990;14:195.
165. Sillence D: Osteogenesis imperfecta: an expanding panorama of variants. *Clin Orthop* 1981;159:11.
166. Sillence DO, Danks DM: The differentiation of genetically distinct varieties of osteogenesis imperfecta in the newborn period. *Clin Res* 1978;26:178.
167. Sillence DO, Senn A, Danks DM: Genetic heterogeneity in osteogenesis imperfecta. *J Med Genet* 1979;16:101.
168. Smith R: Osteogenesis imperfecta: where next? [editorial]. *J Bone Joint Surg* 1997;79-B:177.
169. Sofield HA, Millar EA: Fragmentation, realignment, and intramedullary rod fixation of deformities of the long bones of children: a ten-year appraisal. *J Bone Joint Surg* 1959;41-A:1371.
170. Sperry K: Fatal intraoperative hemorrhage during spinal fusion surgery for osteogenesis imperfecta. *Am J Forensic Med Pathol* 1989;10:54.
171. Stockley I, Bell MJ, Sharrard WJ: The role of expanding intramedullary rods in osteogenesis imperfecta. *J Bone Joint Surg* 1989;71-B:422.
172. Stoltz MR, Dietrich SL, Marshall GJ: Osteogenesis imperfecta [Perspectives]. *Clin Orthop* 1989;242:120.
173. Stott NS, Zions LE: Displaced fractures of the apophysis of the olecranon in children who have osteogenesis imperfecta. *J Bone Joint Surg* 1993;75-A:1026.
174. Strach EH: Hyperplastic callus formation in osteogenesis imperfecta: report of a case and a review of the literature. *J Bone Joint Surg* 1953;35-B:417.
175. Superti-Furga A, Pistone F, Romano C, et al: Clinical variability of osteogenesis imperfecta linked to COL1A2 and associated with a structural defect in the type I collagen molecule. *J Med Genet* 1989;26:358.
176. Taitz LS: Child abuse and osteogenesis imperfecta. *BMJ* 1987;295:1082.
177. Tiley F, Albright JA: Osteogenesis imperfecta: treatment by multiple osteotomy and intramedullary rod insertion. Report on thirteen patients. *J Bone Joint Surg* 1973;55-A:701.
178. Tongsong T, Wanapirak C, Siringkul S: Prenatal diagnosis of osteogenesis imperfecta type II. *Int J Gynaecol Obstet* 1998;61:33.
179. Tosi LL: Osteogenesis imperfecta. *Curr Opin Pediatr* 1997;9:94.
180. Trelstad RL, Rubin D, Gross J: Osteogenesis imperfecta congenita: evidence for a generalized molecular disorder of collagen. *Lab Invest* 1977;36:501.
181. Tsipouras P: Osteogenesis imperfecta. In Beighton P (ed): *McKusick's Hereditary Disorders of Connective Tissue*, p 281. St. Louis, Mosby, 1997.

182. Vandemark WE, Page MA: Massive hyperplasia of bone following fractures of osteogenesis imperfecta: report of two cases. *J Bone Joint Surg* 1948;30-A:1015.
183. Vrolik W: *Tabulae ad Illustrandam Embryogenesis Hominis et Mammalium tam Naturalem quam Abnormem*. Amstelodami, 1849.
184. Wenger DR, Abrams RA, Yaru N, et al: Obstruction of the colon due to protrusio acetabuli in osteogenesis imperfecta: treatment by pelvic osteotomy. Report of a case. *J Bone Joint Surg* 1988;70-A:1103.
185. Wilkinson JM, Scott BW, Clarke AM, et al: Surgical stabilisation of the lower limb in osteogenesis imperfecta using the Sheffield telescopic intramedullary rod system. *J Bone Joint Surg* 1998;80-B:999.
186. Williams PF: Fragmentation and rodding in osteogenesis imperfecta. *J Bone Joint Surg* 1965;47-B:23.
187. Williams PF, Cole WH, Bailey RW, et al: Current aspects of the surgical treatment of osteogenesis imperfecta. *Clin Orthop* 1973;96:288.
188. Wynne-Davies R, Gormley J: Clinical and genetic patterns in osteogenesis imperfecta. *Clin Orthop* 1981;159:26.
189. Yeoman PM: Multiple osteotomies and intramedullary fixation of the long bones of osteogenesis imperfecta. *Proc R Soc Med* 1960;53:946.
190. Yong-Hing K, MacEwen GD: Scoliosis associated with osteogenesis imperfecta. *J Bone Joint Surg* 1982;64-B:36.
191. Zions LE, Ebramzadeh E, Stott NS: Complications in the use of the Bailey-Dubow extensible nail. *Clin Orthop* 1998;348:186.
192. Ziv I, Rang M, Hoffman HJ: Paraplegia in osteogenesis imperfecta: a case report. *J Bone Joint Surg* 1983;65-B:184.