

Orthopaedic-Related Syndromes

- Marfan's Syndrome, 1585
- Hereditary Progressive Arthropathopathy (Stickler's Syndrome), 1593
- Congenital Contractural Arachnodactyly (Beals' Syndrome), 1594
- Homocystinuria, 1596
- Nail-Patella Syndrome (Hereditary Onychoosteodysplasia), 1599
- Larsen's Syndrome, 1602
- Apert's Syndrome, 1615
- Down Syndrome (Trisomy 21), 1616
- Neurofibromatosis, 1624
- Fibrodysplasia Ossificans Progressiva, 1632
- Ehlers-Danlos Syndrome, 1639
- Gaucher's Disease, 1642
- Arthrogyrosis (Arthrogyrosis Multiplex Congenita), 1647
- Cranioacropotarsal Dysplasia (Freeman-Sheldon or "Whistling Face" Syndrome), 1662
- Cornelia de Lange's Syndrome, 1663
- Rubinstein-Taybi Syndrome, 1665
- Otopalatodigital Syndrome, 1666
- Proteus Syndrome, 1666
- Klippel-Trénaunay Syndrome, 1670
- Metatropic Dwarfism (Dysplasia), 1673
- Camptomelic Dysplasia, 1677
- Chondroectodermal Dysplasia (Ellis-van Creveld Syndrome), 1679
- Asphyxiating Thoracic Dysplasia (Jeune's Disease), 1683

Marfan's Syndrome

INTRODUCTION

Marfan's syndrome represents a clinically diverse group of patients classically characterized by tall stature; long, thin limbs; long, thin "spider-like" digits (arachnodactyly); dislocation of the ocular lens; and cardiac anomalies. In 1896, Marfan, a French pediatrician, described to his Parisian colleagues the clinical features of Gabrielle, a 5-year-old girl with long, thin limbs (leading him to describe the girl's condition as *dolichostemelia*, meaning long, thin limbs), spider-like digits, and joint contractures that prevented her from walking.³⁹ Achard in 1902 named the syndrome arachnodactyly,² although Marfan himself considered this characterization too limited. Boerger in 1914 identified the characteristic ocular anomaly of lens dislocation (ectopia lentis).⁹ Weve in 1931 demonstrated that this syndrome was an autosomal dominant condition.⁸⁰ It was only after the identification of associated cardiac anomalies by Baer and colleagues in 1943 that the description of the major features of Marfan's syndrome was complete.⁴ Ironically, the diagnosis of Marfan's patient has been challenged by Hecht and Beals,³⁰ who believe that Gabrielle's condition more likely represented Beals' syndrome,³ since she apparently lacked the typical ocular and cardiac anomalies associated with Marfan's syndrome.* A comparison of Mar-

fan's drawing of Gabrielle's limb and digital anomalies (Fig. 30-1) with the features of Beals' syndrome suggests the strength of Beals and Hecht's argument. A thorough and detailed description of this entity is given by Godfrey,²² and an entertaining review of the history of the evolution of the description is provided by Steel.⁷⁰

HEREDITY AND INCIDENCE

Marfan's syndrome is transmitted as an autosomal dominant disorder. There is great variability in the nature and severity of clinical manifestations, and the unwary physician may not recognize the syndrome in mildly affected patients. Although a family history of Marfan's syndrome is an important diagnostic criterion, the incidence of spontaneous mutations is thought to be between 15 and 30 percent. The lack of a specific laboratory test to confirm the diagnosis of Marfan's syndrome and the variable clinical expression, including milder manifestations, of the disorder make it difficult to estimate the incidence of the Marfan's syndrome with certainty. The prevalence is thought to be approximately 1 per 10,000 population in the United States.²²

ETIOLOGY

Marfan's syndrome is due to a defective gene, FBN1, located on the long arm of chromosome 15.^{16,17,34,75} This gene encodes

* See references 21, 22, 25, 33, 44, 54-56, 59, 70.

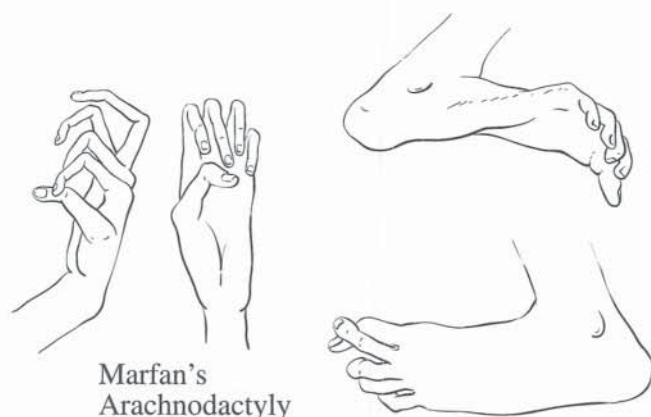


FIGURE 30-1 Appearance of the extremities of Gabrielle, as drawn by Marfan. Their appearance is remarkably similar to that of patients now identified as having Beals' syndrome (see Fig. 30-5), leading Hecht and Beals to contend that Marfan's patient actually had congenital contractural arachnodactyly.

for fibrillin-1, a large glycoprotein closely associated with elastin. In addition to the aortic media and suspensory ligaments of the lens, fibrillin microfibrils are found in skin, tendon, cartilage, and periosteum.* In contradistinction, the much rarer Beals syndrome is due to a defective gene, FBN2, located on chromosome 5 that encodes for the glycoprotein fibrillin-2.

Despite the identification of the specific gene whose defect results in Marfan's syndrome, no specific laboratory test exists to categorically confirm or exclude the diagnosis of Marfan's syndrome. This is due in part to the fact that a great many mutations of the gene have been identified, apparently even within specific families known to harbor the defect. Thus, the diagnosis is based on the presence and severity of the clinical manifestations of the disease.⁴⁴

CLINICAL MANIFESTATIONS

Classic florid Marfan's syndrome is easily recognized as an unusually tall, lanky individual with arachnodactyly, disproportionately long arms, chest wall deformity, extreme myopia, and a loud cardiac murmur (Fig. 30-2).† Many patients have much less florid manifestations, however, and the clinician should rely on an awareness of the condition followed by the strict fulfillment of specific criteria to make this diagnosis. Some individuals may have subtle deformities suggestive of the condition, such as a taller than average appearance, ligamentous laxity, myopia, and minimal cardiac abnormalities, such as mild mitral valve prolapse. In the past, such patients were characterized as having forme fruste Marfan's syndrome.^{23,54,60,62,70} However, as Pyeritz and colleagues have pointed out,⁵⁴ inclusion of such patients in a vague category does not help elucidate the nature of the condition or aid in the management of the condition, and the use of this term and the categorization of patients in this manner should be discouraged. Unfortunately, the large number of FBN1 gene mutations that have been identified in clear cases of the syndrome suggests that further apprecia-

tion of the gene defects may not simplify the diagnosis of Marfan's syndrome.

A number of historical personages have been retrospectively thought to have had Marfan's syndrome. Perhaps the most famous was Abraham Lincoln.⁶⁴ Although Lincoln was tall and lanky with large hands, lending credence to this suggestion, he had no known family history of the disorder or cardiac anomaly, and he wore glasses for reading only after the age of 50.⁷⁰ Thus, it is unlikely that Lincoln had Marfan's syndrome. Blood stains from Lincoln's garments have been preserved, and it is possible that the diagnosis will be specifically confirmed or excluded by the identification of the Marfan gene in these samples.²² More likely to have been affected with Marfan syndrome were the violinist Nicolo Paganini^{21,63} and the composer Rachmaninov.²¹ Certain to have had Marfan's syndrome was US volleyball player Flo Hyman,²¹ whose tragic death on the volleyball court in 1986 emphasizes the importance of both identifying the presence of the condition and screening for its sequelae.

CLINICAL FEATURES

Stature and Proportion. Patients with Marfan's syndrome typically have tall stature and disproportionately long, thin limbs, usually attaining a height of over 6 feet in adult life. The distal bones of the limbs exhibit the excess length most strikingly, resulting in long, slender hands and feet with "spider-like" digits (arachnodactyly). The ratio of the upper body segment (US; measured from the top of the symphysis

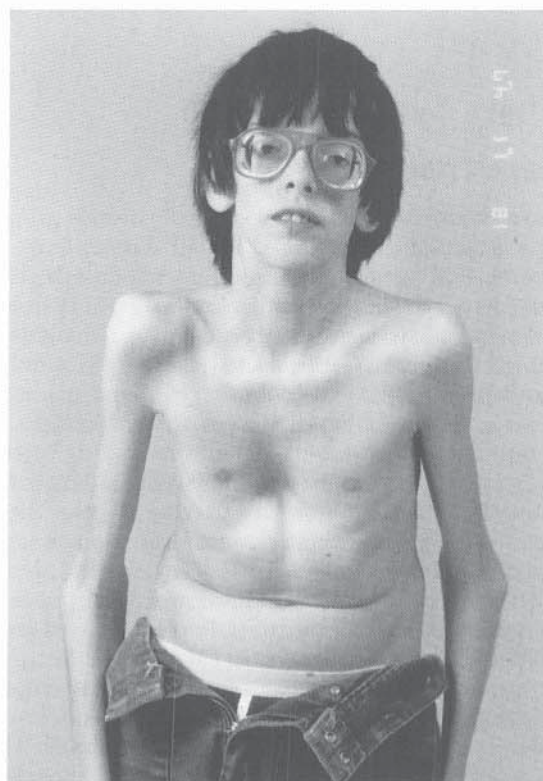


FIGURE 30-2 Clinical appearance of a patient with Marfan's syndrome. Note extreme myopia (represented by thick corrective lens), severe pectus excavatum, long limbs, and arachnodactyly. The patient also has scoliosis and severe planovalgus feet. This appearance is typical of patients with florid manifestations of the syndrome.

* See references 10, 29, 38, 40-42, 48, 52, 53, 57, 77.

† See references 21, 22, 25, 33, 44, 54-56, 59, 70.

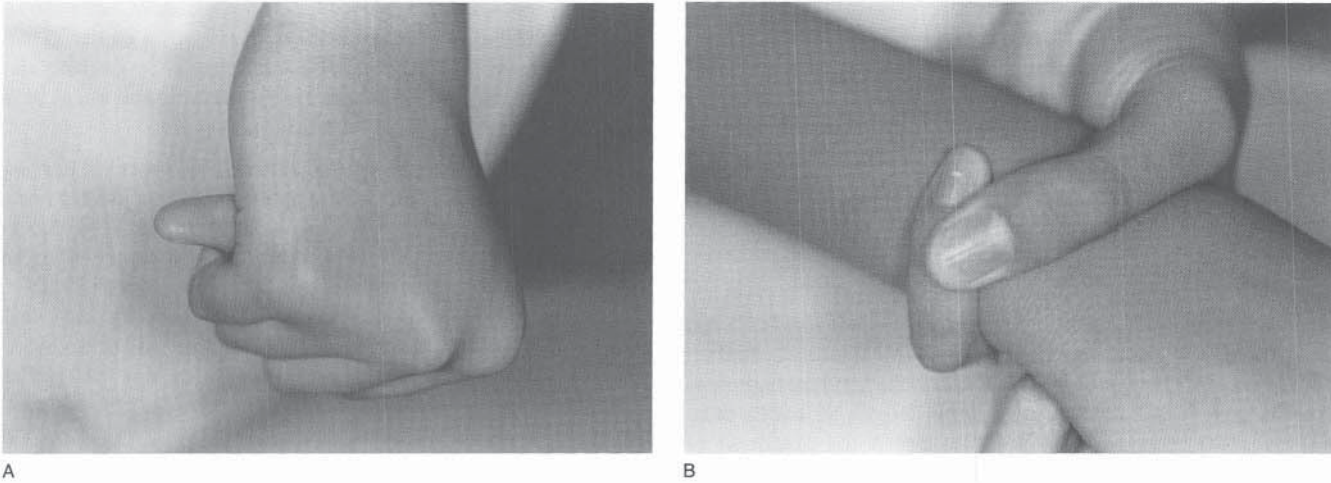


FIGURE 30-3 Clinical signs suggestive of Marfan's syndrome. These signs are suggestive of, but not pathognomonic for, Marfan's syndrome. Their presence results from a combination of joint laxity and long limbs or arachnodactyly. **A**, The thumb sign. With the thumb opposed across the palm and the fingers flexed over the thumb, the distal phalanx of the thumb protrudes beyond the ulnar border of the hand. **B**, The wrist sign. When the patient encircles the opposite wrist with the thumb and small finger, these digits overlap at least to the distal interphalangeal joint of the small finger.

pubis to the top of the head, or by subtracting the lower body segment measurement from the total height) to the lower body segment (LS; measured from the sole to the top of the symphysis pubis) is abnormally low. (The US/LS ratio is 0.93 in the normal adult population.) In addition, the arm span usually exceeds the patient's total height.

Skull and Facies. Patients with Marfan's syndrome often have a high-arched palate, a long, narrow face, and prognathism. The increased height of the skull is associated with enlargement of the frontal sinus.

Eyes. The hallmark of ocular involvement is ectopia lentis (dislocated lens) due to lax or broken suspensory ligaments (zonules). The lens typically dislocates upward and laterally, and may be manifested as iridodensis (fluttering of the iris). The dislocation is best seen on slit-lamp examination following dilation of the pupil. There is usually extreme myopia as a consequence of changes in the shape of the globe. Strabismus, cataract, glaucoma, and detached retina also may occur.

Cardiovascular System. Dilation of the ascending aorta and mitral valve insufficiency are the most common associated cardiovascular anomalies.* Ascending aortic dilation may result in aortic valvular incompetence and frequently leads to a dissecting aneurysm formation. Aneurysms and dissections may also occur in the descending or thoracoabdominal aorta. These cardiovascular anomalies are the most frequent cause of death in patients with Marfan's syndrome, and their presence must be carefully sought.^{12,15,24-26,37,45}

Other Skeletal Manifestations. *Pectus excavatum* is common and is caused by excessive longitudinal growth of the ribs. The anteroposterior (AP) diameter of the thoracic cage is reduced. Recurrence after surgical correction is more common than in the general population.^{3,78} *Pectus carinatum* is also frequently seen in patients with Marfan's syndrome.

Joint laxity is another hallmark of the disease. Marked pes planovalgus and genu recurvatum are typical. Dislocations of the hip, either developmental⁶⁹ or presenting later, and other joints can occur. Perilunate dislocations have been reported and are due to excessive carpal ligamentous laxity.⁵¹ Extreme planovalgus deformity of the feet is a common feature. The combination of joint laxity and long digits results in several clinical signs indicative of but not pathognomonic for Marfan's syndrome (Fig. 30-3A). One of these is the "thumb sign." When present and diagnostic, the nail of the flexed thumb extends beyond the ulnar border of the clenched fist. Although first reported by Parker and Hare,⁴⁹ this sign is often referred to as the Steinberg sign, since Steinberg recommended that it become part of routine screening for Marfan's syndrome.⁷¹ The "wrist sign"⁷⁶ is the ability of the patient to encircle the opposite wrist with the thumb and small finger, with the thumb overlapping the terminal phalanx of the small finger (Fig. 30-3B). The "cross-leg sign" is the ability of the patient to touch the floor with the foot of the crossing-over leg.

The *vertebral column* is significantly affected in patients with Marfan's syndrome. Radiographs typically show tall vertebral bodies with elongated transverse processes. The position of the sacrum is low in relation to the iliac crests. The spinal canal may appear widened in the lumbar region, with concavity of the posterior borders of the vertebral bodies. Increased localized kyphosis and evidence of ligamentous instability have been noted in the cervical spine.³¹ *Scoliosis* is very common, reported in 30 to 100 percent of patients.* The curve pattern in Marfan's syndrome is often double or multiple. Pain is frequently associated with these curves.^{18,67,72} *Spondylolisthesis* of L5-S1 is also relatively common in Marfan's syndrome.^{67,73,81}

Other Associated Anomalies. Other anomalies associated with Marfan's syndrome include polysyndactyly, myopathy,

* See references 4, 7, 12, 15, 20, 24-26, 28, 37, 42, 43, 46, 50, 58, 60, 61, 65, 66.

* See references 8, 33, 45, 59, 62, 67, 68, 72, 73, 78, 82, 83.

talipes equinovarus, muscular underdevelopment, and hypotonia.

Protrusio acetabuli can be seen radiographically, and may manifest as hip pain and stiffness in patients with Marfan's syndrome.^{33,35,36,70,79} Inguinal, femoral, diaphragmatic, and incisional hernias may be present. Subcutaneous fat is usually sparse. The skin is relatively elastic, and striae may be present.

DIAGNOSIS

Although the defective gene for Marfan's syndrome has been identified, the diagnosis remains a clinical one, based on the affected individual fulfilling the criteria for this diagnosis. In the past, an increased metacarpal length to width ratio (metacarpal index) was thought to aid in the diagnosis of Marfan's syndrome. However, there is disagreement among various authors regarding the usefulness and specificity of this radiographic assessment, and this radiographic criterion should probably not be used to make the diagnosis of Marfan's syndrome.^{13,32,47,74} These criteria have recently been updated by De Paepe and colleagues¹⁴ and are summarized in Table 30–1. The attending physician must be alert to the possibility of the existence of this condition. This is particularly true in the scoliosis clinic and primary care physician's office, since the presenting anomalies are most likely to be either scoliosis or a heart murmur. The physician should seek a family history of the disorder or its manifestations, especially tall stature, ligament laxity, poor vision, cardiac anomalies, and sudden or premature death. The examiner should check for the typical manifestations, specifically tall stature, a reduced US/LS ratio, a high-arched palate, spinal deformity, thumb and wrist signs, and a cardiac murmur. Consultation should then be sought with an ophthalmologist and a cardiologist. A slit-lamp examination should be performed to identify the presence of a dislocated lens. Cardiology evaluation should include echocardiography to assess the diameter of the aortic root and look for evidence of mitral valve prolapse.

Requirements. Criteria for the diagnosis of Marfan's syndrome as modified by de Paepe and colleagues¹⁴ are summarized in Table 30–1. *For an individual with a definite family history of Marfan's syndrome* (that is, a definite family history of the disease or genetic confirmation in a first-order relative), one major criterion in one organ system and involvement of a second organ system are required to make the diagnosis. *For an individual with a noncontributory family history*, the presence of major criteria in at least two different organ systems and involvement of a third organ system are required to make the diagnosis of Marfan's syndrome.

Criteria for Involvement

SKELETAL SYSTEM. *Major criteria:* pectus carinatum; pectus excavatum requiring surgery; reduced US/LS ratio, or arm span to height ratio greater than 1.05; wrist and thumb signs; scoliosis of more than 20 degrees or spondylolisthesis; reduced extension at the elbows (less than 170 degrees); medial displacement of the medial malleolus causing pes planus; protrusio acetabuli. *Minor criteria:* moderate pectus excavatum; joint hypermobility; high-arched palate. For the skeletal system to be involved, at least two of the major criteria or one major plus two minor criteria must be present.

OCULAR SYSTEM. *Major criterion:* ectopia lentis. *Minor criteria:* abnormally flat cornea; increased axial length of the globe; hypoplastic iris or hypoplastic ciliary muscle causing decreased miosis. For the ocular system to be involved, at least two minor criteria must be present.

CARDIOVASCULAR SYSTEM. *Major criteria:* dilation of the ascending aorta; dissection of the ascending aorta. *Minor criteria:* mitral valve prolapse, with or without mitral valve regurgitation; dilation of the main pulmonary artery without obvious cause in a patient less than 40 years old; calcification of the mitral annulus in a patient less than 40 years old; dilation or dissection of the descending thoracic or abdominal aorta in a patient less than 50 years old. For the cardiac system to be involved, one major or one minor criterion must be present.

PULMONARY SYSTEM. *Major criteria:* none. *Minor criteria:* spontaneous pneumothorax; apical blebs. For the pulmonary system to be involved, one of the minor criteria must be present.

SKIN AND INTEGUMENT. *Major criteria:* none. *Minor criteria:* stretch marks; recurrent or incisional hernias. For the skin/integument to be involved, one of the minor criteria must be present.

DURA. *Major criterion:* lumbosacral dural ectasia identified on computed tomography (CT) or magnetic resonance imaging (MRI). *Minor criteria:* none. For the dura to be involved, the major criterion must be present.

FAMILY AND GENETIC HISTORY. *Major criteria:* having a parent, sibling, or child who meets these diagnostic criteria independently; presence of the FBN1 mutation known to cause Marfan's syndrome; presence of a haplotype around FBN1 known to be associated with the unequivocal diagnosis of Marfan's syndrome in the family. *Minor criteria:* none. For the family or genetic history to be contributory, one of the major criteria must be present.

DIFFERENTIAL DIAGNOSIS

A number of conditions have clinical features suggestive of Marfan's syndrome and should be considered in the differential diagnosis. Principal among these for the orthopaedic surgeon are homocystinuria, congenital contractural arachnodactyly (Beals' syndrome), and juvenile ophthalmopathy (Stickler's syndrome).

Homocystinuria. Homocystinuria can closely resemble Marfan's syndrome clinically. Patients whose appearance suggests Marfan's syndrome and who have mental retardation or deficiency should be considered as possibly having homocystinuria. This diagnosis can be confirmed by testing the urine for the presence of excessive homocystine or its by-products in the urine (see subsequent discussion under Homocystinuria).

Congenital Contractural Arachnodactyly. Congenital contractural arachnodactyly (Beals' syndrome) also shares some phenotypic similarities with Marfan's syndrome in that the patients have long extremities and usually quite marked arachnodactyly. However, the condition appears to always occur sporadically and is essentially obvious from birth, and affected patients have joint contractures rather

TABLE 30–1 **Diagnostic Criteria for Marfan’s Syndrome****Skeletal System**

For the skeletal system to be considered involved, at least two major criteria or one major criterion plus two minor criteria must be present.

Major Criteria

- Pectus carinatum
- Pectus excavatum requiring surgery
- Reduced upper segment –1 lower segment ratio, or arm span to height ratio >1.05
- Wrist and thumb signs
- Scoliosis of >20 degrees or spondylolisthesis
- Reduced extension at the elbows (<170 degrees)
- Medial displacement of the medial malleolus causing pes planus
- Protrusio acetabuli of any degree (ascertained on radiographs)

Minor Criteria

- Pectus excavatum of moderate severity
- Joint hypermobility
- Highly arched palate with crowding of teeth
- Facial appearance (dolichocephaly, malar hypoplasia, enophthalmus, retrognathia, down-slanting palpebral fissures)

Ocular System

For the ocular system to be considered involved, in addition to the major criterion, at least two minor criteria must be present.

Major Criteria

- Ectopia lentis

Minor Criteria

- Abnormally flat cornea (as measured by keratometry)
- Increased axial length of globe (as measured by ultrasound)
- Hypoplastic iris or hypoplastic ciliary muscle causing decreased miosis

Cardiovascular System

For the cardiovascular system to be considered involved, one major criterion or one minor criterion must be present.

Major Criteria

- Dilation of the ascending aorta with or without aortic regurgitation and involving at least the sinuses of Valsalva
- Dissection of the ascending aorta

Minor Criteria

- Mitral valve prolapse with or without mitral valve regurgitation
- Dilation of the main pulmonary artery, in the absence of valvular or peripheral pulmonary stenosis or any other obvious cause, below the age of 40 years

Pulmonary System

For the pulmonary system to be considered involved, at least one minor criterion must be present.

Major Criteria

- None

Minor Criteria

- Spontaneous pneumothorax
- Apical blebs (ascertained by chest radiography)

Skin and Integumentary System

For the skin and integument to be considered involved, at least one minor criterion must be present.

Major Criteria

- None

Minor Criteria

- Striae atrophicae (stretch marks)
- Recurrent or incisional herniae

Dura

For the dura to be considered involved, the major criterion must be present.

Major Criteria

- Lumbosacral dural ectasia

Minor Criteria

- None

Family/Genetic History

For the family/genetic history to be considered contributory, one major criterion must be present.

Major Criteria

- Having a parent, child, or sibling who meets these diagnostic criteria independently
- Presence of a mutation or *FBN1* known to cause Marfan’s syndrome; or
- Presence of a haplotype around *FBN1*, inherited by descent, known to be associated with unequivocally diagnosed Marfan’s syndrome in the family

Minor Criteria

- None

Requirements for Diagnosis of Marfan’s Syndrome*For the Index Case*

- If the family/genetic history is not contributory, major criteria in at least two different organ systems and involvement of a third organ system must be present.
- If a mutation known to cause Marfan’s syndrome in others is detected, one major criterion in an organ system and involvement of a second organ system must be present.

For a Relative of an Index Case

- Presence of a major criterion in the family history, and one major criterion in an organ system and involvement of a second organ system.

than ligamentous laxity and more problematic kyphoscoliosis rather than the scoliosis seen in Marfan's syndrome. Beals' syndrome is caused by an abnormality of fibrillin-2 due to an abnormality in the FBN2 gene located on chromosome 5 (see subsequent discussion under Congenital Contractural Arachnodactyly).

Hereditary Juvenile Ophthalmorhopathy. (Stickler's syndrome) patients also have some phenotypic features similar to Marfan's syndrome in that they tend to have long, thin limbs (dolichostemelia). In addition, this condition is autosomal dominant, so that a family history is frequently found as well. However, Stickler's syndrome has features of a skeletal dysplasia radiographically. Furthermore, the ocular manifestations are primarily a tendency to retinal detachment, which also occurs in patients with Marfan's syndrome but much less frequently than lens dislocation (see subsequent discussion under Hereditary Progressive Arthro-ophthalmopathy).

Other Conditions. Conditions sharing features of Marfan's syndrome that affect primarily organ systems other than the skeletal system and that must be considered by the geneticist, ophthalmologist, or cardiologist include familial thoracic aortic aneurysm, familial aortic dissection, familial ectopia lentis, familial Marfan-like habitus, MASS phenotype (myopia, mitral valve prolapse, mild aortic regurgitation, skin [striae] and skeletal [minor criteria for Marfan's syndrome] involvement), and Shprintzen-Goldberg syndrome (Marfan-like skeletal changes, craniosynostosis, neurodevelopmental abnormalities, and occasionally aortic dilation).^{14,22}

TREATMENT

There is no specific treatment for patients with Marfan's syndrome. However, the physician should be alert to the various manifestations which may be the first evidence of the disorder. Orthopaedic surgeons should assure themselves that patients presenting with flatfeet, joint instability, or scoliosis do not have other manifestations of Marfan's syndrome. If the skeletal features are consistent with Marfan's syndrome, a cardiologist and ophthalmologist should be consulted.

Cardiovascular System. The most common cardiovascular manifestations of Marfan's syndrome are mitral valve prolapse, with or without regurgitation, and aortic aneurysm. Aortic aneurysm most commonly involves the ascending aorta and in turn can lead to aortic valve incompetence or dissection of the aortic wall. All patients suspected of having Marfan's syndrome should be evaluated by a cardiologist, and echocardiography should be performed to evaluate for the presence of these two conditions. Patients with confirmed Marfan's syndrome should undergo serial echocardiography to monitor for progressive dilation of the aortic root. The aortic root normally measures approximately 3 cm in the adult, depending on body size. Prophylactic aortic root resection is recommended when the dilation reaches 5 to 6 cm.* It is important to monitor for this condition in confirmed cases of Marfan's syndrome, since aortic aneurysm rupture is the most common cause of death in patients with the syndrome,^{15,20,24,46,50,58,66} and the perioperative mortal-

ity is much higher in urgent or emergency repairs than in elective repairs.^{12,15,20,24,25,37} Another treatment to be considered is the use of beta-blockers, which slow the rate of aortic root dilation in adults.^{26,28,44,65,66} Some authors recommend their use in children. Finally, cardiologists often exclude children with Marfan's syndrome from contact or strenuous sports because of the increased incidence of sudden death related to the cardiac manifestations of the syndrome.

Skeletal System

SCOLIOSIS. Scoliosis is one of the most common and important manifestation of Marfan's syndrome from an Orthopaedic perspective and is a frequent presenting complaint in patients with Marfan's syndrome. The incidence of scoliosis is stated to be 30 to 100 percent in different series,* with the variation in incidence likely related to heterogeneity of the study population. The treatment of scoliosis in patients with Marfan's syndrome parallels that in patients with idiopathic scoliosis. In general, curves less than 25 degrees should be observed, bracing should be considered for progressive curves greater than 25 to 30 degrees, and spinal fusion and instrumentation should be considered for curves greater than 45 to 50 degrees. However, the results of treatment of scoliosis in patients with Marfan's syndrome probably differ from the results in patients with idiopathic scoliosis.† Specifically, most reports indicate poor patient tolerance of bracing and a relatively high frequency of progression of the deformity despite bracing. These facts should be known to both family and physician. Patients undergoing spinal fusion and instrumentation may have a higher likelihood of pseudarthrosis, mandating secure instrumentation and careful observation for the development of pseudarthrosis.

In addition to scoliosis, kyphotic deformities and spondylolisthesis also occur regularly in patients with Marfan's syndrome. These deformities may require treatment along the same guidelines as in patients without Marfan's syndrome. Finally, patients with Marfan's syndrome have a higher incidence of back pain, with or without spinal deformity, which may require symptomatic care.^{18,67,72,73,81}

PROTRUSIO ACETABULI. One of the skeletal manifestations of Marfan's syndrome is protrusio acetabuli.^{33,35,36,70,79} This condition is characterized clinically by hip joint stiffness and pain and radiographically by collapse of the acetabular tear-drop (Fig. 30-4). Steel has described surgical closure of the triradiate cartilage in skeletally immature patients who were symptomatic or in whom increasing acetabular deepening was demonstrated radiographically. In his report on 19 hips followed to skeletal maturity after surgical closure of the triradiate cartilage,⁷⁰ radiographic indices normalized in 12, improved in 4, and were unchanged in 3 (all in patients operated on between the ages of 13 and 14 years); all hips were asymptomatic. He recommended the procedure for patients with the condition who were between 8 and 10 years old. Patients operated on at a later age had symptomatic relief but little improvement in the radiographic appearance of their hips.

DEVELOPMENTAL DYSPLASIA OF THE HIP. Patients with Marfan's syndrome may present with developmental dysplasia of the

* See references 12, 15, 20, 24-26, 37, 61, 65, 66.

* See references 8, 21, 22, 33, 56, 59, 62, 67, 83.

† See references 1, 6, 8, 33, 59, 62, 68, 73, 82.

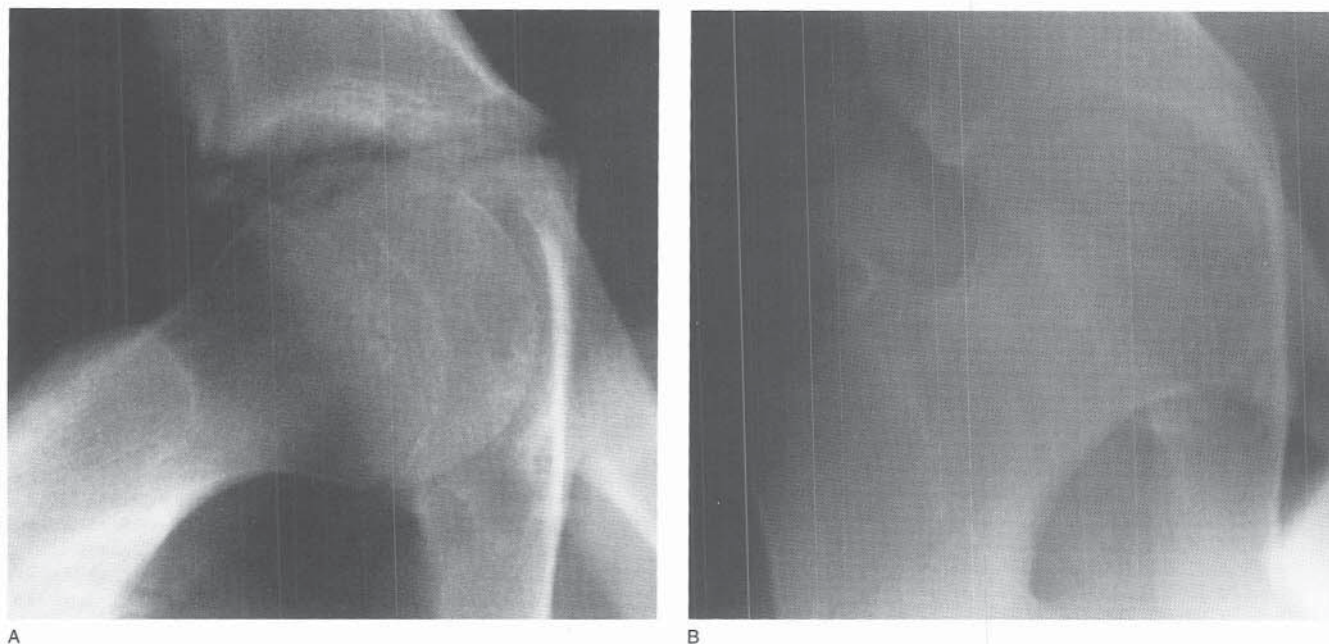


FIGURE 30-4 Protrusio acetabuli in a 14-year-old boy with Marfan's syndrome. **A**, Note the crossing or collapse of the acetabular teardrop. Pain and stiffness of the hip were the presenting manifestations in this patient. **B**, Radiographic appearance 1 year after surgical closure of the triradiate cartilage as described by Steel (see text). There was significant resolution of pain and stiffness.

hip (DDH) as newborns or infants.⁶⁹ In one report, Pavlik harness treatment was unsuccessful in obtaining reduction of the hip, and closed reduction and spica cast immobilization under anesthesia were required. However, the affected hips stabilized in the usual amount of time, and further treatment was not required.⁶⁹

GENERALIZED JOINT LAXITY. The generalized joint laxity that characterizes patients with Marfan's syndrome may manifest as severe planovalgus feet or joint dislocations,^{33,56} especially of the patellofemoral joint. In general, treatment of these conditions should be as conservative as possible, since obtaining and maintaining joint stability can be difficult in these patients.

INFANTILE MARFAN'S SYNDROME

A rare variant of Marfan's syndrome is a relatively severe form presenting in infancy and known as infantile or congenital Marfan's syndrome.^{11,19,27,45,68,77} The clinical characteristics as described by Morse and colleagues⁴⁵ include serious cardiac pathology (often present at birth), congenital contractures (64 percent of our cases, 47 percent of cases reported in the literature), arachnodactyly, dolichocephaly, a high-arched palate, micrognathia, hyperextensible joints, pes planus, anterior chest deformity, iridodonesis, megalocornea, and dislocated lenses. Cardiac anomalies include mitral valve prolapse, valvular regurgitation, and aortic root dilation. Three of the 22 patients identified in the series of Morse and colleagues⁴⁵ died during the first year of life. One-third of the survivors developed severe scoliosis and/or joint dislocations. In the report by Sponseller and colleagues on 14 patients with infantile scoliosis (onset before age 3) and Marfan's syndrome,⁶⁸ four died during treatment. It is likely that most cases are due to a sporadic mutation

in a single germ cell of one parent, as there was a positive family history in only one patient in either series.^{45,68}

Prognosis. In 1972, the predicted average life span of patients with true Marfan's syndrome was 45 years, with premature deaths (almost all due to cardiac complications) occurring at an average age of 32 years.⁴⁶ Beginning with the introduction of aortic root surgery by Bentall and De Bono,⁷ the life span has substantially increased.^{15,20,24,66} Periodic screening with echocardiography, treatment with beta-blockers, and early elective aortic root surgery have led to an increase in predicted average life span to 72 years, with premature deaths occurring at an average age of 41 years.⁶⁶ These improvements and an appreciation for the potentially tragic consequences of not identifying the condition should serve to render the orthopaedist alert to the identification of the presence of this syndrome and appropriate medical evaluation.

REFERENCES

Marfan's Syndrome

1. Amis J, Herring JA: Iatrogenic kyphosis: a complication of Harrington instrumentation in Marfan's syndrome. A case report. *J Bone Joint Surg* 1984;66-A:460.
2. Archard C: Arachnodactylie. *Bull Mem Soc Med Hop Paris* 1902;19:834.
3. Arn PH, Scherer LR, Haller JA Jr, et al: Outcome of pectus excavatum in patients with Marfan syndrome and in the general population. *J Pediatr* 1989;115:954.
4. Baer R, Taussig H, Oppenheimer E: Congenital aneurysmal dilations of the aorta with arachnodactyly. *Bull Johns Hopkins Hosp* 1943;72:309.
5. Beals RK, Hecht F: Congenital contractural arachnodactyly: a heritable disorder of connective tissue. *J Bone Joint Surg* 1971;53-A:987.
6. Beneux J, Rigault P, Pouliquen J, et al: Les deviations rachidiennes de la maladie de Marfan chez l'enfant: étude de 20 cas. *Rev Chir Orthop* 1978;64:471.

7. Bentall H, De Bono A: A technique for complete replacement of the ascending aorta. *Thorax* 1968;23:338.
8. Birch JG, Herring JA: Spinal deformity in Marfan syndrome. *J Pediatr Orthop* 1987;7:546.
9. Boerger F: Über zwei Fälle von Arachnodaktylie. *Z Kinderheilk* 1914; 12:161.
10. Booms P, Withers AP, Boxer M, et al: A novel de novo mutation in exon 14 of the fibrillin-1 gene associated with delayed secretion of fibrillin in a patient with a mild Marfan phenotype. *Hum Genet* 1997;100:195.
11. Buntinx IM, Willems PJ, Spitaels SE, et al: Neonatal Marfan syndrome with congenital arachnodactyly, flexion contractures, and severe cardiac valve insufficiency. *J Med Genet* 1991;28:267.
12. Coselli JS, Le Maire SA: Current status of thoracoabdominal aortic aneurysm repair in Marfan syndrome. *J Cardiac Surg* 1997;12:167.
13. de Oliveira Sobrinho RP, Moretti-Ferreira D, Contini A, et al: Metacarpophalangeal pattern profile in Marfan syndrome and Marfan-like patients. *Am J Med Genet* 1997;72:159.
14. De Paepe A, Devereux RB, Dietz HC, et al: Revised diagnostic criteria for the Marfan syndrome. *Am J Med Genet* 1996;62:417.
15. Devereux R, Roman M: Aortic disease in Marfan's syndrome. *N Engl J Med* 1999;340:1358.
16. Dietz HC, Cutting GR, Pyeritz RE, et al: Marfan syndrome caused by a recurrent de novo missense mutation in the fibrillin gene [see comments]. *Nature* 1991;352:337.
17. Dietz HC, Pyeritz RE, Hall BD, et al: The Marfan syndrome locus: confirmation of assignment to chromosome 15 and identification of tightly linked markers at 15q15-q21.3. *Genomics* 1991;9:355.
18. Duncan RW, Esses S: Marfan syndrome with back pain secondary to pedicular attenuation: a case report [see comments]. *Spine* 1995; 20:1197.
19. Edwards RH: Congenital Marfan syndrome. *Birth Defects Orig Article Ser* 1975;11:329.
20. Finkbohner R, Johnston D, Crawford ES, et al: Marfan syndrome: long-term survival and complications after aortic aneurysm repair. *Circulation* 1995;91:728.
21. Fox E: An Overview of the Marfan Syndrome. Bossier City, LA, Everett Publishing Co, 1989.
22. Godfrey M: The Marfan Syndrome. In Beighton P (ed): *McKusick's Heritable Disorders of Connective Tissue*, p 51. St. Louis, CV Mosby Co, 1993.
23. Golden RL, Lakin HM: The forme fruste in Marfan's syndrome. *N Engl J Med* 1959;260:797.
24. Gott V, Greene P, Alejo D, et al: Replacement of the aortic root in patients with Marfan's syndrome. *N Engl J Med* 1999;340:1307.
25. Gott VL: Antoine Marfan and his syndrome: one hundred years later. *Md Med J* 1998;47:247.
26. Groenink M, Rozendaal L, Naeff MS, et al: Marfan syndrome in children and adolescents: predictive and prognostic value of aortic root growth for screening for aortic complications. *Heart* 1998;80:163.
27. Gruber MA, Graham TP Jr, Engel E, et al: Marfan syndrome with contractural arachnodactyly and severe mitral regurgitation in a premature infant. *J Pediatr* 1978;93:80.
28. Haozi A, Berglund H, Pelikan PC, et al: Heterogeneous aortic response to acute beta-adrenergic blockade in Marfan syndrome. *Am Heart J* 1997;133:60.
29. Hayward C, Brock DJ: Fibrillin-1 mutations in Marfan syndrome and other type-1 fibrillinopathies. *Hum Mutat* 1997;10:415.
30. Hecht F, Beals RK: "New" syndrome of congenital contractural arachnodactyly originally described by Marfan in 1896. *Pediatrics* 1972; 49:574.
31. Hobbs WR, Sponseller PD, Weiss AP, et al: The cervical spine in Marfan syndrome. *Spine* 1997;22:983.
32. Joseph KN: The metacarpal index: obsolete in Marfan syndrome. *Skeletal Radiol* 1992;21:371.
33. Joseph KN, Kane HA, Milner RS, et al: Orthopaedic aspects of the Marfan phenotype. *Clin Orthop* 1992;277:251.
34. Kainulainen K, Pulkkinen L, Savolainen A, et al: Location on chromosome 15 of the gene defect causing Marfan syndrome [see comments]. *N Engl J Med* 1990;323:935.
35. Kharrazi FD, Rodgers WB, Coran DL, et al: Protrusion acetabuli and bilateral basicervical femoral neck fractures in a patient with Marfan syndrome. *Am J Orthop* 1997;26:689.
36. Kuhlman JE, Scott WW Jr, Fishman EK, et al: Acetabular protrusion in the Marfan syndrome. *Radiology* 1987;164:415.
37. Le Maire SA, Coselli JS: Aortic root surgery in Marfan syndrome: current practice and evolving techniques. *J Card Surg* 1997;12:137.
38. Liu W, Qian C, Comeau K, et al: Mutant fibrillin-1 monomers lacking EGF-like domains disrupt microfibril assembly and cause severe Marfan syndrome. *Hum Mol Genet* 1996;5:1581.
39. Marfan A: Un cas de déformation congénitale des quatre membres, plus prononcée aux extrémités, caractérisée par l'allongement des os avec un certain degré d'amincissement. *Bul Soc Chir Paris* 1896;13:220.
40. Milewicz DM: Identification of defects in the fibrillin gene and protein in individuals with the Marfan syndrome and related disorders. *Tex Heart Inst J* 1994;21:22.
41. Milewicz DM: Molecular genetics of Marfan syndrome and Ehlers-Danlos type IV. *Curr Opin Cardiol* 1998;13:198.
42. Milewicz DM, Michael K, Fisher N, et al: Fibrillin-1 (FBN1) mutations in patients with thoracic aortic aneurysms. *Circulation* 1996;94:2708.
43. Miura M, Shimazaki Y, Watanabe T, et al: Bentall operation for a child with Marfan syndrome: a case report. *J Card Surg* 1997;12:116.
44. Moodie DS: Diagnosing Marfan syndrome is still based on clinical characteristics. *Cleve Clin J Med* 1998;65:176.
45. Morse RP, Rockenmacher S, Pyeritz RE, et al: Diagnosis and management of infantile Marfan syndrome. *Pediatrics* 1990;86:888.
46. Murdoch JL, Walker BA, Halpern BL, et al: Life expectancy and causes of death in the Marfan syndrome. *N Engl J Med* 1972;286:804.
47. Nelle M, Troger J, Rupprath G, et al: Metacarpal index in Marfan's syndrome and in constitutional tall stature. *Arch Dis Child (England)* 1994;70:149.
48. Park ES, Putnam EA, Chitayat D, et al: Clustering of FBN2 mutations in patients with congenital contractural arachnodactyly indicates an important role of the domains encoded by exons 24 through 34 during human development. *Am J Med Genet* 1998;78:350.
49. Parker AS, Hare HF: Arachnodactyly. *Radiology* 1945;45:220.
50. Patton DJ, Galliani CA, Johnson WH Jr, et al: Sudden death in Marfan syndrome. *AJR Am J Roentgenol* 1995;165:160.
51. Pennes D, Braunstein E, Shirazi K: Carpal ligamentous laxity with bilateral perilunate dislocation in Marfan syndrome. *Skeletal Radiol* 1985;13:62.
52. Pereira L, Andrikopoulos K, Tian J, et al: Targetting of the gene encoding fibrillin-1 recapitulates the vascular aspect of Marfan syndrome. *Nat Genet* 1997;17:218.
53. Putnam EA, Cho M, Zinn AB, et al: Delineation of the Marfan phenotype associated with mutations in exons 23-32 of the FBN1 gene. *Am J Med Genet* 1996;62:233.
54. Pyeritz R, Murphy E, McKusick V: Clinical variability in the Marfan syndrome(s). *Birth Defects* 1979;15:155.
55. Pyeritz RE, Francke U: The Second International Symposium on the Marfan syndrome. *Am J Med Genet* 1993;47:127.
56. Pyeritz RE, McKusick VA: The Marfan syndrome: diagnosis and management. *N Engl J Med* 1979;300:772.
57. Ramirez F: Fibrillin mutations in Marfan syndrome and related phenotypes. *Curr Opin Genet Dev* 1996;6:309.
58. Roberts WC, Honig HS: The spectrum of cardiovascular disease in the Marfan syndrome: a clinico-morphologic study of 18 necropsy patients and comparison to 151 previously reported necropsy patients. *Am Heart J* 1982;104:115.
59. Robins PR, Moe JH, Winter RB: Scoliosis in Marfan's syndrome: its characteristics and results of treatment in thirty-five patients. *J Bone Joint Surg* 1975;57-A:358.
60. Roman MJ, Devereux RB, Kramer-Fox R, et al: Comparison of cardiovascular and skeletal features of primary mitral valve prolapse and Marfan syndrome. *Am J Cardiol* 1989;63:317.
61. Rozendaal L, Groenink M, Naeff MS, et al: Marfan syndrome in children and adolescents: an adjusted nomogram for screening aortic root dilatation. *Heart* 1998;79:69.
62. Savini R, Cervellati S, Beroaldo E: Spinal deformities in Marfan's syndrome. *Ital J Orthop Traumatol* 1980;6:19.
63. Schoenfeld MR: Nicolo Paganini: musical magician and Marfan mutant? *JAMA* 1978;239:40.
64. Schwartz H: Abraham Lincoln and aortic insufficiency: the declining health of the president. *Calif Med* 1972;116:82.
65. Shores J, Berger K, Murphy E, et al: Progression of aortic dilatation and the benefit of long-term beta-adrenergic blockade in Marfan's syndrome. *N Engl J Med* 1994;330:1335.
66. Silverman DJ, Burton KJ, Gray J, et al: Life expectancy in the Marfan syndrome. *Am J Cardiol* 1995;75:157.

67. Sponseller PD, Hobbs W, Riley LH III, et al: The thoracolumbar spine in Marfan syndrome. *J Bone Joint Surg* 1995;77-A:867.
68. Sponseller PD, Sethi N, Cameron DE, et al: Infantile scoliosis in Marfan syndrome. *Spine* 1997;22:509.
69. Sponseller PD, Tomek IM, Pyertiz RE: Developmental dysplasia of the hip in Marfan syndrome. *J Pediatr Orthop B* 1997;6:255.
70. Steel HH: Protrusio acetabuli: its occurrence in the completely expressed Marfan syndrome and its musculoskeletal component and a procedure to arrest the course of protrusion in the growing pelvis [see comments]. *J Pediatr Orthop* 1996;16:704.
71. Steinberg I: A simple screening test for Marfan syndrome. *AJR Am J Roentgenol* 1966;97:118.
72. Tallroth K, Malmivaara A, Laitinen ML, et al: Lumbar spine in Marfan syndrome. *Skeletal Radiol* 1995;24:337.
73. Taylor LJ: Severe spondylolisthesis and scoliosis in association with Marfan's syndrome: case report and review of the literature. *Clin Orthop* 1987;221:207.
74. Thomas SM, Younger KA, Child A, et al: Is the metacarpal index useful in the diagnosis of Marfan syndrome? *Clin Radiol* 1996;51:570.
75. Tsipouras P, Mastro R, Sarafarazi M, et al: Genetic linkage of the Marfan syndrome, ectopia lentis, and congenital contractural arachnodactyly to the fibrillin genes on chromosomes 15 and 5. *N Engl J Med* 1992;326:905.
76. Walker BA, Murdock JL: The wrist sign: a useful physical finding in the marfan syndrome. *Ann Intern Med* 1970;126:276.
77. Wang M, Wang JY, Cisler J, et al: Three novel fibrillin mutations in exons 25 and 27: classic versus neonatal Marfan syndrome. *Hum Mutat* 1997;9:359.
78. Waters P, Welch K, Micheli LJ, et al: Scoliosis in children with pectus excavatum and pectus carinatum. *J Pediatr Orthop* 1989;9:551.
79. Wenger DR, Ditkoff TJ, Herring JA, et al: Protrusio acetabuli in Marfan's syndrome. *Clin Orthop* 1980;147:134.
80. Weve H: Über Arachnodaktylie (Dystrophia mesodermalis congenita, Typus Marfan). *Arch Augenheilk* 1931;104:1.
81. Winter R: Severe spondylolisthesis in Marfan's syndrome: report of two cases. *J Pediatr Orthop* 1982;2:51.
82. Winter RB: Thoracic lordoscoliosis in Marfan's syndrome: report of two patients with surgical correction using rods and sublaminar wires. *Spine* 1990;15:233.
83. Winter RB, Anderson MB: Spinal arthrodesis for spinal deformity using posterior instrumentation and sublaminar wiring: a preliminary report of 100 consecutive cases. *Int Orthop* 1985;9:239.

Hereditary Progressive Arthro-ophthalmopathy (Stickler's Syndrome)

Hereditary progressive arthro-ophthalmopathy is an autosomal dominant disorder that was first described in 1965 by Stickler and associates, who named the condition hereditary progressive arthro-ophthalmopathy.^{11,12} However, it is much more frequently referred to as Stickler's syndrome. Genetic linkage analyses in some families have suggested that the disorder is due to a mutation of the COL2A1 gene, which encodes for type II collagen.^{1,7,14}

CLINICAL FEATURES

Clinically, the condition is characterized by mild hereditary spondyloepiphyseal dysplasia, premature degenerative arthritis, and congenital myopia that is compounded over time by chorioretinal degeneration and retinal detachment.^{2,10,14-16} In addition, the patients often have micrognathia or cleft palate, somewhat reminiscent of Pierre Robin syndrome.^{5,13} Opitz and associates called attention to Stickler's syndrome, believing that it was underdiagnosed and potentially confuseable with Pierre Robin syndrome.^{4,9} Establishing a correct diagnosis is important because of the

genetic implications and the need for periodic ophthalmologic assessment.⁸

ORTHOPAEDIC MANIFESTATIONS

The orthopaedic manifestations are of a mild spondyloepiphyseal dysplasia.⁶ Coxa valga with or without acetabular protrusion, acetabular dysplasia, and hip subluxation have been described.³ Typically, early degenerative changes occur in the hip due to the dysplasia. The digits may have fusiform enlargement. Vertebral body changes are similar to those of Scheuermann's kyphosis. End-plate irregularities are seen, and scoliotic or kyphotic deformities can occur.

TREATMENT

Treatment includes genetic counseling concerning the autosomal dominant trait of the condition and referral to an ophthalmologist for management of eye complications. Progressive scoliosis or kyphosis may require orthotic treatment or spinal fusion. Total joint arthroplasty may be necessary in midlife because of premature degenerative joint disease.

REFERENCES

Hereditary Progressive Arthro-ophthalmopathy (Stickler's Syndrome)

1. Ahmad NN, McDonald-McGinn DM, Zackai EH, et al: A second mutation in the type II procollagen gene (COL2A) causing Stickler syndrome (arthro-ophthalmopathy) is also a premature termination codon. *Am J Hum Genet* 1993;52:39.
2. Baraitser M: Marshall/Stickler syndrome. *J Med Genet* 1982;19:129.
3. Bennett JT, McMurray SW: Stickler syndrome. *J Pediatr Orthop* 1990;10:760.
4. Herrmann J, France TD, Spranger J, et al: The Stickler syndrome (hereditary arthroophthalmopathy). *Birth Defects Orig Article Ser* 1975;11:76.
5. Kelly TE, Wells HH, Tuck KB: The Weissenbacher-Zweymuller syndrome: possible neonatal expression of the Stickler syndrome. *Am J Med Genet* 1982;11:113.
6. Kozlowski K, Turner G: Stickler syndrome: report of a second Australian family. *Pediatr Radiol* 1975;3:230.
7. Liberfarb RM, Hirose T, Holmes LB: The Wagner-Stickler syndrome; a genetic study. *Birth Defects Orig Article Ser* 1979;15:145.
8. Liberfarb RM, Hirose T, Holmes LB: The Wagner-Stickler syndrome: a study of 22 families. *J Pediatr* 1981;99:394.
9. Opitz JM, France T, Herrmann J, et al: The Stickler syndrome. *N Engl J Med* 1972;286:546.
10. Say B, Berry J, Barber N: The Stickler syndrome (hereditary arthro-ophthalmopathy). *Clin Genet* 1977;12:179.
11. Stickler GB, Belau PG, Farrell FJ, et al: Hereditary progressive arthro-ophthalmopathy. *Mayo Clin Proc* 1965;40:433.
12. Stickler GB, Pugh DG: Hereditary progressive arthro-ophthalmopathy. II. Additional observations on vertebral anomalies, a hearing defect, and a report of a similar case. *Mayo Clin Proc* 1967;42:495.
13. Turner G: The Stickler syndrome in a family with the Pierre Robin syndrome and severe myopia. *Aust Paediatr J* 1974;10:103.
14. Vintiner GM, Temple KI, Middleton-Price HR, et al: Genetic and clinical heterogeneity of Stickler syndrome. *Am J Med Genet* 1991;41:44.
15. Winter RM, Baraitser M, Laurence KM, et al: The Weissenbacher-Zweymuller, Stickler and Marshall syndromes: further evidence for their identity. *Am J Med Genet* 1983;16:189.
16. Zlotogora J, Sagi M, Schuper A, et al: Variability of Stickler syndrome. *Am J Med Genet* 1992;42:337.

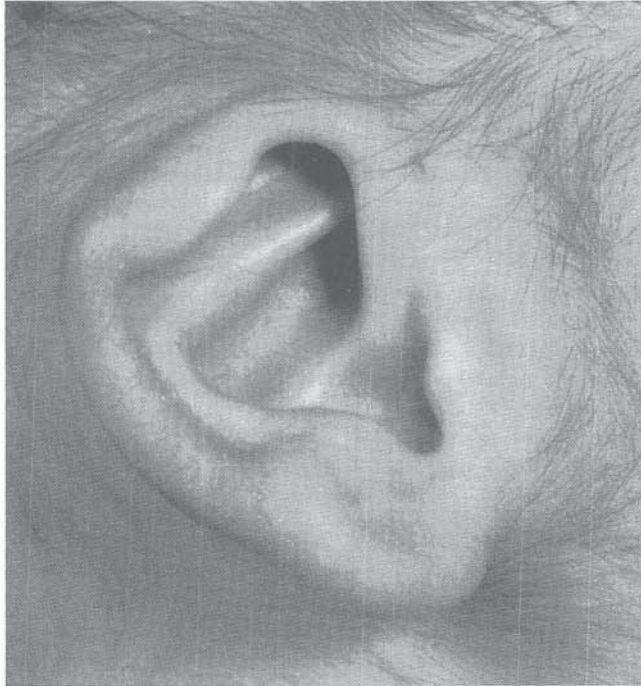


FIGURE 30-5 Infant with congenital contractural arachnodactyly (Beals' syndrome). The "crumpled" appearance of the external ear is typical of this disorder.

Congenital Contractural Arachnodactyly (Beals' Syndrome)

Congenital contractural arachnodactyly (Beals' syndrome) is a rare condition that resembles and has been confused with Marfan's syndrome.^{4,6,10,12,13,16,18,19} In fact, the case Marfan described in 1896 was actually congenital contractural arachnodactyly.^{7,15} Epstein and associates described a case in 1968.⁵ In 1971, Beals and Hecht delineated this syndrome in a report of two kindreds.³

Congenital contractural arachnodactyly is usually differentiated from Marfan's syndrome by the absence of lens dislocation and aortic root dilation (although eye and heart problems can occur²), and by the presence of joint contractures (maximal at the knee) that spontaneously improve with growth and walking.

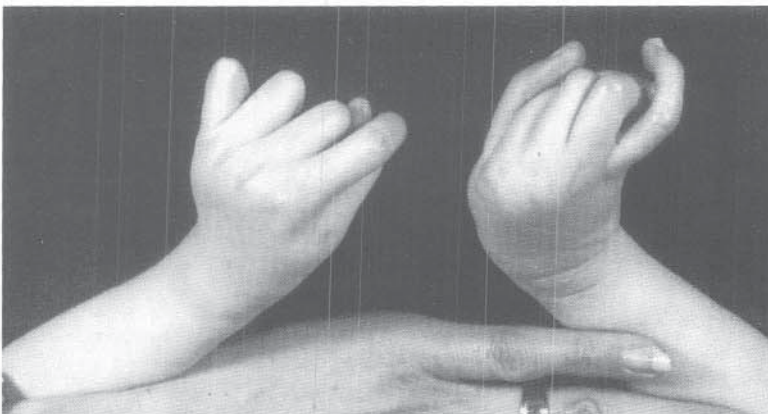


FIGURE 30-6 Congenital contractural arachnodactyly. Very long fingers (arachnodactyly) with crossing of some digits and interphalangeal joint contractures are commonly seen in this condition.

Congenital contractural arachnodactyly is transmitted as an autosomal dominant trait. Genetic linkage studies have identified the defective gene as a mutation of the FBN2 gene located on chromosome 5, which encodes for the protein fibrillin-2.^{17,21,23} Marfan's syndrome is due to a mutation of FBN1 on chromosome 15, which encodes for fibrillin-1. Fibrillin is a large glycoprotein and one of the structural components of the elastin-associated microfibrils.

CLINICAL FEATURES

There is a tendency to retrognathia and a small mouth. The crumpled appearance of the external ear is a distinctive clinical feature. It is caused by extra and prominent crura in the antihelix, partial obliteration of the concha, and flattening of the helix (Fig. 30-5). There may be mild restriction of range of motion of the temporomandibular joints. Intelligence is normal.

The initial descriptions of congenital contractural arachnodactyly suggested that patients with this condition did not exhibit eye or heart abnormalities. As more cases have been described, it is now known that these patients can have myopia¹ and milder cardiac abnormalities than seen in Marfan's syndrome (most typically mitral valve prolapse with regurgitation).^{14,24}

The joint contractures in congenital contractural arachnodactyly are present at birth. Knee flexion contracture is the most severe; it may be as great as 90 degrees and may delay walking. The hips are normal. The ankles are in calcaneus position, with limited plantar flexion and excessive dorsiflexion. In the hands and feet, there are flexion contractures of the proximal interphalangeal joints. The elbows do not extend completely, and the forearms are restricted in supination or pronation, or both. The joint contractures tend to improve spontaneously with growth and development. This restoration of joint motion may be nearly complete, making the diagnosis of congenital contractural arachnodactyly somewhat difficult in the adolescent.

The limbs, fingers, and toes are long and gracile (Figs. 30-6 and 30-7). The long narrow foot may show metatarsus varus. Progressive scoliosis develops in the spine and may be mild or very severe (Fig. 30-8).

RADIOGRAPHIC FINDINGS

Radiographs show the elongated appearance of the diaphysis of the long bones, especially of the digits.⁸ Scoliosis will

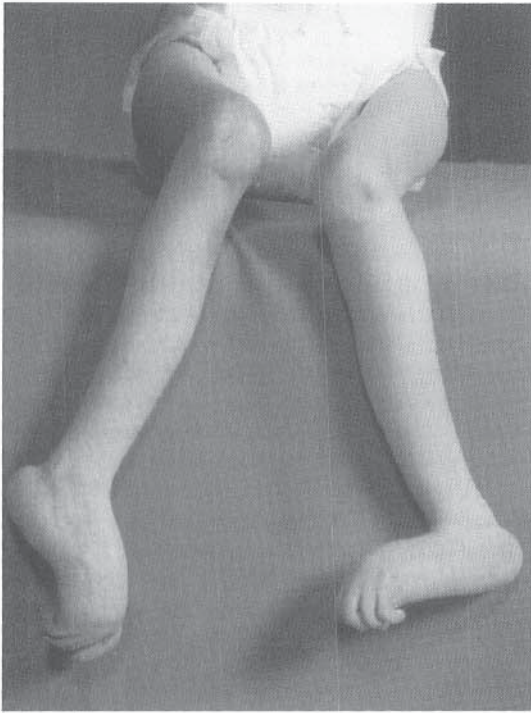

FIGURE 30-7 Congenital contractural arachnodactyly (Beals' syndrome). In the lower extremities, digital anomalies of the feet are similar to those of the hands. Flexion contractures of the knees, present at birth, may improve with growth or require surgical release.

be evident, and slight osteopenia⁹ may also be present (Fig. 30-9).

DIFFERENTIAL DIAGNOSIS

Congenital contractural arachnodactyly should be distinguished from Marfan's syndrome, homocystinuria, arth-

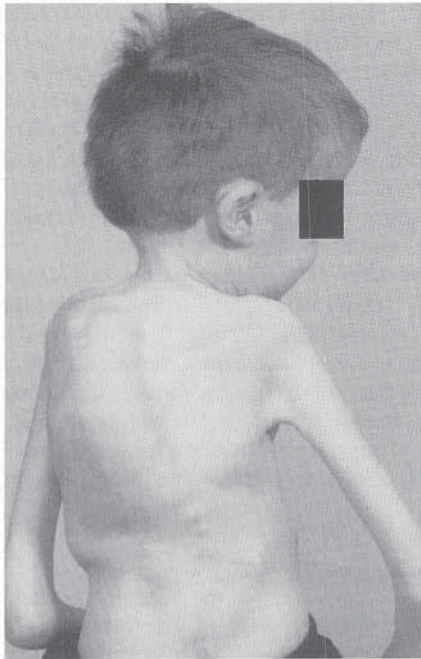


FIGURE 30-8 Congenital contractural arachnodactyly (Beals' syndrome). This patient also developed severe, progressive, infantile-like scoliosis.

rogryposis multiplex congenita, and Achard syndrome in the diagnosis.

Homocystinuria is distinguished from congenital contractural arachnodactyly by the presence of lens dislocation, cardiovascular disease (especially thromboembolism), mental retardation, and characteristic biochemical abnormalities in the urine and tissues. These findings are usually not observed in congenital contractural arachnodactyly.

Arthrogryposis is characterized by congenital joint contractures that are usually more rigid than those seen in congenital contractural arachnodactyly, have much less tendency to resolve, and often are associated with other structural anomalies, such as talipes equinovarus, vertical talus, dislocated hips, and dislocated or hyperextended knees.²⁰

In *Achard syndrome*, arachnodactyly is present, but it lacks the dolichostenomelia joint contractures that are present in congenital contractural arachnodactyly. Achard syndrome is further differentiated from Marfan's syndrome by the absence of lens dislocation and cardiac abnormalities.

TREATMENT

A cardiac examination, including echocardiography, should be performed, with periodic reassessment as indicated.² Contracted joints are treated by gentle passive stretching exercises and splinting to maintain and increase range of motion. Surgical soft tissue release, particularly of the knee (where the flexion contracture is the most severe), should be delayed

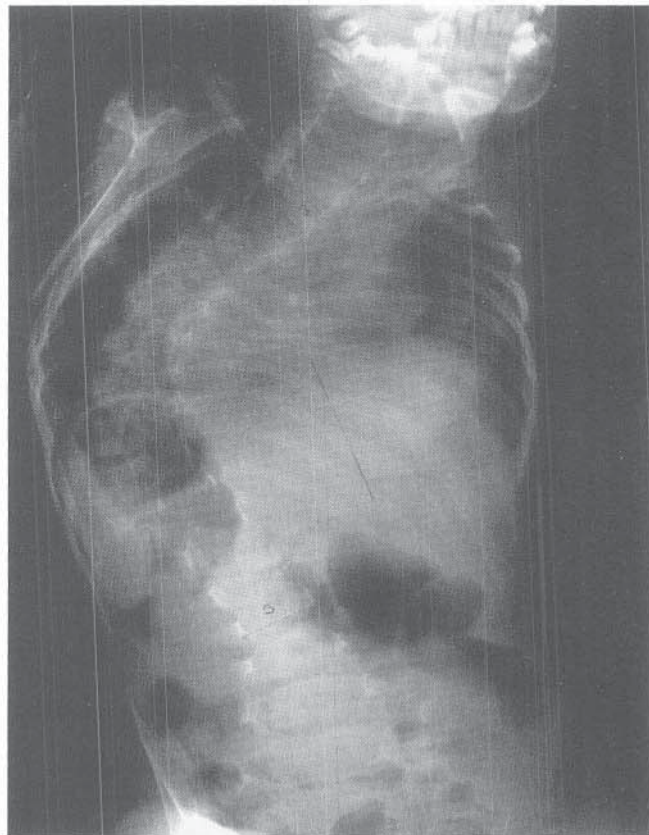


FIGURE 30-9 Radiographic appearance of the spine at the same age as the child shown in Figure 30-8. The scoliosis proved refractory to brace management and ultimately required spinal fusion and instrumentation.

until late childhood or early adolescence.¹¹ Such releases may not be required at all, since the contractures tend to resolve spontaneously. The scoliosis, however, is usually progressive and is managed by orthosis. Progressive, severe scoliosis can produce significant deformity, similar to infantile or neuromuscular scoliosis, and may require substantial treatment, including early anterior and posterior fusion.

REFERENCES

Congenital Contractural Arachnodactyly (Beals' Syndrome)

1. Bard LA: Congenital contractural arachnodactyly and intraocular colobomas. *Birth Defects Orig Article Ser* 1979;15:189.
2. Bawle E, Quigg MH: Ectopia lentis and aortic root dilatation in congenital contractural arachnodactyly. *Am J Med Genet* 1992;42:19.
3. Beals RK, Hecht F: Congenital contractural arachnodactyly: a heritable disorder of connective tissue. *J Bone Joint Surg* 1971;53-A:987.
4. Bjerkreim I, Skoglund LB, Trygstad O: Congenital contractural arachnodactyly. *Acta Orthop Scand* 1976;47:250.
5. Epstein CJ, Graham CB, Hodgkins WE, et al: Hereditary dysplasia of bone with kyphoscoliosis, contractures, and abnormally shaped ears. *J Pediatr* 1968;73:379.
6. Hale MS, Rodman HD, Lipshin J: Congenital contractural arachnodactyly. *West J Med* 1974;120:74.
7. Hecht F, Beals RK: "New" syndrome of congenital contractural arachnodactyly originally described by Marfan in 1896. *Pediatrics* 1972;49:574.
8. Hernandez R, Poznanski AK, Hensinger R: Case report 16. *Skeletal Radiol* 1977;1:175.
9. Ho N-K, Khoo T-K: Congenital contractural arachnodactyly: report of a neonate with advanced bone age. *Am J Dis Child* 1979;133:639.
10. Kontras SB: Congenital contractural arachnodactyly. *Birth Defects Orig Art Ser* 1975;11:63.
11. Langenskiöld A: Congenital contractural arachnodactyly: report of a case and of an operation for knee contracture. *J Bone Joint Surg* 1985;67-B:44.
12. Lowry RB, Guichon BC: Congenital contractural arachnodactyly: a syndrome simulating Marfan's syndrome. *Can Med Assoc J* 1972;107:531.
13. MacLeod PM, Fraser FC: Congenital contractural arachnodactyly (a heritable disorder of connective tissue distinct from Marfan's syndrome). *Am J Dis Child* 1973;126:810.
14. MacNab AJ, D'Orsogni L, Cole DE, et al: Cardiac abnormalities complicating congenital contracture. *Arch Dis Child* 1991;66(special ed 10):1143.
15. Marfan M: Un cas de déformation congénitale des quatre membres, plus prononcée aux extrémités, caractérisée par l'allongement des os avec un certain degré d'aminicissement. *Bull Soc Med Hop Paris* 1896;13:220.
16. McKusick VA: More speculation on Marfan syndrome. *J Pediatr* 1972;80:530.
17. Park ES, Putnam EA, Chitayat D, et al: Clustering of FBN2 mutations in patients with congenital contractural arachnodactyly indicates an important role of the domains encoded by exons 24 through 34 during human development. *Am J Med Genet* 1998;78:350.
18. Passarge E: A syndrome resembling congenital contractural arachnodactyly. *Birth Defects Orig Art Series* 1975;11:53.
19. Penchaszadeh VB, Barreiro C, Groiso JA: Marfan syndrome with congenital contractures. *Birth Defects Orig Art Ser* 1975;11:109.
20. Poznanski AK, LaRowe PC: Radiographic manifestations of the arthrogyposis syndrome. *Radiology* 1970;95:353.
21. Putnam EA, Zhang H, Ramirez F, et al: Fibrillin-2 (FBN2) mutations result in the Marfan-like disorder, congenital contractural arachnodactyly. *Nat Genet* 1995;11:456.
22. Steg NL: Congenital contractural arachnodactyly in a black family. *Birth Defects Orig Art Ser* 1975;11:57.
23. Tsiouras P, Del Mastro R, Sarfarzi M, et al: Genetic linkage of the Marfan syndrome, ectopia lentis, and congenital contractural arachnodactyly to the fibrillin gene on chromosomes 15 and 5. The International

Marfan syndrome Collaborative Study. *N Engl J Med* 1992;326:905.

24. Viljoen D, Ramesar R, Behare O: Beals syndrome: clinical and molecular investigation in a kindred of Indian descent. *Clin Genet* 1991;39:181.

Homocystinuria

Homocystinuria is an inborn error of methionine metabolism, inherited as an autosomal recessive trait, that in its classic form is caused by deficiency of the enzyme cystathionine synthase (sometimes called cystathionine- β -synthase or cystathionine synthetase).^{*} Clinically the disorder is characterized by mental retardation, a tendency to thromboembolic complications, lens dislocation (ectopia lentis), and various skeletal abnormalities that strongly resemble those of Marfan's syndrome. The condition was first described by Field and associates¹⁵ in 1962, and was later reported independently by Gerritsen and Waisman.¹⁸ Prior to these publications (and probably still), cases of homocystinuria had been misdiagnosed as Marfan's syndrome.²⁹

The worldwide prevalence of homocystinuria is reported to be approximately 1 in 335,000. This prevalence varies regionally, from 1 in 65,000 in Ireland to 1 in 900,000 in Japan. A bacterial inhibition assay or amino acid chromatography can be used to screen children at birth for homocystinuria; however, approximately 20 percent of documented cases are missed by these methods. Thus, because of the relatively low prevalence of the disorder and the inaccuracy of screening methods, routine screening for homocystinuria has been discontinued in many countries.³²

BIOCHEMICAL DEFECT AND PATHOPHYSIOLOGY

The deficiency in the enzyme cystathionine synthase (or synthetase) blocks the conversion of homocysteine to cystathionine (Fig. 30-10). The abnormally accumulated homocysteine is converted to homocystine, and as a result, the level of homocystine in the tissues and plasma is elevated, and homocystine is excreted in large quantities in the urine.¹¹ The plasma concentration of methionine is also increased. Cystathionine is normally present in brain tissue and is a precursor to cysteine. In the homocystinuric patient, cystathionine cannot be found in the brain, and cystine becomes an essential amino acid for the patient.

There are other extremely rare causes of homocystinuria: vitamin B₁₂ malabsorption syndrome (Imerslund-Gröbeck syndrome); vitamin B₆ depletion; 5-methyltetrahydrofolate-homocysteine methyltransferase deficiency as a result of defective production of cofactor methylcobalamin; and 5,10-methylene tetrahydrofolate reductase deficiency. The latter two causes of homocystinuria are inheritable metabolic defects. In this text, only the "classic" homocystinuria is discussed.

CLINICAL FEATURES

The clinical features consist of a tendency toward venous and arterial thrombosis,^{14,22} mental retardation,^{8,14,37} disloca-

* See references 2, 6, 10, 18-20, 23, 24, 26, 27, 31, 33, 36.

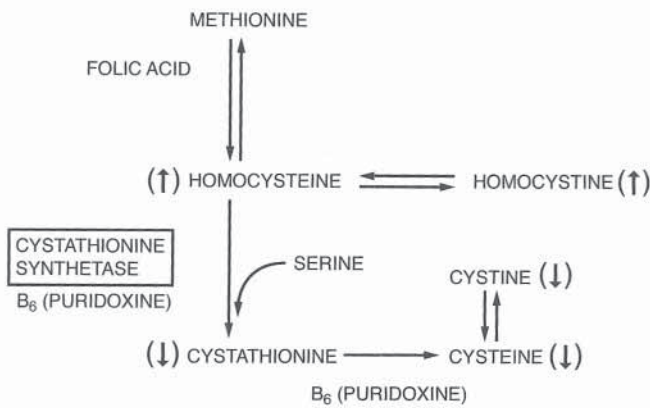


FIGURE 30-10 Scheme of the normal metabolic pathway of methionine and homocysteine, and the consequences of cystathionine synthetase deficiency (the enzymatic defect in homocystinuria). Homocysteine is converted by cystathionine synthetase to cystathionine, which is a precursor to cysteine and is normally present in the brain. In homocystinuria, cystathionine synthetase deficiency results in decreased quantities of cystathionine, which cannot be found in the brain; cystine becomes an essential amino acid for these patients. The block in the metabolic pathway leads to increased quantities of homocysteine (converted from homocysteine) in plasma, tissues, and urine.

tion of the lens,⁴⁴ and skeletal changes resembling those of Marfan's syndrome, with the additional findings of osteoporosis and metaphyseal enlargement (particularly around the knee).^{3,4,28,30,34,39}

Vascular Changes. The lesions in the blood vessels consist of intimal fibrosis, abnormality of the elastic laminae, atherosclerosis, and thrombosis. Homocysteine in itself is a very toxic substance, causing endothelial lesions.¹² Another factor in the pathogenesis of thrombosis is platelet stickiness.⁴⁰ Venous and arterial thrombosis can become life-threatening. Death can occur because of myocardial infarction, pulmonary embolism, mesenteric thrombosis, or cerebral vascular accident. About 20 percent of patients with homocystinuria develop serious thrombosis. Following surgery, the incidence of venous thrombosis is very high. Surgery must be advised in the context of this risk, and anti-thrombotic measures must be taken to minimize this threat.

Mental Retardation. Mental retardation is common but not uniformly present; some patients with homocystinuria have normal intelligence.³⁵ In those who are retarded, the IQ is usually about 50 and can deteriorate with age. Whether the mental retardation is due to the biochemical abnormalities or to intermittent cerebral thrombosis is not certain. In general, homocystinuric patients who respond to pyridoxine are less retarded. Adolescents with homocystinuria may exhibit schizophrenia-like states. Patients may develop seizures and have abnormal electroencephalograms.

Dislocation of the Lens. Dislocation is not observed in infancy but develops later in childhood. It appears to be caused by a defective suspensory ligament. Lens dislocation can produce glaucoma.

Skeletal Changes. The limbs are excessively long and thin (dolichostenomelia); the disproportionately long limbs make the arm span exceed the height of the patient, and the length from head to symphysis pubis is less than from the symphysis pubis to heel. Arachnodactyly is present but

is not as severe or frequent as in Marfan's syndrome. There may be fixed flexion deformity of the digits and flexion deformity of the elbow with limited supination. The feet and toes are long. Severe pes planovalgus is common; some patients have cavus feet. Most patients have scoliosis—usually a left lumbar, right thoracic curve, with the lumbar curve greater than the thoracic curve. Osteoporosis, especially in the spine, is often a striking feature. The vertebral bodies frequently exhibit biconcave end-plates, in addition to the generalized osteopenia.

Widening of the metaphyses and enlargement of the epiphyses of the long bones, particularly at the knees, are important features in homocystinuria.⁵ These are usually not present in Marfan's syndrome.

Associated anomalies are pectus carinatum or excavatum, high-arched palate, a facial appearance characterized by malar flush, and light-colored hair.

DIAGNOSIS

Several studies indicate that a delay in diagnosis is frequent, despite the presence of typical clinical features.^{9,32} The authors emphasize that unusual myopia (high, abnormally progressive, or occurring at a very young age), especially when combined with skeletal manifestations, should alert the attending physician to the possibility of homocystinuria.

Homocystinuria is apparently due to a number of potential genetic or biochemical abnormalities, as the spectrum of clinical manifestations and variable response to pyridoxine might suggest. Thus, confirmation of the diagnosis with laboratory tests is not always simple.^{13,21} The measurement of sulfur amino acid concentrations (especially total homocysteine) in plasma or urine is a good screening tool for this condition. In patients whose clinical features and laboratory screening suggest the diagnosis of homocystinuria, cystathionine synthase assays can be done using fibroblasts cultured from skin biopsy.¹⁶

Features distinguishing homocystinuria from Marfan's syndrome are given in Table 30-2.

TREATMENT

Patients with the diagnosis of homocystinuria should have a trial of treatment with pyridoxine (vitamin B₆), to which approximately 50 percent of patients respond with reversal of the biochemical abnormalities.^{1,7,25} This biochemical reversal may reduce the risk of thromboembolic complications and prevent progression of the osteopenia or mental retardation, but to what extent is uncertain. Preservation of good vision is enhanced if the diagnosis is made and treatment is initiated within the first 6 weeks of life.³⁸ In addition, Wilcken and Wilcken⁴² have demonstrated a significant reduction in thromboembolic events (myocardial infarction and pulmonary edema) in a group of patients treated with a combination of pyridoxine, folic acid, and hydrocobalamin. About 50 percent of patients do not respond to pyridoxine therapy, presumably because of individual variations of the exact nature of the metabolic disorder.^{41,43}

Progressive scoliosis in skeletally immature patients is initially treated with a thoracolumbar orthosis. However, this treatment often fails to prevent progression of the deformity, and spinal fusion and instrumentation must be consid-

TABLE 30-2 Features Discriminating Homocystinuria and Marfan's Syndrome

Feature	Homocystinuria	Marfan's Syndrome
Inheritance	Autosomal recessive	Autosomal dominant
Etiology	Deficiency in enzyme cystathionine synthase	Defective fibrillin-1
Neurologic features	Mental retardation present in most but not all Convulsions; schizophrenia-like state	Absent Absent
Vascular changes	Tendency to thrombosis of veins and arteries High incidence of thromboembolism	Dissecting aneurysm Rupture of aorta Prolapse of mitral valve
Lens dislocation	Present, usually downward Not present at birth	Present, usually upward Can be present at birth
Skeletal changes	Osteoporosis with platyspondyly and biconcave vertebrae Dolichostenomyelia Flaring of metaphysis with enlargement of epiphysis at knee Joint laxity, dislocation rare Moderate arachnodactyly Pectus excavatum carinatum Scoliosis	Osteoporosis absent or minimal Dolichostenomyelia Epiphysis and metaphysis normal Joint laxity typical Severe arachnodactyly Pectus excavatum carinatum Scoliosis

Modified from Tachdjian MO: Pediatric Orthopedics, 2nd ed, p 889. Philadelphia, WB Saunders Co, 1990.

ered. Vertebral body osteopenia and the risk of thromboembolic complications must be taken into consideration when advising and proceeding with surgery.

REFERENCES

Homocystinuria

- Barber GW, Spaeth GL: The successful treatment of homocystinuria with pyridoxine. *J Pediatr* 1969;75:463.
- Beals RK: Homocystinuria: a report of two cases and review of the literature. *J Bone Joint Surg* 1969;51-A:1564.
- Boers GHJ, Polder TW, Cruysberg JRM, et al: Homocystinuria versus Marfan's syndrome: the therapeutic relevance of the differential diagnosis. *Neth J Med* 1984;27:206.
- Brenton DP: Skeletal abnormalities in homocystinuria. *Postgrad Med J* 1977;53:488.
- Brenton DP, Dow CJ, James JIP, et al: Homocystinuria and Marfan's syndrome: a comparison. *J Bone Joint Surg* 1972;54-B:277.
- Brill PW, Mitty HA, Gaull GE: Homocystinuria due to cystathionine synthase deficiency: clinical-roentgenologic correlations. *AJR Am J Roentgenol* 1974;121:45.
- Carson NA, Carre IJ: Treatment of homocystinuria with pyridoxine. *Arch Dis Child* 1969;44:387.
- Carson NAJ, Neill DW: Metabolic abnormalities detected in a survey of mentally backward individuals in Northern Ireland. *Arch Dis Child* 1962;37:505.
- Cruysberg JR, Boers GH, Trijbels JM, et al: Delay in diagnosis of homocystinuria: retrospective study of consecutive patients. *BMJ* 1996;313:1037.
- Cusworth DC, Dent CE: Homocystinuria. *Br Med Bull* 1969;25:42.
- Cusworth DC, Gattereau A: Inhibition of renal tubular reabsorption of homocystine by lysine and arginine. *Lancet* 1968;2:916.
- Dehnel JM, Frances MJO: Somatomedin (sulphation factor)-like activity of homocystine. *Clin Sci* 1972;43:903.
- Drayer JIM, Cleophas AJM, Trijbels JMF, et al: Symptoms, diagnostic pitfalls and treatment of homocystinuria in seven adult patients. *Neth J Med* 1980;23:89.
- Dunn HG, Perry TL, Dolman CL: Homocystinuria: a recently discovered cause of mental defect and cerebrovascular thrombosis. *Neurology* 1966;16:407.
- Field CMB, Carson NAJ, Cusworth DC, et al: Homocystinuria, a new disorder of metabolism [abstract], p 274. Program book of the 10th International Congress of Pediatrics, Lisbon, 1962.
- Fowler B, Jakobs C: Post- and prenatal diagnostic methods for the homocystinurias. *Eur J Pediatr* 1998;157(suppl 2):S88.
- Gaull G, Sturman JA, Schaffner F: Homocystinuria due to cystathionine synthase deficiency: enzymatic and ultrastructural studies. *J Pediatr* 1974;84:381.
- Gerritsen T, Waisman HA: Homocystinuria, an error in the metabolism of methionine. *Pediatrics* 1964;33:413.
- Gibson JB, Carson NA, Neill DW: Pathologic findings in homocystinuria. *J Clin Pathol* 1964;17:427.
- Grieco AJ: Homocystinuria: pathogenetic mechanisms. *Am J Med Sci* 1977;273:120.
- Hagberg B, Hambraeus L: Some aspects of the diagnosis and treatment of homocystinuria. *Dev Med Child Neurol* 1968;10:479.
- Harker LA, Slichter SJ, Scott CR, et al: Homocystinuria, vascular injury and arterial thrombosis. *N Engl J Med* 1974;291:537.
- Kang AH, Trelstad RL: A collagen defect in homocystinuria. *J Clin Invest* 1973;52:257.
- Kennedy C, Shih VE, Rowland LP: Homocystinuria: a report in two siblings. *Pediatrics* 1965;36:736.
- Komrower GM, Lambert AM, Cusworth DC, et al: Dietary treatment of homocystinuria. *Arch Dis Child* 1966;41:666.
- Kraus JP: Komrower lecture. Molecular basis of phenotype expression in homocystinuria. *J Inherit Metab Dis* 1994;17:383.
- Kurczynski TW, Muir WA, Fleisher LD, et al: Maternal homocystinuria: studies of an untreated mother and fetus. *Arch Dis Child* 1980;55:721.
- MacCarthy JMT, Carey MC: Bone changes in homocystinuria. *Clin Radiol* 1968;19:128.
- McKusick VA: Homocystinuria. In McKusick VA (ed): *Heritable Disorders of Connective Tissue*, p 224. St. Louis, CV Mosby Co, 1972.
- Morreels CW, Fletcher BD, Weilbaecher RG, et al: The roentgenographic features of homocystinuria. *Radiology* 1968;90:1150.
- Mudd SH, Levy HL, Skovby F: Disorders of transsulfuration. In Scriver CR, Beaudet AL, Sly WS, et al (eds): *The Metabolic and Molecular Bases of Inherited Disease*, 7th ed, vol 1, p 1279. New York, McGraw-Hill, 1982.
- Naughten ER, Yap S, Mayne PD: Newborn screening for homocystinuria: Irish and world experience. *Eur J Pediatr* 1998;157(suppl 2):S84.
- Sardharwalla IB, Fowler B, Robins AJ, et al: Detection of heterozygotes for homocystinuria. *Arch Dis Child* 1974;49:553.
- Schedewie H, Willich E, Grobe H, et al: Skeletal findings in homocystinuria: a collaborative study. *Pediatr Radiol* 1973;1:12.
- Schimke RN, McKusick VA, Huang T, et al: Homocystinuria: studies of 20 families with 38 affected members. *JAMA* 1965;193:711.
- Smith R: *Biochemical Disorders of the Skeleton*, p 210. London, Butterworth, 1979.
- Spaeth GL, Barber GW: Prevalence of homocystinuria among mentally retarded: evaluation of a specific screening test. *Pediatrics* 1967;40:586.
- Taylor RH, Burke J, O'Keefe M, et al: Ophthalmic abnormalities in homocystinuria: the value of screening. *Eye* 1998;12:427.
- Thomas PS, Carson NAJ: Homocystinuria: the evolution of skeletal changes in relation to treatment. *Ann Radiol* 1978;21:95.
- Uhlemann ER, Tempas JH, Lucky AW, et al: Platelet survival and morphology in homocystinuria due to cystathionine synthase deficiency. *N Engl J Med* 1976;295:1283.

41. Wilcken B, Turner B: Homocystinuria: reduced folate levels during pyridoxine treatment. *Arch Dis Child* 1973;48:58.
42. Wilcken DE, Wilcken B: The natural history of vascular disease in homocystinuria and the effects of treatment. *J Inherit Metab Dis* 1997;20:295.
43. Wong PWK, Justice P, Hruba M, et al: Folic acid nonresponsive homocystinuria due to methylenetetrahydrofolate reductase deficiency. *Pediatrics* 1977;59:749.
44. Zavala C, Cobo A, Lisker R, et al: Fequency of homocystinuria amongst the blind. *Clin Genet* 1973;4:98.

Nail-Patella Syndrome (Hereditary Onycho-osteodysplasia)

In 1820, Chatelain described a patient with congenital anomalies of the nails, elbows, and knees—the earliest report of nail dystrophy associated with skeletal dysplasia.² In 1897, Little quoted a description by Sedgwick of a family of which 18 members in four generations had no thumbnails and no patellae, thus suggesting the hereditary nature of this disorder.¹³ Involvement of the elbows was reported by Wrede in 1909.²⁵ A detailed study of this triad of anomalies was made by Osterreicher in 1931.¹⁷

Turner in 1933 observed flaring of the iliac crests and prominence of the anterior-superior iliac spines in some of the affected patients.²³ Fong in 1946, during routine pyelography, noted conical bony projections on the posterior ilia, which he termed “iliac horns”; he did not, however, associate them with any syndrome.⁶ A few years later these iliac horns were observed in association with knee, elbow, and nail anomalies and reported by other authors.^{16,21} Thus, iliac horns were established as an important constituent of this syndrome (Fig. 30–11).

The popular name of nail-patella syndrome has been applied to this triad of anomalies, but Love and Beiler in 1957 proposed the term hereditary osteo-onychodysplasia (HOOD).¹⁴ It is also referred to as hereditary onycho-osteodysplasia.⁴

The exact incidence of this syndrome is not known. Mino and associates in 1948 collected over 100 cases from the literature.¹⁶ Duncan and Souter in 1963 found reports in the world literature of 44 families exhibiting the syndrome.⁴

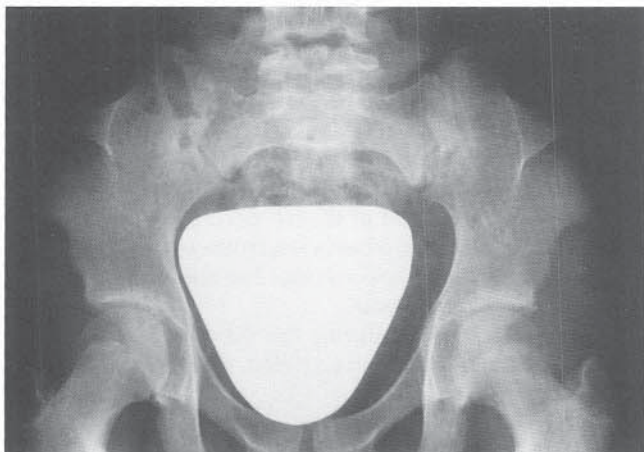


FIGURE 30–11 AP pelvic radiograph of a 14-year-old girl with nail-patella syndrome. Bilateral iliac horns are seen protruding from the iliac wings.

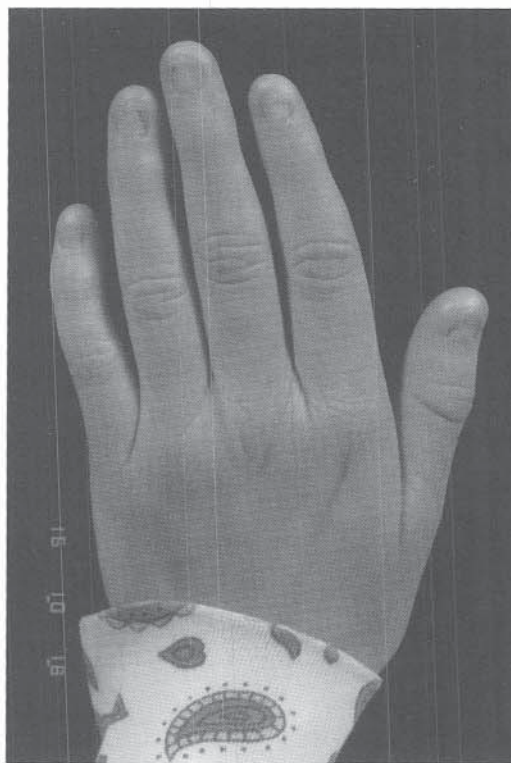


FIGURE 30–12 Dystrophic nails in a 10-year-old girl with nail-patella syndrome. The ulnar digits are less affected than the thumb.

The entire series comprised over 400 affected persons, but details were available on only 252 individuals. Wynne-Davies and associates reported a birth incidence of 1 in 50,000 and a probable prevalence of about 1 per 1 million population.²⁷

GENETICS

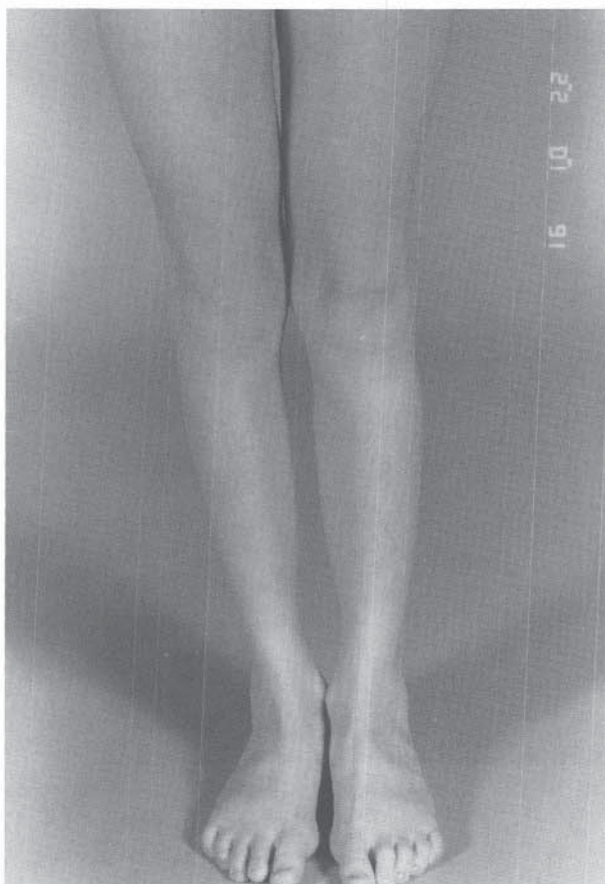
Onycho-osteodysplasia is transmitted as an autosomal dominant trait.⁵ There is a linkage between the locus of the nail-patella gene and that of the ABO blood groups on chromosome 9.^{1,15,19,20}

CLINICAL FEATURES

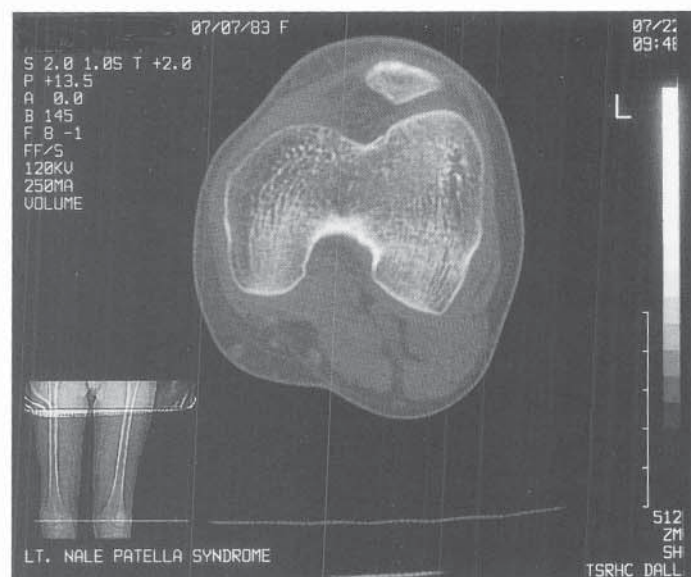
Dystrophy is greatest in the thumbnails and becomes less severe in the more ulnar digits (Fig. 30–12). The little finger is rarely affected. Abnormalities of the toenails have been noted in some patients. The thumb nail may be absent, bifid, or hemiatrophic (the ulnar side of the nail is usually the part that is absent). The nails may be decreased in length and show numerous longitudinal cracks. Nail deformity is present in 98 percent of cases.

Bony abnormalities of the digits have not been demonstrated. The mesodermal tissues of the fingers appear to be involved to some extent. The terminal pulp may extend around from the volar aspect onto the dorsal surface. The dorsal skin creases over the distal interphalangeal joints may be absent or poorly developed. There may be laxity of the ligaments of the metacarpophalangeal and interphalangeal joints.

This abnormality manifests as an absence or hypoplasia of the patella. The hypoplastic patella may be ovoid, triangu-



A



B

FIGURE 30-13 A, Clinical appearance of the lower extremities of a 10-year-old girl with nail-patella syndrome and patellofemoral instability. B, CT scan of the patellofemoral joint reveals hypoplasia of the patella and a shallow femoral groove.

lar, or irregular in shape and may arise from several ossific centers. It may be located more distally than in the normal knee, superimposed on both the femoral and lateral tibial condyles.

The presenting complaint may be recurrent lateral dislocation of the patella caused by hypoplasia of the lateral femoral condyle. Some degree of genu valgum is usually present. The medial femoral condyle is frequently large and prominent, while the lateral femoral condyle is underdeveloped (Fig. 30-13). The medial tibial plateau may slip downward and medially, or it may even be grooved. The medial margin of the proximal tibial metaphysis tends to sweep upward and medially in a characteristic arc.

The carrying angle of the elbow joint is increased with varying degrees of cubitus valgus. There is hypoplasia of the lateral side of the elbow joint involving not only the capitellum and lateral condyle but also the radial head. The radial head may articulate normally with the capitellum, or there may be subluxation or dislocation posteriorly. (Fig. 30-14).¹⁸ There may be a pointed exostosis of the lateral aspect of the coronoid process. Range of motion of the elbow joints is usually limited.

RADIOGRAPHIC FINDINGS

Iliac horns¹¹ and flaring of the iliac crests with prominence of the anterior superior iliac spines are the two types of

pelvic abnormalities encountered. Iliac horns, one of the most common characteristic features of onycho-osteodysplasia, are bilateral, are present in 75 percent of cases, and may be visible, palpable, or impalpable, according to their size. Secondary centers of ossification may occur at their tips. They are present quite early in life. When outflaring of the iliac crests, with prominence of the anterior superior iliac spines, is combined with iliac horns, the appearance of the pelvis has been likened to that of an elephant's ear.

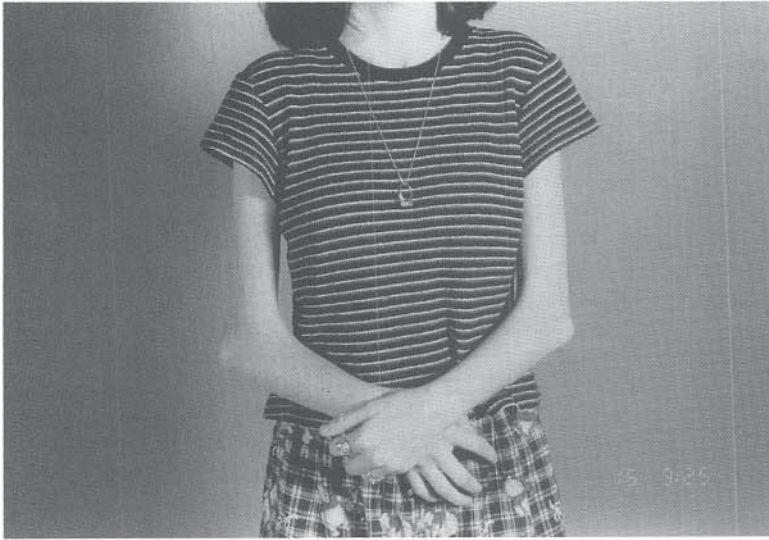
ASSOCIATED ANOMALIES

Other anomalies that may be found in association with the foregoing main lesions include clubfoot and other congenital foot abnormalities,^{7,10} DDH, scoliosis, glenoid and acromial dysplasia,²⁸ and congenital contracture of the little finger. Abnormal pigmentation of the iris occurs in about 50 percent of cases. Plummer-Vinson syndrome (dysphagia, hypochromic anemia, and koilonychia) has also been associated with nail-patella syndrome.

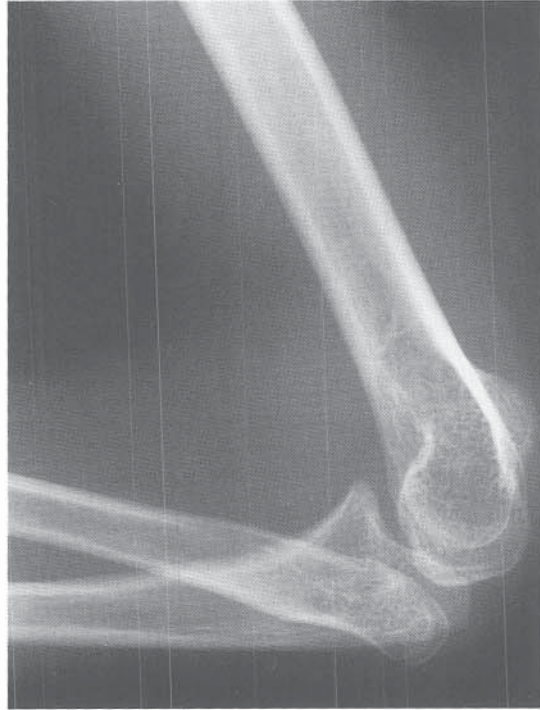Later in life, usually during the third or fourth decade, nephropathy and proteinuria develop, with subsequent renal failure.^{3,5,8,9,12,22,24,26}

TREATMENT

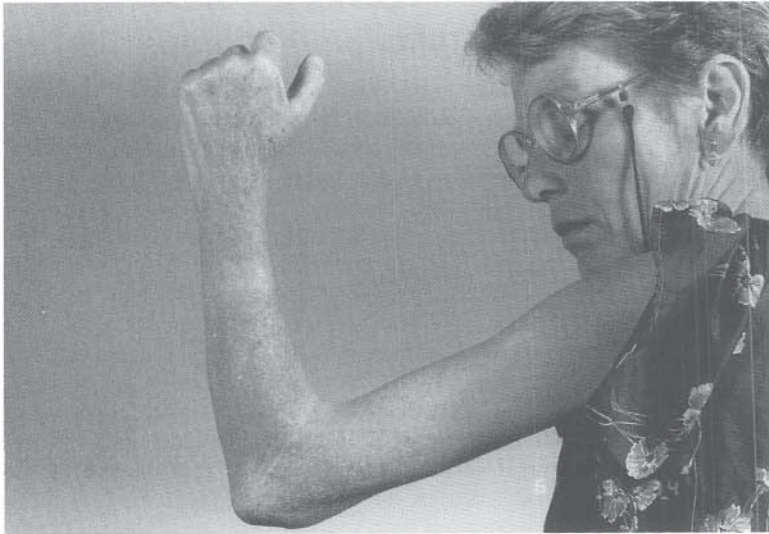
There is no specific treatment for the disorder. Recurrent dislocation of the patella may occur, which, if disabling, is



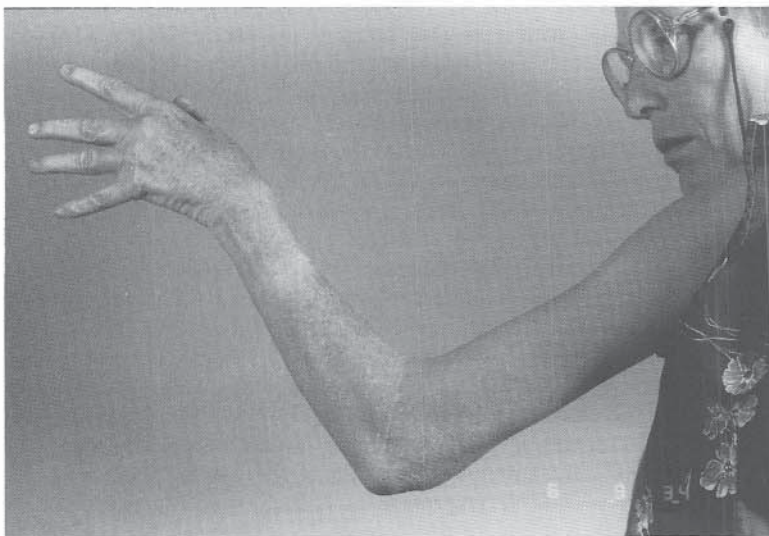A



B



C



D

FIGURE 30-14 A, Bilateral radial head dislocations in a 15-year-old girl with nail-patella syndrome. B, The radial head is dislocated posteriorly. C and D, There is significant limitation in both elbow flexion and extension in the girl's mother.

treated by proximal and/or distal realignment. In a series reported by Guidera and associates, approximately 50 percent of children with nail-patella syndrome underwent knee surgery to treat instability.⁷ Foot deformities often require posteromedial clubfoot releases.

REFERENCES

Nail-Patella Syndrome (Hereditary Onycho-Osteodysplasia)

1. Campeau E, Watkins D, Rouleau GA, et al: Linkage analysis of the nail-patella syndrome. *Am J Hum Genet* 1995;56:243.
2. Chatelain, 1820. Cited by: Roeckerath W: *Fortschr Geb Rontgenstr* 1951;75:700.
3. Darlington D, Hawkins CF: Nail-patella syndrome with iliac horns and hereditary nephropathy: necropsy report and anatomical dissection. *J Bone Joint Surg* 1967;49-B:164.
4. Duncan JG, Souter WA: Hereditary onycho-osteodysplasia: the nail-patella syndrome. *J Bone Joint Surg* 1963;45-B:242.
5. Duthie RB, Hecht F: The inheritance and development of the nail-patella syndrome. *J Bone Joint Surg* 1963;45-B:259.
6. Fong EE: "Iliac horns" (symmetrical bilateral central posterior iliac processes). *Radiology* 1946;47:517.
7. Guidera KJ, Satterwhite Y, Ogden JA, et al: Nail patella syndrome: a review of 44 orthopaedic patients. *J Pediatr Orthop* 1991;11:737.
8. Hawkins CF, Smith OE: Renal dysplasia in a family with multiple hereditary abnormalities including iliac horns. *Lancet* 1950;1:803.
9. Hoger PH, Henschel MG: Skeletal anomalies in nail-patella syndrome: case report and overview. *Hautarzt* 1997;48:581.
10. Hough J, Macnical MF: Foot deformities associated with onycho-osteodysplasia: a familial study and a review of associated features. *Int Orthop* 1985;9:135.
11. Karabulut N, Ariyurek M, Erol C, et al: Imaging of "iliac horns" in nail-patella syndrome. *J Comput Assist Tomogr* 1996;20:530.
12. Kozlovskaja NL, Tareeva IE, Popova VV, et al: Kidney involvement in hereditary osteo-onychodysplasia. *Ter Arkh* 1997;69:37.
13. Little EM: Congenital absence or delayed development of the patella. *Lancet* 1897;2:781.
14. Love WH, Beiler DD: Osteo-onychodysplasia. *J Bone Joint Surg* 1957;39-A:645.
15. McIntosh I, Clough MV, Schaffer AA, et al: Fine mapping of the nail-patella syndrome locus at 9q34. *Am J Hum Genet* 1997;60:133.
16. Mino RA, Mino VH, Livingston RG: Osseous dysplasia and dystrophy of the nails: review of the literature and report of a case. *AJR Am J Roentgenol* 1948;60:633.
17. Osterreicher W: Family with anonychia, patella abnormalities and dislocation of the radius: dominant characteristic over five generations. *Z Mensch Vererb Konstitutionsl* 1931;15:465.
18. Reichenbach H, Hormann D, Theile H: Hereditary congenital posterior dislocation of radial heads. *Am J Med Genet* 1995;55:101.
19. Renwick JH, Lawler SD: Genetic linkage between the ABO and nail-patella loci. *Ann Hum Genet* 1954;19:312.
20. Renwick JH, Schulze J: Male and female recombination fractures for the nail-patella ABO linkage in man. *Ann Hum Genet* 1965;28:379.
21. Thompson EA, Walker ET, Weens HS: Iliac horns: an osseous manifestation of hereditary arthrodysplasia associated with dystrophy of the fingernails. *Radiology* 1949;53:88.
22. Trinn C, Szoke B, Magyarlaki T, et al: Nail-patella syndrome: clinicopathologic characteristics. *Orv Hetil* 1996;137:2253.
23. Turner JW: A hereditary arthrodysplasia associated with hereditary dystrophy of thumb nails. *JAMA* 1933;100:882.
24. Wildfeuer T, Albrecht G: Nail-patella syndrome. *Hautarzt* 1996;47:860.
25. Wrede: Kongenitale erbliche Luxation der Patells nach aussen. *Berl Klin Wochenschr* 1909;46:373.
26. Wright LA, Fred HL: Fatal renal disease associated with hereditary osteo-onychodysplasia. *South Med J* 1969;62:833.
27. Wynne-Davies R, Hall C, Apley AG: *Atlas of Skeletal Dysplasias*, p 614. Edinburgh, Churchill Livingstone, 1985.
28. Yarali HN, Erden GA, Karaaslan F, et al: Clavicular horn: another bony projection in nail-patella syndrome. *Pediatr Radiol* 1995;25:549.

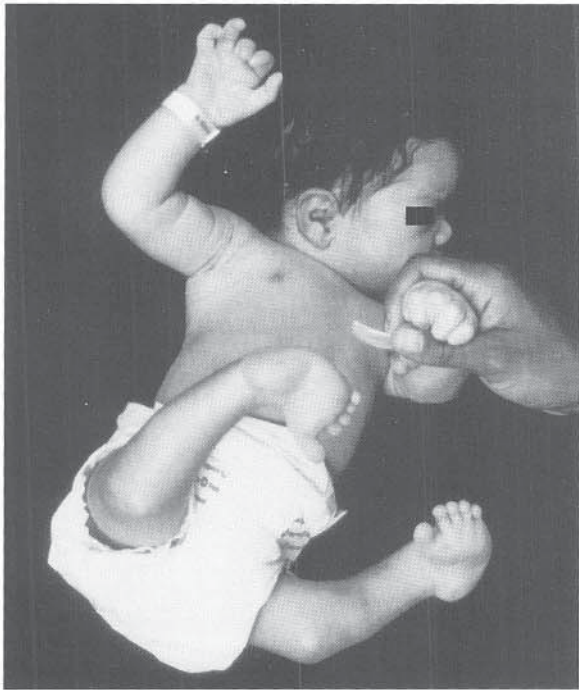
Larsen's Syndrome

Of all the syndromes or conditions likely to be seen by the pediatric orthopaedist, Larsen's syndrome comes with potentially so many orthopaedic deformities requiring treatment that its management has been termed a Herculean task,⁵ owing to the number of dislocated joints, foot deformities, and spine deformities, including a potentially lethal cervical kyphosis, which must be addressed. Once an infant has been diagnosed, a thorough investigation of the entire musculoskeletal system is necessary, with prioritization of the management of these multiple deformities. Even with optimal care of each individual deformity, the functional outcome at maturity may be guarded at best, owing to the additive morbidity and possible complications of management of bilateral dislocations of the hips and knees, independent of any spinal deformities and foot surgeries that might be also required. The magnitude of the task of managing these patients has been noted since the first description of the syndrome by Larsen and associates in 1950.¹²

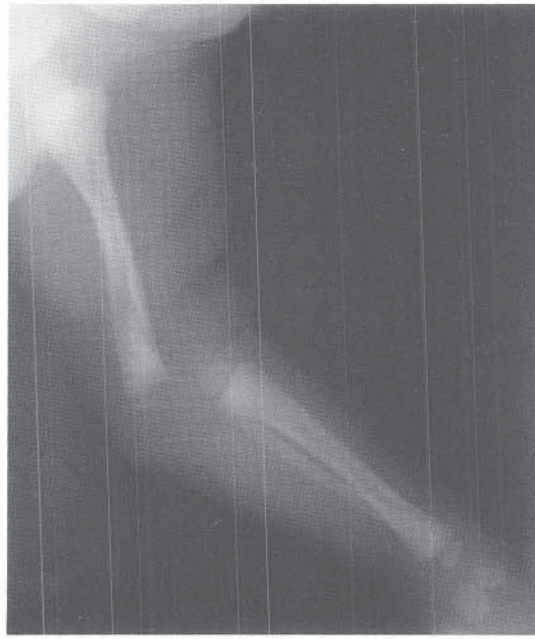CLINICAL FEATURES

An initial evaluation is often required soon after birth, because the orthopaedic manifestations are so dramatic. The lower extremities most frequently exhibit bilateral hyperextension deformities of the knees and fairly rigid clubfeet. The knee deformity spans a spectrum from simple congenital hyperextension deformity to complete (type C) anterior dislocation of the tibia on the femur (Fig. 30-15),³ with the more severe dislocation being common. The hips are often teratologically dislocated, with obvious foreshortening of the thighs, but often with remarkable mobility, reflecting the generalized ligamentous laxity seen in Larsen's syndrome. Other obvious skeletal manifestations include deformities of the hands and elbows. The elbows frequently demonstrate radiohumeral dislocation with lateral prominence of the radial heads even in the infant, and there may be more extensive dislocation with a total disruption of the radiocapitellar and the humeroulnar joints (Fig. 30-16). In the latter case the elbow will be fixed by webbing in the antecubital space, with a flexion contracture varying from 60 to 90 degrees.¹⁷ The fingers are usually long and cylindrical, with a series of shortened metacarpals, and a spatulate thumb where the terminal phalanx is short and wide. Dislocation of the metacarpal joint of the thumb can occur (Fig. 30-16). The appearance of the fingers is distinctly different from classic arthrogryposis, one of the possible diagnoses to be considered in this setting.

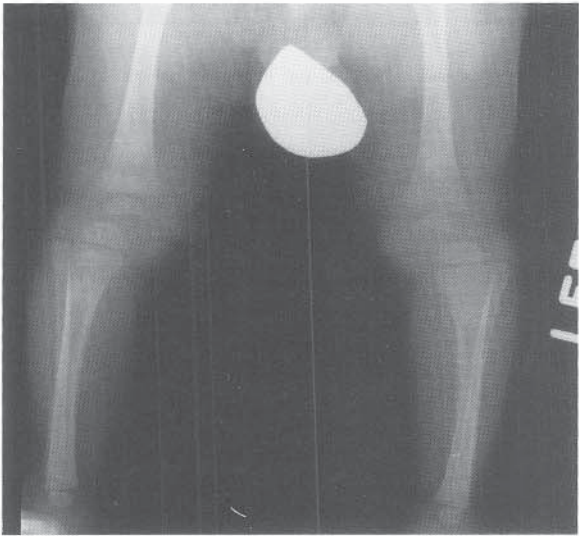
Facial dysmorphism aids in the immediate identification of patients with Larsen's syndrome, who characteristically have a flattened nasal bridge, relatively widely spaced eyes, and a prominent forehead (hypertelorism). The depression of the nasal bridge is a universal characteristic that makes the facial findings, in conjunction with the orthopaedic deformities, pathognomonic. Other nonorthopaedic involvement includes elasticity of the thoracic cage and tracheo- and laryngomalacia. Indeed, respiratory failure or early respiratory death have been reported as part of the syndrome.^{6,13,26} Acquired lesions of the mitral valve and aorta, similar to those found in Marfan's syndrome and other



A



C



B

FIGURE 30-15 Larsen's syndrome. A, A newborn infant with obvious dislocated knees and clubfeet. B and C, Radiographs of type C complete dislocation of the knee.

Illustration continued on following page

hyperelasticity conditions, can further complicate the surgical management of these children.^{11,28,29}

NEUROLOGIC EVALUATION

The neurologic evaluation of children with suspected Larsen's syndrome is critical. These patients are often described as being hypotonic, a condition associated with hyperelasticity syndromes and often implicated in the delay of achievement of certain motor skills such as the ability to walk. In infants who are "floppy" or who have delay in reaching milestones, it may be a dangerous oversimplification to attribute such delay to the syndrome per se or to the presence of multiple joint dislocations or foot deformities, for the possibility of cervical cord compression must always be en-

tertained in *any* infant with hypotonicity. In patients with a known associated cervical kyphosis, the presence of this deformity must be determined as early as possible to avoid chronic myelopathy and neurologic morbidity. Should cervical cord compression occur prior to complete myelination, the classic signs of spasticity and/or hyperactive deep tendon reflexes indicating spinal cord compression are likely to be absent, and the patient will exhibit a flaccid-type paresis (hypotonicity). Although the tracheo- or bronchomalacia observed in patients with Larsen's syndrome^{22,25,26} can be responsible for pulmonary compromise or death in infancy, patients with cord compression and flaccid paresis will also suffer respiratory weakness and failure. Thus, the importance of early neurologic evaluation and radiographic identification of cervical kyphosis cannot be overemphasized in

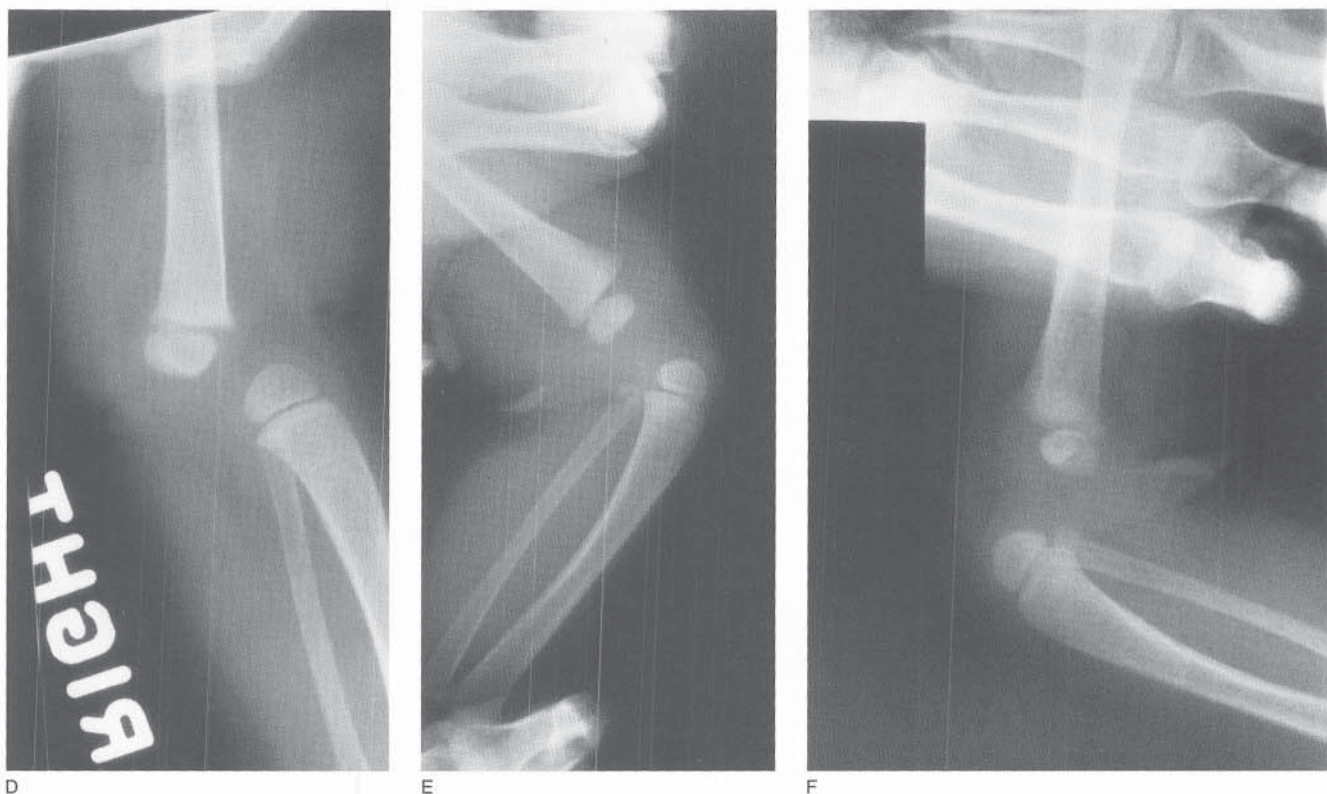


FIGURE 30-15 *Continued.* D, Type B subluxation of the knee in another patient. E and F, Incomplete reduction following cast correction. Both knees subsequently underwent open reduction.

this patient population to avoid chronic myelopathy and irreversible neurologic morbidity.¹⁰ A review of the literature strongly suggests the probable underdiagnosis of cervical kyphosis and cord impingement, as the cervical spine deformities were not emphasized in the original description of the syndrome,¹² and except for sporadic reports,^{1,4,15,19,20} there has been little emphasis on this most critical and potentially catastrophic lesion in patients with the syndrome.

DIFFERENTIAL DIAGNOSIS

Other entities that share features with Larsen's syndrome and must be excluded in the diagnosis include other hyperelasticity syndromes, such as Marfan's syndrome or Ehlers-Danlos syndrome, and, because of the contractures and extremity deformities, arthrogryposis multiplex congenita and Beals' syndrome (congenital contractural arachnodactyly). The latter are usually differentiated by the fact that patients with Larsen's syndrome have a relatively normal muscle mass. Patients with Beals' syndrome or classic arthrogryposis may suffer birth fractures as a result of rigid joints. Arthrogryptic patients lack normal flexion creases, and, with the exception of the elasticity of the chest cage in patients with Larsen's syndrome, which may manifest in the newborn as paradoxical motion on inspiration and stridor, infants with Larsen's syndrome are generally more robust and are actively moving. Patients with hyperelasticity syndromes do not exhibit the *multiple* joint dislocations typical of Larsen's syndrome. A milder form of Larsen's syndrome lacking full-blown joint dislocations may be confused with other hyperelasticity syndromes. The dysmorphic facies of

Larsen's syndrome should then be the physical finding that settles the issue.

Larsen's syndrome is classically inherited by an autosomal dominant pattern,^{7,18} and so a family history of the disorder would be an important additional feature in a patient with an otherwise uncertain diagnosis.

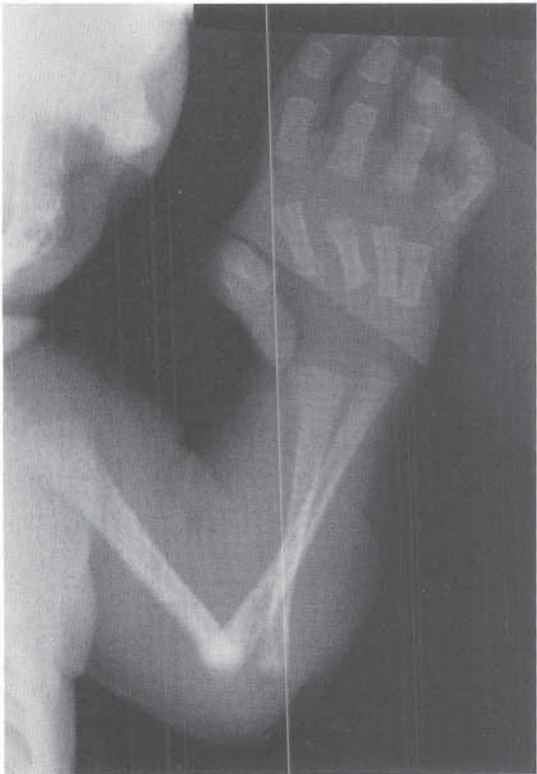RADIOGRAPHIC FINDINGS

An unusual radiographic finding, a separate, additional ossification center for the calcaneus (Fig. 30-17), may aid in the diagnosis.^{5,27} The additional calcaneal apophysis is a quite consistent finding, and its absence would cast doubt on a diagnosis of classic Larsen's syndrome. Extra carpal ossification centers have also been observed^{5,23,27} as another confirming radiographic finding (Fig. 30-18).

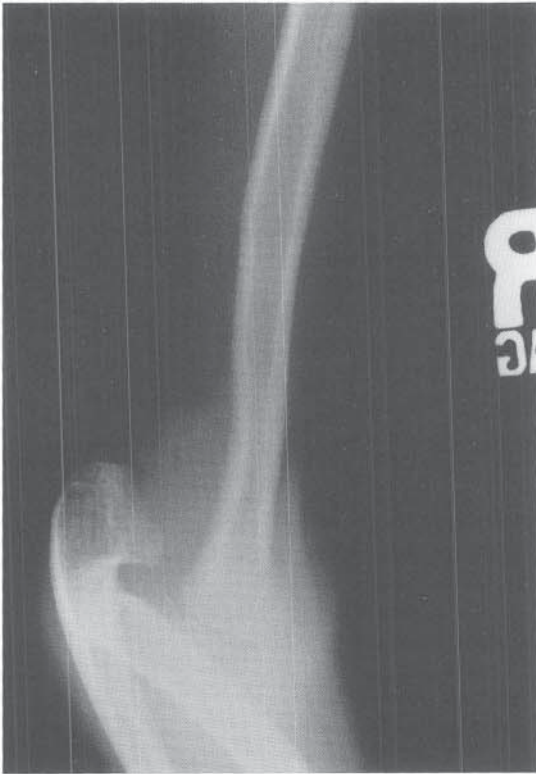TREATMENT

Because of the multiple deformities presenting simultaneously, the order of treatment should be prioritized as early as possible.

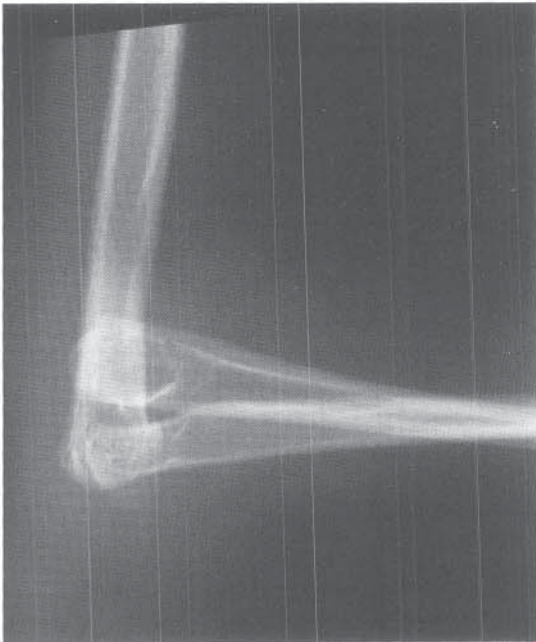Cervical Kyphosis. To minimize morbidity from unsuspected or undiagnosed cervical kyphosis, definitive management should be planned first for this deformity. The actual surgical stabilization of a cervical kyphosis need not precede treatment of other deformities, but the presence of cervical kyphosis must be acknowledged even if spinal cord impingement is not present, and appropriate anesthetic precautions must be taken during surgical procedures for other deformities to avoid possible catastrophic complications.^{1,12,19}



A

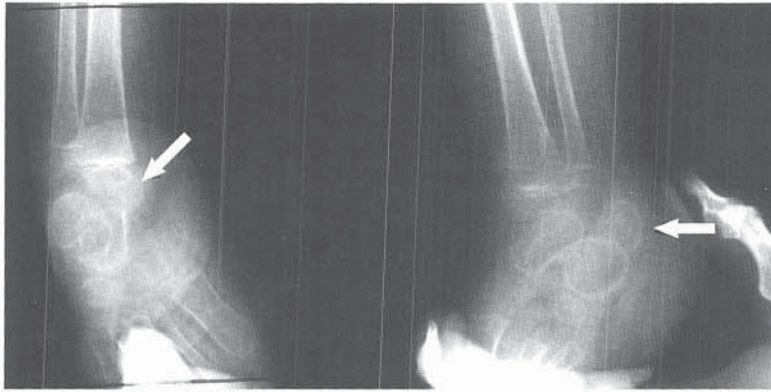


B

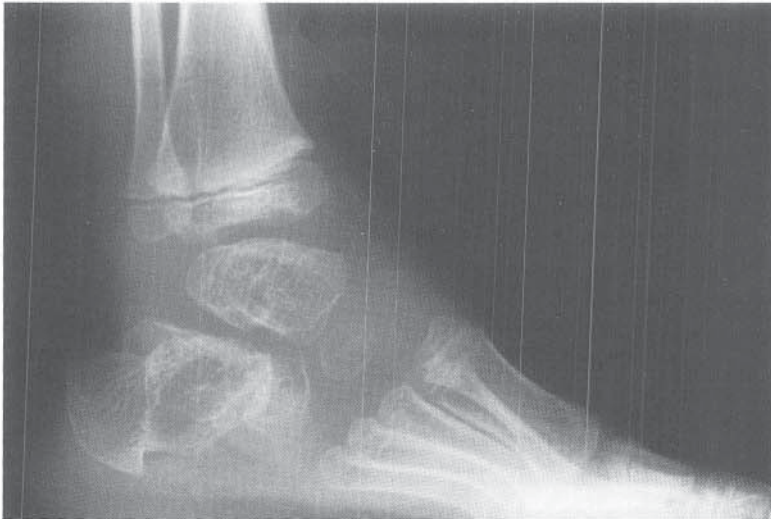

C

FIGURE 30-16 Larsen's syndrome. A, Right elbow in a newborn. Note complete radiocapitellar and humeroulnar dislocation. The thumb is also dislocated at the metacarpophalangeal joint. B and C, Radiographic appearance at age 6. Marked webbing and a 90-degree flexion contracture accompany the untreated deformity.



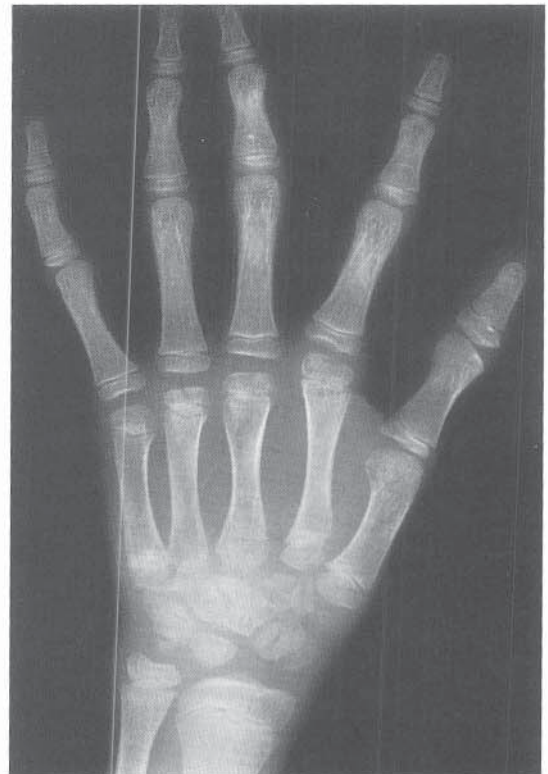A



B

FIGURE 30-17 Unusual radiographic findings that may aid in the diagnosis of Larsen's syndrome. **A**, Accessory calcaneal apophyses in a 2-year-old with clubfeet. **B**, The accessory calcaneal apophysis has fused to the main calcaneus at age 5.

FIGURE 30-18 Larsen's syndrome: extra carpal bone ossific nuclei in a 9-year-old.



In a patient with the full-blown syndrome, we recommend the following prioritization of treatment in the infant: cervical kyphosis (or other threatened instability); congenital dislocation of the knee; congenital dislocation of the hip; and last, foot deformities requiring correction to reach plantigrade position. The treatment of cervical kyphosis may not be required early in the absence of objective signs of spinal cord compression. Early MRI evaluation is crucial to determine the urgency of stabilization (Fig. 30–19). Posterior cervical fusion in infants less than 1 year old is associated with a definite risk of pseudarthrosis and therefore failure, and it has been our experience that delay of posterior cervical fusion to around the age of 18 months, if neurologically feasible, may result in a higher rate of fusion and subsequent correction of the deformity by continued anterior growth.¹⁰ The details of treatment of cervical kyphosis can be found in Chapter 10, Disorders of the Neck.

Congenital Dislocation of the Knee. Congenital dislocation of the knee in Larsen's syndrome is occasionally amena-

ble to nonoperative treatment. The full spectrum of knee dislocation has been observed. If the knee is merely hyperextended (Curtis 2, type A), it may be possible, with serial casting and quadriceps stretching, to achieve reduction by flexion. More often than not, however, the quadriceps contracture is more severe and obliteration of the suprapatellar pouch complete.³⁰ Spurious reduction may occur with persistent manipulation and casting (Fig. 30–15). Once recognized, this leaves operative treatment as the only method for achieving reduction and concentric knee flexion. Therefore, an early attempt at closed reduction by flexion and serial casting should be made in the newborn, and if the reduction is successful, it can be maintained by splintage, which may include the use of a Pavlik harness to maintain the knees in a flexed position.²¹ In a relatively mild case, knee hyperextension and hip dislocation may be treated simultaneously by a Pavlik harness in the neonatal period,⁸ provided that knee flexion greater than 40 to 45 degrees can be achieved (Fig. 30–20).

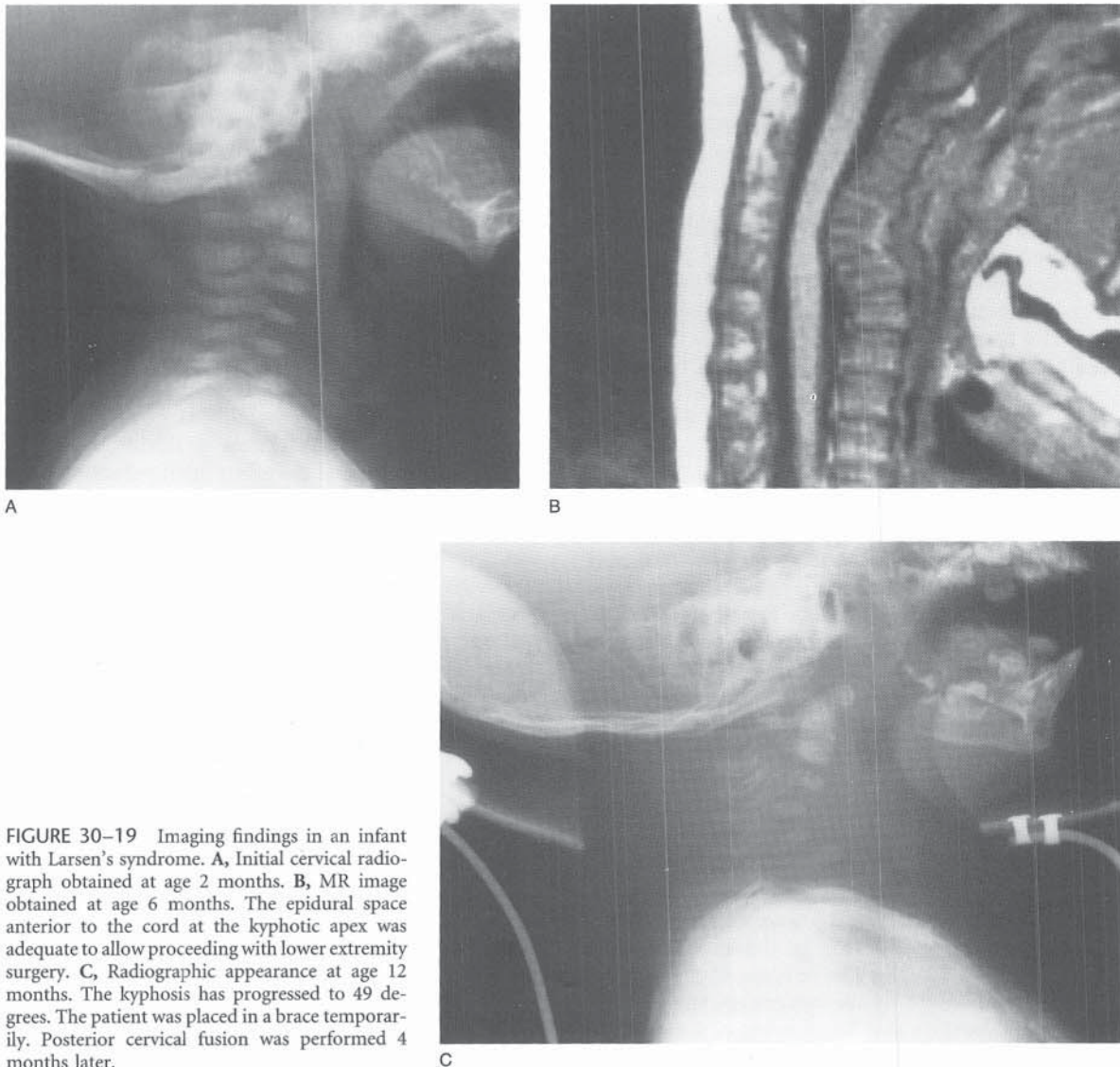


FIGURE 30–19 Imaging findings in an infant with Larsen's syndrome. **A**, Initial cervical radiograph obtained at age 2 months. **B**, MR image obtained at age 6 months. The epidural space anterior to the cord at the kyphotic apex was adequate to allow proceeding with lower extremity surgery. **C**, Radiographic appearance at age 12 months. The kyphosis has progressed to 49 degrees. The patient was placed in a brace temporarily. Posterior cervical fusion was performed 4 months later.

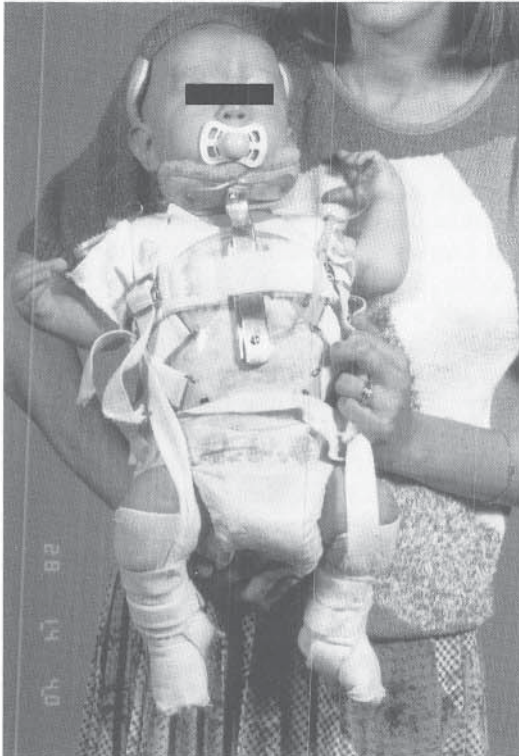

FIGURE 30–20 Simultaneous treatment of dislocated hips and knees with a Pavlik harness in Larsen's syndrome. The patient had recently undergone posterior cervical fusion as well.

Open reduction of congenital dislocation of the knee is probably the second most important operative procedure performed, after cervical spine stabilization, if the patient is to have good functional outcome and ambulatory ability as an adult. The best results are obtained when the knees are reduced by the age of 2.^{2,3,9,24} The traditional treatment of congenital dislocation of the knee involves extensive quadriceps mechanism lengthening to achieve flexion, as well as an anterior arthrotomy to release intra- and extra-articular adhesions preventing knee flexion and to mobilize the patellofemoral joint. However, the end result of an extensive V-Y quadriceps lengthening is a relatively incompetent quadriceps mechanism, producing extensor weakness and poor ambulatory function. If the knee is in addition unstable due to existing ligamentous insufficiency (particularly cruciate), or if extensive intra-articular release is required to achieve reduction, the quadriceps weakness further reduces function, and severe valgus or frank subluxation may result, making the patient brace dependent. Marked instability at the time of reduction, requiring temporary transarticular fixation, is an ominous sign for the later development of valgus, subluxation, and fixed flexion contracture due to re-subluxation of the tibia. In such a clinical scenario, the impaired knee function becomes the most significant disability (Fig. 30–21).

Experience with arthrotomy and *primary* femoral shortening to gain reduction and flexion of the knee has been more encouraging (Fig. 30–22). The purpose of the femoral shortening is to gain length of the quadriceps mechanism without extensive dissection and lengthening of the musculotendon unit itself. With shortening of the femur, the exten-

sion contracture is decompressed, and with a more limited arthrotomy, intra-articular and extra-articular obstructions to reduction of the knee can be released or excised without damage to the suprapatellar quadriceps mechanism itself. The patellofemoral joint can be realigned by extending the arthrotomy proximally on the lateral side of the knee, freeing the patella from its laterally dislocated position and realigning it in its appropriate intercondylar groove, again aided by the femoral shortening. The bony shortening is stabilized by an appropriately small or mini DCP plate. Following bony healing, the knees are splinted in a flexed position and gradually brought to full extension as the child grows and ambulatory status develops.

Late angular deformity, primarily valgus, is common following the earlier knee reduction surgery. If the valgus is associated with marked anterolateral instability, ligamentous reconstruction can be attempted. We have utilized the ilio-tibial band transfer to substitute for the anterior cruciate combined with imbrication of the posteromedial corner to stabilize such knees, with definite short-term improvement. Longer-term resubluxation may occur due to gradual stretching of the ligamentous replacement. As always, any cruciate ligamentous transfer in the immature knee risks growth disturbance of the proximal tibial physis (Fig. 30–22). Bony realignment by varus osteotomy may also be appropriate for valgus alignment. Although not addressing directly the pathologic ligamentous and articular structures, realignment may improve symptomatic valgus adequately by preventing further stretching of medial and posterior capsules.¹⁶

Congenital Dislocation of the Hip. Congenital dislocation of the hip may be amenable to closed treatment in the newborn. Congenital dislocation of the hip may seem teratologic in patients with Larsen's syndrome, but closed reduction and stabilization have been successfully performed. Knee hyperextension and congenital dislocation of the hip can be treated simultaneously in the neonate by means of a Pavlik harness. If hip stability is not achieved with the harness, maintaining the knees in flexion is still beneficial for subsequent formal closed or open reduction of the hips, which will then be immobilized in a spica cast. Knee flexion obviously is helpful in applying an appropriate spica cast.

Failure to achieve closed reduction should not be unexpected. The dislocations are teratologic in many instances, and one attempt at anterior open reduction and capsulorrhaphy should be planned if teratologic dislocation persists following closed treatment in infancy. Because hyperlaxity is usually a contributor to the hip instability, capsulorrhaphy should be planned, and this is best done through a traditional anterior ilioinguinal approach. We have no experience with medial open reduction without capsulorrhaphy in patients with Larsen's syndrome.

Anterior open reduction and capsulorrhaphy of the hip is best performed around the age of 1, and if both ipsilateral knee and hip are dislocated, the surgical treatment of both joints in the same extremity should be combined. Because femoral shortening may be required to achieve a stable hip reduction without risking avascular necrosis, we have performed a middiaphyseal femoral shortening to aid reduction simultaneously of both the hip and knee (Fig. 30–22). Both

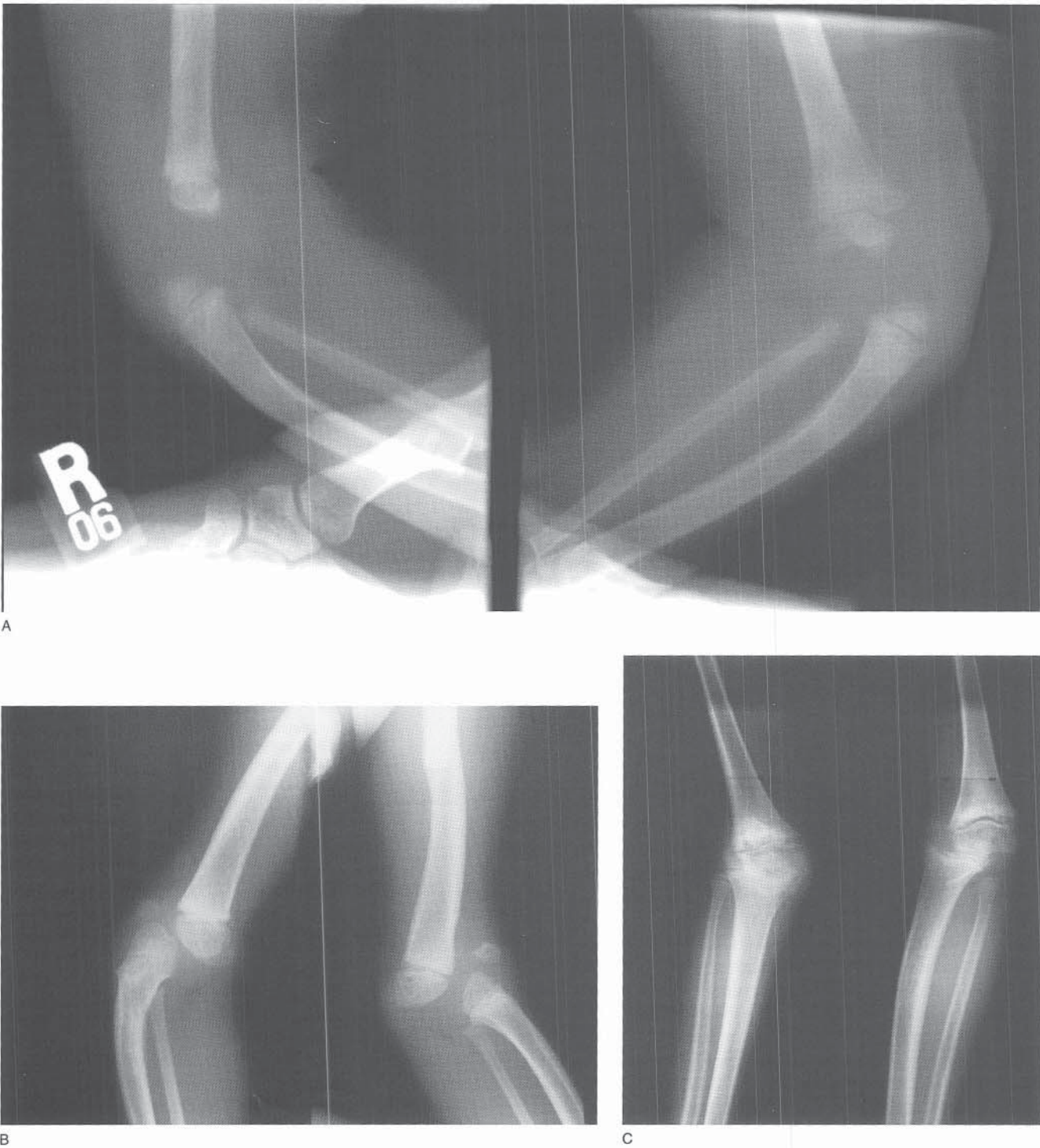


FIGURE 30-21 Larsen's syndrome. **A**, Following bilateral open reduction of dislocated knees at age 14 months, both tibias have resubluxated anteriorly due to incomplete release and decompression by femoral shortening. **B**, Two years later, frank dislocations are present in spite of bracing. Quadriceps function was good, and further surgery was refused. **C**, By age 11, unstable dislocated knees required full-time bracing, and function was poor.

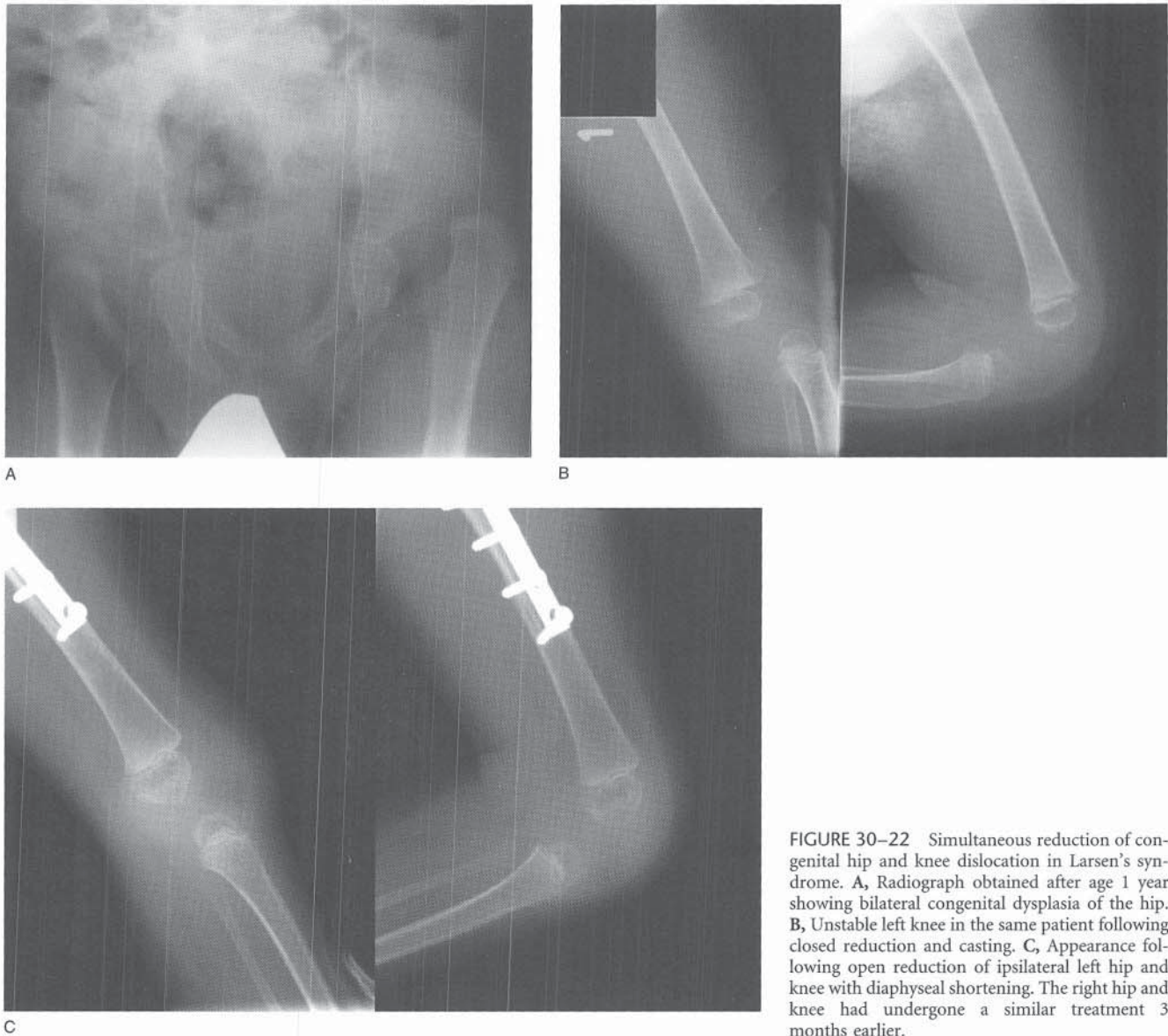
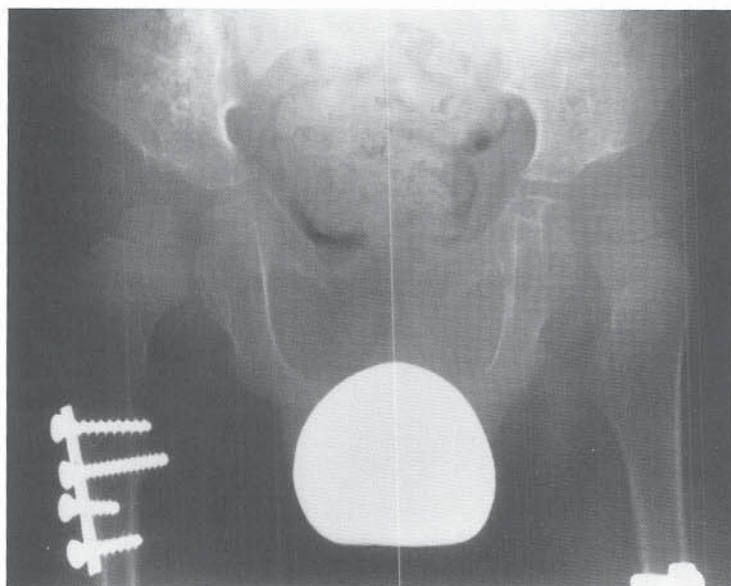


FIGURE 30-22 Simultaneous reduction of congenital hip and knee dislocation in Larsen's syndrome. **A**, Radiograph obtained after age 1 year showing bilateral congenital dysplasia of the hip. **B**, Unstable left knee in the same patient following closed reduction and casting. **C**, Appearance following open reduction of ipsilateral left hip and knee with diaphyseal shortening. The right hip and knee had undergone a similar treatment 3 months earlier.

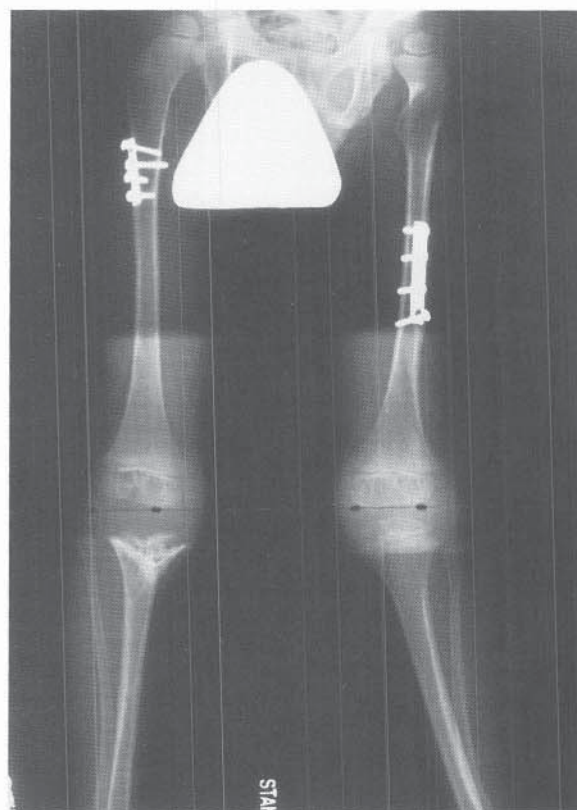
joints of the same extremity undergo open reduction, aided by the diaphyseal shortening. With the knee flexed, the quadriceps realigned, and the incision closed, clearing of the acetabulum, capsulorrhaphy, and wound closure of the hip follow. The involved extremity is then immobilized in a spica cast for an appropriate period of time, and the contralateral extremity with one or both joints dislocated can be approached in 2 to 3 months. Simultaneous reduction of both the hip and the knee, aided by a single diaphyseal femoral shortening, has proved to be the most efficacious method of achieving joint reduction with a minimum of surgical procedures (Fig. 30-22).

If a patient presents late with dislocated hips or if open reduction has failed, leaving the hips unreduced is a viable option. Indeed, Larsen and colleagues did not treat the dislocated hips in some of their patients because of the excellent motion and absence of hyperlordosis.¹²

Foot Deformities. Foot deformities in Larsen's syndrome usually include equinovarus or equinovalgus position of the foot. In order of priority of treatment, foot deformities are usually addressed after the knee and hip have been stabilized, and, as with other congenital foot problems involving significant equinus, waiting until the patient is ambulatory and fully weightbearing is beneficial in helping to maintain correction. Although operative treatment is frequently required for equinovarus deformities, it is not unreasonable to attempt closed correction with casting or other stretching techniques during the treatment period for hip and knee joints. The equinus of Larsen's syndrome tends to be quite resistant, however, and judicious tendo Achillis lengthening and posterior release will likely be required to achieve a plantigrade foot. Because of the overall ligamentous laxity, caution is recommended on releasing other components of the clubfoot, as hyperpronated/valgus overcorrection is



D



E

FIGURE 30–22 *Continued.* D, Hip reduction 2 years postoperatively. E, Appearance 5 years postoperatively. The left knee is unstable and has subluxated into valgus and recurvatum. The right knee was treated by cruciate ligament reconstruction and posteromedial capsular imbrication 2 years later, and is stable but has suffered proximal tibial growth arrest.

common. An apparently rigid clubfoot in an infant may later become pathologically flexible. Minimal release of the equinus and hindfoot varus in the 1-year-old who has completed treatment for other joint dislocations may be all that is required.

Equinovalgus deformities may not require treatment at all, or may simply require a tendo Achillis lengthening.¹⁴ Patients with Larsen's syndrome also tend to develop serpentine or Z-foot deformities, in which hindfoot valgus is combined with forefoot adductus (Fig. 30–23). Because of the ligamentous laxity, therapeutic intervention is rarely required, and supportive shoe wear or orthotics may be all that is needed. On occasion it may be necessary to correct the hyperpronated portion of the deformity by hindfoot stabilization. Because of the ligamentous laxity, the feet of patients with Larsen's syndrome frequently appear to have significant deformity in the weightbearing position but remain asymptomatic (Fig. 30–23).

Congenital Dislocation of the Elbow or Radial Head.

Congenital dislocation of these structures is a fairly frequent finding in patients with Larsen's syndrome but rarely requires treatment (see Fig. 30–16).¹⁶ Patients with radial head dislocation are treated as any other patient with this congenital dislocation: excision of the radial head is performed at maturity in the patient who is symptomatic. The arms remain functional, with an adequate range of motion of the elbow, and thus the skeletal anomaly is generally ignored. In the more severe humeroulnar dislocations, the deformity would appear to require treatment, in that the elbows are frequently in a flexed position, with webbing and significant

contracture (see Fig. 30–16).¹⁷ Because of the bizarre absence of the distal humerus in these patients, treatment has generally been declined, owing to the inability to restore a normal articulation by open reduction. Proximal radioulnar synostosis, although reported in two-thirds of the patients in Laville's series,¹⁴ is an uncommon elbow abnormality, again with little therapeutic implication because of lack of symptoms or functional impairment.

Scoliosis. Scoliosis in patients with Larsen's syndrome manifests at a later age and is treated like any other juvenile onset idiopathic deformity, with one caveat. Because of the plasticity of the thoracic cage and the laxity of the costochondral joints, bracing for scoliosis in this patient population must be prescribed with caution, for the chest wall could be significantly deformed with scoliosis pads. As with other patients with hyperlaxity, there may be an absolute thoracic lordosis that contraindicates bracing. Scoliosis has been reported in 25 to 70 percent of patients with Larsen's syndrome,^{14,16} with approximately half of the patients subsequently undergoing operative stabilization. Because of the earlier onset of the deformity, most patients with Larsen's syndrome will require anterior and posterior fusion to eliminate the crankshaft phenomenon. In patients with sagittal imbalance caused by cervical kyphosis, the lordosis of the thoracic deformity caused by a cervical kyphosis above may be an incipient feature which then allows the scoliosis to progress (Fig. 30–24). As with any juvenile onset deformity, the condition can progress rapidly and dramatically. Fusion of a progressive scoliosis is recommended as soon as the deformity exceeds 60 degrees.

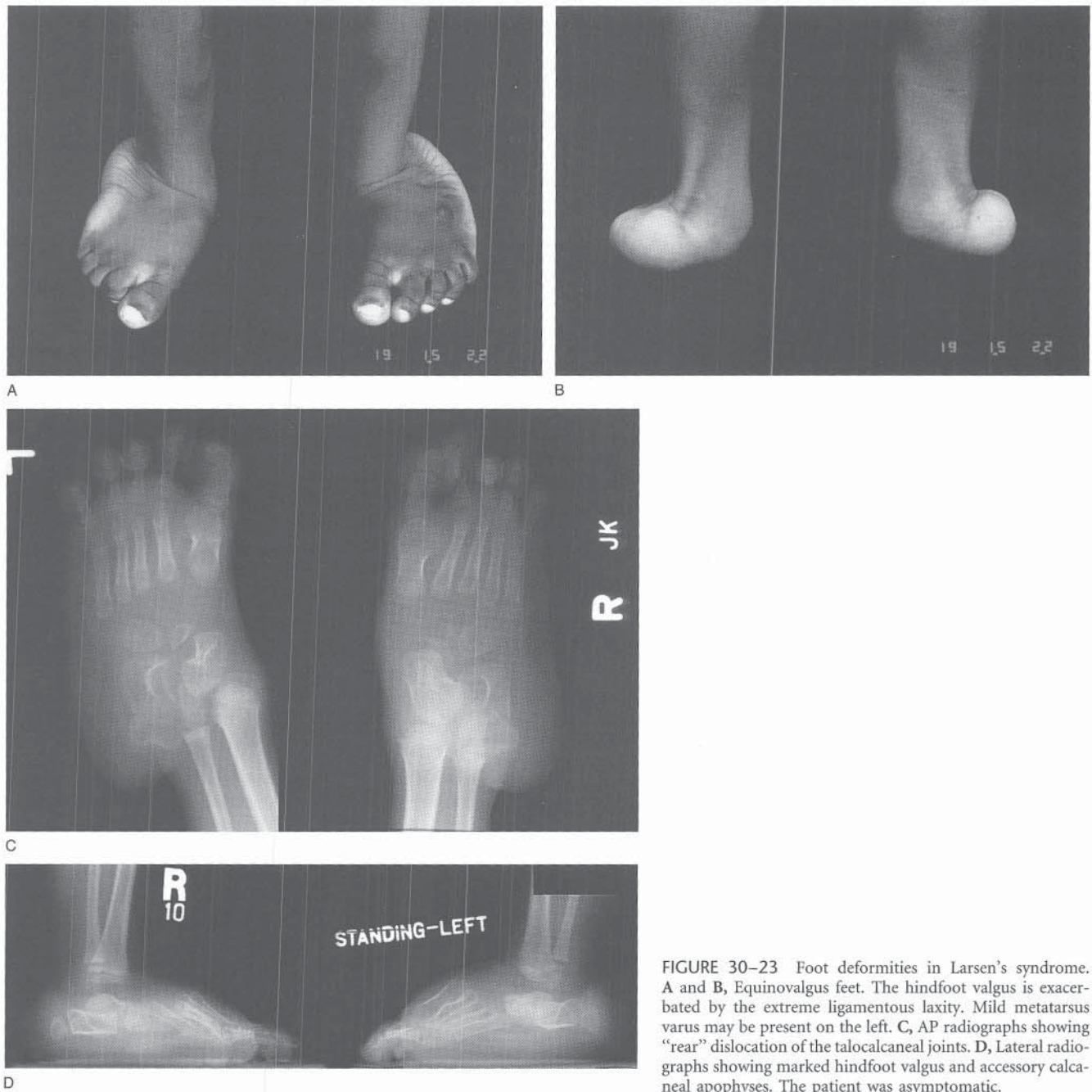

FIGURE 30-23 Foot deformities in Larsen's syndrome. A and B, Equinovalgus feet. The hindfoot valgus is exacerbated by the extreme ligamentous laxity. Mild metatarsus varus may be present on the left. C, AP radiographs showing "rear" dislocation of the talocalcaneal joints. D, Lateral radiographs showing marked hindfoot valgus and accessory calcaneal apophyses. The patient was asymptomatic.

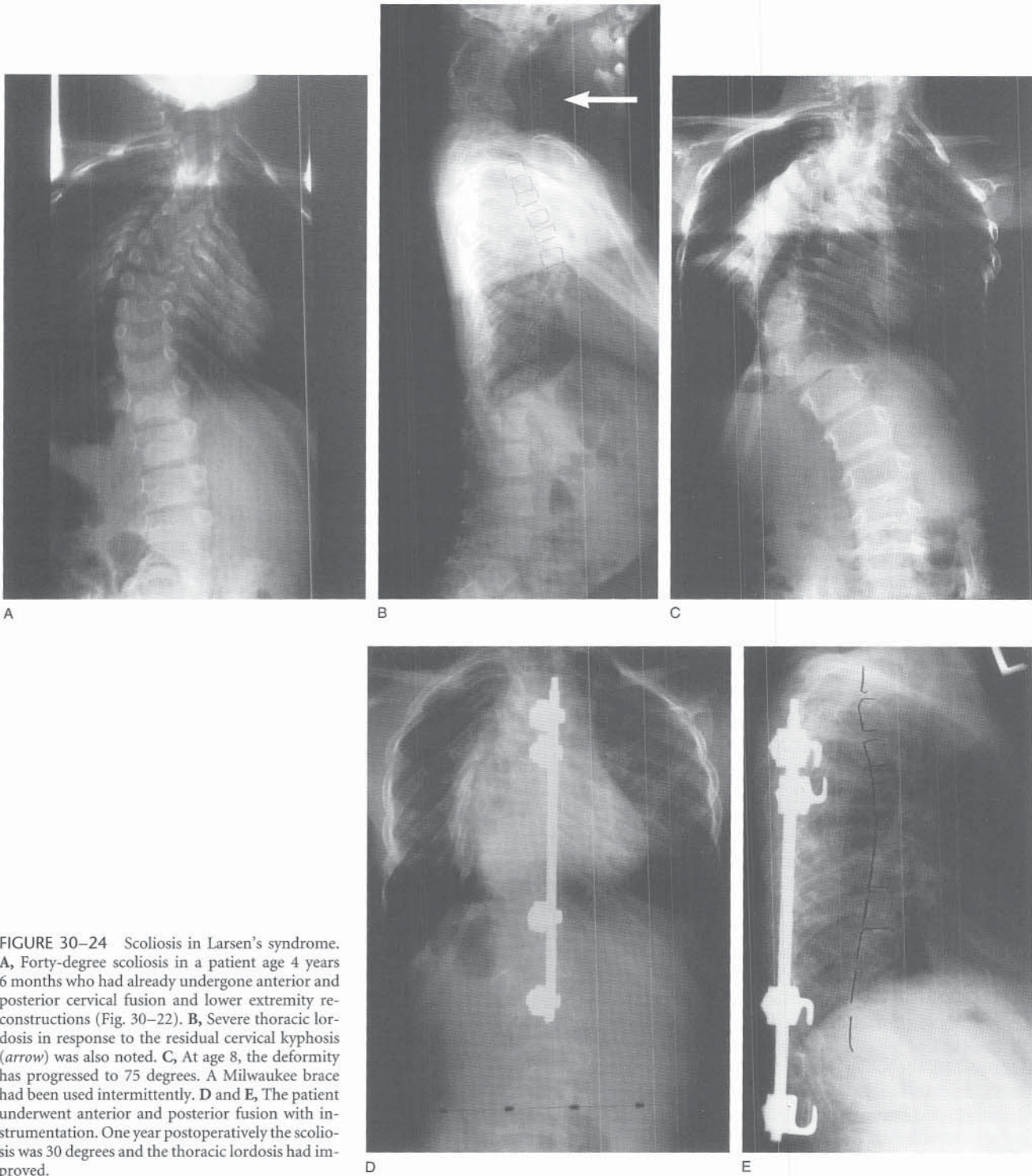


FIGURE 30-24 Scoliosis in Larsen's syndrome. **A**, Forty-degree scoliosis in a patient age 4 years 6 months who had already undergone anterior and posterior cervical fusion and lower extremity reconstructions (Fig. 30-22). **B**, Severe thoracic lordosis in response to the residual cervical kyphosis (*arrow*) was also noted. **C**, At age 8, the deformity has progressed to 75 degrees. A Milwaukee brace had been used intermittently. **D** and **E**, The patient underwent anterior and posterior fusion with instrumentation. One year postoperatively the scoliosis was 30 degrees and the thoracic lordosis had improved.

Cervical spondylolisthesis or hyperlordosis may present in the older child or adolescent. The deformity may be clinically apparent, with a progressively protruding jaw, or the child may present with neck pain (Fig. 30-25). Spondylolisthesis at C6-7 or C7-T1 has been noted in younger children, associated with the pars defects and incomplete posterior elements of the cervical spine in Larsen's syndrome

(see Chapter 12, Kyphosis). The spondylolisthesis generally does not progress and may be asymptomatic in the adolescent. On the other hand, late presentation of cervicothoracic spondylolisthesis with symptoms may require fusion (Fig. 30-25B). Hyperlordosis per se has not required treatment unless there is dural impingement from posteriorly, as has been seen in one patient who grew into hyperlordosis after

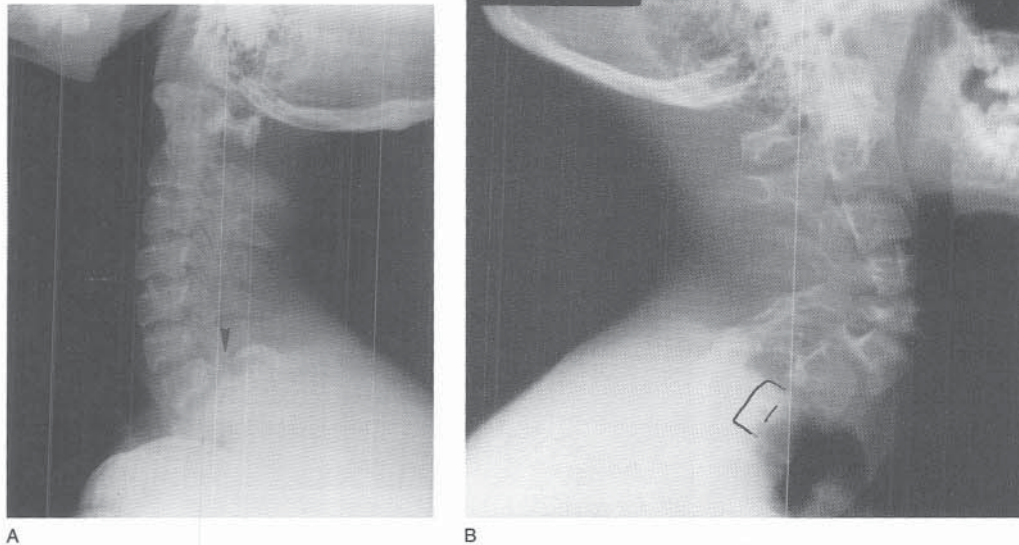


FIGURE 30-25 Spondylolisthesis in Larsen's syndrome. **A**, Radiograph of a 15-year-old boy with spondylolysis at C7-T1 (arrowhead). The patient had been followed for a presumed potential instability at C1-2, when the hypoplastic ring of C1 and the synostosis of C2-3 were observed at an early age. No instability ever developed. The spondylolysis was asymptomatic. **B**, Radiograph of an 18-year-old man with progressive throat protrusion and neck pain showing spondylolisthesis at C6-7 and C7-T1. There was no neurologic deficit. Symptomatic relief with a four-poster brace was achieved, but more definitive stabilization is likely to be required.

having undergone fusion 11 years earlier for kyphosis (see Chapter 10, Disorders of the Neck).

SUMMARY

Patients with Larsen's syndrome usually require treatment for multiple orthopaedic deformities, which must be identified, prioritized, and managed in a staged fashion. Optimal outcome depends on, in order of importance, stabilization of cervical kyphosis and prevention of chronic myelopathy; stable reduction of congenital knee dislocation(s) with quadriceps muscle-sparing surgery (i.e., femoral shortening); reduction of congenital hip dislocation(s) with maintenance of good range of motion and functional hip musculature; and creation of plantigrade feet. Scoliosis may have to be addressed in the older child, while upper extremity (i.e., elbow) deformities have generally not required treatment. Mistaking syndromic hypotonicity for the more sinister cervical myelopathy in the infant and young child should be avoided now that the predilection for cervical kyphosis in Larsen's syndrome is known.

REFERENCES

Larsen's Syndrome

- Bellon JM, Filipe G: Problemes rachidiens rencontres au cours syndrome de Larsen: a propos de 3 cas. *Rev Chir Orthop* 1987;73:57.
- Bensahel H, Dal Monte A, Hjelmstedt A, et al: Congenital dislocation of the knee. *J Pediatr Orthop* 1989;9:174.
- Curtis BH, Fisher RL: Congenital hyperextension with anterior subluxation of the knee: surgical treatment and long-term observations. *J Bone Joint Surg* 1969;51-A:255.
- Francis WR Jr, Noble DP: Treatment of cervical kyphosis in children. *Spine* 1988;13:883.
- Goldberg MJ: Syndromes of orthopaedic importance. In Morrissy RT, Weinstein SL (eds): *Lovell and Winter's Pediatric Orthopaedics*, p 265. Philadelphia, Lippincott-Raven, 1996.
- Habermann ET, Sterling A, Dennis RI: Larsen's syndrome: a heritable disorder. *J Bone Joint Surg* 1976;58-A:558.
- Harris R, Cullen CH: Autosomal dominant inheritance in Larsen's syndrome. *Clin Genet* 1971;2:87.
- Iwaya T, Sakaguchi R, Tsuyama N: The treatment of congenital dislocation of the knee with the Pavlik harness. *Int Orthop* 1983;7:25.
- Johnson E, Audell R, Oppenheim WL: Congenital dislocation of the knee. *J Pediatr Orthop* 1987;7:194.
- Johnston CE II, Birch JG, Daniels JL: Cervical kyphosis in patients who have Larsen syndrome. *J Bone Joint Surg* 1996;78-A:538.
- Kiel EA, Frias JL, Victorica BE: Cardiovascular manifestations in the Larsen syndrome. *Pediatrics* 1983;71:942.
- Larsen LJ, Schottstadt ER, Bost FC: Multiple congenital dislocations associated with characteristic facial abnormality. *J Pediatr* 1950;37:574.
- Latta RJ, Graham CB, Aase J, et al: Larsen's syndrome: a skeletal dysplasia with multiple joint dislocations and unusual facies. *J Pediatr* 1971;78:291.
- Laville JM, Lakermance P, Limouzy F: Larsen's syndrome: review of the literature and analysis of thirty-eight cases. *J Pediatr Orthop* 1994;14:63.
- Lefort G, Mourad H, de Niscault G, et al: Dislocation du rachis cervical supérieur dans le syndrome de Larsen. *Chir Pediatr* 1983;24:211.
- Lubicky JP, Herman J: Clinical review of patients with Larsen's syndrome. Unpublished data, 2000. Shriner's Hospital for Children, Department of Orthopaedics, Chicago, IL.
- Lutter LD: Larsen syndrome: clinical features and treatment. A report of two cases. *J Pediatr Orthop* 1990;10:270.
- McKusick V: *Heritable Disorders of the Connective Tissue*, p 344. St. Louis, CV Mosby Co, 1972.
- Micheli LJ, Hall JE, Watts HG: Spinal instability in Larsen's syndrome: report of three cases. *J Bone Joint Surg* 1976;58-A:562.
- Muzumdar AS, Lowry RB, Robinson CE: Quadriplegia in Larsen syndrome. *Birth Defects Orig Artic Ser* 1977;13:202.
- Nogi J, MacEwen GD: Congenital dislocation of the knee. *J Pediatr Orthop* 1982;2:509.

22. O'Herlihy C, O'Brien N: Neonatal stridor with Larsen's syndrome. *Israel J Med Sci* 1977;13:912.
23. Oki T, Terashima Y, Murachi S, et al: Clinical features and treatment of joint dislocations in Larsen's syndrome: report of three cases in one family. *Clin Orthop* 1976;119:206.
24. Ooishi T, Sugioka Y, Matsumoto S, et al: Congenital dislocation of the knee: its pathologic features and treatment. *Clin Orthop* 1993;287:187.
25. Rock MJ, Green CG, Pauli RM, et al: Tracheomalacia and bronchomalacia associated with Larsen syndrome. *Pediatr Pulmonol* 1988;5:55.
26. Ronningen H, Bjerkreim I: Larsen's syndrome. *Acta Orthop Scand* 1978;49:p138.
27. Steel HH, Kohl EJ: Multiple congenital dislocations associated with other skeletal anomalies (Larsen's syndrome) in three siblings. *J Bone Joint Surg* 1972;54-A:75.
28. Strisciunglio P, Sebastio G, Andria G, et al: Severe cardiac anomalies in sibs with Larsen syndrome. *J Med Genet* 1983;20:422.
29. Swenson RE, Linnebur AC, Paster SB: Striking aortic root dilatation in a patient with the Larsen syndrome. *J Pediatr* 1975;86:914.
30. Uhthoff HK, Ogata S: Early intrauterine presence of congenital dislocation of the knee. *J Pediatr Orthop* 1994;14:254.

Apert's Syndrome

Apert's syndrome is one of a group of relatively rare deformities known as the acrocephalosyndactyly syndromes. In 1906, Eugene Apert described a group of children who had "a very high skull, flattened at the back and sometimes on the sides, while the upper frontal region bulges and syndactyly in all four limbs."¹ Apert's syndrome is the most common acrocephalosyndactyly syndrome to be seen by the pediatric orthopaedic hand surgeon.³

Although the condition is said to be autosomal dominant, it is almost always the result of a spontaneous genetic mutation, since affected individuals rarely have offspring. Lack of reproduction is likely due to the cosmetic aspect of their severe facial anomalies, which until modern times could not be reconstructed. The condition occurs in 1 in 100,000 (or more) live births.³ Upton feels strongly that at least initially, affected children are normal mentally, and that modern craniofacial reconstruction throughout childhood can yield a normal functioning brain. Historically, many of these unfortunate people were institutionalized and their intellectual potential was never realized. Even today, about half require some special assistance in school.

CLINICAL MANIFESTATIONS

There are striking and characteristic facial features caused by (1) premature closure of the basal portions of the coronal and frequently the lambdoidal sutures, (2) shallow orbits, causing a bulging-eyed appearance (exophthalmos), and (3) failure of forward growth of the maxilla, which results in a parrot-beaked nose, high-arched palate, and crowding of maxillary teeth and tongue (the latter can lead to upper airway difficulties). Other than the musculoskeletal anomalies, there are no other associated abnormalities in these children.

The musculoskeletal anomalies are most apparent in the hands and feet. These deformities include symmetric, complex, and complicated syndactyly. Skeletal dysplasia of the glenohumeral joint and occasionally of the elbow joint can also limit the positioning of these severely deformed hands.

The hand deformity is variably severe, but two general hand patterns exist: the less severely affected, flat or "spade-

like" hand, and the more severely affected, cupped or "spoonlike" hand. Common to both patterns are (1) short, radially deviated thumbs with a delta-shaped proximal phalanx, (2) a complex osseous syndactyly of index, long, and ring fingers, (3) symphalangism with little or no interphalangeal motion of the fingers, (4) a simple cutaneous syndactyly in the fourth web space, and (5) a less severely affected fifth digit. The fifth ray is the most normal digit these children have; the metacarpal and distal interphalangeal joints are usually functional, but a functioning proximal interphalangeal joint is lacking. A proximal IV–V metacarpal synostosis is frequently present that limits the opposition of this "best digit" with the thumb.

TREATMENT

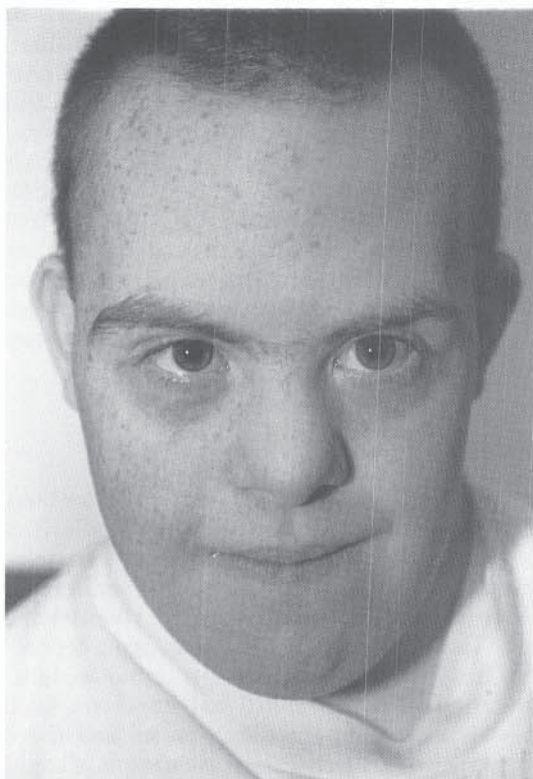
The early treatment of hand deformities is essential for these children. It is most important to coordinate the efforts of the craniofacial team with the pediatric hand surgeon, since the treatment of both head and hand anomalies must begin in infancy. The long-term outcome for these children and their ability to function independently as an adult depends on protecting their brains with appropriate craniofacial surgery and restoring whatever limited but important hand function can be restored by carefully planned and timed hand surgery early in life. Psychological evaluations of adults with this condition show self-esteem, sense of mastery, and competence to be highly correlated with hand function.²

The surgical reconstruction of the hands involves complicated decision making that centers on (1) developing the best possible thumb-index web space, (2) mobilizing the "best digit" (always located on the ulnar border of these hands), and (3) decision making regarding the optimum number of digits to reconstruct from the remaining II, III, IV synostotic digital mass. Hand surgery on these children should be done in centers where teams of surgeons can begin the reconstruction as early as possible and carry out bilateral hand procedures, often beginning before age 1. The challenging goal is to provide the child with useful hands, with the bulk of the hand reconstruction completed by the time the child enters school at age 5. The details of this treatment are beyond the scope of this book and out of the realistic realm of most general pediatric orthopaedic and hand surgeons. These children should be referred to centers where their anesthetic, craniofacial, and hand surgery challenges are managed on a more routine basis. A recent publication by Van Heest, House, and Reckling goes into the details of decision making and provides an excellent bibliography for further reading.⁴

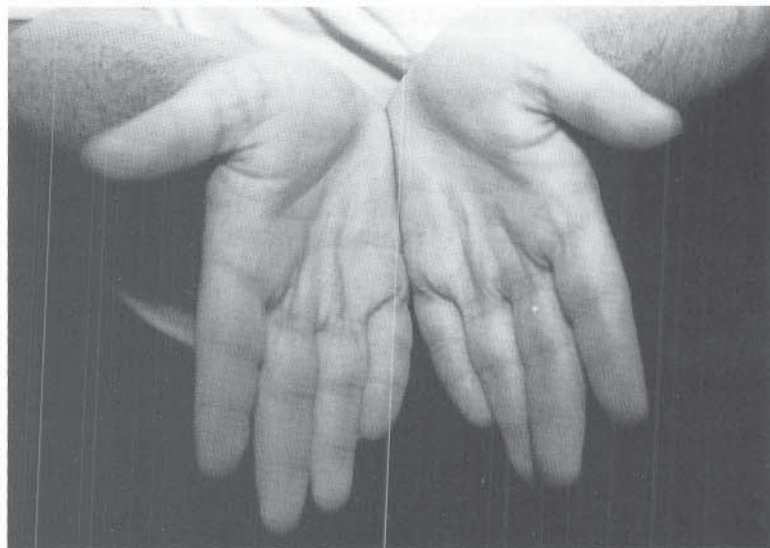
REFERENCES

Apert's Syndrome

1. Apert E: Apert syndrome. In Buck-Gramcko D (ed): *Congenital Malformations of the Hand and Forearm*, p 159. New York, Churchill Livingstone, 1998.
2. Belfer ML, Harrison AM, Murray JE: Body image and the process of reconstructive surgery. *Am J Dis Child* 1979;133:532.
3. Upton J: Apert's syndrome. In McCarthy J (ed): *Plastic Surgery*, vol 8, p 5293. Philadelphia, WB Saunders Co, 1990.
4. Van Heest AE, House JH, Reckling WC: Two-stage reconstruction of Apert acrosyndactyly. *J Hand Surg* 1997;22-A:315.



A



B

FIGURE 30–26 Clinical appearance of a 14-year-old boy with Down syndrome. A, Note the characteristic flat face with slanted palpebral fissures. B, His hands are short and broad, with the appearance of clinodactyly in the little finger.

Down Syndrome (Trisomy 21)

INTRODUCTION

Down syndrome is the most frequent and most readily recognizable trisomy occurring in humans. It was reported in 1866 by J. L. Down, who remarked that “a large number of congenital idiots are typical mongols.”¹⁶ As recently as the 1970s, patients with this syndrome were referred to as mongoloid. It was not until 1959 that Lejeune and Turpin identified an extra chromosome 21 as the cause of this condition.²¹ All affected individuals have, in some form, three copies of this chromosome. Most (nearly 95 percent) have three free-standing copies, or *full 21 trisomy*. Approximately 4 percent of affected individuals have a *translocation* involving chromosome 21. The majority of these translocations exist as fusions at the centromere between chromosomes 13, 14, 15, or 21 t(21q;21q). For children born of mothers younger than 30 years of age, the incidence of translocation is slightly higher (6 to 9 percent of affected children).^{21,26} Because of this possibility, chromosome studies should be done on every Down syndrome individual. If a translocation is identified, parental studies should be done to identify which normal-appearing parent is the translocation carrier. This individual can then be counseled about the higher risk of bearing future chromosomally abnormal offspring. The remaining 1 percent of patients with Down syndrome are *mosaic*, with some normal cells.

Recent genetic studies have further localized the abnormal regions on chromosome 21.^{12,13,51} Many of the features attributable to Down syndrome are found in the region D21S55, or Down syndrome chromosome region (DCR),

located on Q22.2 or the very proximal Q22.3. Further genetic research is expected to provide greater insight into the abnormal regions on chromosome 21 responsible for the numerous abnormalities seen in Down syndrome.

More than half of trisomy 21 conceptions abort early in pregnancy. Nevertheless, the overall incidence is 1 in 600 to 800 live births.²¹ The incidence increases with increasing maternal age at the time of delivery: it is 1 in 1,500 at ages 15 to 29 years, 1 in 800 at ages 30 to 34 years, 1 in 270 at ages 35 to 39 years, 1 in 100 at ages 40 to 44 years, and 1 in 50 at age 45 and older.²⁶

Recommendations for prenatal screening for Down syndrome continue to evolve.⁹ During pregnancy, the maternal serum alpha-fetoprotein concentration is lower, unconjugated estriol decreases, and human chorionic gonadotropin increases in the presence of a trisomy 21 fetus. A fourth biochemical assay screening test, serum inhibin measurements, has also been found useful. Ultrasonography provides further noninvasive information. If the results of these tests indicate an increased risk of Down syndrome, particularly in women over 35 years of age, it is reasonable to consider amniocentesis and chromosome analysis.

CLINICAL FEATURES

The prominent clinical features seen in Down syndrome include hypotonia, a flat face with upward and slanted palpebral fissures or epicanthic folds, a tendency to keep the mouth open with the tongue protruding, hyperlaxity leading to hyperflexibility of joints, relatively small stature with an awkward gait, varying degrees of mental retardation, a high-arched palate, short, broad hands with a simian crease, and

a hypoplastic middle phalanx of the fifth finger, leading to a clinodactyly appearance (Fig. 30–26). Other less evident findings include speckled irides, intestinal atresia, cardiac malformations, and radiographically demonstrated dysplasia of the pelvis.

Over time, muscle tone tends to improve, but joint hyperlaxity remains. Improvement in mental development slows with increasing age, and the mean IQ of older patients is 24. The social performances of children with Down syndrome usually extend beyond their mental age.

Physical growth is slow, and development of the secondary centers of ossification is often delayed. Thyroid dysfunction is common but often not readily noticeable. This should lead the primary caretaker to periodically undertake thyroid function studies.

The major cause of early mortality in Down syndrome is congenital heart disease. With continued improvements in surgical care for congenital heart defects, survival has been

increasing. Nevertheless, life expectancy remains shorter for those with congenital heart defects than for those without.

ORTHOPAEDIC ASPECTS AND TREATMENT

Instability of the Upper Cervical Spine in Down Syndrome. Atlantoaxial (C1–2) instability, first described nearly 40 years ago, continues to be the primary orthopaedic concern in individuals with Down syndrome. A study of 404 patients with Down syndrome reported an incidence of 14.6 percent (13.1 percent were asymptomatic, 1.5 percent produced neurologic symptoms).³⁹ Others report incidences ranging from 9 percent to 31 percent.^{30,38,43,45,47} The diagnosis is confirmed with measurements taken from lateral radiographs of the upper cervical spine obtained in flexion, extension, and neutral position (Fig. 30–27). The atlanto-dens interval (ADI) is measured in millimeters. This is the shortest distance between the posterior aspect of the anterior arch

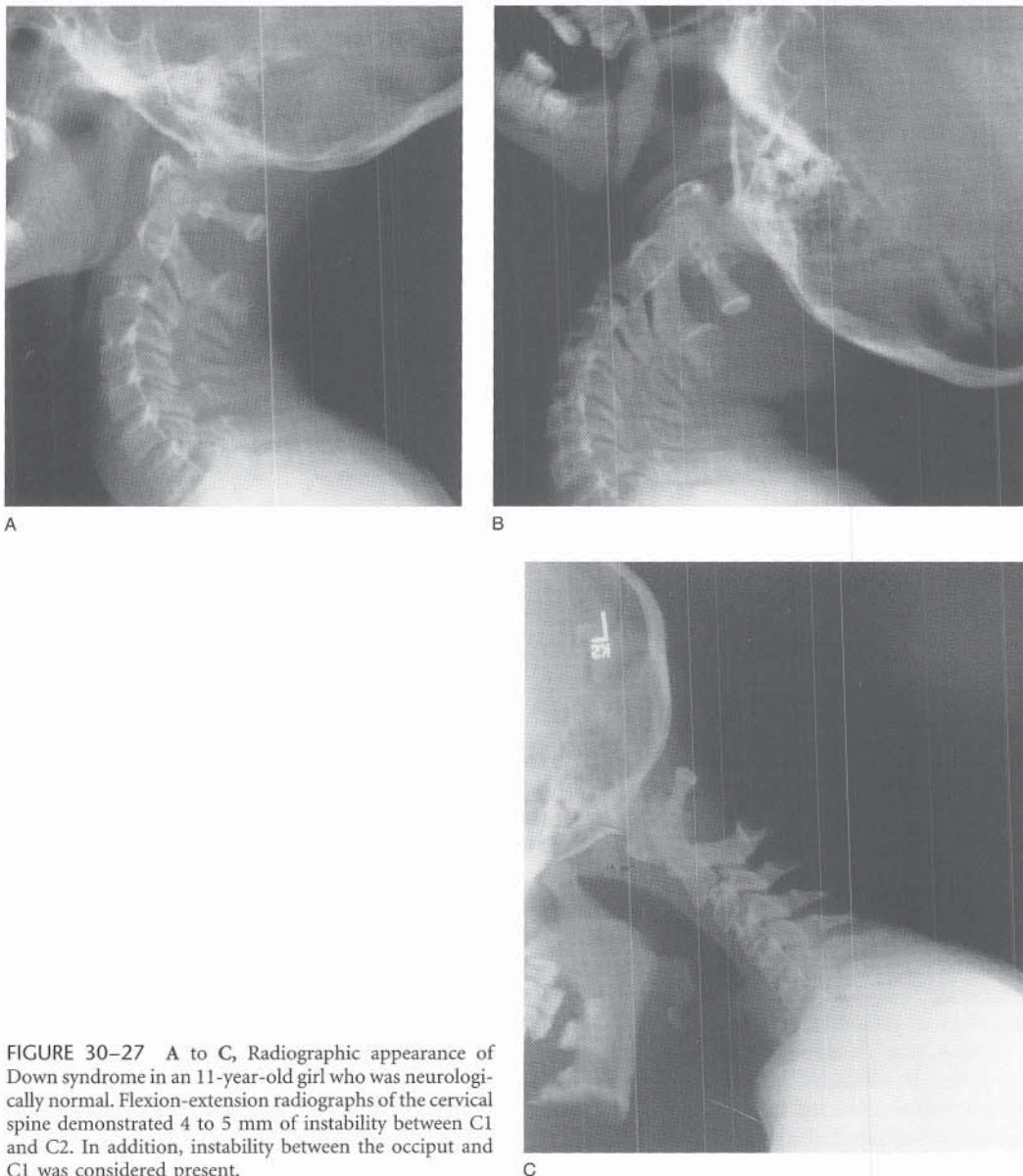


FIGURE 30–27 A to C, Radiographic appearance of Down syndrome in an 11-year-old girl who was neurologically normal. Flexion-extension radiographs of the cervical spine demonstrated 4 to 5 mm of instability between C1 and C2. In addition, instability between the occiput and C1 was considered present.

of C1 and the adjacent anterior aspect of the odontoid process of C2. If this interval is 5 mm or greater, atlantoaxial instability is considered to be present.^{37,40} Instability is usually best demonstrated on the lateral radiograph obtained during flexion. CT can show additional specific skeletal anomalies of the C1–2 region but is not necessary in screening for instability.³⁶

The neurologic manifestations of symptomatic atlantoaxial instability may be difficult to identify. Subtle findings may include easy fatigability, difficulties in walking, abnormal gait, neck pain, limited neck mobility, torticollis or head tilt, incoordination, and clumsiness. More definite findings include sensory deficits, spasticity, hyperreflexia, clonus, extensor plantar reflex, and other motor neuron and posterior column signs and symptoms. These signs and symptoms often remain stable for months or years. Occasionally, they progressively worsen. Trauma rarely is responsible for the initial appearance or progression of these symptoms. At the present time, no studies have been able to provide helpful information to identify asymptomatic patients at risk for developing neurologic symptoms.

The atlantoaxial instability is due primarily to laxity of the transverse ligament of C1 and joint capsules. This localized laxity does not necessarily correlate with patients' generalized ligamentous laxity.¹⁰ In addition, abnormal development of the odontoid process of C2 (such as persistent synchondrosis, ossiculum terminale, or hypoplasia) may predispose the individual to instability.³⁷ The reported prevalence of odontoid dysplasia approximates 7 percent, but this figure may underestimate the actual frequency of odontoid dysplasia, because most screening studies involve only lateral radiographs of the upper cervical spine.^{37,43} If AP radiographs and other imaging procedures were also obtained, more skeletal anomalies would likely be detected in the C1–2 region. Children with Down syndrome and atlantoaxial instability are more likely to have spina bifida of C1 than those without instability.

Special Olympics. Orthopaedists and pediatricians are often asked to evaluate children with Down syndrome prior to them becoming eligible to participate in the Special Olympics. In 1983, the Special Olympics organization introduced a requirement that lateral neck radiographs be obtained before individuals with Down syndrome would be allowed to participate in the nationwide Special Olympics competitive program. Down children with radiographic evidence of C1–2 instability were then excluded from certain activities which were thought at the time to be associated with an increased risk of injury to the cervical spine. In 1984, the American Academy of Pediatrics (AAP) published a position statement that supported the Special Olympics' requirement.¹ However, at present, participation in sports by the asymptomatic child with atlantoaxial instability has not been shown to be a significant risk factor for the development of neurologic symptoms.¹¹ Based in part on this information, the AAP Committee on Sports Medicine and Fitness decided that there is insufficient evidence supporting the value of cervical spine radiographs in screening for possible catastrophic neck injuries in children with Down syndrome, and in 1995 the committee retracted its statement of support for routine screening for Special Olympics.² The Special Olympics has not removed its requirement that radiographs

of the cervical spine be obtained in all athletes with Down syndrome prior to participation. Therefore, orthopaedists and pediatricians will continue to be called on to order these tests.

The arguments for continued screening of patients with Down syndrome include the theoretical possibility of preventing the rare occurrence of sports-related catastrophic spinal cord injury among individuals with asymptomatic instability. Another purpose is to identify the rare, previously unrecognized patient with symptomatic instability. Arguments *against* screening include the rarity of symptomatic instability, inaccuracy of the screening test, the fact that some patients with abnormal radiographs initially will have normal radiographs later on,³³ and the absence of evidence that a screening program is effective in preventing symptomatic disease. Screening is also expensive, which may prevent some individuals from being able to participate in the Special Olympics.²

Occipital-Atlantal Instability. Over the past 20 years there has been an increased awareness that instability that can also exist at the occipital-atlantal joint.^{7,18,31,48,50} This finding was first reported in 1981 by Hungerford, who described a case of combined atlantoaxial instability with neurologic compromise.²⁵

The radiographic diagnosis of instability is much more difficult to make at the occipital-atlantal joint than at the C1–2 level. The reported incidence of occipital-atlantal hypermobility has ranged from 8.5 percent³⁴ to 71 percent of patients with Down syndrome, reflecting the considerable variation in techniques used to measure instability at the occiput–C1 level.²⁷ Three popular techniques used to measure this instability are the Powers ratio,³⁵ the Weisel-Rothman technique,⁵² and the basion-axial interval (BAI) (Fig. 30–28).²² The advantage to using the Powers ratio is that it is not influenced by radiographic magnification; it is a ratio rather than a direct measurement. In addition, because the Powers ratio is not referenced off the axis (C2), any accompanying atlantoaxial instability will not affect its value. Unfortunately, accurate localization of the opisthion, one of the necessary radiographic landmarks, is difficult and negatively affects the reproducibility and measurement of the Powers ratio. The Weisel-Rothman technique for establishing abnormal motion of the occipital-atlantal joint appears to be the most reproducible on lateral radiograph measurements.²⁷ The BAI method is not applicable to children with Down syndrome because it does not account for the multilevel instability that is so often seen in this patient population. Ultimately, in the neurologically symptomatic patient, the clearest picture of instability and spinal cord compression will be obtained with MRI.

It is important to be aware that hypermobility in the upper cervical spine in Down syndrome can occur simultaneously in both the occipital-atlantal joint and the atlantoaxial joint.⁴⁸ If an increase in motion is seen radiographically between the occiput and C2, it will generally occur only in the presence of an accompanying atlantoaxial instability.⁵⁰ Other regions of cervical spine instability can occur (i.e., C2–3) and should always be sought during the evaluation.⁸ Ossification of the posterior longitudinal ligament has also been described in a patient with Down syndrome and myelopathy.⁴⁹

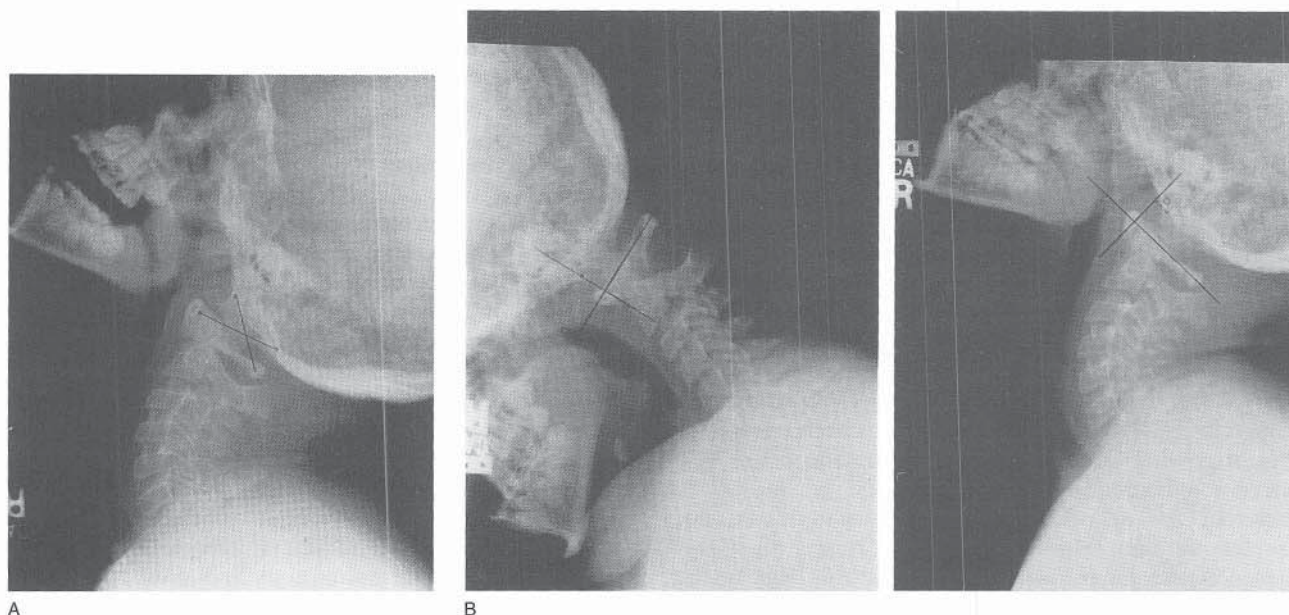
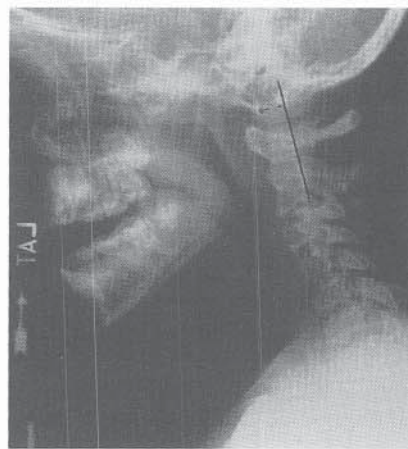


FIGURE 30–28 Methods for measuring occipital-atlantal instability. **A**, Powers ratio measurement. On a lateral extension radiograph of the cervical spine, the distance between the basion (**B**) and the anterior aspect of the posterior ring of C1 (**C**) is divided by the distance between the opisthion (**O**) and the posterior aspect of the anterior arch of C1 (**A**). The Powers ratio, BC/OA , for this radiograph is 0.90. **B**, The Wiesel-Rothman technique, here used with flexion (1) and extension (2) radiographs of the cervical spine. A transverse line is drawn from the anterior arch of C1 to the most posterior aspect of the posterior ring. A perpendicular is constructed to this line along the posterior aspect of the anterior arch of the atlas. The closest distance between this line and the basion is measured (**D**), and the difference between this distance in flexion and extension represents the amount of instability. **C**, The basion-axial interval (BAI), which is established by measuring the distance between a line drawn along the posterior aspect of the body of C2 and the basion. (From Karol LA, Sheffield EG, Crawford K, et al: Reproducibility in the measurement of atlanto-occipital instability in children with Down syndrome. *Spine* 1996;21:2463.)



Treatment of Upper Cervical Spine Instability. Non-operative treatment for upper cervical spine instability in Down syndrome has never been shown to be effective in preventing possible neurologic deterioration. Families should be counseled that certain sports (gymnastics, diving, high jump, and so on) can lead to excessive stress on the neck.

At present, the indications for surgical stabilization remain relatively controversial.¹⁷ In the past, some investigations recommended early fusion when atlantoaxial instability was identified, with or without myelopathy. The purpose was to prevent potential neurologic catastrophe.^{4,14,28} However, with today's recognition that the vast majority of asymptomatic patients with C1–2 instability will remain asymptomatic, the need for prophylactic surgical stabilization has never been substantiated.

Some authors report that instability greater than 10 mm should be stabilized with a posterior C1–2 arthrodesis, regardless of the presence or absence of symptoms.²⁹ They cite the lack of secondary soft tissue restraints (incompetent

transverse ligament, capsular structures, and alar ligaments) as the reason to proceed. Because of the high risk of complications associated with attempts at surgical stabilization, I recommend MRI evaluation for the rare individual without neurologic symptoms or signs whose instability exceeds 10 mm. If the spinal cord is significantly impinged on when the neck is in the flexed position (as demonstrated by MRI), surgical stabilization should be undertaken. For those without significant impingement (i.e., open posterior ring of C1), close observation is warranted. Meticulous examination must be carried out in this situation to identify the presence of subtle neurologic findings. Others report that treatment plans for these children should depend on the space available for the cord rather than on absolute values of displacement.⁴⁸

The one absolute indication for stabilization between C1 and C2 (with posterior arthrodesis) is the occurrence of neurologic symptoms. Preoperative evaluation with flexion-extension radiographs and MRI should be performed to determine the exact location(s) of instability, the amount of cord impingement, and whether normal alignment can

be reestablished between C1 and C2. Instability may be seen alone or in combination at the occiput–C1 level, C1–2 level, or C2–3 regions.

Several surgical techniques have been proposed. The first, in situ autogenous bone graft without internal fixation, continues to be effective, as reported in the literature.⁴¹ Stable fibrous union is common with this method. However, because it provides no inherent stability, postoperative halo-vest immobilization is mandatory. In addition, if normal alignment of C1 on C2 was reestablished at the time of surgery, there is a greater risk of redisplacement in the postoperative period with this method because of the lack of internal fixation. On the other hand, this technique is preferred if a *fixed* subluxation of C1 on C2 is recognized preoperatively. If preoperative traction has been unsuccessful in improving C1–2 alignment, attempts to operatively achieve a reduction should not be made but rather the subluxated C1–2 articulation should be fused in situ. Passage of sublaminar wire underneath an intact ring at C1 in this instance carries far too much neurologic risk, due to the

lack of available space. Once in situ fusion has been achieved in the patient with fixed C1–2 subluxation, potential neurologic compromise may necessitate future resection of the dens.

The second, and most common, surgical technique utilizes sublaminar wires for internal fixation. This method requires that normal C1–2 alignment be restored, thus providing adequate space for the spinal cord before the wires are passed. Autogenous bone graft is utilized, and use of a halo vest is still required. The use of wires increases the likelihood, but does not guarantee, that normal C1–2 alignment achieved at the time of surgery will be maintained (Fig. 30–29). It also shortens the time needed for external immobilization. Facet screws placed between C1 and C2 provide greater stabilization than sublaminar wiring,³² and this technique should be considered *if* normal C1–2 alignment is obtained intraoperatively.

Additional methods have been reported for arthrodesis between the occiput and upper cervical spine. In one method, a contoured autogenous iliac crest bone graft is

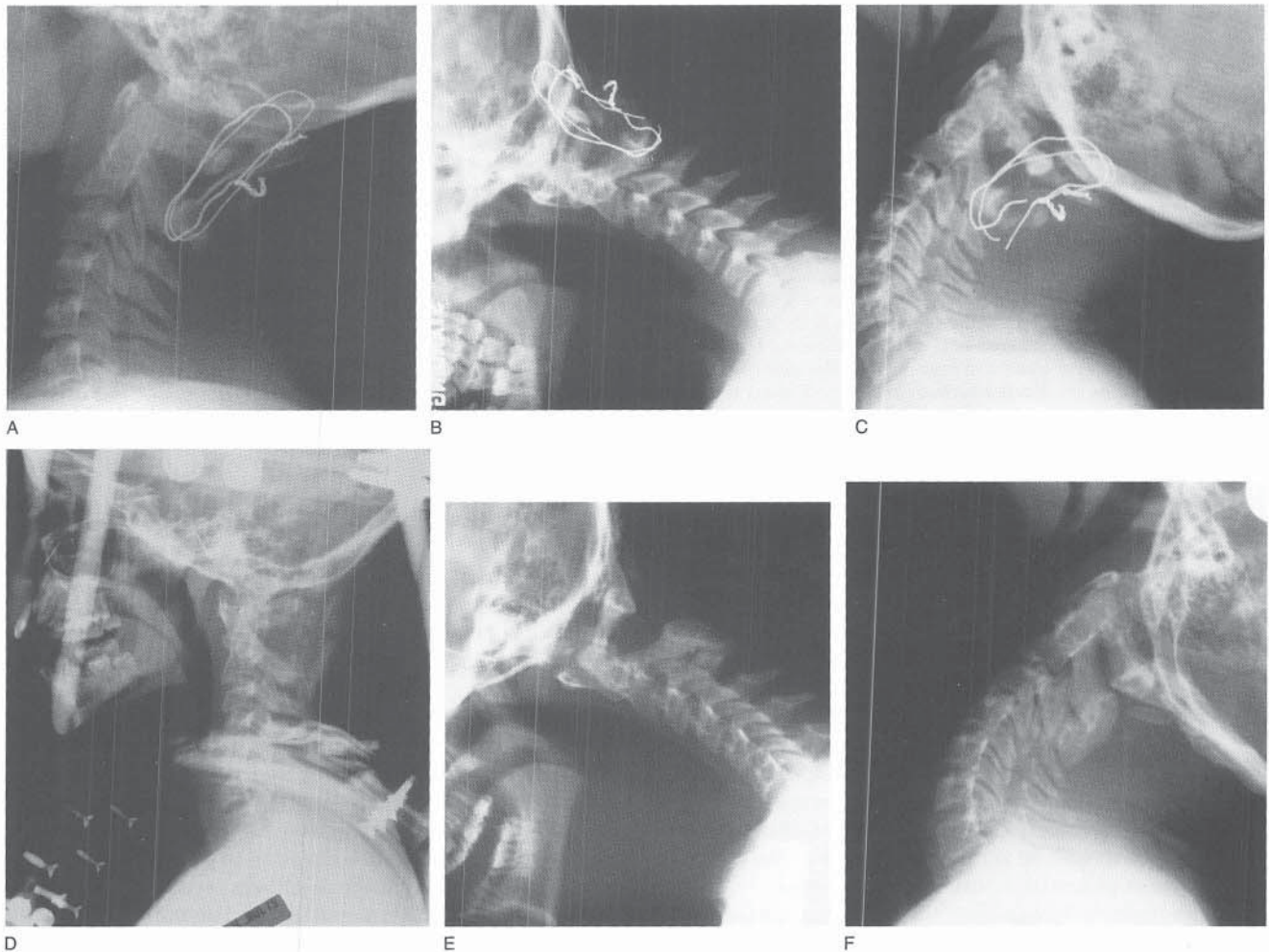


FIGURE 30–29 Treatment of upper cervical spine instability in Down syndrome. A, The patient in Figure 30–27 was treated by posterior fusion (with wire fixation) between the occiput and C2, with external immobilization provided by a soft collar only. B and C, Six months later, the wires were noted to be broken, and motion was evident at C1–2. D, The wires were removed, and in situ fusion between the occiput and C2 was repeated. External immobilization with a halo vest was used postoperatively. E and F, Three years later, the occiput–C1 fusion was solid. Spontaneous fusion between C2 and C3 had also occurred. Nonunion between C1 and C2 persisted but was accepted, as only a 3-mm difference in atlanto-dens interval was evident between flexion and extension.

secured with wires between the occiput and C2 (sometimes C3).¹⁵ A halo-vest device is used postoperatively. Another method uses a Luque loop rod and wires to avoid rigid postoperative external immobilization.²³ Both of these methods have the advantage of allowing decompression of spinal cord impingement at C1 by removing its posterior ring.

Recent reports in the literature indicate a high rate (73 to 100 percent) of complications following attempts at upper cervical spine arthrodesis in Down syndrome.^{17,42} Major complications include nonunion, loss of reduction of C1 on C2 (even in the presence of sublaminar wire fixation), late subaxial instability, infection, progressive neurologic deterioration, resorption of autogenous bone graft, and death in the postoperative period. The fact that sublaminar wiring of the atlas may not protect against the potential loss of reduction of C1 on C2 emphasizes the need for postoperative halo-vest immobilization.

It bears reemphasizing that although upper cervical spine instability in patients with Down syndrome can be progressive and may have serious consequences, there are no data with which to predict which asymptomatic patients will progress or develop symptoms. Minor trauma rarely precipi-

tates neurologic deterioration in previously asymptomatic patients.¹⁷ Therefore, attempts at fusion in those with asymptomatic atlantoaxial instability or occipital-atlantal instability should be approached with great caution. In myelopathic patients with documented weakness or functional decline, surgical stabilization should be attempted following preoperative radiographic and MRI evaluation.

Hip Disorders. Radiographs of the hip joint in Down syndrome often demonstrate a deep acetabulum, horizontal acetabular roof, a deep-seated femoral head, a normal femoral neck-shaft angle, and moderately increased femoral anteversion. This orientation would be expected to create an intrinsically stable joint. Despite this, hip dysplasia or dislocation occurs in nearly 5 percent of children with Down syndrome and is the most common hip disorder seen in this population.⁵ The dislocations are not congenital but rather occur between the ages of 2 and 10 years. They can progressively evolve into a chronic dysplasia or fixed dislocation (Fig. 30–30).^{3,5,19,20,44}

The etiology of these recurrent, usually painless dislocations is related to joint hypermobility and ligamentous laxity.

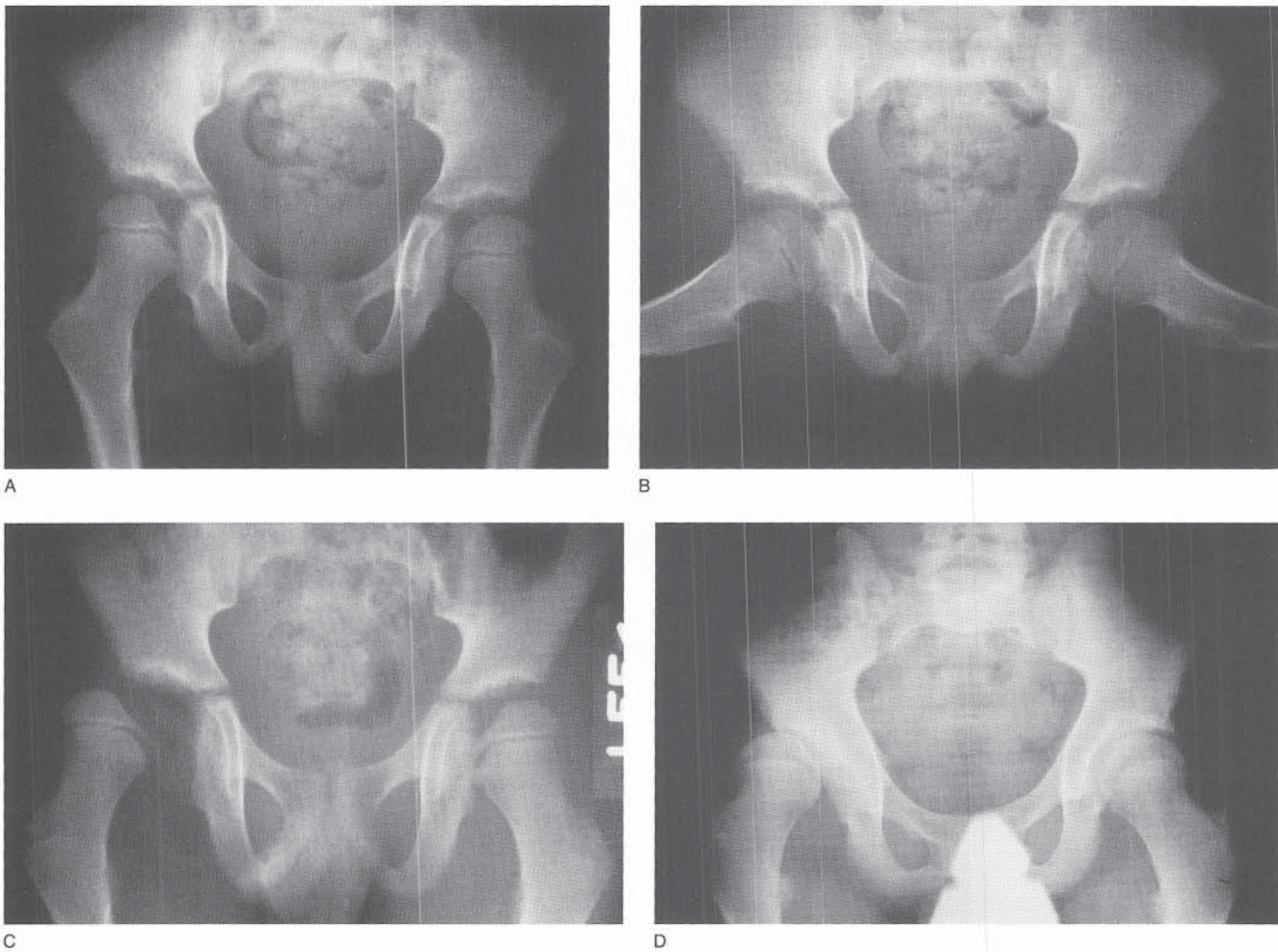
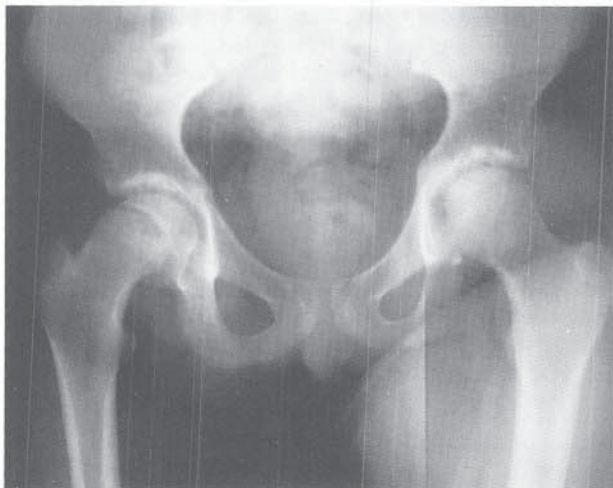


FIGURE 30–30 A and B, AP and lateral radiographs of the pelvis in a 5-year-old child with Down syndrome. C, The right hip was dislocatable with little effort. This did not cause pain. Surgical stabilization of the hip was recommended, but the family refused. D, Ten years later, acetabular dysplasia of the right hip was radiographically evident. The patient remained asymptomatic and the family elected to avoid any orthopaedic intervention.

The hip capsule is thin, attenuated, and poorly developed. Increased femoral neck anteversion and an increase in the neck-shaft angle may be noted radiographically.

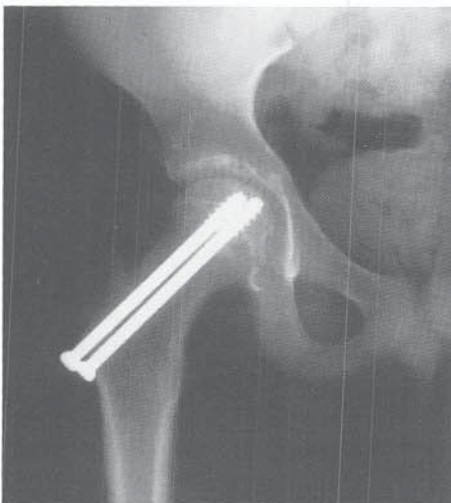The goal of treatment is to create a stable, normal hip joint that lasts the patient's lifetime. Achieving this can be difficult. Nonoperative methods include closed reduction and immobilization in a hip spica cast followed by the use of an abduction brace. Although nonoperative treatment is

thought to be of minimal benefit in children with joint laxity,^{5,19} a recent report on two patients with Down syndrome noted lasting benefit.²⁰ Cast immobilization is used for 2 to 3 months. Thereafter the child wears an ambulatory abduction orthosis full-time for 4 months and then at night only for an additional 2 to 4 months. This extensive amount of abduction treatment is probably critical to the success of nonoperative management.

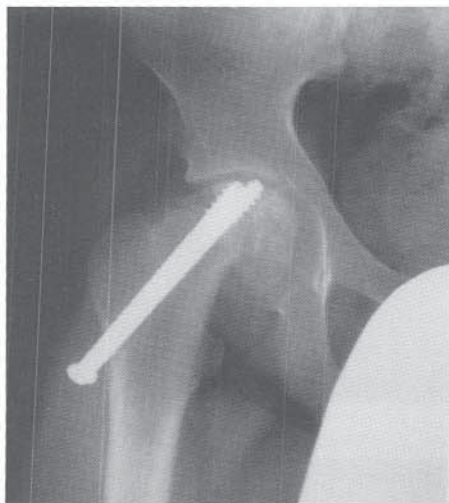

A

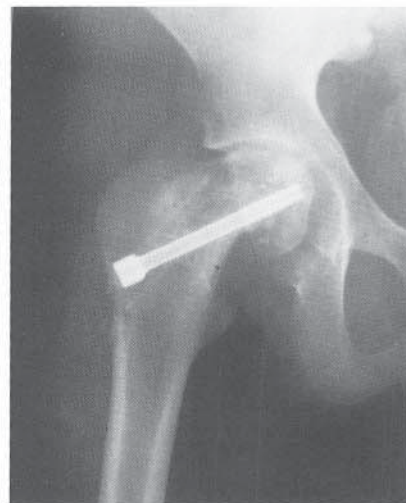FIGURE 30-31 A 14-year-old boy with Down syndrome had moderate discomfort involving his right hip. He remained ambulatory. **A**, AP pelvic radiograph demonstrating a slipped capital femoral epiphysis of the right hip. **B**, At the time of surgery, the femoral head was unstable, demonstrating motion. It was stabilized with two screws. **C**, Five months later the patient had a limp but no pain. The radiograph showed evidence of avascular necrosis of the femoral head and screw penetration into the joint. **D** and **E**, Because the physis remained open, the two screws were removed and replaced with one screw. Further collapse occurred, and the screw was removed 6 months later. After 2 years the patient remains pain-free but has a pronounced limp. **F**, On the radiograph, the joint space is maintained despite an irregular femoral head.



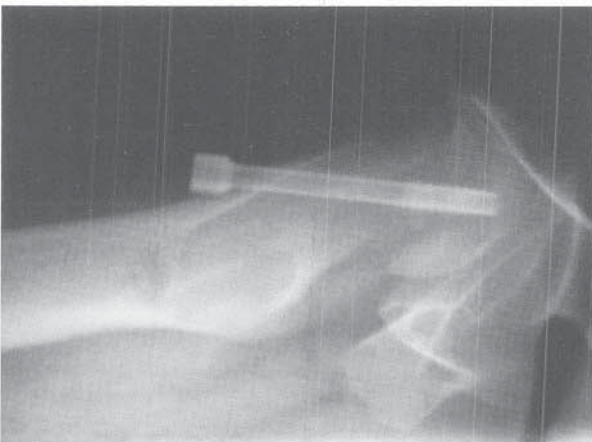
B



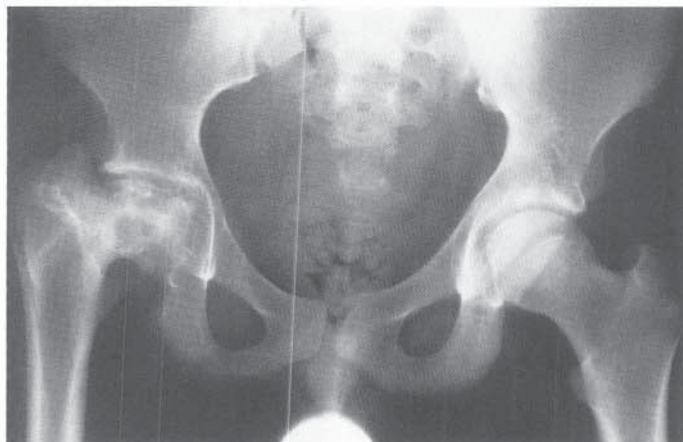
C



D



E



F

Operative treatment should be undertaken if conservative cast or brace management has failed to remedy the recurrent dislocations. If the acetabulum is normal and sufficient, capsular plication combined with varus derotation femoral osteotomy may provide a reduced and stable hip. If the acetabulum is insufficient and dysplastic, a Salter or Dega osteotomy combined with capsular plication and varus derotation osteotomy may be effective.^{3,19,44} Despite meticulous attention to surgical detail, complications have been reported in as many as 50 percent of cases.⁵ The prominent complications include redislocation and infection. The risk of wound infection is always increased in the Down syndrome population.

Other hip disorders that occur in these children include slipped capital femoral epiphysis and avascular necrosis.^{6,46} Unlike unaffected children, patients with Down syndrome often ambulate nearly pain-free on hips that radiographically show severe deterioration (Fig. 30–31). If slipped capital femoral epiphysis is diagnosed, it is imperative to evaluate for thyroid dysfunction, owing to its frequent association.

When all of the hip disorders are considered in the younger Down syndrome population, the incidence of some form of hip abnormality has been reported as 7.9 percent.⁴⁴ In the adult population, hip abnormalities occur with even greater frequency.²⁴ A normal hip at maturity does not preclude later subluxation or dislocation. There does not seem to be a safe age at which hip stability can be guaranteed. As hips progress from mild to severe subluxation or dislocation in adulthood, deterioration in walking ability leads to difficulties with community activities.

Patellofemoral Disorders. Instability of the patella can be quite debilitating.¹⁴ The knee may give way, leading to frequent episodes of falling. Quadriceps strengthening exercises and patellar stabilizing braces may provide benefit to some individuals. Should nonoperative treatment be unsuccessful, operative intervention includes the Galleazzi-Dewar realignment. A shallow trochlear groove in the femur, combined with tissue laxity, can make patellar stabilization difficult to achieve.

Foot Disorders. Flat feet are common because of the generalized ligamentous laxity. Treatment is usually unnecessary because of the lack of symptoms. Customized arch supports may provide relief to those with discomfort. Rarely should surgery be undertaken to alter this condition. Along with flat feet, hallux valgus occurs widely in patients with Down syndrome. Alterations for shoe wear usually accommodate the abnormalities. On occasion, bunionectomies provide relief in the adult population.

REFERENCES

Down Syndrome (Trisomy 21)

- American Academy of Pediatrics Committee on Sports Medicine: Atlanto-axial instability in Down's syndrome. *Pediatrics* 1984;74:152.
- American Academy of Pediatrics Committee on Sports Medicine and Fitness: Atlantoaxial instability in Down syndrome: subject review. *Pediatrics* 1995;96:151.
- Aprin H, Zink WP, Hall JE: Management of dislocation of the hip in Down syndrome. *J Pediatr Orthop* 1985;5:428.
- Aung M: Atlanto-axial dislocation in Down's syndrome. *Bull LA Neurol Soc* 1973;38:197.
- Bennet GC, Rang M, Roye DP, et al: Dislocation of the hip in trisomy 21. *J Bone Joint Surg* 1982;64-B:289.
- Berghof R, Carstens C: [Hip joint problems in patients with Down's syndrome]. *Z Orthop Grenzgeb* 1992;130:136.
- Brooke DC, Burkus JK, Benson DR: Asymptomatic occipito-atlantal instability in Down's syndrome. *J Bone Joint Surg* 1987;69-A:293.
- Citow JS, Munshi I, Chang-Stroman T, et al: C2/3 instability in a child with Down's syndrome: case report and discussion. *Pediatr Neurosurg* 1998;28:143.
- Copel JA, Bahado-Singh RO: Prenatal screening for Down's syndrome: a search for the family's values [editorial]. *N Engl J Med* 1999;341:521.
- Cremers MJ, Beijer HJ: No relation between general laxity and atlantoaxial instability in children with Down syndrome. *J Pediatr Orthop* 1993;13:318.
- Cremers MJ, Bol E, de Roos F, et al: Risk of sports activities in children with Down's syndrome and atlantoaxial instability. *Lancet* 1993;342:511.
- Dahmane N, Ghezala GA, Gosset P, et al: Transcriptional map of the 2.5-Mb CBR-ERG region of chromosome 21 involved in Down syndrome. *Genomics* 1998;48:12.
- Delabar JM, Theophile D, Rahmani Z, et al: Molecular mapping of twenty-four features of Down syndrome on chromosome 21. *Eur J Hum Genet* 1993;1:114.
- Diamond LS, Lynne D, Sigman B: Orthopedic disorders in patients with Down's syndrome. *Orthop Clin North Am* 1981;12:57.
- Dormans JP, Drummond DS, Sutton LN, et al: Occipitocervical arthrodesis in children: a new technique and analysis of results. *J Bone Joint Surg* 1995;77-A:1234.
- Down J: Observations on an ethnic classification of idiots., Vol. 3, p 259. *Clinical Lecture Reports, London Hospital, 1866.*
- Doyle JS, Lauerman WC, Wood KB, et al: Complications and long-term outcome of upper cervical spine arthrodesis in patients with Down syndrome. *Spine* 1996;21:1223.
- Gabriel KR, Manson DE, Carango P: Occipito-atlantal translation in Down's syndrome. *Spine* 1990;15:997.
- Gore DR: Recurrent dislocation of the hip in a child with Down's syndrome: a case report. *J Bone Joint Surg* 1981;63-A:823.
- Greene WB: Closed treatment of hip dislocation in Down syndrome. *J Pediatr Orthop* 1998;18:643.
- Hall J: Chromosomal clinical abnormalities. In Behrman RE (ed): *Nelson's Textbook of Pediatrics*, p 314. Philadelphia, WB Saunders Co, 1996.
- Harris JH, Carson GC, Wagner LK: Radiologic diagnosis of traumatic occipitovertebral dissociation. *AJR Am J Roentgenol* 1994;162:881.
- Higo M, Sakou T, Taketomi E, et al: Occipitocervical fusion by Luque loop rod instrumentation in Down syndrome. *J Pediatr Orthop* 1995;15:539.
- Hresko MT, McCarthy JC, Goldberg MJ: Hip disease in adults with Down syndrome. *J Bone Joint Surg* 1993;75-B:604.
- Hungerford GD, Akkaraju V, Rawe SE, et al: Atlantooccipital and atlantoaxial dislocation with spinal cord compression in Down's syndrome: a case report and review of the literature. *Br J Radiol* 1981;54:758.
- Jones K: Chromosomal abnormality syndromes. In Jones K (ed): *Smith's Recognizable Patterns of Human Malformation*, p 8. Philadelphia, WB Saunders Co, 1997.
- Karol LA, Sheffield EG, Crawford K, et al: Reproducibility in the measurement of atlanto-occipital instability in children with Down syndrome. *Spine* 1996;21:2463.
- Kobori M, Takahashi H, Mikawa Y: Atlanto-axial dislocation in Down's syndrome: report of two cases requiring surgical correction. *Spine* 1986;11:195.
- Loder RT, Hensinger RN: Developmental abnormalities of the cervical spine. In Weinstein S (ed): *The Pediatric Spine: Principles and Practice*, p 412. New York, Raven Press, 1994.
- Martel W, Tishler JM: Observations in the spine in mongolism. *AJR Am J Roentgenol Radium Ther Nucl Med* 1966;94:630.
- Matsuda Y, Sano N, Watanabe S, et al: Atlanto-occipital hypermobility in subjects with Down's syndrome. *Spine* 1995;20:2283.
- Mitchell TC, Sadasivan KK, Ogden AL, et al: Biomechanical study of atlantoaxial arthrodesis: transarticular screw fixation versus modified Brooks posterior wiring. *J Orthop Trauma* 1999;13:483.
- Ohswa T, Izawa T, Kuroki Y, et al: Follow-up study of atlanto-axial instability in Down's syndrome without separate odontoid process. *Spine* 1989;14:1149.

34. Parfenchuck TA, Bertrand SL, Powers MJ, et al: Posterior occipitoatlantal hypermobility in Down syndrome: an analysis of 199 patients. *J Pediatr Orthop* 1994;14:304.
35. Powers B, Miller MD, Kramer RS, et al: Traumatic anterior atlanto-occipital dislocation. *Neurosurgery* 1979;4:12.
36. Poeschel SM, Moon AC, Scola FH: Computerized tomography in persons with Down syndrome and atlantoaxial instability. *Spine* 1992;17:735.
37. Poeschel SM, Scola FH, Tupper TB, et al: Skeletal anomalies of the upper cervical spine in children with Down syndrome. *J Pediatr Orthop* 1990;10:607.
38. Poeschel SM, Scola FH, Perry CD, et al: Atlanto-axial instability in children with Down Syndrome. *Pediatr Radiol* 1981;10:129.
39. Poeschel SM, Scola FH: Atlantoaxial instability in individuals with Down syndrome: epidemiologic, radiographic, and clinical studies. *Pediatrics* 1987;80:555.
40. Poeschel SM, Scola FH, Pezzullo JC: A longitudinal study of atlanto-dens relationships in asymptomatic individuals with Down syndrome. *Pediatrics* 1992;89:1194.
41. Rizzolo S, Lemos MJ, Mason DE: Posterior spinal arthrodesis for atlantoaxial instability in Down syndrome. *J Pediatr Orthop* 1995;15:543.
42. Segal LS, Drummond DS, Zanotti RM, et al: Complications of posterior arthrodesis of the cervical spine in patients who have Down syndrome. *J Bone Joint Surg* 1991;73-A:1547.
43. Semine AA, Ertel AN, Goldberg JM, et al: Cervical spine instability in children with Down syndrome (trisomy 21). *J Bone Joint Surg* 1978;60-A:649.
44. Shaw ED, Beals RK: The hip joint in Down's syndrome: a study of its structure and associated disease. *Clin Orthop* 1992;278:101.
45. Spitzer R, RJ, Wybar KC: A study of abnormalities of the skull, teeth, and lenses in mongolism. *Can Med Assoc J* 1961;84:567.
46. Stack RE, Peterson LF: Slipped capital femoral epiphysis and Down's disease. *Clin Orthop* 1966;48:111.
47. Tishler JM, Martel W: Dislocation of the atlas in mongolism: preliminary report. *Radiology* 1965;84:904.
48. Tredwell SJ, Newman DE, Lockitch G: Instability of the upper cervical spine in Down syndrome. *J Pediatr Orthop* 1990;10:602.
49. Tyrrell PN, Cassar-Pullicino VN, McCall IW: Ossification of the posterior longitudinal ligament in Down's syndrome. *Eur Spine J* 1998;7:172.
50. Uno K, Kataoka O, Shiba R: Occipitoatlantal and occipitoaxial hypermobility in Down syndrome. *Spine* 1996;21:1430.
51. Vidal-Taboada JM, Bergonon S, Scartezzini P, et al: High-resolution physical map and identification of potentially regulatory sequences of the human SH3BGR located in the Down syndrome chromosomal region. *Biochem Biophys Res Commun* 1997;241:321.
52. Wiesel SW, Rothman RH: Occipitoatlantal hypermobility. *Spine* 1979;4:187.

Neurofibromatosis

INTRODUCTION

Neurofibromatosis is a hereditary, hamartomatous disorder that affects numerous systems of the body, including the central and peripheral nervous systems, skeleton, skin, and deeper soft tissues. Over the past decade, a great deal of information about neurofibromatosis has been gained from molecular genetic studies.^{2,4,15,16,35,39,40,43} Two distinct entities of this disorder exist. The first, neurofibromatosis type 1 (NF-1), also known as von Recklinghausen's disease or peripheral neurofibromatosis, is due to a defect in chromosome 17. The second entity, neurofibromatosis type 2 (NF-2), previously known as bilateral acoustic neurofibromatosis or central neurofibromatosis, results from a defect in the long arm of chromosome 22. Children with orthopaedic manifestations of the disease, such as spinal deformities or congenital tibial pseudarthrosis, are almost always afflicted with NF-1. Rarely will the child with NF-2 require orthopaedic intervention.

HISTORICAL PERSPECTIVE

Tilesius, Virchow, and von Recklinghausen are names that are historically tied to neurofibromatosis.²⁸ In 1793, Tilesius provided one of the earliest descriptions of a patient thought to have this disorder.³⁸ Known as "the wart man," this patient had numerous growths on his skin, café-au-lait spots, macrocephaly, and scoliosis (Fig. 30–32). Between 1847 and 1863, Virchow presented a series of reports describing patients with neuromas and fibromas. In 1882 Virchow's student, Frederick von Recklinghausen, presented the report, "On multiple cutaneous fibromas and their relationship to multiple neuromas," in which he reviewed the existing literature on neurofibromatosis and added two cases.⁴² He linked the simultaneous existence of the fibromas and neuromas for the first time and coined the term *neurofibroma*. Subsequently the eponym "von Recklinghausen's disease" has been used synonymously with what today is known as neurofibromatosis type 1.

For a century, neurofibromatosis and the famous "elephant man" figure Joseph Cary Merrick were linked.³⁶ In the 1880s, Merrick was of interest to physicians in London because of severe disfigurement of his head and extremities and vertebral abnormalities. All were thought to be due to neurofibromatosis. Nearly 100 years later, with a better understanding of various syndromes, Merrick has been reclassified as more likely having Proteus syndrome rather than neurofibromatosis.⁶

NEUROFIBROMATOSIS TYPE 1 (VON RECKLINGHAUSEN'S DISEASE)

NF-1 is the most common single gene disorder affecting the human nervous system. Its incidence is estimated to be between 1 in 2,500 and 1 in 4,000.^{7,9,10,20} There is no sex or ethnic group predilection for this disorder. Although it is inherited in an autosomal dominant fashion, approximately 50 percent of all NF-1 cases are thought to result from new mutations. The penetrance of this disorder is close to 100 percent, so that nearly every individual who carries the abnormal gene on chromosome 17 will eventually show some clinical feature of NF-1. Mildly affected parents may have a severely affected child, and the reverse is also true. Less than 10 percent will require orthopaedic management, but

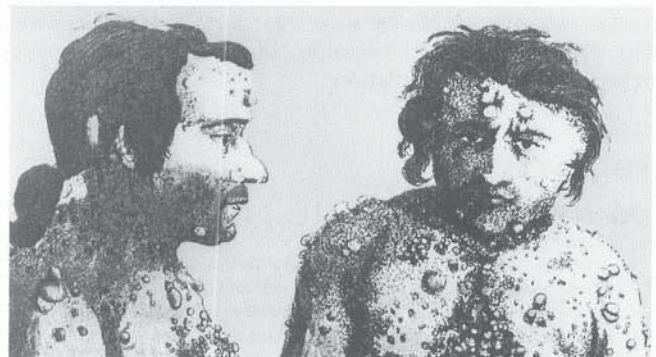


FIGURE 30–32 Neurofibromatosis. Appearance of "the wart man," Johann Gottfried Rheinhard, as described and illustrated by Tilesius in 1793. (From Morse RP: Neurofibromatosis type 1. *Arch Neurol* 1999;56:365.) Copyrighted 1999, American Medical Association.

TABLE 30-3 NIH Criteria for the Diagnosis of Neurofibromatosis

- More than six café-au-lait spots, at least 15 mm in greatest diameter in adults and 5 mm in children
- Two or more neurofibromas of any type or one plexiform neurofibroma
- Freckling in the axillae or inguinal regions (Crowe's sign)
- Optic glioma
- Two or more Lisch nodules (iris hamartomas)
- A distinctive bone lesion, such as sphenoid dysplasia or thinning of the cortex of a long bone, with or without pseudarthrosis
- A first-degree relative (parent, sibling, or offspring) with NF-1 by the above criteria

From MacCollin M, Mautner VF: Diagnosis and management of neurofibromatosis 2 in childhood. *Semin Pediatr Neurol* 1998;5(4):243-252. The criteria were formulated by an NIH Consensus Development Conference.

for those who do, several operative interventions to manage this ongoing multisystem disease process can be expected.

Many systems of the body can be affected, and the resultant potential complications can be numerous. These complications include cognitive deficits, epilepsy, hydrocephalus, intracranial tumors, optic gliomas, short stature, scoliosis, hemihypertrophy, pseudarthrosis of extremity bones, precocious puberty, hypothalamic dysfunction, hypertension, and renal artery stenosis.³⁰

Genetic Aspects of NF-1. Mapping of the NF-1 gene on chromosome 17 was reported in 1987.² This was followed 3 years later by reports documenting the ability to clone the abnormal gene.^{4,16,43} Mutations in the NF-1 gene have been identified in both benign neurofibromas and malignant tumors associated with NF-1, thereby leading to the classification of the NF-1 gene as a tumor suppressor gene. Neurofibromin, the protein encoded by the NF-1 gene, is thought to have an important role in cell growth and differentiation.³⁰

In 1995 a protein truncation assay was reported for use in confirming the diagnosis of NF-1 in patients with equivocal physical signs and in prenatal diagnosis in families with multiple affected generations.¹⁸ This assay enables the investigator to detect approximately 60 percent of germ-line mutations in the NF-1 gene. At this time, the sensitivity and specificity of this test have not been confirmed.

Diagnosis of NF-1. In 1987 the Consensus Development Conference on Neurofibromatosis at the National Institutes of Health (NIH) reported on seven different criteria that are found in patients with NF-1 (Table 30-3).²⁹ If two or more of these criteria are identified in a child, that individual can be considered to have NF-1. Subsequent reports over the past decade have reinforced the usefulness of these criteria.^{12,17}

Clinical Features of NF-1

CAFÉ-AU-LAIT SPOTS. Café-au-lait spots are the most common clinical finding in NF-1, present in more than 90 percent of affected patients. These spots are areas of hyperpigmentation which usually have rounded borders (as opposed to the irregular border seen in Albright's disease). They become clinically obvious during the first 2 years of life (Fig. 30-33). To fulfill one of the criteria for the diagnosis of NF-1 as established by the NIH Consensus Development Conference, more than six of these spots must be present. Each

must be at least 15 mm in greatest diameter in adults and at least 5 mm in diameter in children. However, café-au-lait spots by themselves are insufficient to confirm the diagnosis of NF-1. Should these spots be noted in an infant (in the absence of other findings), the family should be told that this might be the early presentation of NF-1 but that further evaluation will necessary over time. Additional criteria that will confirm the diagnosis usually become apparent by age 5 to 10 years.²³

AXILLARY AND INGUINAL FRECKLING. Axillary and inguinal freckling is the second most common clinical feature found in children with NF-1, with a frequency approximating 80 percent by age 6 years.³² The freckling consists of diffuse hyperpigmented spots 1 to 3 mm in diameter (Fig. 30-34).

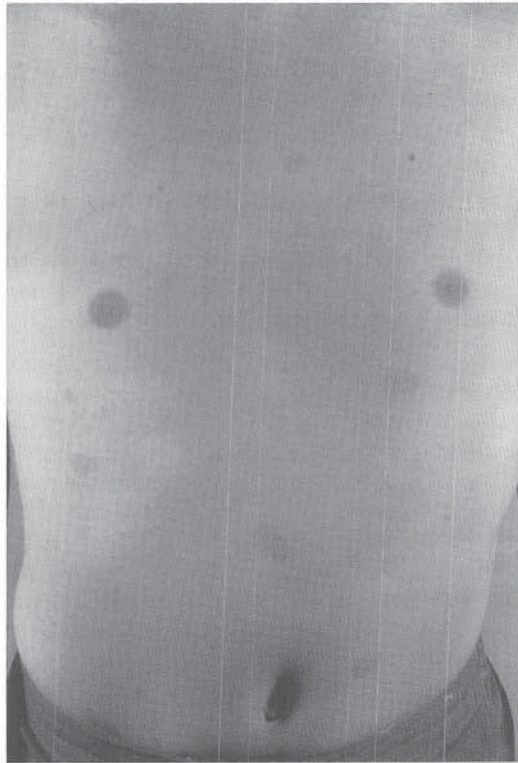
CUTANEOUS NEUROFIBROMAS. Cutaneous neurofibromas, called fibroma molluscum by Virchow approximately 150 years ago, contain axons and Schwann cells. They usually become evident in preadolescence and increase in number thereafter. Clinically, these nodules are frequently raised above the skin surface and may have a slight bluish hue (Fig. 30-35). Cutaneous neurofibromas do not transform into malignant tumors. This characteristic distinctly separates them from the more worrisome plexiform neurofibromas, of which 1 to 4 percent are premalignant.³⁰ Rarely are cutaneous neurofibromas associated with CNS lesions.

LISCH NODULES. Lisch nodules are dome-shaped elevations on the surface of the iris and are identified by the ophthalmologist using a slit lamp. When seen, they are pathognomonic for NF-1. The incidence of Lisch nodules increases markedly with age. The reported frequency is between 22 and 81 percent by the age of 5 or 6 years. By 20 years of age, nearly 100 percent of patients will have evidence of Lisch nodules.²⁵

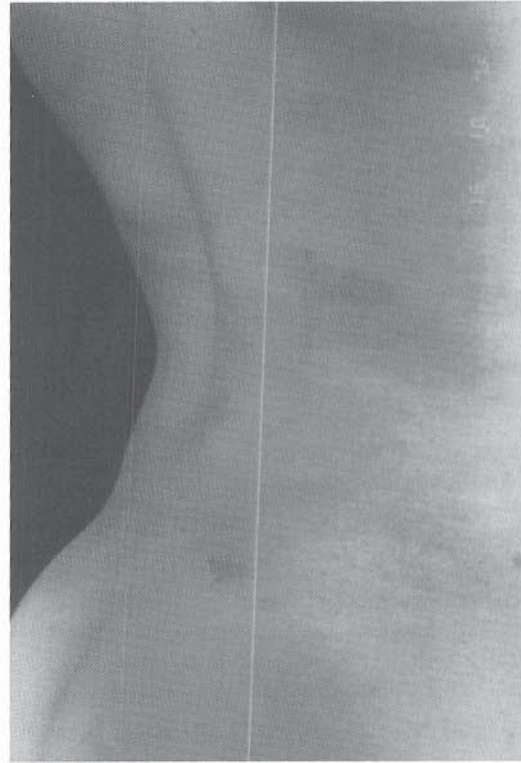
PLEXIFORM NEUROFIBROMAS. Plexiform neurofibromas are very sensitive subcutaneous neurofibromas described as being "ropy" and feeling like a "bag of worms" when palpated. They are found in 25 percent of patients affected by NF-1 and may lead to significant disfigurement. Often cutaneous hyperpigmentation will overlie the plexiform neurofibromas, some of which may extend into deeper tissues such as muscle, fascia, bone, and visceral regions (Fig. 30-36).³⁴ Growth of these tumors may vary greatly, and larger lesions may lead to overgrowth of an extremity. Because malignant transformation of these normally benign plexiform tumors occurs in 1 to 4 percent of cases, resection of the lesions should be considered if they become large, painful, conspicuous, or rapidly expanding. Early removal is easier and may improve the cosmetic appearance (Fig. 30-37).

VERRUCOUS HYPERPLASIA. Verrucous hyperplasia represents thickened overgrowth of the skin which has a velvety-soft feel on palpation. Crevices commonly form within the hyperplastic area, intermittently resulting in an infection requiring antibiotics. *Elephantiasis (pachydermatocele)* represents excessive amounts of this skin, which may be associated with overgrowth of underlying dysplastic bone. Fortunately, these two features—verrucous hyperplasia and elephantiasis—are uncommon.

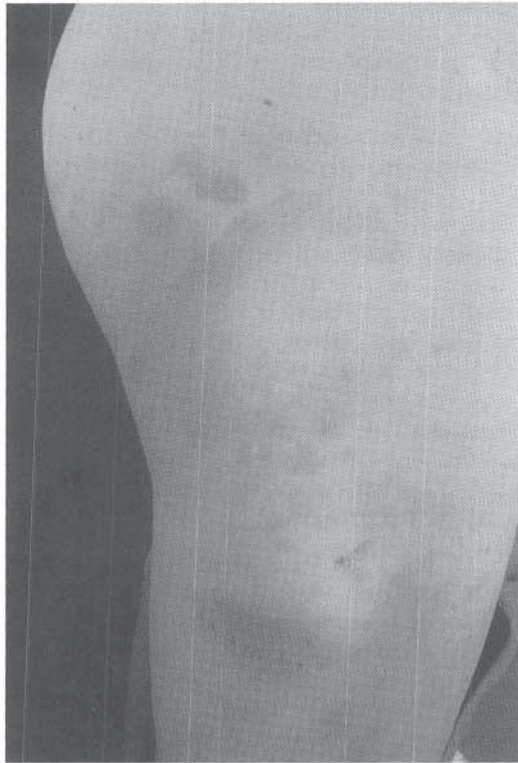
OPTIC GLIOMA. These low-grade pilocytic astrocytomas are the most common CNS tumors in NF-1, occurring in 15



A



B



C

FIGURE 30-33 Café-au-lait spots in neurofibromatosis. These spots with rounded borders are seen on a patient's abdomen (A) back (B), and thigh (C). They are expected to vary in size.

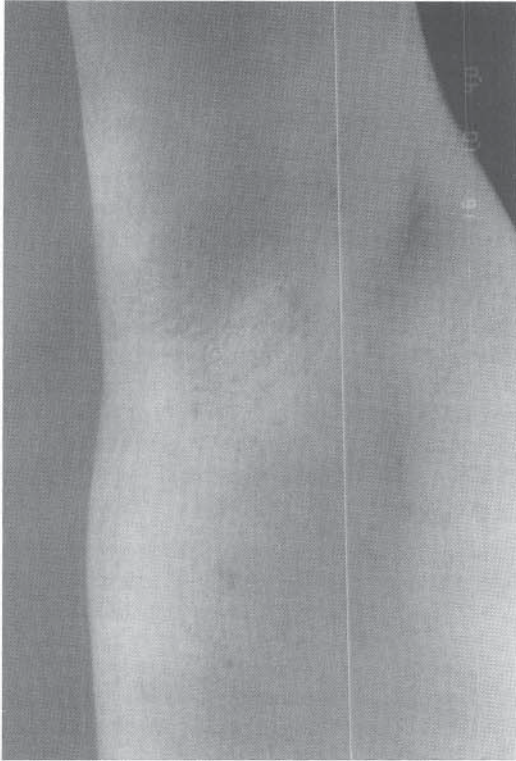


FIGURE 30-34 Axillary freckling (consisting of numerous 1- to 3-mm hyperpigmented spots) is present in nearly 80 percent of individuals with neurofibromatosis by age 6 years.

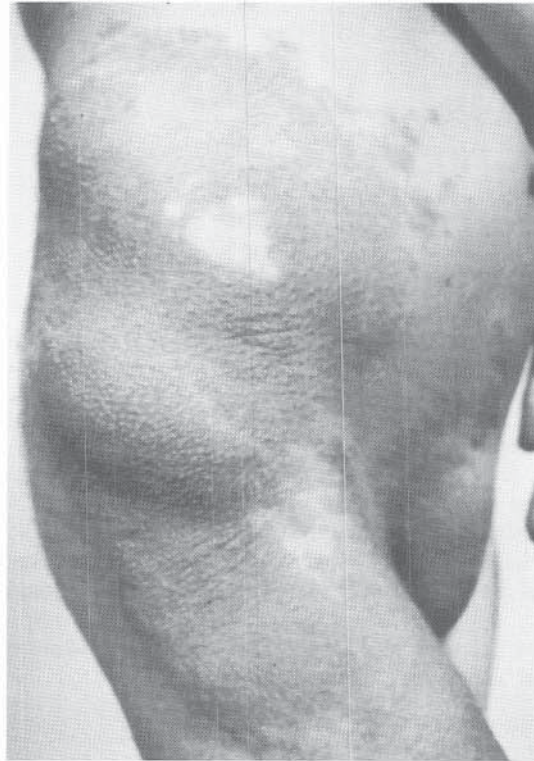


FIGURE 30-36 A large nevus overlying a plexiform neurofibroma. (From Crawford AH: Neurofibromatosis in children. *Acta Orthop Scand Suppl* 1986;57:218.)

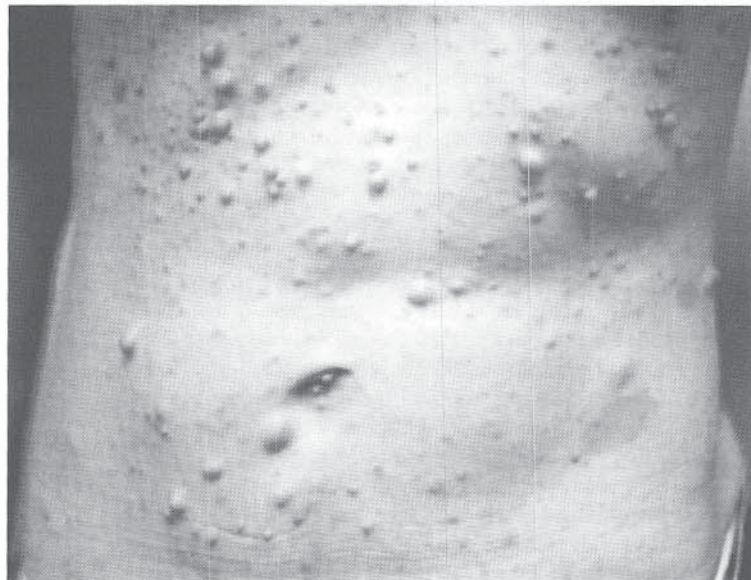


FIGURE 30-35 Cutaneous neurofibromas (called fibroma molluscum by Virchow) in neurofibromatosis. (From Crawford AH: Neurofibromatosis in children. *Acta Orthop Scand Suppl* 1986;57:218.)

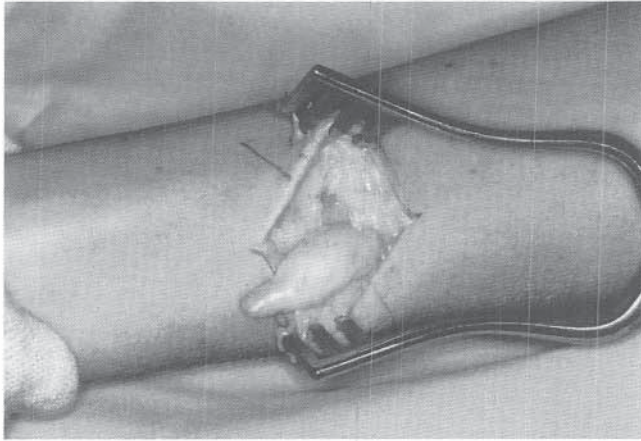


FIGURE 30–37 This tender enlarging subcutaneous neurofibroma in the forearm was benign on histologic examination.

to 20 percent of patients studied with CT or MRI. Less than half become symptomatic. Those that do become symptomatic can cause decreased visual acuity, visual field defects, proptosis, headache, nausea, anorexia, and hypothalamic dysfunction. Optic gliomas may involve the intraorbital portion of the nerve, the chiasm, the intracerebral visual nerve pathways, or any combination. It is unknown why some tumors progress rapidly to cause symptoms while others remain asymptomatic for many years.

Skeletal Abnormalities in NF-1

SPINAL DEFORMITIES. Scoliosis is the most common skeletal manifestation of neurofibromatosis (Fig. 30–38).^{7,8,11,21,22} Typically it affects the thoracic spine, consists of a short, sharply angled curve, and involves four to six vertebra. The reported incidence is between 10 and 60 percent.^{1,5,7,11,18,37} The higher reported rates may have been biased in that they were determined in neurofibromatosis patients followed by musculoskeletal specialists. The most recent report, citing a 10 percent incidence of scoliosis, appears to more accurately reflect the entire neurofibromatosis population.¹

The cause of spinal deformity in neurofibromatosis is unknown. Proposed explanations include primary mesodermal dysplasia, osteomalacia, erosion or infiltration of the bone by localized neurofibromatosis tumors, and endocrine disturbances.⁷

Neurofibromatosis scoliosis can be either dystrophic or nondystrophic, depending on accompanying abnormalities specific to this disorder.* Differentiation between the two is important because the prognosis and management differ significantly. Dystrophic scoliosis is more common, has a greater tendency to progress, and includes a subgroup (patients with severe kyphoscoliosis) at risk for developing neurologic deficits.³⁷ Nondystrophic scoliosis more closely resembles idiopathic scoliosis in both its curve patterns and its behavior. It has recently become clear that nondystrophic curves in younger children can modulate into the more worrisome dystrophic type over the course of several years.⁸

A more complete discussion of scoliosis associated with neurofibromatosis and its treatment is given in Chapter 11, Scoliosis.

* See references 3, 7, 14, 22, 24, 33, 37, 44.

CONGENITAL PSEUDARTHROSIS OF THE TIBIA. Congenital pseudarthrosis of the tibia is frequently associated with neurofibromatosis (Fig. 30–39). The term may be somewhat inaccurate, however, since most clinically apparent pseudarthroses of the tibia are not present at birth. Instead, the orthopaedist encounters a tibial deformity (anterolateral bowing) that, over time, will usually fracture and subsequently result in pseudarthrosis. More accurate terms for this disease process might be congenital anterolateral bowing or congenital tibial dysplasia.⁹

The relationship of this disorder with neurofibromatosis has been known since 1937. Up to 55 percent of cases of anterolateral bowing and pseudarthrosis are associated with NF-1. The tibial abnormality by itself may be evident very early in life. Other findings that confirm the diagnosis of NF-1 (café-au-lait spots, axillary freckling, or cutaneous neurofibromas) may not yet be present. Over time, as other associated findings evolve, the clinical appearance of NF-1 becomes clear. Congenital pseudarthrosis of the tibia and its numerous methods of treatment are discussed in detail in the section entitled Congenital Anterolateral Bowing in Chapter 21, Disorders of the Leg.

HEMIHYPERTROPHY. Overgrowth of an extremity is uncommon and, when it occurs, is usually unilateral (Fig. 30–40). The hypertrophy may result from neurosegmental overgrowth, which implies that a nerve dysplasia is primarily responsible rather than a primary bone dysplasia.⁴¹ Autonomous hypertrophy of brachial or lumbosacral plexus nerve roots can lead to the enlargement of an extremity.

Although primarily neural in etiology, both bone and soft tissues are affected. Changes in the soft tissue include some or all of the following: hemangiomas, lymphangiomas, elephantiasis, and numerous beaded plexiform neurofibromas.⁹ The long bone is elongated and may have an irregular or thickened cortex. Macrodactyly is commonly associated with this, with disproportionate enlargement of either the toes or the fingers.

Attempts to debulk the soft tissue lesion and surgically diminish the bony overgrowth usually result in minimal, if any, improvement. Early epiphysiodesis has a modest effect on this unilateral generalized bony enlargement. Attempts to resect hypertrophic plexus nerve roots, perhaps in the belief that they represent plexiform neurofibromas, may result in severe motor or sensory deficit.

Malignant Degeneration of Neurofibromas. NF-1 predisposes affected individuals to an increased risk of malignancy, primarily neurofibrosarcoma. The risk increases with age, and higher incidences of malignant degeneration are found in the more severely affected patient. Plexiform neurofibromas that enlarge rapidly or are associated with progressive pain should be very carefully evaluated for malignant degeneration. Other tumors, such as leukemia, rhabdomyosarcoma of the urogenital tract, and Wilms' tumor, have also been reported in patients with NF-1.

Cognitive Deficits. Learning disabilities are common in children with NF-1, with a reported frequency of 30 to 60 percent.³¹ When compared to the general population, those with NF-1 have been found to have lower IQs. There does not appear to be a specific profile of learning disabilities, as language-based learning problems (reading and spelling) are

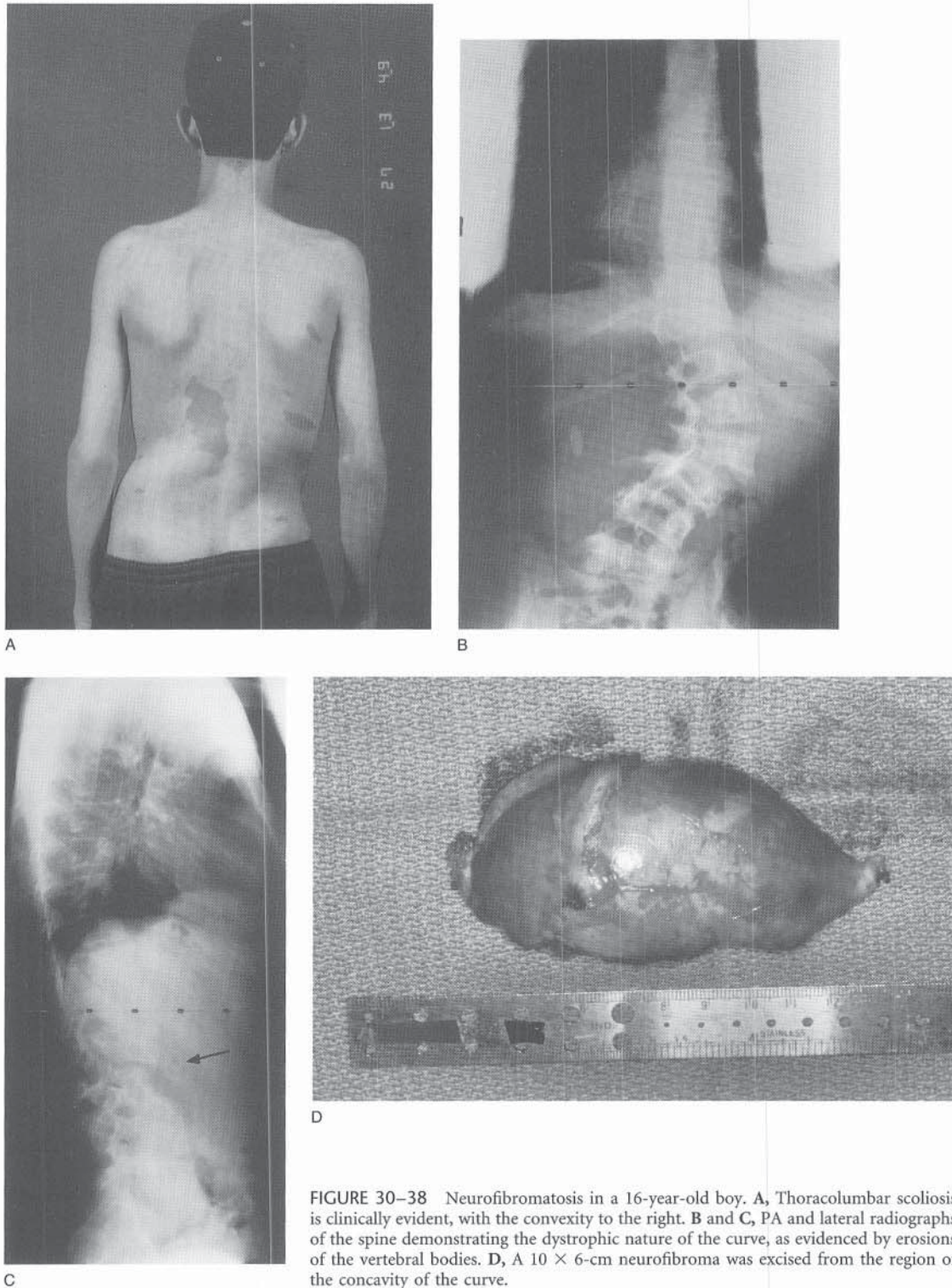


FIGURE 30-38 Neurofibromatosis in a 16-year-old boy. **A**, Thoracolumbar scoliosis is clinically evident, with the convexity to the right. **B** and **C**, PA and lateral radiographs of the spine demonstrating the dystrophic nature of the curve, as evidenced by erosions of the vertebral bodies. **D**, A 10 × 6-cm neurofibroma was excised from the region of the concavity of the curve.

as common as nonverbal learning deficits. Poor organizational skills and attentional skills tend to affect performance in many areas.

NEUROFIBROMATOSIS TYPE 2

Neurofibromatosis 2 (NF-2) is also an autosomal dominant disorder, although approximately 50 percent of new cases

result from spontaneous genetic mutation.²⁶ It has nearly full penetrance as measured by development of NF-2-associated tumors by age 18 years. Its incidence is 1 in 40,000 individuals, making it much less common than NF-1.¹³ No sex or ethnic predilection has been demonstrated. The musculo-skeletal deformities encountered in NF-1 are generally absent in NF-2, and there is essentially no overlap between the two types once a thorough examination is performed.

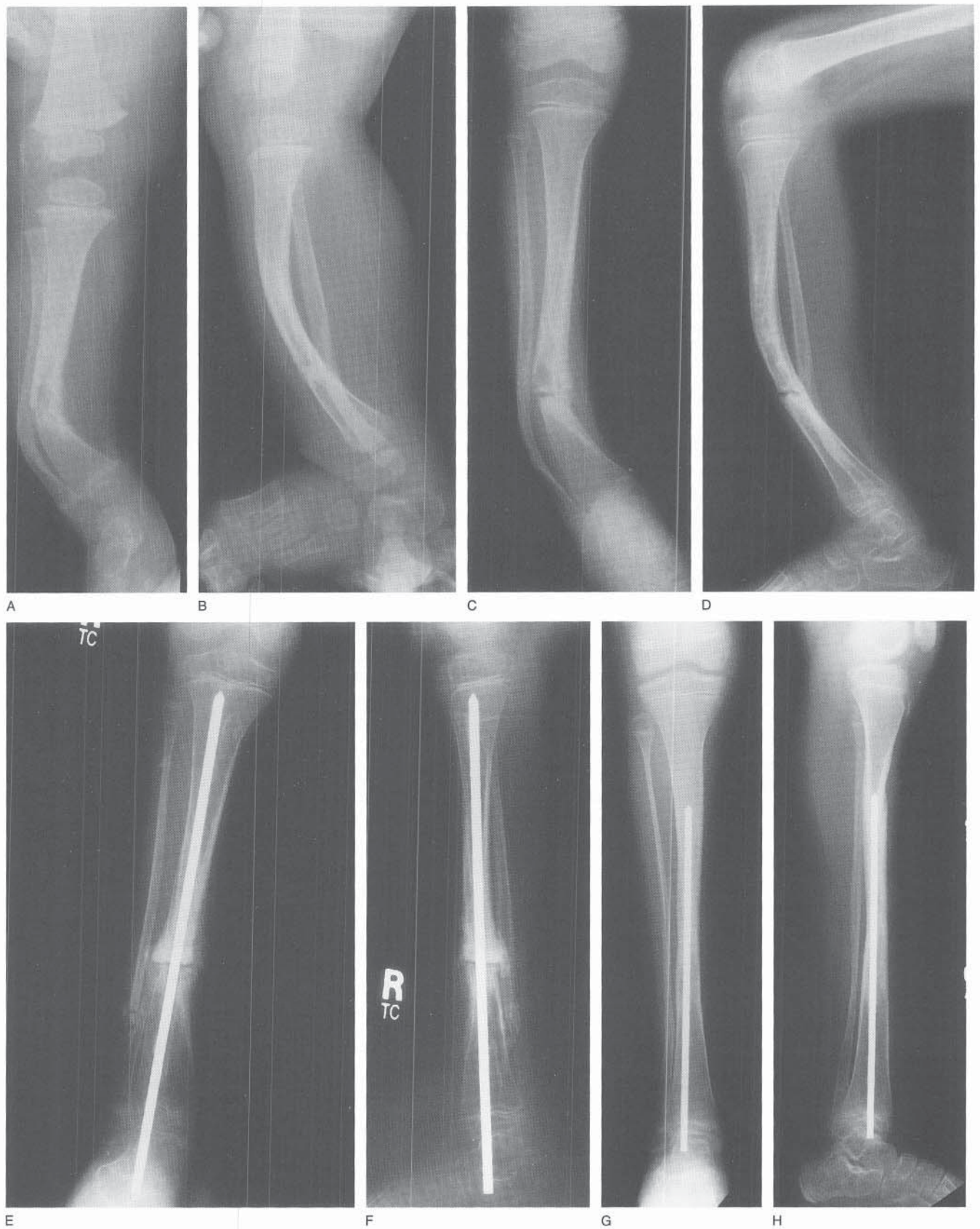

FIGURE 30-39 Congenital pseudarthrosis of the tibia in neurofibromatosis. **A and B**, Radiographs in a 1-year-old child showing severe anterolateral bowing. **C and D**, By age 5 years, a distinct pseudarthrosis from a fracture was evident at the apex of the deformity. **E and F**, After a failed attempt to achieve union of the fracture, a second surgical intervention with a Williams rod was undertaken at age 6 years 3 months. **G and H**, Six years later the patient was asymptomatic and had a mild lower limb length discrepancy.

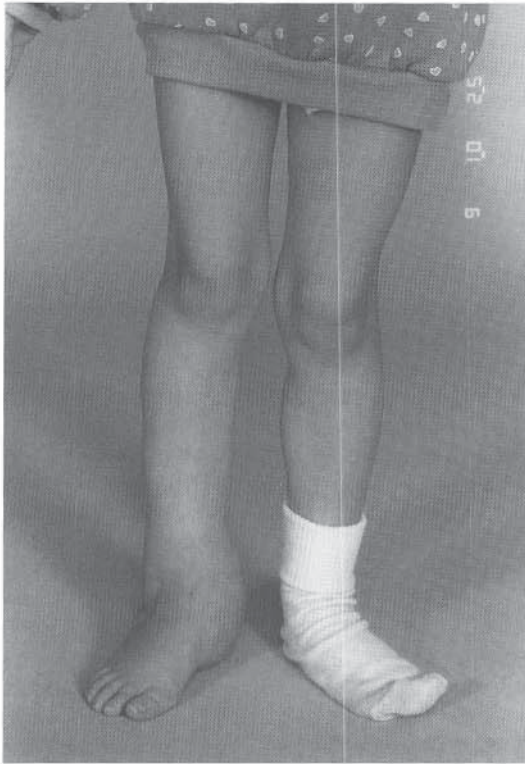


FIGURE 30–40 Hemihypertrophy of the right lower extremity in a girl age 4 years 5 months with neurofibromatosis.

The NIH Consensus Development Conference criteria for NF-2 are given in Table 30–4.^{12,17}

The NF-2 gene, located on the long arm of chromosome 22, was identified in 1993. It encodes a novel member of the protein 4.1 family of cytoskeletal-associated elements.^{35,39,40} Its protein product is merlin or schwannomin.

Vestibular schwannomas in the eighth cranial nerve occur in nearly every individual with NF-2.²⁶ These tumors are not seen in NF-1. In adulthood, patients exhibit progressive deterioration in hearing, ambulation difficulties, diminished vision, and chronic pain. When NF-2 is found in children,

TABLE 30–4 NIH Criteria for the Diagnosis of Neurofibromatosis Type 2

The diagnostic criteria for neurofibromatosis type 2 are met if a person has either of the following:

- Bilateral eighth nerve masses seen with appropriate imaging techniques (i.e., CT or MRI)
- A first-degree relative with neurofibromatosis 2 and either a unilateral eighth nerve mass or two of the following:
 - Neurofibroma
 - Meningioma
 - Glioma
 - Schwannoma
 - Juvenile posterior subcapsular lenticular opacity

From Crawford AH, Schorry EK: Neurofibromatosis in children: the role of the orthopaedist. *J Am Acad Orthop Surg* 1999;7:217. The criteria were formulated by an NIH Consensus Development Conference.

neurologic symptoms such as spinal cord compression or visual dysfunction are much more common than the symptoms referable to vestibular schwannomas.

Although schwannomas are the most common tumor type associated with NF-2, meningiomas occur in 50 percent of affected individuals. Spinal cord tumors are seen in more than 80 percent, but most remain asymptomatic.²⁷

REFERENCES

Neurofibromatosis

1. Akbarnia BA, Gabriel KR, Beckman E, et al: Prevalence of scoliosis in neurofibromatosis. *Spine* 1992;17:S244.
2. Barker D WE, Hguyen K, et al: Gene for von Recklinghausen's neurofibromatosis is in the pericentromeric region of chromosome 17. *Science* 1987;230:1100.
3. Calvert PT, Edgar MA, Webb PJ: Scoliosis in neurofibromatosis: the natural history with and without operation. *J Bone Joint Surg* 1989;71-B:246.
4. Cawthon RM, Weiss R, Xu G, et al: A major segment of the neurofibromatosis type 1 gene: cDNA sequence, genomic structure and point mutations. *Cell* 1990;62:193.
5. Chaglassian JH, Riseborough EJ, Hall JE: Neurofibromatous scoliosis: natural history and results of treatment in thirty-seven cases. *J Bone Joint Surg* 1976;58-A:695.
6. Cohen M: Further thoughts about the elephant man. *Am J Med Genet* 1988;29:777.
7. Crawford A: Neurofibromatosis. In Weinstein S (ed): *The Pediatric Spine: Principles and Practice*, p 619. New York, Raven Press, 1994.
8. Crawford AH: Pitfalls of spinal deformities associated with neurofibromatosis in children. *Clin Orthop* 1989;245:29.
9. Crawford AH, Schorry EK: Neurofibromatosis in children: the role of the orthopaedist. *J Am Acad Orthop Surg* 1999;7:217.
10. Crowe FW, Schull WJ, Neel JV: *A Clinical, Pathological and Genetic Study of Multiple Neurofibromatosis*. St. Louis, Charles C Thomas, 1956.
11. Di Simone RE, Berman AT, Schwentker EP: The orthopedic manifestation of neurofibromatosis: a clinical experience and review of the literature. *Clin Orthop* 1988;230:277.
12. Eldridge R: Consensus statement revisited. In Mulvihill JJ (moderator): Neurofibromatosis 1 (Recklinghausen disease) and neurofibromatosis 2 (bilateral acoustic neurofibromatosis): an update. *Ann Intern Med* 1990;113:39.
13. Evans DG, Huson HM, Donnai D, et al: A genetic study of type 2 neurofibromatosis in the United Kingdom. I. Prevalence, mutation rate, fitness, and confirmation of maternal transmission effect on severity. *J Med Genet* 1992;29:841.
14. Funasaki H, Winter RB, Lonstein JB, et al: Pathophysiology of spinal deformities in neurofibromatosis: an analysis of seventy-one patients who had curves associated with dystrophic changes. *J Bone Joint Surg* 1994;76-A:692.
15. Gabriel KR: Neurofibromatosis. *Curr Opin Pediatr* 1997;9:89.
16. Goldberg NS, Collins FS: The hunt for the neurofibromatosis gene. *Arch Dermatol* 1991;127:1705.
17. Gutmann DH, Aylsworth A, Carey JC, et al: The diagnostic evaluation and multidisciplinary management of neurofibromatosis 1 and neurofibromatosis 2. *JAMA* 1997;278:51.
18. Heim RA, Kam-Morgan LN, Binnie CG, et al: Distribution of 13 truncating mutations in the neurofibromatosis 1 gene. *Hum Mol Genet* 1995;4:975.
19. Holt JF: 1977 Edward B. D. Neuhauser Lecture: Neurofibromatosis in children. *AJR Am J Roentgenol* 1978;130:615.
20. Huson SM, Harper PS, Compston DAS: Von Recklinghausen neurofibromatosis: a clinical and population study in southeast Wales. *Brain* 1988;111:1355.
21. Joseph KN, Bowen JR, MacEwen GD: Unusual orthopedic manifestations of neurofibromatosis. *Clin Orthop* 1992;278:17.
22. Kim HW, Weinstein SL: Spine update: the management of scoliosis in neurofibromatosis. *Spine* 1997;22:2770.
23. Korf B: Diagnostic outcome in children with multiple cafe au lait spots. *Pediatrics* 1992;90:924.
24. Lam KS, Mehdian H, White B: The effects of simple trauma on patients

- with cervical spine neurofibromatosis: two case reports. *Eur Spine J* 1997;6:77.
25. Lubs ML, Bauer MS, Formas ME, et al: Lisch nodules in neurofibromatosis type 1. *N Engl J Med* 1991;324:1264.
 26. MacCollin M, Mautner VF: The diagnosis and management of neurofibromatosis 2 in childhood. *Semin Pediatr Neurol* 1998;5:243.
 27. Mautner VF, Tatagiba M, Lindenau M, et al: Spinal tumors in patients with neurofibromatosis type 2: MR imaging study of frequency, multiplicity, and variety. *AJR Am J Roentgenol* 1995;165:951.
 28. Morse RP: Neurofibromatosis type 1. *Arch Neurol* 1999;56:364.
 29. NIH Consensus Development Conference Statement: Neurofibromatosis. *Neurofibromatosis* 1988;1:172.
 30. North KN: Neurofibromatosis 1 in childhood. *Semin Pediatr Neurol* 1998;5:231.
 31. North KN, Riccardi V, Samango-Sprouse C, et al: Cognitive function and academic performance in neurofibromatosis 1: consensus statement from the NF1 Cognitive Disorders Task Force. *Neurology* 1997;48:1121.
 32. Obringer AC, Meadows AT, Zackai EH: The diagnosis of neurofibromatosis type 1 in the child under the age of six years. *Am J Dis Child* 1989;143:717.
 33. Ogilvie J: Neurofibromatosis. In Lonstein B, Winter R, Ogilvie J (eds): *Moe's Textbook of Scoliosis and Other Deformities*, p 33. Philadelphia, WB Saunders Co, 1994.
 34. Reith JD, Goldblum JR: Multiple cutaneous plexiform schwannomas: report of a case and review of the literature with particular reference to the association with types 1 and 2 neurofibromatosis and schwannomatosis. *Arch Pathol Lab Med* 1996;120:399.
 35. Rouleau GA, Merel P, Lutchman M, et al: Alteration in a new gene encoding a putative membrane-organizing protein causes neurofibromatosis type 2. *Nature* 1993;363:515.
 36. Seward G: The elephant man. Part 1. *Br Dent J* 1990;169:173.
 37. Sirois JL III, Drennan JC: Dystrophic spinal deformity in neurofibromatosis. *J Pediatr Orthop* 1990;10:522.
 38. Tilesius von Tilenau W: *Historia pathologica singularis cutis turpitudinis: Jo Godofredi Rheinhardi viri L annorum*. Leipzig, Germany, S. L. Crusius, 1793.
 39. Trofatter JA, MacCollin M, Rutter JL, et al: A novel moesin-, ezrin-, radixin-like gene is a candidate for the neurofibromatosis 2 tumor suppressor. *Cell* 1993;72:791.
 40. Tsukita S, Yonemura S, Tsukita S: ERM family: from cytoskeleton to signal transduction. *Curr Opin Cell Biol* 1997;9:70.
 41. Turra S, Santini S, Cagnoni G, et al: Gigantism of the foot: our experience in seven cases. *J Pediatr Orthop* 1998;18:337.
 42. von Recklinghausen F: *Über die multiplen Finbrome der Haut und ihre Beziehung zu den multiplen Neuromen*. Berlin, Germany, Hirschwald, 1882.
 43. Wallace MR, MD, Andersen LB, et al: Type 1 neurofibromatosis gene: identification of a large transcript disrupted in three NF 1 patients. *Science* 1990;249:181.
 44. Wilde PH, Upadhyay SS, Leong JC: Deterioration of operative correction in dystrophic spinal neurofibromatosis. *Spine* 1994;19:1264.

Fibrodysplasia Ossificans Progressiva

INTRODUCTION

Fibrodysplasia ossificans progressiva is a rare disorder of connective tissue differentiation that is characterized by congenital malformation of the great toe and progressive heterotopic ossification of tendons, ligaments, fascia, and skeletal muscle.¹⁻⁴ Previously it was also referred to as myositis ossificans progressiva. This condition usually becomes evident within the first 10 years of life, with an equal prevalence in males and females. The diagnosis can be readily established if the clinician, while assessing the progressively developing subfascial nodules or ossification, is aware of the relationship between fibrodysplasia ossificans progressiva and the great toe deformity. Otherwise, uncertainty as to the cause of the

painful lesions may lead to biopsy. In this disorder biopsy should be avoided, as it almost certainly exacerbates the condition and, depending on the stage of maturation of the biopsied specimen, can lead to some confusion as to the histologic diagnosis.

Usually fibrodysplasia ossificans progressiva begins in childhood as painful erythematous subfascial nodules most commonly located on the posterior neck and back. These individual nodules occasionally resolve but more often progressively worsen and eventually mature into heterotopic bone. This transformation, which begins in childhood, progresses throughout life, leading to numerous sites of heterotopic ossification. This ossification, in turn, spans normal joints and severely debilitates the individual by eliminating motion of the jaw, neck, spine, shoulders, hips, and more distal joints. Over the past 15 years, numerous medical disciplines have devoted attention to this debilitating rare disorder in hopes that a better understanding will lead to more effective treatment.

ETIOLOGY

The cause of fibrodysplasia ossificans progressiva remains in question. Most cases are due to new gene mutations.⁵ The gene or genes responsible for this disorder are unknown. Chromosomal anomalies have not yet been identified. An autosomal dominant mode of inheritance has been confirmed, with the most recent substantiation reported in 1993. Kaplan and colleagues reported on the transmission of this disorder from an affected parent to his offspring,¹⁴ and Connor and colleagues reported on a three-generation family with a wide range of phenotypic severity ranging from disabling ectopic bone formation and premature death to an asymptomatic adult whose only manifestation was characteristic big toe malformations.⁵ Maternal gonadal mosaicism may be another possible mode of transmission of this disorder, in light of a report of two affected half-sisters with the same unaffected mother and different unaffected fathers.¹² Reports such as these are rare, for several reasons. The condition itself is rare, reproductive fitness in affected patients appears to be low, the severe deformity may lead to difficulty with gestation and delivery, and there may also be a component of decreased fertility due to primary and secondary amenorrhea in patients.

It has been suggested that the genetic marker human leukocyte antigen B27 (HLA-B27) may be associated with fibrodysplasia ossificans progressive, as it is with ankylosing spondylitis, another disorder with less severe hyperostosis. Recent evidence refutes this, finding that the pathogenesis of these two disorders differs.³

Clinical tests have not demonstrated any enzymatic or metabolic abnormalities with the exception of mild, transient elevations in serum alkaline phosphatase levels during new episodes of heterotopic ossification.

CLINICAL FEATURES

The primary congenital skeletal abnormality in patients with fibrodysplasia ossificans progressiva is malformation of the great toes.³² The toes are short, tend to be in a valgus position, and have an abnormally shaped proximal phalanx (Fig. 30-41). They may become monophalangeal if the abnormal

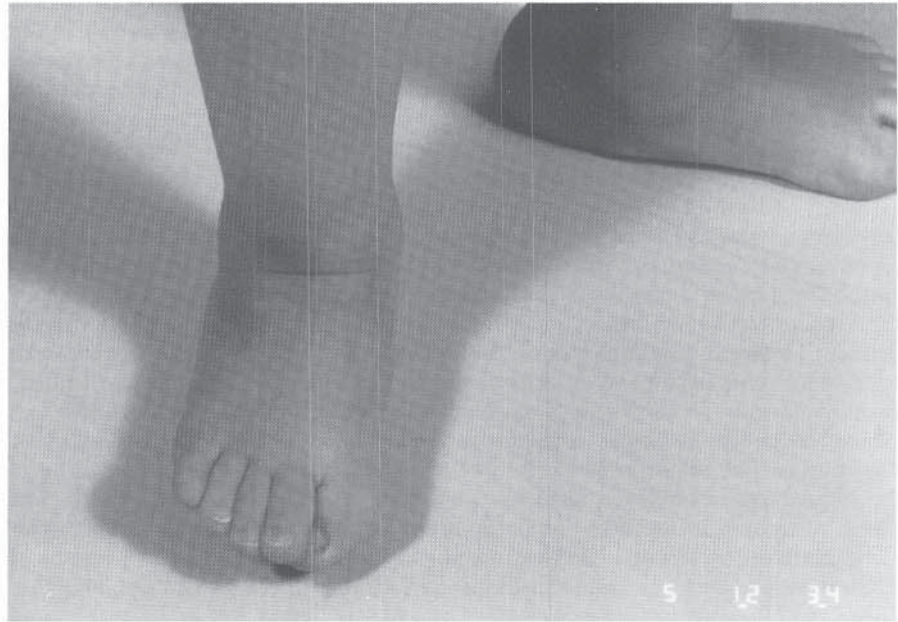
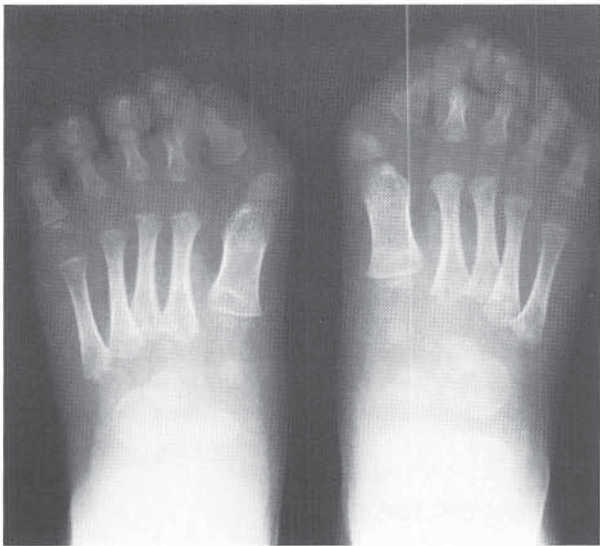
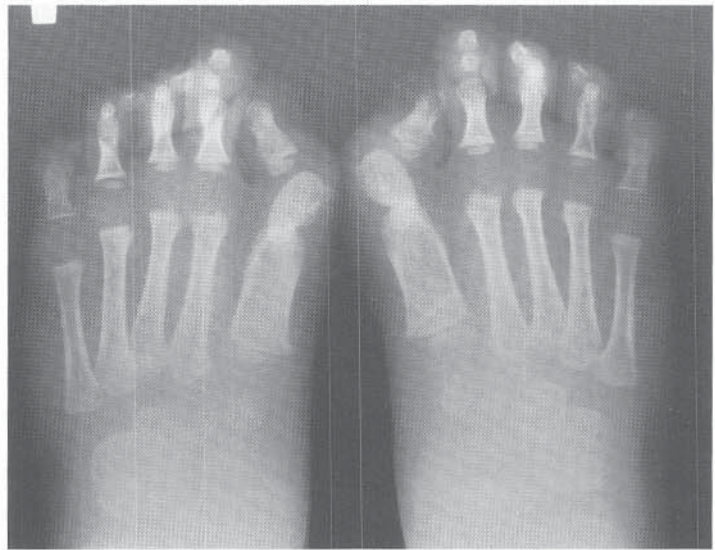


FIGURE 30–41 **A**, A 3-year-old boy with fibrodysplasia ossificans progressiva has short, valgus-positioned great toes. **B**, The proximal phalanx is abnormally shaped and the interphalangeal joint is fixed in valgus. **C**, In another 3-year-old, the proximal phalanx is fused to the first metatarsal.

A



B



C

epiphyses fuse. Often no attention is given to the toe deformity until the painful nodules or ossification develop. Some patients have clinically abnormal short thumbs due to short first metacarpals (Fig. 30–42).

The most common site of onset of the heterotopic ossification is the neck, followed by the spine and shoulder girdle (Fig. 30–43).⁴ Other primary sites that have been reported include the elbow and wrist, knee, and hip. The average age at onset is 5 years (range, birth to 25 years), and nearly 80 percent of the patients have some restrictive heterotopic ossification by age 7 years. By age 15, nearly 95 percent of patients have severely restricted mobility in the upper limbs. The typical pattern is for the heterotopic ossification to proceed in a direction that is axial to appendicular, cranial to caudad, and proximal to distal.

As the lesions develop they tend to go through several stages.¹⁸ During the first few weeks (the early lesion) pain, erythema, swelling, warmth, and tenderness are noted.²⁴ After several weeks (the intermediate lesion) the swelling begins to subside. There is a decrease in the pain, erythema, and tenderness but an increase in induration. After approximately 12 weeks (the late lesion) the swelling disappears and there remains a hard, nontender lesion that is visible radiographically as a new area of ossification. Severe disability subsequently develops secondary to the extra-articular ankylosis of the major joints.

In patients with fibrodysplasia ossificans progressiva, any form of trauma to the deep tissues is often a stimulus for new bouts of heterotopic ossification, including relatively minor events such as immunizations and dental injections.^{20,22,26} Patients can often date the onset of new lesions to the time of an otherwise minor soft tissue injury, and they frequently anticipate the onset of a focal flare-up within

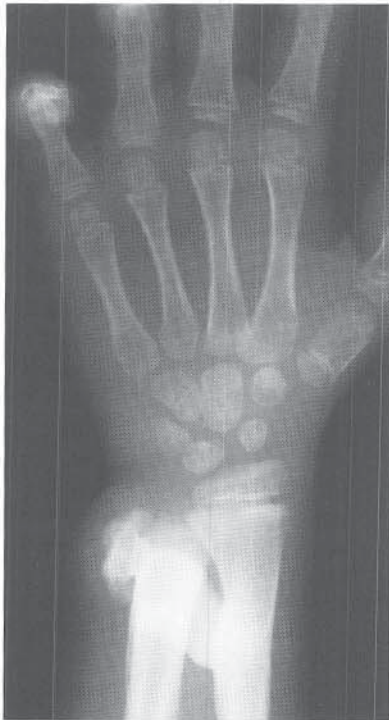

FIGURE 30–42 At age 8 years, the patient in Figure 30–41C has an extremely short first metacarpal and, clinically, has short thumbs.

several days following the trauma. Biopsies often trigger a clinical flare-up, but the mechanism is not understood. Unlike other forms of heterotopic ossification, the ossification that occurs in patients with fibrodysplasia ossificans progressiva is irreversible. Resection of a mature lesion invariably leads to the formation of new and more robust ossification.

Often the presenting limitation of motion occurs in the neck, as ossification matures along the cervical spine (Fig. 30–44). In addition to axial skeleton involvement, ossification occurs in the shoulder girdle and severely restricts motion of the upper extremities. Involvement of the wrists and elbows occurs much later, if at all. Likewise, as the disorder progresses in the lower extremities, limitation of range of motion occurs earlier in the hip than in the knee or ankle (Fig. 30–45).^{28,29} By age 30 most patients are capable of either a sitting or a standing position only. Few are able to both sit and stand with comfort and stability.

Limitation in jaw mobility creates great difficulty in feeding and maintaining adequate nutrition. Surgical attempts to restore mobility of the jaw through resection of ossified muscle have been unsuccessful.⁶

Spinal deformity is common in patients with fibrodysplasia ossificans progressiva.³¹ Approximately 65 percent of patients will have radiographic evidence of scoliosis and 42 percent will have hypokyphosis. These rapidly developing abnormalities are usually associated with spontaneously occurring lesions in the paravertebral soft tissues. These lesions ossify prior to skeletal maturity, forming unilateral bony bridges along the spine. This limits the growth on the ipsilateral side of the spine while growth continues uninhibited on the contralateral side. Over time, a severe scoliotic deformity may result (Fig. 30–46).

Fortunately the diaphragm, as well as the extraocular, cardiac, and smooth muscles are characteristically spared. Patients have extremely limited chest expansion and depend on diaphragmatic breathing. Lung volumes are reduced to approximately 44 percent of normal values, but flow rates are relatively normal.¹⁹ Electrocardiographic (ECG) evidence of right ventricular dysfunction is found in older patients with fibrodysplasia ossificans progressiva. The presence of severely restrictive chest wall disease is associated with a high incidence of right ventricular abnormalities on the ECG. Whether cor pulmonale eventually occurs has not been clearly demonstrated. Premature death may result from respiratory failure due to restricted movement of the thoracic cage or from inanition caused by ankylosis of the jaw.

RADIOGRAPHIC FEATURES

Radiographs of the heterotopic skeleton demonstrate features of normal bone modeling. These include the development of tubular and flat bones with mature cortical and trabecular organization, the presence of well-defined cortical-endosteal borders enclosing medullary canals, and the presence of metaphyseal funnelization in isolated ossicles or at sites of synostoses. Characteristics of bone remodeling include the response of heterotopic bone to weightbearing stress with osteosclerosis of use and osteopenia of disuse and the resistance of heterotopic bone to fatigue failure with the absence of pathologic fractures and stress fractures.¹⁷

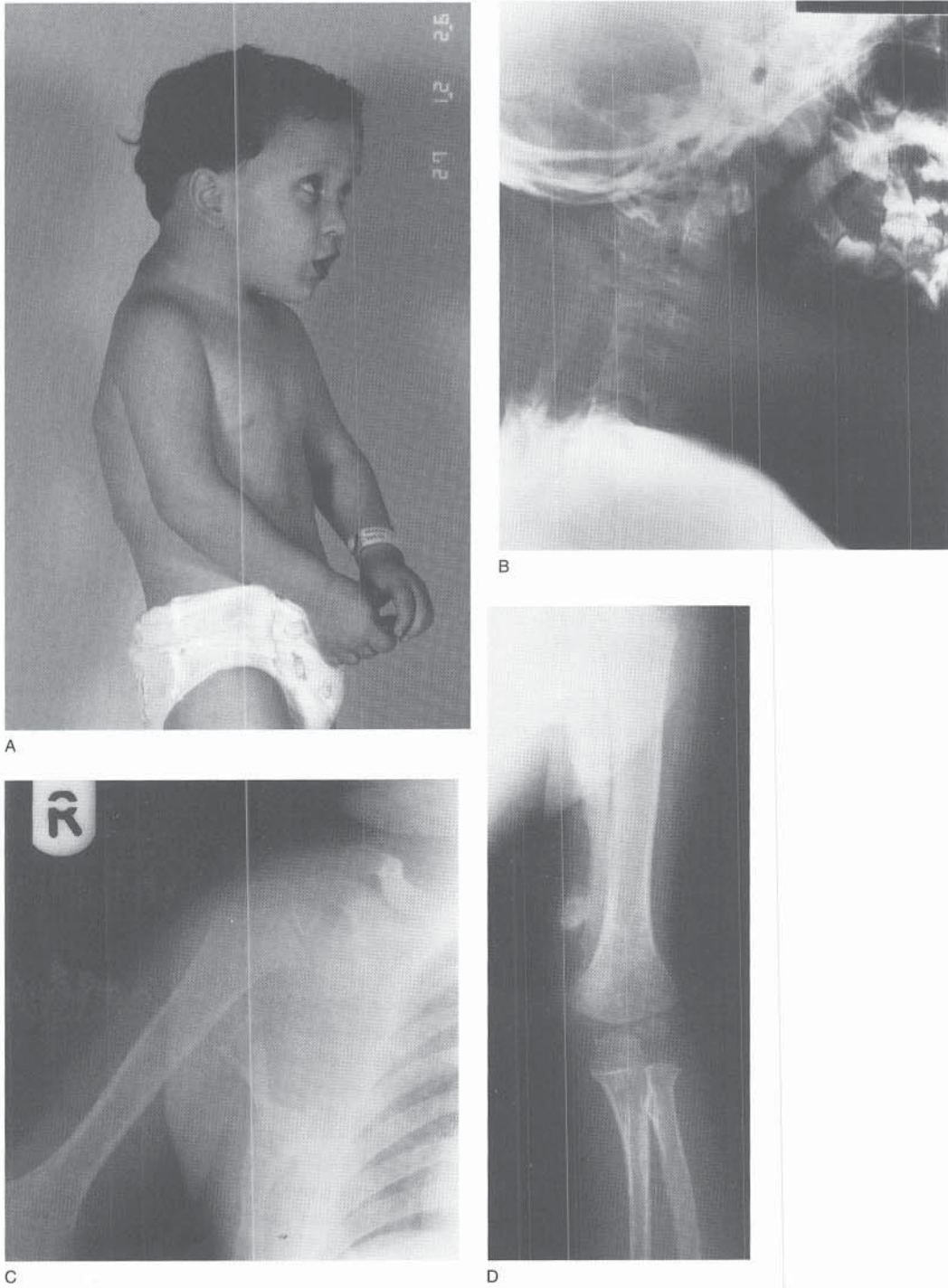


FIGURE 30-43 A, At age 4 years, the patient in Figure 30-41A had no range of motion of his neck due to heterotopic ossification in the posterior soft tissues (B). C and D, Neither of his shoulders had any mobility.

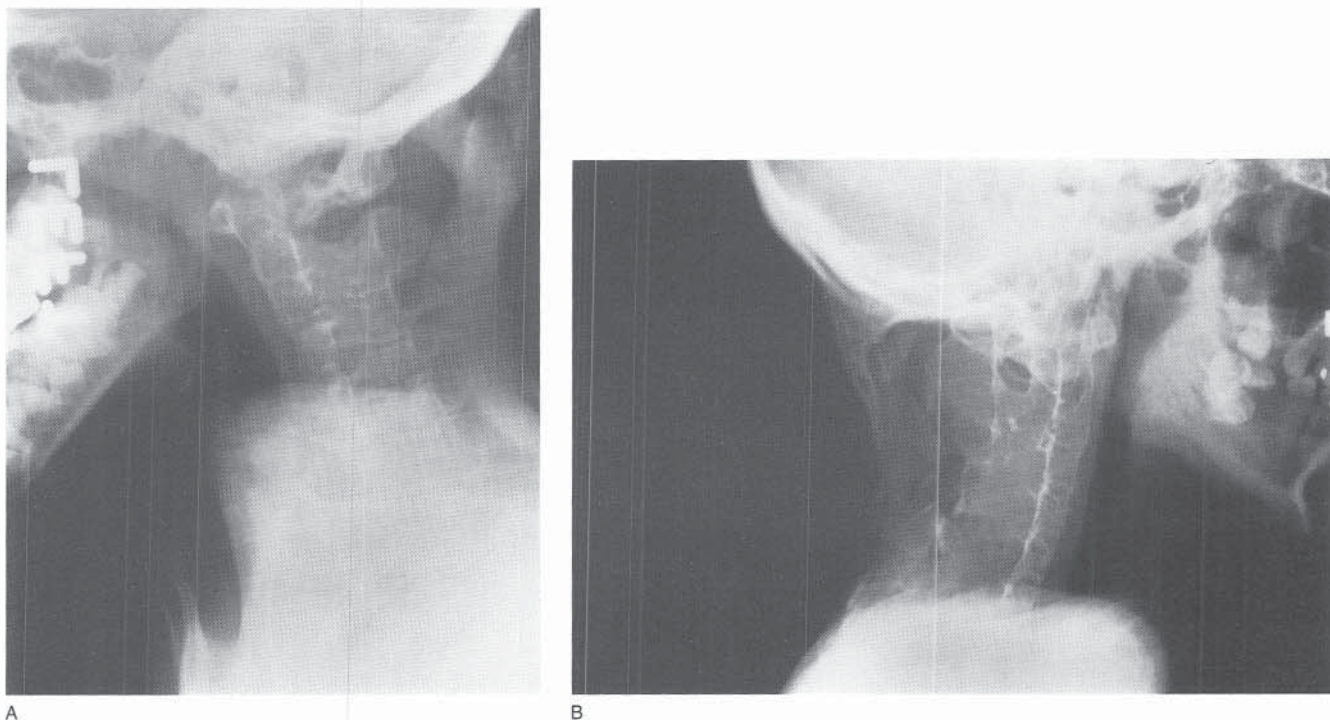


FIGURE 30-44 Fibrodysplasia ossificans progressiva. **A**, At age 6 years, the patient in Figure 30-42 had ossification of the soft tissue of his neck. **B**, Thirteen years later, the cervical spine had completely fused.

HISTOLOGY

The earliest lesions of fibrodysplasia ossificans progressiva consist of loose myxoid fibrous tissue resembling the lesions found in juvenile fibromatosis.¹⁸ The fibroblastic proliferation infiltrates and replaces normally formed fibrous connective tissue and striated muscle. Numerous small blood vessels are prominent in early lesions. Cells immunoreactive for S-100 protein (expressed in chondroblasts) and cartilaginous foci are scattered among proliferating fibroblasts. Intense

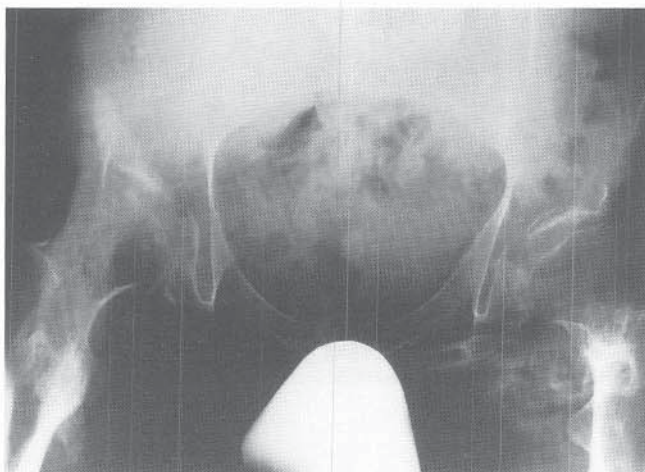


FIGURE 30-45 Fibrodysplasia ossificans progressiva. At age 19, the patient in Figure 30-44 had hips that were clinically ankylosed in 45 degrees of flexion.

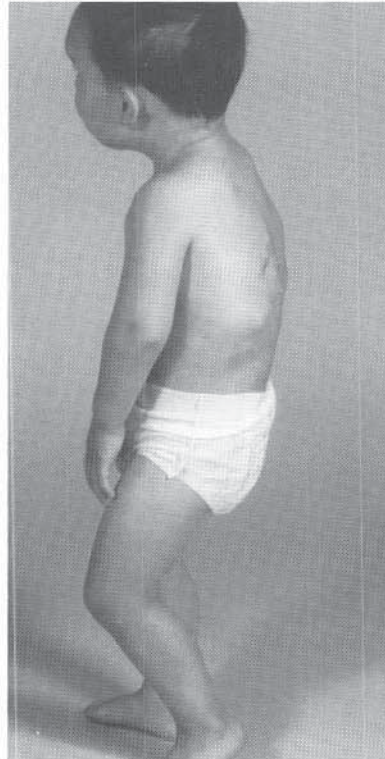
perivascular lymphocytic infiltration into normal-appearing skeletal muscle has also been found in the very early stages of fibrodysplasia ossificans progressiva.

Endochondral ossification is the prominent and identifying histologic feature of maturing lesions. Cartilage and bone formation gradually replaces the fibroblastic proliferation in muscle and adjacent connective tissue. The newly developed marrow cavity is adipose. Only the absence of normal anatomic orientation reveals this bone as being abnormal.

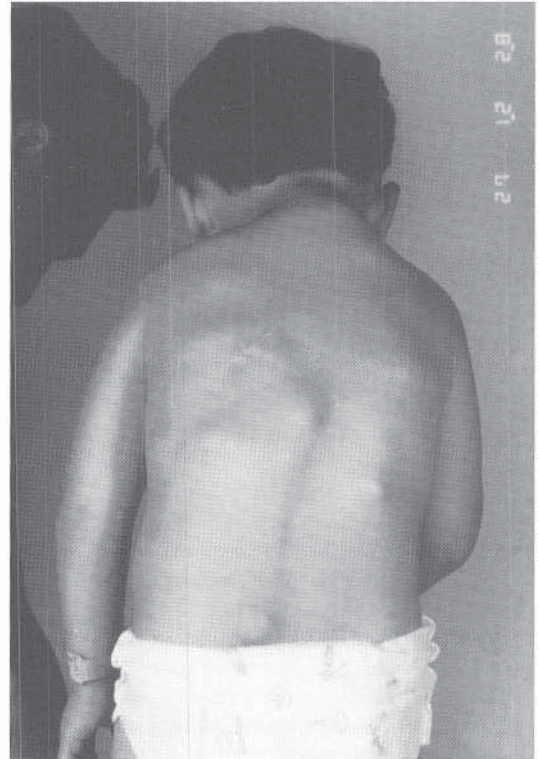
The finding of intense perivascular lymphocytic infiltration in the early lesions has lent support to a recent discovery that lymphocytes may play a role in the biochemical pathogenesis of heterotopic ossification and fibrodysplasia ossificans progressiva.¹⁰ Bone morphogenetic protein-4 (BMP-4), a potent osteogenic morphogen, is uniquely overexpressed in the lymphoblastoid cells in periosteal fibroproliferative lesion cells of patients with fibrodysplasia ossificans progressiva.^{9,10,21,27,30,33,34} BMP-4 is responsible for directing the formation and regeneration of the skeletal and hematopoietic systems in vertebrates. Its presence provides a unique perspective that eventually may lead to successful understanding and treatment of fibrodysplasia ossificans progressiva. Certainly this is one of the first genetic diseases in humans associated with the disorder of, and the expression of, BMP-4.

Abnormal levels of basic fibroblast growth factor have also been found in patients with fibrodysplasia ossificans progressiva.¹³ Basic fibroblast growth factor is an extremely potent *in vivo* stimulator of angiogenesis and is elevated in the urine during acute flare-ups of fibrodysplasia ossificans progressiva. This may provide a biochemical basis for con-

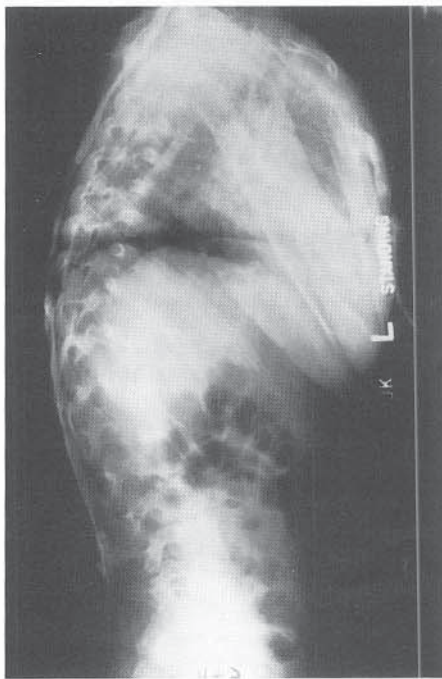
FIGURE 30–46 Fibrodysplasia ossificans progressiva. **A** to **C**, At age 4 years, the patient in Figure 30–43 also had numerous sites of ossification in the paravertebral tissues of his back. **D**, This limited growth led to a 47-degree scoliotic deformity of the lumbar spine. **E**, Because of the likelihood that the progressive scoliosis would create excessive deformity between the trunk and pelvis, anterior fusion of the lumbar spine was performed. The scoliosis remained stabilized at 48 degrees 4 years postoperatively.



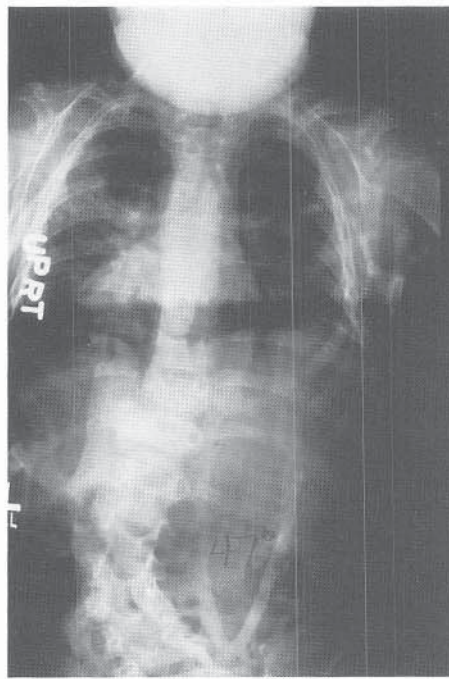
A



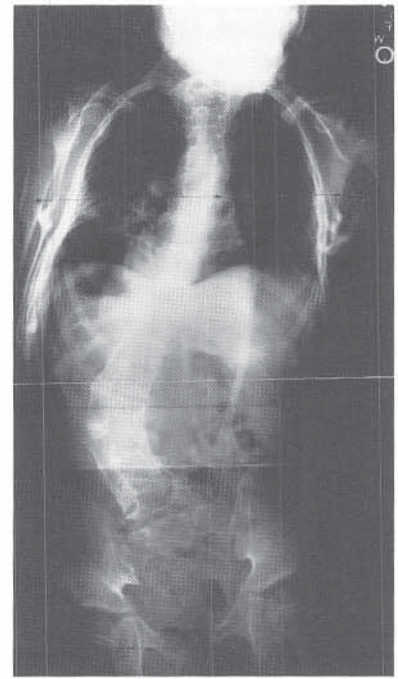
B



C



D



E

sidering antiangiogenic therapy for inhibiting endochondral osteogenesis in this disorder.

This new information regarding BMP-4 and basic fibroblast growth factor provides support for the concept that defective regulation of the induction of endochondral osteogenesis is the main pathogenetic mechanism in fibrodysplasia ossificans progressiva.

TREATMENT

Tripping and falling can be catastrophic in patients with fibrodysplasia ossificans progressiva.¹¹ Two-thirds of falls lead to a painful flare-up of disease activity and half of all falls lead to permanent disability, particularly if trauma to the head occurs. Therefore, precautionary measures should be taken to minimize the risk of injury without compromising the patient's functional level and independence. These recommendations include limiting high-risk activities, using protective head gear, installing safety measures in living environments, and augmenting stabilizing and protective functions.

Fractures that occur in either the normal bone or heterotopic bone can be expected to heal uneventfully, although other sites of ossification may evolve.⁸

Surgical excision of heterotopic bone is futile, as any form of trauma (including operative) predictably leads to the stimulation of even more abundant heterotopic ossification. This makes the orthopaedic management of patients very difficult, especially of patients with severe spinal deformities or ankylosed lower extremities fixed in an awkward position. If the lower extremities require repositioning for improved sitting, the patient and surgeon must be prepared for the possibility of other lesions developing secondary to the operative stress. Deformity of the spine is very perplexing. Operative intervention for scoliosis deformities has been shown to exacerbate the disease. Equally worrisome, in the young patient, anterior growth of a scoliotic spine that is tethered posteriorly can lead to significant deformity and pelvic obliquity. A recent study reported that the risks associated with operative correction of spinal deformities in fibrodysplasia ossificans progressiva may outweigh the benefits.³¹ However, in an occasional patient the risk of progressive spinal deformity may warrant surgical arthrodesis (Fig. 30–46).

These patients also present difficult anesthetic risks because of neck stiffness, small oral access, restrictive pulmonary disease, and abnormalities in cardiac conduction.^{23,25}

There is no known, clearly effective medical therapy for fibrodysplasia ossificans progressiva. Etidronate has been studied because of its inhibitory effect on bone mineralization and its potential to impair the rapid ossification process observed after acute episodes of fibrodysplasia ossificans progressiva. The results of studies utilizing intravenous administration of etidronate and oral steroids suggest that these agents may provide some benefit.² More controlled data on the spontaneous resolution of early flare-ups, however, are needed to clarify the true benefit of this management. Isotretinoin (13-*cis*-retinoic acid) also inhibits differentiation of mesenchymal tissue into cartilage and bone. A study examining the effectiveness of isotretinoin was unable to determine whether it was effective or detrimental in preventing disease flare-ups in regions that had even minimal heterotopic ossification at the time therapy began.³⁵ The

authors recommended extreme caution when using this medication in patients with fibrodysplasia ossificans progressiva.

At the current time, for early lesions it is reasonable to use anti-inflammatory drugs, including corticosteroids, in addition to analgesics and etidronate until the acute phase subsides. Etidronate must be used cautiously, as excessive doses have a deleterious but reversible affect on metaphyseal bone (rachitic-like changes).³²

With modern treatment, particularly the ability to provide nutrition and airway management, relatively long-term survival is possible.

REFERENCES

Fibrodysplasia Ossificans Progressiva

1. Brantus JF, Meunier PJ: Effects of intravenous etidronate and oral corticosteroids in fibrodysplasia ossificans progressiva. *Clin Orthop* 1998;346:117.
2. Bridges AJ, Hsu KC, Singh A, et al: Fibrodysplasia (myositis) ossificans progressiva. *Semin Arthritis Rheum* 1994;24:155.
3. Calvert GT, Shore EM: Human leukocyte antigen B27 allele is not correlated with fibrodysplasia ossificans progressiva. *Clin Orthop* 1998;346:66.
4. Cohen RB, Hahn GV, Tabas JA, et al: The natural history of heterotopic ossification in patients who have fibrodysplasia ossificans progressiva: a study of forty-four patients. *J Bone Joint Surg* 1993;75-A:215.
5. Connor JM, Skirton H, Lunt PW: A three generation family with fibrodysplasia ossificans progressiva [see comments]. *J Med Genet* 1993;30:687.
6. Crofford LJ, Brahim JS, Zasloff MA, et al: Failure of surgery and isotretinoin to relieve jaw immobilization in fibrodysplasia ossificans progressiva: report of two cases. *J Oral Maxillofac Surg* 1990;48:204.
7. Delatycki M, Rogers JG: The genetics of fibrodysplasia ossificans progressiva. *Clin Orthop* 1998;346:15.
8. Einhorn TA, Kaplan FS: Traumatic fractures of heterotopic bone in patients who have fibrodysplasia ossificans progressiva: a report of 2 cases. *Clin Orthop* 1994;308:173.
9. Gannon FH, Kaplan FS, Olmsted E, et al: Bone morphogenetic protein 2/4 in early fibromatous lesions of fibrodysplasia ossificans progressiva. *Hum Pathol* 1997;28:339.
10. Gannon FH, Valentine BA, Shore EM, et al: Acute lymphocytic infiltration in an extremely early lesion of fibrodysplasia ossificans progressiva. *Clin Orthop* 1998;346:19.
11. Glaser DL, Rocke DM, Kaplan FS: Catastrophic falls in patients who have fibrodysplasia ossificans progressiva. *Clin Orthop* 1998;346:110.
12. Janoff HB, Muenke M, Johnson LO, et al: Fibrodysplasia ossificans progressiva in two half-sisters: evidence for maternal mosaicism. *Am J Med Genet* 1996;61:320.
13. Kaplan F, Sawyer J, Connors S, et al: Urinary basic fibroblast growth factor: a biochemical marker for preosseous fibroproliferative lesions in patients with fibrodysplasia ossificans progressiva. *Clin Orthop* 1998;346:59.
14. Kaplan FS, McCluskey W, Hahn G, et al: Genetic transmission of fibrodysplasia ossificans progressiva: report of a family. *J Bone Joint Surg* 1993;75-A:1214.
15. Kaplan FS, Shore EM, Zasloff MA: Fibrodysplasia ossificans progressiva: searching for the skeleton key [editorial]. *Calcif Tissue Int* 1996;59:75.
16. Kaplan FS, Smith RM: Fibrodysplasia ossificans progressiva (FOP). *J Bone Miner Res* 1997;12:855.
17. Kaplan FS, Strear CM, Zasloff MA: Radiographic and scintigraphic features of modeling and remodeling in the heterotopic skeleton of patients who have fibrodysplasia ossificans progressiva. *Clin Orthop* 1994;304:238.
18. Kaplan FS, Tabas JA, Gannon FH, et al: The histopathology of fibrodysplasia ossificans progressiva: an endochondral process. *J Bone Joint Surg* 1993;75-A:220.
19. Kussmaul WG, Esmail AN, Sagar Y, et al: Pulmonary and cardiac function in advanced fibrodysplasia ossificans progressiva. *Clin Orthop* 1998;346:104.
20. Lanchoney TF, Cohen RB, Rocke DM, et al: Permanent heterotopic

ossification at the injection site after diphtheria-tetanus-pertussis immunizations in children who have fibrodysplasia ossificans progressiva. *J Pediatr* 1995;126(5 pt 1):762.

21. Lanchoney TF, Olmsted EA, Shore EM, et al: Characterization of bone morphogenetic protein 4 receptor in fibrodysplasia ossificans progressiva. *Clin Orthop* 1998;346:38.
22. Luchetti W, Cohen RB, Hahn GV, et al: Severe restriction in jaw movement after routine injection of local anesthetic in patients who have fibrodysplasia ossificans progressiva. *Oral Surg Oral Med Oral Pathol Oral Radiol Endod* 1996;81:21.
23. Meier R, Bolliger KP: [Anesthesiologic problems in patients with fibrodysplasia ossificans progressiva]. *Anaesthesist* 1996;45:631.
24. Moriatis JM, Gannon FH, Shore EM, et al: Limb swelling in patients who have fibrodysplasia ossificans progressiva. *Clin Orthop* 1997;336:247.
25. Newton MC, Allen PW, Ryan DC: Fibrodysplasia ossificans progressiva. *Br J Anaesth* 1990;64:246.
26. Nussbaum BL, O'Hara I, Kaplan FS: Fibrodysplasia ossificans progressiva: report of a case with guidelines for pediatric dental and anesthetic management. *ASDC J Dent Child* 1996;63:448.
27. Olmsted EA, Gannon FH, Wang ZQ, et al: Embryonic overexpression of the c-Fos protooncogene: a murine stem cell chimera applicable to the study of fibrodysplasia ossificans progressiva in humans. *Clin Orthop* 1998;346:81.
28. Rocke DM, Zasloff M, Peeper J, et al: Age- and joint-specific risk of initial heterotopic ossification in patients who have fibrodysplasia ossificans progressiva. *Clin Orthop* 1994;301:243.
29. Sawyer JR, Klimkiewicz JJ, Iannotti JP, et al: Mechanism for superior subluxation of the glenohumeral joint in fibrodysplasia ossificans progressiva. *Clin Orthop* 1998;346:130.
30. Shafritz AB, Shore EM, Gannon FH, et al: Overexpression of an osteogenic morphogen in fibrodysplasia ossificans progressiva [see comments]. *N Engl J Med* 1996;335:555.
31. Shah PB, Zasloff MA, Drummond D, et al: Spinal deformity in patients who have fibrodysplasia ossificans progressiva. *J Bone Joint Surg* 1994;76-A:1442.
32. Smith R: Fibrodysplasia (myositis) ossificans progressiva: clinical lessons from a rare disease. *Clin Orthop* 1998;346:7.
33. Wozney JM, Rosen V: Bone morphogenetic protein and bone morphogenetic protein gene family in bone formation and repair. *Clin Orthop* 1998;346:26.
34. Xu M, Shore EM: Mutational screening of the bone morphogenetic protein 4 gene in a family with fibrodysplasia ossificans progressiva. *Clin Orthop* 1998;346:53.
35. Zasloff MA, Rocke DM, Crofford LJ, et al: Treatment of patients who have fibrodysplasia ossificans progressiva with isotretinoin. *Clin Orthop* 1998;346:121.

Ehlers-Danlos Syndrome

Ehlers-Danlos syndrome comprises a group of inherited disorders characterized by abnormalities of collagen metabolism, which results in varying degrees of joint laxity, skin hyperelasticity, and abnormalities of other organs. In 1682, Job van Meeckeren described the first case, noting "extraordinary dilatability of the skin."¹¹ Ehlers, in 1901, described patients with loose-jointedness and subcutaneous hemorrhages.⁴ Danlos, in 1908, added subcutaneous tumors that may develop at pressure points to the description.³ Although more than 13 types of Ehlers-Danlos syndrome have been identified, some characteristics are common among those afflicted.

CLINICAL FEATURES

Skin manifestations vary from mild to extreme laxity (Fig. 30-47). In some cases the patient's skin can be pulled over the elbow out 10 to 15 cm, with remarkably delayed relaxation. Elastic skin over the palms and soles of the feet (Fig.

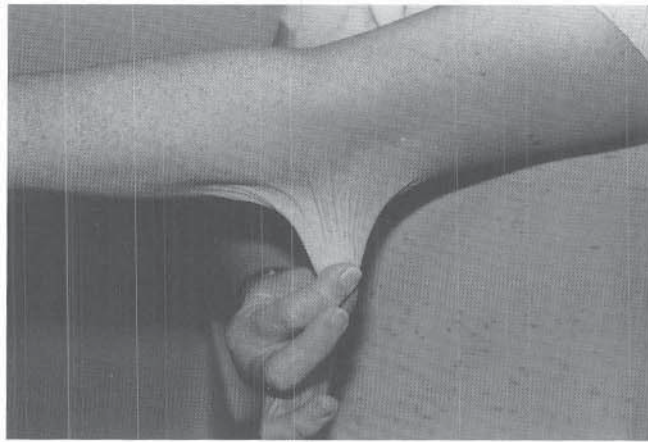


FIGURE 30-47 Hyperlaxity of the skin of the elbow in Ehlers-Danlos syndrome.

30-48) causes excessive motion in these areas of normally immobile skin. The skin in some individuals is extremely thin, being described as similar to cigarette paper or parchment (Fig. 30-49). Some patients bruise easily, and hyperpigmentation in the bruised areas may persist. In other individuals masses called pseudotumors form at sites of friction such as the elbows, heels, and knees. Bleeding gums occur in some forms of Ehlers-Danlos syndrome.

Joint hypermobility is present in all forms. In most cases there is hyperextensibility of the joints of the fingers, wrists, elbows, knees, and ankles (Fig. 30-50). Specific degrees of hypermobility of these five areas have been considered diagnostic of pathologic laxity by Wynne-Davies (Fig. 30-51).¹² In more severe cases, the joints can be distracted to an excessive degree. Some patients have a history of recurrent dislocation of the patellae or shoulders. In the most severe cases, joint dislocations become chronic or fixed. Many patients have chronic joint pains, most often in the shoulders, hands, and knees. The pain usually is refractory to interventions.⁹ Chronic effusions and hemarthrosis are sometimes present.

Scoliosis, spondylolisthesis, and atlantoaxial instability occur occasionally.

Pulmonary and intestinal ruptures occur in type IV

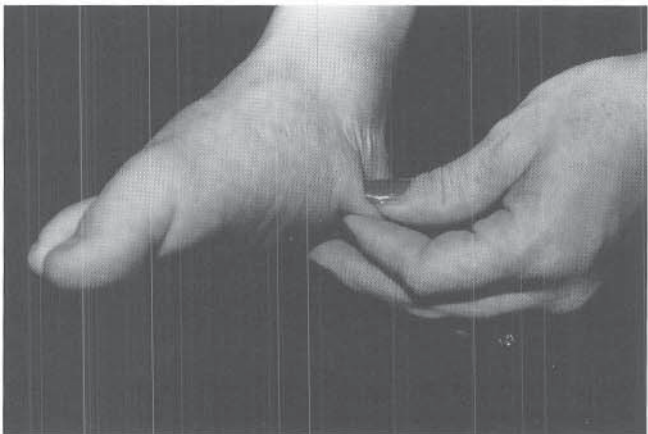


FIGURE 30-48 Hyperlaxity of the skin on the sole of the foot in Ehlers-Danlos syndrome.

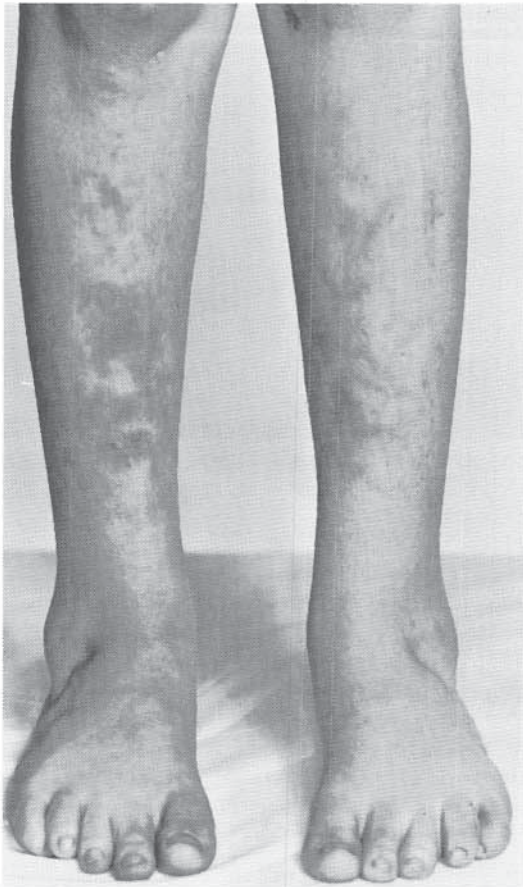

FIGURE 30-49 Ehlers-Danlos syndrome. Note the hyperpigmented, cigarette paper-like skin of the legs in a 10-year-old boy.

Ehlers-Danlos syndrome. Wound dehiscence may be a problem in any patient with skin fragility.

CLASSIFICATION

The eight commonly identified types of Ehlers-Danlos syndrome, named in the Berlin nosology in 1986 by Beighton and associates,¹ are described below.

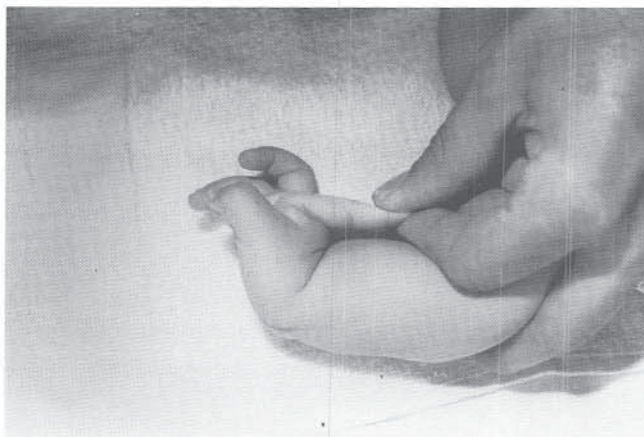


FIGURE 30-50 Hyperextension of the metacarpal joint of the index finger in Ehlers-Danlos syndrome.

Type I (Gravis). Type I is a severe form, with marked skin and joint laxity. Recurrent bruising is common, resulting in persistent areas of hyperpigmentation. All tissues are friable, and subcutaneous nodules may be present. The inheritance is autosomal dominant.

Type II (Mitis). Type II is a mild form that is similar to type I but with less severe degrees of laxity of the skin and joints. Inheritance also is autosomal dominant.

Type III (Benign Hypermobile). Type III is primarily notable for joint hyperlaxity. There are few skin findings. Scar formation is normal. This type of Ehlers-Danlos syndrome is commonly seen in orthopaedic practice, and often is not specifically diagnosed. The clinician should take into account the characteristics of this syndrome when planning surgical procedures such as stabilization of recurrent patellar or shoulder dislocations. In these patients, soft tissue repairs may gradually stretch out, negating the effects of a careful surgical repair. The floppy mitral valve syndrome occurs in this group. Inheritance is autosomal dominant.

Type IV (Ecchymotic). Type IV is characterized by very thin pale skin that is minimally hyperextensible but bruises easily, with resultant pigmented scars. Only the joints of the hands are hyperextensible. In this type, vascular and bowel rupture may occur.¹⁰ Mitral valve prolapse is also associated with type IV.⁵ The basic defect is a decrease in the production of type III collagen. Inheritance is either autosomal dominant or recessive.

Type V. Type V also is noted for fragility and hyperextensibility of the skin, with limited joint hypermobility. Inheritance is through an X-linked recessive mode.

Type VI. Type VI is characterized by moderate skin and joint laxity. Patients have ectopy of the lens of the eye, and scoliosis occurs; thus, type VI has been termed the *ocular-scoliotic* type of Ehlers-Danlos syndrome. The biochemical defect is a deficiency of lysine hydroxylase, resulting in lowered hydroxylysine content and poor cross-linking in the collagen.⁸ Inheritance is autosomal recessive.

Type VII. Type VII is also called *arthrochalasia multiplex congenita* because of the extreme hyperlaxity of the joints. The patients are of short stature. The basic defect is a deficiency in procollagen peptidase and an abnormal alpha₂ chain of the collagen. The collagen deficit of this type of Ehlers-Danlos syndrome is similar to that found in osteogenesis imperfecta type IV. Ehlers-Danlos syndrome type VII does not have bone fragility and osteogenesis imperfecta type IV does not have joint instability, but both conditions have joint laxity. Inheritance is autosomal dominant.⁶

Type VIII. Type VIII is characterized by progressive periodontal disease in addition to joint and skin hyperlaxity. Inheritance is autosomal dominant.⁷

A revised classification of Ehlers-Danlos syndrome has been proposed by Beighton and associates in which each type is identified by major and minor criteria and by biochemical etiology (Table 30-5).²

REFERENCES

Ehlers-Danlos Syndrome

1. Beighton P, de Paepe A, Danks D, et al: International nosology of heritable disorders of connective tissue, Berlin, 1986. *Am J Med Genet* 1988;29:581.

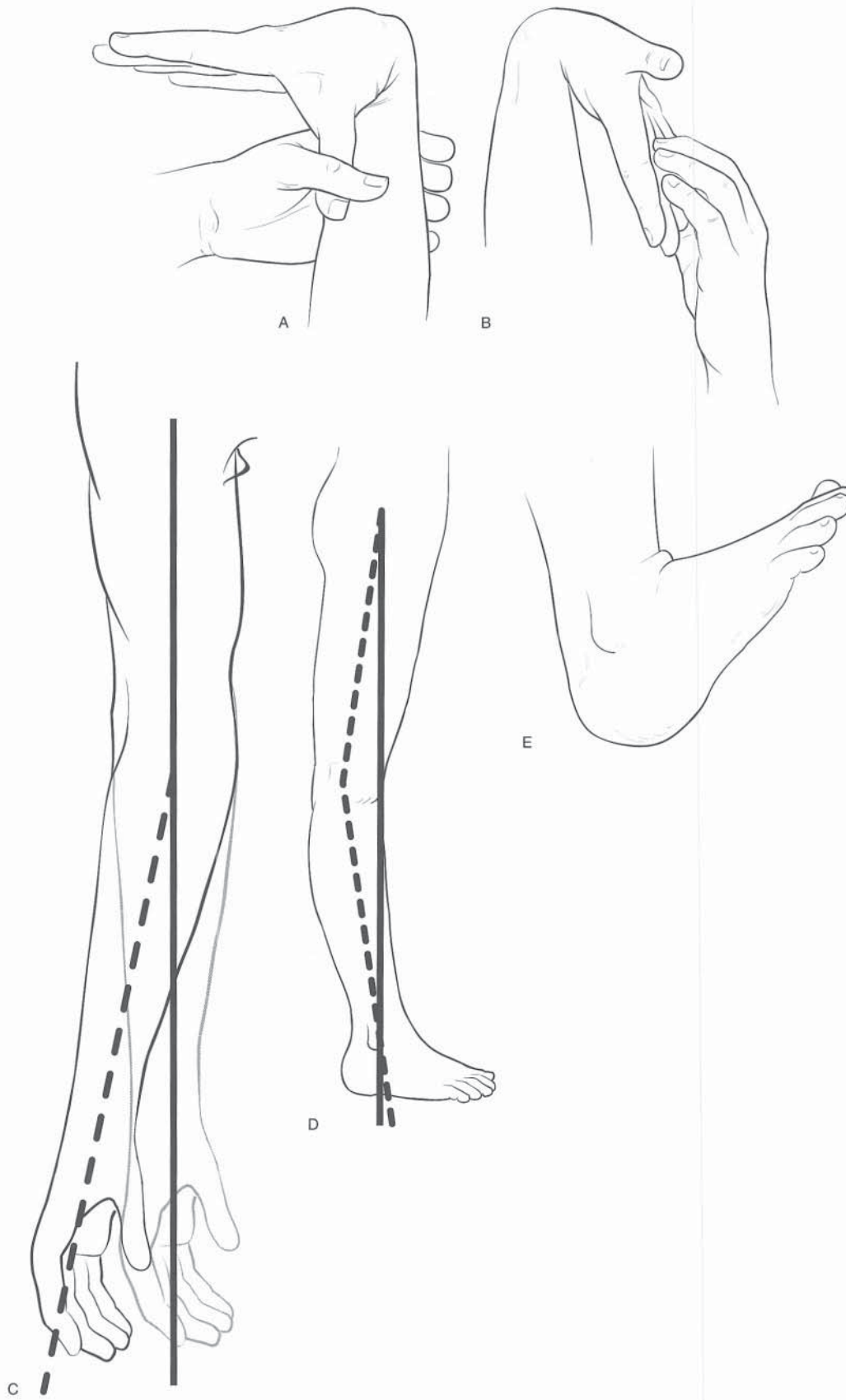


FIGURE 30-51 The criteria for ligamentous laxity (after Wynne-Davies). A, Flexion of the thumb to the volar forearm. B, Dorsiflexion of the fingers parallel to the forearm. C, Hyperextension of the elbow to 15 degrees. D, Hyperextension of the knee to 15 degrees. E, Dorsiflexion of the ankle to 60 degrees. (From Wynne-Davies R: Acetabular dysplasia and familial joint laxity: two etiological factors in congenital dislocation of the hip. A review of 589 patients and their families. *J Bone Joint Surg* 1970;52-B:704.)

TABLE 30-5 Revised Classification of Ehlers-Danlos Syndrome

Type	Inheritance	Major Criteria	Minor Criteria	Etiology
Classic	Autosomal dominant	Skin hyperextensibility; widened atrophic scars; joint hypermobility	Smooth, velvety skin; molluscoid pseudotumors; subcutaneous spheroids; complications of joint hypermobility; muscle hypotonia; easy bruising; manifestations of tissue extensibility and fragility; surgical complications	No uniform cause known
Hypermobility	Autosomal dominant	Skin involvement; generalized joint hypermobility	Recurring joint dislocations; chronic joint/limb pain; positive family history	Unknown
Vascular	Autosomal dominant	Thin, translucent skin; arterial/intestinal/uterine fragility or rupture; characteristic facial appearance	Acrogeria; hypermobility of small joints; tendon and muscle rupture; clubfoot; early-onset varicose veins; arteriovenous, carotid-cavernous sinus fistula; pneumothorax; gingival recession; positive family history; sudden death in a close relative	Structurally abnormal collagen type III or mutation in COL3A1 gene
Kyphoscoliosis	Autosomal recessive	Generalized joint laxity; severe muscle hypotonia at birth; scoliosis at birth (progressive); scleral fragility and rupture of the ocular globe	Tissue fragility, including atrophic scars, easy bruising; arterial rupture; marfanoid habitus; microcornea; radiologic osteopenia; family history	Deficiency in lys1 hydroxylase; homozygosity or compound heterozygosity for mutant PLOD allele(s)
Arthrochalasia	Autosomal dominant	Severe generalized joint hypermobility with recurrent subluxations; congenital bilateral hip dislocation	Skin hyperextensibility; tissue fragility; easy bruising; muscle hypotonia; kyphoscoliosis; radiologic osteopenia	Mutations leading to the deficient processing of the amino-terminal end of the pro-alpha ₁ (I) (type A) or pro-alpha ₂ (I) (type B) chains of collagen type I because of slipping of exon 6 in either gene
Dermatosparaxis	Autosomal recessive	Severe skin fragility; sagging, redundant skin	Soft, doughy skin texture; easy bruising; premature rupture of fetal membranes; large hernias	Deficiency in procollagen I N-terminal peptidase caused by homozygosity of mutant allele

- Beighton P, de Paepe A, Steinmann B, et al: Ehlers-Danlos syndromes: revised nosology, Villefranche, 1997. Ehlers-Danlos National Foundations (USA) and Ehlers-Danlos Support Group (UK). *Am J Med Genet* 1998;77:31.
- Danlos M: Un cas de cutis laxa avec tumeurs par contusion chroniques des coudes et des genoux (xanthome juvénile pseudodiabétique de MM. Hallopeau et Mace de Lepinary). *Bull Soc Fr Dermatol Syph* 1908;70:1908.
- Ehlers E: Cutis laxa, Neigung zu Haemorrhagien in der Haut, Lockerung mehrerer Artikulationen. *Dermatol Z* 1901;8:173.
- Jaffe AS, Geltman EM, Rodey GE, et al: Mitral valve prolapse: a consistent manifestation of type IV Ehlers-Danlos syndrome. The pathogenetic role of the abnormal production of type III collagen. *Circulation* 1981;64:121.
- Lichtenstein JR, Martin GK, Kohn LD, et al: Defect in conversion of procollagen to collagen in a form of Ehlers-Danlos syndrome. *Science* 1973;182:298.
- Piette E, Douniau R: Juvenile parodontolysis symptomatic of Ehlers-Danlos syndrome: a sporadic case? *Acta Stomatol Belg* 1980;77:217.
- Pinnell SR, Krane SM, Kenzora JE, et al: A heritable disorder of connective tissue, hydroxylysine-deficient collagen disease. *N Engl J Med* 1972;286:1018.
- Sacheti A, Szemere J, Bernstein B, et al: Chronic pain is a manifestation of the Ehlers-Danlos syndrome. *J Pain Symptom Manage* 1997;14:88.
- Stillman AE, Painter R, Hollister DW: Ehlers-Danlos syndrome type IV: diagnosis and therapy of associated bowel perforation. *Am J Gastroenterol* 1991;86:360.
- van Meeckeren JA: De dilatabilitate extraordinaria cutis. Chap 32, *Observations medico-chirurgicae*. Amsterdam, 1682.
- Wynne-Davies R: Acetabular dysplasia and familial joint laxity: two etiological factors in congenital dislocation of the hip. A review of 589 patients and their families. *J Bone Joint Surg* 1970;52-B:704.

Gaucher's Disease

GENETICS

Gaucher's disease is an autosomal recessive inborn disturbance of lipid metabolism characterized by a deficiency in the enzyme beta-glucocerebrosidase, which cleaves glucosylceramide.¹³ At least 36 different mutations have been described in the glucocerebrosidase gene that produces Gaucher's disease.^{9,38} Molecular genetic research has localized the glucocerebrosidase gene to 1q21.¹⁷ There has been variable correlation between the specific genotype and the phenotypic expression in patients with Gaucher's disease.^{8,52,65,68}

HEREDITY

Gaucher's disease is the most common lipid storage disorder known. It is especially prevalent in the Ashkenazi Jewish population. In a screening study conducted in Israel, the carrier frequency among those tested was 1 in 17.³⁷

PATHOLOGY

Glucocerebrosides accumulate within the reticuloendothelial system and sometimes in the CNS. Pale-staining foam cells, known as Gaucher cells, accumulate (Fig. 30-52). The

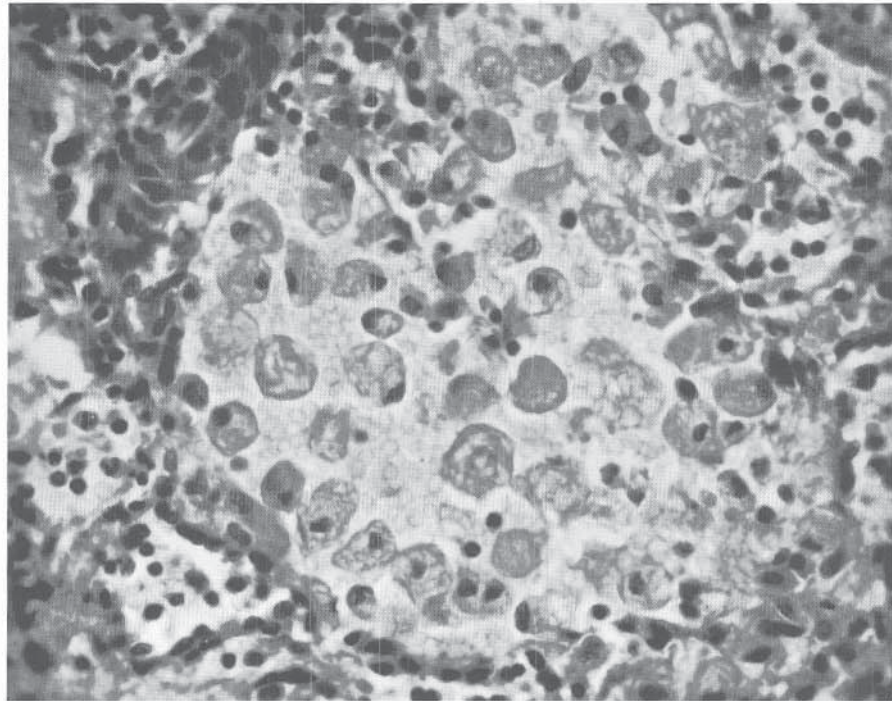


FIGURE 30–52 Gaucher cells, characteristic of Gaucher's disease (hematoxylin-eosin, $\times 400$)

disease may manifest with hepatosplenomegaly, bone marrow suppression, and bone lesions.

CLINICAL FEATURES

Brady and Barranger in 1983 defined three distinct forms of Gaucher's disease.¹² Type 1 Gaucher's disease is also referred to as the chronic non-neuropathic form or the adult form, although it most often becomes evident during childhood.⁷⁰ It is the most common clinical form and manifests within the first two decades of life. The severity of the disease is extremely variable, with a tendency for increasing severity in children. Splenomegaly, enlargement of lymph nodes, bone lesions, and skin pigmentation abnormalities are present. The CNS is not involved.

Type 2 disease is the acute infantile neuropathic form. This type is very rare. It appears in infancy and primarily involves the CNS. The disease is fatal within 18 months of onset. There is extensive neuronal destruction due to accumulation of glucosylsphingosine. Bony involvement is not significant.

The third type is the subacute neuropathic or juvenile form. It has the features of the chronic form and CNS involvement. The disease manifests during childhood with slowly progressive neural dysfunction, gait abnormality, seizures, and mental retardation.

In all three forms the bone marrow is infiltrated, causing anemia, leukopenia, and thrombocytopenia. These aberrations manifest clinically as fatigue, bleeding tendencies, and recurrent infections. Enlargement of the spleen results in abdominal protuberance. Enlarged lymph nodes are palpable.

DIAGNOSIS

The diagnosis of Gaucher's disease is often initially missed.⁶⁶ The definitive method of diagnosis is enzyme assay of beta-

glucocerebrosidase activity,¹⁵ which demonstrates reduced acid beta-glucosidase activity in peripheral blood leukocytes. Genotyping at the glucocerebrosidase gene locus can provide additional information and identify carriers. The histologic diagnosis of Gaucher's disease is not necessary.⁵¹

PRENATAL DIAGNOSIS

A prenatal diagnosis can be successfully made by enzyme assays of cells obtained from amniocentesis or chorionic villous sampling, and by DNA analysis for known mutations.⁷¹

ORTHOPAEDIC MANIFESTATIONS

The orthopaedic problems that develop in types 1 and 3 Gaucher's disease vary among patients.²⁰ There are six different bony manifestations of Gaucher's disease: bone marrow infiltration, avascular necrosis (AVN), bone crises, pathologic fracture, lytic lesions, and osteomyelitis.

Bone Marrow Infiltration. The bone marrow is infiltrated by Gaucher cells, which multiply and replace the hematopoietic cells. The metaphysis and diaphysis expand, and the adjacent cortex becomes thinned, creating the appearance of an Erlenmeyer flask on radiographs (Fig. 30–53).⁴⁶ The distal femur is most commonly involved. The expansion and erosion of the cortices can produce chronic bone pain.

Avascular Necrosis. AVN is caused by interruption of the microvasculature by the expanding mass of Gaucher cells. AVN of the femoral head is common, occurring in up to 75 percent of patients in a series reported by Amstutz (Fig. 30–54).²³ It usually is bilateral. There may be segmental involvement, or the total head may be affected. The joint space may become narrowed, with resultant osteoarthritis.⁶⁷ The humeral head is also frequently involved.²¹ Marrow

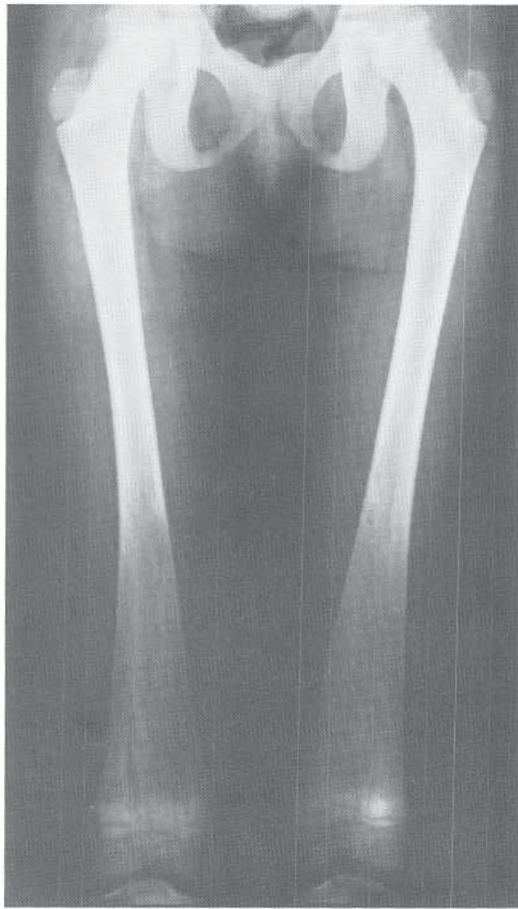


FIGURE 30-53 Bilateral "Erlenmeyer flask" deformity of the femora in Gaucher's disease.

changes consistent with AVN can be easily seen on MRI.^{29,61} Histologic examination of avascular femoral heads shows sheets of Gaucher cells and fibrous tissue filling the marrow spaces.

Bone Crises. Bone crises resembling those seen in patients with sickle cell anemia may occur. They manifest as acute episodes of severe pain in a limb with localized tenderness, warmth, redness, inability to use the limb, fever, and leukocytosis. In short, they resemble infection.⁷ Bone crises occur in both the lower and the upper extremities.⁴² Radiographs show periosteal new bone formation and mottled rarefaction of the involved bone.

Technetium bone scans may be helpful in differentiating between bone crisis and osteomyelitis. A "cold" scan supports the diagnosis of bone crisis, since osteomyelitis usually produces increased uptake.^{18,43} Similarly, gallium scanning will show decreased uptake in Gaucher's disease and increased uptake in osteomyelitis.⁵⁰ Subperiosteal edema has been seen in patients with Gaucher's disease during bone crises.¹⁶ Lipophilic tracer scans have recently been used in a few cases to differentiate bone pain due to Gaucher's disease from infection.⁴⁵ Bell and associates recommended performing blood cultures, technetium bone scans, and CT on all patients with Gaucher's disease suspected of having bone crises or osteomyelitis.⁷ When aspiration of the bone is necessary, it should be carried out under aseptic conditions to prevent secondary infection from occurring.

The course of bone crises in Gaucher's disease is self-limiting, with the pain gradually subsiding within days or weeks. The pathophysiology of the crisis is presumed to be vaso-occlusive. The Gaucher cells mechanically block the circulation, leading to a marked elevation in intramedullary pressure. A recent study, supported by MRI findings of signal change within the bone and subperiosteal fluid collections, proposed that subacute hemorrhage due to coagulopathy leads to bone crises.³⁶ The issue, though, remains unsettled.

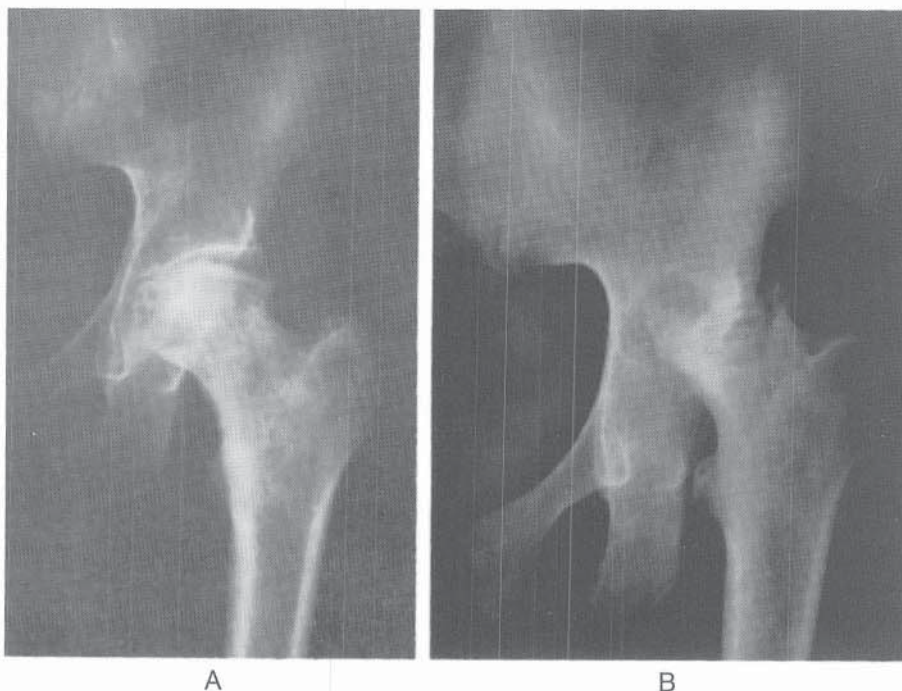


FIGURE 30-54 Gaucher's disease in a 52-year-old woman. A, Necrosis of the left femoral head. The joint space is narrowed and the superior surface of the head is somewhat collapsed. B, The same hip 18 months later. Note the complete disintegration of the joint with severe collapse and superolateral migration of the femoral head. (From Amstutz HC, Carey EJ: Skeletal manifestations and treatment of Gaucher's disease. *J Bone Joint Surg* 1966; 48-A:683.)

Pathologic Fractures. Osteopenia and AVN predispose to pathologic fracture in Gaucher's disease.^{57,67} The sites most frequently involved are the proximal femur and the spine.²⁸ In pediatric patients, the fractures heal with conservative treatment, although there is a tendency for fractures of the proximal femur to heal in varus alignment.²⁸ Fracture healing may be prolonged, even in children.⁴⁰ Kyphosis may result from vertebral compression fractures, and cord and root impingement have been described in rare cases.^{31,44,62} Usually more than one vertebra is involved.

Lytic Lesions. The presence of bubbly, expansile lytic lesions in the long bones is caused by marked aggregates of Gaucher cells.⁵⁶ Occasionally the masses of Gaucher cells protrude from the bone into the soft tissue and mimic malignancy.³⁰ Tumor formation may occur in Gaucher's disease, but it is rare.^{58,69} There is an increased risk of hematologic cancer occurring in late adulthood.⁶⁴

Osteomyelitis. Osteomyelitis is a serious problem in Gaucher's disease.⁵⁵ The ischemic bone is inherently susceptible to infection and, when osteomyelitis does occur, the lack of vascular supply to the bone makes antibiotic treatment difficult.⁷ Patients with Gaucher's disease are prone to infection with anaerobic organisms not commonly seen in osteomyelitis.²⁵ Technetium bone scans may show increased uptake, and gallium scanning can often help in making the correct diagnosis.⁵⁰ Surgical treatment is often contraindicated in Gaucher's disease because frequently the result is chronic osteomyelitis.

TREATMENT

Significant advances have been made in recent years in the treatments available to patients with Gaucher's disease. Splenectomy had long been used for patients with hypersplenism and thrombocytopenia. Unfortunately, splenectomy leaves the patient at increased risk for infection.²⁶ Splenectomy also results in greater invasion of the bone marrow for hematopoiesis. For these reasons, partial splenectomy came into favor, but follow-up studies have shown regrowth of the remnant spleen with the reappearance of splenomegaly.^{4,33,54,73}

Bone marrow transplantation has been successful in the treatment of Gaucher's disease.^{14,35} Plasma levels of glucocerebroside return to normal, but the Gaucher cells persist for a prolonged time.⁶⁰ Because of the risks of overwhelming infection, bone marrow transplant has not become the primary form of treatment for Gaucher's disease.⁸

Enzyme replacement therapy became possible in 1991 and is currently advocated as the treatment for children with type 1 Gaucher's disease.^{53,70} Placental human glucocerebrosidase (αglucuronidase) and recombinant glucocerebrosidase (imiglucerase) are the two enzymes that have been used.⁶ The indications for treatment are massive splenomegaly, growth failure, and severe bony, hematologic, and pulmonary complications. Improvement in hepatosplenomegaly, anemia, and thrombocytopenia usually is apparent within 6 months. The bone disease responds more slowly.¹⁰ Partial restoration of vertebral body height has been described in pediatric patients.³²

The neurologic abnormalities seen in type 2 Gaucher's disease are not reversed with enzyme treatment.²² Babies

with type 2 disease still die in infancy despite enzyme replacement.^{11,23,59} There have been rare cases of neurologic improvement in type 3 disease.⁷⁴

Because enzyme therapy is extremely expensive, it is not widely available. A recent Canadian study reported that the cost of enzyme therapy was "currently about \$21,000 per infusion for adults at the starting dose recommended by the manufacturer."⁴⁹ Studies are underway to determine the absolute minimum amount of enzyme necessary to control the disease.^{8,24,34,72,75} Response to therapy must be measured, and protocols for the monitoring of enzyme replacement therapy have been outlined.¹⁵ MRI has been very useful in following the restoration of more normal bone marrow in patients on enzyme therapy.^{1,29}

Molecular genetic research has led to the development of gene therapy for the treatment of Gaucher's disease.¹⁹ Transfer of the gene that codes for glucocerebrosidase via a retroviral vector to hematopoietic progenitors has been successful in mice. Preliminary results of this technique in human patients with Gaucher's disease indicate the persistence of genetically corrected cells.⁵

ORTHOPAEDIC CONSIDERATIONS

Orthopaedic treatment is required for management of the pathologic fractures. In children, treatment should be conservative, as operative intervention carries the risk of subsequent development of chronic osteomyelitis. Fracture frequency and bone crises were reduced in one study of patients with Gaucher's disease treated with aminohydroxy propylidene bisphosphonate.⁶³ Another study advocates the use of steroids, either intravenously or orally, for symptomatic treatment of bone crises.¹⁶ Clearly, bone crisis must be specifically differentiated from osteomyelitis if steroids are to be administered.

AVN of the femoral head may be quite painful in children with Gaucher's disease. Symptomatic management of osteonecrosis of the femoral head includes bed rest and analgesics, followed by nonweightbearing on the involved limb if it makes the patient more comfortable. On follow-up, most children are asymptomatic for several years.⁴¹ Presently there is no role for surgery in the prevention or early treatment of AVN in Gaucher's disease.

Severe osteoarthritis of the hip due to AVN is treated by total hip arthroplasty.^{47,48} In a study with a 14-year follow-up, it was concluded that the majority of arthroplasties performed in patients with Gaucher's disease resulted in increased mobility and resolution of pain.²⁷ Total shoulder arthroplasty has likewise been successful in treating osteoarthritis associated with Gaucher's disease.⁶⁷ Redirectional osteotomy of the femur has been described in a case of segmental AVN.³⁹

In the rare instance in which orthopaedic surgery is performed on a patient with Gaucher's disease, it is imperative that the surgeon and the anesthesiologist be aware of the tendency for coagulopathy in these patients.

REFERENCES

Gaucher's Disease

- Allison JW, James CA, Arnold GL, et al: Reconversion of bone marrow in Gaucher disease treated with enzyme therapy documented by MR. *Pediatr Radiol* 1998;28:237.

2. Amstutz HC: The hip in Gaucher's disease. *Clin Orthop* 1973;90:83.
3. Amstutz HC, Carey EJ: Skeletal manifestations and treatment of Gaucher's disease. *J Bone Joint Surg* 1966;48-A:670.
4. Bar-Maor JA: Partial splenectomy in Gaucher's disease: follow-up report. *J Pediatr Surg* 1993;28:686.
5. Barranger JA, Rice EO, Dunigan J, et al: Gaucher's disease: studies of gene transfer to haematopoietic cells. *Baillieres Clin Haematol* 1997;10:765.
6. Barton NW, Brady RO, Dambrosia JM, et al: Replacement therapy for inherited enzyme deficiency: macrophage-targeted glucocerebrosidase for Gaucher's disease [see comments]. *N Engl J Med* 1991;324:1464.
7. Bell RS, Mankin HJ, Doppelt SH: Osteomyelitis in Gaucher disease. *J Bone Joint Surg* 1986;68-A:1380.
8. Beutler E: Gaucher disease: new molecular approaches to diagnosis and treatment. *Science* 1992;256:794.
9. Beutler E: Gaucher disease as a paradigm of current issues regarding single gene mutations of humans. *Proc Natl Acad Sci USA* 1993;90:5384.
10. Beutler E: Enzyme replacement therapy for Gaucher's disease. *Baillieres Clin Haematol* 1997;10:751.
11. Bove KE, Daugherty C, Grabowski GA: Pathological findings in Gaucher disease type 2 patients following enzyme therapy. *Hum Pathol* 1995;26:1040.
12. Brady RO, Barranger JA: Glucosyl ceramide lipidosis: Gaucher disease. In Stanbury JB, Wyngaarden JB, Fredrickson DS, et al (eds): *The Metabolic Basis of Inherited Disease*, p 842. New York, McGraw-Hill Book Co, 1983.
13. Brady RO, Kanfer JN, Shapiro D: Metabolism of glucocerebrosides. II. Evidence of enzymatic deficiency in Gaucher's disease. *Biochem Biophys Res Commun* 1965;18:221.
14. Chan KW, Wong LT, Applegarth D, et al: Bone marrow transplantation in Gaucher's disease: effect of mixed chimeric state. *Bone Marrow Transplant* 1994;14:327.
15. Charrow J, Esplin JA, Gribble TJ, et al: Gaucher disease: recommendations on diagnosis, evaluation, and monitoring. *Arch Intern Med* 1998;158:1754.
16. Cohen IJ, Kornreich L, Mekhmandarov S, et al: Effective treatment of painful bone crises in type I Gaucher's disease with high dose prednisolone. *Arch Dis Child* 1996;75:218.
17. Cormand B, Montfort M, Chabas A, et al: Genetic fine localization of the beta-glucocerebrosidase (GBA) and prosaposin (PSAP) genes: implications for Gaucher disease. *Hum Genet* 1997;100:75.
18. Dolen EG, Berdon WE, Ruzal-Shapiro C: "Cold bone scans" as a sign of hemorrhagic infarcts of the spine in Gaucher's disease. *Pediatr Radiol* 1997;27:514.
19. Dunbar C, Kohn D: Retroviral mediated transfer of the cDNA for human glucocerebrosidase into hematopoietic stem cells of patients with Gaucher disease: a phase I study. *Hum Gene Ther* 1996;7:231.
20. Elstein D, Itzhaki M, Mankin HJ: Skeletal involvement in Gaucher's disease. *Baillieres Clin Haematol* 1997;10:793.
21. Epps CH Jr: Painful hematologic conditions affecting the shoulder. *Clin Orthop* 1983;173:38.
22. Erikson A, Bembi B, Schiffmann R: Neuronopathic forms of Gaucher's disease. *Baillieres Clin Haematol* 1997;10:711.
23. Erikson A, Johansson K, Mansson JE, et al: Enzyme replacement therapy of infantile Gaucher disease. *Neuropediatrics* 1993;24:237.
24. Figueroa ML, Rosenbloom BE, Kay AC, et al: A less costly regimen of alglucerase to treat Gaucher's disease [see comments]. *N Engl J Med* 1992;327:1632.
25. Finkelstein R, Nachum Z, Reissman P, et al: Anaerobic osteomyelitis in patients with Gaucher's disease. *Clin Infect Dis* 1992;15:771.
26. Freud E, Cohen IJ, Neuman M, et al: Should repeated partial splenectomy be attempted in patients with hematological diseases? Technical pitfalls and causes of failure in Gaucher's disease. *J Pediatr Surg* 1997;32:1272.
27. Goldblatt J, Sacks S, Dall D, et al: Total hip arthroplasty in Gaucher's disease: long-term prognosis. *Clin Orthop* 1988;228:94.
28. Goldman AB, Jacobs B: Femoral neck fractures complicating Gaucher disease in children. *Skeletal Radiol* 1984;12:162.
29. Hermann G, Pastores GM, Abdelwahab IF, et al: Gaucher disease: assessment of skeletal involvement and therapeutic responses to enzyme replacement. *Skeletal Radiol* 1997;26:687.
30. Hermann G, Shapiro R, Abdelwahab IF, et al: Extrasosseous extension of Gaucher cell deposits mimicking malignancy. *Skeletal Radiol* 1994;23:253.
31. Hermann G, Wagner LD, Gendal ES, et al: Spinal cord compression in type I Gaucher disease. *Radiology* 1989;170:147.
32. Hill SC, Parker CC, Brady RO, et al: MRI of multiple platyspondyly in Gaucher disease: response to enzyme replacement therapy. *J Comput Assist Tomogr* 1993;17:806.
33. Holcomb GW III, Greene HL: Fatal hemorrhage caused by disease progression after partial splenectomy for type III Gaucher's disease. *J Pediatr Surg* 1993;28:1572.
34. Hollak CE, Aerts JM, Goudsmit R, et al: Individualised low-dose alglucerase therapy for type 1 Gaucher's disease [see comments]. *Lancet* 1995;345:1474.
35. Hoogerbrugge PM, Brouwer OF, Bordigoni P, et al: Allogeneic bone marrow transplantation for lysosomal storage diseases. The European Group for Bone Marrow Transplantation [see comments]. *Lancet* 1995;345:1398.
36. Horev G, Kornreich L, Hadar H, et al: Hemorrhage associated with "bone crisis" in Gaucher's disease identified by magnetic resonance imaging. *Skeletal Radiol* 1991;20:479.
37. Horowitz M, Pasmanik-Chor M, Borochowitz Z, et al: Prevalence of glucocerebrosidase mutations in the Israeli Ashkenazi Jewish population. *Hum Mutat* 1998;12:240.
38. Horowitz M, Zimran A: Mutations causing Gaucher disease. *Hum Mutat* 1994;3:1.
39. Iwase T, Hasegawa Y, Iwata H: Transtrochanteric anterior rotational osteotomy for Gaucher's disease: a case report. *Clin Orthop* 1995;317:122.
40. Katz K, Cohen IJ, Ziv N, et al: Fractures in children who have Gaucher disease. *J Bone Joint Surg* 1987;69-A:1361.
41. Katz K, Horev G, Grunebaum M, et al: The natural history of osteonecrosis of the femoral head in children and adolescents who have Gaucher disease. *J Bone Joint Surg* 1996;78-A:14.
42. Katz K, Horev G, Rivlin E, et al: Upper limb involvement in patients with Gaucher's disease. *J Hand Surg* 1993;18-A:871.
43. Katz K, Mechlis-Frish S, Cohen IJ, et al: Bone scans in the diagnosis of bone crisis in patients who have Gaucher disease [published erratum appears in *J Bone Joint Surg* 1991;73-A:791]. *J Bone Joint Surg* 1991;73-A:513.
44. Katz K, Sabato S, Horev G, et al: Spinal involvement in children and adolescents with Gaucher disease. *Spine* 1993;18:332.
45. La Civita L, Mariani G, Porciello G, et al: Bone involvement in Gaucher's disease: "bone crisis" or disease complication? *Clin Exp Rheumatol* 1996;14:195.
46. Lachiewicz PF: Gaucher's disease. *Orthop Clin North Am* 1984;15:765.
47. Lachiewicz PF, Lane JM, Wilson PD Jr: Total hip replacement in Gaucher's disease. *J Bone Joint Surg* 1981;63-A:602.
48. Lau MM, Lichtman DM, Hamati YI, et al: Hip arthroplasties in Gaucher's disease. *J Bone Joint Surg* 1981;63-A:591.
49. MacKenzie JJ, Amato D, Clarke JT: Enzyme replacement therapy for Gaucher's disease: the early Canadian experience. *Can Med Assoc J* 1998;159:1273.
50. Miller JH, Ortega JA, Heisel MA: Juvenile Gaucher disease simulating osteomyelitis. *AJR Am J Roentgenol* 1981;137:880.
51. Mistry PK, Abrahamov A: A practical approach to diagnosis and management of Gaucher's disease. *Baillieres Clin Haematol* 1997;10:817.
52. Mistry PK, Smith SJ, Ali M, et al: Genetic diagnosis of Gaucher's disease. *Lancet* 1992;339:889.
53. Morales LE: Gaucher's disease: a review. *Ann Pharmacother* 1996;30:381.
54. Morgenstern L, Verham R, Weinstein I, et al: Subtotal splenectomy for Gaucher's disease: a follow-up study. *Am Surg* 1993;59:860.
55. Noyes FR, Smith WS: Bone crises and chronic osteomyelitis in Gaucher's disease. *Clin Orthop* 1971;79:132.
56. Ozturk H, Unsal M, Aydingoz U, et al: Pseudotumor formation in tibia in Gaucher's disease. *Eur J Radiol* 1998;26:284.
57. Pastores GM, Wallenstein S, Desnick RJ, et al: Bone density in type 1 Gaucher disease. *J Bone Miner Res* 1996;11:1801.
58. Pins MR, Mankin HJ, Xavier RJ, et al: Malignant epithelioid hemangioendothelioma of the tibia associated with a bone infarct in a patient who had Gaucher disease: a case report. *J Bone Joint Surg* 1995;77-A:777.
59. Prows CA, Sanchez N, Daugherty C, et al: Gaucher disease: enzyme therapy in the acute neuronopathic variant. *Am J Med Genet* 1997;71:16.
60. Rapoport JM, Ginns EI: Bone-marrow transplantation in severe Gaucher's disease. *N Engl J Med* 1984;311:84.

61. Rosenthal DI, Scott JA, Barranger J, et al: Evaluation of Gaucher disease using magnetic resonance imaging. *J Bone Joint Surg* 1986;68-A:802.
62. Ruff ME, Weis LD, Kean JR: Acute thoracic kyphosis in Gaucher's disease: a case report. *Spine* 1984;9:835.
63. Samuel R, Katz K, Papapoulos SE, et al: Aminohydroxy propylidene bisphosphonate (APD) treatment improves the clinical skeletal manifestations of Gaucher's disease. *Pediatrics* 1994;94:385.
64. Shiran A, Brenner B, Laor A, et al: Increased risk of cancer in patients with Gaucher disease. *Cancer* 1993;72:219.
65. Sidransky E, Bottler A, Stubblefield B, et al: DNA mutational analysis of type 1 and type 3 Gaucher patients: how well do mutations predict phenotype? *Hum Mutat* 1994;3:25.
66. Sidransky E, Tayebi N, Ginns EI: Diagnosing Gaucher disease: early recognition, implications for treatment, and genetic counseling. *Clin Pediatr (Phila)* 1995;34:365.
67. Tauber C, Tauber T: Gaucher disease: the orthopaedic aspect. Report of seven cases. *Arch Orthop Trauma Surg* 1995;114:179.
68. Tsuji S, Choudary PV, Martin BM, et al: A mutation in the human glucocerebrosidase gene in neuronopathic Gaucher's disease. *N Engl J Med* 1987;316:570.
69. Watanabe M, Yanagisawa M, Sonobe S, et al: An adult form of Gaucher's disease with a huge tumour formation of the right tibia. *Int Orthop* 1984;8:195.
70. Zevin S, Abrahamov A, Hadas-Halpern I, et al: Adult-type Gaucher disease in children: genetics, clinical features and enzyme replacement therapy. *Q J Med* 1993;86:565.
71. Zimran A, Elstein D, Abrahamov A, et al: Prenatal molecular diagnosis of Gaucher disease. *Prenat Diagn* 1995;15:1185.
72. Zimran A, Elstein D, Levy-Lahad E, et al: Replacement therapy with imiglucerase for type 1 Gaucher's disease [see comments]. *Lancet* 1995;345:1479.
73. Zimran A, Elstein D, Schiffmann R, et al: Outcome of partial splenectomy for type I Gaucher disease. *J Pediatr* 1995;126:596.
74. Zimran A, Hadas-Halpern I, Zevin S, et al: Low-dose high-frequency enzyme replacement therapy for very young children with severe Gaucher disease. *Br J Haematol* 1993;85:783.
75. Zimran A, Hollak CE, Abrahamov A, et al: Home treatment with intravenous enzyme replacement therapy for Gaucher disease: an international collaborative study of 33 patients. *Blood* 1993;82:1107.

Arthrogryposis (Arthrogryposis Multiplex Congenita)

Arthrogryposis is a term used for a variety of conditions that have in common diminished fetal movements with congenital joint stiffness and varying degrees of muscle weakness. The disorder should be considered a symptom complex rather than a disease, and a definite diagnosis should be sought. Specific syndromes with the features of arthrogryposis have different prognoses and inheritance patterns, and knowledge of these patterns allows accurate patient counseling.

The most common type of arthrogryposis is termed amyoplasia or classic arthrogryposis, and the descriptions that follow refer to this form of the disorder. Distal arthrogryposis is characterized by restriction of motion of the distal joints of the hands, feet, and sometimes the knees, and has been classified into six types. Contractural arachnodactyly (Beals' syndrome) and multiple pterygium syndrome have been mistaken for arthrogryposis.²⁰

Arthrogryposis is a rare disorder that occurs in about 1 in 3,000 live births, while true amyoplasia occurs in about 1 in 10,000 live births.^{20,43} It was first described in 1841 by Otto.³⁰ Schanz in 1897 termed the condition multiple congenital contractures,⁷⁶ while Rosencranz coined the term arthrogryposis.³⁶ In 1923 Stern proposed the term arthrogryposis multiplex congenita, which is used today.⁴⁸

The clinical picture, especially at birth, is often one of dramatic deformities and immobility (Fig. 30–55). The parents need considerable counseling to realize that despite the obvious musculoskeletal abnormalities, most affected individuals are able to lead productive, functional lives, with satisfactory correction of most of the deformities.^{41,45}

ETIOLOGY

The clinical findings of arthrogryposis result from failure of the fetus to move normally. The fibrosis of joints and the lack of creases, the thin, atrophic extremities, and the fatty accumulations about the joints all result from fetal akinesia. This lack of motion is most often due to failure of skeletal muscle development, which may be due to abnormalities at the anterior horn cell or more proximally or distally in the nervous system. Associated muscle diseases include congenital muscular dystrophies, congenital myopathies, intrauterine myositis, and mitochondrial disorders.⁶ The syndrome has been associated with gastroschisis, intestinal atresia, Poland's sequence, and Möbius' anomaly, all of which have a vascular interruption etiology, suggesting that arthrogryposis may also have a vascular etiology.³⁵

Amyoplasia may be caused by defective myogenic regulatory genes. The effect appears as a defective somite due to lack of induction by the notocord and neural tube. The muscle matrix, derived from lateral mesoderm, is present, but myocytes, which are derived from somitic mesoderm, are absent and replaced by adipose cells.³⁷

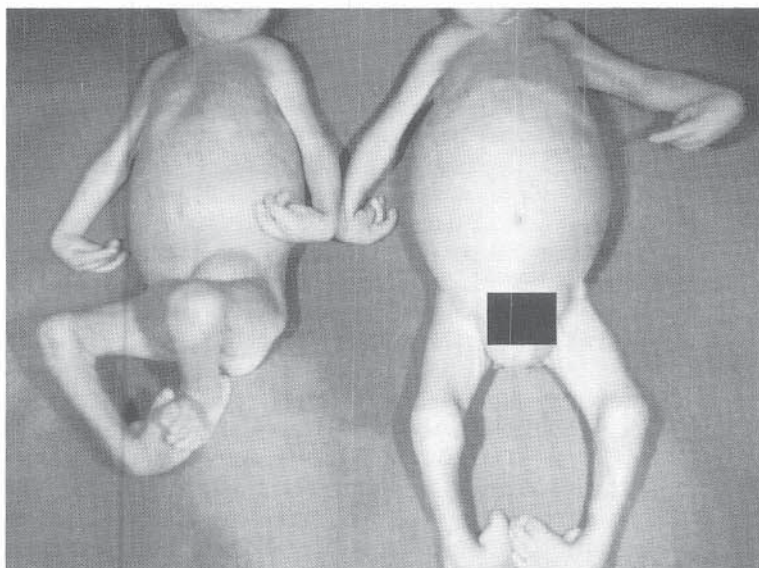
Several cases have been reported in which mothers with myasthenia gravis have passed to the affected fetus antibodies that inhibit the function of fetal acetylcholine receptor. These mothers are likely to have other affected children.³³

A number of animal studies have demonstrated the basic pathologic mechanism of the disease. Chick embryos treated with curare for 2 days are born with ankylosis of the joints similar to human arthrogryposis.¹¹ Fetal joints that were immobilized had similar findings.¹⁷ One case has been described in an infant born to a mother who was treated with muscle relaxants for tetanus at 10 to 12 weeks of gestation.²³ Rat fetuses treated with curare had multiple joint contractures, pulmonary hypoplasia, micrognathia, fetal growth retardation, short umbilical cord, and polyhydramnios. These findings were termed the fetal akinesia sequence.²⁶ These findings in humans have been termed the Pena-Shokeir syndrome.^{31,32}

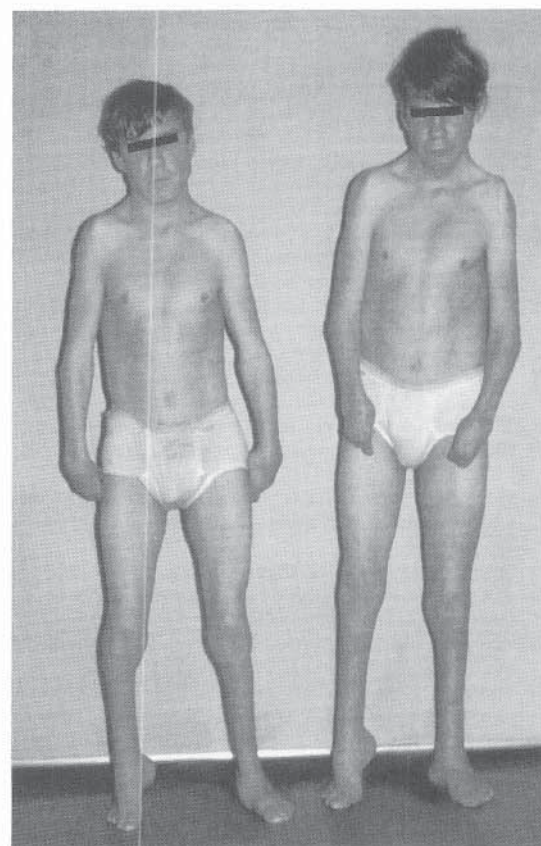
Experimentally in chick embryos, prenatal contracture of the joints can be caused by the Newcastle disease virus and by coxsackievirus.³⁴ Akbani virus may cause similar joint contractures in cattle.⁴⁹

GENETICS

Several genetic patterns have been recognized in arthrogryposis, but most cases of arthrogryposis (i.e., amyoplasia type) are sporadic without an inheritance risk. Autosomal dominant transmission has been noted especially in type I distal arthrogryposis. Autosomal recessive inheritance has also been noted, as well as X-linked recessive inheritance.²⁰ Rare cases of mitochondrial inheritance have also been reported.



A



B

FIGURE 30–55 Twins with arthrogyriposis. **A**, At birth the characteristic deformities are present. The shoulder muscles are atrophic, the shoulders are adducted, the elbows are extended, and the wrists are flexed. In the lower extremities the knees are variably flexed, and there are equinovarus deformities of the feet. **B**, The same boys at age 16. Lower extremity surgery was relatively successful; the upper extremities remain in the original positions. Today more aggressive upper extremity surgery would have been performed. However, when asked about their activities, they replied that they both played on a six-man high school football team.

CLINICAL MANIFESTATIONS

Classic Arthrogyriposis. Classic arthrogyriposis, or amyoplasia, presents with striking musculoskeletal abnormalities. These bright-eyed, intelligent children always have contractures of the extremities and usually have a midline cutaneous hemangioma on the forehead. The most frequent posture is that of elbow extension, wrist flexion, and ulnar deviation, knee extension or flexion, and equinovarus foot deformities (Figs. 30–55 to 30–57). The arms and legs are thin and atrophic and the joints lack flexion creases. Accumulations of fat in the extremities often give the limbs a sausagelike appearance. In some cases the elbows are flexed, the knees are in valgus or varus position, and the feet may have calcaneovalgus, varus, or vertical talus deformities. In most patients both upper and lower extremities are involved, but occasionally only the lower or upper extremities are involved. The prenatal diagnosis has been made as early as 19 weeks of gestation, based on absent fetal movement and characteristic contractures.⁴² Breech position is common and probably is due to inability of the fetus to kick strongly enough to turn to a vertex position.³⁹ Many are delivered by cesarean section, and birth fractures are fairly common.

Active and passive joint motion is usually markedly limited, but affected joints usually retain at least a “jog” of

motion. Head and neck motion is generally normal. Shoulder motion is variably limited, with flexion usually preserved. At the elbow there may be considerable difference between the active and passive range of motion, with passive flexion to 90 degrees a common finding. The wrists and fingers generally have marked reduction of motion, and the fingers are often ulnarly deviated with flexion contractures. The thumb often has little opposition, and grasping is often done between the fingers. The pathognomonic posture, the “waiter’s tip” posture, is one of shoulder adduction and internal rotation, elbow extension, forearm pronation, and wrist flexion.

In the lower extremities the range of motion of the hip is often relatively preserved, especially in flexion and extension. The knees may be stiff in flexion or extension, and the available range is often hingelike rather than a gliding motion. The feet may be stiff in an equinovarus position with little ankle or foot motion. Rocker-bottom deformities occur with vertical talus, and equinovalgus and calcaneovalgus postures also occasionally noted. Some children develop scoliosis, usually a neuropathic C curve with pelvic obliquity.

Distal Arthrogyriposis. Distal arthrogyriposis syndromes involve the more peripheral joints. Type I is associated with specific findings in the hands—medially overlapping fingers,

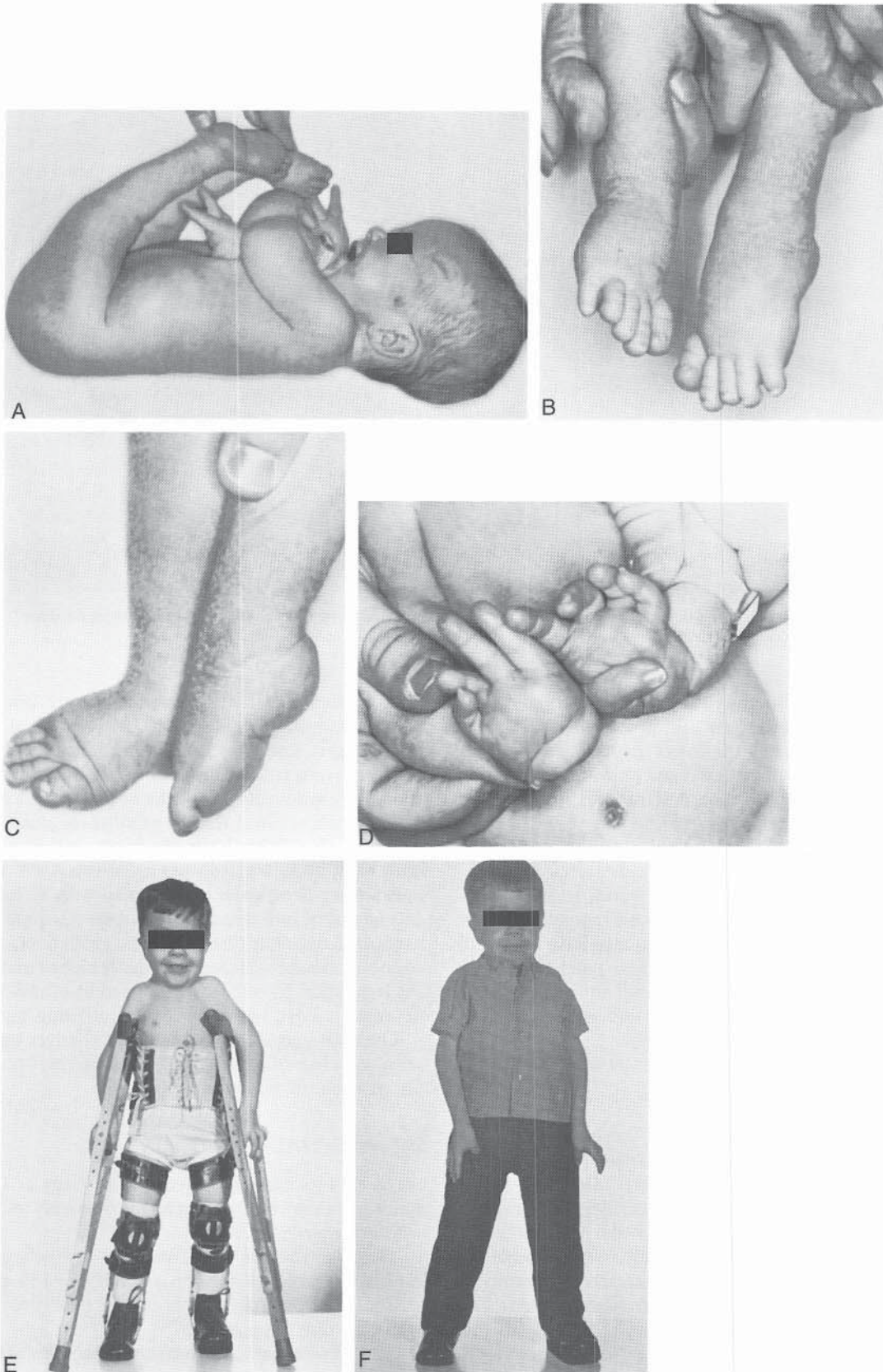


FIGURE 30-56 Arthrogyposis. **A**, Unusually flexed elbows and hyperextended knees at birth. **B**, Both feet have rigid equinovarus deformities. **C**, Lateral view of the feet showing the extreme equinus of the left foot. **D**, Palmar view of the hands of the same patient. Note the adducted thumbs. **E** and **F**, The patient, 3 years later, is able to walk with the help of braces. He had bilateral heel cord lengthening and flexion release of both hips.

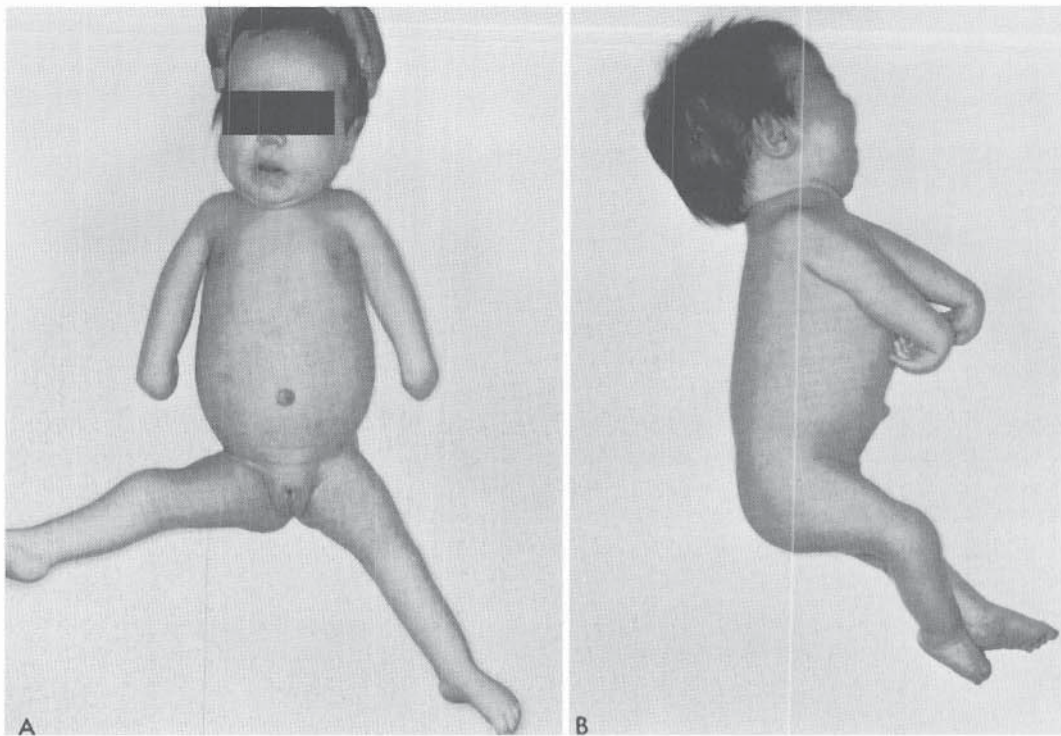


FIGURE 30-57 A and B, Arthrogryposis with major involvement of the upper extremities. Note the atrophic shoulder girdle, extended elbows which have no flexion creases, the flexed wrists, and the flexed fingers.

flexed, adducted thumb, clinched fists, ulnar deviation of the fingers, and camptodactyly. Talipes equinovarus and vertical talus are found in the lower extremities.^{3,4,25} It is transmitted as an autosomal dominant trait, with the gene located on chromosome 9.^{5,20} A variant with craniofacial abnormalities has also been reported.²⁷

Type IIa distal arthrogryposis is accompanied by cleft palate and short stature. Type IIb, a mitochondrial disorder, has ptosis, ophthalmoplegia, hard and woody muscles, and absent palmar creases, along with distal contractures. Father-to-son and mother-to-son transmission have been reported in this type.^{16,18} Type IIc has cleft lip and palate, type II d has scoliosis, and type IIe has trismus and an unusual contracture of the hand with wrist flexion and metacarpophalangeal joint extension.²⁰

PATHOLOGY

The pathophysiology of arthrogryposis begins with failure of fetal movement, usually caused by failure of development of the anterior horn cells at the spinal level (the neuropathic form). Consequently the spinal cord is smaller than normal, especially at the cervical and lumbar levels. Anterior horn cells are diminished in number but otherwise normal in appearance. The ventral roots are decreased in number, while the dorsal roots are normal. Occasionally there are abnormalities in the brain, with reduced Betz cells in the motor cortex and incomplete fissuring with large lateral ventricles.^{12,13,15,24}

The pathology of the articular joints indicates normal embryologic development with subsequent failure of movement. Thus, articular cartilage is well formed and joint spaces are present. The joint capsules are thickened and fibrotic,

joint creases are absent, bursal areas are poorly formed, especially about the knee, tendons are often fibrosed to their sheaths, and muscles are thin, atrophic, and at times infiltrated with fat. Accumulations of subcutaneous fat occur in atypical locations such as the upper and lower thigh, and may themselves limit flexion of adjacent joints.

In the myopathic form the brain, spinal cord, anterior horn cells, and nerve rootlets are normal.^{1,14,24} The affected muscles are firm, pale, and fibrous, with fibrous and fatty degeneration. Individual muscle fibers are quite varied, with haphazard distribution of large and small fibers. Endomesial connective tissue is increased. Muscle biopsy may distinguish the two types. In one study 93 percent of children had the neurogenic type, with only 7 percent being myopathic.⁷

Over time, articular degenerative changes occur secondarily, with loss of articular cartilage and eventual spontaneous arthrodesis in some joints.

DIFFERENTIAL DIAGNOSIS

Some authors have indicated that as many as 150 different syndromes may be considered to have features in common with arthrogryposis.¹⁹

Freeman-Sheldon syndrome, or “whistling face” syndrome, has limited extension of multiple joints and a characteristic puckered facial appearance that gives rise to the whistling face designation.

Multiple pterygium syndrome resembles arthrogryposis in the presence of contractures of joints, but the knee and elbow contracture are often extreme, with winglike webbing on the flexor surface.

Individuals with Beals’ syndrome or congenital contractural arachnodactyly have long, gracile extremities simi-

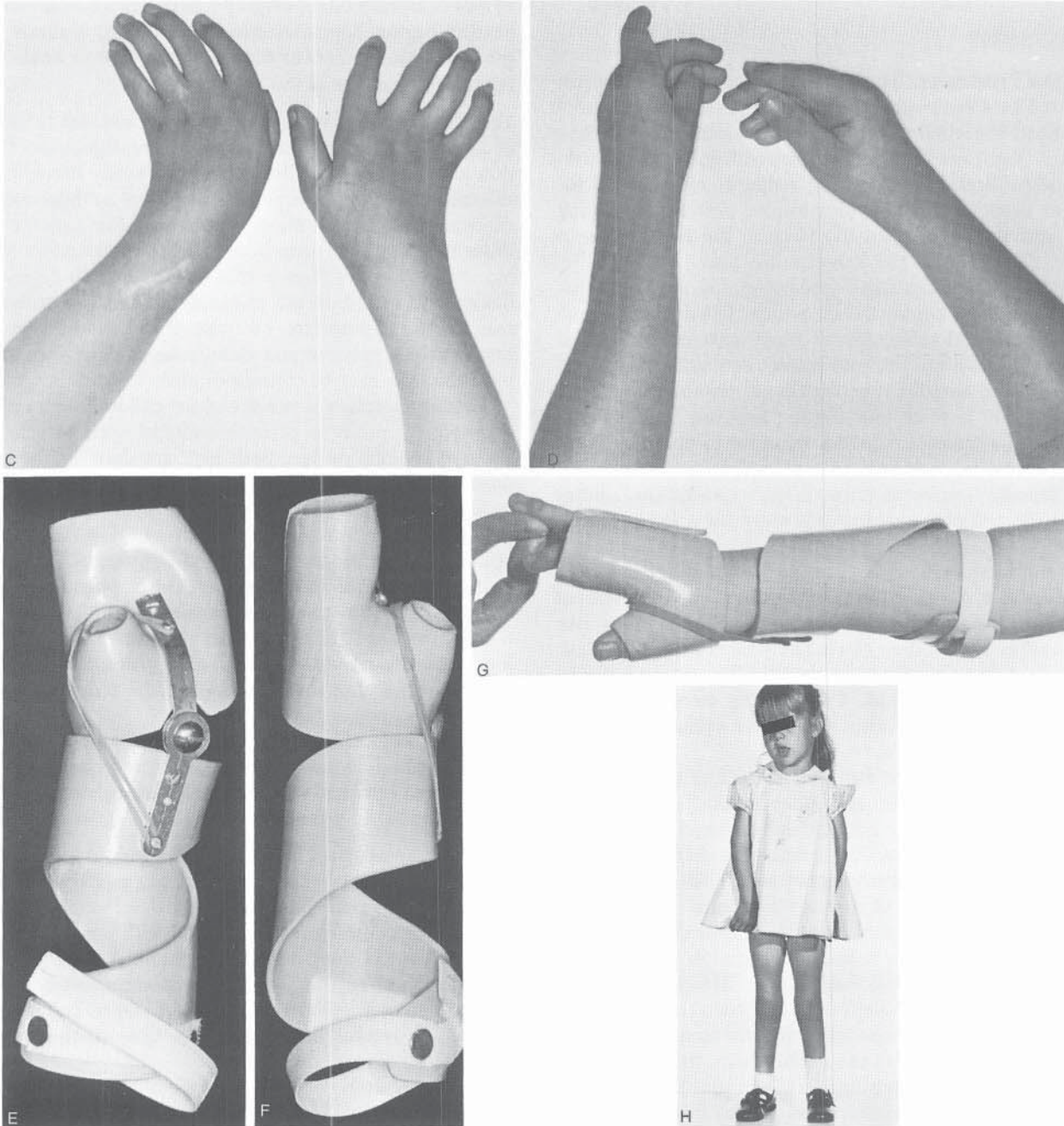


FIGURE 30-57 *Continued.* C and D, Postoperative photographs. E to G, The type of splint used to maintain correction in various views and on the patient. H, Clinical appearance of patient at 4 years of age.

lar to what is seen in Marfan's syndrome, but also have contractures of the fingers and toes and mild loss of extension of other joints.

Some dwarfing syndromes such as diastrophic dysplasia have restrictions of joint motion, but are distinguished by other characteristic features, especially the limb shortening.

TREATMENT

Goals of Treatment. The treatment of arthrogryposis must be based on a thorough understanding of this unique disorder. First, the children are quite intelligent and sensitive to pain. Vigorous stretching of their stiff joints is counterproductive both for improving range of motion and for patient rapport. Second, the complex unit of the gliding joint did not form normally because the fetus failed to move. For example, the knee cannot move normally because (1) the muscles failed to develop, (2) the prepatellar bursa and the suprapatellar pouch failed to develop, (3) the skin and subcutaneous tissue envelope developed as a cylinder without normal creases and lacks the normal excess of skin anteriorly, which allows motion, and (4) the joint capsule is thick and fibrotic and not large enough to allow the femoral condyles to move to and fro. Thus, the surgeon must recognize that simple solutions, such as a capsular release or joint surface replacement, cannot create the complex anatomy necessary for a freely mobile joint.

A third essential understanding is that this disorder is quite variable. At one extreme are children with involvement limited to the feet and calves or to the elbows and wrists; at the other are children (fortunately rare) who have active motion of their head and neck only. Treatment must be tailored to the individual. The following discussion relates to "typical," fairly severe cases; many variations will be encountered in practice.

In most patients the two major goals of treatment are independent ambulation and independent function of the upper extremities for activities of daily living. In one follow-up study of 53 patients, 73 percent were able to ambulate independently or with occasional aids.⁴⁶ To achieve these goals it is necessary (1) to correct the alignment of the lower extremities so that plantigrade standing and walking are possible, (2) to preserve existing joint motion and place that motion in the most functional location, (3) to increase active motion where appropriate tendon-muscle transfers are possible, and (4) to reposition stiff joints for functional advantage. At times, often with older individuals, the surgeon and patient must choose between fixed deformities in either a sitting or a standing position, and in such cases there is no "right" decision. Some severely involved persons prefer the many advantages of the sitting position for wheelchair mobility, driving, and working. Others deal with life in a standing position despite the obvious difficulties it poses for driving and working.

Timing of Treatment. A well-planned treatment program should seek to accomplish as much functional improvement in as few operative procedures as possible, preferably finishing by age 6 or 7. With typical involvement of four extremi-

ties, early stretching and cast correction may be useful for wrist and knee positional contractures. Surgical correction of the knees will usually precede hip surgery, and should be done by age 6 months. Hip reduction is performed at our institution at around 6 months of age. Hand and feet are often corrected in the same operative procedure at early "standing age." We have found a higher rate of recurrence of foot deformity if foot surgery is performed before weight-bearing begins. Late corrective osteotomies, scoliosis surgery, and osteotomies or fusions of the foot or ankle may be necessary as late as the teenage years.

The Hip. In recent years it has become clear that reduction of dislocated hips in arthrogryposis is advantageous for function and not nearly as difficult as previously thought. We recommend early reduction of unilateral or bilateral hip dislocation in the vast majority of cases. Most patients with dislocated hips have some active flexion or extension of the hip and a range of passive motion of 60 to 90 degrees. If flexion and extension are markedly limited, hip reduction may not be appropriate. Likewise, if the child is virtually totally unable to move and ambulation is clearly not likely, hip reduction may be contraindicated.

Closed reduction is not useful for children with arthrogryposis. We prefer to perform a medial open reduction at about 6 months of age. Both hips are done in the same procedure if necessary. Our experience has mirrored that of Szoke and Staheli in that satisfactory results are the rule rather than the exception. In their series, 80 percent of 40 treated hip dislocations had good outcomes.⁵⁰ The procedure is described in Chapter 15, Developmental Dysplasia of the Hip. Postoperative immobilization is limited to 6 weeks in a cast in the human position. Further splinting is usually unnecessary and may promote stiffness. A femoral shortening may be added if the reduction is too tight.

In the older child the hip is reduced with an anterior approach and femoral shortening when necessary. Acetabular dysplasia is treated with an appropriate pelvic osteotomy, usually the Salter procedure.

OTHER HIP DEFORMITIES. Hip abduction and adduction contractures are occasionally encountered, and the resultant pelvic obliquity may contribute to the development of scoliosis. Minor contractures are treated with appropriate soft tissue releases. Contracture of the iliotibial band produces a hip flexion, abduction, external rotation contracture. Proximal and distal iliotibial band release (the Ober-Yount procedure) may resolve the contracture. Osteotomies may be required for severe contractures.

Fixed extension contracture of the hip is a rare but challenging deformity. Soft tissue releases may be considered, but if they are followed by hip flexion deformity, ambulatory function may be lost. In addition, flexion after release of the hip extensors and hip capsule may still be limited by the sciatic nerve tension. A shortening osteotomy may be the only alternative in the latter situation.

The Knees. There is considerable variation in the knee deformities at birth. Flexion contractures are most frequent, but extension contractures, hyperextension, and varus and valgus deformities are also encountered.

KNEE HYPEREXTENSION AND DISLOCATION. Hyperextended or dislocated knees may respond to stretching and casting and this should be initiated in the early neonatal period (see Fig. 30–56).²⁸ (The treatment should also be abandoned if unsuccessful after several casts). If knee flexion or reduction of the anteriorly dislocated tibia is not achieved, we perform surgical correction between 4 and 6 months of age.

Release of Knee Hyperextension or Dislocation. An anterior release of the knee capsule and patella is performed through an anteromedial longitudinal incision. The quadriceps is lengthened in a V-Y-plasty through the central tendon of the quadriceps. Alternatively the femur may be shortened 2 to 3 cm at midshaft and plated to reduce the need for quadriceps lengthening. At the conclusion of the procedure the knee should flex to 90 degrees. Postoperatively the knee is splinted in flexion. The amount of flexion should be determined while the surgeon inspects the blood flow to the prepatellar skin after tourniquet release. Because the normal redundant anterior skin is not present in this condition, this skin will slough if the knee is splinted in so much flexion that the cutaneous blood flow is compromised. Early passive range-of-motion exercises are important and should start 2 to 3 weeks postoperatively. Splinting in flexion should be continued for 3 months.

Long-term studies have shown a significant rate of degenerative changes in the knees of adults, especially those with extension deformities.⁴⁷

KNEE FLEXION CONTRACTURES. The flexed knee is the deformity that most often limits functional ambulation. It is very resistant to passive stretching and difficult to correct surgically.²⁸ Excessive manipulation may result in fractures or epiphyseal separations at the distal femur or proximal tibia.⁴⁴ Recurrent deformity is common, especially if hamstring power is unopposed by the quadriceps. Surgery may be considered after 6 months of age.

Correction of Knee Flexion Contracture. The knee is approached first through a Henry posterolateral incision. The interval between the biceps and fascia lata is entered and the dissection is carried posteriorly deep to the popliteal neurovascular structures. The posterior capsule of the knee is readily visualized. The biceps tendon is lengthened and the fascia lata transected. The posterior capsule is opened laterally and as far medially as possible. If full extension is achieved, the procedure may be terminated. At this point partial correction is usually achieved and further release is required.

Next, a medial incision is made just medial to the semitendinosus. The semitendinosus, semimembranosus, gracilis, and sartorius are lengthened. The remainder of the posterior capsule medially is also sectioned. If full extension is possible, the procedure is complete. Often the knee will still lack full extension, and an anterior release will be necessary.

Finally, the knee is opened anteriorly through a medial parapatellar incision. Fibrous and fatty accumulations are often encountered anteriorly between the tibia and femur, and these are resected. If the patella is encased in fibrous tissue against the femoral condyles, it is released fully. At this point any remaining structures (except the neurovascular bundle) that prevent extension are released. Often these

structures include the anterior and posterior cruciates and the collateral ligaments. If the knee cannot be extended because the neurovascular structures are tight, a femoral shortening is performed with plate fixation. The surgeon must not stress the knee after femoral shortening because the bone purchase of plate and screws is often tenuous.

The knee is splinted in full extension with careful monitoring of the neurovascular status of the leg and foot. Range-of-motion exercises can be started at 3 to 4 weeks, or after 6 weeks if the femur has been shortened. Long-term bracing of the knee may be necessary, especially if the quadriceps is not functional or the knee is unstable.

Flexion deformities at skeletal maturity may be corrected with a closing wedge distal femoral osteotomies. However, femoral extension osteotomies done in growing children are not successful. Either the deformity will recur with growth or, if excessive angulation is done, a Z deformity of the distal femur will develop. Varus and valgus deformities may accompany extension or flexion deformities and are corrected at the time of reduction of the primary deformity. Patellar instability is occasionally present and may be addressed surgically with lateral release, medial advancement, and correction of knee valgus if necessary.

The Feet. The most frequent foot deformity is a rigid equinovarus deformity that is more severe and rigid than an idiopathic clubfoot (see Fig. 30–56). Virtually any other deformity may be present, with vertical talus, equinovalgus, and cavus being the more common.

TALIPES EQUINOVARUS. The equinovarus foot in arthrogryposis is typically markedly plantar flexed with greater or lesser degrees of varus and adductus. Marked calf atrophy and lack of flexion creases are usual. The tendons are often fibrosed within their sheaths and lack mobility. The joints of the foot and ankle are severely fibrosed, and may be narrowed or at times fused. The extreme rigidity in the typical case precludes correction by passive stretching or casting. Atypical cases may at times be more flexible and responsive to manipulative means.

Surgical Correction of Talipes Equinovarus. The posteromedial release is the initial procedure for the arthrogryptic clubfoot. The surgeon must be prepared to augment the release with bony surgery when necessary. We use a Cincinnati incision and expose the medial tendons and neurovascular bundle. Often the tendons are atretic and should be sectioned or excised without repair. The Achilles tendon should be resutured with the foot in neutral dorsiflexion.

The subtalar, tibiotalar, talonavicular, and calcaneocuboid joints are opened and released completely. Releases are done stepwise until the foot is plantigrade. When residual deformity remains, other options should be used. When residual adductus remains, lateral column shortening is indicated. Lateral column shortening can be done several ways, our preference being cuboid decancellation. Unlike excision of the anterior calcaneus (Lichtblau procedure) or fusion of the calcaneocuboid joint (Evans procedure), some motion may be retained after excision of the midportion of the cuboid. If residual equinovarus is present after release, decancellation of the talus (Verebelyi-Ogston procedure) should be considered. This is usually done through a lateral incision. A curet is used to remove the cancellous bone of

the talus. The lateral cortex and cartilaginous anlage are incised and the talus is crushed by dorsiflexing and everting the foot to allow positioning of the foot in neutral dorsiflexion and valgus. Postoperative splinting or casting should be used for 6 weeks. The foot should then be maintained in an orthosis indefinitely to avoid loss of correction.

These procedures usually produce a plantigrade foot, but one with poor range of motion. Recurrence of deformity is common in spite of orthotic wear. Repeat surgery requires bony wedge resection or triple arthrodesis. We avoid talectomy because many feet re deform afterward, with little available for further salvage. If the talus is preserved, a triple arthrodesis is a reasonable late option. Ankle fusion is also possible in unusually severe instances. Without the talus, neither procedure is possible when the deformity recurs.

VERTICAL TALUS. The vertical talus deformity is treated surgically if it is severe enough to interfere with plantigrade walking and shoe wear. The procedure is done as described in this text, with navicular excision often necessary. The results of these procedures are somewhat better than those for equinovarus feet, and postoperative stiffness and recurrence are less frequent.

CAVOVARUS DEFORMITY. These deformities may be corrected with plantar release, midfoot osteotomy, or triple arthrodesis in the older child, depending on the severity of the deformity.

Treatment of the Upper Extremities

PRINCIPLES. In earlier practice it was thought that children should be left to function bimanually with the shoulders internally rotated and adducted, the elbows extended, and the wrists flexed. They often were adept at writing with the hands turned backward and the pencil gripped between adducted fingers. Bimanual grasping was essential. Today much greater function is achieved with early repositioning of the extremities, adding active elbow flexion when possible to allow functional activities with the hands forward. The following principles help achieve these goals.

1. Joint motion should be preserved if at all possible. Even quite limited range of motion may be quite useful and functional and should not be sacrificed.
2. Passive motion of a joint must be gained before restoring active motion.
3. A bimanual function pattern will be necessary in most patients, as neither hand will be likely to have a strong unilateral grasp.
4. The shoulders and elbows should allow the hands to work at a tabletop level. This is important for feeding and working, especially in the computer age.

The ultimate goal for most patients is independent living and employment, and proper upper extremity management may make this possible. Our preference is to complete the major changes in limb position by age 4. We feel that by age 8 the use patterns are so well established that the child will not adapt well to the new limb function after that age.

Our first goal is to achieve passive elbow flexion. The second priority is to correct humeral rotation and then reposition the wrist and correct the thumb-in-palm deformity. Often the latter procedures are performed at one sitting.

THE SHOULDER. The shoulder is often contracted into adduction and internal rotation by joint incongruity and soft tissue contractures (see Fig. 30–57). Scapulothoracic motion may be limited, in addition to the lack of glenohumeral motion. Typically there is little active flexion or abduction of the shoulder. The major obstacle to function of the elbow and hand is the internal rotation contracture. Consequently, one of the most useful procedures in the upper extremity is an external rotation osteotomy of the humerus to allow the forearm to clear the body as the elbow flexes. This allows the hands to function at the midline in front of the body. The osteotomy may be performed at the midshaft level and fixed with a plate, or at the supracondylar level with crossed pin fixation. Postoperatively the arm should be immobilized only long enough to achieve early bony union.

THE ELBOW. The elbow deformity is usually one of full extension without active flexion, but with some active triceps function retained (see Fig. 30–57). Many children have passive flexion, but many others have an extension contracture. If elbow flexion is limited to 45 degrees or less, a tricepsplasty is indicated to gain functional range of motion. Elbow stability in extension should not be sacrificed, as crutch use may be necessary. Modified crutches may be required as well.

Posterior Release with Tricepsplasty. A posterior elbow release with tricepsplasty is performed through a posterior curvilinear incision. The ulnar nerve should be released from its tunnel and transferred anteriorly into a subcutaneous, protected position. During closure the subcutaneous tissue is tacked to the medial epicondyle to prevent posterior displacement of the nerve.

The triceps is lengthened through a long W incision with the lateral and medial limbs of the W extending into the triceps expansion (Plate 30–1). The posterior capsule of the elbow is opened at the tip of the olecranon. The elbow is gently flexed, serially releasing the most posterior fibers of the collateral ligaments as necessary. The surgeon must take care to avoid a fracture or epiphyseal separation from forceful manipulation. It should be possible to achieve at least 90 degrees of flexion and still maintain medial and lateral stability. The triceps is closed in a V to Y with the medial and lateral limbs closed over the central tongue of triceps tendon.

Postoperatively the elbow is splinted in 90 degrees of flexion for 3 weeks. Then active and passive range-of-motion exercises are begun and a resting splint is used for another 3 weeks. The parents should be taught to work with the child over the next months to maintain both flexion and extension.

Procedures to Achieve Active Elbow Flexion. The ideal transfer to gain active elbow flexion would be to use an expendable muscle, synergistic with elbow flexion, which can be appropriately aligned and which has good strength. It cannot be unopposed, or a flexion contracture will develop. Unfortunately, this combination is not available for most children with this disorder. Preoperative selection of a muscle-tendon unit for transfer is difficult and not aided by imaging studies. It may be necessary to make an incision over the proposed muscle to evaluate its bulk, color, and contractility (with electrical stimulation) before using that muscle for transfer.

Bipolar pectoralis major transfer: The entire pectoralis major muscle can be transferred by mobilizing it on its

neurovascular pedicle.¹⁰ The muscle is routed so that the tendon of insertion is transferred to the coracoid or acromion, which becomes the new origin of the muscle (Fig. 30–58). The broad fascia of the origin is mobilized and transferred to the ulna, either directly or with a graft if necessary. This is a good option if the pectoralis major is strong. The disadvantage of this transfer is that the scars may be disfiguring, especially in girls, with resultant breast asymmetry if done unilaterally.

Bipolar latissimus transfer: For this transfer the entire latissimus dorsi is mobilized on its pedicle and moved anteriorly through the axilla (Figs. 30–59 to 30–61).⁵⁴ The original tendon of insertion is moved to the coracoid or acromion, where it becomes the origin of the new muscle arrangement. The remainder of the muscle and its fascial prolongation are attached to the ulna distal to the coronoid process. This transfer is used if the latissimus is strong, but in most arthrogryptic children the muscle is fibrotic and not of satisfactory quality for transfer.

Transfer of the long head of the triceps: This transfer is feasible because the long head of the triceps has a separate neurovascular pedicle and is sufficiently independent from the rest of the triceps to be easily separated (M. B. Ezaki, personal communication to J. A. Herring, July 2000). It is present in most children with arthrogryposis and can be tested manually. A fascia lata graft is used to prolong the tendon to allow insertion into the proximal ulna. Although the muscle is not large, satisfactory active elbow flexion can be gained without loss of active elbow extension.

Triceps transfer: A procedure often mentioned for this purpose is the triceps transfer.^{2,9,29,51,52} Short term follow-up has shown significant improvement in many children, but over time, flexion contractures develop and function deteriorates. If both sides have been done, elbow-extended activities (such as crutch walking) are impossible, but even worse, if only one is flexed, bimanual activities are not feasible. Thus we no longer use this transfer.

Steindler flexorplasty: The Steindler flexorplasty⁴⁷ produces elbow flexion by transferring the flexor pronator origin from the medial epicondyle to the anterior humerus. It may be useful if the patient can isolate the muscle preoperatively and also can stabilize the wrist against excess flexion with the radial wrist extensors. Unfortunately, most children with arthrogryposis lack radial wrist extensors. This transfer will produce unacceptable wrist flexion unless these wrist extensors are present. Thus it is rarely indicated.

Unipolar pectoralis major transfer (Clark procedure): This procedure was also popular in the past. It is no longer recommended, for a couple of major reasons. First, the line of pull is such that active elbow flexion can only be achieved when the arm is abducted. When the shoulder is adducted, muscle pull results only in further adduction. Second, over time an adduction contracture is likely to develop.⁸

Free gracilis transfers: The gracilis may be transferred as a free tissue transfer (M. B. Ezaki, personal communication to J. A. Herring, 2000). In this procedure the intercostal nerves are used to innervate the transferred muscle. The difficulty with the transfer is the lack of better sources of innervation. In addition, the gracilis is often fibrotic and nonfunctional in children with arthrogryposis.

THE WRIST. The wrist in arthrogryposis is usually flexed and deviated ulnarward, and a small range of motion is available

(see Fig. 30–57). All the structures on the volar side are contracted, including the joint capsule, the tendons, the skin, and subcutaneous tissue. The radial wrist extensors are fibrotic and nonfunctional, but the extensor carpi ulnaris is often spared. Carpal coalitions are common.

Early stretching and splinting has been recommended, but the efficacy is uncertain. Overzealous, painful stretching is clearly inappropriate. Surgical treatment is indicated to reorient the wrist into a neutral position while maintaining any available motion. We have found a midcarpal wedge resection to be the most useful procedure to correct flexion and ulnar deviation. Simultaneous transfer of an appropriate tendon to provide radial extension can be done if a donor tendon is available. Often the extensor carpi ulnaris is available and works well for this transfer.

Dorsal, Radial Closing Wedge Osteotomy of the Midcarpus and Tendon Transfers. The wrist is approached through a transverse or longitudinal incision on the flexor surface of the distal third of the forearm. The fascia over the wrist flexors is opened. If the flexor carpi ulnaris has muscle bulk and excursion, it may be transferred to the extensor carpi radialis. In the usual case the flexor carpi ulnaris, flexor carpi radialis, and palmaris longus are fibrotic and are sectioned at the wrist to increase wrist extension.

A second dorsal incision is made at the level of the proximal carpal row. The digital and thumb extensors are isolated and protected. The wrist extensors are isolated from the dorsal capsule and sectioned. The extensor carpi ulnaris is mobilized and transferred across the midline of the wrist and secured to the distal stump of the wrist capsule or radial wrist extensors.

The radiocarpal capsule is left intact and the wrist is opened at the midcarpal level. A wedge resection of the midcarpus is made with a closing wedge dorsally and radially to gain neutral alignment of the wrist.²² The osteotomy is closed and secured with several interosseous wires or nonabsorbable sutures. Redundant capsule and synovium are resected and the dorsal capsule is closed. The wrist is splinted or casted for 6 weeks, and then a splint is used full-time for 3 months and part-time for a full year.

Proximal Row Carpectomy. Proximal row carpectomy was used in the past, but because the capitate and radial articulations are grossly abnormal, the procedure usually produced an undesirable incongruity of the radiocarpal articulation. In addition, the usual carpal coalitions preclude sustained, useful range of motion.

Wrist Fusion. Wrist fusion may be done as a salvage procedure but is undesirable because even a small amount of motion may be quite functional for the patient.⁵³

THE HAND. Flexion contractures of the fingers considerably limit the function of the hand. Passive stretching and splinting rarely add significant range of motion. The contractures include the flexor tendons, neurovascular bundles, and skin. Consequently, surgical procedures to date have not added to finger motion or function. Certainly no procedure should result in diminished sensation, as this will severely alter the function of the hand.

The thumb-in-palm deformity is another significant functional impediment and one that may respond to appropriate releases.

Text continued on page 1660

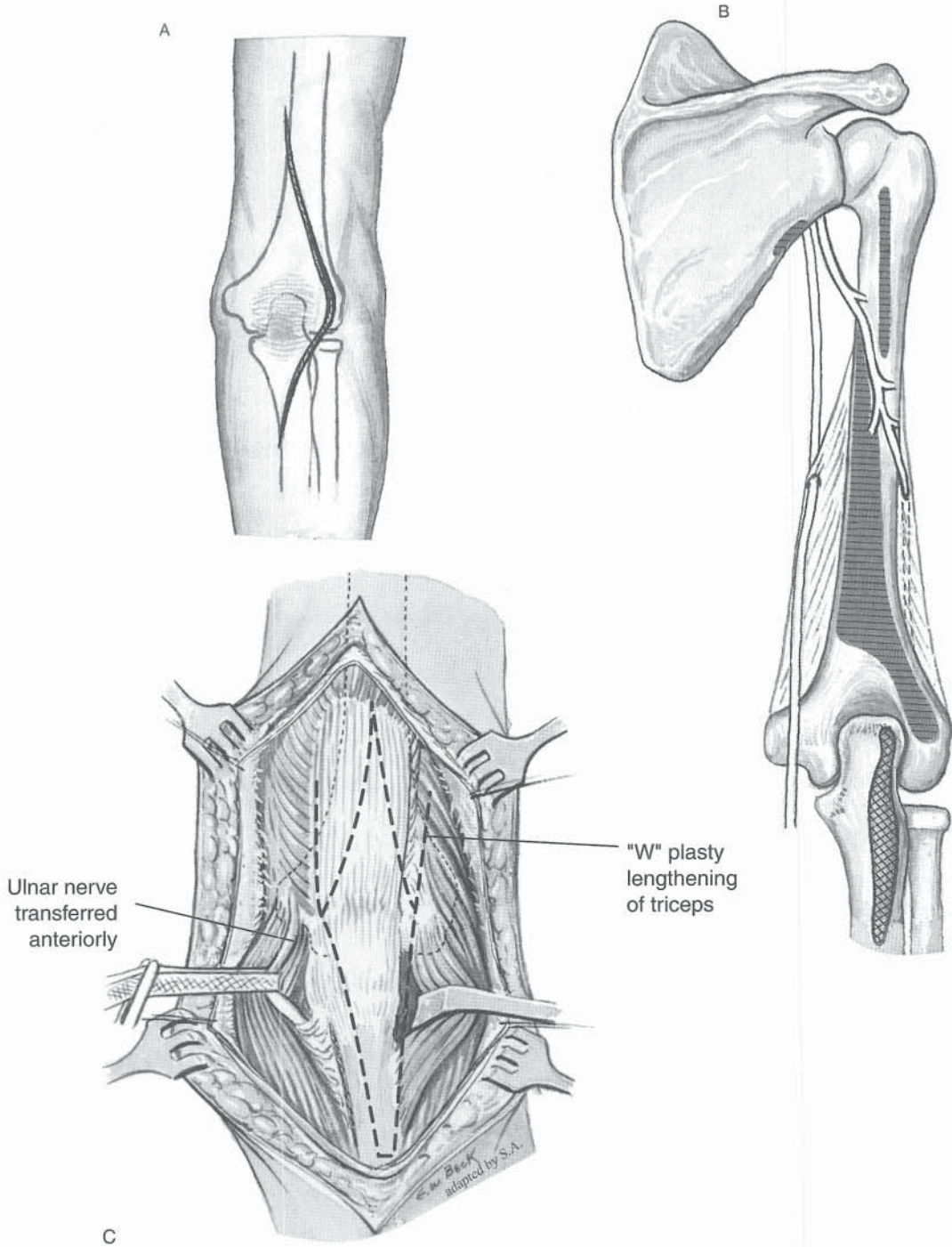
Posterior Release of Elbow Extension Contracture

A, The patient is placed in a lateral position. A midline incision is made on the posterior aspect of the arm, beginning in its middle half and extending distally to a point lateral to the olecranon process; then the incision is carried over the subcutaneous surface of the shaft of the ulna for a distance of 5 cm. The subcutaneous tissue is divided, and the wound flaps are mobilized.

B, The ulnar nerve is identified and mobilized medially to protect it from injury. The intermuscular septum is exposed laterally.

C, Left: The ulnar nerve is mobilized and transferred anteriorly. **Right:** The triceps muscle is lengthened in a W fashion, leaving a long proximal tongue.

Plate 30-1. Posterior Release of Elbow Extension Contracture



Posterior Release of Elbow Extension Contracture *Continued*

D, Then the triceps muscle is freed and mobilized proximally as far as its nerve supply permits. The motor branches of the radial nerve to the triceps enter the muscle in the interval between the lateral and medial heads as the radial nerve enters the musculospiral groove. The distal portion of the detached triceps is then sutured to itself to form a tube.

E and F, Through a curvilinear incision in the antecubital fossa, the interval between the brachioradialis and the pronator teres is developed.

G, With an Ober tendon passer, the triceps tendon is passed into the anterior wound subcutaneously, superficial to the radial nerve.

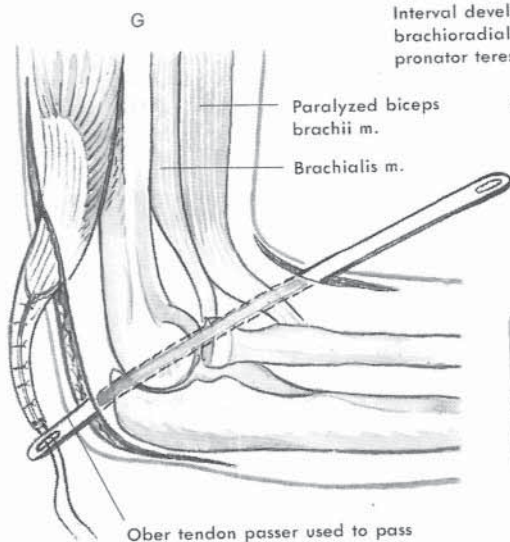
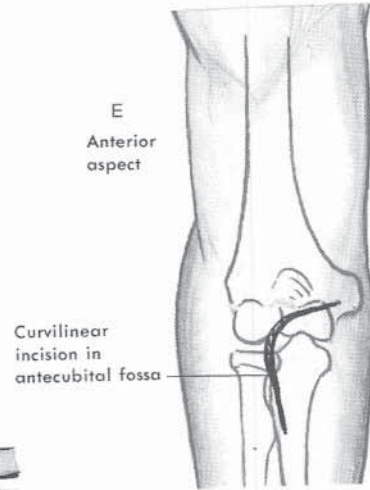
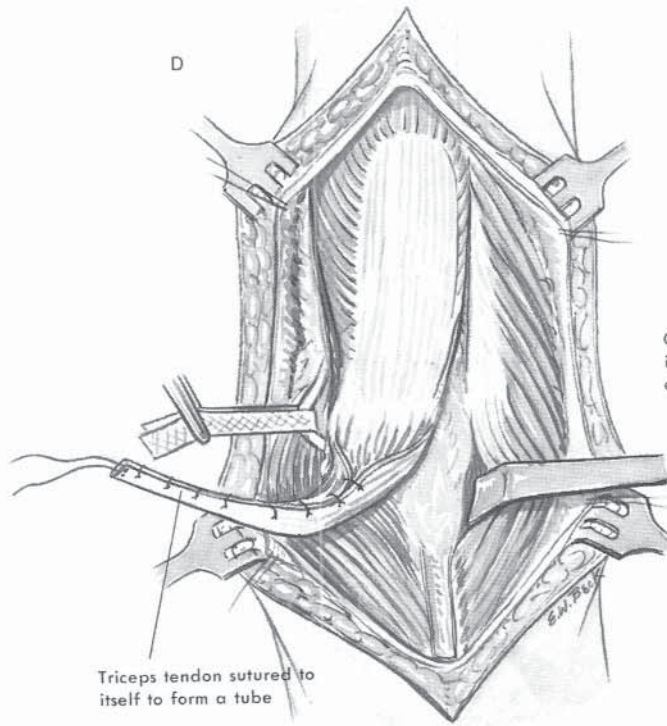
H, With the elbow in 90 degrees of flexion and the forearm in full supination, the triceps tendon is either sutured to the biceps tendon or anchored to the radial tuberosity by a suture passed through a drill hole.

The wound is closed in routine fashion. An above-elbow cast is applied with the elbow in 90 degrees of flexion and full supination.

POSTOPERATIVE CARE

Four weeks after surgery the cast is removed and active exercises are performed to develop elbow flexion. Gravity provides extension to the elbow.

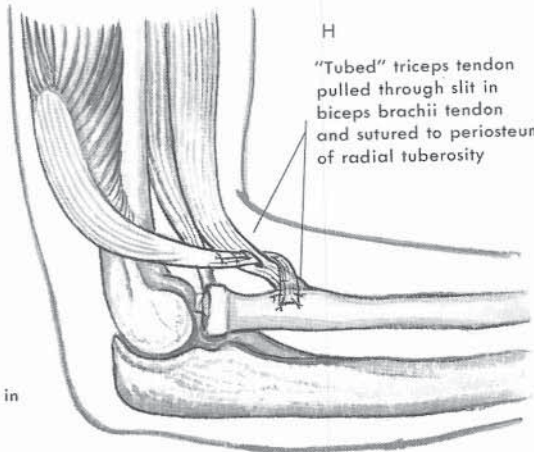
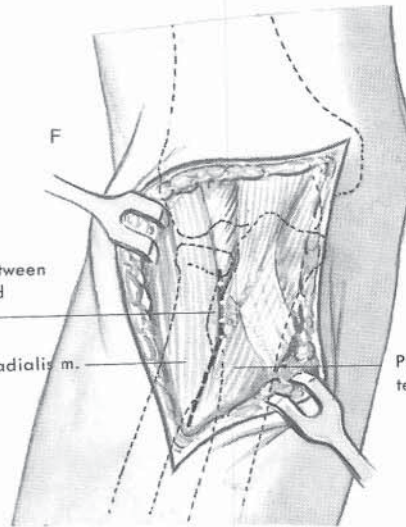
Plate 30-1. Posterior Release of Elbow Extension Contracture



Interval developed between brachioradialis m. and pronator teres m.

Brachioradialis m.

Pronator teres m.



Long arm cast applied for four weeks. Elbow in 90° flexion, forearm in full supination

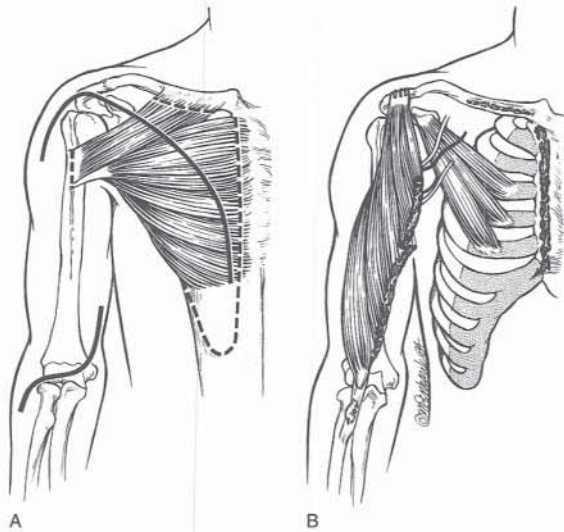
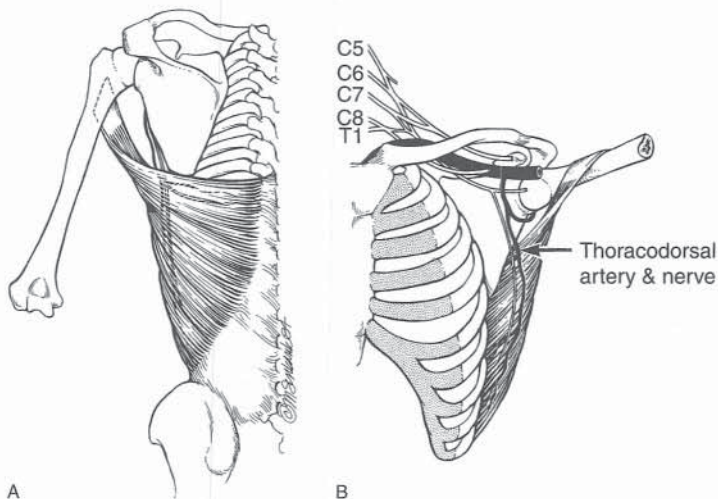


FIGURE 30-58 Bipolar transplantation of the pectoralis major muscle for elbow flexion. **A**, Incisions employed. *Solid lines* indicate skin incisions and *dotted lines* indicate the exact extent of detachment of the pectoralis major and rectus abdominis sheath. **B**, The completely detached pectoralis major is rotated on its two neurovascular pedicles. Its origin is attached to the biceps tendon, and its insertion is attached to the acromion through drill holes. (From O'Brien E: Flaccid dysfunction of the elbow. In Morrey BF (ed): *The Elbow and Its Disorders*, p. 602. Philadelphia, WB Saunders Co, 1985.)

Thenar Release. The skin incision is planned to provide maximum increase in skin length. A four-flap Z-plasty is used to open the thumb-index web space. Lack of supple skin on the palmar aspect of the thumb may be improved with a rotation flap based on the index metacarpal, transposed over the thumb metacarpophalangeal joint.

The origins of the thenar muscles are exposed and divided, taking care to preserve the neurovascular bundle. The adductor is released as well. The transverse head is freed from the long metacarpal shaft and the oblique head is freed from the base of the metacarpal. The deep palmar arch and the terminal branch of the ulnar nerve must be protected between the two heads of the adductor pollicis. The thumb is then placed in an abducted position and the flaps are rotated.



Scoliosis and Spine Deformity. Neuromuscular scoliosis is an occasional problem in arthrogryposis, with reported rates ranging from 2.5 to 34 percent (20 percent is a likely average).^{21,38} It may stem from pelvic obliquity, and proper management begins with correction of related hip contractures. The curves are usually a C curve. Bracing has not been useful for these deformities. Milder curves may stabilize; progressive curves require surgical management. Instrumentation to the pelvis is usually necessary; wires and rods or hooks and rods may be utilized.

REFERENCES

Arthrogryposis (Arthrogryposis Multiplex Congenita)

1. Adams RD, Denny-Brown D, Pearson CM: *Diseases of Muscle*. New York, Paul B. Hoeber, 1953.
2. Axt MW, Niethard FU, Doderlein L, et al: Principles of treatment of the upper extremity in arthrogryposis multiplex congenita type I. *J Pediatr Orthop B* 1997;6:179.
3. Bamshad M, Bohnsack JF, Jorde LB, et al: Distal arthrogryposis type 1: clinical analysis of a large kindred. *Am J Med Genet* 1996;65:282.
4. Bamshad M, Jorde LB, Carey JC: A revised and extended classification of the distal arthrogryposes. *Am J Med Genet* 1996;65:277.
5. Bamshad M, Watkins WS, Zenger RK, et al: A gene for distal arthrogryposis type I maps to the pericentromeric region of chromosome 9. *Am J Hum Genet* 1994;55:1153.
6. Banker B: Arthrogryposis multiplex congenita: spectrum of pathologic changes. *Hum Pathol* 1986;17:656.
7. Banker BQ: Neuropathologic aspects of arthrogryposis multiplex congenita. *Clin Orthop* 1985;194:30.
8. Brooks D, Seddon H: Pectoralis transplantation for paralysis of the flexor of the elbow. *J Bone Joint Surg* 1959;41-B:36.
9. Carroll R, Hill N: Triceps transfer to restore elbow flexion. *J Bone Joint Surg* 1970;52-A:239.
10. Carroll RE, Kleinman WB: Pectoralis major transplantation to restore elbow flexion to the paralytic limb. *J Hand Surg* 1979;4:501.
11. Drachman DB, Coulombre A: Experimental club foot and arthrogryposis multiplex congenita. *Lancet* 1962;2:523.
12. Drachman DB, Banker BQ: Arthrogryposis multiplex congenita: a case due to disease of the anterior horn cells. *Arch Neurol* 1961;5:77.
13. Ek JI: Cerebral lesions in arthrogryposis multiplex congenita. *Acta Paediatr* 1958;47:302.
14. Fitti RM, D'Auria TM: Arthrogryposis multiplex congenita. *J Pediatr* 1956;48:797.
15. Fowler M: A case of arthrogryposis multiplex congenita with lesions in the nervous system. *Arch Dis Child* 1959;34:505.
16. Friedman BD, Heidenreich RA: Distal arthrogryposis type IIB: further

FIGURE 30-59 **A** and **B**, The anatomy of the latissimus dorsi. Shortly after entering the muscle the single neurovascular pedicle (thoracodorsal nerve and artery) divides into lateral and medial branches. (From O'Brien E: *Flaccid dysfunction of the elbow*. In Morrey BF (ed): *The Elbow and Its Disorders*, p. 596. Philadelphia, WB Saunders Co, 1985.)

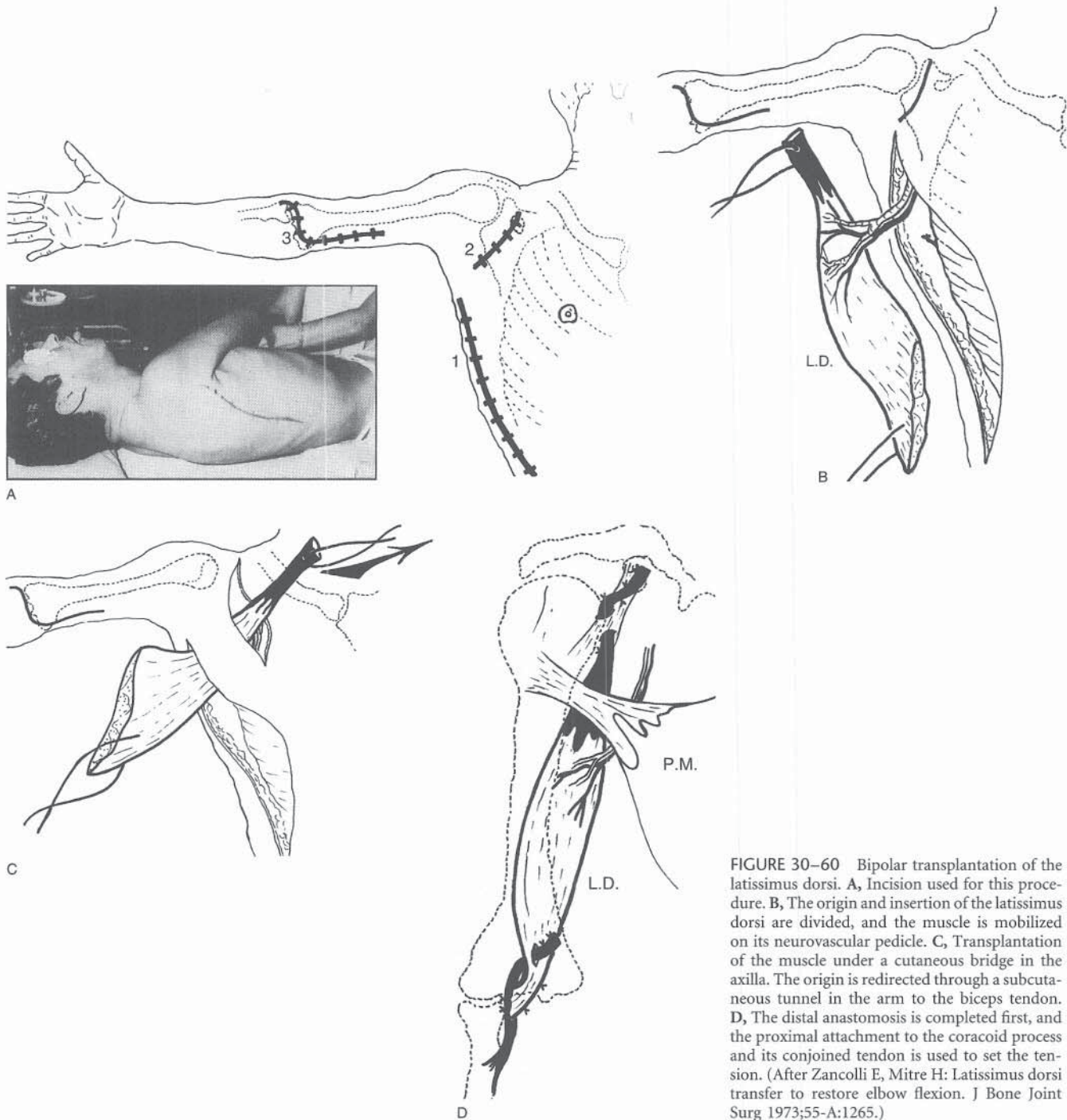


FIGURE 30-60 Bipolar transplantation of the latissimus dorsi. **A**, Incision used for this procedure. **B**, The origin and insertion of the latissimus dorsi are divided, and the muscle is mobilized on its neurovascular pedicle. **C**, Transplantation of the muscle under a cutaneous bridge in the axilla. The origin is redirected through a subcutaneous tunnel in the arm to the biceps tendon. **D**, The distal anastomosis is completed first, and the proximal attachment to the coracoid process and its conjoint tendon is used to set the tension. (After Zancolli E, Mitre H: Latissimus dorsi transfer to restore elbow flexion. *J Bone Joint Surg* 1973;55-A:1265.)

clinical delineation and 54-year follow-up of an index case. *Am J Med Genet* 1995;58:125.

17. Fuller DJ: Immobilization of foetal joints: a cause of progressive prenatal deformity. *J Bone Joint Surg* 1975;57-B:115.
18. Gripp KW, Scott CI Jr, Brockett BC, et al: Extending the spectrum of distal arthrogryposis. *Am J Med Genet* 1996;65:286.
19. Hall J: An approach to congenital contractures (arthrogryposis). *Pediatr Ann* 1981;10:15.
20. Hall J: Arthrogryposis multiplex congenita: etiology, genetics, classification, diagnostic approach, and general aspects. *J Pediatr Orthop B* 1997;6:159.
21. Herron L, Westin G, Dawson E: Scoliosis in arthrogryposis multiplex congenita. *J Bone Joint Surg* 1978;60-A:293.
22. Huish SB: Carpal wedge osteotomy for the arthrogryptic wrist. Submitted for publication. *J Bone Joint Surg [Am]* 2001.
23. Jago RM: Arthrogryposis following treatment of maternal tetanus with muscle relaxants: case report. *Arch Dis Child* 1970;45:277.
24. Kanof A, Aronson SM, Volk BW: Arthrogryposis: a clinical and pathological study of three cases. *Pediatrics* 1956;17:532.
25. Klemp P, Hall JG: Dominant distal arthrogryposis in a Maori family with marked variability of expression. *Am J Med Genet* 1995;55:414.
26. Moessinger AC: Fetal akinesia deformation sequence: an animal model. *Pediatrics* 1983;72:857.
27. Moore CA, Weaver DD: Familial distal arthrogryposis with craniofacial abnormalities: a new subtype of type II? *Am J Med Genet* 1989;33:231.
28. Murray C, Fixsen JA: Management of knee deformity in classical arthrogryposis multiplex congenita (amyoplasia congenita). *J Pediatr Orthop B* 1997;6:186.
29. O'Brien E: Flaccid dysfunction of the elbow. In Morrey BF (ed): *The Elbow*, p 589. Philadelphia, WB Saunders Co, 1985.

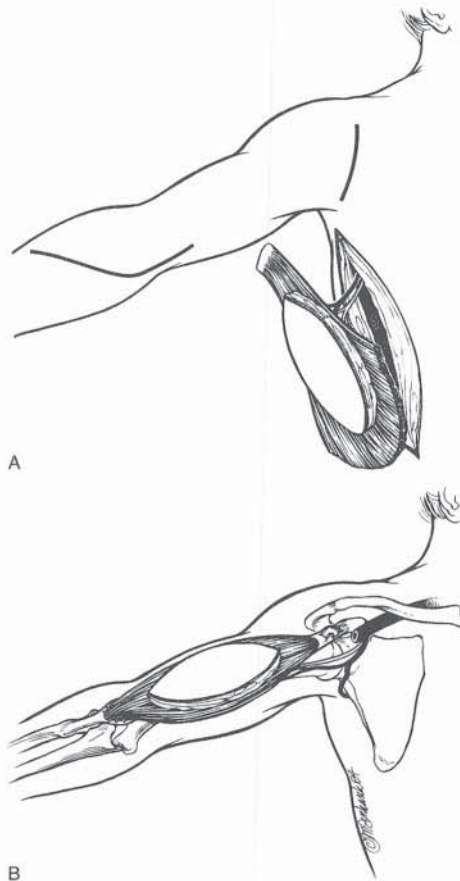


FIGURE 30-61 A and B, Technique used for a myocutaneous latissimus dorsi transplantation. (From O'Brien E: Flaccid dysfunction of the elbow. In Morrey BF (ed): *The Elbow and Its Disorders*, p. 598. Philadelphia, WB Saunders Co, 1985.)

30. Otto AW: Monstrum humanum extremitatibus incurvatus: monstrorum sexcentorum descriptio anatomica in Vratislaviae Museum [English translation]. *Clin Orthop* 1985;194:4.
31. Pena SDJ, Shokeir MHK: Autosomal recessive cerebro-oculo-facio-skeletal (COFS) syndrome. *Clin Genet* 1974;5:285.
32. Pena SDJ, Shokeir MHK: Syndrome of camptodactyly, multiple ankyloses, facial anomalies, and pulmonary hypoplasia: a lethal condition. *J Pediatr* 1974;85:373.
33. Riemersma S, Vincent A, Beeson D, et al: Association of arthrogryposis multiplex congenita with maternal antibodies inhibiting fetal acetylcholine receptor function. *J Clin Invest* 1996;98:2358.
34. Robertson GG, Williamson AP, Blattner RJ: A study of abnormalities in early chick embryos inoculated with New Castle disease virus. *J Exp Zool* 1955;129:5.
35. Robertson WL, Glinki LP, Kirkpatrick SJ, et al: Further evidence that arthrogryposis multiplex congenita in the human sometimes is caused by an intrauterine vascular accident. *Teratology* 1992;45:345.
36. Rosencranz E: Ueber kongenitale Kontracturen der oberen Extremitäten. *Z Orthop Chir* 1905;14:52.
37. Sarnat HB: New insights into the pathogenesis of congenital myopathies. *J Child Neurol* 1994;9:193.
38. Sarwark J, MacEwen G, Scott C: Scoliosis in amyoplasia congenita. Presented at the 20th Annual Meeting of the Scoliosis Research Society, Coronado, CA, 1985.
39. Sarwark JF, MacEwen GD, Scott CI Jr: Amyoplasia (a common form of arthrogryposis). *J Bone Joint Surg* 1990;72-A:465.
40. Schanz A: Ein Fall von multiplen kongenitalen Kontracturen. *Z Orthop Chir* 1898;5:9.
41. Sells JM, Jaffe KM, Hall JG: Amyoplasia, the most common type of arthrogryposis: the potential for good outcome. *Pediatrics* 1996;97:225.
42. Sepulveda W, Stagiannis KD, Cox PM, et al: Prenatal findings in generalized amyoplasia. *Prenat Diagn* 1995;15:660.

43. Silberstein EP, Kakulas BA: Arthrogryposis multiplex congenita in Western Australia. *J Paediatr Child Health* 1998;34:518.
44. Simonian PT, Staheli LT: Periarticular fractures after manipulation for knee contractures in children. *J Pediatr Orthop* 1995;15:288.
45. Södergård J, Hakamies-Blomqvist L, Sainio K, et al: Arthrogryposis multiplex congenita: perinatal and electromyographic findings, disability, and psychosocial outcome. *J Pediatr Orthop B* 1997;6:p167.
46. Södergård J, Ryoppy S: The knee in arthrogryposis multiplex congenita. *J Pediatr Orthop* 1990;10:p177.
47. Steindler A: A muscle plasty for the relief of the flail elbow in infantile paralysis. *Interstate Med J* 1918;5:235.
48. Stern WG: Arthrogryposis multiplex congenita. *JAMA* 1923;81:1507.
49. Swinyard CA, Bleek EE: The etiology of arthrogryposis (multiple congenital contractures). *Clin Orthop* 1985;194:15.
50. Szoke G, Staheli L, Jaffe K, et al: Medial-approach open reduction of hip dislocation in amyoplasia-type arthrogryposis. *J Pediatr Orthop* 1996;16:127.
51. Van Heest A, Waters PM, Simmons BP: Surgical treatment of arthrogryposis of the elbow. *J Hand Surg* 1998;23-A:1063.
52. Williams P: The elbow in arthrogryposis. *J Bone Joint Surg* 1973;55-B: 834.
53. Williams P: The management of upper limb problems in arthrogryposis. *Clin Orthop* 1985;194:60.
54. Zancolli E: Latissimus dorsi transfer to restore elbow flexion. *J Bone Joint Surg* 1973;55-A:1265.

Craniocarpotarsal Dysplasia (Freeman-Sheldon or "Whistling Face" Syndrome)

Craniocarpotarsal dysplasia was first described in 1938 by Freeman, an orthopaedic surgeon, and Sheldon a pediatrician.⁸ Inheritance of Freeman-Sheldon syndrome usually is sporadic, but both dominant and recessive autosomal transmission have been reported.^{1,5,10}

CLINICAL FEATURES

Freeman-Sheldon syndrome is characterized by a typical "whistling" facies (i.e., a small pursed mouth, long philtrum, small nose, deeply sunken eyes, and a scarlike contracture that extends from the middle of the lower lip to the chin; Fig. 30-62); ulnar deviation and thumb-in-palm deformity (Fig. 30-63); rigid talipes equinovarus (Fig. 30-64), which usually is bilateral; and short stature, generally below the third percentile.^{2,7,10,12,14}

Other associated anomalies are scoliosis and kyphosis, developmental dislocation of the hip, occasional spina bifida occulta, asymmetric pinnae, mild pterygium coli, and pectus excavatum. The clinical presentation may mimic that of distal arthrogryposis. Craniocervical abnormalities have also been described.¹³

TREATMENT

The foot and hand deformities require surgical correction.^{3,7,14,15} The feet can be very difficult to realign, and recurrence of deformity is common. Anesthetic complications can be troublesome, particularly difficulty with intubation due to microstomia and micrognathia.^{4,6,9,11}

REFERENCES

- Craniocarpotarsal Dysplasia (Freeman-Sheldon or "Whistling Face" Syndrome)
1. Alves AFP, Azevedo ES: Recessive form of Freeman-Sheldon's syndrome or "whistling face." *J Med Genet* 1977;14:139.

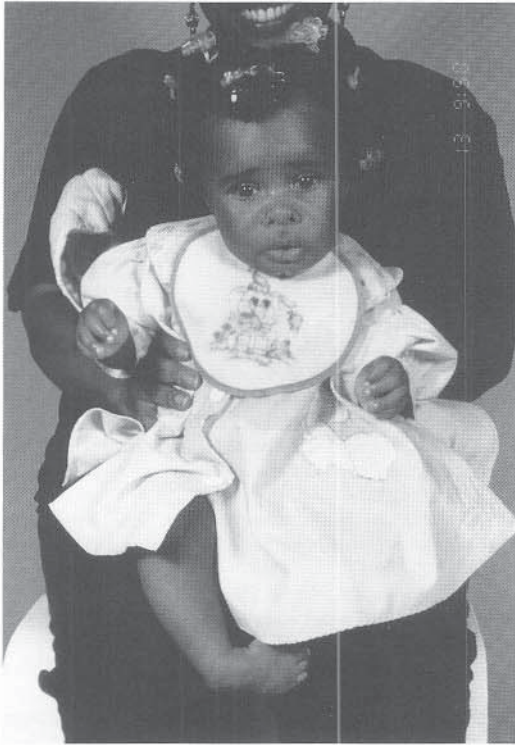

FIGURE 30-62 Clinical appearance of a baby with Freeman-Sheldon syndrome. Notice the pursed lips, small nose, and deep-set eyes.

2. Antley RM, Uga N, Burzynski NJ, et al: Diagnostic criteria for the whistling face syndrome. *Birth Defects Orig Art Series* 1975;11:161.
3. Call WH, Strickland JW: Functional hand reconstruction in the whistling-face syndrome. *J Hand Surg* 1981;6:148.
4. Cervinka J, Gorlin RJ, Figalova P, et al: Craniocarpotarsal dysplasia or whistling face syndrome. *Arch Otolaryngol* 1970;91:183.
5. Dallapiccola B, Giannotti A, Lembo A, et al: Autosomal recessive form of whistling face syndrome in sibs. *Am J Genet* 1989;30:542.
6. Duggar RG, De Mars PD, Bolton VE: Whistling face syndrome: general anesthesia and early postoperative caudal analgesia. *Anesthesiology* 1989;70:545.
7. Estrada R, Rosenfeld W, Salazar JD, et al: Freeman-Sheldon syndrome with unusual hand and foot abnormalities. *J Natl Med Assoc* 1981; 73:664.
8. Freeman EA, Sheldon JH: Cranio-carpo-tarsal dystrophy: an undescribed congenital malformation. *Arch Dis Child* 1938;13:277.

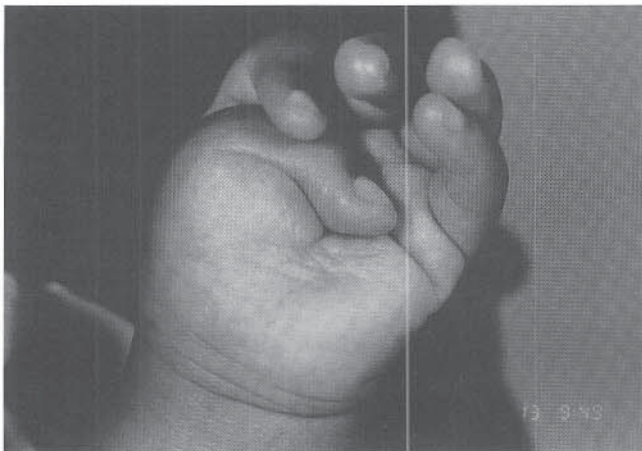


FIGURE 30-63 Rigid thumb-in-palm deformity in a child with Freeman-Sheldon syndrome.

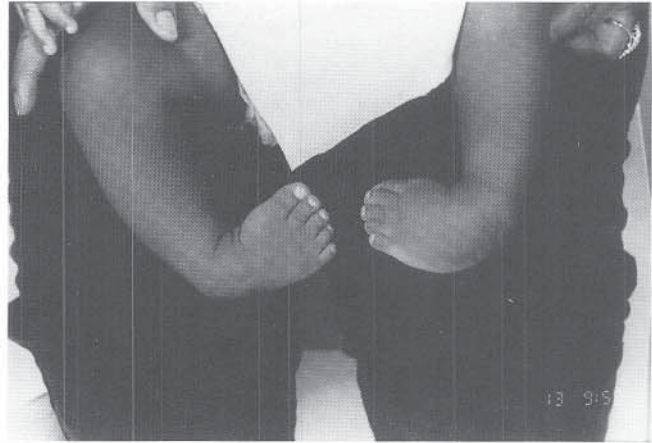


FIGURE 30-64 Bilateral severe clubfoot in Freeman-Sheldon syndrome.

9. Jones R, Dolcourt JL: Muscle rigidity following halothane in two patients with Freeman-Sheldon. *Anesthesiology* 1992;77:599.
10. Malkawi H, Tarawneh M: The whistling face syndrome, or craniocarpotarsal dysplasia: report of two cases in a father and son and review of the literature. *J Pediatr Orthop* 1983;3:364.
11. Munro HM, Butler PJ, Washington EJ: Freeman-Sheldon (whistling face) syndrome: anaesthetic and airway management. *Paediatr Anaesth* 1997;7:345.
12. Rinsky LA, Bleck EE: Freeman-Sheldon ("whistling face") syndrome. *J Bone Joint Surg* 1976;58-A:148.
13. Song HR, Sarwark JF, Sauntry S, et al: Freeman Sheldon syndrome (whistling face syndrome) and craniovertebral junction malformation producing dysphagia and weight loss. *Pediatr Neurosurg* 1996;24:272.
14. Weinstein S, Gorlin RJ: Cranio-carpo-tarsal dysplasia or the whistling face syndrome. I. Clinical considerations. *Am J Dis Child* 1969;117:427.
15. Wenner SM, Shalvoy RM: Two stage correction of thumb adductor contracture in Freeman-Sheldon syndrome. *J Hand Surg* 1989;14:937.

Cornelia de Lange's Syndrome

This rare syndrome is characterized by short stature, microcephaly, mental retardation, and distinctive facies comprising bushy eyebrows that meet in the midline, a small up-turned nose, and full eyelashes (Fig. 30-65).^{7,10,14} The patients have more body hair than usual, and may be covered in persistent lanugo. Mental retardation is usually quite severe, and features of autism (such as self-mutilation) are common.¹¹ Affected children cannot speak, and sensorineural hearing loss is frequently present.^{6,16} The severity of mental retardation has been linked to the birth weight of the infant, with larger children faring better.⁴ Congenital heart malformations are present in 29 percent of children, and cleft palate has also been associated with the syndrome.¹²

Genetic studies of patients with Cornelia de Lange's syndrome have not led to a definitive gene locus for the disease, although the long arm of chromosome 3 has been suspected.^{1,5,7,13,17,18} The risk for future pregnancies of normal parents is approximately 5 percent. Prenatal ultrasound shows a small for gestational age fetus, but is usually nonspecific otherwise.^{2,9,15}

Orthopaedic manifestations of Cornelia de Lange's syndrome include a proximal thumb due to first metacarpal shortening, clinodactyly of the fifth finger, and flexion contractures of the elbows (Fig. 30-66).⁸ There is wide variability in the severity of phenotype in patients with Cornelia de Lange's syndrome. The upper extremity manifestations



FIGURE 30–65 Clinical appearance of a child with Cornelia de Lange's syndrome. Distinctive features include the bushy eyebrows, flexion contractures of the elbows, and radial head dislocations.

range from flexion contractures of the elbows, to radial head dislocations, to radial hemimelia with ray deficiencies.

In the lower extremities, flexion contractures of the knees have been infrequently described. Syndactyly of the second and third toes is commonly seen. Toe deformities, such as hallux valgus, can occur. Hip dysplasia has also been reported in patients with Cornelia de Lange's syndrome.³

REFERENCES

Cornelia de Lange's Syndrome

1. Babu KA, Verma RS, Rodriguez J, et al: A possible clinical implication of homozygous inversions of 9qh regions with Cornelia de Lange syndrome (CLS). *Hum Hered* 1985;35:265.
2. Drolshagen LF, Durmon G, Berumen M, et al: Prenatal ultrasonographic appearance of "Cornelia de Lange" syndrome. *J Clin Ultrasound* 1992;20:470.
3. Grant RE, Schneider JA, Ferguson EJ, et al: Total hip reconstruction in a woman with Cornelia de Lange syndrome: a case report. *J Natl Med Assoc* 1997;89:530.
4. Hawley PP, Jackson LG, Kurnit DM: Sixty-four patients with Brachmann-de Lange syndrome: a survey. *Am J Med Genet* 1985;20:453.
5. Holder SE, Grimsley LM, Palmer RW, et al: Partial trisomy 3q causing mild Cornelia de Lange phenotype [see comments]. *J Med Genet* 1994;31:150.
6. Ichiyama T, Hayashi T, Tanaka H, et al: Hearing impairment in two boys with Cornelia de Lange syndrome. *Brain Dev* 1994;16:485.
7. Ireland M, Burn J: Cornelia de Lange syndrome: photo essay. *Clin Dymorphol* 1993;2:151.
8. Joubin J, Pettrone CF, Pettrone FA: Cornelia de Lange's syndrome: a review article (with emphasis on orthopedic significance). *Clin Orthop* 1982;171:180.

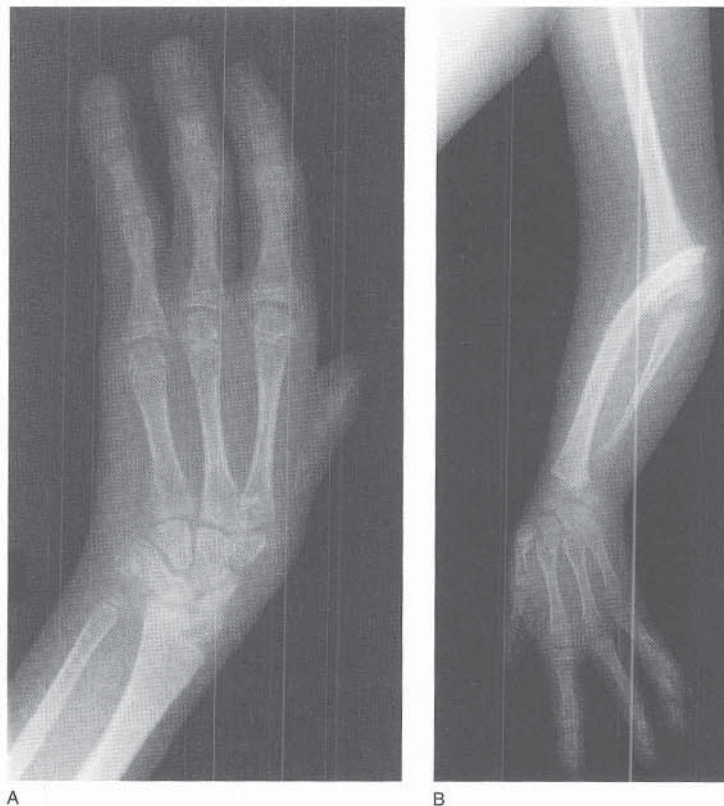

FIGURE 30–66 A, AP hand radiograph of a 12-year-old girl with Cornelia de Lange's syndrome. The first metacarpal is strikingly small so that the thumb appears smaller and proximally displaced. The fifth ray is absent. B, Upper extremity of the same girl. The proximal radius is dislocated and the ulna is hypoplastic.

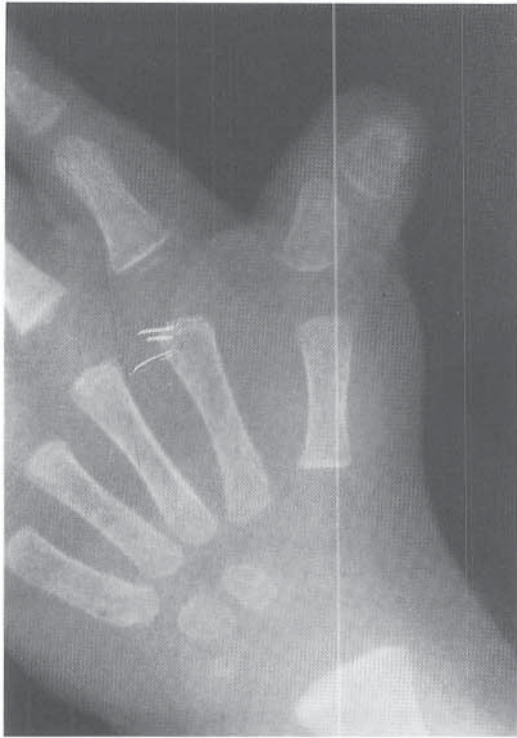

FIGURE 30-67 Radiograph of a hand showing radial deviation of the thumb with a delta proximal phalanx. This deformity is a consistent finding in Rubinstein-Taybi syndrome.

9. Kliever MA, Kahler SG, Hertzberg BS, et al: Fetal biometry in the Brachmann-de Lange syndrome. *Am J Med Genet* 1993;47:1035.
10. Kline AD, Barr M, Jackson LG: Growth manifestations in the Brachmann-de Lange syndrome. *Am J Med Genet* 1993;47:1042.
11. Kline AD, Stanley C, Belevich J, et al: Developmental data on individuals with the Brachmann-de Lange syndrome. *Am J Med Genet* 1993;47:1053.
12. Kousseff BG, Newkirk P, Root AW: Brachmann-de Lange syndrome: 1994 update. *Arch Pediatr Adolesc Med* 1994;148:749.
13. Kozma C: Autosomal dominant inheritance of Brachmann-de Lange syndrome. *Am J Med Genet* 1996;66:445.
14. Levin AV, Seidman DJ, Nelson LB, et al: Ophthalmologic findings in the Cornelia de Lange syndrome. *J Pediatr Ophthalmol Strabismus* 1990;27:94.
15. Manouvrier S, Espinasse M, Vaast P, et al: Brachmann-de Lange syndrome: pre- and postnatal findings [see comments]. *Am J Med Genet* 1996;62:268.
16. Sataloff RT, Spiegel JR, Hawkshaw M, et al: Cornelia de Lange syndrome: otolaryngologic manifestations. *Arch Otolaryngol Head Neck Surg* 1990;116:1044.
17. Shaffer LG, Overhauser J, Jackson LG, et al: Genetic syndromes and uniparental disomy: a study of 16 cases of Brachmann-de Lange syndrome. *Am J Med Genet* 1993;47:383.
18. Tranebjaerg L, Baekmark UB, Dyhr-Nielsen M, et al: Partial trisomy 3q syndrome inherited from familial t(3; 9)(q26.1; p23). *Clin Genet* 1987;32:137.

Rubinstein-Taybi Syndrome

Rubinstein-Taybi syndrome is recognized clinically by characteristic facial features, which include a broad, long nose that has been called “comical” or Cyrano-like, and by broad distal phalanges of the thumb and great toe. The great toe may also have a delta phalanx and be deviated into varus.⁴ Affected individuals are mentally retarded, with IQ values between 35 and 80.²

ORTHOPAEDIC MANIFESTATIONS

There are three “orthopaedic” manifestations. First are the typical thumb and toe deformities, which should prompt clinical recognition of the syndrome (Figs. 30-67 and 30-68). The second feature is a report of cervical spondylolisthesis associated with congenital vertebral anomalies.³ The third musculoskeletal problem is dislocation of the patella.

SURGICAL TREATMENT

Surgical treatment of patellar dislocations has been reported to be successful.⁶ Most of the patients had chronic, bilateral patellar dislocations. Another indication for surgical treatment is a symptomatic varus of the thumb or great toe. Realignment procedures, though, may be plagued with recurrence due to the growth disturbance related to the delta phalanx.

ASSOCIATED ANOMALIES

Children with Rubinstein-Taybi syndrome will have other anomalies and thus need to be carefully evaluated prior to surgery. They often have congenital heart defects, and occasionally they have gastrointestinal abnormalities.^{2,7} A significant incidence of mediastinal vascular rings is reported, with tracheal and esophageal obstruction.⁵ Unusual reactions to anesthetic agents have also been reported.⁸ And finally, giant keloid formation has been reported¹ as well.

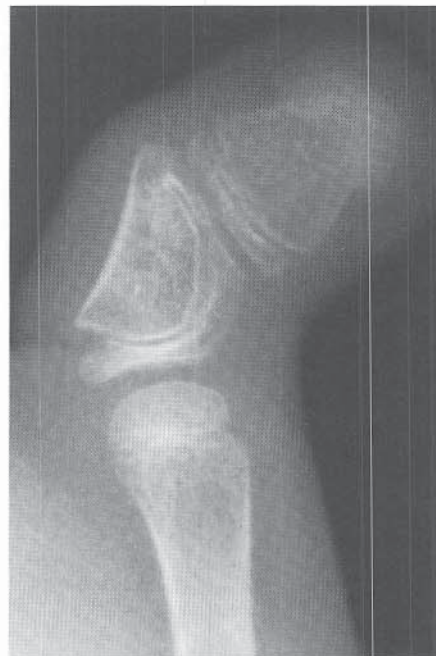

FIGURE 30-68 Radiograph of the thumb of an older child showing that the delta phalanx is the result of a bracket epiphysis. Consideration should be given to resection of the bracket in order to allow longitudinal growth.

REFERENCES

Rubinstein-Taybi Syndrome

- Hendrix JD Jr, Greer KE: Rubinstein-Taybi syndrome with multiple flamboyant keloids. *Cutis* 1996;57:346.
- Hennekam RC, Van Den Boogaard MJ, et al: Rubinstein-Taybi syndrome in The Netherlands. *Am J Med Genet (Suppl)* 1990;6:17.
- Robson MJ, Brown LM, Sharrad WJW: Cervical spondylolisthesis and other skeletal abnormalities in Rubinstein-Taybi syndrome. *J Bone Joint Surg* 1980;62-B:297.
- Rubinstein JH: Broad thumb-hallux (Rubinstein-Taybi) syndrome 1957-1988. *Am J Med Genet (Suppl)* 1990;6:3.
- Shashi V, Fryburg JS: Vascular ring leading to tracheoesophageal compression in a patient with Rubinstein-Taybi syndrome. *Clin Genet* 1995;48:324.
- Stevens CA: Patellar dislocation in Rubinstein-Taybi syndrome. *Am J Med Genet* 1997;72:188.
- Stevens CA, Bhakta MG: Cardiac abnormalities in the Rubinstein-Taybi syndrome. *Am J Med Genet* 1995;59:346.
- Stirt JA: Anesthetic problems in Rubinstein-Taybi syndrome. *Anesth Analg* 1981;60:534.

Otopalatodigital Syndrome

The otopalatodigital syndrome is characterized by cleft palate, deafness, hallux valgus, and occasional spine deformities. It is thought to be an X-linked dominant trait. Omphalocele has been reported in three cases.⁵

Type I was first described by Taybi in 1962.⁴ Findings include mild mental deficiency, small stature, moderate conductive deafness, and craniofacial changes, including frontal and occipital prominence with hypertelorism and a small nose and mouth. There is limited elbow extension and medial tibial bowing (Fig. 30-69). The distal phalanges of the thumbs and toes are short and broad, and there may be hallux valgus. Transmission is by X-linked dominant expression in males and intermediate expression in females.^{1,4}

Type II was described by Fitch and colleagues in 1976 and has more severe facial deformities, especially a prominent forehead with hypertelorism and a prominent forehead. There is usually a cleft palate. The fingers are flexed and overlap, and the thumbs and great toes are short and broad. Often polydactyly is present and occasionally syndactyly of the hands and feet. The phalanges of the fingers and toes are poorly ossified or absent. Joint subluxation is present at the elbows, wrists, knees, and hips. The vertebral bodies are flattened, and the ilia may be hypoplastic. Most affected children are stillborn or die before 5 months of age from respiratory disorders.^{2,3,5}

REFERENCES

Otopalatodigital Syndrome

- Dudding B, Gorlin RJ, Langer L: The oto-palato-digital syndrome: a new symptom-complex consisting of deafness, dwarfism, cleft palate, characteristic facies, and a generalized bone dysplasia. *Am J Dis Child* 1967;113:214.
- Fitch N, Jequier S, Papageorgiou A: A familial syndrome of cranial, facial, oral, and limb anomalies. *Clin Genet* 1976;10:226.
- Holder SE, Winter RM: Otopalatodigital syndrome type II. *J Med Genet* 1993;30:310.
- Taybi H: Generalized skeletal dysplasia with multiple anomalies. *AJR Am J Roentgenol* 1962;88:450.
- Young K, Barth CK, Moore C, et al: Otopalatodigital syndrome type II associated with omphalocele: report of three cases. *Am J Med Genet* 1993;45:481.

Proteus Syndrome

In 1983, Wiedemann and associates described "a newly recognized hamartomatous syndrome" in four boys, characterized by the clinical constellation of (1) partial gigantism of the hands and/or feet, (2) pigmented nevi, (3) hemihypertrophy, (4) subcutaneous hamartomatous tumors, and (4) macrocephaly or other skull anomalies.²⁵ The authors were certain that the syndrome had been recognized and described by previous authors, including Graetz¹⁰ in 1928 and Tentamy and associates in 1976.²⁰

Wiedemann and associates recommended that the syndrome be considered one of the congenital hamartomatous disorders, separate and distinct from conditions such as neurofibromatosis, Klippel-Trénaunay-Weber syndrome, Ollier's disease, and Maffucci's syndrome.²⁵

Because this disorder was characterized by such striking and varied deformities, they called it Proteus syndrome, after the Greek god of the same name.²⁵ Proteus (meaning polymorphous) was capable of transforming himself into any shape to disguise himself in order to escape from his enemies. Wiedemann and associates felt certain that this syndrome was capable of doing the same to prevent detection by the physician as a specific disorder.

One of the interesting aspects of this extremely rare condition (fewer than 100 cases have been described in the English literature under the term *Proteus*) is that it is now considered likely that Joseph (more commonly but incorrectly known as John) Merrick of "Elephant Man" fame, described by Sir Frederick Treves²¹ in 1885, suffered from Proteus syndrome^{4,22} and not neurofibromatosis, as was long and commonly believed.

The genetic implications of Proteus syndrome are not well understood. Possible transmission from father to son has been reported.⁸ Spontaneous mutation as a lethal autosomal dominant condition, with survival attributed to mosaicism, has been postulated by others.¹ However, no other cases reported in the English literature recorded a positive family history or a history of a consanguineous relationship.

CLINICAL FEATURES

The clinical features are truly protean in their variety, severity, and combinations in described cases.^{2,5,13,23,24} These features are particularly well summarized in reviews by Wiedemann and associates²⁵ and Stricker.¹⁹ The primary clinical features are macrodactyly, hemihypertrophy, pigmented nevi, subcutaneous tumors (mostly lymphangiomas), and axial skeletal anomalies (Fig. 30-70). Individual patients may not exhibit all of these features, and the severity of the features varies among patients. For example, lower extremity hemihypertrophy can be a relatively minor finding or it can be severely grotesque, affecting limb function and greatly challenging the treating physician.¹⁴

Macrodactyly (Fig. 30-71) is the most common feature described. The digits are usually normal at birth but can enlarge massively over time. In the hand, the third and fourth digits are most commonly affected. *Hemihypertrophy* is nearly as common and may be partial, complete, or independent of macrodactyly. *Pigmented (epidermal) nevi* are present in more than 75 percent of patients and may be

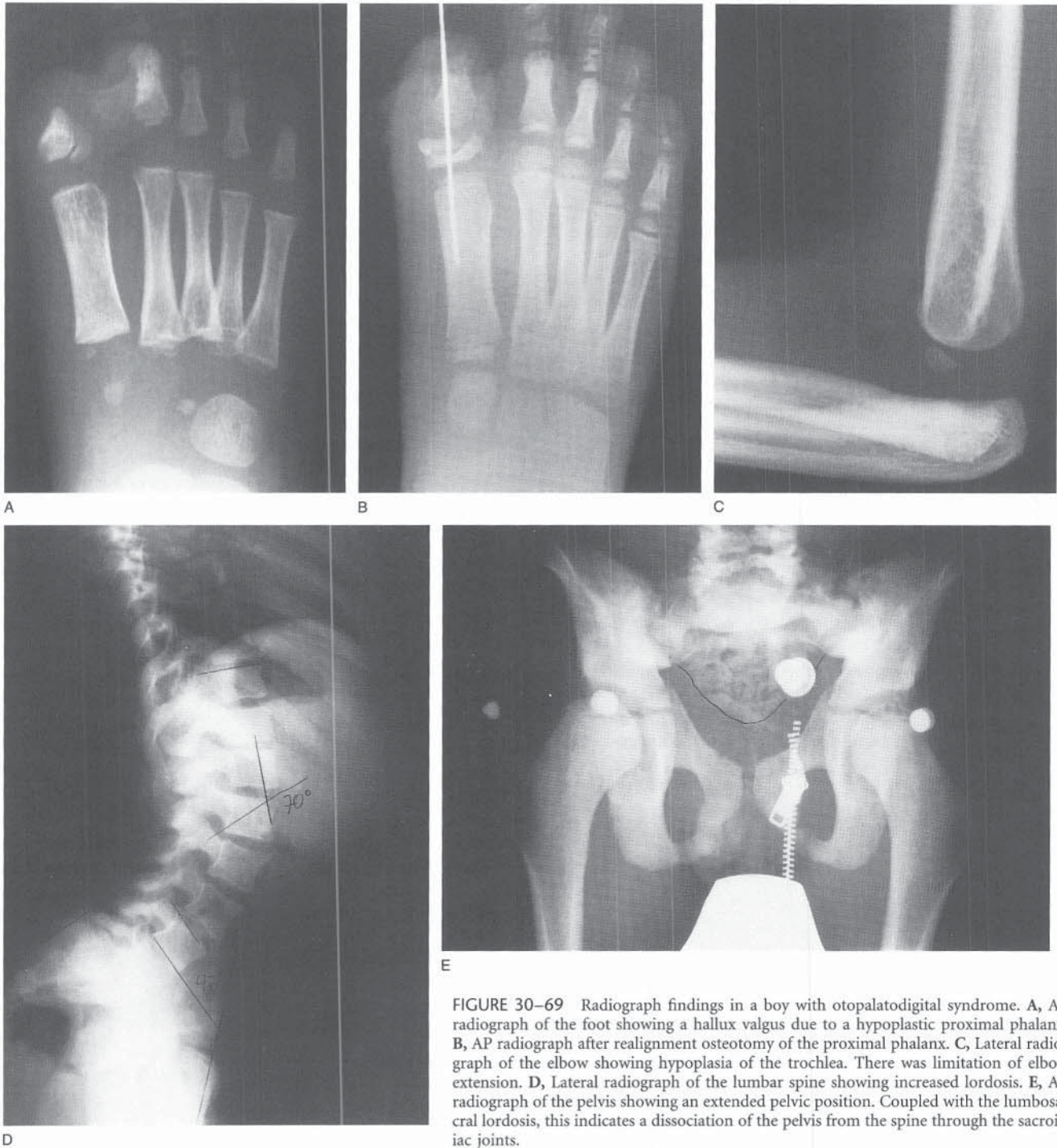


FIGURE 30-69 Radiograph findings in a boy with otopalatodigital syndrome. **A**, AP radiograph of the foot showing a hallux valgus due to a hypoplastic proximal phalanx. **B**, AP radiograph after realignment osteotomy of the proximal phalanx. **C**, Lateral radiograph of the elbow showing hypoplasia of the trochlea. There was limitation of elbow extension. **D**, Lateral radiograph of the lumbar spine showing increased lordosis. **E**, AP radiograph of the pelvis showing an extended pelvic position. Coupled with the lumbosacral lordosis, this indicates a dissociation of the pelvis from the spine through the sacroiliac joints.

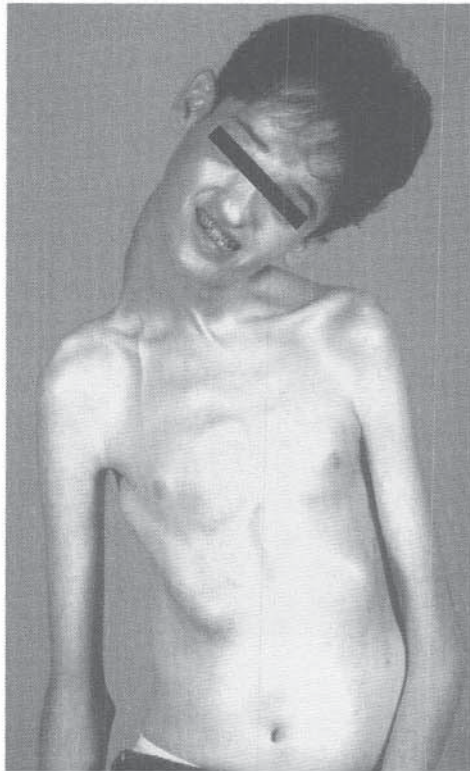


FIGURE 30-70 Adolescent with Proteus syndrome. Note the cranial bossing. The patient has cervicothoracic scoliosis with spondylomegaly (see Fig. 30-72), digital macrodactyly, hemihypertrophy, hindfoot varus of the left foot and valgus of the right, and subcutaneous tumors.

located anywhere on the body. Abrupt midline margins are frequently noted. These lesions may be covered with thickened skin. *Subcutaneous soft tissue tumors* may also be found anywhere in the body. On biopsy, most are lymphangiomas that are frequently confluent with surrounding normal tissue, making resection difficult. *Axial skeletal anomalies*

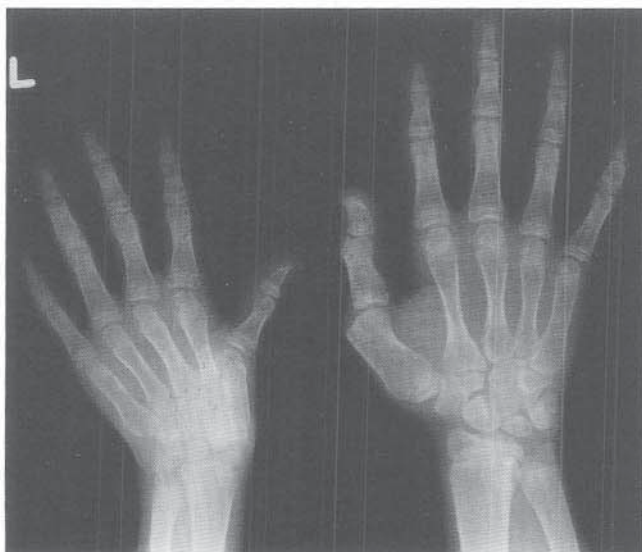


FIGURE 30-71 Hemihypertrophy of the right hand in Proteus syndrome. Note the enlargement of the distal radius and ulna, and macrodactyly of the first ray.

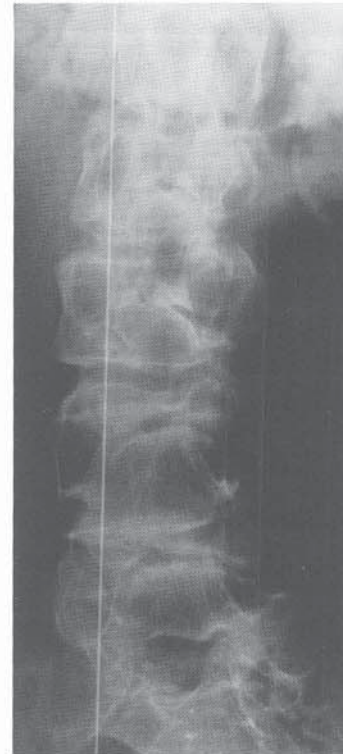


FIGURE 30-72 Spondylomegaly of the lumbar vertebra in Proteus syndrome.

include vertebral gigantism, with or without scoliosis and/or kyphosis (Fig. 30-72), and bony protuberances of the skull in the frontotemporal or parieto-occipital areas. Other skeletal features that have been noted include genu valgum, hindfoot deformities (Fig. 30-73), verrucous soft tissue hypertrophy of the sole of the foot (described by Cohen as a “moccasin” lesion⁴) (Fig. 30-74), hip dysplasia, exostoses, and generalized acceleration of skeletal growth.

Reported neurologic sequelae include gross motor delay, mental retardation in some patients, intracranial lesions, a case of sinus thrombosis,⁷ and peripheral nerve enlargement

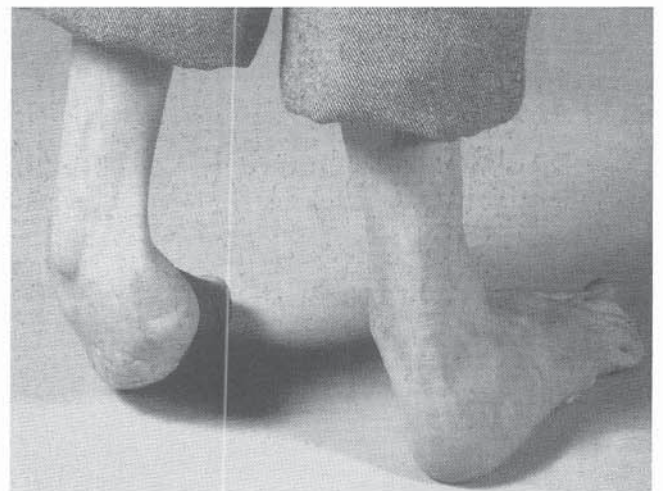


FIGURE 30-73 Hindfoot varus of the left foot and hindfoot valgus of the right foot, in same patient as in Figure 30-70.

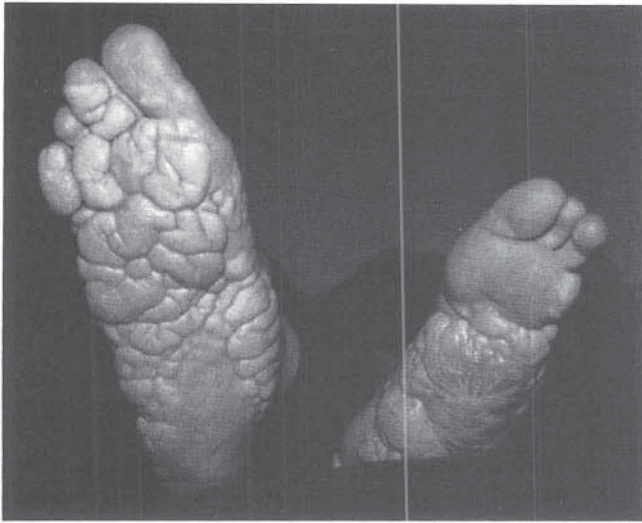


FIGURE 30-74 Verrucous soft tissue hypertrophy of the left foot (“moccasin deformity”) in Proteus syndrome. The patient has undergone resection of the lateral two rays to manage osteomyelitis and tissue necrosis due to previous fixed varus deformity of the foot.

with entrapment syndromes.¹⁵ At least three cases of spinal cord compression have been reported.^{17,18} Two were due to intrathecal angioliipoma and one to acute kyphosis. Intra-abdominal neoplasms (usually benign) have been described.⁹ Finally, death secondary to airway obstruction has been reported, occurring spontaneously during sleep (the victims included a 5-year-old child and Merrick, at age 29), preoperatively after sedation, and postoperatively.

DIAGNOSIS

The diagnosis of Proteus syndrome is entirely clinical. It is based on demonstration of the characteristic features of this disorder, and not on meeting the criteria of the similar congenital hamartomatous conditions. Hotamisligil has proposed a rating scale based on the presence of six clinical features to assist in the diagnosis (Table 30-6).¹²

TABLE 30-6 Rating Scale for the Diagnosis of Proteus Syndrome

Clinical Features	Points
Macroductyly and/or hemihypertrophy	5.0
Thickening of skin	4.0
Lipomas and subcutaneous tumors	4.0
Verrucous epidermal nevus	3.0
Macrocephaly and/or Buckelshadel	2.5
Other minor abnormalities	1.0

Definitive diagnosis, >13 points; questionable diagnosis, 10–13 points; diagnosis excluded, <10 points.

From Stricker S: Musculoskeletal manifestations of Proteus syndrome: report of two cases with literature review. *J Pediatr Orthop* 1992;12:667. Modified from Hotamisligil GS: Proteus syndrome and hamartoses with overgrowth. *Dysmorphol Clin Genet* 1990;4:87.

DIFFERENTIAL DIAGNOSIS

The primary entities to be distinguished from Proteus syndrome include idiopathic hemihypertrophy, isolated macroductyly, neurofibromatosis, Ollier’s disease, Maffucci’s syndrome, and Klippel-Trénaunay-Weber syndrome. Idiopathic hemihypertrophy and isolated macroductyly are normally distinguished by the absence of other clinical manifestations associated with Proteus syndrome. Neurofibromatosis patients often have a family history of the disorder as well as café-au-lait spots, axillary freckling, Lesch-Nihan nodules, and distinctly different bony abnormalities (when present). Ollier’s disease is characterized primarily by typical osseous lesions and by the skeletal distortions that result from interference of the enchondromas with normal physal growth. Maffucci’s syndrome is similar to Ollier’s disease, with the additional features of hemangiomas and a propensity to soft tissue malignancies. Klippel-Trénaunay-Weber syndrome is characterized by more severe and extensive vascular anomalies than simple pigmented nevi, and, as a rule, the skeletal abnormalities are limited to gigantism associated with the soft tissue hypertrophy. These various disorders and their clinical features are described elsewhere in this text.

ORTHOPAEDIC MANAGEMENT

The orthopaedic problems encountered in the reported cases of Proteus syndrome include management of macroductyly, limb length inequality, genu valgum, hindfoot deformity, and spinal deformity (especially scoliosis).^{3,6,11,19} Reaccumulation of hypertrophied tissues appears to be common after reduction procedures, and in general, ablations are preferable when clinically appropriate. Biopsy of non-neoplastic enlargement has revealed mature adiposal tissue in a fibrous stroma in almost all reported cases. The treatment of genu valgum by osteotomy in skeletally immature patients frequently results in recurrence of deformity. Limb length inequality has been managed by shortening osteotomies or epiphysiodesis. Scoliosis does not seem to respond to bracing, and instrumentation and fusion may be required. Despite fusion, though, progression of deformity can occur.

Finally, the treating surgeon should be alert to the possibility of spinal cord compromise, entrapment neuropathies, and perioperative respiratory problems due to positional obstruction or difficulty with intubation.¹⁶

REFERENCES

Proteus Syndrome

1. Aylsworth AS, Friedmann PA, Powers SK, et al: New observations with genetic implications in two syndromes: (1) father to son transmission of the Nager acrofacial dysostosis syndrome; and (2) parental consanguinity in the Proteus syndrome. *Am J Hum Genet* 1987;41:A43.
2. Azouz EM, Costa T, Fitch N: Radiologic findings in the Proteus syndrome. *Pediatr Radiol* 1987;17:481.
3. Barmakian JT, Posner MA, Silver L, et al: Proteus syndrome. *J Hand Surg* 1992;17-A:32.
4. Cohen MM Jr: Understanding Proteus syndrome, unmasking the Elephant Man, and stemming elephant fever. *Neurofibromatosis* 1988; 1:260.
5. Cremin BJ, Viljoen DL, Wynchank S, et al: The Proteus syndrome:

- the magnetic resonance and radiological features. *Pediatr Radiol* 1987;17:486.
6. Demetriades D, Hager J, Nikolaidis N, et al: Proteus syndrome: musculoskeletal manifestations and management. A report of two cases. *J Pediatr Orthop* 1992;12:106.
 7. Dietrich RB, Glidden DE, Roth GM, et al: The Proteus syndrome: CNS manifestations. *AJNR Am J Neuroradiol* 1998;19:987.
 8. Goodship J, Redfearn A, Milligan D, et al: Transmission of Proteus syndrome from father to son? *J Med Genet* 1991;28:781.
 9. Gordon PL, Wilroy RS, Lasater OE, et al: Neoplasms in Proteus syndrome. *Am J Med Genet* 1995;57:74.
 10. Graetz I: Über einen Fall von sogenannter "totaler halbseitiger Körperhypertrophie." *Z Kinderheilk* 1928;45:381.
 11. Guidera KJ, Brinker MR, Kousseff BG, et al: Overgrowth management in Klippel-Trénaunay-Weber and Proteus syndromes. *J Pediatr Orthop* 1993;13:459.
 12. Hotamisligil GS: Proteus syndrome and hamartoses with overgrowth. *Dysmorphol Clin Genet* 1990;4:87.
 13. Lacombe D, Taieb A, Vergnes P, et al: Proteus syndrome in 17 patients: clinical and genetic considerations. *Genet Couns* 1991;2:93.
 14. Mayatepek E, Kurczynski W, Ruppert ES, et al: Expanding the phenotype of the Proteus syndrome: a severely affected patient with new findings. *Am J Med Genet* 1989;32:402.
 15. McCullagh M, Harper J, Pitt MC, et al: Median nerve compression in Proteus syndrome. *Pediatr Surg Int* 1998;13:449.
 16. Pennant JH, Harris MF: Anaesthesia for Proteus syndrome. *Anaesthesia* 1991;46:126.
 17. Ring D, Snyder B: Spinal canal compromise in Proteus syndrome: case report and review of the literature. *Am J Orthop* 1997;26:275.
 18. Skovby F, Graham JM Jr, Sonne-Holm S, et al: Compromise of the spinal cord in Proteus syndrome. *Am J Med Genet* 1993;47:656.
 19. Stricker S: Musculoskeletal manifestations of Proteus syndrome: report of two cases with literature review. *J Pediatr Orthop* 1992;12:667.
 20. Temtamy SA, Rogers JG: Macroductyly, hemihypertrophy, and connective tissue nevi: report of a new syndrome and review of the literature. *J Pediatr* 1976;89:924.
 21. Treves F: A case of congenital deformity. *Trans Pathol Soc Lond* 1885;36:494.
 22. Tribbles AR, Cohen MM Jr: The Proteus syndrome: the Elephant Man diagnosed. *BMJ* 1986;293:683.
 23. Vaughn RY, Selinger CG, Howell RA, et al: Proteus syndrome: diagnosis and surgical management. *J Pediatr Surg* 1993;28:5.
 24. Viljoen DL, Nelson MM, de Jong G, et al: Proteus syndrome in Southern Africa: natural history and clinical manifestations in six individuals. *Am J Med Genet* 1987;27:87.
 25. Wiedemann H-R, Burgio GR, Aldenhoff P, et al: The Proteus syndrome: partial gigantism of the hands and/or feet, nevi, hemihypertrophy, subcutaneous tumors, macrocephaly, skull anomalies and possible accelerated growth and visceral affections. *Eur J Pediatr* 1983;140:5.

Klippel-Trénaunay Syndrome

In 1900, Klippel and Trénaunay described a patient with the triad of cutaneous nevus, varicosities, and limb hypertrophy.¹⁰ In a review of 50 other cases from the literature, they also described what they called "forme-fruste" cases, in which the patients manifested only two features of the triad, and "crossed dissociation" (*forme croisée dissociée*) cases, in which the hypertrophied limb was the uninvolved or lesser involved extremity.

In 1907, F. Parkes Weber apparently independently described three cases with same triad,²² and in 1918 he described an additional patient with the triad and arteriovenous fistulae.²³ In 1965, Lindenaier also distinguished between the presence or absence of arteriovenous fistulae in association with the triad.¹² Unfortunately, his outline of the history of the descriptive publications referred to F. Parkes Weber as Parkes-Weber, apparently without justification for hyphenation of the name.¹¹ Since then, some

confusion over terminology and specific definition of the syndrome has prevailed.

Some authors use the *Klippel-Trénaunay syndrome* strictly for patients with at least two of the classic triad, reserving the terms *Parkes-Weber* or *Klippel-Trénaunay-Weber syndrome* for patients with some of these features plus arteriovenous fistulae. Others refer to *Klippel-Trénaunay-Weber syndrome* without specifying (or necessarily identifying or requiring) the presence of an arteriovenous fistula in the grouping of patients under this eponym. Still others have suggested that patients with two or more of any of the four features be referred to as having *Klippel-Trénaunay-type syndrome*.²

This confusion in terminology is compounded by the lack of understanding of the pathophysiology of the disorder, an absence of any identifiable genetic features, and the fact that the diagnosis is purely a clinical, descriptive one. Furthering the confusion are rare individual cases in which the classic triad overlaps with features associated with neurofibromatosis or Proteus syndrome.⁸ Because the original description by Klippel and Trénaunay consisted of the "classic triad" of nevus, varicosity, and bone and soft tissue hypertrophy, and because several large series have demonstrated the relatively rare association of the triad with arteriovenous fistulae, we prefer to use the term *Klippel-Trénaunay syndrome* and reserve the term *Klippel-Trénaunay-Weber syndrome* for patients with two or more features of the triad plus arteriovenous fistulae.

PATHOPHYSIOLOGY

The etiology of Klippel-Trénaunay syndrome is not known. It is clearly not a genetic condition, although its features are most commonly evident from birth.

Baskerville and associates conducted a study of blood flow and deep vein competence in 33 patients with 36 affected lower extremities (some patients had a nevus on the otherwise unaffected contralateral lower limb).³ An abnormal lateral venous channel was found in 23 limbs (68 percent), but only five patients (14 percent) had atresia of the deep vein system. Some patients did have incompetent communicating veins in the calf and valveless or incompetent deep veins. Blood flow measurement in the calf revealed that flow was greater in the limbs with a nevus and greatest in limbs with both nevus and hypertrophy, compared with a completely unaffected limb. However, all measured values were within normal limits, confirming for the authors that an arteriovenous fistula was not present. Furthermore, there was no correlation between the increase in calf blood flow and the extent of hypertrophy. The authors felt that Klippel-Trénaunay syndrome was caused by a mesodermal defect, resulting in maintenance of fetal microscopic arteriovenous communications.

In a histologic study of tissue samples from 29 surgically treated patients, the most common and consistent vascular lesions represented "venous fibromuscular dysplasia," according to the investigators.¹¹ The lesions consisted of abnormal development of the vein wall with alternating segments of normal, hypertrophied, or deficient media. Aneurysmal dilation occurred where the media was deficient. Only one microscopic arteriovenous fistula was identified in one of

two amputated lower limb specimens; neither amputated limb demonstrated deep vein atresia or absence.

CLINICAL FEATURES

Nevus. The *nevus*, or birthmark, is most commonly a port-wine stain that may be located anywhere on the body, but usually is discoloring the hypertrophied limb at a minimum. This mark is virtually always present at birth. Its size and intensity can change as the patient matures, often fading but rarely disappearing. Abrupt midline borders usually demarcate larger lesions.

Varicosities. Varicosities typically develop with growth, but may be present from birth. In the lower limb, these varicosities include a lateral system and usually are not associated with deep venous system incompetence.

Bone and Soft Tissue Hypertrophy. Bone and soft tissue hypertrophy of a limb varies considerably in onset and severity. In some cases the hypertrophy is present at birth, while in others it develops with growth. The distortions can vary from a mild limb length discrepancy to greater than 10 cm inequality, with very disfiguring anomalies or enlargements of the digits (Fig. 30–75).^{7,8,14,15,17} In the majority of cases (up to 90 percent of patients), the lower extremity is involved, but the upper extremity can be the hypertrophied limb. Usually the limb affected by the nevus and varicosities

is the one that is hypertrophied. However, in perhaps 1 to 2 percent of cases, the contralateral limb is the enlarged one (a feature that Klippel and Trénaunay noted and termed “crossed dissociation”).

Some series of this syndrome identify up to 68 percent of patients as having only two of the features of the triad. Other authors specifically exclude patients without the full complement of features, despite the fact that Klippel and Trénaunay recognized this as a “forme-fruste” variant of the syndrome.

Associated orthopaedic conditions that have been described include developmental dysplasia of the hip (10 of 252 patients in the series by Jacob and associates⁸), syndactyly, metatarsus adductus, congenital clubfoot, and scoliosis.

Nonorthopaedic features that can occur over time in these patients include thrombophlebitis, recurrent cellulitis, friability of the extremity, pelvic and intra-abdominal varices causing local hemorrhage, hematuria, rectal bleeding, intra-abdominal bleeding, and, rarely, intracranial hemorrhage.^{1,3–5,8,9,16,17,20} In a review of 49 patients by Baskerville and associates, 25 percent had had one or more severe spontaneous hemorrhages from dilated varices, 22 percent had suffered a venous thromboembolism, and 29 percent had had episodes of rectal bleeding or hematuria from pelvic angiomas.³ In the series of 252 patients reported by Jacob and associates, 11 had deep vein thrombosis and nine had pulmonary embolism, which was fatal in one patient.⁸ Risk

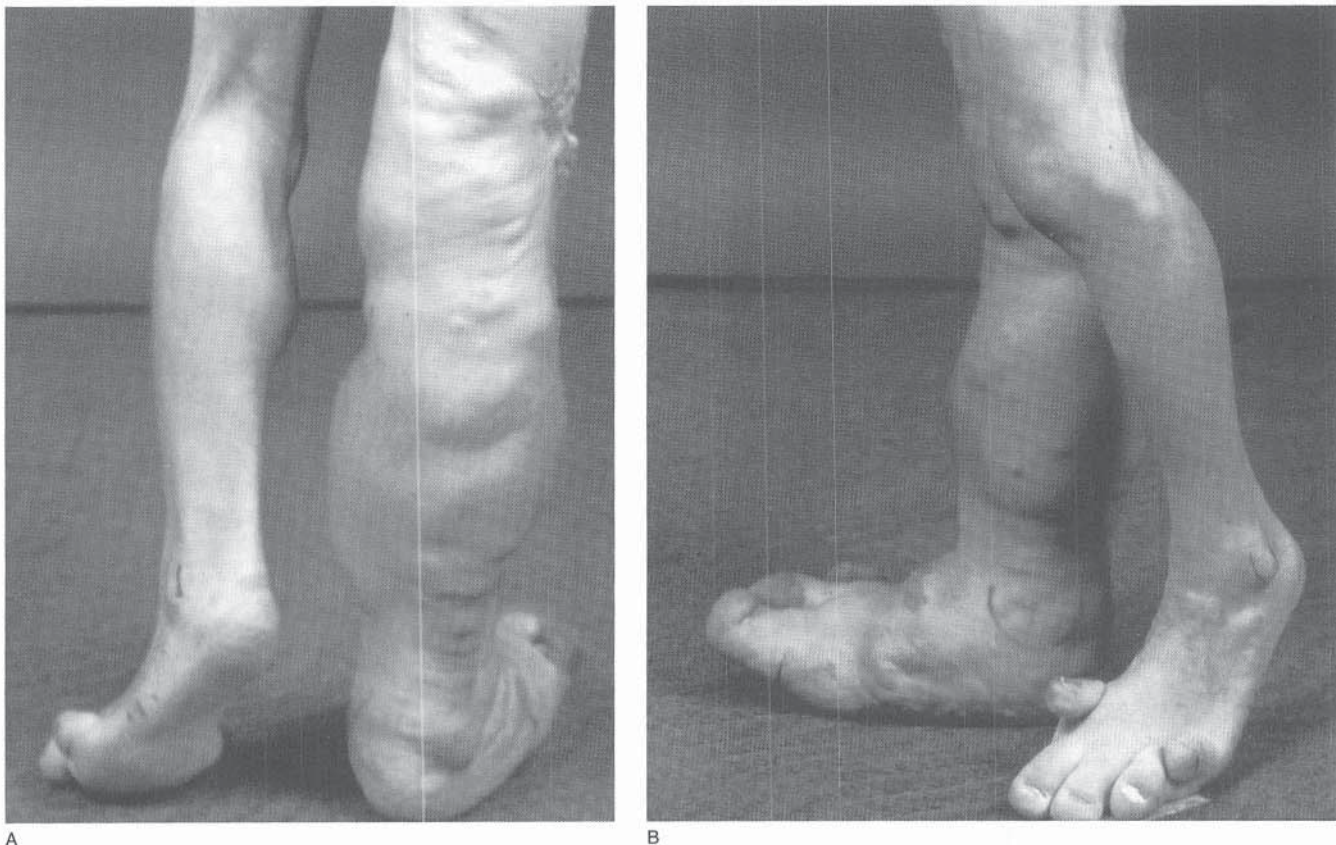


FIGURE 30–75 A and B, Patient with classic Klippel-Trénaunay syndrome. Note the triad of port-wine stain, varicosities, and significant bone and soft tissue hypertrophy of the right lower extremity.

factors for developing deep vein thrombosis included pelvic surgery, pregnancy, sclerotherapy, oral contraceptive use, and invasive investigations.

DIAGNOSIS

The diagnosis is based on the identification of the three clinical features of the triad—nevus, varicosities, and bone and soft tissue hypertrophy. In most series females slightly outnumber males, in a 1.3:1 ratio.^{8,14,17} Most patients (90 percent in the series reported by Jacob and associates) have evidence of the syndrome at birth.⁸ In the series reported by Jacobs and associates, family members recognized the presence of some features in the affected child by 9 years of age.

PATIENT EVALUATION

Patients with the Klippel-Trénaunay triad should be assessed for the presence and extent of limb length inequality. If present, the discrepancy should be further documented with scanograms, repeated as necessary during the patient's growth.

The presence of arteriovenous fistulae should be assessed clinically by palpating and auscultating for bruits and by examining the patient for evidence of high-output cardiac failure.¹³ If either is present, an arteriography should be performed. As mentioned previously, the presence of true arteriovenous fistulae is very uncommon in Klippel-Trénaunay syndrome, and if they are present, the entity should be more precisely delineated as the Klippel-Trénaunay-Weber syndrome.

In patients with symptomatic varices who are candidates for superficial varicosity ligation, the competency of the deep venous system should be carefully evaluated by phlebography, Doppler flow studies, or MRI prior to surgery. Other symptomatic vascular lesions, such as intrapelvic or intramuscular angiomas, should be assessed by MRI to determine the extent of the lesion and the feasibility of resection.

TREATMENT

The majority of patients with Klippel-Trénaunay syndrome will need only symptomatic treatment.^{8,14,17} If the varicosities are minimal, the nevus is superficial and stable, and the lower extremity hypertrophy results in less than 2 cm of limb length inequality without significant foot distortion, supportive treatment and reassurance only may be necessary.²¹

Ligation or sclerotherapy can be considered for treating symptomatic varicosities. Prior to these procedures, though, the presence and competence of the deep venous system must be carefully assessed. Otherwise, the treatments are unlikely to be successful.^{8,17} Intermittent or prophylactic antibiotics may be necessary for recurrent cellulitis. Thrombophlebitis and thromboembolism may require bed rest, elevation of the extremity, and anticoagulation therapy. Prophylactic therapy against thrombophlebitis and thromboembolism should be carefully considered when major orthopaedic, pelvic, or invasive investigational procedures are to be performed. The use of oral contraceptives increases the risk of these complications and should be avoided.

Resection of venous or lymphatic lesions is generally difficult and is often incomplete or followed by recurrence of the lesion. Thus, careful preoperative assessment with MRI is required, and the resection should only be performed based on the degree of problems created by the lesion. The surgeon also needs to take into account potential recurrence, intraoperative bleeding, and the pain that can result from the attempted resection.

Venous or lymphatic stasis can cause soft tissue swelling of an extremity, compounding the true bony and soft tissue hypertrophy of the syndrome. This problem can be managed by a program of nocturnal, intermittent pneumatic compression, combined with the prescription of a custom-fitted graduated compression support garment to be used during daytime for the affected extremity. This approach can significantly improve the soft tissue swelling component of limb enlargement, and can also improve symptoms from varicosities or friable superficial lesions.^{8,19} Reduction in limb enlargement, however, does not appear to influence limb length inequality at maturity.

ORTHOPAEDIC CONSIDERATIONS

Orthopaedic management is generally directed toward treating the bony and soft tissue hypertrophy. Shoe lifts and custom-fitted shoes may need to be prescribed if there is significant limb length inequality or differences in foot size. Skeletally immature patients with limb length inequality greater than 2 cm should be monitored by clinical examination supplemented with scanograms. Because the rate of growth of the hypertrophied limb is unpredictable,^{7,8,14,17} length discrepancies need to be documented on a regular basis. The most appropriate surgical procedure to manage limb length discrepancy greater than 2 cm is appropriately timed epiphysiodesis of the longer limb. Wound healing has not been reported to be a problem after standard epiphysiodesis techniques.^{6,7}

For patients with local gigantism, reduction procedures, epiphysiodesis, ray or digital resection, or amputation can be considered for functional or cosmetic purposes. Local reduction procedures often are unsatisfactory because of inadequate reduction, recurrence, or wound healing problems. Ray resection for the treatment of localized digital gigantism or as a method of foot reduction has been reported to be successful, and wound healing is not a common problem.^{6,8} Occasionally, a Syme or below-knee amputation is necessary for extreme gigantism or poor foot function.^{8,18} However, the treating surgeon and family must be aware that wound dehiscence, bleeding, or infection have complicated virtually every reported amputation in patients with Klippel-Trénaunay syndrome. These complications require extended local care or repeated debridements; however, good function and fitting of the residual limb has ultimately been achieved in most cases.

REFERENCES

Klippel-Trénaunay Syndrome

1. Aronoff DM, Roshon M: Severe hemorrhage complicating the Klippel-Trénaunay-Weber syndrome. *South Med J* 1998;91:1073.
2. Atiyeh BS, Musharrafieh RS: Klippel-Trénaunay-type syndrome: an eponym for various expressions of the same entity. *J Med* 1995;26:253.

3. Baskerville PA, Ackroyd JS, Thomas ML, et al: The Klippel-Trénaunay syndrome: clinical, radiological and haemodynamic features and management. *Br J Surg* 1985;72:232.
4. Darwish K, Bleau BL: Extensive small bowel varices as a cause of severe anemia in Klippel-Trénaunay-Weber syndrome. *Am J Gastroenterol* 1998;93:2274.
5. de Leon-Casasola OA, Lema MJ: Anesthesia for patients with Sturge-Weber disease and Klippel-Trénaunay syndrome. *J Clin Anesth* 1991; 3:409.
6. Gates PE, Drvaric DM, Kruger L: Wound healing in orthopaedic procedures for Klippel-Trénaunay syndrome. *J Pediatr Orthop* 1996;16:723.
7. Guidera KJ, Brinker MR, Kousseff BG, et al: Overgrowth management in Klippel-Trénaunay-Weber and Proteus syndrome. *J Pediatr Orthop* 1993;13:459.
8. Jacob AG, Driscoll DJ, Shaughnessy WJ, et al: Klippel-Trenaunay syndrome: spectrum and management. *Mayo Clin Proc* 1998;73:28.
9. Katsaros D, Grundfest-Boniatowski S: Successful management of visceral Klippel-Trénaunay-Weber syndrome with the antifibrinolytic agent tranexamic acid (Cyclocapron): a case report. *Am Surg* 1998; 64:302.
10. Klippel M, Trénaunay P: Du noeuv variqueux osteohypertrophique. *Arch Gen Med* 1900;185:641.
11. Lie JT: Pathology of angiodyplasia in Klippel-Trénaunay syndrome. *Pathol Res Pract* 1988;183:747.
12. Lindenauer SM: The Klippel-Trénaunay syndrome: varicosity, hypertrophy and hemangioma with no arteriovenous fistula. *Ann Surg* 1965;162:303.
13. McCarthy RE, Lytle JO, van Devanter S: The use of total circulatory arrest in the surgery of giant hemangioma and Klippel-Trénaunay syndromes in neonates. *Clin Orthop* 1993;289:237.
14. McGrory BJ, Amadio PC: Klippel-Trénaunay syndrome: orthopaedic considerations. *Orthop Rev* 1993;22:41.
15. McGrory BJ, Amadio PC, Dobyns JH, et al: Anomalies of the fingers and toes associated with Klippel-Trénaunay syndrome. *J Bone Joint Surg* 1991;73-A:1537.
16. Oyesiku NM, Gahm NH, Goldman RL: Cerebral arteriovenous fistula in the Klippel-Trénaunay-Weber syndrome. *Dev Med Child Neurol* 1988;30:245.
17. Samuel M, Spitz L: Klippel-Trénaunay syndrome: clinical features, complications and management in children. *Br J Surg* 1995;82:757.
18. Sooriakumaran S, Landham TL: The Klippel-Trénaunay syndrome. *J Bone Joint Surg* 1991;73-B:169.
19. Stringel G, Dastous J: Klippel-Trénaunay syndrome and other cases of lower limb hypertrophy: pediatric surgical implications. *J Pediatr Surg* 1987;22:645.
20. Taira T, Tamura Y, Kawamura H: Intracranial aneurysm in a child with Klippel-Trénaunay-Weber syndrome: case report. *Surg Neurol* 1991;36:303.
21. van der Poley HM, van der Poley MN, van der Poley-Stapert JD: Psychological aspects of the Klippel-Trénaunay syndrome. *J Psychosom Res* 1995;39:183.
22. Weber FP: Angioma formation in connection with hypertrophy of limbs and hemihypertrophy. *Br J Dermatol* 1907;19:231.
23. Weber FP: Hemangiectatic hypertrophy of limbs: congenital phlebarteriectasis and so-called congenital varicose veins. *Br J Child Dis* 1918;15:13.

Metatropic Dwarfism (Dysplasia)

First described as a separate entity by Maroteaux and colleagues in 1966, this rare skeletal dysplasia is often confused with both achondroplasia and Morquio's syndrome.^{7,9} Initially patients have short limbs and a "normal" length trunk, but the limbs then "change" into more disproportionately short extremities with prominent contracted joints, while the trunk changes to a moderate to severe kyphoscoliosis, producing a shorter and more deformed individual. Thus, the changing nature of the clinical severity suggested the name metatropic, meaning changing or variable course.

Initial radiographs often are diagnostic. The spine demonstrates severe platyspondyly and delayed ossification of the

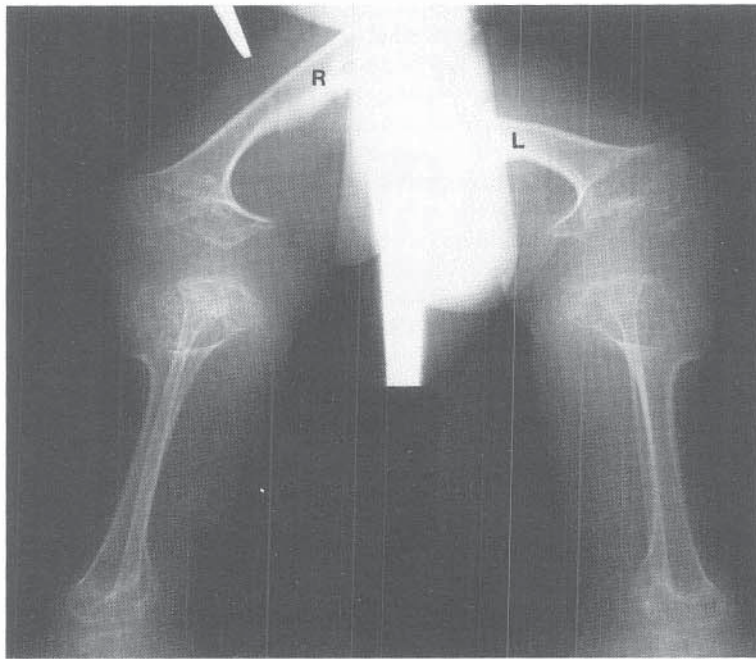
vertebral bodies, while the extremities show a "dumbbell" pattern of marked metaphyseal flaring combined with extreme shortening (Fig. 30-76). This has been explained from a pathologic specimen as a result of continued perichondrial ring functioning, producing circumferential metaphyseal growth in the face of total physal failure producing no longitudinal growth.⁴ Later on the joints demonstrate irregular articular surfaces, ossification of the epiphyses is delayed, and joint incongruity and premature arthritic changes are common. Odontoid hypoplasia with a high incidence of C1-2 instability is almost universal.¹⁰

Clinically, some infants have a tail-like appendage over the lower sacrum. The head and face are usually normal, which makes the differentiation from achondroplasia relatively straightforward, although an enlarged head and ventriculomegaly (macrocephaly greater than 97th percentile) are also common.¹⁰ The progression of the limb contractures is notable, so that patients may have difficulty achieving an upright posture, and, more important, their ambulation may then deteriorate, owing to progression of the contractures, which are incompatible with upright gait (Fig. 30-77). Asymmetric lower extremity contractures can be responsible for pelvic obliquity, which may then be additive to the severity of the kyphoscoliosis that develops in the first few years of life (Fig. 30-77).

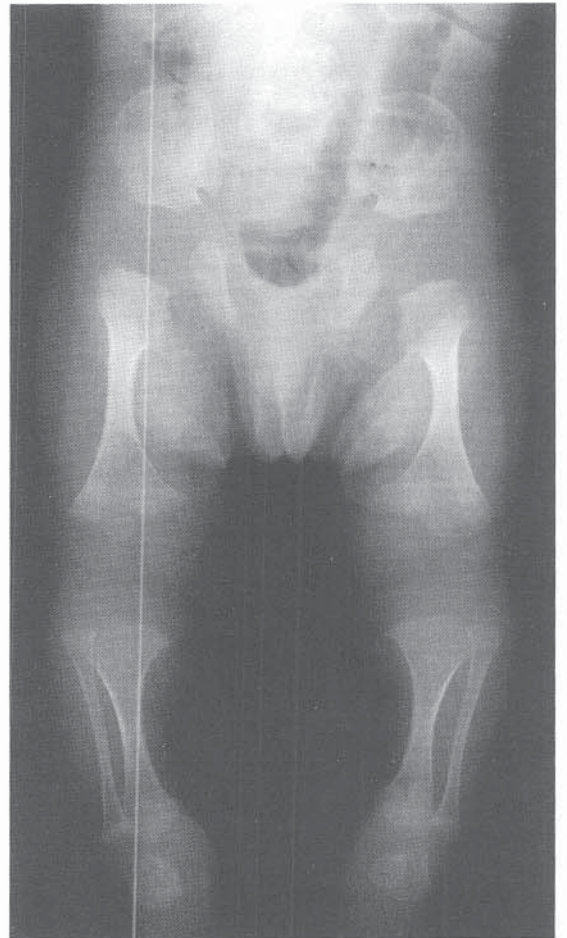
Knowledge of the clinical course of metatropic dysplasia is somewhat limited, with about 75 reported cases as of 1995.⁸ The spectrum of severity includes a lethal perinatal form and, at the opposite extreme, a mild form with minimal changes.^{2,6,9} Most patients achieve adult age, with stature less than 1.20 m.⁷ Many infants have severe respiratory difficulties that are life-threatening, with a significant component being the small, narrowed thorax (Figs. 30-77). While restrictive and obstructive changes have been detected by pulmonary function tests, the possibility of respiratory compromise due to myelopathy from C1-2 instability must never be forgotten, nor should symptomatic hydrocephalus.^{1,10} The mechanical problems with respiration may be complicated by pectus excavatum or carinatum.

In patients who survive infancy and achieve ambulatory status, orthopaedic treatment is directed toward the upper cervical spine and the kyphoscoliosis. Severe limb deformities may justify corrective osteotomies, but there is little in the literature to describe either the application of such surgery or its efficacy. Because severe, progressive contractures may eliminate the ability to walk, all other things being equal, it would seem that "some" treatment to prevent this outcome would be indicated (Fig. 30-76 and 30-77). We have no experience in lower extremity realignment in these patients, and, as already mentioned, there is little in the literature describing such intervention.

The C1-2 instability producing spinal cord compression and myelopathy is well known and, with identification of odontoid hypoplasia on the earliest radiographs, should not escape detection (Fig. 30-78). Neurologic assessment of the patients and periodic plain radiography should be performed, with MRI assessment (Fig. 30-78) added if there is any question of progressive subluxation—which is often fixed on flexion-extension films—or myelopathy. Prompt posterior C1-2 fusion, usually supported by a halo vest, is probably the treatment of choice once upper cervical instability or cord compression is confirmed. Weakness due



A



B

FIGURE 30-76 Radiographic appearance of metatropic dwarfism. **A**, Lateral radiographs of lower extremities in a 6-year-old child with metatropic dysplasia in a maximum knee extension. Note the more severe flexion deformity on the left. The flared metaphyses and dumbbell shape of the long bones are obvious. **B**, Lower extremities of a 3-month-old exhibiting early evidence of metatropic metaphyseal changes.

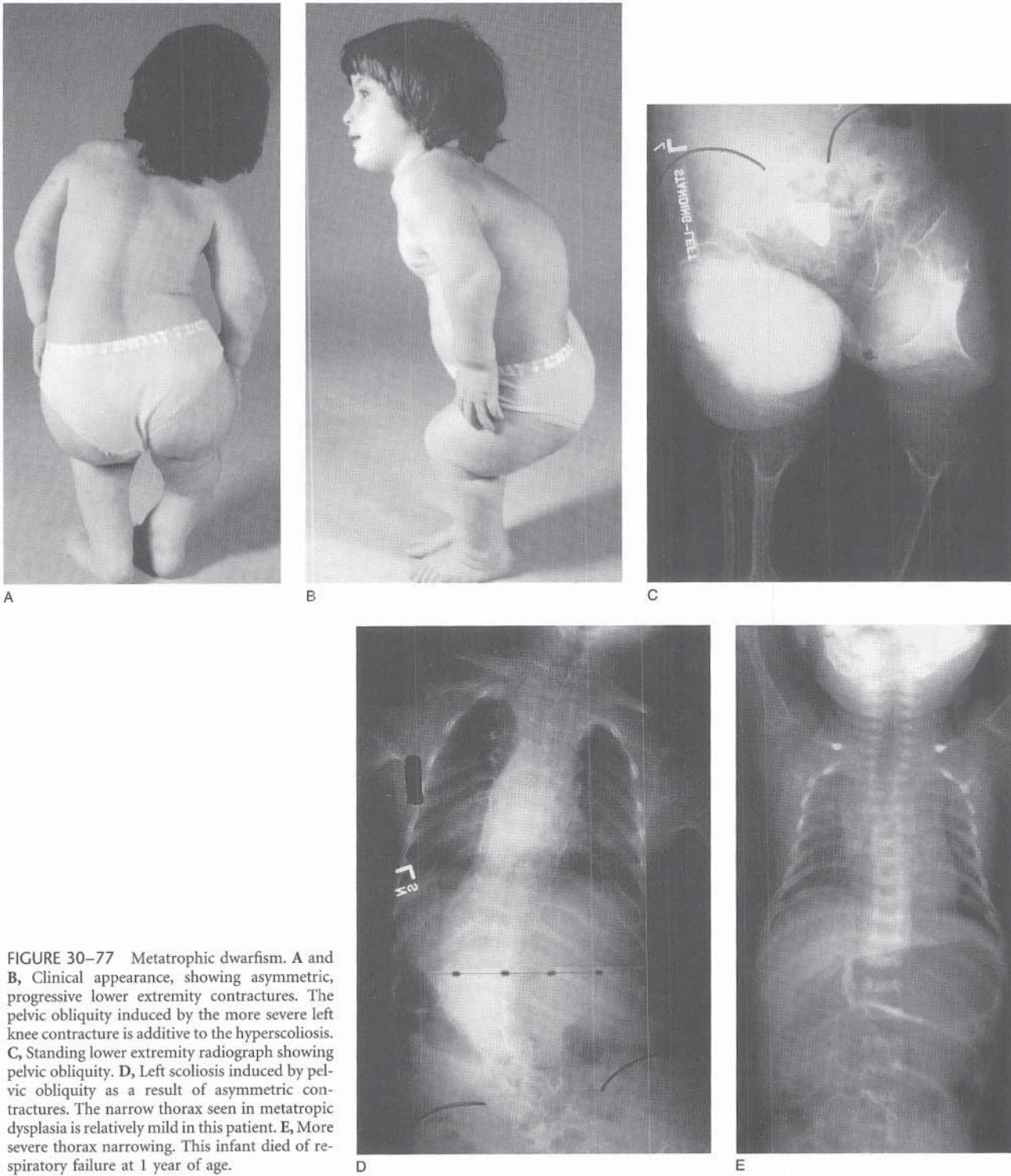
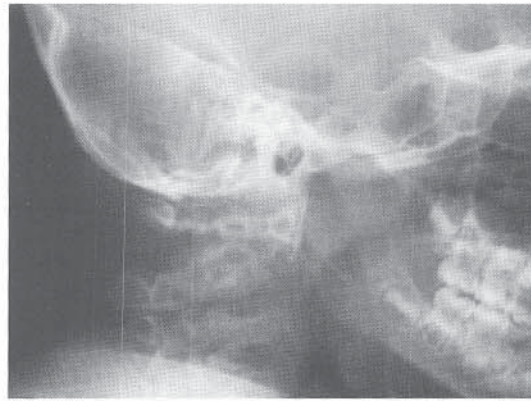
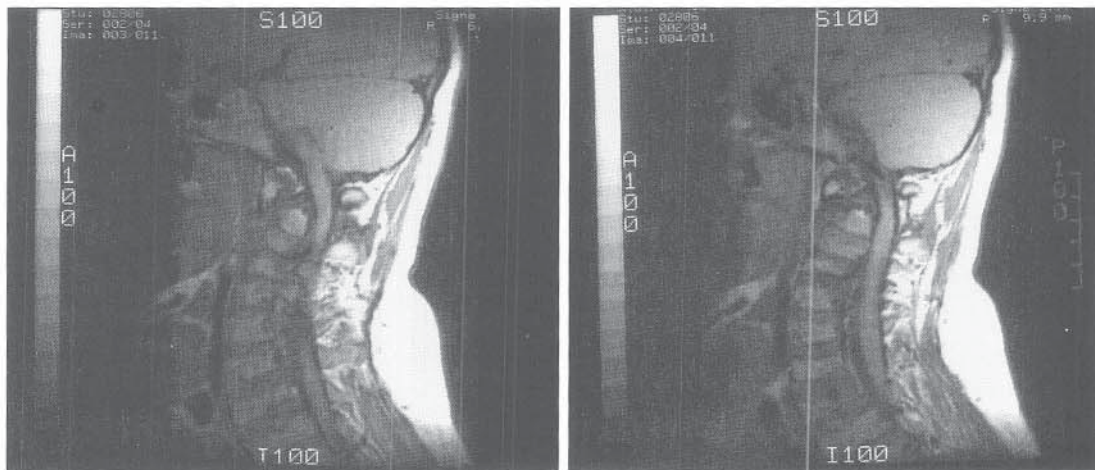


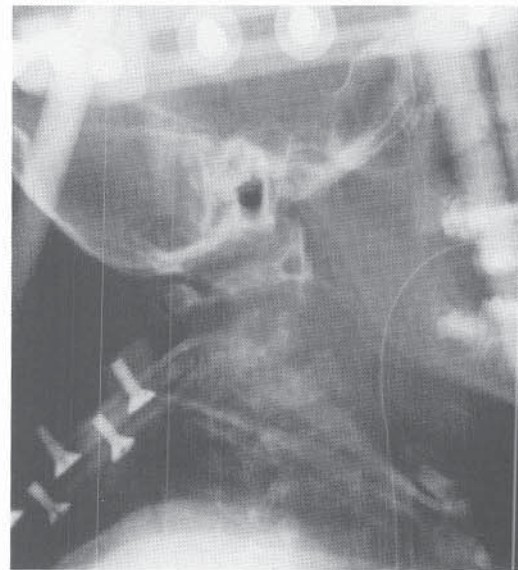
FIGURE 30-77 Metatrophic dwarfism. **A** and **B**, Clinical appearance, showing asymmetric, progressive lower extremity contractures. The pelvic obliquity induced by the more severe left knee contracture is additive to the hyperscoliosis. **C**, Standing lower extremity radiograph showing pelvic obliquity. **D**, Left scoliosis induced by pelvic obliquity as a result of asymmetric contractures. The narrow thorax seen in metatrophic dysplasia is relatively mild in this patient. **E**, More severe thorax narrowing. This infant died of respiratory failure at 1 year of age.



A



B



C

FIGURE 30–78 Imaging findings in metatropic dwarfism. A, Odontoid hypoplasia with C1–2 fixed subluxation in flexion. B, MR imaging showing stenosis at C1–2 at the posterosuperior margin of the dens. Weakness was the primary complaint, although unequivocal neurologic findings were absent. C, Reduction was achieved with the halo vest and posterior occiput–C2 fusion. The patient went on to a radiographically solid arthrodesis without significant improvement in functional strength.

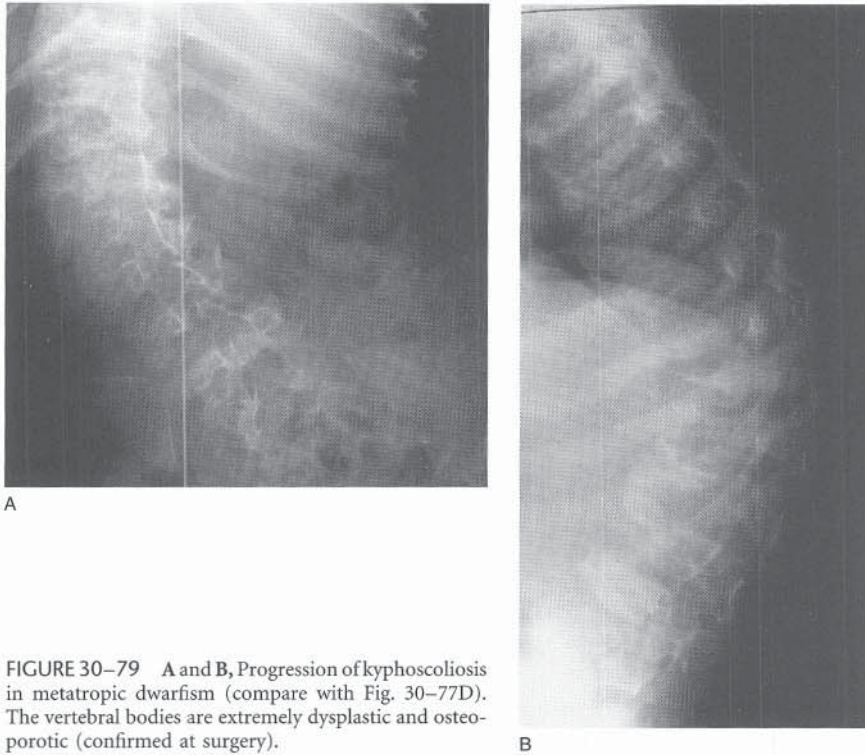


FIGURE 30-79 A and B, Progression of kyphoscoliosis in metatropic dwarfism (compare with Fig. 30-77D). The vertebral bodies are extremely dysplastic and osteoporotic (confirmed at surgery).

to myelopathy, producing respiratory compromise, should not be a source of mortality in this dysplasia.

Kyphoscoliosis may progress rapidly during the early years of life, with the deformities typically being rigid. Because of the rigidity of the spine, any pelvic obliquity due to asymmetric lower extremity deformities will exacerbate the labored posture and gait. Orthotic management has been mentioned in the literature,¹ but because of the small size of the patients and the rigidity of the deformity, it probably has little efficacy. Subcutaneous instrumentation without fusion has been reported in children as young as 2 years,⁵ with little improvement in the clinical course, owing to the well-known complications associated with that procedure (loss of fixation, infection, recurrence or worsening of the deformity). In patients presenting at a later age, osteotomy and halo traction has been reported³ with definite improvement, particularly in the kyphosis, followed by spinal fusion augmented with instrumentation. In our own experience, *in situ* fusion and cast correction has been utilized, primarily because of the diminutive spinal elements and osteopenia present (Fig. 30-79). Intervention prior to the development of neurologic compromise^{1,3} from the kyphoscoliosis, with stabilization of the deformity, would be the goal of any spinal surgery in metatropic dysplasia.

REFERENCES

Metatropic Dwarfism (Dysplasia)

1. Bassett GS: The osteochondrodysplasias. In Morrissy RT, Weinstein SL (eds): Lovell and Winter's Pediatric Orthopedics, p 214. Philadelphia, Lippincott-Raven, 1996.

2. Beck M, Roubicek M, Rogers JG, et al: Heterogeneity of metatropic dysplasia. *Eur J Pediatr* 1983;140:231.
3. Bethem D, Winter RB, Lutter L: Disorders of the spine in diastrophic dwarfism. *J Bone Joint Surg* 1980;62A:529.
4. Boden SD, Kaplan FS, Fallon MD, et al: Metatropic dwarfism: uncoupling of endochondral and perichondral growth. *J Bone Joint Surg* 1987;69A:174.
5. Johnston CE II: Scoliosis in metatropic dwarfism. *Orthopedics* 1983; 6:491.
6. Kozlowski K, Campbell J, Anderson B, et al: Metatropic dysplasia and its variants (analysis of 14 cases). *Australas Radiol* 1988;32:325.
7. Maroteaux P: Bone Diseases of Children. Philadelphia, JB Lippincott Co, 1979.
8. Nieves-Gil A, Gonzalez-Molina E, Martinez-Ayucar MM, et al: Metatropic dysplasia: a case report. *Am J Perinatol* 1995;12:129.
9. Rimoin DL, Siggers DC, Lachman RS, et al: Metatropic dwarfism, the Kniest syndrome and the pseudoachondroplastic dysplasias. *Clin Orthop Relat Res* 1976;114:140.
10. Shohat M, Lachman R, Rimoin DL: Odontoid hypoplasia with vertebral cervical subluxation and ventriculomegaly in metatropic dysplasia. *J Pediatr* 1989;114:239.

Camptomelic Dysplasia

Camptomelic dysplasia is a severe and rare form of short-limbed dwarfism that is sometimes fatal. Abnormal formation of fetal cartilage is considered to be the basic defect, and defective cartilage in the tracheal rings and lower respiratory tract may cause respiratory failure.⁶

CLINICAL FEATURES

The term *camptomelic* (sometimes *campomelic*) refers to bowing of the long bones, primarily involving the tibiae and femurs, although there are reports of bowing of the humeri,

radii, and ulnas.^{2,3} Progressive spinal deformity also is usually present (Fig. 30–80). Other clinical features include a flattened face with a high forehead, a low nasal bridge, micrognathia, cleft palate, short palpebral fissures, and malformed or low-set ears. Occasionally there are developmental defects of the heart and kidneys. Hydromyelia and diastematomyelia have also been reported.^{4,5}

The bowing of the long bones appears to be due to an abnormality in the formation of the cartilage anlage during fetal development (a dyschondrogenesis). Enchondral growth at the physes is normal, but diaphyseal cylinderization is markedly abnormal. Roth and associates have suggested that these abnormalities are due to an exogenous teratogen that transiently affects the fetus.⁶

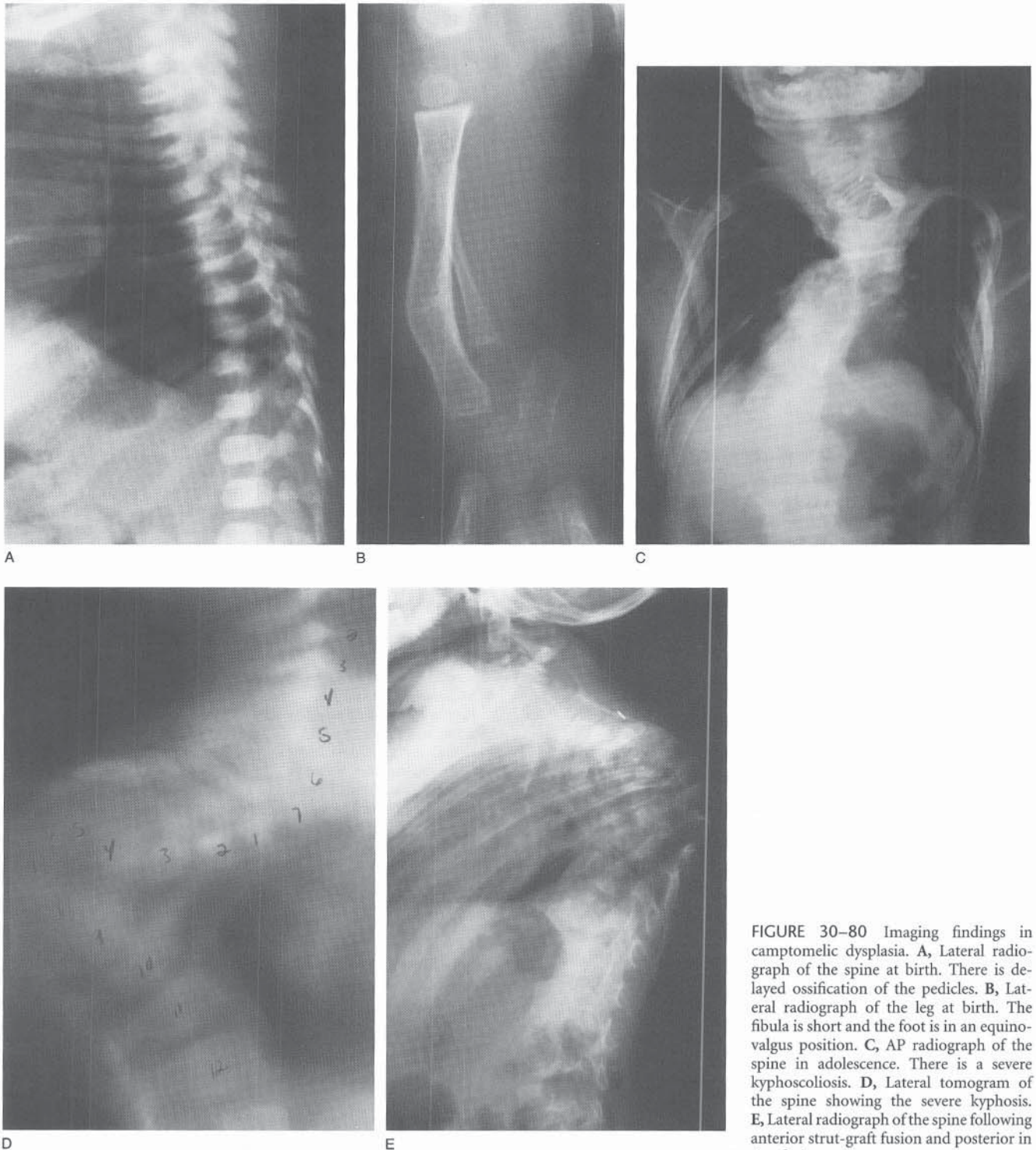


FIGURE 30–80 Imaging findings in camptomelic dysplasia. **A**, Lateral radiograph of the spine at birth. There is delayed ossification of the pedicles. **B**, Lateral radiograph of the leg at birth. The fibula is short and the foot is in an equinovalgus position. **C**, AP radiograph of the spine in adolescence. There is a severe kyphoscoliosis. **D**, Lateral tomogram of the spine showing the severe kyphosis. **E**, Lateral radiograph of the spine following anterior strut-graft fusion and posterior in situ fusion.

SPINAL DEFORMITY

Spinal deformity is present in most patients. It becomes severe in early childhood and is often markedly progressive in nature. Progression of the spinal deformity results in further pulmonary compromise and death, if untreated. In a study of eight patients with camptomelic dysplasia, Thomas and associates reported major difficulties in their management.⁷ The average initial kyphosis was 114 degrees and the scoliosis was 61 degrees. Postoperative measurements showed minimal correction. Fifty percent of the patients developed pseudarthroses and 33 percent had neurologic complications. The authors recommended non-instrumented anterior and posterior fusions with halo cast immobilization as the treatment of choice.

Coscia and associates reported significant spinal findings in eight patients with camptomelic dysplasia.¹ Late ossification of the midthoracic pedicles was a clear diagnostic criterion for the syndrome. Thoracic hyperkyphosis averaged 126 degrees and scoliosis was 63 degrees. Three patients had cervical kyphosis averaging 66 degrees, and one patient became quadriplegic after a seizure. One patient had cervical spondylolisthesis. Hypoplasia of the vertebral bodies was the major cause of deformity. The authors noted that patients with camptomelic dysplasia are surviving longer than previously expected and should have their spinal deformities appropriately treated. Treatment was difficult and was complicated by pseudarthroses and neurologic deficits.

REFERENCES

Camptomelic Dysplasia

1. Coscia MF, Bassett GS, Bowen JR, et al: Spinal abnormalities in camptomelic dysplasia. *J Pediatr Orthop* 1989;9:6.
2. Khajavi A, Lachman R, Rimoin D, et al: Heterogeneity in the camptomelic syndromes: long- and short-bone varieties. *Radiology* 1976;120:641.
3. Khajavi A, Lachman RS, Rimoin DL, et al: Heterogeneity in the camptomelic syndromes: long and short bone varieties. *Birth Defects Orig Artic Ser* 1976;12:98.
4. Krous HF, Turbeville DF, Altshuler GP: Camptomelic syndrome: possible role of intrauterine viral infection. *Teratology* 1979;19:9.
5. Mellows HJ, Pryse-Davies J, Bennett MJ, et al: The camptomelic syndrome in two female siblings. *Clin Genet* 1980;18:137.
6. Roth SI, Jimenez JF, Husted S, et al: The histopathology of camptomelia (bent limbs): a dyschondrogenesis. *Clin Orthop* 1982;167:152.
7. Thomas S, Winter RB, Lonstein JE: The treatment of progressive kyphoscoliosis in camptomelic dysplasia. *Spine* 1997;22:1330.

Chondroectodermal Dysplasia (Ellis–van Creveld Syndrome)

This extremely rare form of dysplasia was first described by Ellis and van Creveld in 1940.² It is characterized by four components: chondrodysplasia; polydactyly; ectodermal dysplasia affecting the hair, teeth, and nails; and congenital heart failure. The dysplasia is one of the short-rib polydactyly syndromes.³ As its name implies, this syndrome affects both mesodermal and ectodermal tissues. The prevalence of Ellis–van Creveld dysplasia is 0.1 per million. Particularly affected are the Pennsylvania Amish.⁷

GENETICS

Ellis–van Creveld syndrome is inherited as an autosomal recessive disorder. The *lcous* gene has been mapped to chromosome 4p16.1.^{6,9}

CLINICAL FEATURES

Chondrodysplasia in Ellis–van Creveld syndrome results in acromelic and mesomelic shortness of the limbs. The shortening is most prominent in the most distal aspects of the limbs (e.g., the phalanges). The tibia and fibula are also short, with the fibula shorter than the tibia (unlike in achondroplasia). The short stature is primarily due to the shortness of the lower legs. The trunk appears long, and the femora and humeri are less involved. Shortness is present at birth but becomes more apparent with subsequent growth (Fig. 30–81).

Polydactyly of the hands is a hallmark of this dysplasia (Fig. 30–82). The polydactyly is most often postaxial, on the ulnar side of the hand. The feet are affected less often. Syndactyly is seen in some cases.

Clinically, ectodermal dysplasia is characterized by abnormalities of the nails, hair, and teeth. The nails are small, hypoplastic, and dystrophic (Fig. 30–83). The teeth are described as “natal” and are pointed, dystrophic, or absent.^{4,5} The upper lip may be adherent to the underlying gum.

Congenital heart disease is present in approximately 50 percent of patients with Ellis–van Creveld syndrome.¹ Malformations usually seen in this population are single atrium, atrial septal defects, and ventricular septal defects.

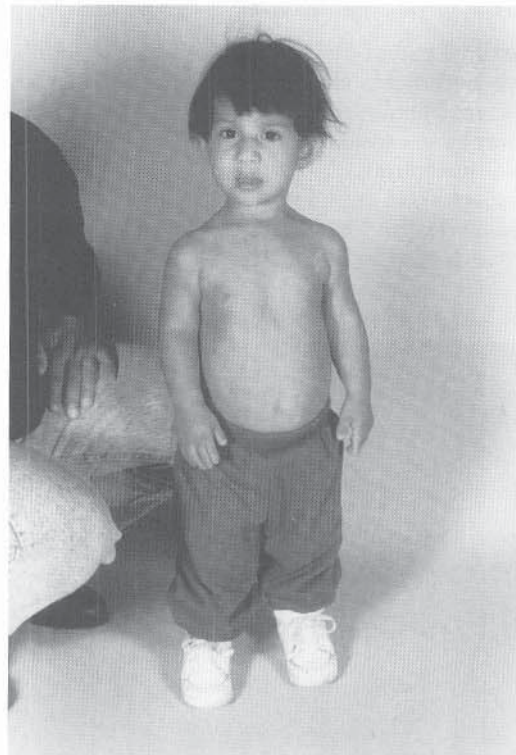


FIGURE 30–81 Two-year-old girl with Ellis–van Creveld syndrome. Note the shortening of the humeri and polydactyly of the right hand.

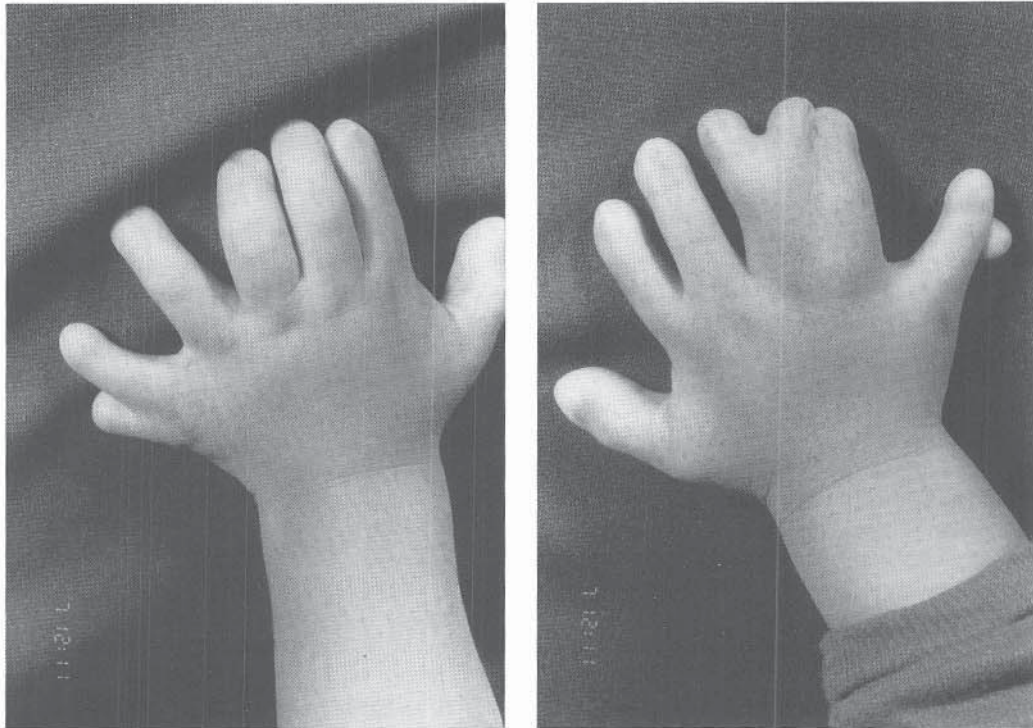


FIGURE 30-82 Polysyndactyly associated with Ellis-van Creveld syndrome. There are more extra digits on the ulnar side of the hand.

Mental retardation has been reported in some patients with Ellis-van Creveld syndrome. CNS and renal malformations have been reported in isolated cases.^{8,10,12}

RADIOGRAPHIC FINDINGS

The proximal end of the tibia is widened and pointed. The epiphysis of the tibia characteristically appears hypoplastic and deficient laterally, resulting in genu valgum (Fig. 30-84). There may be an exostosis projecting from the medial proximal tibial metaphysis.

The fingers are very short. Ossification centers of the distal phalanges may be absent. Fusion of two or more of the carpals is seen in about 71 percent of patients.¹¹ Most

often the capitate and hamate are fused (Fig. 30-85). There may be accessory carpal bones accompanying the polydactyly.¹¹ Tarsal coalitions may be present.

The femora and humeri are often bowed. The spine is normal. The ribs are short, and the thorax is long and

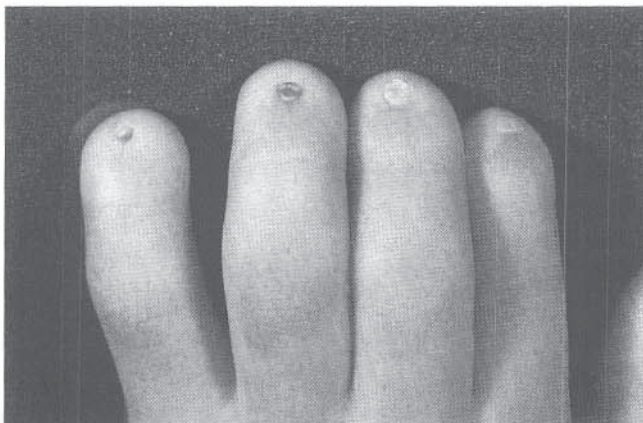


FIGURE 30-83 Hypoplastic dystrophic fingernails in a child with Ellis-van Creveld syndrome.

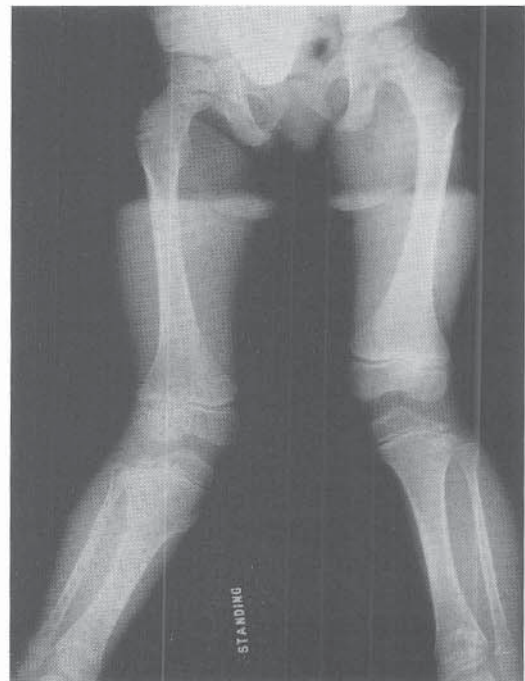

FIGURE 30-84 Genu valgum results from hypoplasia of the lateral proximal tibial epiphysis in Ellis-van Creveld syndrome.

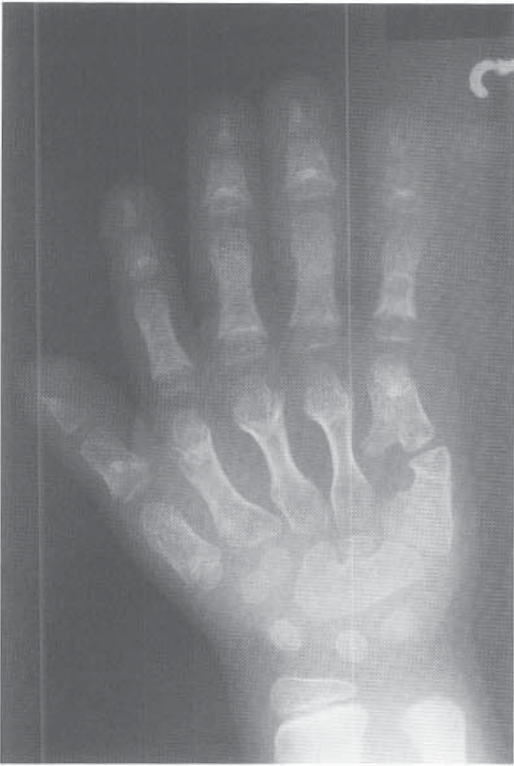

FIGURE 30-85 Carpal coalitions and distal phalangeal hypoplasia in a 4-year-old girl with Ellis-van Creveld syndrome.

narrow. The pelvis has a distinctive appearance. The iliac bones are small, with a decrease in their vertical height. An inferior hook may be present in the region of the triradiate cartilage. With further growth, the pelvic radiographs become normal.

TREATMENT

During infancy, cardiac surgery is often required to treat congenital malformations.

ORTHOPAEDIC CONSIDERATIONS

Excision of polydactyly of the hands and feet can be performed, following evaluation and treatment of heart defects.

Genu valgum develops during early childhood as a result of the abnormal proximal tibial epiphysis and growth plate. Orthotic treatment may delay surgery, but when the valgus becomes symptomatic, proximal tibial osteotomy should be performed (Fig. 30-86). Recurrence of deformity is universal, so it is wise to warn parents of this prior to the initial surgery (Fig. 30-87).

The goal of surgery is complete correction of the mechanical axis of the limb, and internal rotation through the osteotomy is required to correct the external rotation deformity. In severe cases of genu valgum due to Ellis-van Creveld syndrome, medial femoral condylar overgrowth contributes to the deformity. In such cases, distal femoral osteotomy should be performed, with the proximal tibial osteotomy done to correct the alignment of the extremity. Repeat osteotomies will be necessary with further growth. As the child nears the end of skeletal growth, combining proximal tibial

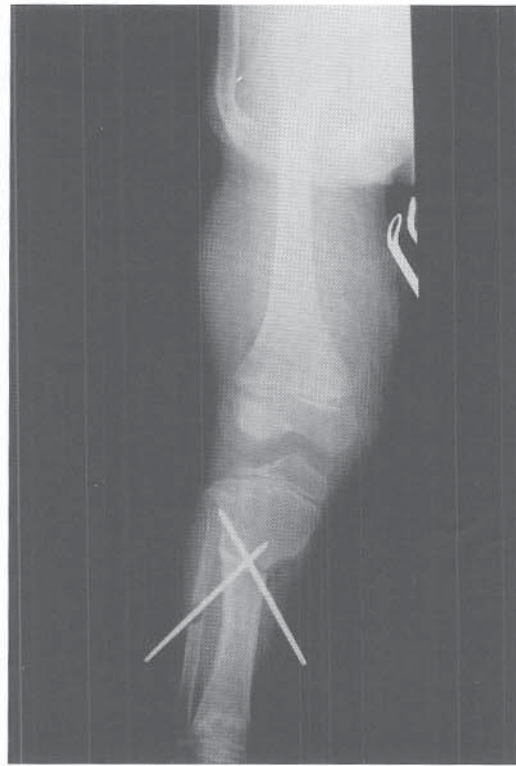

FIGURE 30-86 Proximal tibial osteotomy for treatment of genu valgum in a 4-year-old with Ellis-van Creveld syndrome (same patient as in Fig. 30-84).

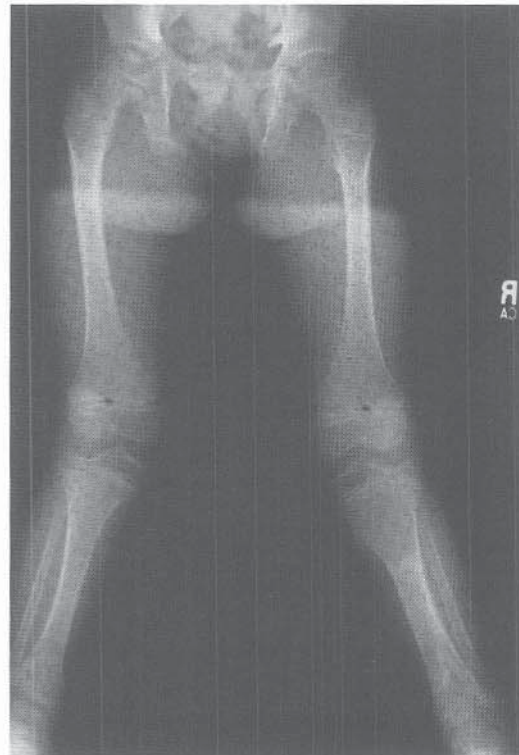

FIGURE 30-87 Recurrent valgus 1 year 7 months after osteotomy to treat Ellis-van Creveld syndrome.

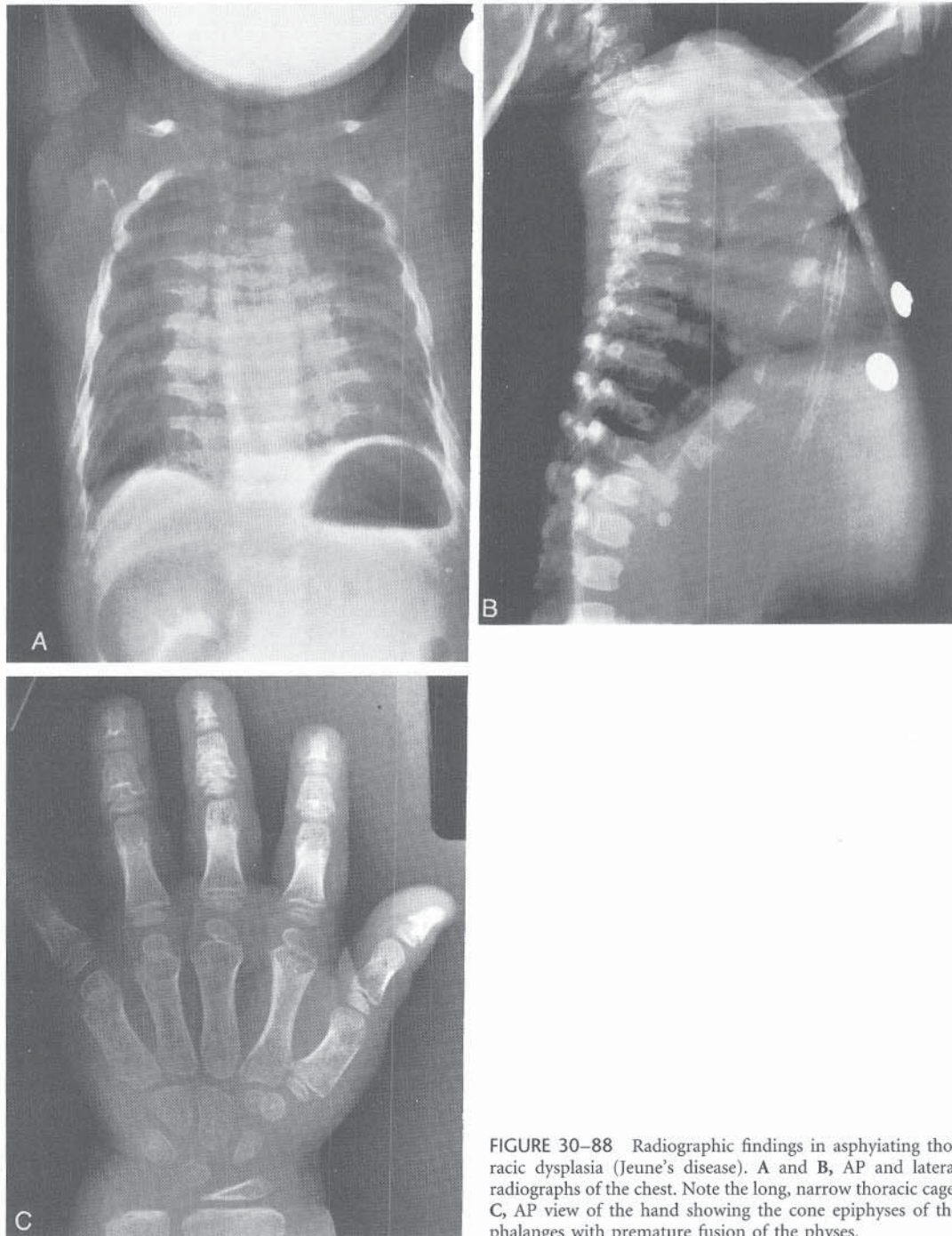


FIGURE 30-88 Radiographic findings in asphyxiating thoracic dysplasia (Jeune's disease). A and B, AP and lateral radiographs of the chest. Note the long, narrow thoracic cage. C, AP view of the hand showing the cone epiphyses of the phalanges with premature fusion of the physes.

osteotomy with closure of the proximal medial tibial physis may prevent further recurrence.

Patellar dislocation can occur due to the genu valgum. Surgical realignment of the quadriceps mechanism and of the bony anatomy is the treatment of choice.

REFERENCES

Chondroectodermal Dysplasia (Ellis-van Creveld Syndrome)

1. da Silva EO, Janovitz D, de Albuquerque SC: Ellis-van Creveld syndrome: report of 15 cases in an inbred kindred. *J Med Genet* 1980;17:349.
2. Ellis RWB, van Creveld S: Syndrome characterized by ectodermal dysplasia, polydactyly, chondro-dysplasia and congenital morbus cordis: report of three cases. *Arch Dis Child* 1940;15:65.
3. Erzen M, Stanescu R, Stanescu V, et al: Comparative histopathology of the growth cartilage in short-rib polydactyly syndromes type I and type III and in chondroectodermal dysplasia. *Ann Genet* 1988;31:144.
4. Hattab FN, Yassin OM, Sasa IS: Oral manifestations of Ellis-van Creveld syndrome: report of two siblings with unusual dental anomalies. *J Clin Pediatr Dent* 1998;22:159.
5. Himelhoch DA, Mostofi R: Oral abnormalities in the Ellis-van Creveld syndrome: case report. *Pediatr Dent* 1988;10:309.
6. Ide SE, Ortiz de Luna RI, Francomano CA, et al: Exclusion of the MSX1 homeobox gene as the gene for the Ellis-van Creveld syndrome in the Amish. *Hum Genet* 1996;98:572.
7. McKusick VA: Metaphyseal dysostosis and thin hair: a new recessively inherited syndrome. *Lancet* 1964;1:832.

8. Moudgil A, Bagga A, Kamil ES, et al: Nephronophthisis associated with Ellis-van Creveld syndrome. *Pediatr Nephrol* 1998;12:20.
9. Polymeropoulos MH, Ide SE, Wright M, et al: The gene for the Ellis-van Creveld syndrome is located on chromosome 4p16. *Genomics* 1996;35:1.
10. Rosemberg S, Carneiro PC, Zerbini MC, et al: Brief clinical report: chondroectodermal dysplasia (Ellis-van Creveld) with anomalies of CNS and urinary tract. *Am J Med Genet* 1983;15:291.
11. Taylor GA, Jordan CE, Dorst SK, et al: Polycarpaly and other abnormalities of the wrist in chondroectodermal dysplasia: the Ellis-van Creveld syndrome. *Radiology* 1984;151:393.
12. Zangwill KM, Boal DK, Ladda RL: Dandy-Walker malformation in Ellis-van Creveld syndrome. *Am J Med Genet* 1988;31:123.

Asphyxiating Thoracic Dysplasia (Jeune's Disease)

Asphyxiating thoracic dysplasia is an autosomal recessive condition first described by Jeune and associates in 1954.⁶ It is characterized by hypoplasia of the chest, with a long, narrow thorax that is decreased in both the AP and transverse diameters. Affected babies usually die during the neonatal period from respiratory insufficiency. A milder form that does not lead to death in infancy has been described.⁵

PATHOLOGY

Asphyxiating thoracic dysplasia of Jeune is differentiated histologically into two types. Type 1 is characterized by patchy distribution of endochondral ossification in the physis, an irregular physal-metaphyseal junction, and large islands of poorly mineralized cartilage in the metaphysis. Type 2 is characterized by a uniform distribution of disorganized endochondral ossification, which is accompanied by advancing cartilage forming lattice-like meshwork in the metaphysis.¹¹

CLINICAL FEATURES

The patient's limbs are short, and there may be associated postaxial polydactyly. Cone epiphyses may occur in the hands and feet, with premature fusion. The clinical features of Jeune's disease overlap with those seen in other short-rib polydactyly syndromes, such as Ellis-van Creveld syndrome (Fig. 30-88).^{4,7}

RADIOGRAPHIC FINDINGS

Radiographic findings classify the dysplasia into two forms that correlate with the histologic findings. In type I, the metaphyseal ends are irregular due to the patchy endochon-

dral ossification. In type II, the metaphyseal ends are smooth, as the endochondral ossification is more uniformly disturbed.¹²

PRENATAL DIAGNOSIS

The prenatal diagnosis of Jeune's disease by ultrasound has been reported. Findings on ultrasound include a thorax that is small for gestational age and short limbs.^{2,9}

TREATMENT

Aggressive pulmonary care has allowed some infants with Jeune's dysplasia to survive. Restrictive lung disease due to the small chest is universal. Thoracic surgery, including rib expansion to enlarge the chest, has recently been described.^{3,10} In adolescence and young adulthood, surviving patients with Jeune's disease develop renal failure because of nephronophthisis.⁸ Successful renal transplantation has been performed.¹

REFERENCES

Asphyxiating Thoracic Dysplasia (Jeune's Disease)

1. Amirou M, Bourdat-Michel G, Pinel N, et al: Successful renal transplantation in Jeune syndrome type 2. *Pediatr Nephrol* 1998;12:293.
2. Chen CP, Lin SP, Liu FF, et al: Prenatal diagnosis of asphyxiating thoracic dysplasia (Jeune syndrome). *Am J Perinatol* 1996;13:495.
3. Davis JT, Ruberg RL, Leppink DM, et al: Lateral thoracic expansion for Jeune's asphyxiating dystrophy: a new approach. *Ann Thorac Surg* 1995;60:694.
4. Franceschini P, Guala A, Vardeu MP, et al: Short rib-dysplasia group (with/without polydactyly): report of a patient suggesting the existence of a continuous spectrum. *Am J Med Genet* 1995;59:359.
5. Giorgi PL, Gabrielli O, Bonifazi V, et al: Mild form of Jeune syndrome in two sisters. *Am J Med Genet* 1990;35:280.
6. Jeune M, Carron R, Beraud C, et al: Polychondrodystrophie avec blocage thoracique d'évolution fatale. *Pediatrie (Lyon)* 1954;9:390.
7. Moudgil A, Bagga A, Kamil ES, et al: Nephronophthisis associated with Ellis-van Creveld syndrome. *Pediatr Nephrol* 1998;12:20.
8. Ring E, Zobel G, Ratschek M, et al: Retrospective diagnosis of Jeune's syndrome in two patients with chronic renal failure. *Child Nephrol Urol* 1990;10:88.
9. Skiptunas SM, Weiner S: Early prenatal diagnosis of asphyxiating thoracic dysplasia (Jeune's syndrome): value of fetal thoracic measurement. *J Ultrasound Med* 1987;6:41.
10. Weber TR, Kurkchubasche AG: Operative management of asphyxiating thoracic dystrophy after pectus repair. *J Pediatr Surg* 1998;33:262.
11. Yang SS, Heidelberg KP, Brough AJ, et al: Lethal short-limbed chondrodysplasia in early infancy. *Perspect Pediatr Pathol* 1976;3:1.
12. Yang SS, Langer LO Jr, Cacciarelli A, et al: Three conditions in neonatal asphyxiating thoracic dysplasia (Jeune) and short rib-polydactyly syndrome spectrum: a clinicopathologic study. *Am J Med Genet Suppl* 1987;3:191.