

Muscular Dystrophies, 1463	McArdle's Syndrome (Myophosphorylase Deficiency), 1491
Duchenne's Muscular Dystrophy, 1467	Idiopathic Paroxysmal Myoglobinuria, 1492
Becker's Muscular Dystrophy, 1477	Polymyositis and Dermatomyositis, 1492
Emery-Dreifuss Muscular Dystrophy, 1478	Pyomyositis (Suppurative Myositis), 1496
Limb-Girdle Muscular Dystrophy, 1479	Myositis Ossificans (Myositis Ossificans Circumscripta), 1496
Facioscapulohumeral Muscular Dystrophy, 1480	Idiopathic Fibrosis of Muscles (Progressive Fibrosis of the Quadriceps), 1499
Other Forms of Muscular Dystrophy, 1481	Myasthenia Gravis, 1500
Myotonic Dystrophy, 1487	
Thomsen's Myotonia (Myotonia Congenita), 1489	
Metabolic Diseases of Muscle, 1489	

## Muscular Dystrophies

### DEFINITION

The muscular dystrophies are a group of genetically determined, progressive diseases of skeletal muscle (Table 28-1). Muscular dystrophies are not inflammatory in etiology and so are classified as myopathies rather than as myositis. By definition, pathologic changes occur within the muscle fibers themselves, but there is no abnormality in the innervation of the muscle, and the peripheral nerves are normal.

### HISTORICAL ASPECTS

The first documentation of muscular dystrophy was by Meryon in 1852 when he described a family in which four boys developed progressive atrophy and weakness of the muscles during childhood.<sup>110</sup> In characterizing one child's clinical course, he wrote, "In May, 1847 when nearly nine years of age, he walked from Brutton Street to Westminster Bridge, but in November, 1848, he could neither walk nor stand, and in 1850, his arms were fast losing power." Even though an autopsy revealed degeneration of muscle, Meryon, unfortunately, still confused the condition with a progressive neurologic atrophy.

In 1868 Duchenne published his treatise on *le paralysie musculaire pseudo-hypertrophique ou paralysie myosclerosique* (pseudohypertrophic or myosclerotic muscular paralysis).<sup>37</sup> He characterized the entity as a muscle disease of childhood or adolescence, most commonly seen in boys, in which there was progressive weakness of the muscles, beginning in the lower limbs and spreading to the trunk and arms; enlargement (pseudohypertrophy) of the weakened muscles; and hyperplasia of interstitial connective tissue and

an increase in fat cells in the affected muscles. Duchenne also noted that the changes occurred only in muscles and that there were no pathologic changes in the nervous system.

In 1879 Gowers described his classic clinical sign of the patient "climbing up the legs" (Fig. 28-1), and later delineated another form of muscular dystrophy that primarily affected the distal musculature.<sup>54,55</sup> Limb-girdle and facioscapulohumeral dystrophies and myotonic dystrophy were all described in the later 1800s by such prominent neurologists as Landouzy, Dejerine, Erb, and Thomsen.<sup>44,45,92,160</sup>

### CLASSIFICATION

The classification of progressive muscular dystrophy that is most relevant from clinical and genetic standpoints is the system proposed by Walton (Table 28-2).<sup>169,170</sup>

### ETIOLOGY

Significant advances in molecular genetic research have helped to establish the etiology of the primary progressive muscular dystrophies.

The gene responsible for Duchenne's muscular dystrophy is located on the Xp21 region of the X chromosome and spans two million base-pairs.<sup>70,90</sup> One-third of all cases of Duchenne's muscular dystrophy occur as a result of spontaneous mutation,<sup>145</sup> which is better understood when one keeps in mind the very large size of this gene. The Xp21 region of the X chromosome encodes for dystrophin, a 400-kilodalton protein<sup>76</sup> present in skeletal, smooth, and cardiac muscles and in the brain. Dystrophin is critical to the stability of cell membrane cytoskeleton. Boys with Duchenne's muscular dystrophy have mutations that disrupt the transla-

TABLE 28-1 Clinical Features of Principal Types of Muscular Dystrophy

Clinical Features	Duchenne's	Becker's	Emery-Dreifuss	Limb-Girdle	Facioscapulo-humeral
Incidence	Most common	Less common, but not rare	Uncommon	Less common	Not common
Age at onset	Usually before 3 yr; some between 3 and 6 yr	Usually after 7 yr		Variable (usually by second decade, occasionally later)	Variable (usually in second decade)
Sex prevalence	Male	Male	Male	Either sex	Either sex
Inheritance	X-linked recessive	X-linked recessive	X-linked recessive	Autosomal recessive	Autosomal dominant
Responsible gene	Xp21 region of X chromosome	Xp21 region of X chromosome	Xq28 region of X chromosome	Located on chromosome 15 and responsible for production of calpain 3	4q35 region of chromosome 4
Pattern of muscle involvement	Proximal (pelvic and shoulder girdle muscles affected early; spreads to periphery of limbs late in course)	Proximal (similar to Duchenne type, but loss of muscle strength is slower)	Humeroperoneal distribution	Proximal (shoulder and pelvic girdle, spreads to periphery late)	Face and shoulder girdle; later spreads to pelvic girdle
Muscles spared until late	Gastrocnemius, toe flexors, posterior tibial, hamstrings, hand muscles, upper trapezius, biceps, triceps, face, jaw, pharyngeal, laryngeal, and ocular			In upper extremity, brachioradialis and hand; in lower extremity, calf muscles	Back extensors, iliopsoas, hip abductors, quadriceps
Pseudohypertrophy	80% of cases (calf muscles)	Same as Duchenne's		Less than 30% of cases	Rare
Contractural deformities	Common	Common in severe cases; less common in milder cases	Common	Develop late in course; less severe than in Duchenne type	Mild, occur late
Scoliosis and kyphoscoliosis	Common in late stage	More common in severe cases	Does occur but may self-stabilize	Mild in late stage	Mild, occur late
Cardiac involvement	Hypertrophy and tachycardia common; in late stages, widespread degeneration, fibrosis, and fatty infiltration	ECG abnormalities common; dilated cardiomyopathy in high percentage of patients; mitral regurgitation and heart failure seen in late stages	Cardiomyopathy, most commonly presenting as heart block	Very rare	Very rare
Intellectual level	Commonly decreased	Normal	Normal	Normal	Normal

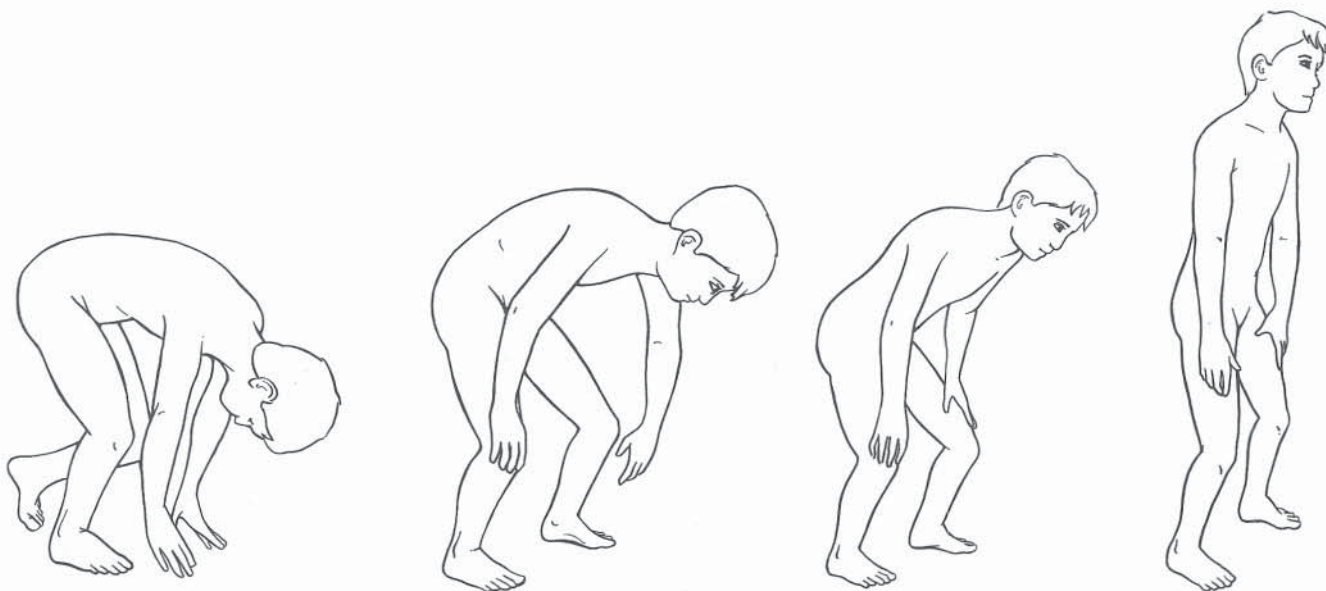


FIGURE 28-1 Gowers' sign: the patient with hip extensor weakness "walks" his hands up his legs to raise his trunk to an upright position.



**TABLE 28–2 Walton’s Classification of Progressive Muscular Dystrophy**

Pure muscular dystrophies
X-linked recessive inheritance
Duchenne’s muscular dystrophy
Becker’s muscular dystrophy
Emery-Dreifuss dystrophy
Autosomal recessive inheritance
Scapulohumeral—“limb-girdle”
Early onset in childhood—“Duchenne-like”
Congenital muscular dystrophies
Autosomal dominant inheritance
Facioscapulohumeral
Scapuloperoneal
Late-onset proximal
Distal (adult)
Distal (infantile)
Ocular
Oculopharyngeal
Dystrophies with myotonia
Myotonia congenita
Dystrophia myotonica
Paramyotonia congenita

tional reading frame or the promoter region of DNA, resulting in a lack of dystrophin.

Becker’s muscular dystrophy, which is a more benign form of muscular dystrophy, occurs in males and is transmitted in an X-linked recessive manner, similar to Duchenne’s dystrophy. The gene responsible for Becker’s muscular dystrophy is the same gene that encodes dystrophin. However, boys with Becker’s muscular dystrophy have in-frame mutations, resulting in lower molecular weight dystrophin or lower amounts of normal molecular weight dystrophin.<sup>70</sup> Genetic testing has revealed that 60 to 80 percent of children with Duchenne’s or Becker’s muscular dystrophy have demonstrable mutations or deletions of the dystrophin gene.<sup>14,136</sup>

Dystrophin is not abnormal in other forms of muscular dystrophy, though. The gene locus for Emery-Dreifuss muscular dystrophy is located on the long arm of the X chromosome at Xq28.<sup>18,34,174</sup> This gene encodes for emerin, a protein that is present in the nuclear membranes of skeletal and cardiac muscle.<sup>98</sup> Whereas dystrophin is normal in Emery-Dreifuss syndrome, emerin is absent.

The gene associated with myotonic dystrophy is located on chromosome 19. In this disease, there is an expansion of a sequence of three nucleotides—cytosine, thymine, and guanine. The number of repeats of this trinucleotide (CTG) increases as the gene is passed on through generations, and the clinical manifestations of myotonic dystrophy become more severe with increasing number of repeats. Thus, there is *anticipation* in the phenotype of the disease, with children of affected mothers exhibiting greater severity.

The locus for facioscapulohumeral dystrophy is located on chromosome 4, specifically at the 4q35 region.<sup>12,172</sup>

## **PATHOLOGY**

The pathologic changes seen within the muscles are similar in all forms of muscular dystrophy.<sup>67</sup> Each disease is a separate entity based on its genetic transmission, age of patient

at onset, clinical course, distribution of involvement, and, now, results of molecular genetic testing.

The most important histologic feature of muscular dystrophy is loss of muscle fibers, which is caused by segmental necrosis and the eventual fragmentation of the fibers (Fig. 28–2).<sup>2</sup> There is marked variation in the size of individual muscle fibers, with fibers ranging from 10 to 230 microns in size. In addition, the arrangement of large and small fibers is random. Enlarged “hypercontracted” fibers may contain abnormally increased amounts of calcium. The muscle fibers retract from their endomysial sheaths, with forking or branching of fibers (“splitting”), which some researchers hypothesize may represent an attempt at regeneration. Necrosis of the muscle fibers is accompanied by phagocytosis, with histiocytic proliferation in the areas of necrosis. The sarcolemmal nuclei are enlarged in regenerating fibers. There is an increase in interstitial connective tissue, and there is substantial infiltration of adipose tissue.<sup>69</sup>

The histopathologic findings vary with disease severity. Fiber necrosis, splitting, phagocytosis, and fatty replacement are most pronounced in Duchenne’s muscular dystrophy. In later-onset dystrophies (e.g., distal muscular dystrophy), fiber size variation, fibrosis, and central nucleation are more common. In myotonic dystrophy a unique finding of rows of central nuclei and annulets is sometimes seen. Histochemistry often reveals a predominance and smallness of type I fibers.

Analysis of dystrophin in muscle biopsy specimens has become an integral part of evaluating and diagnosing muscular dystrophy.<sup>68,69,115</sup> The content of dystrophin in muscle biopsy specimens can be determined by immunofluorescent staining, using antibodies against parts of the dystrophin molecule. Commonly, a Western blot of a homogenate of muscle tissue is examined for the presence, amount, and molecular weight of dystrophin.<sup>75</sup> An enzyme-linked immunosorbent assay (ELISA) is also used to quantify the amount of dystrophin.<sup>28</sup>

Because dystrophin is absent in the vast majority of boys with Duchenne’s muscular dystrophy, a definitive diagnosis can be made when no dystrophin is seen.<sup>123</sup> In patients with Becker’s muscular dystrophy, dystrophin is altered in size or amount, or both. The amount of dystrophin present has been correlated with clinical phenotype, specifically the age at which the patient loses independent walking.<sup>124</sup> The presence of normal dystrophin rules out the diagnoses of Duchenne’s or Becker’s muscular dystrophy while raising the possibility of limb-girdle dystrophy or one of the other less common forms of dystrophy.

Dystrophin analysis has also been used in genetic testing to help distinguish potential carriers of Duchenne’s and Becker’s muscular dystrophy. In some women who are carriers, dystrophin immunostaining has been documented as abnormal.<sup>26,71,102</sup>

## **BIOCHEMICAL CONSIDERATIONS**

The level of creatine kinase (CK) in the blood is elevated in patients with muscle disease and is not specific to muscular dystrophies.<sup>121</sup> As the muscle cell degenerates, CK is released. Serum CK levels can be elevated 20 to 200 times above normal limits.<sup>145</sup> Serum CK levels generally are higher in children with Duchenne’s muscular dystrophy than in those



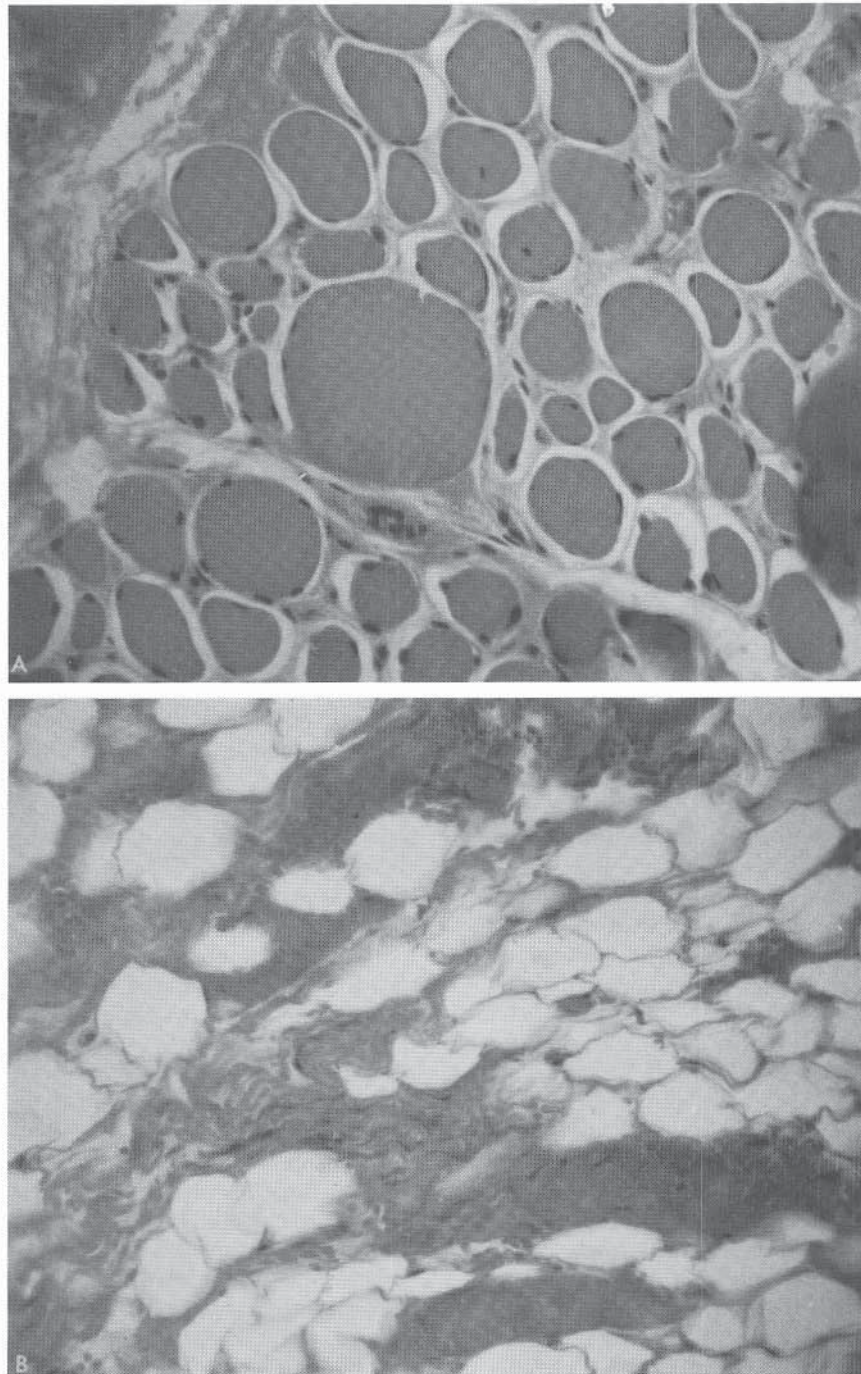


FIGURE 28-2 Histologic changes in progressive muscular dystrophy. **A**, Transverse section taken from the vastus lateralis muscle of a 7-year-old boy with early-stage disease (hematoxylin-eosin,  $\times 400$ ). Note the substantial variation in the size of individual muscle fibers and retraction of the muscle fibers from the endomysial sheaths. **B**, Longitudinal section from an enlarged gastrocnemius muscle. Note accumulation of adipose tissue and reduction in the number of muscle fibers (hematoxylin-eosin,  $\times 250$ ).

with Becker's muscular dystrophy; however, there is some overlap between the two diseases, and a distinction between Duchenne's and Becker's muscular dystrophy cannot be made simply by measuring serum CK levels. In Duchenne's muscular dystrophy the CK level is elevated in the presymptomatic phase of the disease, falls as the disease worsens, and approaches near normal levels in end-stage disease.<sup>31</sup> In some cases, female carriers of Duchenne's muscular dys-

trophy have been found to have elevated levels of CK; however, genetic counseling based simply on CK levels is ill-advised.<sup>71,103</sup>

Aldolase is another enzyme that is elevated in children with muscular dystrophy. Its course is similar to that of CK: the serum level is highest in the early phase of the disease, declines as the disease progresses, and approaches normal levels in the end stage of the disease.<sup>31</sup> Serum glutamic oxalo-



acetic transaminase (SGOT) and lactate dehydrogenase (LDH) may also be elevated, but abnormalities in these enzyme levels are nonspecific for muscle disease.

### ELECTROMYOGRAPHY/NERVE CONDUCTION VELOCITY

Electromyography (EMG) can help differentiate myopathic and neuropathic processes. The EMG recording in patients with muscular dystrophies is distinguished by a pattern of low-amplitude, short-duration, polyphasic motor unit potentials.<sup>145</sup> Nerve conduction velocities (NCVs) are normal in patients with muscular dystrophies. It should be noted that NCV increases with age as myelination occurs in young children.<sup>117,132</sup> Normal adult values (i.e., 50 m/sec) usually are seen by 6 years of age.

## Duchenne's Muscular Dystrophy

Duchenne's muscular dystrophy is the most common form of muscular dystrophy, occurring in one per 3,500 boys.<sup>41,145</sup> It is transmitted in an X-linked recessive fashion in which all affected persons are male, while females are carriers of the gene. On very rare occasions, females with Turner's syndrome exhibit the disease because of their XO genotype. Other rare chromosomal events, such as translocations, can also result in clinically affected girls.

It can be very difficult for an orthopaedist to make the diagnosis of Duchenne's muscular dystrophy when the child is seen for the first time. Differentiating Duchenne's muscular dystrophy from polymyositis is sometimes difficult, but certain features of the two diseases can help in establishing the correct diagnosis (Table 28-3). It is extremely important to establish a diagnosis of Duchenne's muscular dystrophy as soon as possible, because a delay may lead to further pregnancies in a carrier female and births of affected children in an uninformed family.<sup>135</sup>

### CLINICAL FEATURES

The disease usually manifests in children between 3 and 6 years of age. The onset of weakness is insidious. Affected boys may achieve motor milestones at slightly older ages, and there may be a mild delay in walking. Although the disease usually is not noted until after 3 years of age, Gowers' sign may be present as early as 15 months.

Presenting signs can range from a waddling gait to difficulty climbing stairs to marked muscle weakness and clumsiness. In the early stages of the disease, there may be notable toe-walking during ambulation. Duchenne's muscular dystrophy should be considered in any young boy who presents with ankle equinus and a normal birth history.

The muscle weakness develops symmetrically. Weakness is noted initially in the proximal musculature, with the hip extensors often the first muscles to be affected. Lower extremity involvement usually precedes upper extremity disease by 3 to 5 years. As the disease process progresses, contractures occur predictably in certain muscle groups while sparing others. Weakness coupled with contractures leads to deviations in gait.

TABLE 28-3 Differential Diagnosis of Duchenne's Muscular Dystrophy and Polymyositis

Features	Duchenne's Muscular Dystrophy	Polymyositis
Sex prevalence	Males	Females
Inheritance	Sex-linked recessive	None
Pattern of muscle involvement	Proximal, much more selective	Proximal, sometimes distal
Facial muscle weakness	May be present in some forms	Almost never
Weakness of neck and back extensors	Rare except very late	Common
Dysphagia	Very rare except terminally	Frequent
Muscular atrophy	Severe	Mild (with tenderness)
Pseudohypertrophy	Common	Rare
Deep tendon reflexes	Preserved until late	Preserved longer
Skin changes	Not observed	Present
Electromyography	Short, low-amplitude potentials	Short, low-amplitude potentials; fibrillations
Serum enzymes (CK and aldolase)	Elevated	Elevated
Muscle biopsy	Variable fiber size degeneration	Degeneration and inflammatory cells
Specific treatment	None	Steroids (definite clinical response if given early in high dosage)
Prognosis	Usually death within 20 yr	Spontaneous remission in 80%

Ankle equinus often is the first sign of Duchenne's muscular dystrophy. Contracture at the ankle leads to toe-walking and a tendency to hyperextend the knees. This knee hyperextension locks the posterior capsule of the knee, thereby augmenting the weak quadriceps and preventing buckling of the knee. Hip extensor weakness leads to anterior tilt of the pelvis, resulting in hyperlordosis of the lumbar spine during gait.<sup>156</sup> The body realigns itself during gait to take advantage of the stability offered by the hip and knee joints.<sup>74</sup> The hip becomes more stable as the ground reaction force comes to lie posterior to the joint, while the knee gains stability when the ground reaction force is located anterior to the joint.<sup>74,155</sup> Thus, the patient partially overcomes weakness in the quadriceps by locking the knee joint via the posterior capsule in full extension (Fig. 28-3).

Muscle weakness is also present in the gluteal muscles early in the disease, leading to development of a Trendelenburg gait.<sup>155,156</sup> The stance phase limb abductors are not strong enough to hold up the pelvis as the contralateral limb enters swing phase. As a result, the child will bring the weight of the upper body over the stance limb via trunk sway to augment abductor strength (Fig. 28-4). This results in a waddling appearance as the trunk sways back and forth over each limb during stance phase. The base of the gait also widens in an attempt to improve stability and decrease falling. Subsequent contractures of the iliotibial band cause further widening of the base of the gait.

As the disease progresses and muscle weakness becomes more pronounced, the stance phase of gait is prolonged and the swing phase shortens. The child's cadence decreases as



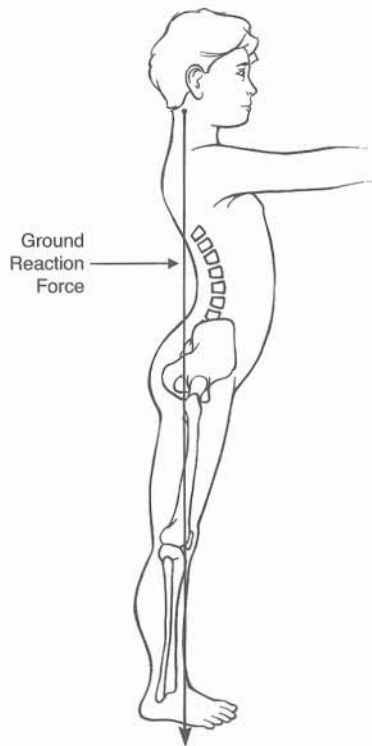


FIGURE 28-3 Typical posture of ambulatory patients with Duchenne's muscular dystrophy. To compensate for weak quadriceps and prevent buckling of the hip, the patient will lock the knee joint in full extension. Stability is increased when the ground reaction force is posterior to the hip and anterior to the knee.

it becomes more difficult to take steps.<sup>156</sup> The amount of time spent in double-limb support increases as the patient experiences more difficulty standing on a single limb.

### PHYSICAL EXAMINATION

The physical examination findings will vary, depending on the stage of the disease. Initially, the only discernible contracture is in the gastrocnoleus. The muscle belly of the gastrocnoleus is usually enlarged (termed *pseudohypertrophy*) (Fig. 28-5). Enlargement results from fibrofatty replacement of muscle fibers, which is most notable in the gastrocnoleus muscle and feels like hard rubber. The patient will be unable to fully dorsiflex the ankles.

Careful, complete muscle testing will reveal weakness in the proximal musculature of the lower extremities. Hip abductor weakness can be demonstrated by having the patient attempt to stand on one leg. Viewing the individual from behind during this maneuver, the clinician will see a drop in the hemipelvis on the side of the nonweightbearing limb (Trendelenburg's sign), which indicates weakness of the gluteal muscles (see Fig. 28-4). If the examiner is not sure whether the patient has muscular weakness, the child should be asked to sit on the floor of the examining room and then to rise quickly to a stand without assistance. Difficulty in performing such a maneuver leads the patient to use the arms to push up on the lower extremities to assist in hip extension and knee extension while standing up. A boy with Duchenne's muscular dystrophy will "walk" his hands up his legs to raise his trunk to an upright position

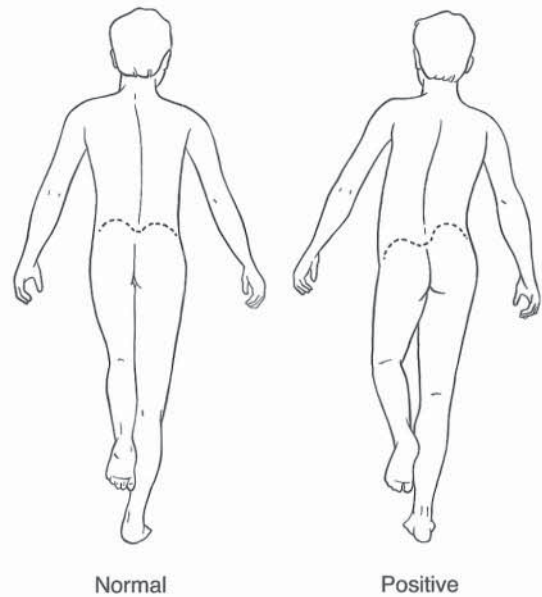


FIGURE 28-4 Trendelenburg gait. The stance phase limb abductors are not strong enough to hold up the pelvis as the contralateral limb enters swing phase. As a result, the patient will bring the weight of the upper body over the stance limb via trunk sway to augment abductor strength. Viewing the patient, the clinician will see a drop in the hemipelvis on the side of the nonweightbearing limb, which indicates weakness of the gluteal muscles.

(Gowers' sign) (see Fig. 28-1).<sup>54</sup> A second clinical sign is Meryon's sign.<sup>110</sup> When the examiner lifts the child by the chest, the child's arms abduct and slide through the embrace of the examiner's arms because of shoulder girdle weakness.

As the severity of the disease increases, contractures occur throughout the lower extremities. Abduction contractures of the hips develop because of tightness of the iliotibial

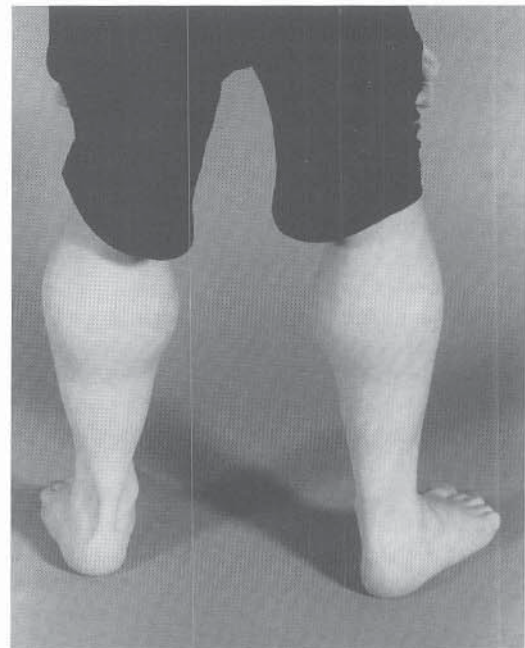


FIGURE 28-5 In patients with Duchenne's muscular dystrophy, the muscle belly of the gastrocnoleus is usually enlarged (termed *pseudohypertrophy*).



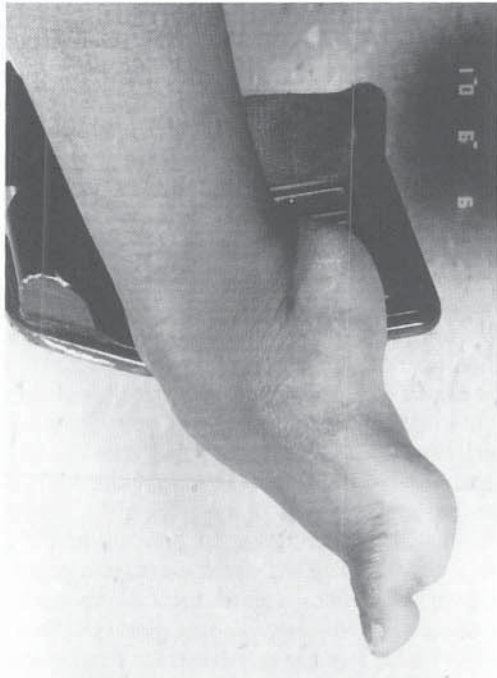


FIGURE 28–6 Equinovarus contracture of the foot in a nonambulatory patient with Duchenne's muscular dystrophy.

bands. The contractures can be demonstrated with Ober's test, which is performed with the child lying on his side. The leg is abducted, then the hip is extended and brought into adduction in the extended position. Abduction contractures in Duchenne's muscular dystrophy usually exceed 30 degrees. Ankle equinus becomes more pronounced, and varus of the hindfoot appears as the posterior tibialis muscle becomes contracted (Fig. 28–6). Knee flexion and hip flexion contractures develop as the child loses the ability to walk and starts using a wheelchair more often. When measuring hip flexion contractures, the hip must be adducted, as the abduction contracture may mask the severity of the flexion contracture.

Scoliosis appears in late childhood or early adolescence. It is quite mild at first but progresses relentlessly in a great majority of cases. The curve is frequently accompanied by an increase in lumbar kyphosis after the patient starts using a wheelchair. When the patient is in the wheelchair, the trunk will list to the side, and sitting without the assistance of the upper extremities becomes progressively more difficult.

In the upper extremities, contractures eventually develop in the elbow flexors. The patient loses the ability to abduct the shoulders. Hand function usually is not affected until late in the course of the disease. Boutonnière and swan-neck deformities develop in the fingers but rarely interfere with the patient's ability to use a motorized wheelchair.

## MEDICAL CONCERNS

As the myopathy worsens, the pulmonary and cardiac systems are affected. The first sign of pulmonary insufficiency is a reduction in expiratory muscle strength. With advancing age, there is a steady decline in pulmonary function.<sup>62</sup> Cardiac changes include right ventricular hypertrophy, sinus

tachycardia, mitral valve prolapse, and diminution of the QRS wave.<sup>11,125</sup> Death from respiratory failure usually occurs by the late teens to early twenties, although assisted ventilation may extend the lives of some children.<sup>3,65</sup>

## DIAGNOSIS

The first responsibility of the orthopaedic surgeon is to establish the diagnosis. Molecular genetic testing has eliminated the need for muscle biopsy in many patients, but there continues to be a group of patients in whom muscle biopsy is still necessary.

The vastus lateralis is most often the site for the biopsy. It is important to excise enough muscle so that dystrophin analysis can be performed in addition to light microscopy. The muscle sample must be nontraumatized. Careful surgical technique is employed so that the specimen is not stretched or crushed, and handling of the specimen is minimized. Preoperative consultation with the pathologist is essential so that the tissue is delivered promptly and is not placed in an inappropriate solution. Fresh tissue for cryostat section is essential for accurate diagnosis.

Debate exists as to whether open biopsy is preferable to needle biopsy. Special clamps to maintain the muscle length have fallen out of favor as more specific testing of the tissue has become available. In a study by Mubarak and associates, needle biopsy was found to be diagnostic in a majority of cases, required less anesthetic, and left minimal scarring.<sup>119</sup>

## TREATMENT

There is no definitive treatment at present for Duchenne's muscular dystrophy, and the disease is inevitably fatal. Orthopaedic management focuses on maximizing the child's function whenever possible. The primary goal of early treatment is to help the patient maintain functional ambulation as long as possible. When the patient becomes nonambulatory, management is directed toward treating scoliosis when it develops and addressing the problems associated with nonambulation as they occur.

**Physical Therapy.** Physical therapy is provided to prolong mobility and to stretch the muscles to prevent or minimize contractures. A stretching program at home, combined with the use of orthoses at night, can delay the progression of equinus. The patient is trained in the use of orthotics while still ambulatory.<sup>63</sup> Upper extremity weakness generally precludes the use of walkers or crutches. After surgery or fractures, aggressive mobilization of the patient in a physical therapy setting is crucial to minimize postoperative weakening of the muscles. When the child is no longer able to walk, appropriate wheelchair seating is prescribed and the patient is trained in transfers and in the use of the motorized chair.

**Lower Limb Surgery.** As muscle weakness worsens and contractures develop, walking becomes more labored and unstable, resulting in many falls. Soft tissue surgery can improve gait and prolong the time during which the child is able to walk. The timing of this surgery is controversial.<sup>166</sup> Surgery for lower limb contractures in patients with Duchenne's muscular dystrophy has been classified by Shapiro and Specht (Table 28–4).<sup>145</sup> The *early-extensive ambulatory approach* entails release at the hip, hamstrings, and heel cords



**TABLE 28–4 Shapiro and Specht’s Classification of Contracture Surgery of the Lower Limbs in Duchenne’s Muscular Dystrophy**

<b>Early-extensive ambulatory approach:</b> Release at hip, hamstrings, heel cords, and posterior tibialis transfer before onset of significant contractures.
<b>Moderate ambulatory approach:</b> Rarely includes hip abductor releases, and surgery is performed while child is still able to walk but is experiencing increasing difficulty.
<b>Minimum ambulatory approach:</b> Correction of only the equinus contractures.
<b>Rehabilitative approach:</b> Operative intervention after child ceases walking, but surgery is pursued with goal of reestablishing ambulation.
<b>Palliative approach:</b> Surgical correction of equinovarus after full-time wheelchair use has begun, with goal of pain relief and improved ability to wear shoes.

Adapted from Shapiro R, Specht L: The diagnosis and orthopaedic treatment of inherited muscular diseases of childhood. *J Bone Joint Surg* 1993;75-A:439.

and posterior tibialis transfer before the onset of significant contractures. The *moderate ambulatory approach* rarely includes hip abductor releases, and surgery is performed while the child is still able to walk but is experiencing increasing difficulty doing so. The *minimum ambulatory approach* consists of correcting only the equinus contractures. The *rehabilitative approach* is defined as operative intervention with the goal of reestablishing ambulation after the child has ceased to walk. The *palliative approach* consists of surgical correction of equinovarus after full-time wheelchair use has begun, with the goals of relieving pain and improving the ability to wear shoes.

The strongest proponents of early surgery (i.e., surgery performed between ages 4 and 6 years) are Rideau and associates, who recommend operating before contractures develop.<sup>137</sup> They propose that the quality of ambulation without braces is enhanced and the time when the child will need a wheelchair is delayed. Others report similar success with early surgery.<sup>9,47,52</sup> On the other hand, Manzur and associates conducted a randomized trial of early surgery in 10 boys with Duchenne’s muscular dystrophy and reported no beneficial effect on strength or function after following the patients for 12 to 37 months.<sup>99</sup> Smith and associates reported results in 54 patients, 28 of whom underwent lower limb surgery at a later age (average age, 10 years) and 25 of whom declined surgery.<sup>149</sup> The children who underwent surgery maintained their ability to walk an average of 2½ years longer than patients who did not undergo surgery, and were able to stand for almost a year after they lost the ability to walk.

It is difficult to compare the results of the various studies of lower extremity surgery in patients with Duchenne’s muscular dystrophy. On average, such operations prolong walking time 2 to 3½ years, but the age at which children with Duchenne’s muscular dystrophy lose ambulation varies somewhat, from 7 to 16 years (with Becker’s muscular dystrophy, loss of ambulation may occur after 16 years). It may be that children who were able to walk for the longest period of time after surgery had milder disease to start with—that is, they may have had some dystrophin present—and thus their diagnosis should have been severe Becker’s muscular dystrophy rather than Duchenne’s. Shapiro and Specht point

out that the results of future studies may be more convincing as more accurate diagnoses are achieved through dystrophin analysis.<sup>145</sup>

There is agreement that if surgery is performed after the child has lost the ability to walk, the operation must be done in a timely manner if ambulation is to be reestablished.<sup>166</sup> Once the patient becomes nonambulatory, muscle strength is quickly lost. There is a small window of time—3 to 6 months—after the child stops walking when surgery can make ambulation possible again.<sup>149</sup> Operations after this time will not help the patient regain the ability to walk. However, foot surgery in the nonambulatory patient can make shoe wear possible.

There are factors other than age that play an important role in determining the success of tendon surgery in patients with Duchenne’s muscular dystrophy.<sup>165</sup> The child’s motivation to retain walking ability and to cooperate with postoperative bracing and physical therapy cannot be overlooked. Depression, which is common in patients in the surgical age group, can interfere with postoperative care and home exercise programs. The parents’ motivation must also be taken into account. Another factor is obesity, which is common in boys with Duchenne’s muscular dystrophy<sup>39</sup> and is a poor prognostic sign for regaining the ability to ambulate after surgery.<sup>20</sup>

Equinus is managed by percutaneously lengthening the Achilles tendon.<sup>173</sup> Varus is treated by surgery on the posterior tibialis tendon. Some authors recommend tenotomy or lengthening of the posterior tibialis, but most advocate anterior transfer of the tendon through the interosseous membrane to the center of the dorsum of the foot (Plate 28–1).<sup>113</sup> This approach not only addresses varus of the hindfoot, it also augments dorsiflexion of the ankle, leading to less frequent recurrence of deformity.<sup>58,166</sup>

Knee surgery consists of lengthening or tenotomy of the hamstrings. Abduction contractures of the hips are treated by resecting the iliotibial band through a proximal Ober release, with or without a distal Yount resection, or through a fasciectomy of the iliotibial band. Hip flexion contractures can be improved by release of the sartorius, rectus femoris, and tensor fasciae latae.<sup>57</sup>

Postoperative care should allow for early weightbearing and ambulation. The child should be placed in a standing position on the first postoperative day. Because every day of bedrest adds to the child’s weakness, particular effort must be made to mobilize the child immediately. Casting should be limited to below the hips so that the child can take steps with the cast on. Short-leg casts are preferable when immobilization of the knees is not crucial. When surgery is performed on older children (10 years old or older), bracing with lightweight knee-ankle-foot orthoses (KAFOs) is necessary to prolong ambulation (Fig. 28–7).<sup>166</sup> The need for bracing should be anticipated before surgery so that the orthoses are ready immediately after surgery. Locked-knee KAFOs are needed postoperatively for ambulation. Many children have a well-founded fear of falling in their KAFOs because their upper extremity weakness prevents them from breaking the fall. For children with sufficient arm function, a walker may be of assistance.

**Spinal Surgery.** Nearly all children with Duchenne’s muscular dystrophy develop scoliosis, which becomes increas-



ingly pronounced after the child is nonambulatory. One in four children will develop scoliosis before becoming nonambulatory.<sup>22</sup> The curves are long and sweeping, and associated with pelvic obliquity. The pattern of the deformity does not resemble that seen in idiopathic scoliosis but instead is neuromuscular in appearance (Fig. 28–8). Thoracolumbar kyphosis is commonly present, but lumbar hyperlordosis may be seen in some boys. If left untreated, many curves progress beyond 90 degrees. This makes it difficult for the child to sit comfortably and leads to skin breakdown because the muscle weakness interferes with the patient's ability to relieve pressure during sitting.<sup>148</sup>

The appropriate treatment for scoliosis is surgical intervention. Bracing has been tried but is not recommended for this patient population, for several reasons. First, the goal of bracing is to prevent progression of the curvature during the time of spinal growth, yet progression occurs in these patients despite bracing.<sup>29,32,38</sup> Second, the period of time during which the risk of progression exists is prolonged because of the patient's profound muscle weakness. Third, bracing can impede full respiratory effort. Pulmonary function is already precarious in these children, with forced vital capacity (FVC) decreasing by approximately 4 percent each year and by another 4 percent for each 10 degrees of thoracic scoliosis.<sup>91</sup> Because curvature progression is the rule rather than the exception and because pulmonary function deteriorates rapidly when the patient is no longer able to walk, it is preferable to perform surgery earlier, when the child's respiratory status is functionally better. Delaying surgery because of brace treatment may make any subsequent operation unsafe, owing to the presence of pulmonary disease.<sup>138,153,154</sup>

Indications for spinal fusion for scoliosis in Duchenne's muscular dystrophy are different from indications for fusion in idiopathic scoliosis. Surgery should be performed once a curve reaches 30 degrees and the patient is nonambulatory, since curvature progression is guaranteed and pulmonary function will deteriorate over time as the curve worsens.<sup>73,148,153</sup> Mubarak and associates recommend surgery for curves greater than 20 degrees in children whose FVC is greater than 40 percent of normal.<sup>120</sup> Surgery is best tolerated before the patient's FVC is less than 35 percent of age-matched normal values.<sup>114</sup> Although surgery has been performed in children with more advanced pulmonary disease, the risks of prolonged mechanical ventilation and postoperative pneumonia increase. Preoperative planning must include a cardiac evaluation<sup>144</sup> and pulmonary function tests. If the child's projected life span is less than 2 years, surgery may be contraindicated.<sup>157</sup>

Surgery consists of posterior spinal fusion with instrumentation. Luque instrumentation with sublaminar wires provides segmental fixation at each vertebra and allows the child immediate mobilization without the need for external support.<sup>97</sup> Rigid cross-linking of the rods is essential to maintain correction. Recently, the use of the unit rod also has been recommended in posterior spinal fusions in patients with Duchenne's muscular dystrophy (Fig. 28–9). There is debate regarding the need to extend the fusion to the pelvis. Mubarak and associates reported that for mild curves without preexisting pelvic obliquity, fusion to L5 was sufficient.<sup>120</sup> In our clinical practice, most patients have curves with preexisting pelvic obliquity at the time of presentation for treat-

ment of the spine. Because one of the primary goals of the operation is to ensure a level pelvis for comfortable seating, most surgeons continue to fuse to the pelvis using the Galveston or Dunn-McCarthy technique (Fig. 28–10).<sup>4,5,21,104,111</sup> Marchesi and associates describe using sacral screws into S1 in patients with Duchenne's muscular dystrophy, rather than the Galveston rods between the tables of the ilium.<sup>100</sup> Regardless of the particular technique used, we recommend caudal fixation to control pelvic obliquity.

The effect of spinal fusion and correction of scoliosis on pulmonary function has been studied by a number of investigators. Kennedy and associates prospectively followed children with Duchenne's muscular dystrophy who did and did not have spinal fusions.<sup>84</sup> They found no difference in the rate of pulmonary deterioration or in long-term survival between the two groups of patients. Miller and associates also found no significant difference in respiratory function between those patients who had spinal fusion and those who did not,<sup>112</sup> but reported that surgery did improve sitting comfort.<sup>111</sup> Shapiro and associates agree that the primary goal of surgery is to maintain seating, and also found no beneficial effect on pulmonary function.<sup>144</sup> On the other hand, Galasko and associates reported that children whose scoliosis was stabilized maintained better pulmonary function and lived longer.<sup>50,51</sup>

The complication rate of spinal surgery for patients with Duchenne's muscular dystrophy is of concern. In a series of 30 boys who underwent spinal fusion surgery, Ramirez and associates found that major complications occurred in 27 percent of cases.<sup>134</sup> During spinal fusion, loss of blood can be substantial, and preparation for the transfusion of several units of blood should be made.<sup>171</sup> Postoperative infection is not uncommon. Instrumentation failure can occur. Medical complications, such as pneumonia, occur more frequently in this patient population. Miller and associates found pulmonary complications in 17 percent of 183 patients who underwent surgery.<sup>114</sup> Cardiac complications have been reported during anesthesia<sup>77</sup> and in the postoperative period.<sup>30</sup> Sudden death can occur on rare occasions in these children during the perioperative period.<sup>134</sup>

Studies have shown that the families of children with Duchenne's muscular dystrophy who did undergo spinal fusions felt that their children's quality of life was positively affected by their surgery.<sup>56,134</sup> Without surgery, the scoliosis interferes with comfortable sitting in a wheelchair, thereby deterring the children from getting out into the community and forcing them into their beds during the terminal phase of the disease. One substantial functional change noted by parents is that the child is no longer able to feed himself after spinal fusion surgery, as the spine can no longer collapse and enable the child to lower the head to the level of the food tray. Families should be counseled both about the serious risks of this surgery and about the consequences if the surgery is not performed.

**Anesthesia Concerns.** Malignant hyperthermia has been associated with muscular dystrophies, in particular with Duchenne's and Becker's muscular dystrophies. The use of succinylcholine and inhalation agents should be avoided during surgery.<sup>83,93</sup> Intraoperative cardiac arrest,<sup>77</sup> intraoperative anaphylaxis due to latex allergy,<sup>36</sup> and complete air-

*Text continued on page 1477*



### **Anterior Transfer of Posterior Tibial Tendon Through Interosseous Membrane**

#### **OPERATIVE TECHNIQUE**

**A,** A 4-cm-long incision is made over the medial aspect of the foot, beginning posterior and immediately distal to the tip of the medial malleolus and extending to the base of the first cuneiform bone. A second longitudinal incision is made 1.5 cm posterior to the subcutaneous medial border of the tibia, beginning at the center of the middle third of the leg and ending 3 cm from the tip of the medial malleolus.

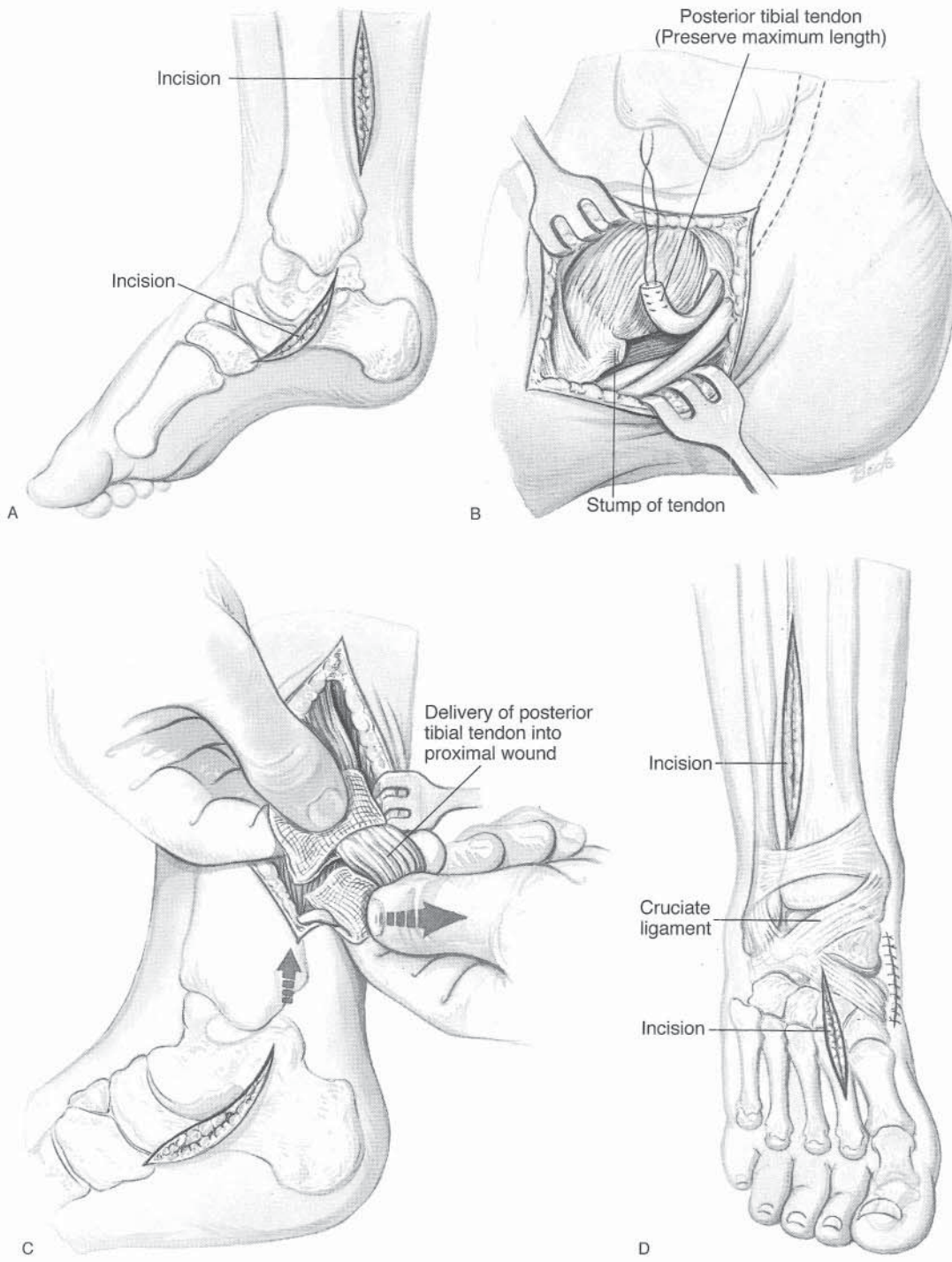
**B,** The posterior tibial tendon is identified at its insertion and its sheath is divided. The tendon is freed and sectioned at its attachment to the bone, preserving maximal length. The peritenon of the distal 3 cm of the tendon is excised, and a 0-0 silk whip suture is inserted in its distal end.

**C,** The posterior tibial muscle is identified in the leg incision and its sheath is opened and freed. Traction on the stump in the foot incision will help in its identification. Moist sponges and two-hand technique are used to deliver the posterior tibial tendon into the proximal wound. The muscle belly is freed well up the tibia. The surgeon must be careful to preserve the nerve and blood supply to the posterior tibial muscle.

**D,** Next, a longitudinal skin incision is made anteriorly one fingerbreadth lateral to the crest of the tibia, starting at the proximal margin of the cruciate ligament of the ankle and extending 7 cm proximally. Then a 4-cm-long longitudinal incision is made over the dorsum of the foot, centered over the base of the second metatarsal.



# PLATE 28-1. Anterior Transfer of Posterior Tibial Tendon Through Interosseous Membrane





### **Anterior Transfer of Posterior Tibial Tendon Through Interosseous Membrane** *Continued*

E, The anterior tibial muscle is exposed and elevated from the anterolateral surface of the tibia together with the anterior tibial artery and extensor hallucis longus muscle. It is retracted laterally, exposing the interosseous membrane. Next, a large rectangular window is cut in the interosseous membrane. The surgeon should avoid stripping the periosteum from the tibia or fibula.

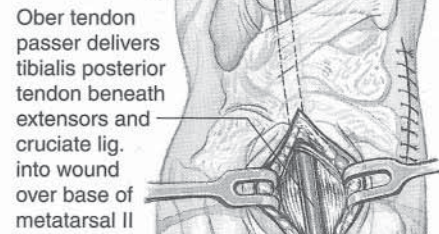
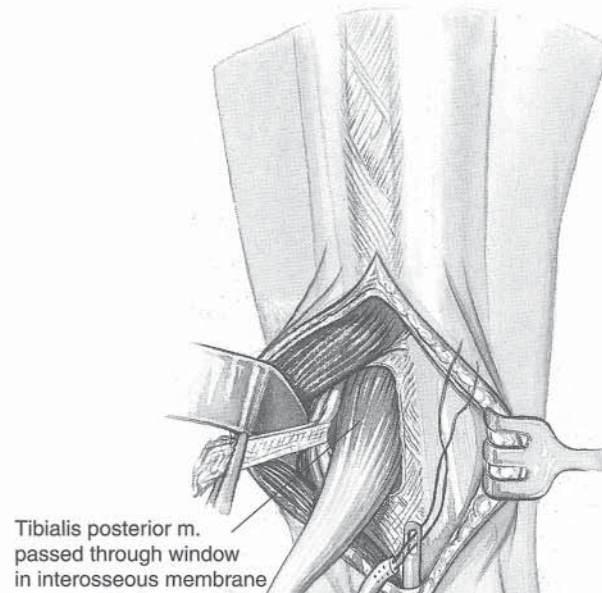
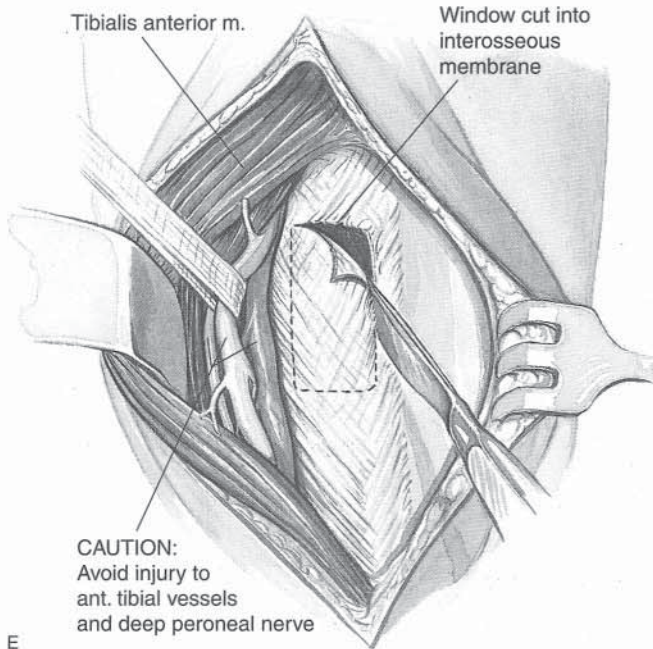
F and G, With an Ober tendon passer, the posterior tibial tendon is passed through the window in the interosseous membrane from the posterior into the anterior tibial compartment. Care is taken not to twist the tendon or damage its nerve or blood supply. Next, with the aid of an Ober tendon passer, the posterior tibial tendon is passed beneath the cruciate ligament and the extensors and delivered into the wound on the dorsum of the foot. It is anchored to the base of the second metatarsal bone through a bone tunnel. The wounds are closed in layers in the usual manner. A short-leg cast is applied that will hold the foot in neutral position at the ankle joint.

#### **POSTOPERATIVE CARE**

The principles of postoperative care are the same as for any tendon transfer.

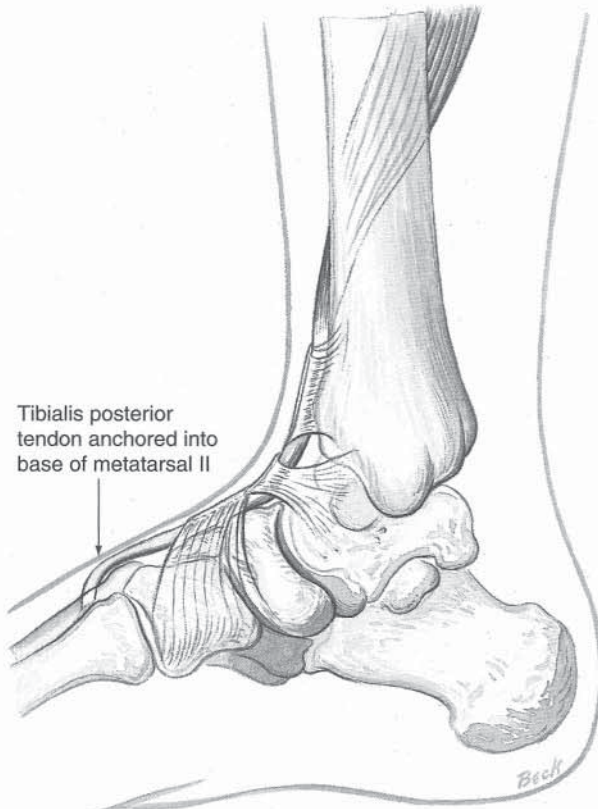


# PLATE 28-1. Anterior Transfer of Posterior Tibial Tendon Through Interosseous Membrane



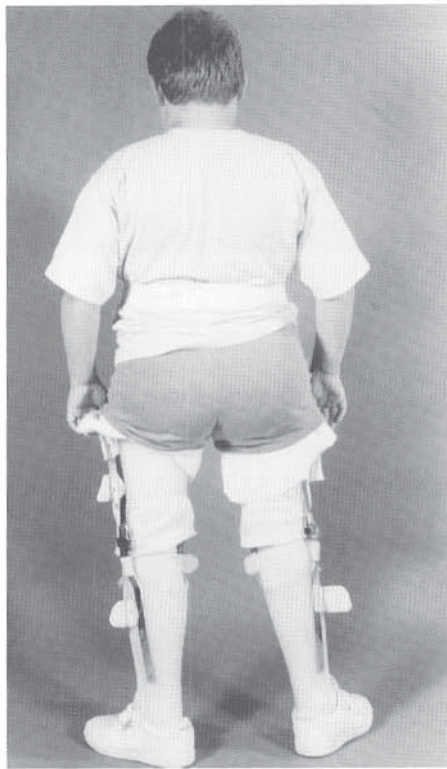V IV III II I

F

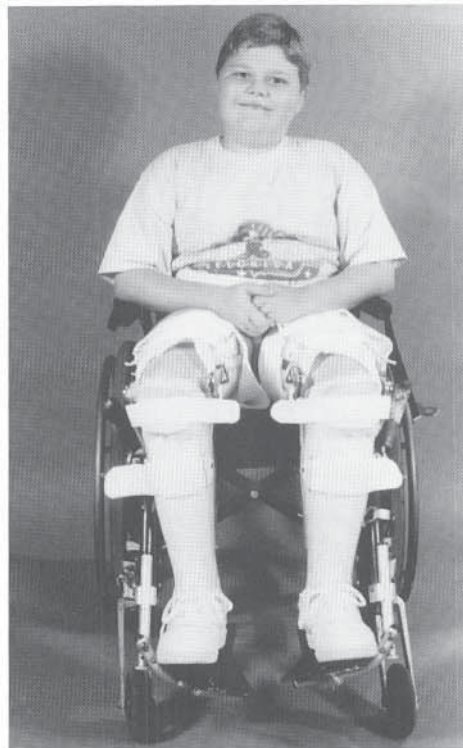

G





A



B

FIGURE 28-7 Postoperative lightweight knee-ankle-foot orthoses (KAFOs) used by a patient with Duchenne's muscular dystrophy. **A**, Braces can be used standing and walking. **B**, Wheelchair mobility for distance is accomplished by unlocking the knees.

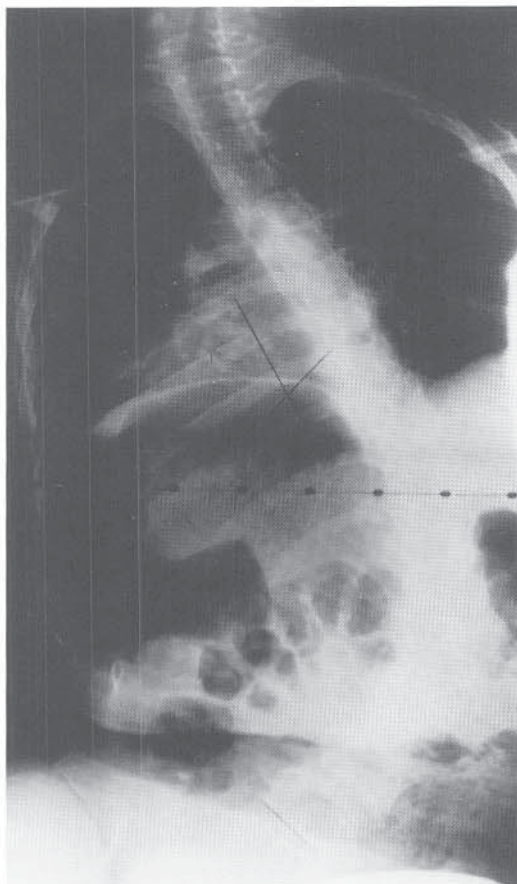


FIGURE 28-8 Long sweeping thoracolumbar curve in a patient with Duchenne's muscular dystrophy.

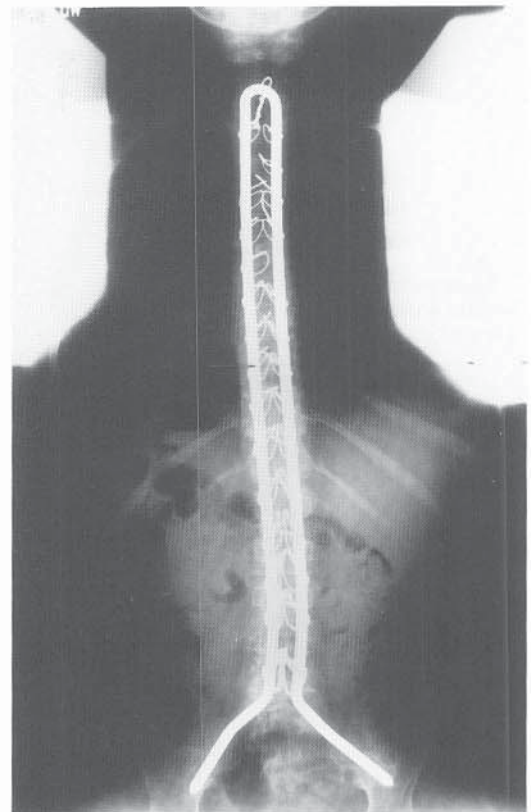


FIGURE 28-9 Posterior spinal fusion with unit rod instrumentation in Duchenne's muscular dystrophy.



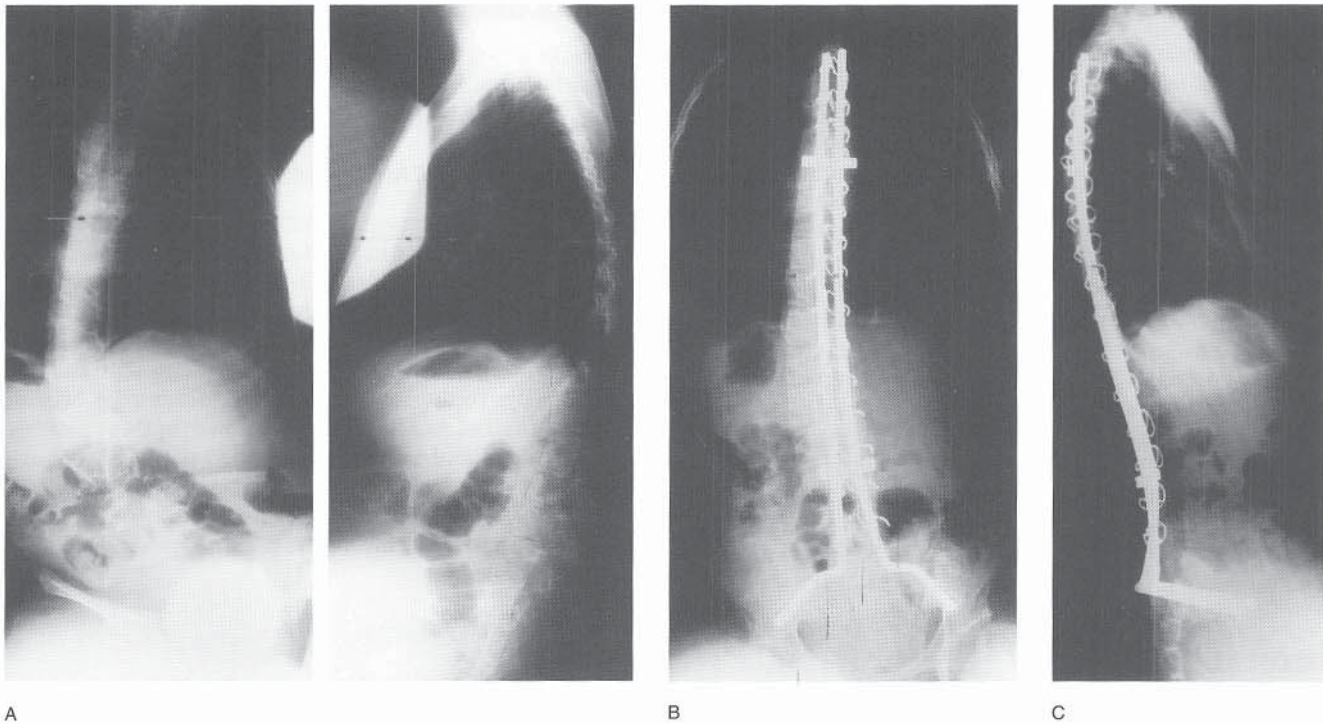


FIGURE 28-10 Preoperative (A) and postoperative (B, C) radiographs of posterior spinal fusion with Luque-Galveston instrumentation in a patient with Duchenne's muscular dystrophy.

way obstruction due to tracheobronchial compression after intubation<sup>139</sup> have also been described in children with Duchenne's muscular dystrophy. Hypotensive anesthetic techniques to minimize blood loss have been used in select Duchenne's patients with mild scoliosis.<sup>49</sup>

**Treatment of the Upper Extremities.** Children with Duchenne's muscular dystrophy commonly have elbow flexion and shoulder adduction contractures, but these conditions do not require treatment. Wrist flexion, ulnar deviation, and finger flexion contractures may develop, and these conditions are best treated with daily passive stretching exercises. When wrist dorsiflexion is limited to neutral, splinting is indicated.<sup>145</sup> Surgery generally is not required to treat conditions in the upper extremity secondary to Duchenne's muscular dystrophy.

**Steroid Therapy.** The efficacy of oral steroids in slowing the progression of Duchenne's muscular dystrophy has been tested in clinical trials. Prednisone has been shown to delay the loss of muscle strength in patients with Duchenne's muscular dystrophy for up to 3 years.<sup>46,59,60,108</sup> However, prednisone therapy is associated with significant side effects, including weight gain and osteopenia. Thus, the role of prednisone in the management of Duchenne's patients remains controversial.

**Gene Therapy.** Research is now focusing on the genetic treatment of Duchenne's muscular dystrophy.<sup>76,82,115,116,129,130</sup> Myoblast transfer to introduce healthy dystrophin via injection into the muscles of children with Duchenne's muscular dystrophy is presently unsuccessful, but the application remains under investigation.<sup>107,115</sup> Injection of dys-

trophin cDNA has been successful in the dystrophin-deficient mouse.<sup>81</sup>

## Becker's Muscular Dystrophy

Becker's muscular dystrophy<sup>13</sup> resembles Duchenne's muscular dystrophy, but the age at onset is later and the rate of muscle deterioration is slower than in Duchenne's muscular dystrophy. The age at presentation is generally after 7 years of age, and the patient may be able to continue to ambulate into the early adult years.

Becker's muscular dystrophy is inherited in an X-linked recessive pattern. The genetic etiology of the disease is a mutation at the Xp21 locus on the X chromosome, the same location as the mutation seen in Duchenne's muscular dystrophy. Genetic testing can identify the mutation in many patients.<sup>14,136</sup>

Because this locus encodes for dystrophin, the protein is abnormal in Becker's muscular dystrophy also. The site of deletion in the Xp21 locus determines the amount or size of dystrophin (i.e., in-frame deletion = Becker's, out-of-frame deletion = Duchenne's).<sup>25</sup> In-frame deletions (compared with Duchenne's muscular dystrophy) result in the production of subnormal amounts of dystrophin or in the production of dystrophin that is abnormal in size.<sup>68,70</sup> The presence of diminished amounts of dystrophin on histochemical stains of muscle biopsies is diagnostic of Becker's muscular dystrophy. The prevalence of Becker's muscular dystrophy, as established by dystrophin analysis, has been reported to be 2.38 per 100,000, a rate greater than was assumed before dystrophin analysis became available.<sup>27</sup>



## CLINICAL FEATURES

The clinical manifestations of Becker's muscular dystrophy can vary significantly, with the severity of the patient's weakness directly related to the amount of dystrophin present. In milder forms of the disease (in which dystrophin levels are 20 percent of normal or higher), patients may be able to walk in their twenties.<sup>70</sup> In the most severe form, little dystrophin is present. Before the availability of dystrophin analysis, these boys were often misdiagnosed as having Duchenne's muscular dystrophy. Other patients with severe Becker's muscular dystrophy were thought to have spinal muscular atrophy<sup>106</sup> or limb-girdle muscular dystrophy.<sup>126</sup> Bushby and associates have described two groups of patients with Becker's muscular dystrophy.<sup>24</sup> Children in the first group are younger at onset, lose the ability to ambulate in adolescence, and more frequently have cardiac involvement. In the second group onset occurs at a later age, the disease follows a milder clinical course, and patients may walk until age 40. Calf pseudohypertrophy is seen in Becker's muscular dystrophy (as it is in Duchenne's) (Fig. 28–11).

## MEDICAL CONCERNS

Cardiac involvement is frequently seen in patients with Becker's muscular dystrophy. Up to 71 percent of people with the disease have electrocardiographic (ECG) abnormalities.<sup>72</sup> A high percentage of patients develop a dilated cardiomyopathy, which can be incapacitating and life-threatening. Because patients with Becker's muscular dystrophy live longer than patients with Duchenne's, a more significant long-term workload is placed on the weakened myocardium, leading to mitral regurgitation and heart failure.<sup>141</sup>

## MUSCLE BIOPSY

In young patients, muscle biopsy shows active necrosis of muscle fibers with regeneration.<sup>159</sup> In older patients a chronic myopathic process is seen on biopsy.<sup>79</sup>

## ORTHOPAEDIC MANAGEMENT

Orthopaedic management for patients with Becker's muscular dystrophy is similar to that for patients with Duchenne's muscular dystrophy. Ankle equinus has been treated successfully by Vulpius heel-cord lengthening, with posterior tibialis transfer to the dorsum of the foot as needed.<sup>145</sup> Lower extremity bracing is often prescribed for patients with Becker's muscular dystrophy (as opposed to Duchenne's) because the rate of loss of muscle strength is slower in these patients. As the patient becomes nonambulatory, scoliosis develops. Scoliosis occurs more often in patients with severe Becker's muscular dystrophy. Spinal fusion, using the same principles as those for patients with Duchenne's muscular dystrophy, is recommended.<sup>35</sup>

## OTHER TREATMENTS

Medical treatment with prednisolone has been investigated, with improvement in muscular strength reported.<sup>10</sup> Gene therapy is also under investigation.<sup>82</sup>

## Emery-Dreifuss Muscular Dystrophy

Emery-Dreifuss muscular dystrophy is an uncommon, X-linked recessive form of muscular dystrophy that was

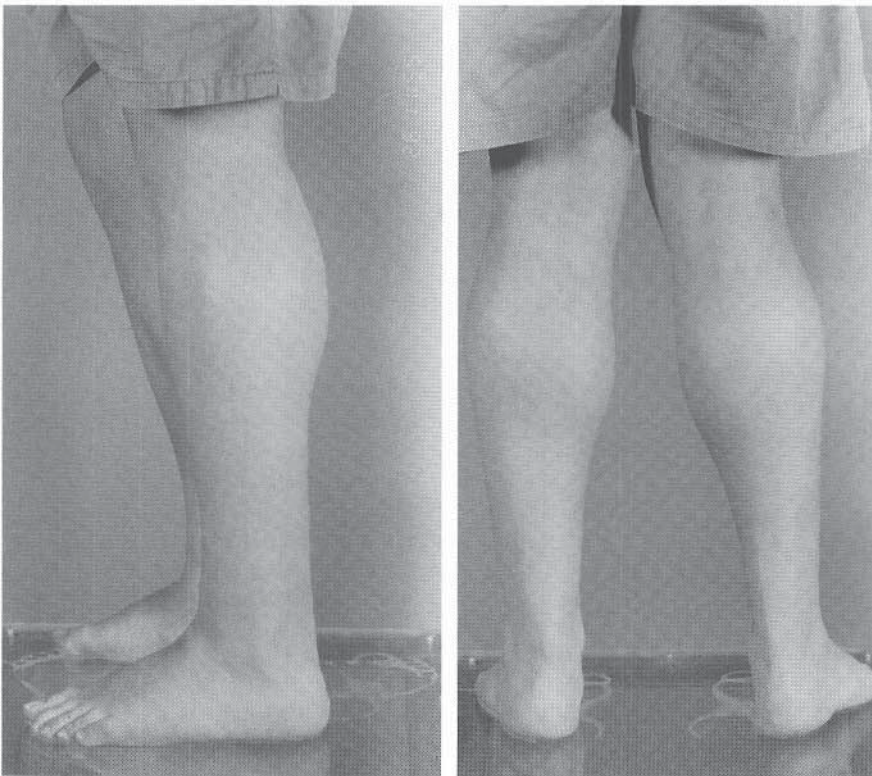


FIGURE 28–11 Pseudohypertrophy of the calf in a boy with Becker's muscular dystrophy.



first described in 1966.<sup>43</sup> One gene responsible for Emery-Dreifuss muscular dystrophy is located in the Xq28 region of the X chromosome.<sup>34,53,66</sup> The Xq28 region encodes for a nuclear membrane protein named emerin.<sup>98</sup> The exact nature of the abnormalities in this gene has been described in the literature.<sup>147,174</sup> The disease usually is inherited as an X-linked recessive trait; however, rare instances of autosomal dominant inheritance have been reported.<sup>40,140</sup>

## CLINICAL FEATURES

Emery-Dreifuss dystrophy is associated with the classic triad of slowly progressive muscle wasting and weakness, cardiomyopathy (most commonly presenting as heart block), and early contractures.<sup>40,42</sup> Muscle weakness manifests in a humeroperoneal distribution. Presenting symptoms are mild weakness, clumsiness, and toe-walking. Gowers' sign may be present. Patients usually retain the ability to walk as they become older.

## SERUM ENZYMES

Serum CK levels are elevated in affected males with Emery-Dreifuss dystrophy, but the levels are not as high as those seen in patients with Duchenne's or Becker's muscular dystrophy. Female carriers of the disease usually do not have elevated CK levels.<sup>16</sup>

## MEDICAL CONCERNS

The most serious medical condition associated with Emery-Dreifuss muscular dystrophy is cardiomyopathy. Patients are susceptible to conduction defects, and sudden death due to complete heart block has been reported in patients in their twenties. In a series reported by Merlini and associates, 30 of 73 patients died suddenly, with most of the patients not exhibiting cardiac symptoms prior to fatal heart block.<sup>109</sup> Insertion of a pacemaker in patients diagnosed with Emery-Dreifuss dystrophy has been recommended.<sup>17,40,127,133,161,176</sup>

## MUSCLE BIOPSY

Muscle biopsies from patients with Emery-Dreifuss muscular dystrophy show a normal level of dystrophin but an absence of emerin.<sup>122</sup> Microscopically, the muscles appear myopathic. Biopsies of cardiac muscle show structural changes within the myocardium.<sup>168</sup> Skin biopsy to determine the presence or absence of emerin has been proposed as a diagnostic test.<sup>118</sup>

## ORTHOPAEDIC MANAGEMENT

Orthopaedic deformities associated with Emery-Dreifuss muscular dystrophy result from joint contractures, which are a hallmark of the disease. Achilles tendon contractures may be present at diagnosis, and if so, patients may benefit from heel-cord lengthening.<sup>146</sup> Characteristic elbow flexion contractures occur, but rarely exceed 90 degrees. Further flexion, pronation, and supination are preserved. Physical therapy may help the patient, but surgery is rarely indicated. Cervical extension contractures limit flexion of the neck. Although flexion is lost, the contracture usually does not

progress beyond the neutral position of the neck. Over time, lateral rotation may also become limited (rigid spine syndrome).<sup>146</sup>

Scoliosis does occur in patients with Emery-Dreifuss syndrome but, unlike the curves in Duchenne's and Becker's muscular dystrophies, the curvature may stabilize. Thus, curvatures in these patients do not always require spinal fusion. The progression of the curve should be closely monitored. The effect of contractures of the spine stabilizing curves up to 40 degrees has been described.<sup>146</sup>

## ANESTHESIA CONCERNS

Anesthesia in persons with Emery-Dreifuss muscular dystrophy carries an increased risk to the patient. Intubation can be difficult because of cervical contractures, and cardiac arrhythmias may occur.<sup>78</sup>

## Limb-Girdle Muscular Dystrophy

Limb-girdle muscular dystrophy, described by Walton and Nattrass in 1954,<sup>170</sup> is characterized by weakness in the proximal muscles of the limbs.<sup>105</sup> The disease is primarily inherited as an autosomal recessive trait, although an autosomal dominant form has also been described.<sup>101</sup> Genetic analysis has identified two abnormalities: one in a group of membrane proteins termed sarcoglycans, and the other in calpain 3.<sup>80</sup> The gene responsible for the production of calpain 3 is located on chromosome 15.<sup>48</sup>

Onset usually occurs in the second or third decade, at an average patient age of 17.2 years.<sup>175</sup> The disease normally is more benign than Duchenne's muscular dystrophy, although the clinical course is variable. The age at onset and the clinical symptoms mimic Becker's muscular dystrophy, and limb-girdle muscular dystrophy was often confused with Becker's prior to the availability of molecular genetic testing.<sup>8</sup> The disease has also been mistaken for the Kugelberg-Welander form of spinal muscular atrophy.<sup>128</sup>

## CLINICAL FEATURES

There are two major patterns of weakness in limb-girdle muscular dystrophy. In the pelvic-femoral type described by Leyden,<sup>95</sup> muscle weakness primarily involves the pelvic girdle musculature. In particular the iliopsoas, gluteus maximus, and quadriceps are affected. Shoulder weakness becomes apparent soon thereafter. The tibialis anterior is affected before the gastrocnemius.<sup>15</sup> Contractures of the Achilles tendon and elbows are mild and occur many years into the disease.<sup>164</sup> Weakness in hip abduction and extension leads to increased lumbar lordosis. In the less common scapulo-humeral type, the shoulder girdle is affected more, with pelvic weakness occurring several years later. Presenting symptoms include difficulty lifting the arms above the head, rising from the floor, or climbing stairs. Patients usually retain the ability to walk into adulthood.

## LABORATORY FINDINGS

Serum CK levels may be normal or elevated. Muscle biopsy and EMG reveal myopathy. Nerve conduction velocity is



normal.<sup>150</sup> The diagnosis is made by dystrophin analysis of muscle tissue,<sup>8</sup> which is normal in limb-girdle muscular dystrophy but abnormal in Duchenne and Becker forms.

### MEDICAL CONCERNS

Cardiac involvement is rare in patients with limb-girdle muscular dystrophy. Recently, ECG and echocardiographic abnormalities have been discovered in 50 percent and 25 percent of patients, respectively.<sup>150</sup> The clinical significance of these findings, however, remains in question. Pulmonary involvement also occurs but is much milder than in Duchenne's or Becker's muscular dystrophy. The severity of pulmonary disease does not correlate with the degree of muscle weakness present in the limbs.<sup>152</sup>

### TREATMENT

Treatment for limb-girdle muscular dystrophy is similar to that for Becker's muscular dystrophy. Scoliosis rarely requires orthopaedic intervention as the onset of the disease is later than that of Duchenne's muscular dystrophy.

## Facioscapulohumeral Muscular Dystrophy

Facioscapulohumeral (FSH) muscular dystrophy is inherited as an autosomal dominant trait and usually causes symptoms in the second decade of life. The incidence of FSH dystrophy is one per 20,000 live births.<sup>6</sup> The gene for the disease has been localized to chromosome 4q35.<sup>142</sup> The gene product

has not yet been identified.<sup>16</sup> Penetrance of the gene is variable, the clinical severity of the disease may vary among family members, and there may be anticipation.

### CLINICAL FEATURES

The clinical course of FSH muscular dystrophy is characterized by slow progression. Initial findings are a lack of facial wrinkles (noticeable around the eyes and on the forehead), a transverse smile, and inability to fully and forcefully close the eyelids. A characteristic pattern of weakness involving the facial muscles and scapular stabilizers ensues.

The most significant weakness is seen in the trapezius, rhomboids, and levator scapulae. The glenohumeral abductors (i.e., the deltoid, supraspinatus, infraspinatus, and subscapularis) remain strong. Physical examination reveals winging of the scapulae, in addition to loss of forward flexion and abduction of the shoulder, as a result of loss of stabilization of the scapula on the chest wall (Fig. 28-12). As the patient abducts the glenohumeral joint, the unstable scapula rotates inward, thereby adducting. This lessens the effect of glenohumeral abduction. Patients complain of a loss of range of motion, stretching along the medial border of the scapula, and fatigue.

Lower extremity involvement is uncommon. Because the muscles of the lower limbs are usually spared, most patients remain able to walk. Some patients develop weakness in the anterior tibialis, and these individuals benefit from bracing. The hip girdle is affected late, and some patients may need a wheelchair in their thirties or forties. Spinal deformity has been documented in up to 35 percent of patients, with the primary deformity being hyperlordosis.<sup>145</sup> Scoliosis may

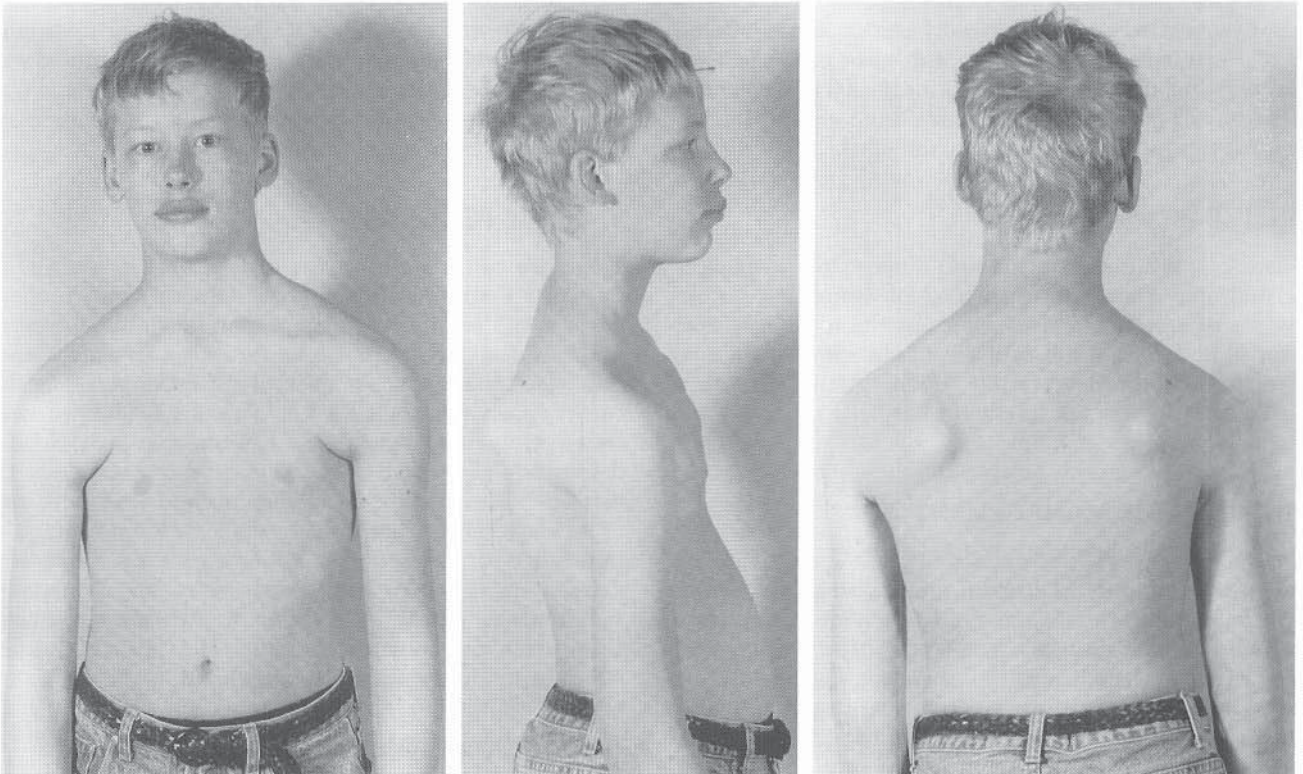


FIGURE 28-12 Clinical appearance of patient with facioscapulohumeral muscular dystrophy. Note the winging of the scapulae.



occur but rarely requires treatment. Life expectancy usually is normal.

### LABORATORY FINDINGS

Serum CK levels usually are normal in patients with FSH muscular dystrophy. Genetic testing reveals demonstrable mutations in only 10 percent of affected persons.<sup>145</sup> Further DNA tests are being developed that will provide more definitive findings.<sup>163</sup> The diagnosis of FSH dystrophy is usually made based on clinical findings. The supraspinatus muscle is recommended for obtaining a biopsy specimen to confirm the diagnosis, as biopsies of other sites often result in nondiagnostic findings.<sup>19</sup>

### MEDICAL CONCERNS

Medical complications from FSH muscular dystrophy are rare. Restrictive pulmonary disease has been documented, but in a 10-year follow-up of 53 such patients, Kilmer and associates reported that only 22 percent experienced pulmonary complications.<sup>86</sup> Cardiac disease is distinctly rare, in contrast to its occurrence in the other forms of muscular dystrophy.<sup>86</sup>

### MEDICAL TREATMENT

The use of prednisone to slow the progression of FSH muscular dystrophy has not proved effective.<sup>158</sup> However, recent trials indicate that albuterol (a  $\beta_2$ -receptor agonist) may be helpful in the treatment of the disease.

### ORTHOPAEDIC MANAGEMENT

Orthopaedic management of patients with FSH dystrophy has focused on restoring shoulder range of motion and on augmenting strength via scapulothoracic stabilization. Ketenjian first described scapulocostal stabilization for scapular winging in 1978 (Plate 28–2).<sup>85</sup> He advocated fixing the scapula to the ribs using double Mersilene tapes, which he preferred to fascia lata. The tapes are passed through drill holes along the medial border of the scapula and around three or four ribs. The position in which the scapula should be stabilized can be determined clinically by manually holding the scapula while the patient abducts the shoulder. In performing this maneuver, the preferred position of the scapula is determined to be 15 to 20 degrees of external rotation. Less rotation does not maximize abduction, and greater abduction limits shoulder adduction. The scapula is not pulled distally, as this may endanger the brachial plexus.

Bunch and Siegel have described their experience with scapulothoracic arthrodesis.<sup>23</sup> They reported that abduction in 30 degrees of flexion increased by an average of 65 degrees. Others have reported an increase in abduction of 28 degrees and in flexion of 40 degrees.<sup>162</sup> The advantage of arthrodesis compared with scapulopexy is the long-lasting stability obtained through bony union.<sup>94</sup> Fixation of the scapula to the ribs is achieved with wires passed through drill holes in the scapula and around the ribs,<sup>23</sup> by plate and wire techniques,<sup>94</sup> or by screw fixation.<sup>88</sup>

The disadvantage of scapulothoracic fusion is subsequent limitation of rib motion, leading to some loss of pulmonary

function. Bunch and Siegel found that vital capacity was reduced by approximately 10 percent in one patient but stated that a reduction in pulmonary function was not clinically significant and should be thought of only as a theoretical disadvantage to arthrodesis.<sup>23</sup> Complications of scapulothoracic arthrodesis include brachial plexus palsy and pseudarthrosis. Perioperative pulmonary complications (e.g., pleural effusions, atelectasis, pneumothorax) have also been described.<sup>94</sup>

## Other Forms of Muscular Dystrophy

### INFANTILE FACIOSCAPULOHUMERAL MUSCULAR DYSTROPHY

An early-onset form of FSH muscular dystrophy that has a distinctly different clinical course than the more common, later-onset form has been reported.<sup>89,145</sup> Facial weakness (also described as facial diplegia) is seen in infancy, with sensorineural hearing loss occurring at an average of 5 years of age. Weakness is rapidly progressive, and the lower extremities are affected as well. The hallmark of this disease is a rapidly progressive lumbar hyperlordosis.

Treatment of the hyperlordosis with spinal orthoses has not been successful and interferes with walking. Spinal fusion after the child loses the ability to ambulate is recommended. Scapulothoracic fusion is not advised, as the advanced weakness associated with this variant of FSH muscular dystrophy precludes improvement in function after the procedure.

### SCAPULOPERONEAL DYSTROPHY

Scapulooperoneal dystrophy is characterized by involvement of the peroneal and tibialis anterior muscles. Patients present with complaints of toe-walking. There is associated weakness of the shoulder girdle and facial muscles. The diagnosis is confirmed by muscle biopsy.

### CONGENITAL MUSCULAR DYSTROPHY

Congenital muscular dystrophy is evident at or shortly after birth and comes in several varieties.<sup>167</sup> The genetic defect in some forms of congenital muscular dystrophy is located on chromosome 6q2 in the area that codes for the protein merosin.<sup>7,33,61,64</sup> Those forms of the disease in which merosin is present may have a milder clinical course.<sup>87,131</sup>

Presenting complaints are hypotonia and motor weakness of the limbs, trunk, and facial muscles. Sucking and swallowing may be difficult. Deep tendon reflexes are decreased or absent. Deformities such as clubfeet and contractures are often present at birth. The deformities tend to worsen with growth and are aggravated by immobilization.<sup>177</sup>

Unlike other forms of muscular dystrophy, congenital muscular dystrophy has a relatively static clinical course. Any progression of weakness is quite mild. Patients who have merosin present within muscle are able to walk by 2 years of age and retain the ability to ambulate into adulthood. Merosin-deficient patients rarely develop the ability to walk independently. Some forms of congenital muscular dystrophy are associated with mental retardation,<sup>96</sup> and changes in the white matter of the brain have been demon-



## Scapulocostal Stabilization for Scapular Winging (Ketenjian)

In winging of the scapula in facioscapulohumeral muscular dystrophy, the scapula is malrotated, with its longitudinal axis deviated medially and its inferomedial angle displaced toward the spinous process of the vertebrae.

### PREOPERATIVE ASSESSMENT

Before surgery, the surgeon determines the position in which the scapula is to be fixed to the thoracic wall. This is done with the patient standing and the surgeon behind the patient.

**A,** The surgeon steadies the scapula with one hand by holding its superomedial border with the thumb and fingers. With the thumb of the opposite hand, the surgeon hooks the inferior angle of the scapula, with the palm and fingers grasping the thoracic cage laterally. The patient's arm hangs loosely at the side.

**B,** Next, the inferior angle of the scapula is displaced laterally until the medial border of the scapula is parallel with the longitudinal axis of the spinous processes of the vertebra. With the scapula fixed on the thoracic cage, the patient actively abducts the shoulder, and the degree of glenohumeral active abduction is measured. In this illustration, active shoulder abduction is 80 degrees.

**C,** Next, the inferior angle of the scapula is displaced laterally, thus laterally rotating the scapula in the coronal (scapular) plane. In this illustration the medial border of the scapula is tilted laterally 40 degrees in relation to the vertebral spines. The patient is asked to actively abduct the shoulder, and the total range of thoracoglenohumeral abduction is measured and correlated with the scapuloaxial angle (the angle formed by the medial border of the scapula with the longitudinal line connecting the spinous processes of the vertebrae).

### OPERATIVE TECHNIQUE

At surgery, the scapula is fixed to the thoracic cage at the scapuloaxial angle obtained at the maximum desired position of shoulder abduction. The operation is performed with the patient prone. The neck, entire thorax, and involved upper limb are prepared and carefully draped to allow free manipulation of the shoulder.

**D,** With the scapula in position to be fixed to the thoracic cage, a longitudinal incision is made at its medial border. The subcutaneous tissue and superficial fascia are divided in line with the skin incision.

**E,** The trapezius, levator scapulae, and rhomboids are sectioned from the medial border of the scapula; these muscles will be atrophic and replaced by fibrous or fibrofatty tissue. The supraspinatus, infraspinatus, and subscapularis are elevated with a periosteal elevator for a distance of 2.5 cm from the medial border of the scapula.

**F,** Next, four drill holes are made 1.3 cm from the medial border of the scapula at the levels of the adjacent ribs when the scapula is placed in the desired position for stabilization. The scapula is tilted to approximately 20 degrees of lateral rotation.

**G,** The ribs underlying the drill holes in the scapula are exposed subperiosteally. The surgeon must be extremely careful not to injure the intercostal vessels and nerves at the inferior margin of the ribs. Then, Mersilene or fascia lata strips are passed around the ribs.

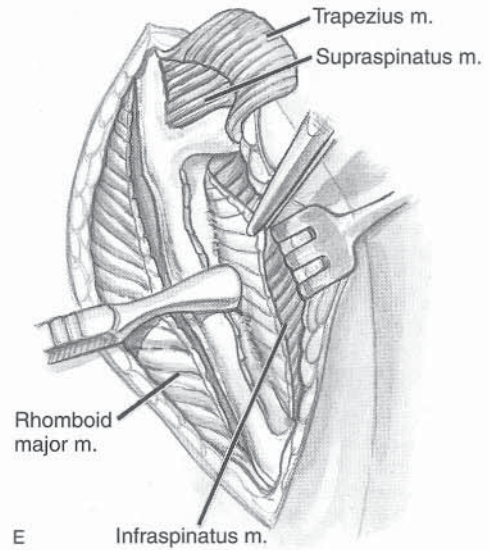
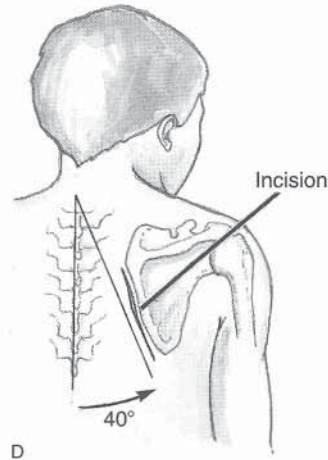
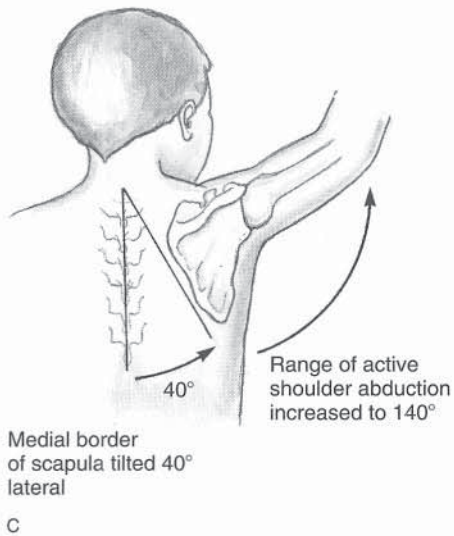
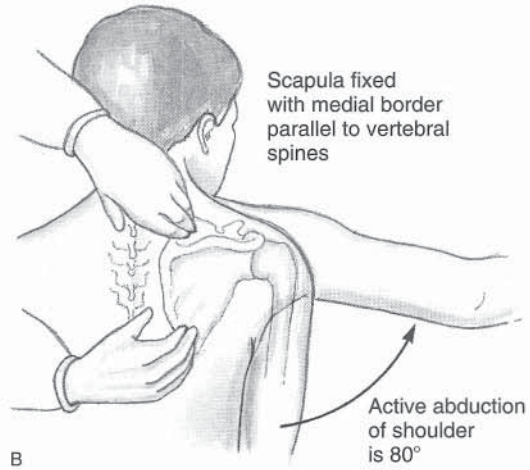
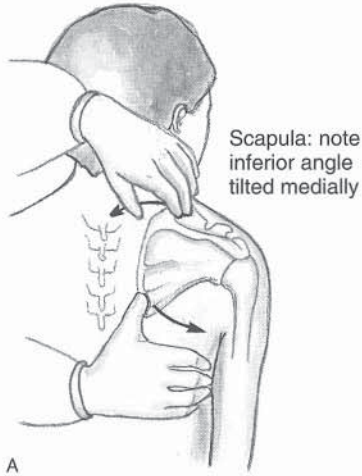
**H,** The strips are passed through drill holes and tied snugly, with the scapula maintained in 20 degrees of lateral rotation. The stability of fixation of the scapula to the rib cage is tested, and the wound is closed in the usual fashion.

### POSTOPERATIVE CARE

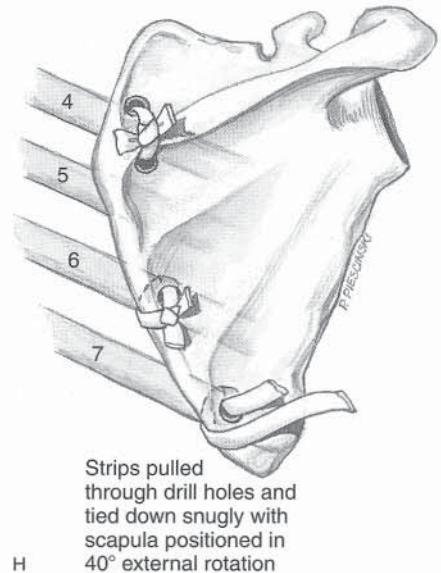
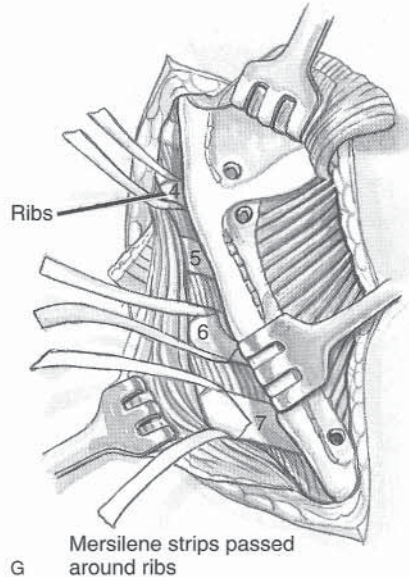
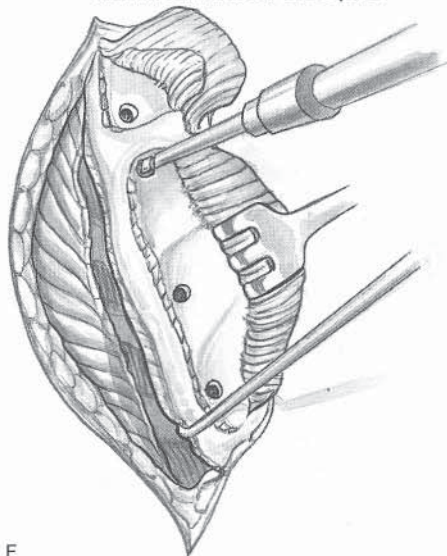
The upper limb is supported in a sling. Several days postoperatively, active assisted and gentle passive range-of-motion exercises are performed several times a day. Codman pendulum exercises are begun 7 days after surgery. The sling support is discontinued 4 to 5 weeks after the operation.



# PLATE 28-2. Scapulocostal Stabilization for Scapular Winging (Ketenjian)



Drill holes made 2.5 cm. from medial border of scapula





strated on magnetic resonance imaging (MRI) in merosin-deficient patients.<sup>131</sup>

EMG studies show myopathic changes. Serum CK levels are often, but not always, elevated. Findings from muscle biopsy are similar to findings in other types of muscular dystrophy. Skin biopsy can provide an easier route of diagnosis in merosin-deficient patients.<sup>143</sup>

## REFERENCES

### Muscular Dystrophies, Duchenne's Muscular Dystrophy, Becker's Muscular Dystrophy, Emery-Dreifuss Muscular Dystrophy, Limb-Girdle Muscular Dystrophy, Facioscapulohumeral Muscular Dystrophy, Other Forms of Muscular Dystrophy

1. A prospective, quantitative study of the natural history of facioscapulohumeral muscular dystrophy (FSHD): implications for therapeutic trials. The FSH-DY Group. *Neurology* 1997;48:38.
2. Adams RD, Denny-Brown D, Pearson CM: *Diseases of Muscle: A Study of Pathology*, 2nd ed. New York, Hoeber, 1962.
3. Alexander MA, Johnson EW, Petty J, et al: Mechanical ventilation of patients with late stage Duchenne muscular dystrophy: management in the home. *Arch Phys Med Rehabil* 1979;60:289.
4. Allen BL Jr, Ferguson RL: The Galveston technique of pelvic fixation with L-rod instrumentation of the spine. *Spine* 1984;9:388.
5. Allen BL Jr, Ferguson RL: The Galveston technique for L rod instrumentation of the scoliotic spine. *Spine* 1982;7:276.
6. Altherr MR, Bengtsson U, Markovich RP, et al: Efforts towards understanding the molecular basis of facioscapulohumeral muscular dystrophy. *Muscle Nerve* 1995;2:S32.
7. Arahata K, Ishii H, Hayashi YK: Congenital muscular dystrophies. *Curr Opin Neurol* 1995;8:385.
8. Arikawa E, Hoffman EP, Kaido M, et al: The frequency of patients with dystrophin abnormalities in a limb-girdle patient population. *Neurology* 1991;41:1491.
9. Bach JR, McKeon J: Orthopedic surgery and rehabilitation for the prolongation of brace-free ambulation of patients with Duchenne muscular dystrophy. *Am J Phys Med Rehabil* 1991;70:323.
10. Backman E, Henriksson KG: Low-dose prednisolone treatment in Duchenne and Becker muscular dystrophy. *Neuromuscul Disord* 1995;5:233.
11. Backman E, Nylander E: The heart in Duchenne muscular dystrophy: a non-invasive longitudinal study. *Eur Heart J* 1992;13:1239.
12. Bakker E, Van der Wielen MJ, Voorhoeve E, et al: Diagnostic, predictive, and prenatal testing for facioscapulohumeral muscular dystrophy: diagnostic approach for sporadic and familial cases. *J Med Genet* 1996;33:29.
13. Becker PE: Two new families of benign sex-linked recessive muscular dystrophy. *Rev Can Biol* 1962;21:551.
14. Beggs AH, Hoffman EP, Snyder JR, et al: Exploring the molecular basis for variability among patients with Becker muscular dystrophy: gene and protein studies. *Am J Hum Genet* 1991;49:54.
15. Belanger AV, McComas AJ: Neuromuscular function in limb girdle dystrophy. *J Neurol Neurosurg Psychiatry* 1985;48:1253.
16. Bialer MG, Bruns DE, Kelly TE: Muscle enzyme and isoenzymes in Emery-Dreifuss muscular dystrophy. *Clin Chem* 1990;36:427.
17. Bialer MG, McDaniel NL, Kelly TE: Progression of cardiac disease in Emery-Dreifuss muscular dystrophy. *Clin Cardiol* 1991;14:411.
18. Bione S, Small K, Aksmanovic VM, et al: Identification of new mutations in the Emery-Dreifuss muscular dystrophy gene and evidence for genetic heterogeneity of the disease. *Hum Mol Genet* 1995;4:1859.
19. Bodensteiner JB, Schochet SS: Facioscapulohumeral muscular dystrophy: the choice of a biopsy site. *Muscle Nerve* 1986;9:544.
20. Bowker JH, Halpin PJ: Factors determining success in reambulation of the child with progressive muscular dystrophy. *Orthop Clin North Am* 1978;9:431.
21. Brook PD, Kennedy JD, Stern LM, et al: Spinal fusion in Duchenne's muscular dystrophy. *J Pediatr Orthop* 1996;16:324.
22. Brooke MH, Fenichel GM, Griggs RC, et al: Duchenne muscular dystrophy: patterns of clinical progression and effects of supportive therapy. *Neurology* 1989;39:475.
23. Bunch WH, Siegel IM: Scapulothoracic arthrodesis in facioscapulohumeral muscular dystrophy. *J Bone Joint Surg* 1993;75-A:372.
24. Bushby KM, Gardner-Medwin D: The clinical, genetic and dystrophin characteristics of Becker muscular dystrophy. I. Natural history. *J Neurol* 1993;240:98.
25. Bushby KM, Gardner-Medwin D, Nicholson LV, et al: The clinical, genetic and dystrophin characteristics of Becker muscular dystrophy. II. Correlation of phenotype with genetic and protein abnormalities. *J Neurol* 1993;240:105.
26. Bushby KM, Goodship JA, Nicholson LV, et al: Variability in clinical, genetic and protein abnormalities in manifesting carriers of Duchenne and Becker muscular dystrophy. *Neuromuscul Disord* 1993;3:57.
27. Bushby KM, Thambayah M, Gardner-Medwin D: Prevalence and incidence of Becker muscular dystrophy. *Lancet* 1991;337:1022.
28. Byers TJ, Neumann PE, Beggs AH, et al: ELISA quantitation of dystrophin for the diagnosis of Duchenne and Becker muscular dystrophies. *Neurology* 1992;42:570.
29. Cambridge W, Drennan JC: Scoliosis associated with Duchenne muscular dystrophy. *J Pediatr Orthop* 1987;7:436.
30. Chalkiadis GA, Branch KG: Cardiac arrest after isoflurane anaesthesia in a patient with Duchenne muscular dystrophy. *Anaesthesia* 1990;45:22.
31. Chung CS, Morton NE, Peters HA: Serum enzymes and genetic carriers in muscular dystrophy. *Am J Hum Genet* 1960;12:52.
32. Colbert AP, Graig C: Scoliosis management in Duchenne muscular dystrophy: prospective study of modified Jewett hyperextension brace. *Arch Phys Med Rehabil* 1987;68:302.
33. Connolly AM, Pestronk A, Planer GJ, et al: Congenital muscular dystrophy syndromes distinguished by alkaline and acid phosphatase, merosin, and dystrophin staining. *Neurology* 1996;46:810.
34. Consalez GG, Thomas NS, Stayton CL, et al: Assignment of Emery-Dreifuss muscular dystrophy to the distal region of Xq28: the results of a collaborative study. *Am J Hum Genet* 1991;48:468.
35. Daher YH, Lonstein JE, Winter RB, et al: Spinal deformities in patients with muscular dystrophy other than Duchenne: a review of 11 patients having surgical treatment. *Spine* 1985;10:614.
36. Dormans JP, Templeton JJ, Edmonds C, et al: Intraoperative anaphylaxis due to exposure to latex (natural rubber) in children. *J Bone Joint Surg* 1994;76-A:1688.
37. Duchenne GB: Recherches sur le paralysie musculaire pseudo-hypertrophique ou paralysie myosclerosique. *Arch Gen Med* 1868;11:5.
38. Dupont G, Gayet E, Pries P, et al: Spinal deformities and wheelchair seating in Duchenne muscular dystrophy: twenty years of research and clinical experience. *Semin Neurol* 1995;15:29.
39. Edwards RHT, Round JM, Jackson MJ, et al: Weight reduction in boys with muscular dystrophy. *Dev Med Child Neurol* 1984;26:384.
40. Emery AE: Emery-Dreifuss syndrome. *J Med Genet* 1989;26:637.
41. Emery AE: Population frequencies of inherited neuromuscular diseases: a world survey. *Neuromuscul Disord* 1991;1:19.
42. Emery AEH: X-linked muscular dystrophy with early contractures and cardiomyopathy (Emery-Dreifuss type). *Clin Genet* 1987;32:360.
43. Emery AEH, Dreifuss FE: Unusual type of benign X-linked muscular dystrophy. *J Neurol Neurosurg Psychiatry* 1966;29:338.
44. Erb WH: Dystrophie muscularis progressive: klinische und pathologisch-anatomische Studien. *Dtsch Nervenheilk* 1891;1:13.
45. Erb WH: Über die "juvenile form" der progressiven Muskelatrophie: ihre Beziehungen zur sogenannten Pseudohypertrophie der Muskeln. *Dtsch Arch Klin Med* 1884;34:467.
46. Fenichel GM, Florence JM, Pestronk A, et al: Long-term benefit from prednisone therapy in Duchenne muscular dystrophy. *Neurology* 1991;41:1874.
47. Forst R, Forst J: Importance of lower limb surgery in Duchenne muscular dystrophy. *Arch Orthop Trauma Surg* 1995;114:106.
48. Fougerousse F, Broux O, Richard I, et al: Mapping of a chromosome 15 region involved in limb girdle muscular dystrophy. *Hum Mol Genet* 1994;3:285.
49. Fox H, Thomas C, Thompson A: Spinal instrumentation for Duchenne's muscular dystrophy: experience of hypotensive anaesthesia to minimize blood loss. *J Pediatr Orthop* 1997;17:750.
50. Galasko CS, Delaney C, Morris P: Spinal stabilization in Duchenne muscular dystrophy. *J Bone Joint Surg* 1992;74-B:210.
51. Galasko CS, Williamson JB, Delaney CM: Lung function in Duchenne muscular dystrophy. *Eur Spine J* 1995;4:263.
52. Goertzen M, Baltzer A, Voit T: Clinical results of early orthopaedic



- management in Duchenne muscular dystrophy. *Neuropediatrics* 1995;26:257.
53. Goldblatt J, Schram LJ, Wallis G, et al: Emery-Dreifuss syndrome and X-linked muscular dystrophy with contractures: evidence for homogeneity. *Clin Genet* 1989;35:1.
  54. Gowers WR: A lecture on myopathy of a distal form. *Br Med J* 1902;2:89.
  55. Gowers WR: *Pseudohypertrophic Muscular Paralysis*. London, Churchill Livingstone, 1879.
  56. Granata C, Merlini L, Cervellati S, et al: Long-term results of spine surgery in Duchenne muscular dystrophy. *Neuromuscul Disord* 1996;6:61.
  57. Green NE: The orthopaedic care of children with muscular dystrophy. *Instr Course Lect* 1987;36:267.
  58. Greene WB: Transfer versus lengthening of the posterior tibial tendon in Duchenne's muscular dystrophy. *Foot Ankle* 1992;13:526.
  59. Griggs RC, Moxley RT, Mendell JR, et al: Duchenne dystrophy: randomized, controlled trial of prednisone (18 months) and azathioprine (12 months). *Neurology* 1993;43:520.
  60. Griggs RC, Moxley RT, Mendell JR, et al: Prednisone in Duchenne dystrophy. *Arch Neurol* 1991;48:383.
  61. Guicheney P, Vignier N, Helbling-Leclerc A, et al: Genetics of laminin alpha 2 chain (or merosin) deficient congenital muscular dystrophy: from identification of mutations to prenatal diagnosis. *Neuromuscul Disord* 1997;7:180.
  62. Hahn A, Bach JR, Delaubier A, et al: Clinical implications of maximal respiratory pressure determinations for individuals with Duchenne muscular dystrophy. *Arch Phys Med Rehabil* 1997;78:1.
  63. Heckmatt JZ, Dubowitz V, Hyde ST, et al: Prolongation of walking in Duchenne muscular dystrophy with lightweight orthoses: review of 57 cases. *Dev Med Child Neurol* 1985;27:149.
  64. Helbling-Leclerc A, Zhang X, Topaloglu H, et al: Mutations in the laminin alpha 2-chain gene (LAMA2) cause merosin-deficient congenital muscular dystrophy. *Nat Genet* 1995;11:216.
  65. Hilton T, Orr RD, Perkin RM, et al: End of life care in Duchenne muscular dystrophy. *Pediatr Neurol* 1993;9:165.
  66. Hodgson S, Boswinkel E, Cole C, et al: A linkage study of Emery-Dreifuss muscular dystrophy. *Hum Genet* 1986;74:409.
  67. Hoffman EP, Clemens PR: HyperCKemic, proximal muscular dystrophies and the dystrophin membrane cytoskeleton, including dystrophinopathies, sarcoglycanopathies, and merosinopathies. *Curr Opin Rheumatol* 1996;8:528.
  68. Hoffman EP, Fischbeck KH, Brown RH, et al: Characterization of dystrophin in muscle-biopsy specimens from patients with Duchenne's or Becker's muscular dystrophy. *N Engl J Med* 1988;318:1363.
  69. Hoffman EP, Hudecki MS, Rosenberg PA, et al: Cell and fiber-type distribution of dystrophin. *Neuron* 1988;1:411.
  70. Hoffman EP, Kunkel LM, Angelini C, et al: Improved diagnosis of Becker muscular dystrophy by dystrophin testing. *Neurology* 1989;39:1011.
  71. Hoffman EP, Pegoraro E, Scacheri P, et al: Genetic counseling of isolated carriers of Duchenne muscular dystrophy. *Am J Med Genet* 1996;63:573.
  72. Hoogerwaard EM, de Voogt WG, Wilde AA, et al: Evolution of cardiac abnormalities in Becker muscular dystrophy over a 13-year period. *J Neurol* 1997;244:657.
  73. Hsu JD: The natural history of spine curvature progression in the nonambulatory Duchenne muscular dystrophy patient. *Spine* 1983;8:771.
  74. Hsu JD, Furumasa J: Gait and posture changes in the Duchenne muscular dystrophy child. *Clin Orthop* 1993;288:122.
  75. Iannaccone ST: Current status of Duchenne muscular dystrophy. *Pediatr Clin North Am* 1992;39:879.
  76. Inui K, Okada S, Dickson G: Gene therapy in Duchenne muscular dystrophy. *Brain Dev* 1996;18:357.
  77. Irwin MG, Henderson M: Cardiac arrest during major spinal scoliosis surgery in a patient with Duchenne's muscular dystrophy undergoing intravenous anaesthesia. *Anaesth Intensive Care* 1995;23:26.
  78. Jensen V: The anaesthetic management of a patient with Emery-Dreifuss muscular dystrophy. *Can J Anaesth* 1996;43:968.
  79. Kaido M, Arahata K, Hoffman EP, et al: Muscle histology in Becker muscular dystrophy. *Muscle Nerve* 1991;14:1067.
  80. Kakulas BA: The differential diagnosis of the human dystrophinopathies and related disorders. *Curr Opin Neurol* 1996;9:380.
  81. Karpati G, Acsadi G: The potential for gene therapy in Duchenne muscular dystrophy and other genetic muscle diseases. *Muscle Nerve* 1993;16:1141.
  82. Karpati G, Gilbert R, Petrof BJ, et al: Gene therapy research for Duchenne and Becker muscular dystrophies. *Curr Opin Neurol* 1997;10:430.
  83. Kelfer HM, Singer WD, Reynolds RN: Malignant hyperthermia in a child with Duchenne muscular dystrophy. *Pediatrics* 1983;71:118.
  84. Kennedy JD, Staples AJ, Brook PD, et al: Effect of spinal surgery on lung function in Duchenne muscular dystrophy. *Thorax* 1995;50:1173.
  85. Ketenjian AY: Scapulothoracic stabilization for scapular winging in facioscapulohumeral muscular dystrophy. *J Bone Joint Surg* 1978;60-A:476.
  86. Kilmer DD, Abresch RT, McCrory MA, et al: Profile of neuromuscular diseases: facioscapulohumeral muscular dystrophy. *Am J Phys Med Rehabil* 1995;74:S131.
  87. Kobayashi H, Garcia CA, Alfonso G, et al: Molecular genetics of familial spastic paraplegia: a multitude of responsible genes. *J Neurol Sci* 1996;137:131.
  88. Kocalkowski A, Frostick SP, Wallace WA: One-stage bilateral thoracoscopic fusion using allografts: a case report. *Clin Orthop* 1991;273:264.
  89. Korf BR, Bresnan MJ, Shapiro F, et al: Facioscapulohumeral dystrophy presenting in infancy with facial diplegia and sensorineural deafness. *Ann Neurol* 1985;17:513.
  90. Kunkel LM: Analysis of deletions in DNA from patients with Becker and Duchenne muscular dystrophy. *Nature* 1986;322:73.
  91. Kurz LT, Mubarak SJ, Schultz P, et al: Correlation of scoliosis and pulmonary function in Duchenne muscular dystrophy. *J Pediatr Orthop* 1983;3:347.
  92. Landouzy L, Dejerine J: De la myopathie atrophique progressive (myopathie hereditaire), debutant, dans l'enfance, par la face, sans alteration du systeme nerveux. *C R Acad Sci (Paris)* 1884;98:53.
  93. Larsen UT, Juhl B, Hein-Sørensen O, et al: Complications during anaesthesia in patients with Duchenne's muscular dystrophy (a retrospective study). *Can J Anaesth* 1989;36:418.
  94. Letournel E, Fardeau M, Lytle JO, et al: Scapulothoracic arthrodesis for patients who have facioscapulohumeral muscular dystrophy. *J Bone Joint Surg* 1990;72-A:78.
  95. Leyden E: *Klinik der Ruchemarks-Krankheiten*, vol 2, p 531. Berlin, Hirschwald, 1876.
  96. Leyten QH, Gabreels FJ, Renier WO, et al: White matter abnormalities in congenital muscular dystrophy. *J Neurol Sci* 1995;129:162.
  97. Luque ER: Segmental spinal instrumentation for correction of scoliosis. *Clin Orthop* 1982;163:192.
  98. Manilal S, Nguyen TM, Sewry CA, et al: The Emery-Dreifuss muscular dystrophy protein, emerin, is a nuclear membrane protein. *Hum Mol Genet* 1996;5:801.
  99. Manzur AY, Hyde SA, Rodillo E, et al: A randomized controlled trial of early surgery in Duchenne muscular dystrophy. *Neuromuscul Disord* 1992;2:379.
  100. Marchesi D, Arlet V, Stricker U, et al: Modification of the original Luque technique in the treatment of Duchenne's neuromuscular scoliosis. *J Pediatr Orthop* 1997;17:743.
  101. Marconi G, Pizzi A, Arimondi CG, et al: Limb girdle muscular dystrophy with autosomal dominant inheritance. *Acta Neurol Scand* 1991;83:234.
  102. Matthews PM, Benjamin D, Van Bakel I, et al: Muscle X-inactivation patterns and dystrophin expression in Duchenne muscular dystrophy carriers. *Neuromuscul Disord* 1995;5:209.
  103. Maunder-Sewry CA, Dubowitz V: Needle muscle biopsy for carrier detection in Duchenne muscular dystrophy. Part 1. Light microscopy-histology, histochemistry and quantitation. *J Neurol Sci* 1981;49:305.
  104. McCarthy RE, Dunn H, McCullough FL: Luque fixation to the sacral ala using the Dunn-McCarthy modification. *Spine* 1989;14:281.
  105. McDonald CM, Johnson ER, Abresch RT, et al: Profiles of neuromuscular diseases: limb-girdle syndromes. *Am J Phys Med Rehabil* 1995;74:S117.
  106. McDonald TD, Medori R, Younger DS, et al: Becker muscular dystrophy or spinal muscular atrophy? Dystrophin studies resolve conflicting results of electromyography and muscle biopsy. *Neuromuscul Disord* 1991;1:195.
  107. Mendell JR, Kissel JT, Amato AA, et al: Myoblast transfer in the treatment of Duchenne's muscular dystrophy. *N Engl J Med* 1995;333:832.
  108. Mendell JR, Moxley RT, Griggs RC, et al: Randomized, double-blind



- six-month trial of prednisone in Duchenne's muscular dystrophy. *N Engl J Med* 1989;320:1592.
109. Merlini L, Granata C, Dominici P, et al: Emery-Dreifuss muscular dystrophy: report of five cases in a family and review of the literature. *Muscle Nerve* 1986;9:481.
  110. Meryon E: On granular or fatty degeneration of the voluntary muscles. *Trans Med Chir Soc Edinb* 1852;35:72.
  111. Miller F, Moseley CF, Koreska J: Spinal fusion in Duchenne muscular dystrophy. *Dev Med Child Neurol* 1992;34:775.
  112. Miller F, Moseley CF, Koreska J, et al: Pulmonary function and scoliosis in Duchenne dystrophy. *J Pediatr Orthop* 1988;8:133.
  113. Miller GM, Hsu JD, Hoffer MM, et al: Posterior tibial tendon transfer: a review of the literature and analysis of 74 procedures. *J Pediatr Orthop* 1982;2:363.
  114. Miller RG, Chalmers AC, Dao H, et al: The effect of spine fusion on respiratory function in Duchenne muscular dystrophy. *Neurology* 1991;41:38.
  115. Miller RG, Hoffman EP: Molecular diagnosis and modern management of Duchenne muscular dystrophy. *Neurol Clin* 1994;12:699.
  116. Miller RG, Sharma KR, Pavlath GK, et al: Myoblast implantation in Duchenne muscular dystrophy: the San Francisco study. *Muscle Nerve* 1997;20:469.
  117. Moglia A, Zandrini C, Rascarioli M, et al: Peripheral nerve conduction velocity in normal infants and children. *Ital J Neurol Sci* 1989;10:311.
  118. Mora M, Cartegni L, Di Biasi C, et al: X-linked Emery-Dreifuss muscular dystrophy can be diagnosed from skin biopsy or blood sample. *Ann Neurol* 1997;42:249.
  119. Mubarak SJ, Chambers HG, Wenger DR: Percutaneous muscle biopsy in the diagnosis of neuromuscular disease. *J Pediatr Orthop* 1992;12:191.
  120. Mubarak SJ, Morin WD, Leach J: Spinal fusion in Duchenne muscular dystrophy: fixation and fusion to the sacropelvis? *J Pediatr Orthop* 1993;13:752.
  121. Munsat TL, Baloh R, Pearson CM, et al: Serum enzyme alterations in neuromuscular disorders. *JAMA* 1973;226:1536.
  122. Nagano A, Koga R, Ogawa M, et al: Emerin deficiency at the nuclear membrane in patients with Emery-Dreifuss muscular dystrophy. *Nat Genet* 1996;12:254.
  123. Nicholson LV, Johnson MA, Gardner-Medwin D, et al: Heterogeneity of dystrophin expression in patients with Duchenne and Becker muscular dystrophy. *Acta Neuropathol* 1990;80:239.
  124. Nicholson LV, Johnson MA, Bushby KM, et al: Functional significance of dystrophin positive fibers in Duchenne muscular dystrophy. *Arch Dis Child* 1993;68:632.
  125. Nigro G, Gomi LI, Politano L, et al: The incidence and evolution of cardiomyopathy in Duchenne muscular dystrophy. *Int J Cardiol* 1990;26:271.
  126. Norman A, Thomas N, Coakley J, et al: Distinction of Becker from limb-girdle muscular dystrophy by means of dystrophin cDNA probes. *Lancet* 1989;1:466.
  127. Oswald AH, Goldblatt J, Horak AR, et al: Lethal cardiac conduction defects in Emery-Dreifuss muscular dystrophy. *S Afr Med J* 1987;72:567.
  128. Pangeyres PK, Mastaglia FL, Kakulas BA: Limb girdle syndromes: clinical, morphological and electrophysiological studies. *J Neurol Sci* 1990;95:201.
  129. Partridge TA: Myoblast transfer: a possible therapy for inherited myopathies? [Invited Review.] *Muscle Nerve* 1991;14:197.
  130. Partridge TA, Davies KE: Myoblast-based gene therapies. *Br Med Bull* 1995;51:123.
  131. Philpot J, Sewry C, Pennock J, et al: Clinical phenotype in congenital muscular dystrophy: correlation with expression of merosin in skeletal muscle. *Neuromuscul Disord* 1995;5:301.
  132. Rabben OK: Sensory nerve conduction studies in children: age-related changes of conduction velocities. *Neuropediatrics* 1995;26:26.
  133. Rakovec P, Zidar J, Sinkovec M, et al: Cardiac involvement in Emery-Dreifuss muscular dystrophy: role of a diagnostic pacemaker. *Pacing Clin Electrophysiol* 1995;18:1721.
  134. Ramirez N, Richards BS, Warren PD, et al: Complications after posterior spinal fusion in Duchenne's muscular dystrophy. *J Pediatr Orthop* 1997;17:109.
  135. Read L, Galasko CS: Delay in diagnosing Duchenne muscular dystrophy in orthopaedic clinics. *J Bone Joint Surg* 1986;68-B:481.
  136. Richards S, Iannaccone ST: Dystrophin and DNA diagnosis in a large pediatric muscle clinic. *J Child Neurol* 1994;9:162.
  137. Rideau Y, Duport G, Delaubier A, et al: Early treatment to preserve quality of locomotion for children with Duchenne muscular dystrophy. *Semin Neurol* 1995;15:9.
  138. Rideau Y, Glorion B, Delaubier A, et al: The treatment of scoliosis in Duchenne muscular dystrophy. *Muscle Nerve* 1984;7:281.
  139. Rittoo DB, Morris P: Tracheal occlusion in the prone position in an intubated patient with Duchenne muscular dystrophy. *Anaesthesia* 1995;50:719.
  140. Rudenskaya GE, Ginter EK, Petrin AN, et al: Emery-Dreifuss syndrome: genetic and clinical varieties. *Am J Med Genet* 1994;50:228.
  141. Saito M, Kawai H, Akaike M, et al: Cardiac dysfunction with Becker muscular dystrophy. *Am Heart J* 1996;132:642.
  142. Sarfarazi M, Wijmenga C, Upadhyaya M, et al: Regional mapping of facioscapulohumeral muscular dystrophy gene on 4q35: combined analysis of an international consortium. *Am J Hum Genet* 1992;51:396.
  143. Sewry CA, Philpot J, Sorokin LM, et al: Diagnosis of merosin (laminin-2) deficient congenital muscular dystrophy by skin biopsy. *Lancet* 1996;347:582.
  144. Shapiro F, Sethna N, Colan S, et al: Spinal fusion in Duchenne muscular dystrophy: a multidisciplinary approach. *Muscle Nerve* 1992;15:604.
  145. Shapiro F, Specht L: The diagnosis and orthopaedic treatment of inherited muscular diseases of childhood. [Current concepts review.] *J Bone Joint Surg* 1993;75-A:439.
  146. Shapiro F, Specht L: Orthopedic deformities in Emery-Dreifuss muscular dystrophy. *J Pediatr Orthop* 1991;11:336.
  147. Small K, Iber J, Warren ST: Emerin deletion reveals a common X-chromosome inversion mediated by inverted repeats. *Nat Genet* 1997;16:96.
  148. Smith AD, Koreska J, Moseley CF: Progression of scoliosis in Duchenne muscular dystrophy. *J Bone Joint Surg* 1989;71-A:1066.
  149. Smith SE, Green NE, Cole RJ, et al: Prolongation of ambulation in children with Duchenne muscular dystrophy by subcutaneous lower limb tenotomy. *J Pediatr Orthop* 1993;13:336.
  150. Stubgen JP: Limb girdle muscular dystrophy: a non-invasive cardiac evaluation. *Cardiology* 1993;83:324.
  151. Stubgen JP: Limb girdle muscular dystrophy: a quantitative electromyographic study. *Electromyogr Clin Neurophysiol* 1995;35:351.
  152. Stubgen JP, Ras GJ, Schultz CM, et al: Lung and respiratory muscle function in limb girdle muscular dystrophy. *Thorax* 1994;49:61.
  153. Sussman MD: Advantage of early spinal stabilization and fusion in patients with Duchenne muscular dystrophy. *J Pediatr Orthop* 1984;4:532.
  154. Sussman MD: Treatment of scoliosis in Duchenne muscular dystrophy. *Dev Med Child Neurol* 1985;27:522.
  155. Sutherland DH: Gait analysis in neuromuscular disease. *Instr Course Lect* 1990;39:333.
  156. Sutherland DH, Olshen R, Cooper L, et al: The pathomechanics of gait in Duchenne muscular dystrophy. *Dev Med Child Neurol* 1981;23:3.
  157. Swank SM, Brown JC, Perry RE: Spinal fusion in Duchenne muscular dystrophy. *Spine* 1982;7:484.
  158. Tawil R, McDermott MP, Pandya S, et al: A pilot trial of prednisone in facioscapulohumeral muscular dystrophy. FSH-DY Group. *Neurology* 1997;48:46.
  159. ten Houten R, De Visser M: Histopathological findings in Becker-type muscular dystrophy. *Arch Neurol* 1984;4:729.
  160. Thomsen J: Tonische Krämpfe in willkürlich beweglichen Muskeln in Folge von Erebter psychischer Disposition (Ataxia musculairs?). *Arch Psychiatr Nervenkr* 1876;6:706.
  161. Tsuchiya Y, Arahata K: Emery-Dreifuss syndrome. *Curr Opin Neurol* 1997;10:421.
  162. Twyman RS, Harper GD, Edgar MA: Thoracoscapular fusion in facioscapulohumeral dystrophy: clinical review of a new surgical method. *J Shoulder Elbow Surg* 1996;5:201.
  163. Upadhyaya M, Maynard J, Rogers MT, et al: Improved molecular diagnosis of facioscapulohumeral muscular dystrophy (FSHD): validation of the differential double digestion for FSHD. *J Med Genet* 1997;34:476.
  164. van der Kooij AJ, Barth PG, Busch HF, et al: The clinical spectrum of limb girdle muscular dystrophy: a survey in The Netherlands. *Brain* 1996;119:1471.
  165. Vignos PJ, Wagner MB, Kaplan JS, et al: Predicting the success of reambulation in patients with Duchenne muscular dystrophy. *J Bone Joint Surg* 1983;65-A:719.
  166. Vignos PJ, Wagner MB, Karlinchak B, et al: Evaluation of a program



- for long-term treatment of Duchenne muscular dystrophy: experience at the University Hospitals of Cleveland. *J Bone Joint Surg* 1996; 78-A:1844.
167. Voit T: Congenital muscular dystrophies: 1997 update. *Brain Dev* 1998;20:65.
  168. Voit T, Krogmann O, Lenard HG, et al: Emery-Dreifuss muscular dystrophy: disease spectrum and differential diagnosis. *Neuropediatrics* 1988;19:62.
  169. Walton JN, Gardner-Medwin D: Progressive muscular and myotonic disorders. In *Disorders of Voluntary Muscle*, 4th ed, p 481. Edinburgh, Churchill Livingstone, 1981.
  170. Walton JN, Nattrass FJ: On the classification, natural history and treatment of the myopathies. *Brain* 1954;77:169.
  171. Weimann RL, Gibson DA, Moseley CF, et al: Surgical stabilization of the spine in Duchenne muscular dystrophy. *Spine* 1983;8:776.
  172. Wijmenga C, Frants RR, Brouwer OF, et al: Location of facioscapulo-humeral muscular dystrophy gene on chromosome 4. *Lancet* 1990; 336:651.
  173. Williams EA, Read L, Ellis A, et al: The management of equinus deformity in Duchenne muscular dystrophy. *J Bone Joint Surg* 1984; 66-B:546.
  174. Wulff K, Ebener U, Wehnert CS, et al: Direct molecular genetic diagnosis and heterozygote identification in X-linked Emery-Dreifuss muscular dystrophy by heteroduplex studies. *Dis Markers* 1997;13:77.
  175. Yamanouchi Y, Arikawa E, Arahata K, et al: Limb-girdle muscular dystrophy: clinical and pathologic reevaluation. *J Neurol Sci* 1995; 129:15.
  176. Yoshioka M, Saida K, Itagaki Y, et al: Follow up study of cardiac involvement in Emery-Dreifuss muscular dystrophy. *Arch Dis Child* 1989;64:713.
  177. Zellweger H, Antonik A: Newborn screening for Duchenne muscular dystrophy. *Pediatrics* 1975;5:30.

## Myotonic Dystrophy

Myotonic dystrophy is a steadily progressive familial disease in which a myopathy involving the face, eye, jaw, neck, and distal limb muscles is associated with myotonia. Onset of the disease usually occurs in late adolescence or adulthood. An earlier onset is seen in offspring of affected mothers, in which case the disease is called *congenital myotonic dystrophy*.

### ETIOLOGY

The condition is transmitted as an autosomal dominant trait. An increase in the clinical severity of the disease with genetic transmission through generations is known as *anticipation*.<sup>10</sup> The genetic defect in myotonic dystrophy is an expansion of a CTG triplet in the myotonin protein kinase gene on chromosome 19.<sup>14,15</sup> The size of the repeat correlates with the severity of the disease, phenotypically.<sup>3,4</sup> Probes have been developed for molecular genetic testing for diagnostic purposes.<sup>8</sup> A characteristic “dive bomber” signal on EMG can be helpful in establishing the presence of myotonia.

### CLINICAL FEATURES

Myotonia, the striking characteristic of the disease, is the failure of voluntary muscles to relax immediately and the persistence of contraction following voluntary movement or mechanical or electrical stimulation. A delay in the relaxation of the hand grip can be noted clinically. Myotonia may be elicited by striking the muscle of the thenar eminence or deltoid with a reflex hammer. A persistent dimple is seen

owing to the prolonged muscle contraction (Fig. 28–13). The muscles most affected by myotonia are those of the hands, face, tongue, and occasionally the limbs. When the patient tightly closes the eyes, there is a delay in relaxation. The degree of myotonia is lessened by repetition of motion.

There is a characteristic facial appearance associated with myotonic dystrophy (Fig. 28–14). The face is expressionless. Ptosis is notable. The patient has difficulty pursing the lips, whistling, and tightly closing the eyes. The voice is nasal and monotonous. Dysarthria may result from laryngeal involvement. The sternocleidomastoid muscles are often involved, with atrophy leading to increasing cervical lordosis.

Myotonic dystrophy affects the distal musculature first, with the muscles of the hand, the tibialis anterior, and the peroneals involved early in the course of the disease. The calf muscles become involved next, and subsequently the quadriceps and hamstrings. The deep tendon reflexes are diminished or absent. Contractures are mild, but children with the congenital form of the disease may have foot deformities.<sup>13</sup> Severe clubfeet, similar to that seen in children with arthrogyrosis, may be present in newborns with congenital myotonic dystrophy.<sup>2</sup> Some patients slowly lose the ability to walk within 20 years from the onset of symptoms.

### ASSOCIATED MEDICAL PROBLEMS

Myotonic dystrophy is associated with mental retardation. Cerebral atrophy and white matter disease can be seen on MRI of the brain, and these findings correlate with increasing size of the triplet expansion.<sup>1,5,6</sup> The severity of mental impairment is greater in the congenital form of the disease.<sup>9</sup> Other associated medical problems include cataracts, gonadal atrophy, and cardiac arrhythmias.<sup>7</sup> Annual ECG has been recommended to monitor for cardiac involvement.<sup>12</sup> Anesthesia poses great risks for patients with myotonic dystrophy.<sup>11</sup> The life span is shortened for most patients with myotonic dystrophy.

### REFERENCES

#### Myotonic Dystrophy

1. Bachmann G, Damian MS, Koch M, et al: The clinical and genetic correlates of MRI findings in myotonic dystrophy. *Neuroradiology* 1996;38:629.
2. Bowen RS, Marks HG: Foot deformities in myotonic dystrophy. *Foot Ankle* 1984;5:125.
3. Gennarelli M, Novelli G, Andreasi BF, et al: Prediction of myotonic dystrophy clinical severity based on the number of intragenic (CTG) trinucleotide repeats. *Am J Med Genet* 1996;65:342.
4. Gharehbaghi-Schnell EB, Finsterer J, Korschineck I, et al: Genotype-phenotype correlation in myotonic dystrophy. *Clin Genet* 1998;53:20.
5. Hashimoto T, Tayama M, Miyazaki M, et al: Neuroimaging study of myotonic dystrophy. I. Magnetic resonance imaging of the brain. *Brain Dev* 1995;17:24.
6. Hashimoto T, Tayama M, Miyazaki M, et al: Neuroimaging study of myotonic dystrophy. II. MRI measurements of the brain. *Brain Dev* 1995;17:28.
7. Hayashi Y, Ikeda U, Kojo T, et al: Cardiac abnormalities and cytosine-thymine-guanine trinucleotide repeats in myotonic dystrophy. *Am Heart J* 1997;134:292.
8. Hecht BK, Donnelly A, Gedeon AK, et al: Direct molecular diagnosis of myotonic dystrophy. *Clin Genet* 1993;43:276.
9. Johnson ER, Abresch RT, Carter GT, et al: Profiles of neuromuscular diseases: myotonic dystrophy. *Am J Phys Med Rehabil* 1995;74 (suppl 5):S104.
10. Lopez de Munain A, Blanco A, Emparanza JI, et al: Anticipation in



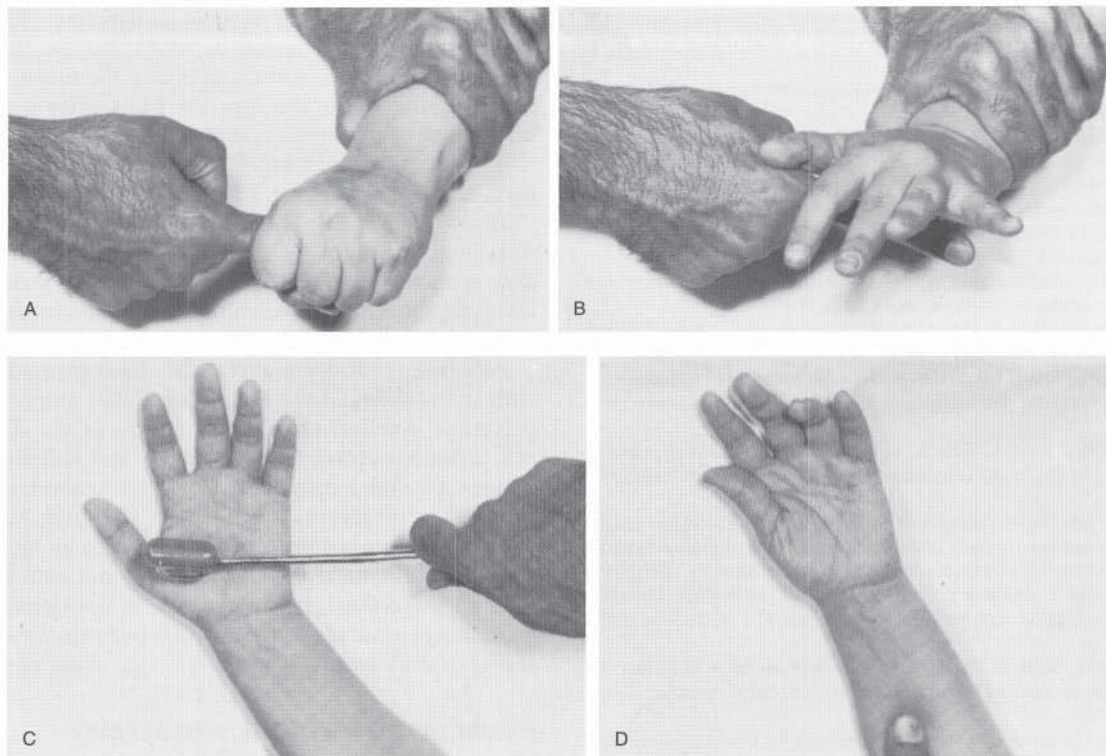


FIGURE 28-13 Clinical signs of myotonia in a patient with myotonic dystrophy. A and B, A delay in the relaxation of the hand can be noted. C, Myotonia may be elicited by striking the muscle of the thenar eminence or deltoid with a reflex hammer. D, A persistent dimple is seen, owing to the prolonged muscle contraction.

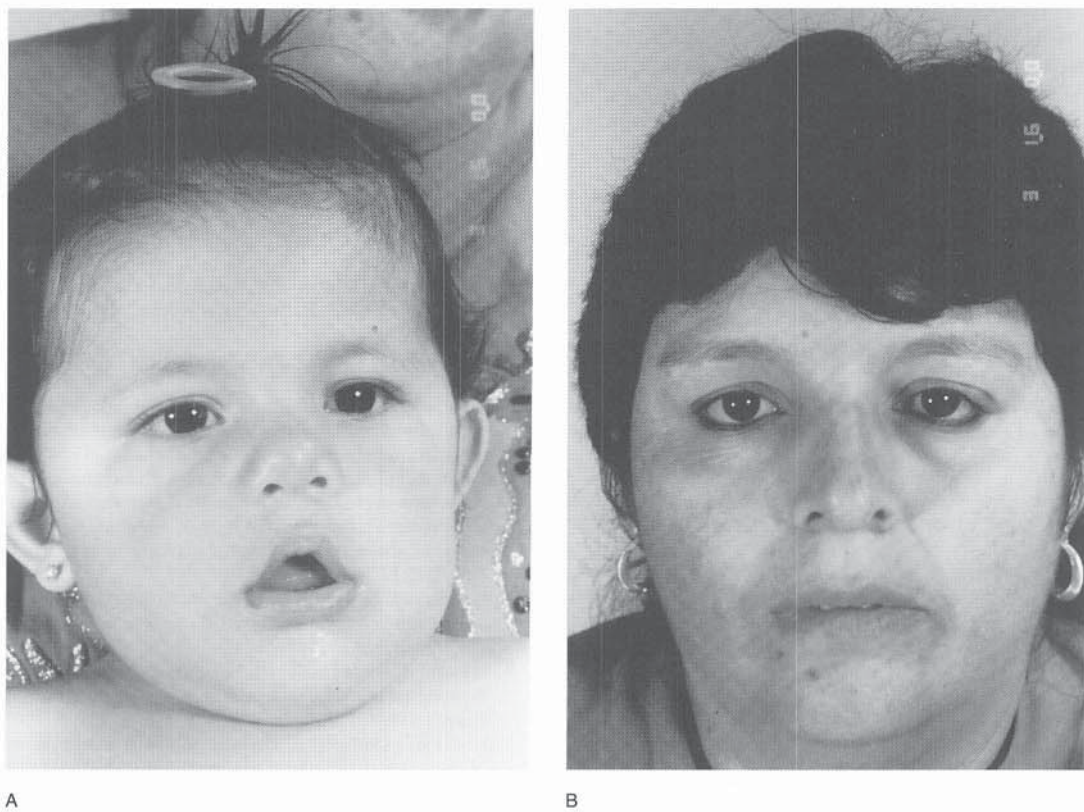

FIGURE 28-14 Characteristic facial appearance associated with myotonic dystrophy as seen in a child (A) and the child's mother (B). The face is expressionless. Ptosis is present.



myotonic dystrophy: a parental-sex-related phenomenon. *Neuroepidemiology* 1994;13:75.

11. Mathieu J, Allard P, Gobeil G, et al: Anesthetic and surgical complications in 219 cases of myotonic dystrophy. *Neurology* 1997;49:1646.
12. Phillips MF, Harper PS: Cardiac disease in myotonic dystrophy. *Cardiovasc Res* 1997;33:13.
13. Roig M, Balliu PR, Navarro C, et al: Presentation, clinical course, and outcome of the congenital form of myotonic dystrophy. *Pediatr Neurol* 1994;11:208.
14. Spranger M, Spranger S, Tischendorf M, et al: Myotonic dystrophy: the role of large triplet repeat length in the development of mental retardation. *Arch Neurol* 1997;54:251.
15. Tachi N, Kozuka N, Ohya K, et al: CTG repeat size and histologic findings of skeletal muscle from patients with congenital myotonic dystrophy. *J Child Neurol* 1996;11:430.

## Thomsen's Myotonia (Myotonia Congenita)

Myotonia congenita is a congenital affliction characterized by myotonia of the entire voluntary musculature. After voluntary contraction of a muscle (for example, gripping the hand), there is inability to quickly relax the muscle. This rare disorder was first described by Thomsen,<sup>8</sup> who himself suffered from the disease.

The disease is transmitted as an autosomal dominant trait, with males and females equally affected. The gene for Thomsen's disease has been located on chromosome 7q35 in the region of the human skeletal muscle chloride channel gene.<sup>1,2,4</sup> The abnormality in the chloride channel causes muscle membrane hyperexcitability, which results in the inability of the muscle to relax electrically.<sup>6</sup> This is a different gene from the gene responsible for myotonic dystrophy, and hence the clinical courses of the two diseases differ.

### **PATHOLOGY**

The muscle fibers in Thomsen's disease are hypertrophied. Dystrophic changes are not seen.<sup>9</sup>

### **CLINICAL FEATURES**

Myotonia may be noted in infancy or early childhood. There may be a history of developmental delay. The presenting complaints are difficulty and stiffness in initiating activity following rest, difficulty in walking or running after prolonged sitting, frequent falling, and clumsiness. The lower limbs are affected more than the upper extremities. The myotonia is worse at the beginning of an activity and lessens with repetitive movements.

The characteristic physical finding is myotonia, which can be noted when the surface of any muscle is struck sharply with a reflex hammer. The stimulated area of the muscle will contract and remain contracted for several seconds before relaxing. Another way to demonstrate myotonia is to ask the patient to rapidly open a tightly clenched fist. Muscle weakness and endocrine abnormalities are not seen in this disease. The neurologic examination is otherwise normal. Diffuse hypertrophy of the muscles develops, resulting in a "Herculean" appearance, which may be present in early childhood or may develop over time.

### **LABORATORY FINDINGS**

EMG shows myotonia. Serum CK and aldolase levels are normal.

### **DIFFERENTIAL DIAGNOSIS**

The primary entities to be distinguished from myotonia congenita are myotonic dystrophy and paramyotonia congenita of Eulenburg (Table 28–5).

### **TREATMENT**

Treatment is medical, consisting of quinine sulfate or procaine amide.<sup>5</sup> Diphenylhydantoin (Dilantin) or mexiletine also relieve myotonia.<sup>3,7</sup>

### **PROGNOSIS**

Disability is minimal. The disease is not progressive, and patients remain ambulatory. Drug therapy is not necessary for all affected individuals, as many learn to live with the myotonia by "warming up" the muscles before commencing activity.

### **REFERENCES**

#### Thomsen's Myotonia (Myotonia Congenita)

1. Abdalla JA, Casley WL, Cousin HK, et al: Linkage of Thomsen disease to the T-cell-receptor beta (TCRB) locus on chromosome 7q35. *Am J Hum Genet* 1992;51:579.
2. Abdalla JA, Casley WL, Hudson AJ, et al: Linkage analysis of candidate loci in autosomal dominant myotonia congenita. *Neurology* 1992;42:1561.
3. Ceccarelli M, Rossi B, Siciliano G, et al: Clinical and electrophysiological reports in a case of early onset myotonia congenita (Thomsen's disease) successfully treated with mexiletine. *Acta Paediatr* 1992;81:453.
4. George AL Jr, Crackower MA, Abdalla JA, et al: Molecular basis of Thomsen's disease (autosomal dominant myotonia congenita). *Nat Genet* 1993;3:305.
5. Geschwind N, Simpson JA: Procaine amide in the treatment of myotonia. *Brain* 1955;78:81.
6. Koch MC, Steinmeyer K, Lorenz C, et al: The skeletal muscle chloride channel in dominant and recessive human myotonia. *Science* 1992;257:797.
7. Kwiecinski H, Ryniewicz B, Ostrzycki A: Treatment of myotonia with antiarrhythmic drugs. *Acta Neurol Scand* 1992;86:371.
8. Thomsen J: Tonische Kranke in willkürlich beweglichen Muskeln in Folge von ererbter psychischer Disposition. *Arch Psychiatr Nervenkr* 1876;6:706.
9. Wohlfart G: Dystrophia myotonica and myotonia congenita: histopathologic studies with special reference to change in the muscle. *J Neuropathol Exp Neurol* 1951;10:109.

## Metabolic Diseases of Muscle

### **PERIODIC PARALYSIS**

Transient and recurring weakness or paralysis of skeletal muscles may occur in familial or sporadic forms. The etiology of periodic paralysis is abnormalities of the skeletal muscle calcium<sup>11,15</sup> and sodium<sup>7,12</sup> channel genes. The episodes of paralysis usually are accompanied by either hypokalemia or hyperkalemia, although an extremely rare form of periodic paralysis exists in which there are no associated changes in serum potassium levels.



TABLE 28–5 Clinical Findings in Myotonia in Children

	Myotonia Congenita (Thomsen's Disease)	Paramyotonia Congenita (Paramyotonia of Eulenberg)	Myotonic Dystrophy
Age at onset	Childhood or infancy	Infancy or early childhood	Childhood to adulthood
Inheritance	Autosomal dominant (1/3 of cases) Recessive gene often (Becker's)	Autosomal dominant	Autosomal dominant
Sex incidence	Males and females equally affected	Males and females equally affected	Males and females equally affected
Precipitating factors	Voluntary movement after prolonged sitting or inactivity	Exposure to cold	Voluntary movement
Clinical findings			
Muscle group involved	Generalized Difficulty walking or running after prolonged sitting Clumsiness	Proximal muscles of limbs, eyelids, and tongue Intermittent attacks of weakness may last from few minutes to 24 hr Myotonia precedes weakness	Muscles in face, tongue, and distal limbs, particularly upper
Response to activity	Improves myotonia	Aggravates myotonia	Aggravates myotonia and fatigued-affected muscles
Muscle hypertrophy	Present ("Herculean" appearance)	Absent	Muscles atrophic
Endocrine, cardiac, other abnormalities	None	None	Testicular atrophy, ECG changes Frontal baldness, mental retardation
Laboratory findings			
Serum potassium level	Normal	High normal or elevated	Normal
Creatine kinase, aldolase levels	Normal	Normal	Elevated
Creatine clearance	Increased	Normal	Decreased
EMG	Rapid volley of action potentials on insertion of electrode into myotonic muscle	Rapid volley of action potentials on insertion of electrode into myotonic muscle	Rapid volley of action potentials of varying amplitude on insertion of electrode into myotonic muscle
Histologic findings	Hypertrophy of muscle fibers No dystrophic changes	Similar to myotonic dystrophy	Dystrophic changes (see text)
Treatment	Quinine hydrochloride and procaine amide effective	Not available Calcium gluconate may abort an attack	No specific treatment
Prognosis	Disability minimal Condition remains static	Improves with age Nonprogressive	Progressive, moderate disability over a period of many years

### HYPOKALEMIC PERIODIC PARALYSIS

Hypokalemic periodic paralysis is a disorder in which paralytic episodes associated with hypokalemia occur in response to prolonged inactivity following vigorous exercise. Stress and exposure to cold can also precipitate attacks.

**Etiology.** This rare disorder is inherited as an autosomal dominant trait. Molecular genetic research has found the locus to be on chromosome 1q, where a single amino acid has been substituted in the area encoding for a skeletal muscle voltage-gated calcium channel (the dihydropyridine receptor).<sup>6,8,11,15,21</sup> Paralytic episodes occur in more than 50 percent of patients with the genetic defect.

Hypokalemic periodic paralysis has been seen in patients with hyperthyroidism,<sup>19</sup> and in association with renal tubular acidosis.<sup>3</sup> Patients with hypokalemic periodic paralysis are also prone to malignant hyperthermia.<sup>14</sup>

**Clinical Features.** The patient wakes up at night paralyzed. The proximal muscles of the lower limbs are affected first, followed by those of the upper limbs. Paralysis of the muscles of the neck, trunk, and face occurs next. The respiratory and ocular muscles are rarely involved. The attacks usually last several hours and are self-limiting (very rarely, the disease is fatal due to respiratory paralysis).

Urinary output is decreased and thirst is increased. Sweating and diuresis follow recovery. The affected muscles appear

swollen during attacks. Deep tendon reflexes are absent. There may be cardiac involvement, and arrhythmias may occur. ECG findings characteristic of hypokalemia are present, and there may be a long QT interval.

Onset of the periodic attacks of paralysis usually occurs in early adolescence. The episodes tend to decrease in number and severity with age. A progressive myopathy with permanent weakness of late onset is seen in all older adults with genetic evidence of the disease.<sup>18</sup>

**Laboratory Findings.** The most notable laboratory finding during the paralytic attacks is hypokalemia, with serum potassium levels dropping to 2.0 to 2.5 mEq/L. As the paralysis resolves, there may be an increase in serum CK and myoglobin levels.<sup>4</sup>

**Treatment.** Paralytic attacks are treated with oral potassium.<sup>23</sup> Acetazolamide has been found to decrease the frequency of attacks and increase muscle strength in affected patients.<sup>16,17</sup> Spironolactone may also be effective in controlling the attacks.<sup>20</sup> Propranolol has been used for acute episodes associated with thyrotoxicosis.<sup>22</sup>

### HYPERKALEMIC PERIODIC PARALYSIS

Hyperkalemic periodic paralysis is characterized by episodes of muscle weakness due to depolarization of the muscle cell



membrane, associated with elevated serum potassium levels.<sup>7</sup> The attacks usually are induced by rest after heavy exercises; they can also be precipitated by exposure to cold or by general anesthesia.<sup>1</sup>

**Etiology.** The disease is transmitted in an autosomal dominant pattern and is caused by a mutation of the sodium channel gene on chromosome 17.<sup>5,12,13</sup>

**Clinical Features.** The paralytic attacks occur during the day. They are frequent and short, lasting 20 to 60 minutes. Rest following exercise induces paralysis; exercise accelerates recovery. The first muscles involved are the gluteals, lower erector spinae, quadriceps, and triceps surae. The paralysis gradually spreads to the musculature of the upper limbs. During severe attacks the neck muscles may be affected. The muscles innervated by the cranial nerves are occasionally involved. Bulbar and respiratory paralysis rarely occur. During the attacks, myotonia may be elicited by direct stimulation, and the deep tendon reflexes are diminished or absent. Cardiac arrhythmias are rare but can occur.<sup>9</sup> The attacks usually start in infancy and early childhood and decrease or disappear with age.

**Laboratory Findings.** During an attack, the serum potassium level will be markedly elevated as potassium is leached out of the muscle cells. The serum potassium level may reach 7.0 mEq/L, with a concomitant increase in urinary potassium levels.

**Treatment.** Mild to moderate episodes of hyperkalemic periodic paralysis do not require treatment. The frequency of the attacks can be reduced by administering diuretics that promote excretion of potassium and sodium. For patients intolerant of diuretic therapy,  $\beta$ -adrenergic agents (e.g., salbutamol) have been reported effective.<sup>2,10</sup> Dichlorophenamide usually is effective in preventing attacks. Severe episodes may require treatment with intravenous calcium gluconate.

## REFERENCES

### Metabolic Diseases of Muscle

1. Ashwood EM, Russell WJ, Burrow DD: Hyperkalemic periodic paralysis and anaesthesia. *Anaesthesia* 1992;47:579.
2. Bendheim PE, Reale EO, Berg BO: Beta-adrenergic treatment of hyperkalemic periodic paralysis. *Neurology* 1985;35:746.
3. Chang YC, Huang CC, Chiou YY, et al: Renal tubular acidosis complicated with hypokalemic periodic paralysis. *Pediatr Neurol* 1995;13:52.
4. De Keyser J, Slabbynck H, Laureys M, et al: Increase in serum myoglobin, creatine kinase, and free fatty acids, during recovery from a paralytic attack in hypokalemic periodic paralysis. *Clin Neurol Neurosurg* 1991;93:241.
5. Ebers GC, George AL, Barchi RL, et al: Paramyotonia congenita and hyperkalemic periodic paralysis are linked to the adult muscle sodium channel gene. *Ann Neurol* 1991;30:810.
6. Elbaz A, Vale-Santos J, Jurkat-Rott K, et al: Hypokalemic periodic paralysis and the dihydropyridine receptor (CACNL1A3): genotype/phenotype correlations for two predominant mutations and evidence for the absence of a founder effect in 16 caucasian families. *Am J Hum Genet* 1995;56:374.
7. Fontaine B, Khurana TS, Hoffman EP, et al: Hyperkalemic periodic paralysis and the adult muscle sodium channel alpha-subunit gene. *Science* 1990;250:1000.
8. Fontaine B, Vale-Santos J, Jurkat-Rott K, et al: Mapping of the hypokalemic periodic paralysis (HypoPP) locus to chromosome 1q31–32 in three European families. *Nat Genet* 1994;6:267.
9. Gould RJ, Steeg CN, Eastwood AB, et al: Potentially fatal cardiac

dysrhythmia and hyperkalemic periodic paralysis. *Neurology* 1985;35:1208.

10. Hanna MG, Stewart J, Schapira AH, et al: Salbutamol treatment in a patient with hyperkalaemic periodic paralysis due to a mutation in the skeletal muscle sodium channel gene (SCN4A). *J Neurol Neurosurg Psychiatry* 1998;65:248.
11. Jurkat-Rott K, Lehmann-Horn F, Elbaz A, et al: A calcium channel mutation causing hypokalemic periodic paralysis. *Hum Mol Genet* 1994;3:1415.
12. Kelly P, Yang WS, Costigan D, et al: Paramyotonia congenita and hyperkalemic periodic paralysis associated with a Met 1592 Val substitution in the skeletal muscle sodium channel alpha subunit: a large kindred with a novel phenotype. *Neuromuscul Disord* 1997;7:105.
13. Koch MC, Ricker K, Otto M, et al: Confirmation of linkage of hyperkalemic periodic paralysis to chromosome 17. *J Med Genet* 1991;28:583.
14. Lambert C, Blanloeil Y, Horber RK, et al: Malignant hyperthermia in a patient with hypokalemic periodic paralysis. *Anesth Analg* 1994;79:1012.
15. Lapie P, Lory P, Fontaine B: Hypokalemic periodic paralysis: an autosomal dominant muscle disorder caused by mutations in a voltage-gated calcium channel. *Neuromuscul Disord* 1997;7:234.
16. Links TP, Smit AJ, Molenaar WM, et al: Familial hypokalemic periodic paralysis: clinical, diagnostic and therapeutic aspects. *J Neurol Sci* 1994;122:33.
17. Links TP, Zwarts MJ, Oosterhuis HJ: Improvement of muscle strength in familial hypokalemic periodic paralysis with acetazolamide. *J Neurol Neurosurg Psychiatry* 1988;51:1142.
18. Links TP, Zwarts MJ, Wilmink JT, et al: Permanent muscle weakness in familial hypokalemic periodic paralysis: clinical, radiological and pathological aspects. *Brain* 1990;113:1873.
19. Miller JD, Quillian W, Cleveland WW: Nonfamilial hypokalemic periodic paralysis and thyrotoxicosis in a 16-year-old male. *Pediatrics* 1997;100:412.
20. Ober KP: Thyrotoxic periodic paralysis in the United States: report of 7 cases and review of the literature. *Medicine* 1992;71:109.
21. Ptacek LJ, Tawil R, Griggs RC, et al: Dihydropyridine receptor mutations cause hypokalemic periodic paralysis. *Cell* 1994;77:863.
22. Shayne P, Hart A: Thyrotoxic periodic paralysis terminated with intravenous propranolol. *Ann Emerg Med* 1994;24:736.
23. Stedwell RE, Allen KM, Binder LS: Hypokalemic paralyses: a review of the etiologies, pathophysiology, presentation, and therapy. *Am J Emerg Med* 1992;10:143.

## McArdle's Syndrome (Myophosphorylase Deficiency)

McArdle's syndrome is a rare disorder of muscle glycogen metabolism characterized by muscular pain, cramping, and weakness, and myoglobinuria following exercise. The symptoms are relieved by rest. The disease was first described by McArdle in 1951.<sup>7</sup> It is also known as glycogen storage disease type V.

The condition is transmitted by an autosomal recessive gene on chromosome 11.<sup>10</sup> The exact mutations within this gene have been described.<sup>11,12</sup>

The underlying pathophysiology of McArdle's syndrome is an absence in muscles of myophosphorylase, an enzyme that splits off the terminal glucose molecule from glycogen. As a result, glycogen cannot be metabolized to lactate. The absence of myophosphorylase can be established by histochemical staining of muscle. Muscle biopsy reveals abnormal accumulation of glycogen.<sup>3</sup> Laboratory tests show failure of blood lactate and pyruvate levels to rise following exercise. Myoglobinuria may be present in many cases. In about 90 percent of patients the diagnosis of McArdle's syndrome can be made from molecular genetic studies of a patient's leukocytes.<sup>9</sup>

Any muscle may be affected. In walking, the calf and



thigh muscles are involved; in chewing, the masseter muscles are affected. The muscles become stiff and remain so for varying lengths of time. The more strenuous the exercise, the more prolonged the symptoms. Muscular ischemia exacerbates the disease. Perfusion studies have demonstrated that patients with McArdle's syndrome do not have a normal increase in blood flow to the muscle with exercise.<sup>6</sup>

An association has been made between McArdle's syndrome and malignant hyperthermia.<sup>5</sup> Renal failure has occurred due to myoglobinuria.<sup>1,4</sup>

Treatment consists of limiting the patient's physical activity. Oral intake of glucose, or preferably fructose, prior to strenuous activity will increase tolerance for exercise.<sup>8</sup> The administration of vitamin B<sub>6</sub> may also enhance fatigue resistance.<sup>2</sup>

## REFERENCES

### McArdle's Syndrome (Myophosphorylase Deficiency)

1. Bank WJ, DiMauro S, Rowland LP: Renal failure in McArdle's disease (lack of muscle phosphorylase). *N Engl J Med* 1972;287:1102.
2. Beynon RJ, Bartram C, Hopkins P, et al: McArdle's disease: molecular genetics and metabolic consequences of the phenotype. *Muscle Nerve* 1995;3:S18.
3. Byard RW, Lach B, Preston DN: Peripheral nerve and vasculature involvement in myophosphorylase deficiency (McArdle's disease). *Pathology* 1991;23:62.
4. Grunfeld JP, Ganeval D, Chanard J, et al: Acute renal failure in McArdle's disease: report of two cases. *N Engl J Med* 1972;286:1237.
5. Issacs H, Badenhorst ME, Du Sautoy C: Myophosphorylase B deficiency and malignant hyperthermia. *Muscle Nerve* 1989;12:203.
6. Jehenson P, Leroy-Willig A, de Kerviler E, et al: Impairment of the exercise-induced increase in muscle perfusion in McArdle's disease. *Eur J Nucl Med* 1995;22:1256.
7. McArdle B: Myopathy due to a defect in muscle glycogen breakdown. *Clin Sci* 1951;10:13.
8. Opie LH, Evans JR, Renold AE: Fructose in McArdle's syndrome. *Lancet* 1962;2:358.
9. el-Schahawi M, Tsugino S, Shanske S, et al: Diagnosis of McArdle's disease by molecular genetic analysis of blood. *Neurology* 1996;47:579.
10. Tsujino S, Shanske S, Di Mauro S: Molecular genetic heterogeneity of myophosphorylase deficiency (McArdle's disease). *N Engl J Med* 1993;329:241.
11. Tsujino S, Shanske S, Nonaka I, et al: The molecular genetic basis of myophosphorylase deficiency (McArdle's disease). *Muscle Nerve* 1995;3:S23.
12. Vorgerd M, Kubish C, Burwinkel B, et al: Mutation analysis in myophosphorylase deficiency (McArdle's disease). *Ann Neurol* 1998;43:326.

## Idiopathic Paroxysmal Myoglobinuria

Idiopathic paroxysmal myoglobinuria, first described in 1911,<sup>10</sup> is characterized by recurrent, transient acute attacks of severe pain and cramping in the muscles, with associated weakness or paralysis.<sup>1-5,7,8,11,14,15</sup> Myoglobinuria occurs within a few hours after an attack.

The muscles of the lower limbs are more frequently affected. With rest, the attack subsides within a few days. In severe cases, oliguria and anuria may be present secondary to renal damage from myoglobin.<sup>6,9,12,13</sup>

There are two types of paroxysmal myoglobinuria. In the first type, the episodes occur primarily in childhood, often following an acute infectious disease. The attacks are fre-

quently accompanied by fever, leukocytosis, and renal insufficiency. Familial incidence is low. In the second type, symptoms usually occur between the second and third decades of life. The episodes are induced by exercise. Recurrent severe attacks may result in permanent muscle atrophy. There is a high familial incidence of this type.

Patients are treated symptomatically, with rest and alkalization of the urine. Renal function should be carefully monitored, as uremia and death may occur in the childhood form of the disease.

## REFERENCES

### Idiopathic Paroxysmal Myoglobinuria

1. Bailie MD: Primary paroxysmal myoglobinuria. *N Engl J Med* 1964;271:186.
2. Berenbaum MC, Birch CA, Moreland JD: Paroxysmal myoglobinuria. *Lancet* 1955;1:892.
3. Borolan TV, Attwoods GR: Myoglobinuria. *J Pediatr* 1965;67:69.
4. Buchanan D, Steiner PR: Myoglobinuria with paralysis (Meyer-Betz disease). *Arch Neurol Psychiatry* 1951;66:107.
5. Comings DE, Rosenfeld H: Idiopathic paroxysmal myoglobinuria. *Ann Intern Med* 1967;55:647.
6. de Langen CD: Myoglobin and myoglobinuria. *Acta Med Scand* 1946;124:213.
7. Gillett RL: Primary myoglobinuria. *N Engl J Med* 1959;260:1156.
8. Korein J, Coddon DR, Mowrey FH: The clinical syndrome of paroxysmal paralytic myoglobinuria. *Neurology* 1959;9:767.
9. Lee T, Goodley EL: Myoglobinuria and renal failure with myopathy. *Pa Med* 1971;74:56.
10. Meyer-Betz F: Beobachtungen an einem eigenartigen mit Muskellähmungen verbundenem Fall von Hämoglobinurie. *Dtsch Arch Klin Med* 1911;101:85.
11. Pearson CM, Beck WS, Bland WH: Idiopathic paroxysmal myoglobinuria: detailed study of a case including radioisotope and serum enzyme evaluation. *Arch Intern Med* 1957;99:367.
12. Schaar FE, LaBree JW, Gleason DF: Paroxysmal myoglobinuria with fatal renal tubular injury. *Cent Soc Clin Res Proc* 1949;22:71.
13. Tavill AS, Evanson JM, Baker SB, et al: Idiopathic paroxysmal myoglobinuria with acute renal failure and hypercalcemia. *N Engl J Med* 1964;271:283.
14. Wheby MS, Miller HS Jr: Idiopathic paroxysmal myoglobinuria. *Am J Med* 1960;29:599.
15. Whisnant CL Jr, Owings RH, Cantell GG, et al: Primary idiopathic myoglobinuria. *Ann Intern Med* 1959;51:141.

## Polymyositis and Dermatomyositis

Juvenile dermatomyositis/polymyositis (JDMS/PM) are childhood inflammatory myopathies that usually affect children between 2 and 15 years of age. The diseases manifest as severe proximal muscle weakness, and, in JDMS, there is a characteristic cutaneous rash. In the United Kingdom and Ireland, an estimated 1.9 million children under 16 years of age are affected with JDMS.<sup>21</sup> The mean age at diagnosis is 6.8 years. Girls are affected five times more frequently than boys.<sup>21</sup> About one-sixth of the cases of polymyositis occur in children.

## ETIOLOGY

In polymyositis and dermatomyositis, humoral and cellular immune functions are disrupted, with research suggesting an underlying disturbance in immunoregulation.<sup>10</sup> Most intriguing is evidence of a viral agent that is capable of precipitating an ongoing, immunologically mediated reaction that



damages muscles and endothelial cells.<sup>18</sup> However, there is no concrete evidence of viral invasion of muscle in these conditions.<sup>10</sup> The current theory about the pathogenesis of dermatomyositis is that the condition involves humorally mediated (i.e., autoimmune) microangiopathies, leading to muscle ischemia and necrosis.<sup>1</sup>

There is a strong association between polymyositis and neoplasm in adults, but childhood polymyositis is very rarely a paraneoplastic phenomena.<sup>20</sup> Polymyositis is a rarely reported complication of chronic graft-versus-host disease (GVHD). Polymyositis associated with chronic GVHD does not affect the overall prognosis of the patient. In addition, polymyositis may be the only manifestation of chronic GVHD.<sup>14</sup>

## **PATHOLOGY**

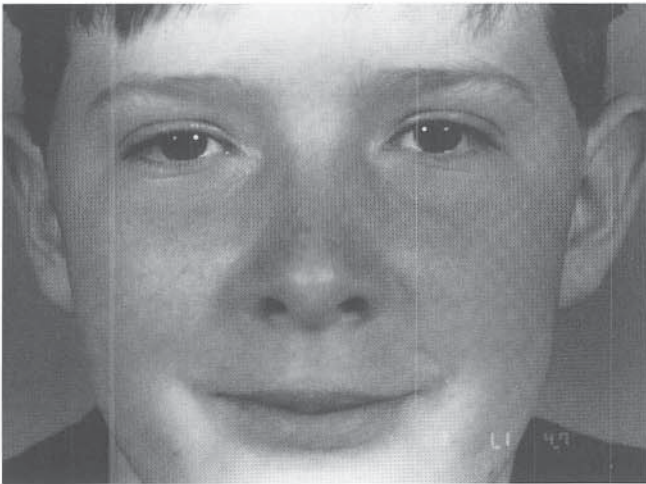Muscle biopsy sites must be carefully selected. The muscle chosen should not be markedly weakened and atrophic, nor

should it be of normal strength. Microscopic examination of biopsy specimens reveals widespread degeneration of muscle fibers with some regeneration present, perivascular collections of chronic inflammatory cells, and phagocytosis of necrotic muscle fibers.<sup>5</sup> Vasculopathy with hyperplasia of the intima of the arteries and veins may be present in dermatomyositis.<sup>1</sup>

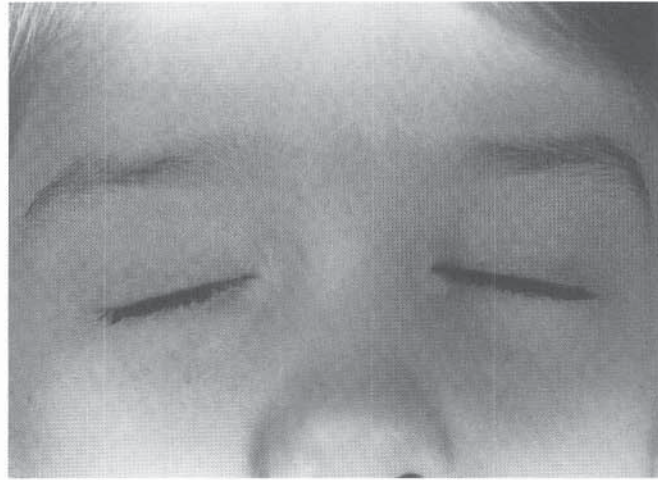## **CLINICAL FEATURES**

Polymyositis is a kaleidoscopic disease with great diversity in its symptoms and variable modes of onset and rate of progression, with exacerbations and remissions.

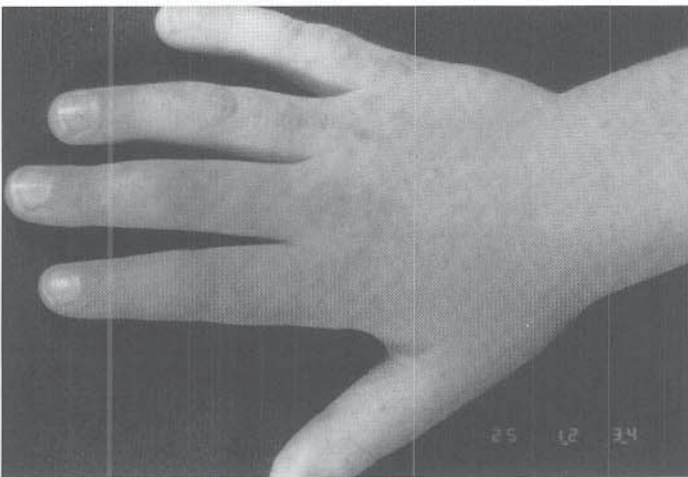
Dermatomyositis in children may have a sudden onset and acute course or may have an insidious beginning and follow a chronic course. Febrile illness is frequently present before dermatomyositis (and polymyositis) is. Exposure to sunlight may exacerbate the rash associated with dermatomyositis.



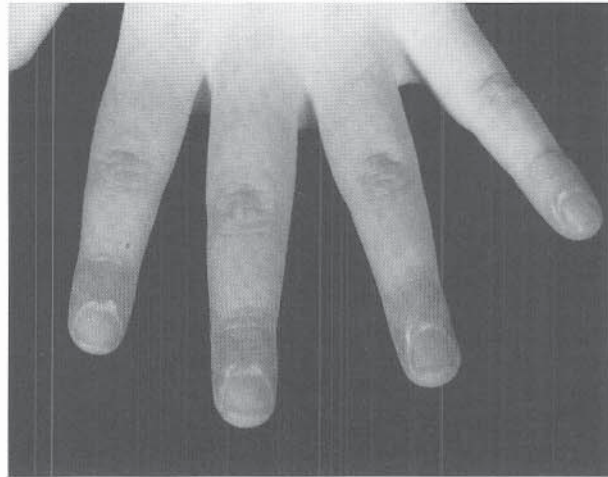
A



B



C



D

**FIGURE 28–15** Characteristic skin changes in dermatomyositis. **A**, Rash consisting of a dusky or faint erythema over the bridge of the nose and malar areas in a butterfly distribution. **B**, Dark iliac (purple) discoloration of the upper eyelids (heliotrope eyelids). **C**, Scaly lesions over the knuckles of the hand (Gottron's sign). **D**, Hyperemia at the base of the fingernails. The skin of the fingertips is shiny, red, and atrophic.



The presenting complaint is muscle weakness. Weakness is first noted in the proximal musculature of the pelvic and shoulder girdles. Patients have difficulty rising from the floor and climbing stairs. The affected muscles become tender and brawny. Pain is most common in the shoulders, upper back, arms, and thighs. As the disease progresses, shoulder abduction becomes difficult. If the sternocleidomastoid muscle is involved, the patient cannot lift her head up from the bed when in the supine position. Involvement of the pharyngeal muscles may cause dysphagia and difficulty in eating. If the muscle weakness spreads, the patient may lose the ability to walk or sit. Progressive involvement may lead to death, but this is an uncommon occurrence.

Skin changes in dermatomyositis are characteristic. There is a rash consisting of a dusky or faint erythema over the bridge of the nose and the malar areas in a butterfly distribution (Fig. 28–15A). A dark lilac (purple) discoloration of the upper eyelids (called heliotrope eyelids) is pathognomonic for dermatomyositis (Fig. 28–15B). The periorbital rash may spread to the neck and upper chest. The extensor surfaces of the elbows, knees, and metacarpophalangeal joints and the area over the medial malleoli become erythematous, atrophic, and scaly. Scaly lesions over the knuckles of the hand are termed Gottron's sign (Fig. 28–15C). A flat, erythematous rash can appear on the face, neck, shoulders, and back (shawl sign). There may be hyperemia at the base of the fingernails, and the skin of the fingertips may be shiny, red, and atrophic (Fig. 28–15D). Nonpitting edema develops in the acute stage of the disease. During the chronic stage, the skin becomes atrophic and adherent to underlying structures.

Calcium deposits may develop in the subcutaneous tissues, muscles, and fasciae, and can be quite problematic as motion is lost (Fig. 28–16).<sup>12</sup> Subcutaneous calcification is more common in children, occurring in 30 to 70 percent of patients with pediatric dermatomyositis.<sup>2</sup> In severe cases, ulceration of the skin overlying such deposits may occur (Fig. 28–17).

Synovitis of the knees, wrists, and small joints of the

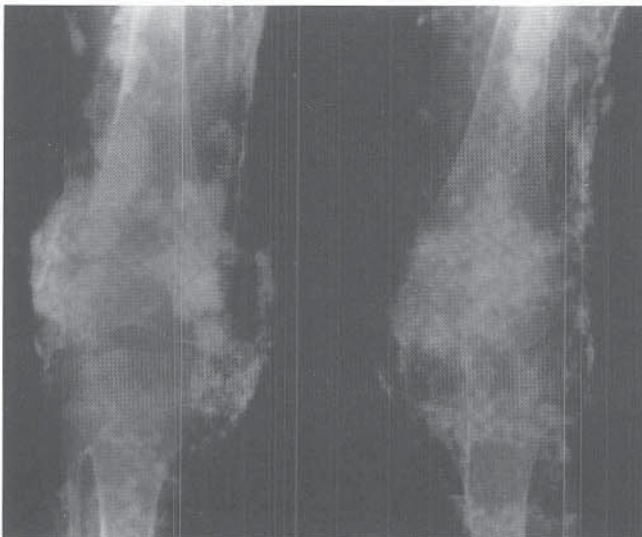


FIGURE 28–16 Ectopic calcification of the knee in a patient with dermatomyositis.

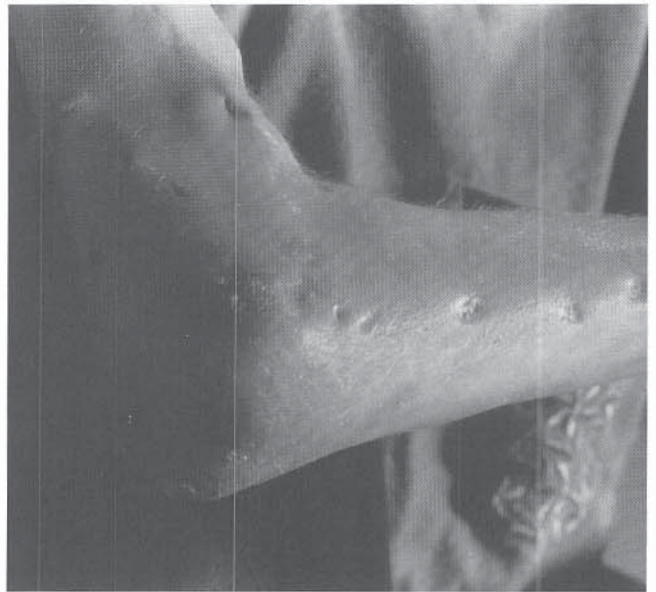


FIGURE 28–17 Multiple ulcerations around the elbow of a child with subcutaneous calcification secondary to dermatomyositis.

fingers occurs in about 40 percent of patients. In a minority of cases the synovitis precedes the onset of muscle weakness. Raynaud's phenomenon—blanching or cyanosis of the fingers on exposure to cold—may also be present.

Systemic effects of dermatomyositis are common. There may be associated pneumonitis, myocarditis or pericarditis, nephritis, or gastrointestinal ischemia. Interstitial lung disease can occur in children and manifests as a cough or dyspnea.<sup>2</sup>

## LABORATORY FINDINGS

In acute polymyositis, there is marked elevation in serum levels of CK, aldolase, and glutamic and pyruvic transaminases. CK levels may be up to 50 times the normal value.<sup>9</sup> The laboratory findings are similar to those seen in muscular dystrophy. As with muscular dystrophy, the laboratory values decrease as the muscle is replaced by fibrous tissue. The erythrocyte sedimentation rate (ESR) is elevated in polymyositis and dermatomyositis.

Rheumatoid factor and antinuclear antibodies are sometimes present, but lupus erythematosus cells are usually absent. Myositis-specific autoantibodies may be detected in some patients, but the clinical significance of their presence remains under investigation.<sup>2</sup> Identification of these autoantibodies may prove useful in classifying the type of inflammatory myopathy present.<sup>17</sup>

## ELECTROMYOGRAPHY

EMG findings include (1) spontaneous fibrillation and positive or sawtooth potentials at complete rest or after mild mechanical irritation, (2) complex polyphasic or short-duration potentials of low amplitude with voluntary contraction, and (3) salvos of repetitive potentials of high frequency occurring after mechanical stimulation. These EMG changes are characteristic of polymyositis but are not absolutely specific for the condition.<sup>15</sup>



## DIAGNOSIS

The definitive diagnosis is often delayed, with a mean 4-month delay reported in a recent study.<sup>21</sup> The following are the criteria for the diagnosis of polymyositis and dermatomyositis: (1) symmetric, progressive weakness of the limb-girdle and sternocleidomastoid muscles; (2) histologic evidence of muscle necrosis in a perifascicular distribution, with perivascular inflammatory exudate on biopsy; (3) elevated serum CK levels; (4) EMG findings of small polyphasic motor units, fibrillation, and repetitive discharges; and (5) a skin rash on the face, neck, and extensor surface of the limbs.<sup>3,4</sup> In polymyositis the first four criteria must be present. In dermatomyositis the skin rash plus three other criteria are necessary for the diagnosis to be assigned.

In polymyositis a muscle biopsy is needed, whereas in dermatomyositis only a skin biopsy is necessary. Multiple percutaneous needle muscle biopsies are as effective as single-site open biopsies in establishing the diagnosis of polymyositis.<sup>8</sup>

Entities to be excluded when a diagnosis of polymyositis or dermatomyositis is entertained include muscular dystrophy, spinal muscular atrophy, hereditary metabolic myopathies such as McArdle's disease, myasthenia gravis, rhabdomyolysis, and inflammatory myopathies such as viral myositis and sarcoid myopathy.

## TREATMENT

In the acute stage of polymyositis and dermatomyositis, when the muscles are painful, tender, and edematous, the patient is placed on bedrest and moist heat is applied over the affected muscles as tolerated. Range-of-motion exercises are performed gently to preserve joint motion. Splints may be needed if contractures develop.

Medical treatment of polymyositis and dermatomyositis consists of immunosuppressant therapy, beginning with corticosteroids.<sup>24</sup> Prednisone is used to diminish the acute inflammatory reaction and thus relieve pain. Serum CK levels are monitored to follow therapeutic response. The return of CK levels to normal may be a favorable prognostic sign. For patients who do not respond to corticosteroids, more potentially toxic immunosuppressant medications are used to control the disease. Methotrexate, azathioprine, cyclosporin A, and intravenous immune globulin (IVIG) have been reported to be useful in some patients.<sup>2,7,11,16,17</sup>

Plasmapheresis and thymectomy<sup>13,19</sup> have also been performed occasionally to treat polymyositis and dermatomyositis.

In the later stages of the disease, excision of mature intramuscular calcification can improve mobility and muscle function.<sup>22</sup> Calcification may recur postoperatively.

## OUTCOME

The results from a number of long-term follow-up studies have been reported. In a 10-year follow-up, Collison and associates found that 58 percent of patients had at least one residual finding on physical examination and that 78 percent of those with JDMS had residual dermatologic sequelae.<sup>6</sup> In a study of 33 patients with JDMS/PM, 45 percent showed complete recovery, 26 percent had remission (steroid depen-

dency), 10 percent developed other connective tissue diseases, 6 percent were wheelchair-dependent, and 3 percent had died at a mean follow-up of 4 years.<sup>23</sup> In that study, patients with the highest CK levels had the worst outcomes. Patients with positive ANA assays were most likely to develop other connective tissue diseases.

## REFERENCES

### Polymyositis and Dermatomyositis

- Adams RD, Denny-Brown D, Pearson CM: Diseases of Muscle, 2nd ed. New York, Harper & Row, 1962.
- Amato AA, Barohn RJ: Idiopathic inflammatory myopathies. *Neurol Clin* 1997;15:615.
- Bohan A, Peter JB: Polymyositis and dermatomyositis. *N Engl J Med* 1975;292:344.
- Bohan A, Peter JB, Bowman RL, et al: A computer-assisted analysis of 153 patients with polymyositis and dermatomyositis. *Medicine* 1977;56:255.
- Carpenter S, Karpati G: The pathological diagnosis of specific inflammatory myopathies. *Brain Pathol* 1992;2:13.
- Collison CH, Sinal SH, Jorizzo JL, et al: Juvenile dermatomyositis and polymyositis: a follow-up study of long-term sequelae. *South Med J* 1998;91:17.
- Dalakas MC: Update on the use of intravenous immune globulin in the treatment of patients with inflammatory muscle disease. *J Clin Immunol* 1995;15(suppl 6):70S.
- Haddad MG, West RL, Treadwell EL, et al: Diagnosis of inflammatory myopathy by percutaneous needle biopsy with demonstration of the focal nature of myositis. *Am J Clin Pathol* 1994;101:661.
- Lundberg I, Ulfgren AK, Nyberg P, et al: Cytokine production in muscle tissue of patients with idiopathic inflammatory myopathies. *Arthritis Rheum* 1997;40:865.
- Mastaglia FL, Ojeda VJ: Inflammatory myopathies. Part 1. *Ann Neurol* 1985;17:215.
- Mastaglia FL, Phillips BA, Zilko P: Treatment of inflammatory myopathies. *Muscle Nerve* 1997;20:651.
- Maugars YM, Berthelot JM, Abbas AA, et al: Long-term prognosis of 69 patients with dermatomyositis or polymyositis. *Clin Exp Rheumatol* 1996;14:263.
- Oddis CV: Therapy for myositis. *Curr Opin Rheumatol* 1991;3:919.
- Parker P, Chao NJ, Ben-Ezra J, et al: Polymyositis as a manifestation of chronic graft-versus-host disease. *Medicine* 1996;75:279.
- Pearson CM: Polymyositis and related disorders. In Walton JN (ed): *Disorders of Voluntary Muscle*, p 305. Boston, Little, Brown, 1964.
- Pistoia V, Buoncompagni A, Scribanis R, et al: Cyclosporin A in the treatment of juvenile chronic arthritis and childhood polymyositis-dermatomyositis: results of a preliminary study. *Clin Exp Rheumatol* 1993;11:203.
- Rider LG, Miller FW: Classification and treatment of the juvenile idiopathic inflammatory myopathies. *Rheum Dis Clin North Am* 1997;23:619.
- Roberts LJ, Fink CW: Childhood polymyositis/dermatomyositis. *Clin Dermatol* 1988;6:36.
- Seggia JC, Abrue P: Plasmapheresis in neurology: critical analysis of indications and protocols. *Arq Neuropsiquiatr* 1992;50:324.
- Sherry DD, Haas JE, Milstein JM: Childhood polymyositis as a paraneoplastic phenomenon. *Pediatr Neurol* 1993;9:155.
- Symmons DP, Sills JA, Davis SM: The incidence of juvenile dermatomyositis: results from a nation-wide study. *Br J Rheumatol* 1995;34:732.
- Tachdjian MO: The neuromuscular system: polymyositis and dermatomyositis. In Tachdjian MO (ed): *Tachdjian's Pediatric Orthopaedics*, 2nd ed, p 2164. Philadelphia, WB Saunders Co, 1990.
- Van Rossum MA, Hiemstra I, Prieur AM, et al: Juvenile dermatomyositis: a retrospective analysis of 33 cases with special focus on initial CPK levels. *Clin Exp Rheumatol* 1994;12:339.
- Yoshioka M, Okuno T, Mikawa H: Prognosis and treatment of polymyositis with particular reference to steroid resistant patients. *Arch Dis Child* 1985;60:236.



## Pyomyositis (Suppurative Myositis)

Pyomyositis is rare because normal muscle is resistant to bacterial infection, owing to muscle's excellent vascular supply. Usually, pyomyositis occurs in patients with severe septicemia or patients who are immunocompromised. Patients with HIV infection are at significant risk of pyomyositis.<sup>2,4,8,12,15</sup> The bacterial infection has also been reported in children following chickenpox and in patients with sickle cell anemia or diabetes mellitus.<sup>1,3</sup> Pyomyositis is more common in males than in females. The disease occurs more frequently in tropical areas of the world,<sup>13</sup> but its incidence in North America appears to be increasing.

### ETIOLOGY

The most common organism to be cultured in pyomyositis is *Staphylococcus aureus*.<sup>10</sup> Penicillin-resistant strains are common.<sup>6</sup>

### CLINICAL FEATURES

The quadriceps, iliopsoas, and other large muscles are commonly involved.<sup>10</sup> Clinically, the patient presents with pain and fever. Localized tenderness and pain on motion are present. Local fluctuation is a late sign. If the iliopsoas or adductor muscles are involved, the symptoms and signs may mimic those of a septic hip.<sup>5,7,20</sup> The clinical presentation may be indolent in patients with HIV infection.<sup>19</sup>

### LABORATORY FINDINGS

Laboratory findings include an elevated white blood cell (WBC) count, ESR, and C-reactive protein level. However, these indices may not be elevated in immunosuppressed patients. In advanced cases, serum CK levels may be elevated from muscle necrosis.<sup>11</sup>

### IMAGING STUDIES

Imaging studies can be very helpful in making the correct diagnosis. Findings on CT include muscle enlargement with heterogeneous attenuation, and the presence of a focal fluid collection with rim enhancement. MRI shows a focal fluid collection of high signal intensity and a hypointense rim on T2-weighted images.<sup>9</sup> Fluid collections may be demonstrated on ultrasound as well.<sup>14,18</sup>

### DIFFERENTIAL DIAGNOSIS

Entities to be distinguished from pyomyositis include osteomyelitis, septic arthritis, cellulitis, and soft tissue sarcoma.<sup>16</sup> If septic arthritis of the hip is ruled out after arthrocentesis, pyomyositis should be considered. In young children, most abscesses in the muscles are, in reality, osteomyelitis that has decompressed through the cortex of the bony metaphysis into the soft tissue. Bony involvement must be looked for on radiographs, on bone scans (when needed), and in surgery during incision and drainage of the soft tissue abscess. In adults, the symptoms of pyomyositis may mimic those of deep vein thrombosis.<sup>21</sup> Pyomyositis of the iliopsoas can simulate acute appendicitis.<sup>22</sup>

### TREATMENT

Treatment of pyomyositis entails intravenous antibiotic therapy and, in nearly all cases, surgical incision and drainage.<sup>10</sup> Because multiple abscesses may be present, it is critical to make the diagnosis of multifocal pyomyositis preoperatively so that all fluid collections can be drained.<sup>17</sup>

### REFERENCES

#### Pyomyositis (Suppurative Myositis)

1. Akman I, Ostrov B, Varma BK, et al: Pyomyositis: report of three patients and review of the literature. *Clin Pediatr* 1996;35:397.
2. Ansaloni L, Acaye GL, Re MC: High HIV seroprevalence among patients with pyomyositis in northern Uganda. *Trop Med Int Health* 1996;1:210.
3. Armstrong DG, D'Amato CR, Strong ML: Three cases of staphylococcal pyomyositis in adolescence, including one patient with neurologic compromise. *J Pediatr Orthop* 1993;13:452.
4. Blumberg HM, Stephens DS: Pyomyositis and human immunodeficiency virus infection. *South Med J* 1990;83:1092.
5. Chen W-S, Wan Y-L: Iliacus pyomyositis mimicking septic arthritis of the hip joint. *Arch Orthop Trauma Surg* 1996;115:233.
6. Cherian T, Pereira SM: Pyomyositis in south Indian children. *Ann Trop Paediatr* 1987;7:190.
7. De Boeck H, Noppen L, Desprechins B: Pyomyositis of the adductor muscles mimicking an infection of the hip: diagnosis by magnetic resonance imaging. A case report. *J Bone Joint Surg* 1994;76-A:747.
8. Gardiner JS, Zauk AM, Minnefor AB, et al: Pyomyositis in an HIV-positive premature infant: case report and review of the literature. *J Pediatr Orthop* 1990;10:791.
9. Gordon BA, Martinez S, Collins AJ: Pyomyositis: characteristics at CT and MRI imaging. *Radiology* 1995;197:279.
10. Hall RL, Callaghan JJ, Moloney E, et al: Pyomyositis in a temperate climate: presentation, diagnosis, and treatment. *J Bone Joint Surg* 1990;72-A:1240.
11. Kuyucu N, Dogru U, Uysal G: Disseminated pyomyositis with high creatine phosphokinase levels. *J Paediatr Child Health* 1997;33:262.
12. Medina F, Fluente M, Jara LJ, et al: Salmonella pyomyositis in patients with the human immunodeficiency virus. *Br J Rheumatol* 1995;34:568.
13. Pretorius ES, Hruban RH, Fishman EK: Tropical pyomyositis: imaging findings and a review of the literature. *Skeletal Radiol* 1996;25:576.
14. Quillin SP, McAlister WH: Rapidly progressive pyomyositis: diagnosis by repeat sonography. *J Ultrasound Med* 1991;10:181.
15. Raphael SA, Wolfson BJ, Parker P, et al: Pyomyositis in a child with acquired immunodeficiency syndrome: patient report and brief review. *Am J Dis Child* 1989;143:779.
16. Reid SE Jr, Nambisan R, Karakousis CP: Pyomyositis: a differential diagnosis from sarcoma. *J Surg Oncol* 1985;29:143.
17. Renwick SE, Ritterbusch JF: Pyomyositis in children. *J Pediatr Orthop* 1993;13:769.
18. Royston DD, Cremin BJ: The ultrasonic evaluation of psoas abscess (tropical pyomyositis) in children. *Pediatr Radiol* 1994;24:481.
19. Schwartzman WA, Lambertus MW, Kennedy CA, et al: Staphylococcal pyomyositis in patients infected by the human immunodeficiency virus. *Am J Med* 1991;90:595.
20. Singer J: Neonatal psoas pyomyositis simulating pyarthrosis of the hip. *Pediatr Emerg Care* 1993;9:87.
21. Wang KC, Fang CM, Chen WJ, et al: Pyomyositis of the calf muscles mimicking distal deep venous thrombosis: a case report. *Am J Orthop* 1997;26:358.
22. Wysoki MG, Angeid-Backman E, Izes BA: Iliopsoas myositis mimicking appendicitis: MRI diagnosis. *Skeletal Radiol* 1997;26:316.

## Myositis Ossificans (Myositis Ossificans Circumscripta)

Myositis ossificans is characterized by heterotopic calcification and ossification in muscle tissue. Injury is an important factor in its pathogenesis.<sup>6</sup> The process most likely represents metaplasia of fibroblasts at the site of injury. When the



condition is not associated with a traumatic injury, the term *pseudomalignant myositis ossificans* has been applied.<sup>18,28</sup>

Myositis ossificans is most common in teenagers, but it also has been frequently described in younger children. There are a few, rare reports of the disorder occurring in infants and newborns.<sup>16,19,31</sup> Myositis ossificans has been described in association with child abuse.<sup>5</sup>

## CLASSIFICATION

The condition may be subdivided into three types. First, there is the traumatic myositis ossificans that follows a severe single injury, such as an elbow fracture or dislocation or extremity surgery.<sup>3,7</sup> Adolescent boys who sustain quadriceps contusions during football play may develop this posttraumatic form.<sup>21</sup> Seventy-five percent of patients with myositis ossificans report a history of trauma.<sup>30</sup> The second type of myositis ossificans develops as a result of repeated micro-trauma and overuse injuries. This type usually occurs in adolescents and young adults. An example is heterotopic bone formation in the soleus muscle in ballerinas. Finally, myositis ossificans can complicate the clinical course of severe neurologic disorders, such as Guillain-Barré syndrome,<sup>20</sup> AIDS encephalopathy,<sup>13</sup> and, more commonly, closed head injury.<sup>36</sup> In a comparison of traumatically brain-injured children and children with hypoxic brain injuries, those who had suffered hypoxia were more likely to develop myositis ossificans.<sup>17</sup> Myositis ossificans is likely to be much more extensive when it is associated with neurologic conditions. A history of discrete trauma may be absent in these patients.

## PATHOLOGY

The pathology of myositis ossificans is most notable for the presence of four histologic zones<sup>1</sup>: (1) a central, undifferentiated zone that is highly cellular, with mitotic figures and extreme variation in the size and shape of cells, (2) an adjacent zone in which there are well-oriented zones of cellular osteoid separated by loose cellular stroma, (3) a more peripheral zone showing new bone formation with osteoblasts and fibrous tissue undergoing trabecular organization, and (4) an outermost zone of well-oriented bone encapsulated by fibrous tissue.

Histologically, the lesion appears more benign at the periphery and very abnormal (with mitotic figures resembling osteosarcoma) in the center. This is distinctly different from an osteosarcoma, in which the periphery or leading edge of the tumor should not appear more organized with benign cellular characteristics. As the heterotopic bone matures, the involved area becomes smaller.

The lesions of myositis ossificans are white and glistening on gross appearance, and gritty in texture.<sup>18</sup> There may be compressed muscle around the lesion, but the mass is clearly delineated from the surrounding tissues.<sup>28</sup>

## CLINICAL FEATURES

Physical findings consist of tenderness over the affected area, palpable swelling, pain on range of motion, and stiffness. The limb may have increased warmth. It is not uncommon for the patient to have a fever.<sup>2</sup> If there is persistent local

discomfort and marked limitation of motion 3 weeks following a posterior dislocation of the elbow, myositis ossificans may be present. The pain and swelling of myositis ossificans may mimic an infection.<sup>2,26</sup>

## IMAGING STUDIES

Radiographs initially are normal, but by 10 days to 4 weeks, fine calcifications will be seen in the muscle, which are referred to as the “dotted veil appearance.”<sup>9,15</sup> Over time the calcification increases. Then the entire calcified mass appears to shrink in size and become more dense. The process is self-limiting, running a course varying from a few weeks to several months. There may be periosteal reaction present in the underlying bone, but there is no erosion of the bony cortex. The mass is separated from the underlying bone by at least a thin line.<sup>28</sup> The lesions are usually located in the diaphysis (Fig. 28–18).

A bone scan with technetium-99m will show increased uptake in the forming heterotopic bone. Abnormal uptake can be seen on the bone scan before plain films show calcification.<sup>37</sup> Thallium and gallium scintigraphy will also show abnormal uptake in myositis ossificans;<sup>29,34</sup> however, neither study can differentiate myositis ossificans from tumor.

Abnormal findings can also be seen on ultrasound before there are changes on plain films.<sup>32</sup> Calcification may first be noted on ultrasound. A focal, hypoechoic mass located within the muscle may be seen.<sup>23</sup>

The MRI characteristics of myositis ossificans have been

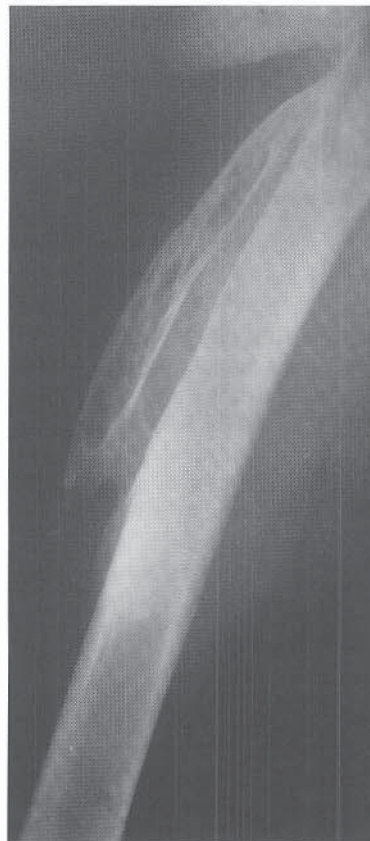

FIGURE 28–18 Posttraumatic myositis ossificans of the thigh. Note the mature bone at the periphery of the calcified lesion.



described. A low-signal-intensity rim is a common finding. Surrounding edema can be seen in relatively new lesions.<sup>24</sup> These patterns, though, are not unique to myositis ossificans and resemble those that have been reported in other lesions. The MRI appearance of the lesion changes with the acuity of the mass.<sup>12,24</sup> The use of gadolinium may be of help in differentiating myositis ossificans from osteogenic sarcoma.<sup>10</sup>

CT scans of myositis ossificans can clearly delineate the peripheral ossification and central lucency of the masses.<sup>4</sup> Separation of the lesion from the underlying bone is best seen on CT. If the lesion is in continuity with the bone, it is not myositis ossificans, and the possibility of tumor or infection arises.

## DIFFERENTIAL DIAGNOSIS

Myositis ossificans must be distinguished from infections, such as osteomyelitis or soft tissue abscess, and from tumors, such as osteogenic sarcoma, parosteal osteosarcoma, and rhabdomyosarcoma.<sup>4,14</sup> The correct diagnosis can usually be made from imaging studies. When the surgeon believes that the lesion is most likely myositis ossificans, serial radiographs can be obtained to follow the evolution and maturation of the mass.

In equivocal cases, biopsy may be necessary to document the different zones of histology associated with myositis ossificans. Although fine-needle biopsy has been successful in establishing the diagnosis of myositis ossificans,<sup>11,25,33</sup> extreme care must be taken in interpreting the results, because such biopsies do not procure enough histologic specimen to demonstrate the zonal architecture of the mass.<sup>22,27,28,39</sup> The histologic findings in a single biopsy specimen taken from the center of the myositis ossificans lesion can strongly resemble the findings of osteosarcoma. Unnecessary ablative surgery, such as amputations, have been performed in cases of myositis ossificans after an incorrect diagnosis was made.<sup>28</sup>

## TREATMENT

Treatment should be conservative. Nonsteroidal anti-inflammatory medication can control pain. Any physical therapy should be discontinued, as persistent passive stretching to regain motion will exacerbate the myositis. Relative rest of the affected extremity is helpful, with motion and activity gradually resumed as the acute phase subsides. Radiation should be avoided in children.

Jackson and Feagin proposed a three-phase treatment plan for patients at risk for myositis ossificans of the quadriceps following thigh contusion.<sup>21</sup> The first phase consists of limiting motion and icing the extremity while avoiding heat or massage. When quadriceps control is regained, phase II begins, with the patient encouraged to do knee extensions and slowly regain flexion. The third phase starts when the patient has 90 degrees of motion and consists of progressive resistance exercises and noncontact sports.

Spontaneous resolution of myositis ossificans has been reported in up to 38 percent of lesions.<sup>28,35,38</sup> Routine surgery is not necessary to remove the calcified lesion.<sup>8</sup> Once the process has matured, symptomatic masses can be excised if they are painful or interfere with motion. Recurrence of the calcification may occur. Surgery is not performed until a

year or so after the acute stage of the disease, at a time when radiographs reveal that the heterotopic bone is fully mature and bone scans show either a return to normal uptake or decreasing activity in the lesion.

## REFERENCES

### Myositis Ossificans (Myositis Ossificans Circumscripta)

- Ackerman LV: Extra-osseous localized non-neoplastic bone and cartilage formation (so-called myositis ossificans): clinical and pathological confusion with malignant neoplasms. *J Bone Joint Surg* 1958;40-A:279.
- Adderson EE, Bohnsack JF: Traumatic myositis ossificans simulating soft tissue infection. *Pediatr Infect Dis J* 1996;15:551.
- Akgun I, Erdogan F, Aydingoz O, et al: Myositis ossificans in early childhood. *Arthroscopy* 1998;14:522.
- Amendola MA, Galzer GM, Agha FP, et al: Myositis ossificans circumscripta: computed tomographic diagnosis. *Radiology* 1983;149:775.
- Ben-Youssef L, Schmidt TL: Battered child syndrome simulating myositis. *J Pediatr Orthop* 1983;3:392.
- Best TM: Muscle-tendon injuries in young athletes. *Clin Sports Med* 1995;14:669.
- Booth DW, Westers BM: The management of athletes with myositis ossificans traumatica. *Can J Sport Sci* 1989;14:10.
- Carlson WO, Kalssen RA: Myositis ossificans of the upper extremity: a long-term follow-up. *J Pediatr Orthop* 1984;4:693.
- Cushman FD, Morwessel RM: Myositis ossificans in children. *Orthopedics* 1995;18:287.
- Cvitanic O, Sedlak J: Acute myositis ossificans. *Skeletal Radiol* 1995; 24:139.
- De Almeida MM, Abecassis N, Almeida MO, et al: Fine-needle aspiration cytology of myositis ossificans: a case report. *Diagn Cytopathol* 1994;10:41.
- De Smet AA, Norris MA, Fisher DR: Magnetic resonance imaging of myositis ossificans: analysis of seven cases. *Skeletal Radiol* 1992;21:503.
- Drane WE, Tipler BM: Heterotopic ossification (myositis ossificans) in acquired immune deficiency syndrome: detection by gallium scintigraphy. *Clin Nucl Med* 1987;12:433.
- Gebhardt MC, Ready JE, Mankin HJ: Tumors about the knee in children. *Clin Orthop* 1990;255:86.
- Geschickter CF, Maseritz IH: Myositis ossificans. *J Bone Joint Surg* 1938;20:661.
- Heifetz SA, Galliani CA, De Rosa GP: Myositis (fasciitis) ossificans in an infant. *Pediatr Pathol* 1992;12:223.
- Heindl UT, Laub MC: Outcome of persistent vegetative state following hypoxic or traumatic brain injury in children and adolescents. *Neuropediatrics* 1996;27:94.
- Heinrich SD, Zembo MM, MacEwen GD: Pseudomalignant myositis ossificans. *Orthopedics* 1989;12:599.
- Howard CB, Porat S, Bar-On E, et al: Traumatic myositis ossificans of the quadriceps in infants. *J Pediatr Orthop B* 1998;7:80.
- Hung JC, Appleton RE, Abernethy L: Myositis ossificans complicating severe Guillain-Barré syndrome. *Dev Med Child Neurol* 1997;39:775.
- Jackson DW, Feagin JA: Quadriceps contusion in young athletes: relation of severity of injury to treatment and prognosis. *J Bone Joint Surg* 1973;55-A:95.
- Jouve JL, Cottalorda J, Bollini G, et al: Myositis ossificans: report of seven cases in children. *J Pediatr Orthop B* 1997;6:33.
- Kirkpatrick JS, Koman LA, Rovere GD: The role of ultrasound in the early diagnosis of myositis ossificans: a case report. *Am J Sports Med* 1987;15:179.
- Kransdorf MJ, Meis JM, Jelinek JS: Myositis ossificans: MR appearance with radiologic-pathologic correlation. *AJR Am J Roentgenol* 1991; 157:1243.
- Layfield LJ, Anders KH, Glasgow BJ, et al: Fine-needle aspiration of primary soft-tissue lesions. *Arch Pathol Lab Med* 1986;110:420.
- Merkow SJ, St Clair HS, Goldberg MJ: Myositis ossificans masquerading as sepsis. *J Pediatr Orthop* 1985;5:601.
- Nuovo MA, Norman A, Chumas J, et al: Myositis ossificans with atypical clinical, radiographic, or pathologic findings: a review of 23 cases. *Skeletal Radiol* 1992;21:87.
- Ogilvie-Harris DJ, Fornasier VL: Pseudomalignant myositis ossificans: heterotopic new-bone formation without a history of trauma. *J Bone Joint Surg* 1980;69-A:1274.



29. Osmanagaoglu K, Kuyvenhoven J, Dierckx RA, et al: Thallium-201 accumulation in myositis ossificans and in juxta-articular ossification. *J Nucl Med* 1995;36:2239.
30. Paterson DC: Myositis ossificans circumscripta: report of four cases without history of injury. *J Bone Joint Surg* 1970;52-B:296.
31. Pazzaglia UE, Beluffi G, Colombo A, et al: Myositis ossificans in the newborn. *J Bone Joint Surg* 1986;68-A:456.
32. Peck RJ, Metreweli C: Early myositis ossificans: a new echographic sign. *Clin Radiol* 1988;39:586.
33. Rooser B, Herrlin K, Rydholm A, et al: Pseudomalignant myositis ossificans: clinical, radiologic, and cytologic diagnosis in 5 cases. *Acta Orthop Scand* 1989;60:457.
34. Salzman L, Lee VW, Grant P: Gallium uptake in myositis ossificans: potential pitfalls in diagnosis. *Clin Nucl Med* 1987;12:308.
35. Spencer JD, Missen GA: Pseudomalignant heterotopic ossification ("myositis ossificans"): recurrence after excision with subsequent re-ossification. *J Bone Joint Surg* 1989;71-B:317.
36. Spencer RF: The effect of head injury on fracture healing: a quantitative assessment. *J Bone Joint Surg* 1987;69-B:525.
37. Suzuki Y, Hisada K, Takeda M: Demonstration of myositis ossificans by <sup>99m</sup>Tc pyrophosphate bone scanning. *Radiology* 1974;111:663.
38. Thorndike A: Myositis ossificans traumatica. *J Bone Joint Surg* 1940; 22:315.
39. Wakely PE Jr, Almeida M, Frable WJ: Fine-needle aspiration biopsy cytology of myositis ossificans. *Mod Pathol* 1994;7:23.

## Idiopathic Fibrosis of Muscles (Progressive Fibrosis of the Quadriceps)

Progressive fibrosis of the quadriceps muscle is a condition in which extension contracture of the knee develops in early childhood due to fibrosis of one or more components of the quadriceps muscle. The condition is more common in girls than in boys.

### ETIOLOGY

The exact cause of progressive fibrosis of the quadriceps is not known. Gunn first proposed the etiology of quadriceps fibrosis as a sequela of multiple injections of antibiotics into the thigh muscles during early infancy.<sup>5</sup> This possible cause has been reported by others.<sup>3,13,15</sup> Nearly all affected children have a history of serious illness during early infancy.<sup>13</sup> Similar fibrotic changes with contractures have been seen in the gluteal muscles and deltoid muscle following intramuscular injections.<sup>4,7,9,11</sup> Fibrosis in the gluteus maximus causes abduction-extension contractures of the hips, while deltoid fibrosis results in abduction contractures of the shoulder with scapular winging.

### PATHOPHYSIOLOGY

The pathophysiology of progressive fibrosis is speculative. It has been proposed that the volume of drug injected in very young babies compresses the capillaries and muscle fibers, causing muscle ischemia which leads to fibrotic changes. Local necrosis may occur as a result of focal disruption of fibers at the site of injection. The irritative nature of the injected drug may also play a role in producing fibrosis.<sup>6</sup>

### CLINICAL FEATURES

The clinical hallmark of progressive fibrosis of the quadriceps is painless, progressive limitation of both active and

passive knee flexion with an extension contracture.<sup>2</sup> The vastus intermedius is most commonly involved. Fibrosis occurs more distally than proximally, within and between the muscle fibers. A dimple in the skin may be present because of the rigid, fibrous septa that extend between the skin and deep fascia. When present, the dimple deepens with forced flexion of the knee. Range of motion is painless within the available arc. There is atrophy of the involved muscle, with subcutaneous hardness and limitation of motion. Genu recurvatum may develop in severe cases. The patella is high-riding.

Habitual dislocation of the patella may also result in chronic cases.<sup>2</sup> Knee flexion in these patients is accomplished through lateral dislocation of the patella. With the patella held within the groove of the femur, the knee cannot be flexed. In these patients, the vastus lateralis is usually involved. This condition differs from congenital lateral dislocation of the patella, as it is an acquired contracture resulting from the progressive fibrosis.

### TREATMENT

Although physical therapy is often prescribed initially, it rarely improves knee flexion significantly.<sup>8</sup> Two different surgical releases have been advocated for the treatment of quadriceps fibrosis. The first is surgical release of the extension contracture by proximal division of the fibrotic muscular bands, which is often combined with transverse division of the iliotibial tract.<sup>12</sup> This approach is preferred in patients less than 10 years old age in whom there are no radiographic changes in the distal femur.<sup>13</sup> The other surgical approach is V-Y quadriceps plasty to lengthen the extensor mechanism as a whole when the fibrosis is extensive.<sup>14</sup>

Postoperative extensor lag may be present but resolves with time in most cases.<sup>1,10</sup> The extensor lag is more prevalent following V-Y-plasty compared with proximal release of the fibrotic bands.<sup>6</sup> When the fibrosis is chronic and genu recurvatum is present, skeletal changes may develop in the distal femur where the articular surface points anteriorly. In such cases it may be necessary to perform a distal femoral flexion osteotomy to gain knee flexion and maintain joint congruity.

### REFERENCES

#### Idiopathic Fibrosis of Muscles (Progressive Fibrosis of the Quadriceps)

1. Alvarez EV, Munters M, Lavine LS, et al: Quadriceps myofibrosis: a complication of intramuscular injections. *J Bone Joint Surg* 1980; 62-A:58.
2. Bose K, Chong KC: The clinical manifestations and pathomechanics of contracture of the extensor mechanism of the knee. *J Bone Joint Surg* 1976;58-B:478.
3. Euliano JJ: Fibrosis of the quadriceps mechanism in children. *Clin Orthop* 1970;70:181.
4. Fernandez de Valderrama JA, Esteve de Miguel R: Fibrosis of the gluteus maximus: a cause of limited flexion and adduction of the hip in children. *Clin Orthop* 1981;156:67.
5. Gunn DR: Contracture of the quadriceps muscle: discussion on the etiology and relationship to recurrent dislocation of the patella. *J Bone Joint Surg* 1964;46-B:492.
6. Jackson AM, Hutton PAN: Injection-induced contractures of the quadriceps in childhood: a comparison of proximal release and distal quadricepsplasty. *J Bone Joint Surg* 1985;67-B:97.



7. Jhunjhunwala HR: Abduction contracture of the deltoid muscle in children. *Int Orthop* 1995;19:289.
8. Lloyd-Roberts GC, Thomas TG: The etiology of quadriceps contracture in children. *J Bone Joint Surg* 1964;46-B:498.
9. Minami M, Yamazaki J, Minami A, et al: A postoperative long-term study of the deltoid contracture in children. *J Pediatr Orthop* 1984; 4:609.
10. Mukherjee PK, Das AK: Injection fibrosis in the quadriceps femoris muscle in children. *J Bone Joint Surg* 1980;62-A:453.
11. Sacristan HD, Sanchez-Barba A, Stern LLD, et al: Fibrosis of the gluteal muscles: report of three cases. *J Bone Joint Surg* 1974;56-A:1510.
12. Sasaki T, Fukuhara H, Iisaka H, et al: Postoperative evaluation of quadriceps contracture in children: comparison of three different procedures. *J Pediatr Orthop* 1985;5:702.
13. Sengupta S: Pathogenesis of infantile quadriceps fibrosis and its correction by proximal release. *J Pediatr Orthop* 1985;5:187.
14. Thompson TC: Quadriceps plasty to improve knee function. *J Bone Joint Surg* 1944;26:366.
15. Valdiserri L, Andrisano A, Manfrini M, et al: Post-injective quadriceps contracture. *Ital J Orthop Traumatol* 1989;15:267.

## Myasthenia Gravis

Myasthenia gravis is a rare autoimmune disease in which antibodies are produced to the nicotinic acetylcholine receptor at the neuromuscular junction. As a result, impulses cannot be transmitted properly across the junction, and the patient experiences muscle weakness or paralysis following repetitive activity. The disease was first described in 1672 by Willis.<sup>25</sup> In the late 1800s, Erb<sup>10</sup> and Goldflam<sup>12</sup> fully described the characteristics of the disorder, while Jolly coined the term *myasthenia gravis*.<sup>16</sup>

### INCIDENCE

The reported prevalence of myasthenia gravis in the general population varies from one in 50,000 to one in 10,000. The disease can manifest at any age but is most common in adulthood. Only about 10 percent of patients with myasthenia gravis are children.<sup>19</sup> One percent of patients with myasthenia gravis present before age 1 year.<sup>6</sup>

### ETIOLOGY

The exact etiology of the disease is not fully understood. It is an autoimmune disorder, with antibody production against a protein antigen at the motor end-plate known as acetylcholine receptor antibodies, or AchRAB. These antibodies can be identified in the blood of many affected patients, although up to 44 percent of younger children are seronegative on testing.<sup>2</sup> The thymus is considered the site of antibody production. Abnormalities of the thymus (e.g., benign tumors, hyperplasia, persistence of the gland) are frequently found in patients with myasthenia gravis.

There appears to be hormonal regulation of the disease, as those patients who are postpubertal are more likely to be seropositive. Additionally, there is a shift in the sex frequency of myasthenia gravis after puberty.<sup>2</sup> In early childhood there is a nearly equal ratio between males and females (1.3 females to 1 male), whereas after puberty the vast majority of patients are female (14 to 1). This supports the theory that hormones play an important modulating role.

Familial cases have been reported.<sup>5,18,20,26</sup> Histocompatibility leukocyte antigen (HLA) phenotypes have been studied

and two have been linked to the therapeutic response and clinical course of the disease.<sup>14</sup>

### CLINICAL FEATURES

Three patterns of presentation of myasthenia gravis in children have been described, based on age at onset and clinical features: (1) neonatal transient myasthenia gravis, (2) congenital myasthenic syndromes, and (3) juvenile myasthenia gravis.<sup>19</sup>

**Neonatal Transient Myasthenia Gravis.** This form of the disease affects 10 to 15 percent of infants born to mothers who have myasthenia gravis.<sup>6</sup> Symptoms consist of generalized muscular weakness, paucity of movement, weak suck, facial weakness, ptosis, and respiratory weakness. Failure to thrive can be a significant problem because of the infant's inability to suck. The symptoms are present at birth and resolve spontaneously within 4 weeks. The etiology of the disease appears to be the passing of maternal antibodies to the acetylcholine receptor through the placenta to the fetus. As the antibodies are destroyed or excreted, the clinical symptoms usually disappear after 6 weeks of age. The disease can be fatal if untreated, but affected newborns respond to neostigmine therapy. Exchange plasmapheresis is advocated for those babies who have generalized weakness,<sup>11</sup> and high-dose immune globulin therapy has also been used.<sup>3</sup>

**Congenital Myasthenic Syndromes.** Congenital myasthenic syndromes are a group of genetically inherited diseases characterized by an abnormal response to acetylcholine, resulting in myasthenia.<sup>4,7,8,24</sup> In many of these forms, the acetylcholine receptor is abnormal. Congenital myasthenic syndromes are not autoimmune in etiology.

These syndromes present at any age, with some patients diagnosed after birth. Most present within the first year of life.<sup>22</sup> Affected infants have poor suck and a weak cry.<sup>9</sup> The clinical course varies among the different types.<sup>22</sup> The spectrum of disease ranges from mild weakness to severe disability with life-threatening respiratory compromise. Congenital contractures of the extremities may be present and may resolve with medical treatment of the myasthenia.<sup>13</sup> Camptodactyly has been reported in these patients.<sup>13</sup> Scoliosis may occur in older children.

**Juvenile Myasthenia Gravis.** In 75 percent of cases, the age at onset of juvenile myasthenia gravis is 10 years or older.<sup>11</sup> These children most often present with ptosis and ophthalmoparesis or ophthalmoplegia. Eye weakness is the most common presenting complaint. Weakness of the upper and lower extremities occurs in fewer children, with the weakness more pronounced later in the day.<sup>11</sup> The child is unable to walk long distances without rest and also has difficulty climbing stairs. Quadriceps weakness leads to frequent falls. Gluteal weakness causes a Trendelenburg gait. Facial weakness produces a sad expression or flat affect. Weakness in mastication is due to easy fatigability of the jaw muscles. Tongue weakness leads to dysarthria. The child will begin to speak clearly but the words become slurred as the tongue fatigues. Respiratory difficulty, which is known as myasthenic crisis, occurs in 40 percent of untreated patients and can be fatal.<sup>11</sup> The neurologic examination reveals normal sensation and normal deep tendon reflexes. Pathologic reflexes are absent. The natural history of juvenile



myasthenia gravis is variable. Usually the disease worsens during the first and second years following onset. However, patients may experience periods of remission lasting months or even years.

## DIAGNOSIS

The key feature of myasthenia gravis is a history of muscular weakness that is precipitated by activity, termed *fatigability*. A positive edrophonium chloride (Tensilon) test confirms the diagnosis. Tensilon, which is an analogue of neostigmine (Prostigmin), has a short duration of action and is rapidly excreted. In normal individuals Tensilon has no effect on muscle strength but does produce cholinergic side effects (e.g., perspiration, salivation, lacrimation, fasciculations). In myasthenic patients, though, there is marked improvement in the motor strength of weak muscles within the first minute of injection of Tensilon, and cholinergic side effects are minimal. In addition, ptosis improves after administration of Tensilon.<sup>11</sup> Five minutes after administration of the drug, the beneficial effects disappear.

Electrophysiologic testing can also establish the diagnosis of myasthenia gravis. Repetitive stimulation of the ulnar nerve results in a decrement in magnitude of the compound muscle action potential in 75 to 88 percent of children with the disorder.<sup>23</sup> As the ulnar nerve is stimulated, the electrical response in the hypothenar muscles diminishes significantly with time. The nerve may be further sensitized by ischemia.<sup>11,23</sup>

Assays for anti-AchRAB are available. The presence or absence of antibodies makes it easier to distinguish the various forms of myasthenia gravis and can help define the prognosis and guide the treatment of these patients.<sup>21</sup>

## TREATMENT

The treatment of myasthenia gravis is medical, surgical, or both. Anticholinesterase therapy with neostigmine or pyridostigmine bromide is often used for long-term medical management. Glucocorticosteroids are also commonly used. Plasmapheresis has been helpful in decreasing the amount of antibody to acetylcholine.

Surgical treatment consists of removal of the thymus, since it is believed to be the primary site of antibody production. Histologic examination of the thymus gland in children with myasthenia gravis often shows follicular hyperplasia.<sup>17</sup> Approximately 60 percent of children with myasthenia gravis show a good response following thymectomy.<sup>17</sup> Muscle strength may improve within 1 week after surgery.<sup>11</sup> The long-term effects of thymectomy on a young patient's immune system probably are not significant. Those patients whose myasthenia gravis is not associated with antibody production to the acetylcholine receptor may not benefit from thymectomy.<sup>6</sup> Patients currently considered appropriate candidates for thymectomy are those whose response to anticholinesterase medications and immunosuppressants is unsatisfactory and those who prefer surgery to long-term immunosuppressant therapy.<sup>15</sup> For patients with peripuber-

tal onset of juvenile myasthenia gravis, better postoperative results are obtained if thymectomy is performed within 12 months of onset of the disease.<sup>12</sup>

## REFERENCES

### Myasthenia Gravis

- Adams C, Theodorescu D, Murphy G, et al: Thymectomy in juvenile myasthenia gravis. *J Child Neurol* 1990;5:215.
- Andrews PI, Massey JM, Howard JF, et al: Race, sex, and puberty influence onset, severity, and outcome in juvenile myasthenia gravis. *Neurology* 1994;44:1208.
- Bassan H, Muhlbaur B, Tomer A, et al: High-dose intravenous immunoglobulin in transient neonatal myasthenia gravis. *Pediatr Neurol* 1998;18:181.
- Beeson D, Palace J, Vincent A: Congenital myasthenic syndromes. *Curr Opin Neurol* 1997;10:402.
- Chin D, Gubbay SS: Familial myasthenia gravis: a study of three families. *Clin Exp Neurol* 1985;21:141.
- Dooley JM, Writer H, Gibson J, et al: Congenital myasthenia gravis: the clinical spectrum. *Clin Pediatr* 1988;27:575.
- Engel AG: Congenital myasthenic syndromes. *Neurol Clin* 1994;12:401.
- Engel AG: Myasthenia gravis and myasthenic syndromes. *Ann Neurol* 1984;16:519.
- Engel AG, Uchitel OD, Walls TJ, et al: Newly recognized congenital myasthenic syndrome associated with high conductance and fast closure of the acetylcholine receptor channel. *Ann Neurol* 1993;34:38.
- Erb W: Zur Casuistik der bulbaren Lahmungen: ueber einen neuen, wahrscheinlich bulbaren Symptomen-complex. *Arch Psychiatry* 1879; 9:336.
- Fenichel GM: Myasthenia gravis. *Pediatr Ann* 1989;18:432.
- Goldflam S: Ueber einen scheinbar heilbaren bulbarparalytischen Symptomencomplex mit Beteiligung der Extremitäten. *Dtsch Z Nervenheilkd* 1893;4:312.
- Hageman G, Smit LM, Hoogland RA, et al: Muscle weakness and congenital contractures in a case of congenital myasthenia. *J Pediatr Orthop* 1986;6:227.
- Hayashi M, Kida K, Yamada I, et al: Involvement of HLA in clinical course of myasthenia gravis. *J Neuroimmunol* 1988;18:171.
- Hermann DN, Carney PR, Wald JJ: Juvenile myasthenia gravis: treatment with immune globulin and thymectomy. *Pediatr Neurol* 1998; 18:63.
- Jolly F: Ueber Myasthenia gravis pseudoparalytica. *Berlin Klin Wochenschr* 1895;32:1.
- Lindner A, Schalke B, Toyka KV: Outcome in juvenile-onset myasthenia gravis: a retrospective study with long-term follow-up of 79 patients. *J Neurol* 1997;244:515.
- Matthes JW, Kenna AP, Fawcett PR: Familial infantile myasthenia: a diagnostic problem. *Dev Med Child Neurol* 1991;33:924.
- Millichap JC, Dodge PR: Diagnosis and treatment of myasthenia gravis in infancy, childhood, and adolescence. *Neurology* 1960;10:1007.
- Pascuzzi RM, Sermas A, Phillips LH, et al: Familial autoimmune myasthenia gravis and thymoma: occurrence in two brothers. *Neurology* 1986;36:423.
- Roach ES, Buono G, McLean WT, et al: Early-onset myasthenia gravis. *J Pediatr* 1986;108:193.
- Shillito P, Vincent A, Newsom-Davis J: Congenital myasthenic syndromes. *Neuromuscul Disord* 1993;3:183.
- Vial C, Charles N, Chauplannaz G, et al: Myasthenia gravis in childhood and infancy: usefulness of electrophysiologic studies. *Arch Neurol* 1991; 48:847.
- Vincent A, Newland C, Croxen R, et al: Genes at the junction: candidates for congenital myasthenic syndromes. *Trends Neurosci* 1997; 20:15.
- Willis T: *De Anima Brutorum*. Oxford, Theato Sheldoniano, 1672;404.
- Zammarchi E, Donati MA, Masi S, et al: Familial infantile myasthenia: a neuromuscular cause of respiratory failure. *Childs Nerv Syst* 1994; 10:347.