

Leg Length Inequality

INTRODUCTION

Leg length inequality in children is a frequent complaint or physical finding noted by the orthopaedist. Incidentally identified leg length inequality is a common finding during screening examinations such as of armed forces recruits, scoliosis screening examinations, and routine assessments of the asymptomatic adult population.^{199,404,450} The management of this deformity varies from no treatment to extensive multistage reconstruction to limb ablation and prosthetic fitting,^{1,83,121,155,298,324} depending on the severity of the inequality and the function of the limb.

Unique aspects of the management of leg length inequality in children include the dynamics of lower limb growth and the need to estimate the projected discrepancy at skeletal maturity. This is necessary to determine the best orthopaedic management of the deformity and the surgeon's ability to alter normal growth as a form of that management. To treat children with leg length inequality properly, the surgeon must be comfortable assessing leg length inequality clinically and radiographically, be cognizant of the various causes of leg length inequality, understand normal growth and the impact of abnormal growth on the individual's limb, be able to chart and estimate ultimate leg length inequality in the skeletally immature child, know what modalities are available to normalize leg length inequality, and select the appropriate management for each patient.

ETIOLOGY

Asymptomatic leg length inequality is relatively common in both the pediatric and adult healthy population.^{199,404,450} Soukka and colleagues found that 53 of 247 asymptomatic adults had a leg length inequality averaging 5 mm, with a maximum of 2 cm.⁴⁰⁴ Helsing found a leg length inequality between 0.5 and 1.5 cm in 32 percent of 600 military recruits, and exceeding 1.5 cm in 4 percent.¹⁹⁹ Rush and Steiner found equal leg lengths in only 23 percent of 1,000 army recruits.³⁷⁰ Similarly, Walker and Dickson found that 138 (2.6 percent) of 5,303 children ages 10 to 14 years who were screened for scoliosis had a pelvic tilt due to leg length inequality or pelvic asymmetry.⁴⁵⁰ Anderson and colleagues reported up to 1 to 2 cm difference in length or circumference in the normal population.¹⁴

In the past, limb length inequality was most commonly

a residuum of poliomyelitis. With vaccination, this is now a rare cause in the Western Hemisphere. The list of possible causes of leg length inequality in children is long (Table 23–1). In general, leg length inequality can be classified as congenital or acquired. Congenital causes include congenital femoral deficiency (including proximal femoral focal deficiency, or PFFD), fibular deficiency, tibial hemimelia, hemimyelomeningocele, idiopathic hemihypertrophy or hemiatrophy, and spinal dysraphism. Acquired causes include physeal growth disturbance from fracture, infection, irradiation, or other cause such as infantile or adolescent Blount's disease; Legg-Perthes disease; malunion of long bone fracture; growth stimulation secondary to long bone fracture; and inflammatory arthritis. Developmental causes, in which the discrepancy evolves with growth, include melorheostosis, congenital clubfoot deformity, enchondromatosis, osteochondromatosis, neurofibromatosis with gigantism, in association with congenital pseudarthrosis of the tibia, or vascular anomalies such as Klippel-Trénaunay syndrome.³⁴⁸

An important diagnostic category is that known as idiopathic hemihypertrophy or hemiatrophy (anisomelia). This topic has been reviewed by Ballock and colleagues,²⁷ who point out that hemihypertrophy can occur as part of a recognized clinical syndrome or in isolation (nonsyndromic). What constitutes hemihypertrophy or hemiatrophy is not clearly delineated except in severe situations.^{27,33} Furthermore, the distinction between normal variation and abnormal hypertrophy or atrophy between the two sides of the body is also not clear; a significant proportion of the "normal" population will have a detectable leg length inequality, as discussed above. One variation of hemiatrophy is Silver-Russell syndrome,³⁴⁷ a syndrome characterized by short stature with associated hemiatrophy (Fig. 23–1). The etiology of idiopathic nonsyndromic hemihypertrophy is not known. A specific exclusionary criterion for idiopathic hemihypertrophy is the absence of cutaneous or vascular anomalies, which can be seen in Proteus syndrome, Klippel-Trénaunay syndrome, neurofibromatosis, or Beckwith-Wiedemann syndrome. Nonsyndromic hemihypertrophy and Beckwith-Wiedemann syndrome have both been associated with the development of childhood neoplasias.* Beckwith-Wiedemann syndrome, described independently by Beckwith³⁷ and Wiedemann,⁴⁵⁶ is characterized by neonatal hypoglycemia, macroglossia, visceromegaly, omphalocele, hemihypertro-

* See references 16, 26, 84, 94, 118, 119, 136, 146, 168, 190, 195, 201, 235, 250, 299, 344, 383, 444.

TABLE 23-1 Summary of Causes of Leg Length Inequality

Causes of Decreased Leg Length

Congenital limb deficiency	
Congenital femoral deficiency	
Congenital fibular deficiency	
Tibial hemimelia	
Neurologic causes	
Asymmetric neurologic disorders	
Hemimyelomeningocele	
Poliomyelitis	
Asymmetric static encephalopathy (e.g., hemiparesis)	
Asymmetric peripheral neuropathy	
Traumatic	
Malunion	
Physcal growth disturbance or arrest after fracture	
Other acquired causes of physcal growth disturbance	
Infection	
Tumor	
Enchondroma	
Osteochondroma	
Unicameral bone cyst	
Irradiation	
Infantile Blount's disease	
Adolescent Blount's disease	
Legg-Calvé-Perthes disease	
Hemiatrophy	
Idiopathic, nonsyndromic hemiatrophy	
Russell-Silver syndrome	
Unilateral clubfoot deformity	
Congenital pseudarthrosis of the tibia	

Causes of Increased Leg Length

Posttraumatic overgrowth	
Femoral shaft fracture	
Tibial shaft fracture	
Soft tissue overgrowth syndromes	
Gigantism with neurofibromatosis	
Klippel-Trénaunay syndrome	
Beckwith-Wiedemann syndrome	
Proteus syndrome	
Idiopathic hemihypertrophy	
Inflammatory arthritis	

phy, and a propensity for the development of embryonal tumors, especially Wilms' tumor (although many different types have been reported).^{*} Elliott and Maher suggested as major criteria for the diagnosis macroglossia, overgrowth, and anterior chest wall defect.¹¹⁹ Ear creases, flame-shaped facial nevi, kidney enlargement, hypoglycemia, and hemihypertrophy are considered minor criteria. Most patients have a birth weight above the 90th percentile. Most cases are sporadic, but autosomal dominant transmission is suspected. Deletions and translocations in chromosome 11, near the locus of insulin-like growth factor II (IGF-II), have been identified, suggesting a correlation between the hypoglycemia and growth stimulation resulting in the hemihypertrophy and soft tissue overgrowth. Some 7 to 9 percent of patients with Beckwith-Wiedemann syndrome have been reported to have tumors; those with hemihypertrophy are at substantially greater risk (24 to 27 percent) for the development of tumor.[†] Nonsyndromic hemihypertrophy has been most commonly associated with Wilms' tumor, but it has also been associated with adrenal carcinoma and hepa-

ptoblastoma. As pointed out by Ballock and colleagues,²⁷ the majority of patients with Wilms' tumor do not have hemihypertrophy, and no large prospective study of the incidence of tumor in nonsyndromic hemihypertrophy has been reported. Wilms' and other tumors can be identified with abdominal ultrasonography. Unfortunately, reliable criteria for diagnosing nonsyndromic hemihypertrophy, the incidence of tumor and the effectiveness of screening in altering the natural history, the frequency with which screening examinations should be performed, and the age at which screening can stop all are unknown or unavailable. Thus, no specific guidelines can be given regarding the indications for and frequency of screening abdominal ultrasonography. At our institution, we perform screening abdominal ultrasonography in patients with the diagnosis of nonsyndromic hemihypertrophy or Beckwith-Wiedemann syndrome every 6 months until the age of 8.

Limb length inequality is a potential complication after long bone fracture, particularly femoral shaft fracture.^{93,215,247,332} The discrepancy may develop from malunion, growth stimulation, or subsequent disturbance of physcal growth.³⁴ In a study of 50 children less than 10 years old with femoral shaft fracture treated by spica immobilization within 72 hours of injury, Corry and Nicol found that 44 overgrew by an average of 7 mm, five had retarded growth, and one showed no effect of the treatment.⁹³ Overgrowth was most likely in the 4- to 7-year-old age group. Hougaard, in a study of 67 patients with femoral shaft fracture, found that overgrowth averaged 10 mm, with a maximum of 2.6 cm; he could not correlate the extent of overgrowth with age, sex, or fracture pattern.²¹⁵ Patients with shortening on follow-up tended to be older and to have fractures with angulation.

IMPACT OF LEG LENGTH INEQUALITY

Leg length inequality in the apparently healthy population is relatively common. The possible relationship of leg length inequality to any number of lower extremity or spinal problems has provoked considerable debate in the medical arena as well as in other health care fields. Some studies have implicated a variable amount of leg length inequality in the development of scoliosis, low back pain, sciatica, excessive stress on either hip or knee joints, and dysfunction of the lower extremity such as stress fracture, plantar fasciitis, or parapatellar knee pain.

Orthopaedists have traditionally been taught to consider leg length equalization by some means when leg length inequality in the absence of other deformity exceeds or is expected to exceed 2 to 2.5 cm at skeletal maturity.^{*} However, a firm rationale for this approach is lacking. A careful review of the literature will discourage anyone who is trying to establish firm and fast guidelines as to what amount of discrepancy should serve as the threshold of inequality beyond which treatment is indicated. Bhave and colleagues evaluated gait parameters in 18 patients before and after an average lengthening of 4.7 cm. They found that significant differences in stance time between the short and long leg improved after lengthening, and that the second peak of the vertical ground reaction force in the shorter limb improved

^{*} See references 16, 26, 94, 118, 119, 168, 250, 326, 383.

[†] See references 16, 26, 94, 118, 119, 168, 250, 383.

^{*} See references 46, 184, 310, 314, 392, 407.

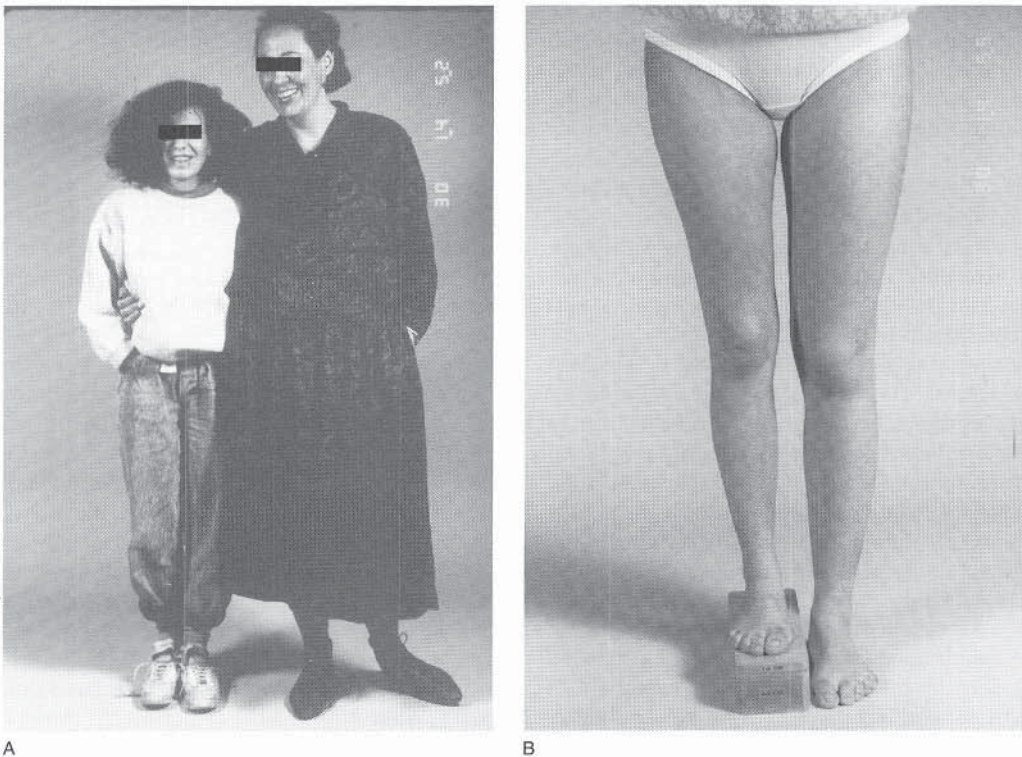


FIGURE 23-1 Patient with Silver-Russell syndrome. A, Patient standing with mother. Note short stature and right-sided hemiatrophy. B, Patient standing on 6 cm of blocks to compensate for shortening of the right femur and tibia.

significantly after lengthening.⁴² Eleven of the patients had complained of lumbosacral pain preoperatively, none after lengthening. Brand and Yack evaluated the resultant hip forces and moments in seven normal subjects walking with lifts of 2.3, 3.5, and 6.5 cm.⁶¹ The 2.3-cm lift produced no effect. The other lifts modestly increased mean peak intersegmental resultant hip forces but not moments in the shorter limb. Goel and colleagues studied the gait of ten subjects without leg length inequality walking with a 1.25-cm lift under one foot and ten asymptomatic patients with 1- to 2-cm leg length inequality walking both with and without corrective lifts. In the equal leg length group and the leg length inequality group walking without a lift, no side-to-side joint moment abnormalities were noted. In the leg length inequality group walking with a corrective lift, side-to-side joint moment differences were significantly increased. The authors concluded that “minor” leg length inequality did not produce predictable changes in joint kinetics likely to lead to joint abnormalities.¹⁶⁴ Kaufman and colleagues, in a gait analysis of 20 subjects with leg length inequality, noted that gait asymmetry beyond that seen in the normal population became evident when the discrepancy exceeded 2 cm (3.7 percent). This asymmetry was variable between subjects but in general was characterized by increased loading on the longer limb.²⁴⁰ Liu and colleagues, in a study of 30 patients with leg length inequality, found that discrepancies less than 2.3 cm resulted in “acceptable” gait asymmetry.²⁷⁰ They also noted that the amount of correction of asymmetry provided by a lift was unpredictable. Song and colleagues evaluated 35 children with leg length inequality ranging from 0.6 to 11.1 cm (0.8 to 15.8 percent shortening) by gait analysis.⁴⁰³ Compensatory mechanisms

for leg length inequality included circumduction or persistent flexion of the longer limb, vaulting over the longer limb, and toe-walking on the shorter limb. Discrepancies of less than 3 percent were not associated with compensatory mechanisms. More mechanical work was performed by the longer leg, and there was a greater vertical displacement of the center of body mass when discrepancies exceeded 5.5 percent, a discrepancy that could not be compensated for by toe-walking.

The association between leg length inequality and low back pain in the adult population is also not very clear from the literature. An increased incidence of leg length inequality in patients with chronic low back pain has been noted by some authors^{138,159,165,429} but not by others.* Amelioration of preexisting low back pain after leg length equalization by either surgical lengthening or shortening has been reported by several authors.^{42,368,436} Similarly, the influence of leg length inequality on the morphology of the spine with or without associated low back pain is also controversial, with some authors noting changes in facet joint orientation and other morphological asymmetries^{158,160,161} and other authors not noticing such changes.^{144,156,209} Leg length inequality has been implicated in the susceptibility of athletes and armed forces recruits to injury by some authors^{142,252,287,288} but not by others.^{50,179,263}

ASSESSMENT OF LEG LENGTH INEQUALITY

Clinical. It is important that an assessment of leg length inequality be incorporated into screening examinations per-

* See references 156, 180, 199, 209, 354, 404, 472, 473.

formed by both orthopaedists and primary care physicians, since in the absence of pain or limb dysfunction, children will tolerate and mask even substantial discrepancies. When screening a child for limb length inequality or when assessing a complaint of such, the physician should determine how long the family has been aware of the apparent leg length inequality, whether there are any associated functional limitations in either limb, any family history of skeletal dysplasia, and any history of fracture, infection, or other significant injury to either extremity. Significant malformations such as congenital clubfoot deformity, skin discoloration, or soft tissue enlargement should be questioned.

Leg length inequality as determined from physical examination can be *structural*, due to a measurable difference in a lower extremity segment, *functional* (or postural), due to asymmetry in positioning of one lower extremity relative to the other, or a combination of these. An accurate assessment of the nature of the leg length inequality then must include both careful assessment of the measured length of the lower extremities and their segments *and* evaluation of the range of motion and resting position of the lumbar spine, hips, knees, and ankles. An excellent illustration of the impact of functional limb length inequality presenting as structural inequality is provided by the gait and clinical assessment of patients with hemiparesis. Relatively minor hip adduction and/or flexion contractures of the involved side will produce the casual clinical impression of substantial structural leg

length inequality, whereas the actual structural discrepancy of the femur or tibia is typically quite small (Fig. 23-2). Ireland and Kessel²²⁹ estimated that a functional discrepancy of 3 cm was created with each 10-degree increment in hip adduction/abduction deformity, up to 40 degrees.

During the initial examination for a complaint of leg length inequality or screening for evidence of same during a routine examination, the child should stand facing away from the examiner, undraped such that the examiner can see the legs and the waist, including the posterior iliac spines. The examiner must be sure that the child is standing evenly, with the knees extended and the feet flat on the floor. In this position, the examiner can rest his or her hands on the iliac crests, or look at the posterior iliac spines for evidence of one leg being longer than the other. If a discrepancy is evident, an excellent estimation of the extent of the discrepancy can be made by having the patient stand on graduated blocks under the shorter leg until the pelvis is level (Fig. 23-3). Younger, nonambulatory, or uncooperative children can be assessed supine on an examining table, with the examiner drawing the child's legs parallel in an extended position and noting the relative levels of the soles of the feet or the medial malleoli, and by flexing the hips 90 degrees and noting relative knee height (Galeazzi's sign). It is important that the legs be held in symmetric positions at the hips, knees, and feet, or a functional discrepancy due to alteration in the position of the joints may be interpreted as a structural

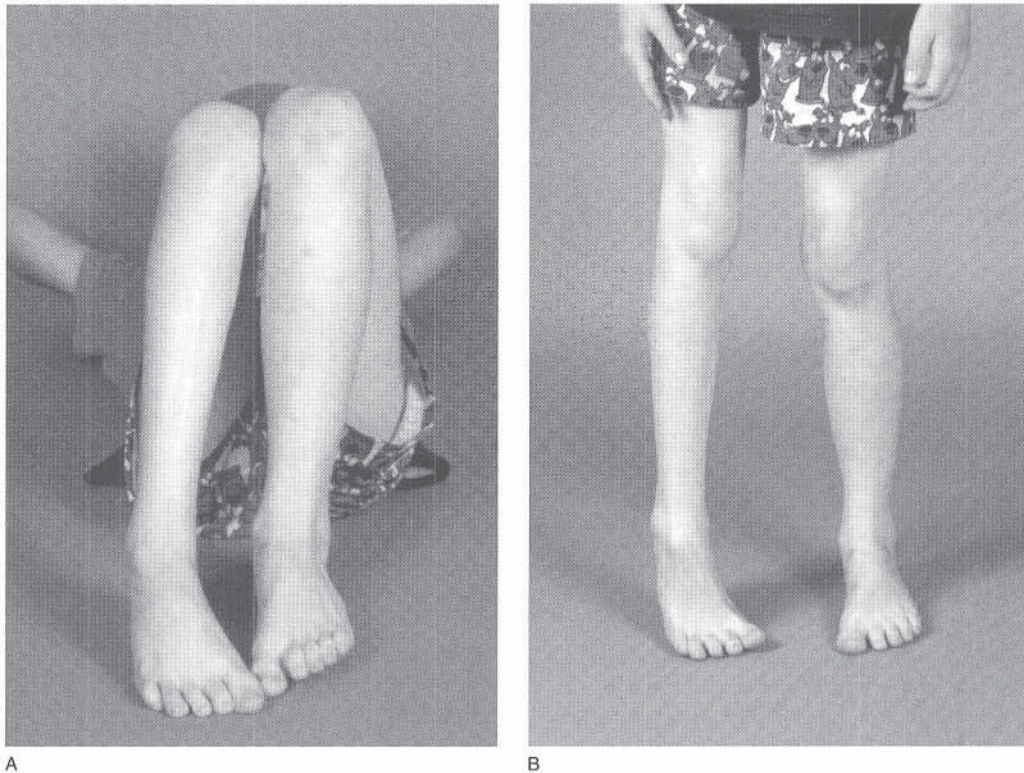


FIGURE 23-2 Apparent limb length inequality in a patient with hemiparesis. **A**, Clinical examination of the patient supine with the hips flexed suggests that there is a limb length inequality, with the hemiparetic side shorter than the unaffected side. This apparent shortening is due to adduction of the hemiparetic leg. **B**, Patient standing. Note apparent (and functional) shortening of the affected right side due to adduction and flexion of the right hip. Careful physical examination will usually reveal that the apparent shortening is secondary to the adducted, slightly flexed position of the hip, producing a *functional* but not a significant *structural* leg length inequality.

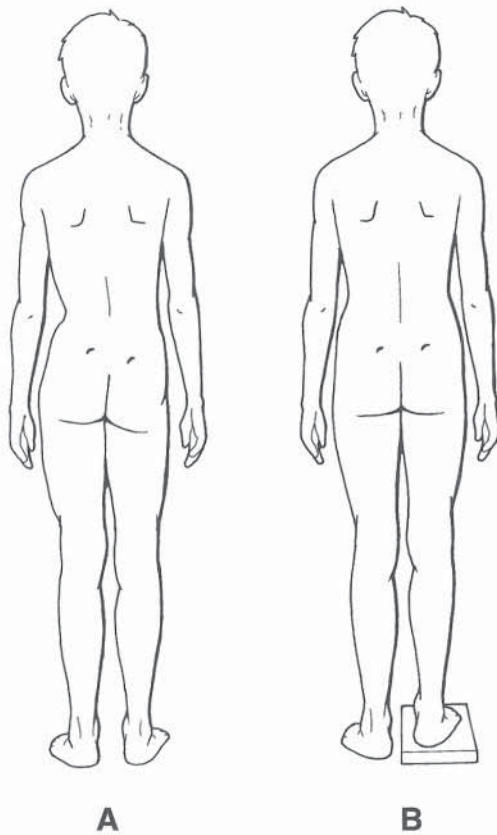


FIGURE 23-3 Clinical assessment of limb length inequality with the aid of graduated blocks. **A**, A true leg length inequality or fixed functional discrepancy will be noted as asymmetric iliac crest or posterior iliac spine heights with the patient standing erect. The examiner must be sure that the patient is standing evenly on the legs with the knees straight and the feet flat on the floor. **B**, A reasonably accurate estimation of leg length inequality may be made by having the patient stand erect on sufficient graduated blocks under the shorter limb to level the pelvis.

discrepancy. The limbs can be measured with a tape measure from the superior iliac spine to the medial joint line and the medial malleolus, or from the umbilicus to the medial malleolus for functional discrepancies (Fig. 23-4). Measurement with a tape is susceptible to error, however, because of variations in the location of these bony landmarks or difficulty identifying them, or because of variations in the position of the joints (particularly the hip) during these measurements.* Smith has described a clinical method for assessing leg length inequality that he calls the “thigh-leg” technique.³⁹⁹ The patient is placed supine on the examining table with the hips and knees flexed 90 degrees. Discrepancy is measured between the table and thigh, between the thighs at the knees, and between the soles with the knees even (Fig. 23-5). Smith found this clinical method significantly superior to tape measurement, and slightly more accurate than block measurement.³⁹⁹

The examiner should carefully assess the arc of motion, resting position, and stability of the lower extremity joints. Simultaneously, the examiner looks for angular deformity of the long bones, vascular anomaly or skin or soft tissue anomaly in the limbs, spinal deformity, or vascular anomaly

over the spine. In cases of suspected idiopathic hemihypertrophy or hemiatrophy, the physician should also look for asymmetry of upper extremity length, hand size, or facial features. Neurologic examination of the lower extremities concentrating on motor strength, tone, and reflexes should be performed to complete the “static” screening assessment. Finally, the examiner watches the patient walk and run to gain insight into how much functional impairment is being produced by the leg length inequality, with or without associated deformity. During this portion of the examination, the examiner notes any compensatory mechanisms the patient is using, specifically circumduction of the long leg, vaulting over the long leg, excessive flexion of the hip and knee of the long leg, or toe-walking on the short leg.

Radiographic. Radiographic documentation of leg length inequality can be accomplished with an anteroposterior (AP) radiograph of the pelvis with the patient standing on an appropriately sized block (Fig. 23-6) under the shorter limb, scanograms, orthoroentograms, or CT scanograms.* Ultrasound has also been described for leg length inequality screening.^{236,430}

PLAIN RADIOGRAPHY

Teleoroentgenography. This is the simplest whole-leg radiographic technique for the assessment of leg length inequality. A radiograph of the entire lower extremity is obtained with the patient supine on the radiographic table, with a long film and radiographic ruler beneath the patient. This technique is also the most susceptible to magnification error, since a single exposure is made from a midpoint on the patient’s lower extremities (Fig. 23-7). It is, however, useful if the patient is unlikely or unwilling to hold still for the multiple exposure techniques described below.

Orthoroentgenography. This radiographic technique was described by Green and colleagues in 1946.¹⁷² The purpose is to minimize measurement error due to magnification by making three separate exposures of the lower extremities centered over the hips, knees, and ankles (Fig. 23-8). One long film with a radiographic ruler is obtained, similar to the teleoroentgenogram. In cases of significant leg length inequality, separate exposures for each leg may be made, with the radiographic beam centered over each joint. It is important that the patient not move between exposures (which Green and colleagues¹⁷² accomplished by strapping the patient to the table after positioning) and that the limbs be aligned neutrally. Saleh and Milne have described using this technique in a weightbearing position, so that angular deformities, mechanical axis deviations, and limb length can be assessed simultaneously in the weightbearing position.³⁷² Weightbearing is not important to the accuracy of the measurement of leg length inequality.⁸⁵

Scanography. This term arose from an early technique called slit scanography but has come to be used for a technique similar to orthoroentgenography, differing in that not only is the radiographic tube moved over the patient for the three exposures, but the film is moved under the patient as well (Fig. 23-9). This reduces the size of film required, making storage and handling easier. The patient needs to remain

* See references 35, 143, 178, 236, 256, 399.

* See references 2, 6, 12, 73, 85, 140, 141, 162, 172, 200, 213, 223, 246, 256, 314, 315, 372, 428.

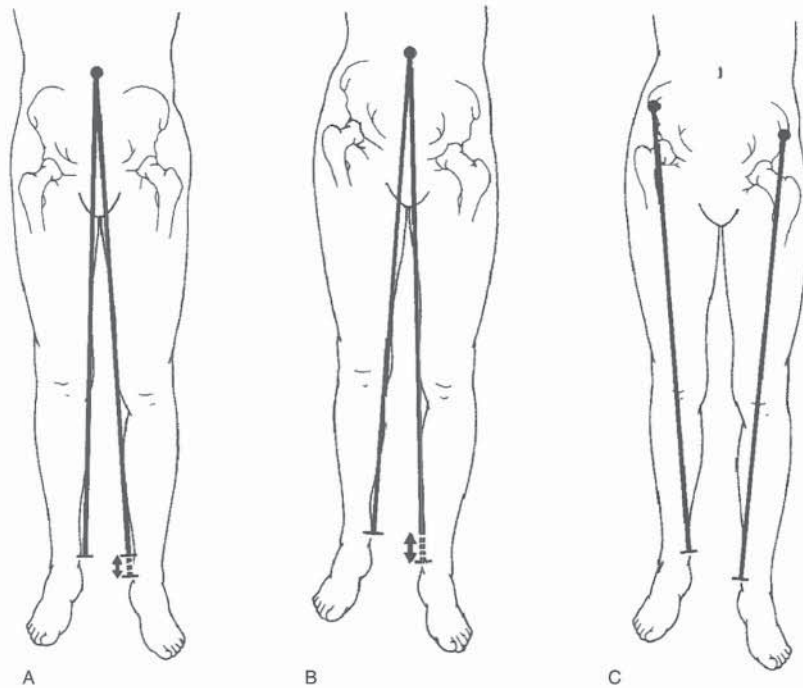


FIGURE 23-4 Assessment of functional and actual leg length inequality on the examining table using a tape measure. Typically the legs will be measured from the umbilicus to the medial malleolus (functional or apparent discrepancy) and from the anterior-superior iliac spine to the medial malleolus (actual, true, or structural discrepancy). See text for further discussion. A, With the legs in an extended and neutral position, in a patient with structural leg length discrepancy, the length of the legs will measure unequally both when measured from the umbilicus to the medial malleolus (left leg is longer than the right) and from the anterior iliac spine to the medial malleolus. B, In a patient with fixed pelvic obliquity but no true limb length inequality, asymmetry will be noted on measurement of the functional leg inequality (from the umbilicus). In this example the abducted left leg will measure longer than the right. C, Measurement from anterior-superior iliac spine to the medial malleolus will demonstrate no structural leg length inequality in the same example as Figure 23-5B.

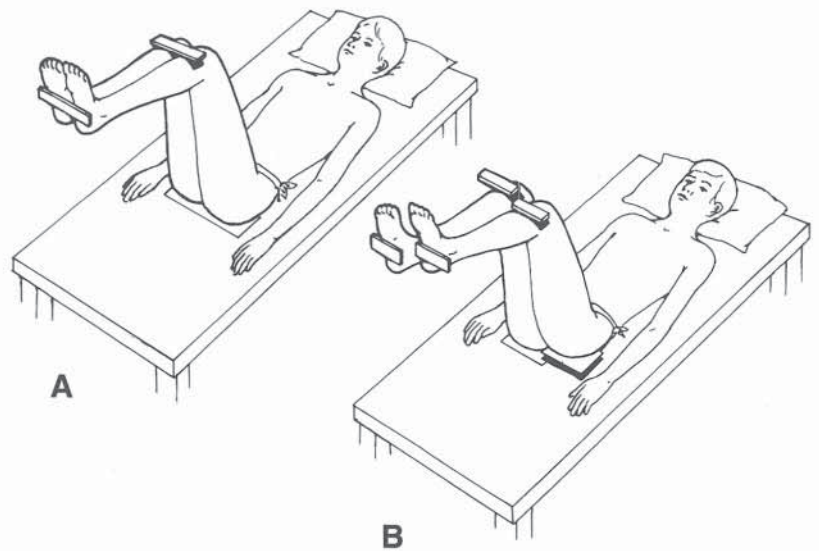


FIGURE 23-5 Thigh-leg technique of leg length inequality estimation during on-table examination. A, The patient is positioned supine on the examination table with the hips and knees flexed 90 degrees. Discrepancy between the two sides is checked between the table and thigh, between the thighs and knees, and between the soles with the knees even. B, An estimation of limb length inequality is made by assessing asymmetry at these three levels. (After Smith CF: Instantaneous leg length determination by "thigh-leg" technique. *Orthopedics* 1996;19:955.)

motionless during the exposures, similar to orthoroentgenography. The entire length of the bone is not available on film, negating this technique as a screening tool to assess the etiology of leg length inequality.

COMPUTED RADIOGRAPHY. An alternative to conventional radiography is low-dose computed radiography (CR). The radiation dosage exposure with this method is reduced significantly (as little as 1 percent of conventional radiography for orthoroentgenograms) and the accuracy is comparable to that of conventional radiography.^{12,246}

COMPUTED AXIAL TOMOGRAPHY SCANOGAM. Computed axial tomography (CT) has become popular for the assessment of

leg length inequality.* Advantages include lower radiation exposure even when the entire limb is exposed, greater accuracy, less susceptibility to error if the patient is poorly positioned, and the ability to accommodate positioning difficulties secondary to joint contractures or the presence of external fixators (Fig. 23-10). This technique is specifically indicated when the patient has a knee flexion contracture or is in a circular external fixator, because the accuracy is greater than that of conventional orthoroentgenography in these conditions.^{2,223,428} The radiology technicians responsible for obtaining CT scanograms must position the patient's

* See references 2, 6, 73, 162, 200, 223, 428.




FIGURE 23-6 Series of graduated blocks used for estimating leg length discrepancy. A reasonably accurate clinical estimation can be made with a series of appropriately marked blocks, and can be used in place of radiographs for screening of leg length inequality and for serial examinations.

limbs symmetrically, or at least be certain that a given positioning difficulty will not interfere with accurate measurement. For example, hip or knee flexion contractures are well accommodated by CT scanography when measurements of segment length are taken from the lateral projection, but only if the limb is in a neutral position with respect to abduction/adduction at the hip or there is no asymmetric frontal plane angular deformity.

ULTRASONOGRAPHY. Ultrasound has been described for the assessment of leg length inequality.^{236,430} Junk and colleagues

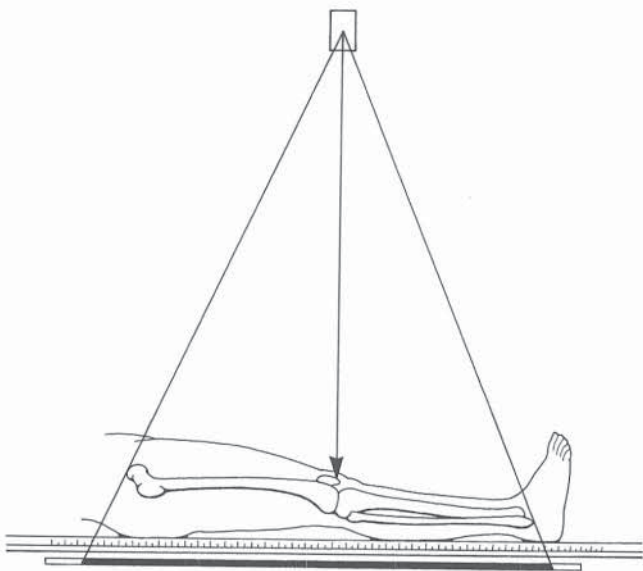


FIGURE 23-7 Technique of teleoroentgenography. A long film and a ruler are placed under the patient, and a single exposure is made centered over the limbs.

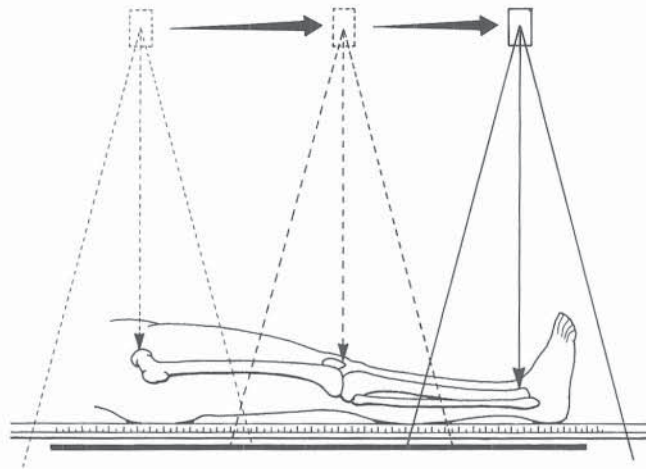


FIGURE 23-8 Technique of orthoroentgenography. A long film and a ruler are placed under the patient. Three (or six) exposures are made at the hip, knee, and ankle level without moving the patient or the film.

found that this technique was more accurate than clinical assessment alone,²³⁶ and Terjesen and colleagues found the accuracy to be within 2 mm of standard radiographic techniques.⁴³⁰ However, special jigs must be constructed, and the patient must not move during the examination. The main advantage of this technique is that exposure to ionizing radiation is not required. We have no experience with this technique for leg length inequality assessment.

PREDICTION OF LEG LENGTH INEQUALITY IN THE SKELETALLY IMMATURE CHILD

Normal Skeletal Growth. An appreciation of normal skeletal growth of the lower extremities is an integral component of the evaluation and appropriate management of leg length inequality. Normal physal growth, the contribution of each lower extremity physis to the overall length and shape of the leg, the concept and timing of skeletal maturation, and the impact of various disorders on normal growth are all components of that understanding.

LONGITUDINAL GROWTH OF LONG BONES. All long bones are characterized as having five regions—the central tubular shaft (diaphysis), which flares into the funnel-shaped metaphyses at either end of the diaphysis, and the relatively bulbous, articular ends (epiphyses). Prior to skeletal maturity, the epiphysis and metaphysis are separated by the cartilaginous growth plate, or physis.

Traditionally, epiphyses have been characterized as being of two types, pressure or traction. A *pressure epiphysis* is articular, located at the end of a long bone, and contributes to the formation of a joint. The greatest portion of the longitudinal growth of a long bone takes place at the physes, forming part of “pressure epiphyses.” *Traction epiphyses* are nonarticular; they serve as sites of origin or insertion for muscles, such as the greater and lesser trochanters, the tuberosities of the proximal humerus, the epicondyles of the distal humerus, and the tibial tubercle. The reader should note that the scheme of the growth plate oversimplifies the anatomy of the physis and the epiphysis, which in many epiphyseal areas

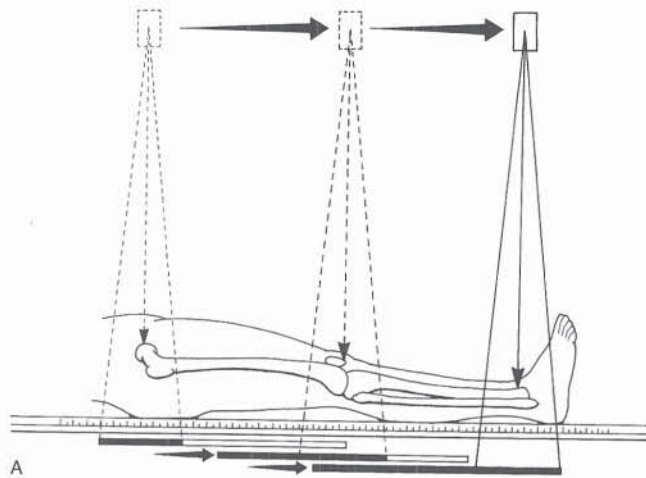
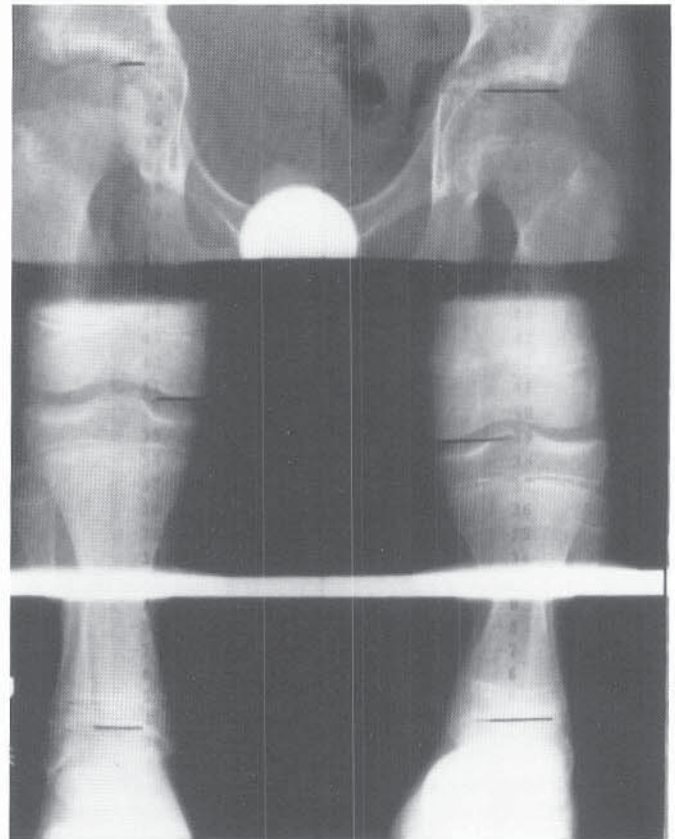


FIGURE 23-9 Technique of scanography. **A**, A 14 × 17-inch film is placed under the patient with a ruler. Three (or six) exposures are made, centered over the hips, knees, and ankles. The film is advanced under the joint to be radiographed and exposed sequentially. **B**, Appearance of scanogram. A smaller film is used, making storage and handling easier. Only a portion of the bone segment is visible on the radiograph.



B

is a great deal more complex structure than a simple “plate.” For example, the upper end of the femur initially incorporates the greater trochanter, femoral neck, and femoral head. With growth and maturation, secondary ossification centers develop in the greater trochanter and head (capital epiphysis), with organization of the proximal growth plate into a continuous physis from the base of the greater trochanter, along the outer femoral neck, and extending into the base of the femoral head. Finally, the physal portion of the upper end of the femur separates into the greater trochanteric physis (“apophysis”) and the capital physis (see Chapter 15, Developmental Dysplasia of the Hip). Other examples of “complex” physes include the proximal and distal humerus, and the triradiate cartilage of the pelvis. It should also be noted that the epiphyses themselves grow circumferentially, and not just at the plate.

The major long bones—the femur, tibia, fibula, humerus, radius, and ulna—have a physis at both ends. The short tubular bones (the phalanges, metatarsals, and metacarpals) typically have one physis, which is located proximally in the phalanges, first metacarpal, and first metatarsal and distally in the other metacarpal and metatarsal bones.

Long bones grow in length at the cartilaginous area of their extremities. This was shown by Stephen Hales in 1731.¹⁹¹ He marked the shafts of the limb bones of newly hatched chicks with two holes. Two months later, when the chickens were killed, the limb bones had increased considerably in length; however, the distance between the two marker

holes had not increased. In 1736, Belchier discovered a new method of marking osseous tissue in pigs by feeding them madder root.³⁸ Several years later Duhamel, in his studies of bone growth, demonstrated that only the osseous tissue formed during the time when the animal was fed madder turned red; that formed before and after was of normal color.¹¹³ In addition to confirming the findings of Hales that the longitudinal growth of long bones takes place at the extremities, Duhamel proposed that interstitial growth also occurs to a varying extent in the diaphysis. He also demonstrated that transverse growth of the diaphysis occurs by appositional bone formation from the periosteum, and not by interstitial growth in the bone tissue. The experiments of Hales and Duhamel were repeated by John Hunter, who showed that appositional bone formation is accompanied by resorption of previously formed bony tissue.²²² Flourens found that resorption of bony tissue is not confined to the endosteal aspect of the diaphysis but also occurs in most parts of bony tissue.¹³² Subsequently it was noted that longitudinal growth could be influenced by mechanical factors, specifically compression and traction, or tension. Hueter²²⁰ and Volkmann,⁴⁴⁶ in 1862, noted that compressive forces in bone resulted in slowing of growth and that tension increased bone growth and the formation of osseous tissues (the Hueter-Volkmann principle). Wolff disputed this, believing that both compression and tension resulted in bone growth stimulation.⁴⁶³ Both Haas in 1945¹⁸⁶ and Gelbke in 1951¹⁵³ demonstrated that wire loops placed around the

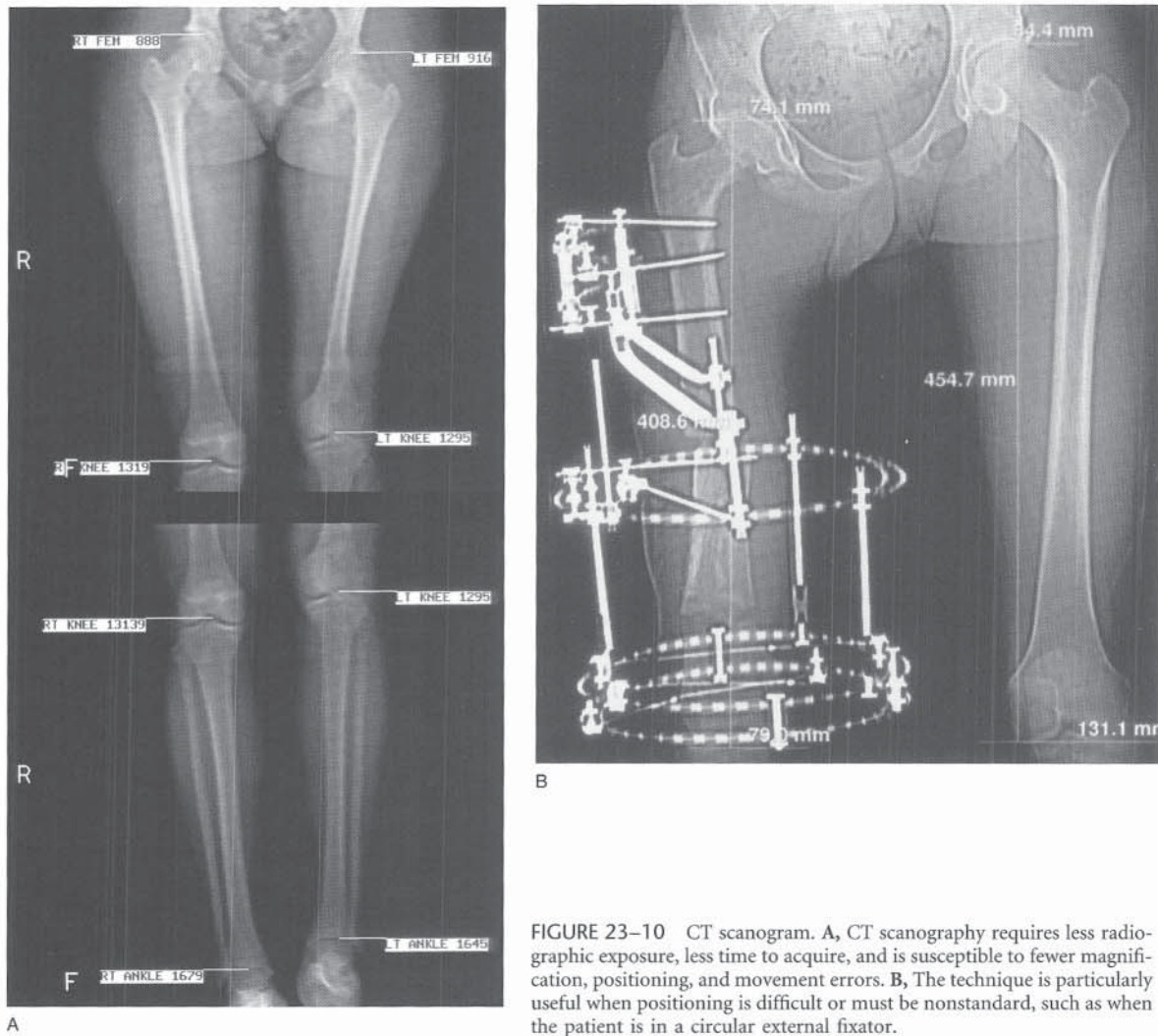


FIGURE 23-10 CT scanogram. **A**, CT scanography requires less radiographic exposure, less time to acquire, and is susceptible to fewer magnification, positioning, and movement errors. **B**, The technique is particularly useful when positioning is difficult or must be nonstandard, such as when the patient is in a circular external fixator.

distal femur in dogs impeded longitudinal bone growth. Haas also noted that pins placed across the physis could restrict longitudinal growth.¹⁸⁸ Gelbke stated that the controversy regarding the influences of compression and tension on longitudinal growth arose from failure to distinguish between growing and mature bone, and that the formation of bone tissue and bone growth were considered to be identical processes.¹⁵³ By placing loose and tightened wire loops around the distal femur of growing dogs, he noted that longitudinal growth would continue for several months, until pressure developed across the physis; the physis would then narrow radiographically and histologically, and finally growth inhibition followed. He also noted that these changes were reversible if he cut the wire after physal narrowing and growth inhibition had occurred. He attempted to produce traction on an apophyseal physis with wire loops, but with less success. He concluded that the effect of tension on the physis did not increase enchondral bone growth, and appeared to have the same effect as compression.

The physis is divided into horizontal zones, termed germinal, proliferative, hypertrophic, and provisional calcification (Fig. 23-11). The entire process of growth in this fashion—longitudinal growth by the cartilaginous “plate,” followed by ossification of the cartilaginous precursor—is

known as enchondral ossification. Horizontal or peripheral growth of the physis occurs as well, in the specialized groove of Ranvier. The control of longitudinal growth, and the mechanisms of cartilage cell hypertrophy, calcification, and ossification, are still not thoroughly understood and are subject to many central hormonal, local hormonal, and mechanical influences.⁴³⁸ The most widely recognized central hormonal regulator of physal growth is growth hormone (GH). GH deficiency is associated with proportionate short stature, and excess GH secretion in the skeletally immature results in gigantism. GH action on physes is mediated by insulin-like growth factors (IGFs) produced both in the liver and physal chondrocytes. Another important class of polypeptides (there are at least ten classes) influencing normal physal activity are the fibroblast growth factors (FGFs), which have mitogenic influence on physal chondrocytes. A defect in the FGF-3 receptor is the genetic defect responsible for achondroplasia.

The reader should note that the longitudinal growth of the epiphyses themselves is not usually specifically taken into account in the estimation of longitudinal growth of any particular long bone. Clinical and radiographic anthropometric measurements of the long bones during growth are usually made from the ends of the epiphysis;

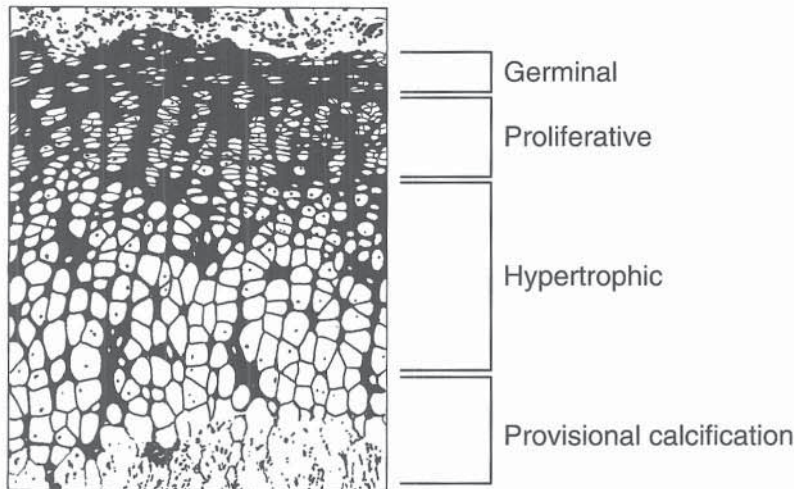


FIGURE 23-11 Scheme of organization of the growth “plate” or physis. The histologically identifiable layers include the resting or germinal layer and the proliferative, hypertrophic, and provisional calcification layers progressing from epiphysis to metaphysis.

estimations of the contribution of longitudinal growth of the physes at either end of the long bones of the upper and lower limb segments are known, and limited to the physes themselves. Thus, as Moseley points out,³¹⁰ growth data on the length of the leg and its femoral and tibial segments pertain to the entire length of the bone from epiphysis to epiphysis, but calculations regarding final length by virtue of growth from the physes ignore the increase in length provided by the epiphysis.^{41,109,255,311,312}

In long bone with physes at either end, the contribution of each physis to the longitudinal growth of the bone is typically asymmetric (see Fig. 1-9 in Chapter 1, Growth and Development). Digby made observations on the contribution of longitudinal growth by assessing growth arrest lines in anatomic specimens.¹¹¹ Anderson, Green, and Messner estimated the contributions to longitudinal growth of the distal femur and proximal tibia by assessing sharply delineated growth arrest lines on consecutive radiographs in a separate, semilongitudinal study of 206 boys and girls, discussed in their 1963 article on growth and the prediction of growth.¹³ These authors found that 71 percent of femoral growth occurred distally and 57 percent of tibial growth occurred proximally.

The timing of the appearance of the secondary centers of ossification, which make the physis radiographically identifiable, also varies with location and to some extent by individual. Finally, the timing of closure with cessation of longitudinal growth in individual physes also varies by location and individual (see Figs. 1-5 and 1-7 in Chapter 1, Growth and Development, for these approximations).

Prediction of Growth Remaining in the Femur and Tibia

ANDERSON-GREEN-MESSNER GROWTH REMAINING CHARTS. Anderson, Green, and Messner have published two articles that provide important information on the longitudinal growth of the femur and tibia and an estimation of growth remaining, to be used to time epiphysiodesis or stapling appropriately.^{13,14} The first, published in 1963, examined longitudinal growth data obtained in 100 children (50 boys and 50 girls) who were assessed at least once a year in the 8 years prior to termination of their growth.¹³ Fifty-one of the children were normal (25 girls and 26 boys) and 49 had poliomy-

elitis affecting one lower extremity only, with the data from the “normal” leg being incorporated into data from the normal children. Orthoroentgenograms (measuring the length of the femur and tibia, including each epiphysis), hand and wrist films for skeletal age (using Greulich and Pyle’s atlas¹⁷⁴), total body size, and other variables were measured at each visit. Visits were scheduled close to the subjects’ birthdays, and measurements (including skeletal age) were recorded against chronological age (Table 23-2). A number of interesting findings emerged from this study. The annual rate of overall growth (stature) rapidly *decreased* from birth to age 6 and was stable from age 6 through 9 (average stature increment, 5.7 cm \pm 0.93 cm). Femoral length increased at an average annual rate of 2.0 \pm 0.27 cm, and tibial length increased at an average annual rate of 1.6 \pm 0.23 cm. A pubertal growth spurt sometime after age 9 was typical (usually reaching a maximum in girls between ages 10 and 12 and in boys between ages 12 and 14). This was followed by a final 4-year period of rapid decline in the rate of growth until cessation of growth (Fig. 23-12). When average figures for stature and femoral or tibial length changes per year of chronological growth were computed, the amplitude of the peak was blunted, since the age at which the growth spurt occurred varied from one child to the next. In general, growth continued for 2 years after the adolescent growth spurt, irrespective of the age at which it had occurred. As a consequence, material based on chronological age is useful in younger children, but because of this variation in onset of the pubertal growth spurt, it is not as valuable in children with 5 to 6 years of growth remaining. Anderson and colleagues used skeletal age as published by Greulich and Pyle, but noted that assessment from the elbow, hip, knee, and foot may also be used, as well as physical maturation parameters (such as the Tanner stages of development; see Chapter 1, Growth and Development).¹³ These authors found that when skeletal age was used as the basis for interval changes, the mean values for growth remaining were essentially the same as if chronological age were used, but the recorded variation around the mean was appreciatively less when skeletal age was used. Thus, estimates of future growth in an individual child could be made with greater precision if skeletal rather than chronological age was used, particularly in children whose level of maturation

TABLE 23-2 Longitudinal Growth Data of 100 Children (51 Healthy and 49 with Unilateral Polio) as Determined by Anderson, Green, and Messner

50 Girls								
Age (yr)	Stature (cm)		Femur (cm)		Tibia (cm)		Skeletal Age (yr)	
	Mean	σ	Mean	σ	Mean	σ	Mean	σ
8	128.1	4.78	33.1	1.63	26.3	1.39	7.6	1.02
9	133.8	4.78	35.0	1.71	28.0	1.50	8.7	1.02
10	139.9	5.24	37.0	1.82	29.8	1.67	9.9	1.03
11	146.6	5.93	39.2	2.00	31.6	1.84	11.1	1.07
12	153.2	6.36	41.1	2.12	33.2	1.95	12.5	1.12
13	158.3	6.14	42.4	2.12	34.2	1.94	13.8	1.06
14	160.8	6.16	43.1	2.15	34.5	1.97	14.8	1.05
15	162.3	6.02	43.2	2.18	34.6	1.98	15.8	1.00
16	162.9	6.10	43.3	2.20	34.6	2.00	16.4	0.92
17	(163.8)	(6.37)	(43.3)	(2.21)	(34.7)	(2.00)	(17.1)	(0.85)
18	(164.9)	(6.10)	(43.3)	(2.21)	(34.7)	(2.00)	(17.8)	(0.46)

Note: Figures in parentheses were based on 21-42 girls only, since data were not available on all subjects at these ages.

50 Boys								
Age (yr)	Stature (cm)		Femur (cm)		Tibia (cm)		Skeletal Age (yr)	
	Mean	σ	Mean	σ	Mean	σ	Mean	σ
8	127.6	5.94	(32.8)	(1.53)	(25.9)	(1.55)	(7.8)	(1.00)
9	133.3	6.15	(34.6)	(1.78)	(27.1)	(1.86)	(8.8)	(1.04)
10	138.5	6.58	36.4	1.87	28.6	1.89	9.9	0.96
11	143.5	6.94	38.2	2.07	30.1	2.07	11.0	0.88
12	149.4	7.72	40.2	2.23	31.8	2.27	12.1	0.76
13	156.3	9.13	42.3	2.52	33.6	2.49	13.1	0.80
14	163.7	9.54	44.3	2.58	35.3	2.54	14.1	0.93
15	169.8	8.68	45.8	2.38	36.4	2.34	15.1	1.14
16	173.2	7.74	46.6	2.27	36.9	2.21	16.3	1.20
17	175.0	7.41	46.9	2.30	37.1	2.21	17.3	1.10
18	175.9	7.37	47.0	2.35	37.1	2.22	(18.0)	(0.89)

Note: Figures in parentheses were based on 31-49 boys only, since data were not available on all subjects at these ages.

Bone lengths, measured from orthoroentgenograms, include both proximal and distal epiphyses. Skeletal ages read according to Greulich-Pyle atlas (1950).

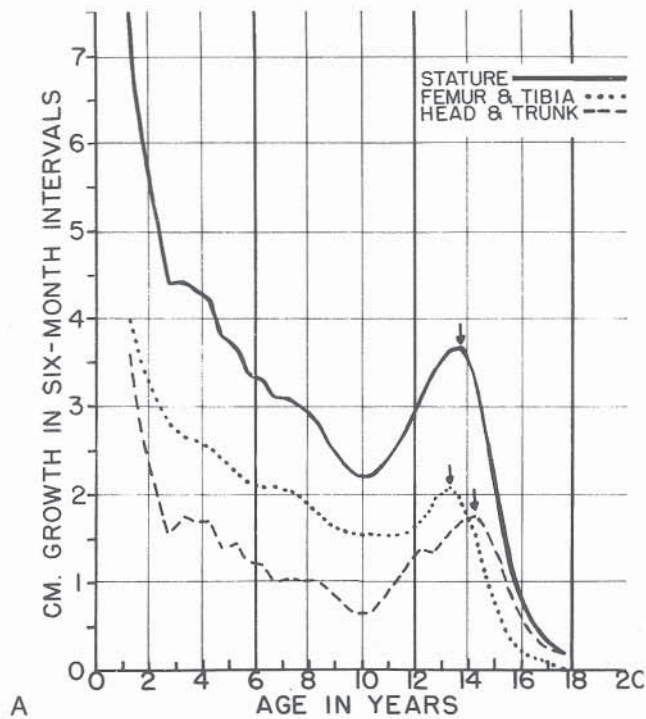
From Anderson M, Green WT, Messner MB: Growth and prediction of growth in the lower extremities. *J Bone Joint Surg* 1963;45-A:3.

was consistently advanced or retarded by 2 years or more compared with their chronological age.

The method that Green and colleagues used to develop the growth remaining charts was to interpolate the length of each of the 100 femora and tibia at specific, equally spaced skeletal ages: 10 + 3, 11 + 3, and so on.¹³ The increments of growth between these consecutive skeletal ages were derived. The growth of the entire femur and tibia were then related to the growth at the specific physes using figures for the proportional contribution of growth obtained from the semi-longitudinal study of sharply delineated growth arrest lines on consecutive radiographs (71 percent of femoral growth occurred distally and 57 percent of tibial growth occurred proximally). These results were then used to compile the growth remaining charts for boys and girls in the distal femur and the proximal tibia (Fig. 23-13). An example of the variations to be encountered is provided by Anderson

and colleagues themselves, who note that the 50th percentile growth remaining at the distal femur for a girl of skeletal age 10 + 3 was 4.1 cm, while the extremes of growth that occurred at that age were actually 2.2 and 7.2 cm; 80 percent of these girls were noted to grow between 3.3 and 5.0 cm.

Anderson and colleagues described how the growth remaining charts were to be used in the 1963 article, having presented less complete versions of it in 1947 and 1957.^{169,170} The first consideration is the growth of the side *not* operated on. They noted that the rate of growth inhibition in poliomyelitis was not constant over the entire period of affectation; they recommended knowing the rate of growth in the 2 to 3 years prior to treatment by epiphysiodesis. Also, if the affected leg physis was not growing at all, no correction was to be expected, only prevention of further leg length inequality. Second, they stated that the importance of a child's relative maturity cannot be overemphasized. They



AVERAGE YEARLY RATES OF GROWTH
DERIVED FROM COMPLETELY LONGITUDINAL SERIES

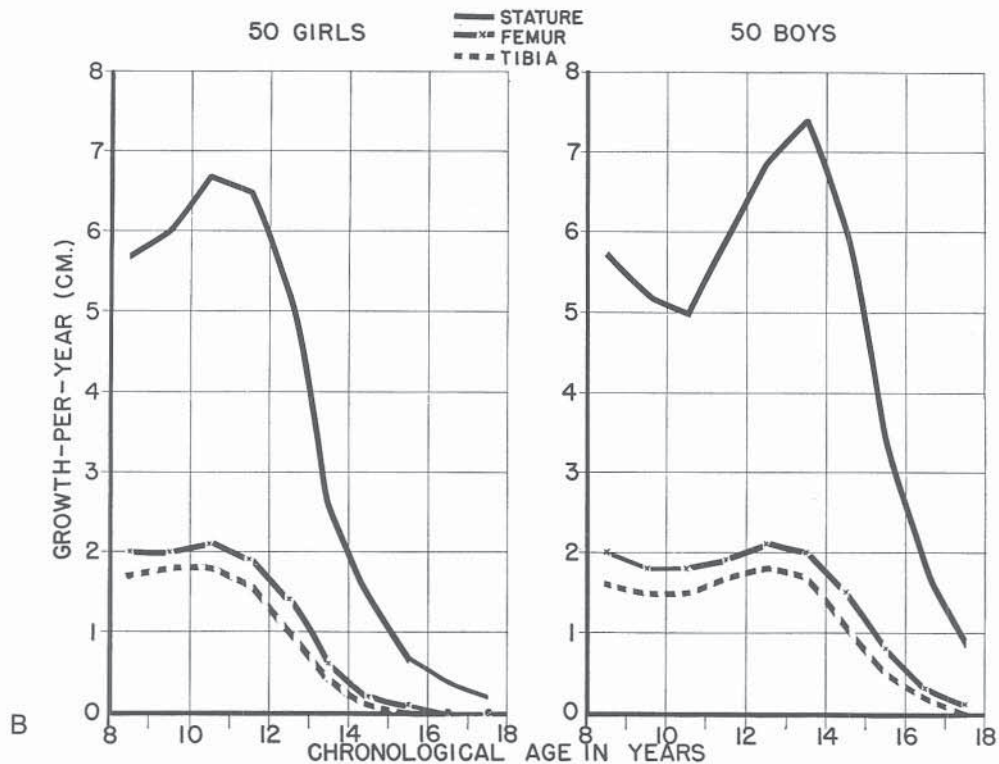
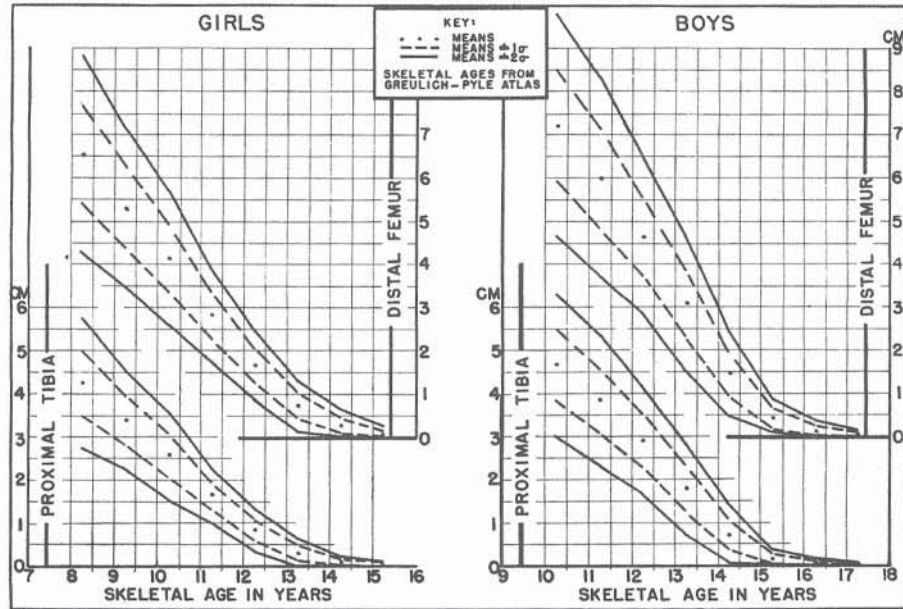


FIGURE 23-12 Average yearly rates of growth (femur, tibia, and total stature) as determined by Anderson, Green, and Messner. Determined from the same data as presented in Table 23-2. A, Pattern of growth in a boy from the age of 1 to 18 years. Note, during the first decade, the decreasing rate of growth of stature and of length of femur, tibia, and trunk. In the second decade, there is a definite short period of accelerated growth—the “adolescent growth spurt.” This general pattern of growth is similar in all children. (From Green WT, Anderson M: AAOS Instructional Course Lectures, vol 17, p 200. St. Louis, Mosby, 1960.) B, Average yearly rates of growth derived from completely longitudinal series. (From Anderson M, Green WT, Messner MB: Growth and prediction of growth in the lower extremities. J Bone Joint Surg 1963;45-A:5.)

GROWTH REMAINING IN NORMAL DISTAL FEMUR AND PROXIMAL TIBIA
FOLLOWING CONSECUTIVE SKELETAL AGE LEVELS

MEANS AND STANDARD DEVIATIONS DERIVED FROM
LONGITUDINAL SERIES 50 GIRLS AND 50 BOYS



II-11-57 THE CHILDREN'S MEDICAL CENTER, BOSTON, MASSACHUSETTS

FIGURE 23-13 Growth remaining charts for the distal femur and proximal tibia for girls and boys, as determined by Anderson, Green, and Messner. These charts are based on the growth data presented in Table 23-2 and an estimated contribution of growth of the distal femur of 70 percent and the proximal tibia of 56 percent to the total length of the respective bone. Data are presented relative to skeletal age from age 8 to skeletal maturity. Skeletal age was determined from hand and wrist films, compared to Greulich and Pyle's atlas (1950).¹⁷⁴ (From the Children's Medical Center, Boston, MA.)

concluded that the forming of a total picture of each child is important, and they did not attempt to reduce prediction of the results to a precise, mathematical formula.

The authors' second paper,¹⁴ published the next year, provided data on the length of the femur and tibia from a completely longitudinal study of 67 boys and 67 girls derived from radiographs taken on their birthdays from age 1 to age 18. The radiographs were teleoroentgenograms in younger children and orthoroentgenograms in older children. The authors used "appropriate" conversion factors on these 6-foot films to arrive at true femoral and tibial length. Recorded femoral length was "from the proximal articulating surface of the capital epiphysis to the most distal point on the lateral condyle" and recorded tibial length was "from the mid-point of a line drawn across the proximal condyles to the mid-point of the distal articulating surface." The data were used to generate the "Length of Femur and Tibia" graphs for boys and girls based on their chronological age (Tables 23-3 and 23-4). (These values are represented graphically in Figs. 23-14A and B.) An appreciation of the difficulty in reconciling maturation and relative height can be seen in the example they gave (Fig. 23-15): longitudinal follow-up of a boy with hemihypertrophy showed a "dip" from 1 SD above the norm to the norm during a period of presumed "delayed" maturation. Thus, assessment during adolescence only would give a false picture of the individual's percentile length of the femur and tibia and would therefore lead to an underestimation of the amount of growth remaining during that time.

MENELAUS METHOD. Menelaus²⁹¹ in 1966 reported on his experience with the White method (reported by White and Stubbins in 1944⁴⁵⁴) and reaffirmed this experience in 1981.⁴⁵³ White had originally suggested that the distal femur grew $\frac{3}{8}$ inch and the proximal tibia grew $\frac{1}{4}$ inch per year, with

growth in boys stopping at age 17 and in girls at age 16. Menelaus modified that assumption of growth cessation to 16 for boys and 14 for girls (Fig. 23-16). The results at skeletal maturity in 44 children who had undergone 53 epiphysiodeses were reported. They used Phemister's technique and immobilization in plaster for 6 weeks. At skeletal maturity, 52 percent of the patients had leg length inequality within $\frac{1}{4}$ inch of calculated, 41 percent within $\frac{3}{4}$ inch, and 7 percent had residual discrepancy of more than $\frac{3}{4}$ inch. Menelaus stated that 89.6 percent of Green and Anderson's patients were within $\frac{1}{2}$ inch of the calculated discrepancy,¹⁷⁰ compared to 80 percent of Menelaus's.

MOSELEY STRAIGHT LINE GRAPH. Moseley in 1977 described a straight-line graph method for calculating the ultimate discrepancy in the skeletally immature child and determining the timing of long-leg epiphysiodesis to correct leg length inequality.³¹¹ His method was further discussed in other publications.^{310,312-315} The graph was constructed by mathematical re-analysis of Anderson, Messner, and Green's chronological growth data on the length of the femur and tibia in normal boys and girls as published in 1964.¹⁴ The purpose of Moseley's graph was to simplify and improve the accuracy of calculations intended to estimate ultimate discrepancy in growing children by incorporating skeletal maturation based on hand-wrist bone films, growth inhibition, and relative size into the calculations. In his words, "the growth of the legs can be represented by straight lines by a suitable manipulation of the scale of the abscissa."³¹¹ As a consequence, with the nomogram of skeletal age to correct for percentile growth (i.e., relative size and skeletal maturation), the growth of the short leg is also represented as a straight line, the leg length inequality is represented as the vertical distance between the lines, the line indicating the growth of the shorter leg will have a less steep slope compared to the

TABLE 23-3 Longitudinal Growth Data, Femur and Tibia—Boys

Femur (cm)			
No.	Age (yr)	Mean	σ_d
21	1	14.48	0.628
57	2	18.15	0.874
65	3	21.09	1.031
66	4	23.65	1.197
66	5	25.92	1.342
67	6	28.09	1.506
67	7	30.25	1.682
67	8	32.28	1.807
67	9	34.36	1.933
67	10	36.29	2.057
67	11	38.16	2.237
67	12	40.12	2.447
67	13	42.17	2.765
67	14	44.18	2.809
67	15	45.69	2.512
67	16	46.66	2.224
67	17	47.07	2.051
67	18	47.23	1.958
Tibia (cm)			
No.	Age (yr)	Mean	σ_d
61	1	11.60	0.620
67	2	14.54	0.809
67	3	16.79	0.935
67	4	18.67	1.091
67	5	20.46	1.247
67	6	22.12	1.418
67	7	23.76	1.632
67	8	25.38	1.778
67	9	26.99	1.961
67	10	28.53	2.113
67	11	30.10	2.301
67	12	31.75	2.536
67	13	33.49	2.833
67	14	35.18	2.865
67	15	36.38	2.616
67	16	37.04	2.412
67	17	37.22	2.316
67	18	37.29	2.254

Note: Data were obtained in 67 healthy boys and 67 healthy girls on their birthdays (i.e., chronological age) from age 1 to age 18, in a separate population from the one used to derive the growth data shown in Table 23-2.

From Anderson M, Messner MB, Green WT: Distribution of lengths of the normal femur and tibia in children from one to eighteen years of age. *J Bone Joint Surg* 1964;46-A:1198.

longer, and the growth inhibition effected by epiphysiodesis can be indicated by altering the growth inhibition (slope of growth of the longer leg) by the expected amount, based on the type of epiphysiodesis performed. The reader should note that the reference line in Moseley's straight-line graph refers to the growth of the *normal* leg rather than the *long* leg. This has some importance in that in cases of overgrowth (such as hemihypertrophy) the abnormal leg should be plotted *above* the normal, shorter leg; this has some slight impact

on subsequent depiction of the limbs, the projected final discrepancy at maturity, and the timing of epiphysiodesis.^{310,312-315} (See Plate 23-1 for a detailed discussion of the application of the straight-line graph method of Moseley.) Moseley found in a review of 23 skeletally mature patients who had undergone epiphysiodeses for leg length inequality that his straight-line graph method yielded a mean error in prediction of ultimate leg length inequality of 0.6 cm,

TABLE 23-4 Longitudinal Growth Data, Femur and Tibia—Girls

Femur (cm)			
No.	Age (yr)	Mean	σ_d
30	1	14.81	0.673
52	2	18.23	0.888
63	3	21.29	1.100
66	4	23.92	1.339
66	5	26.32	1.437
66	6	28.52	1.616
67	7	30.60	1.827
67	8	32.72	1.936
67	9	34.71	2.117
67	10	36.72	2.300
67	11	38.81	2.468
67	12	40.74	2.507
67	13	42.31	2.428
67	14	43.14	2.269
67	15	43.47	2.197
67	16	43.58	2.193
67	17	43.60	2.192
67	18	43.63	2.195
Tibia (cm)			
No.	Age (yr)	Mean	σ_d
61	1	11.57	0.646
67	2	14.51	0.739
67	3	16.81	0.893
67	4	18.86	1.144
67	5	20.77	1.300
67	6	22.53	1.458
67	7	24.22	1.640
67	8	25.89	1.786
67	9	27.56	1.993
67	10	29.28	2.193
67	11	31.00	2.384
67	12	32.61	2.424
67	13	33.83	2.374
67	14	34.43	2.228
67	15	34.59	2.173
67	16	34.63	2.151
67	17	34.65	2.158
67	18	34.65	2.161

Note: Data were obtained in 67 healthy boys and 67 healthy girls on their birthdays (i.e., chronological age) from age 1 to age 18, in a separate population from the one used to derive the growth data shown in Table 23-2.

From Anderson M, Messner MB, Green WT: Distribution of lengths of the normal femur and tibia in children from one to eighteen years of age. *J Bone Joint Surg* 1964;46-A:1199.

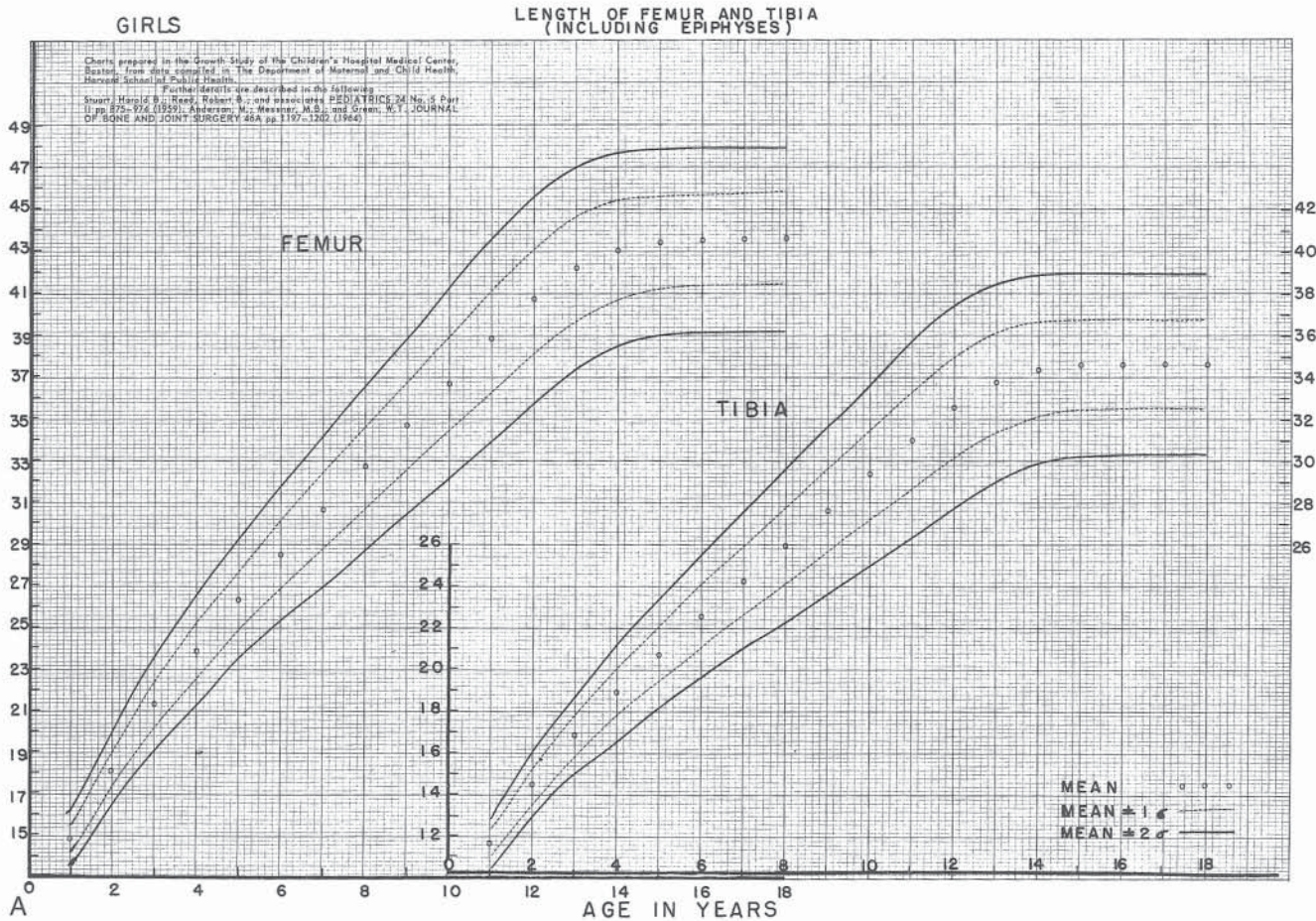


FIGURE 23-14 Average total length of the femur and tibia with 1 and 2 SD range in girls and boys, based on chronological age, as provided by Green and Anderson. A, Girls. (Courtesy of Drs. M. Anderson, M. B. Messner, and W. T. Green.)

Illustration continued on following page

compared to a mean error of 0.9 cm when the Green-Anderson growth remaining method was used.³¹¹

Some assumptions are incorporated into the construction and use of Moseley's straight-line graph. Skeletal age-determined lengths of the femur and tibia do not exist from Anderson and Green's data prior to skeletal age 8,^{13,14} and thus the younger skeletal age nomograms presumably are extrapolations. Moseley pointed out that he assumed that individual patients maintained the same percentile skeletal age, but acknowledged that this is not necessarily the case. In fact, Anderson and colleagues pointed out that there is a tendency for longer femora to grow less and shorter femora to grow more with subsequent maturation (which is one of the reasons why the Menelaus modification of the White-Stubbins method has accuracy comparable to that of the Moseley method).¹³ Finally, the straight-line determination of growth of the shorter (abnormal) leg presumes that the growth inhibition is linear; however, as both Moseley³¹¹ and Shapiro³⁸⁴ have pointed out, that is not necessarily the case. Despite these problems, the accuracy of this method in practice is generally good, and it is the method routinely used at our institution to determine leg length inequality at skeletal maturity and the appropriate timing of epiphysiodesis of the long leg.

Summary of Growth Remaining and Timing of Epiphysiodesis Methods. There are several areas of potential inaccuracy in the application of published longitudinal growth data on the legs and calculation methods of growth remaining made to determine the timing of epiphysiodesis for leg length inequality. Identification of the cause of leg length inequality in children is important to determining the ultimate discrepancy at skeletal maturity. Total physal destruction from infection, fracture, irradiation, or surgical ablation will result in fairly predictable growth retardation from loss of growth of the affected physis for the duration of skeletal growth remaining. Congenital limb deficiencies characteristically exhibit a consistent growth inhibition of the affected leg, so that the percentage shortening remains fairly constant during skeletal growth as the absolute amount of discrepancy increases. However, Shapiro has pointed out that not all growth inhibitions in growing children may be linear (i.e., have a constant percentage growth inhibition or acceleration in the affected limb), as implied by the graphic methods of calculation of ultimate leg length inequality described above.³⁸⁴ Eastwood and Cole noted a linear increase in discrepancy in only eight of 20 patients treated by epiphysiodesis.¹¹⁵ Shapiro described five basic patterns of leg length inequality development based on the assessment of discrep-

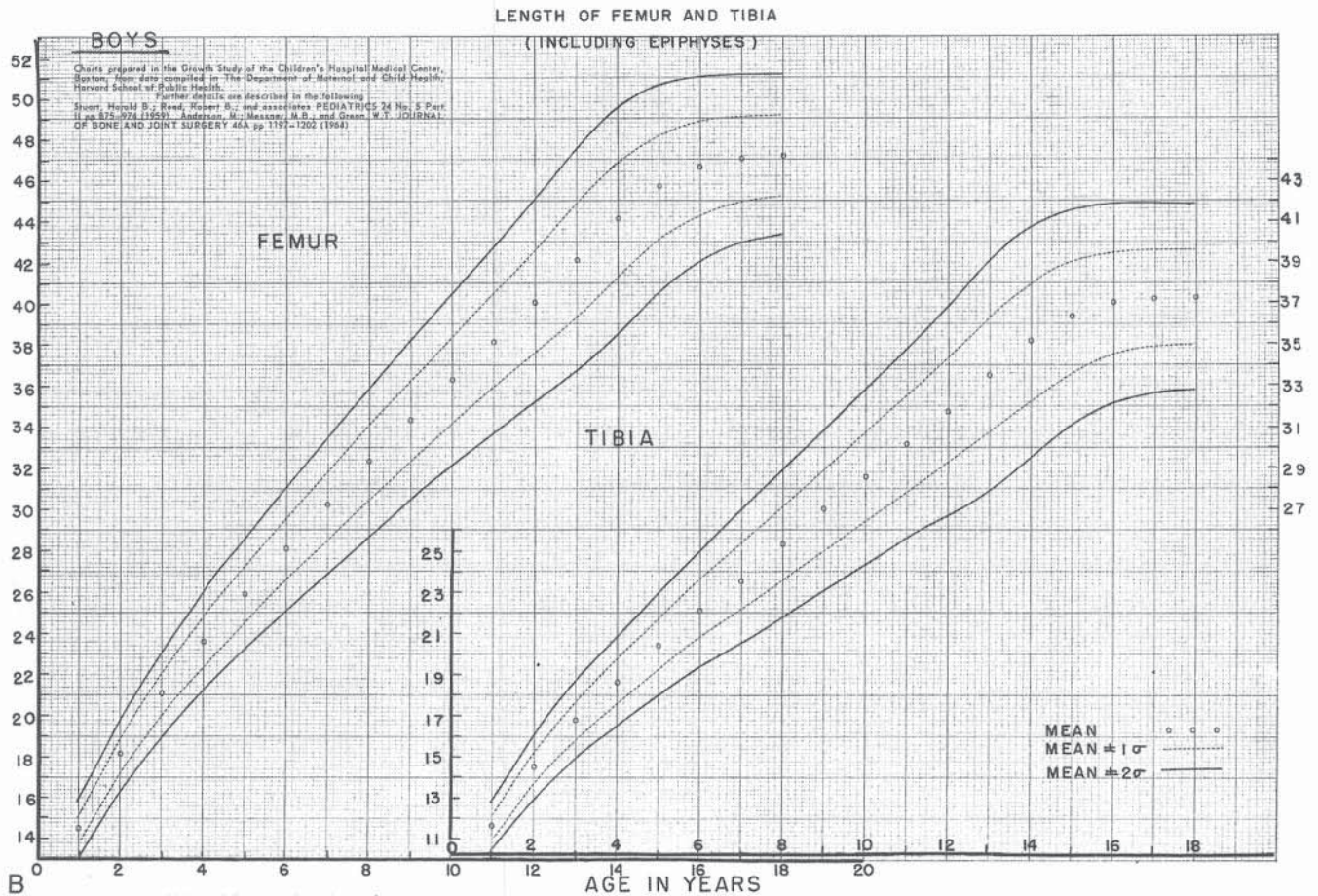


FIGURE 23-14 Continued. B, Boys. (Courtesy of Drs. M. Anderson, M. B. Messner, and W. T. Green.)

ancy development in 803 patients (Fig. 23-17).³⁸⁴ Type 1 is an upward slope pattern, implying a stable percentage growth inhibition compared to the normal leg. Type 2 is characterized by an upward slope-deceleration pattern. Type 3 is characterized by an upward (or downward) slope-plateau pattern and was most typical of post-femoral shaft fracture overgrowth. In Shapiro's series, growth in 85 percent of patients with overgrowth had plateaued by $3\frac{1}{2}$ years after fracture. Type 4 is an upward slope-plateau-upward slope pattern and was seen only in abnormalities involving the proximal femur, such as septic arthritis, Legg-Perthes disease, and avascular necrosis (AVN) associated with the treatment of developmental dysplasia of the hip. Type 5 is characterized by an upward slope-plateau-downward slope pattern, meaning that an initially increasing discrepancy actually decreased with subsequent growth. In Shapiro's series, the type 1 growth pattern was typical of patients with proximal femoral focal deficiency, Ollier's disease (enchondromatosis), congenital femoral deficiency with more than 6 cm of shortening, physeal obliteration from any cause, and poliomyelitis. Some patients with congenital femoral deficiency with less than 6 cm of shortening or with poliomyelitis tended to exhibit a type 2 pattern. Patients with idiopathic hemihypertrophy or hemiatrophy demonstrated type 1, 2, or 3 patterns. Only 31 percent of patients with overgrowth associated with vascular anomalies demonstrated type 1 growth, the remainder following a type 2 or 3 pattern.

Patients with neurofibromatosis most commonly demonstrated a type 1 pattern, but types 2, 3, and 5 were also seen. Similarly, patients with juvenile arthritis exhibited types 1, 2, 3, and 5 patterns. Patients with Legg-Perthes disease exhibited all five patterns.

Prediction of leg length inequality based on serial scanograms, hand and wrist radiographs for skeletal age, and straight-line graph analysis (Figs. 23-18 and 23-19) have other potential pitfalls as well.* Kasser and Jenkins, in a study of normal leg growth in normal children between the ages 5 and 10, found that, except in girls with advanced bone age, using Greulich and Pyle's atlas in preference to chronological age did not improve the accuracy of prediction of leg length at skeletal maturity.²³⁹ There was a mean error of 2.4 cm by the Anderson-Green method and 2.6 cm by the Moseley straight-line graph when the prediction was based on skeletal age. Blair and colleagues found that only 22 of 67 patients treated by epiphysiodesis had a final discrepancy of less than 1 cm.⁴⁸ Ten of the 45 failures were due to inadequate epiphysiodesis and 35 to incorrect use of the Green and Anderson growth prediction charts. Little and colleagues also found that use of Greulich and Pyle's atlas and either the Anderson-Green charts or Moseley's straight-line graph did not improve the accuracy of prediction over use of the Menelaus method alone, which used

* See references 41, 48, 74, 96, 109, 115, 197, 239, 255, 269.

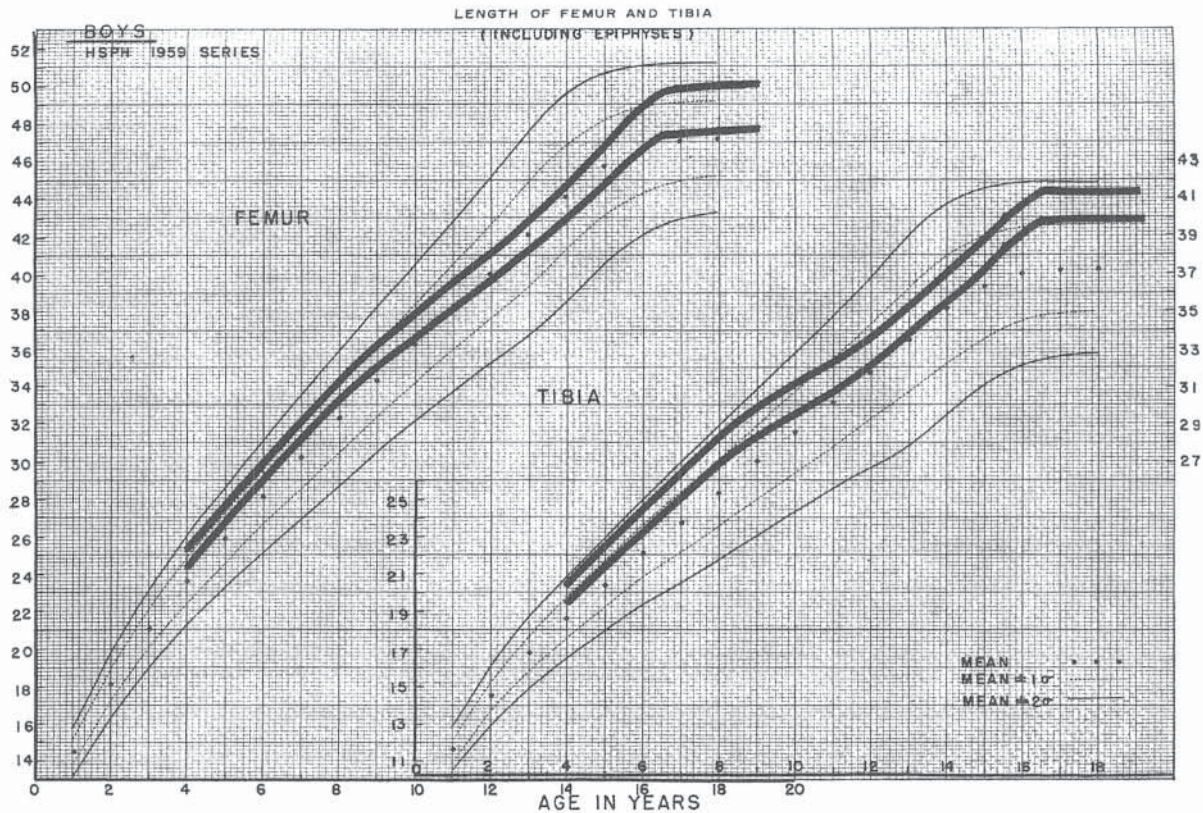


FIGURE 23-15 Example of change in percentile length of both femora and tibiae of a patient followed for hemihyper trophy by Anderson and colleagues. As they noted, if only one examination had been performed when the patient was an adolescent, a false impression of 50th percentile length would have been concluded, resulting in an underestimation of the ultimate discrepancy. This example points to the need for and value of longitudinal follow-up to gain an overall impression of the maturation and relative size of each patient. (From Anderson M, Messner MB, Green WT: Distribution of lengths of normal femur and tibia in children from one to eighteen years of age. *J Bone Joint Surg* 1964;46-A:1200-1201.)

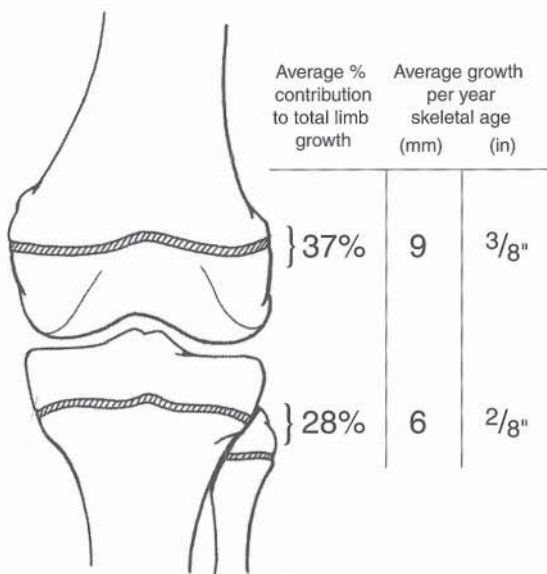


FIGURE 23-16 Approximate percentage contribution to total leg length increase and average growth per skeletal year of maturation (in millimeters and inches) of the distal femoral and proximal tibial physes.

chronological age.²⁶⁹ Lampe and colleagues found that nine of 30 patients treated by epiphysiodesis based on Moseley straight-line graph predictions had a discrepancy of more than 1.5 cm at skeletal maturity, including one patient operated on twice.²⁵⁵ They concluded that the pattern of skeletal maturation limited the accuracy of the method. Beumer and colleagues, in a study of the growth of 182 Dutch children between 1979 and 1994, found that mean femoral and tibial length had increased, compared to the Anderson-Green data.⁴¹ They modified the Moseley straight-line graph based on this information and the use of skeletal age. In a study of 34 patients treated by epiphysiodesis, they found that the new graph better predicted limb length at maturity in 22 and yielded comparable results in five when compared with predictions made using the Moseley straight-line graph. Carpenter and Lester evaluated skeletal age (according to Greulich and Pyle's atlas) in the distal radius and ulna, carpus, and metacarpals and phalanges on 100 hand and wrist radiographs of 45 children less than 10 years old.⁷⁴ They found significant discrepancies between skeletal and chronological age between the regions of the hand and between sexes. Cundy and colleagues assessed variations in the designation of skeletal age in 60 radiographs by four radiologists using Greulich and Pyle's atlas.⁹⁶ They found that 50 percent of children were assigned a skeletal age that differed by more than 1 year, and 10 percent varied by more than 2 years. As Jean-Luc Ferron of Montpellier, France, has pointed out,

Straight-Line Graph for Leg-Length Discrepancy

A to E, Technique of femoral lengthening over an intramedullary femoral nail as described by Paley and colleagues. (From Moseley CF: A straight-line graph for leg-length discrepancy. *J Bone Joint Surg* 1977;59-A:177.)

PLATE 23-1. Straight-Line Graph for Leg-Length Discrepancy



THE DEPICTION OF PAST GROWTH

1 At each visit to the hospital obtain these three values:

1. The length of the normal leg measured by orthoroentgenogram from the most superior part of the femoral head to the middle of the articular surface of the tibia at the ankle.
2. The length of the short leg, and
3. The radiologic estimate of skeletal age.

2 Place the point for the normal leg on the 'normal leg' line at the appropriate length.

3 Draw a vertical line through that point the entire height of the graph and through the skeletal age 'scalar' area of either boys or girls as the case may be. This line represents the current skeletal age.

4 Place the point for the short leg on the current skeletal age line at the correct length.

5 Mark the point where the current skeletal age line intersects that sloping 'scalar' in the skeletal age area which corresponds to the radiologic estimate of skeletal age.

6 Plot successive sets of three points in the same fashion.

7 Draw the straight line which best fits the points plotted previously for successive lengths of the short leg.

DISCREPANCY— is represented by the vertical distance between the two growth lines.

INHIBITION— is represented by the difference in slope between the two growth lines, taking the slope of the normal leg as 100%



THE EFFECT OF SURGERY

EPIPHYSEODESIS

1 Ascertain the length of the normal leg just prior to surgery, and mark that point on the normal leg line.

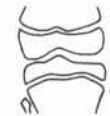2* From that point draw a line parallel to the reference slope for the particular growth plates fused. This is the new growth line for the normal leg.

Reference slopes

* The growth plates each make a known contribution to the total growth of the leg.

Distal femur—37%

Proximal Tibia—28%



65%—both

•• The percentage decrease in slope of the new growth line (taking the previous slope as 100%) exactly represents the loss of the contribution of the fused growth plates.

LENGTHENING

3 Draw the new growth line for the lengthened leg exactly parallel to the previous growth line but displaced upwards by a distance exactly equal to the length increase achieved. Since the growth plates are not affected neither is the growth rate, and the slope of the line is therefore unchanged.



THE PREDICTION OF FUTURE GROWTH

1* Extend to the right the growth line of the short leg.

2* Draw the horizontal straight line which best fits the points plotted previously in the skeletal age area.

GROWTH PERCENTILE— is represented by the position of that horizontal line and indicates whether the child is 'taller' or 'shorter' than the mean.

SKELETAL AGE SCALE— is represented by the intersections of this horizontal line with the scalars in the skeletal age area.

The **Maturity Point** is the intersection of the line with the maturity scalar.

3* Through the maturity point draw a vertical line, the **Maturity Line**. This line represents maturity and the cessation of growth. Its intersections with the growth lines of the two legs represents their anticipated lengths at maturity.

Maturity point.
Anticipated discrepancy at maturity.

* In keeping a child's graph up to date it is recommended that these lines be drawn in pencil. The addition of further data makes this method more accurate and may require slight changes in the positions of these lines.



THE TIMING OF SURGERY

EPIPHYSEODESIS

1 Project the growth line of the short leg to intersect the maturity line, taking into account the effect of a lengthening procedure if necessary.

2 From the intersection with the maturity line draw a line whose slope is equal to the reference slope for the proposed surgery.

3 The point at which this line meets the growth line of the normal leg indicates the point at which the surgery should be done. Note that this point is defined, not in terms of the calendar, but in terms of the length of the normal leg.

Since lengthening procedures do not affect the rate of growth, the timing of this procedure is not critical and will be governed by clinical considerations.

LENGTHENING



POST-SURGICAL FOLLOW-UP

1 Draw the new growth line of the normal leg as shown in section 'C'.

2 Data is plotted exactly as before except that the length of the short leg is plotted first and is placed on the growth line previously established for the short leg.

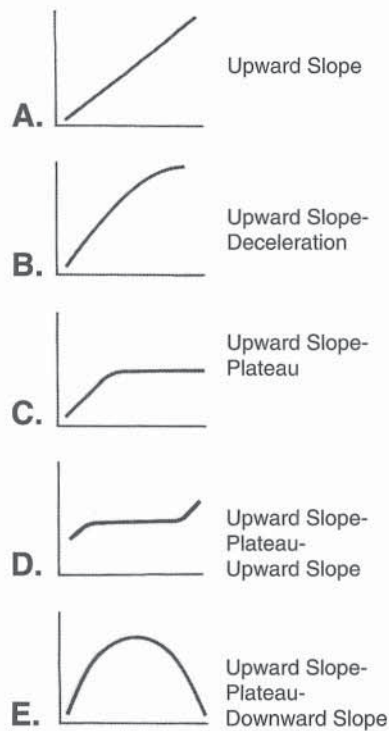


FIGURE 23-17 Five patterns of altered limb growth as described by Shapiro. **A**, Upward slope pattern. This suggests a consistent rate of growth inhibition of the shorter leg. **B**, Upward slope–deceleration pattern. The rate of growth inhibition decreases over time. **C**, Upward slope–plateau pattern. After an initial constant growth inhibition, the legs grow at the same rate (plateau). **D**, Upward slope–plateau–upward slope pattern. A constant rate of growth inhibition is interrupted by a period of growth at the same rate. **E**, Upward slope–plateau–deceleration pattern. The slower-growing limb exhibits an initial growth deceleration followed by symmetric growth and finally increased growth compared to the contralateral limb.

the standard deviation of Greulich and Pyle's atlas is "plus or minus one page."²¹²⁶

TREATMENT OF LEG LENGTH INEQUALITY

Indications. Traditionally, orthopaedists have been taught that leg length inequality greater than 2 to 2.5 cm should be treated by some form of equalization. From a review of the literature it is difficult to justify this figure as an absolute, above which treatment is indicated. Patients with discrepancies of more than 5 percent (corresponding to approximately 4 cm at skeletal maturity in 50th percentile patients) and those who compensate for leg length inequality by toe-walking have been shown in the gait laboratory to have appreciable alteration in gait mechanism and energy consumption. Thus, this is certainly an absolute level above which limb length equalization by some means should be achieved. Treatment of lesser discrepancies in the absence of other deformity in the limb is based on considerably softer evidence of short- or long-term dysfunction in the affected patient. The wise orthopaedist will carefully assess the impact of leg length inequality in each individual and that person's concerns regarding the leg length inequality in determining the best treatment. I have found it helpful

to ask adolescents to wear a shoe lift corresponding to 5 mm less than their discrepancy for a brief period to provide them with a sense of what correction will provide them in situations where the need for treatment is equivocal (usually in the 2 to 2.5 cm range). This will help the surgeon and patient decide whether shortening or epiphysiodesis is indicated. Treatment options for the management of leg length inequality and indications for each are summarized in Table 23-5.

Orthotic Management. In theory, any leg length inequality could be managed with a lift of appropriate size applied to the sole or within the shoe. Interestingly, only rarely is this acceptable to the patient as a long-term solution for the treatment of leg length inequality, and the child and parents are almost always willing to proceed with any appropriate surgical procedure that obviates the use of a lift.

The indication for use of a shoe lift, even in the short term, is not clearcut and is controversial. There is little evidence to support the presumption that the use of a shoe lift provides any short- or long-term protective or mechanical benefits.^{36,61,95,277,377} We consider a lift when a child begins to toe-walk, which is usually when leg length inequality reaches 5 percent of the contralateral side, since increased work of the long leg at this point has been documented.⁴⁰³ A lift of up to 1 cm can be incorporated into most shoes; larger ones do not allow the child to wear the shoe comfortably, and if a larger lift is prescribed, it must be applied to the sole of the shoe. Once the child is compensating for leg length inequality by toe-walking and other compensatory strategies, such as vaulting, circumducting, or increased flexion of the long leg, we consider not only the lift but an orthosis as well. Lifts of more than 8 cm are not easy for the patient to manage, as they may fall over the large lifts or sprain their ankles (Fig. 23-20). The addition of an ankle-foot orthosis (AFO) can be helpful in such circumstances. If the child is actually hopping on the longer leg because the shorter leg is not reaching the floor, an extension orthosis can significantly improve gait. This orthosis is a combination of a suspension component (an AFO, usually set in equinus, with an anterior shell, or more commonly a KAFO), and a shank terminating in a SACH (solid ankle-cushioned heel) prosthetic foot. This allows the patient to ambulate with a level pelvis and wear a normal shoe (Fig. 23-21).

Shortening of the Long Leg

EPIPHYSIODESIS. Phemister is credited with the first description of the technique of epiphysiodesis.³⁵¹ Many reports and modifications of the procedure have followed.* Phemister's index case was a girl he described as having "dyschondroplasia" (Ollier's disease), with shortening and curvature of the left upper and lower extremities; he "excised" the upper epiphysis of the left radius to correct the forearm deformity and the upper epiphysis of the right distal femur to arrest longitudinal growth. Phemister fused the right distal femoral physis through medial and lateral incisions, with excision of the cartilaginous disk to a depth of 1 cm with an osteotome and a bone graft slid distally from the metaphysis, when the child was 8 + 7, with a 2½-inch leg length inequality. At the age of 18, a ¾-inch elevation under the left heel

* See references 22, 23, 48, 65, 68, 70, 71, 109, 169-171, 214, 232, 255, 267, 273, 290, 291, 295, 334, 335, 348, 355, 380, 382, 416, 424, 432, 433, 454.

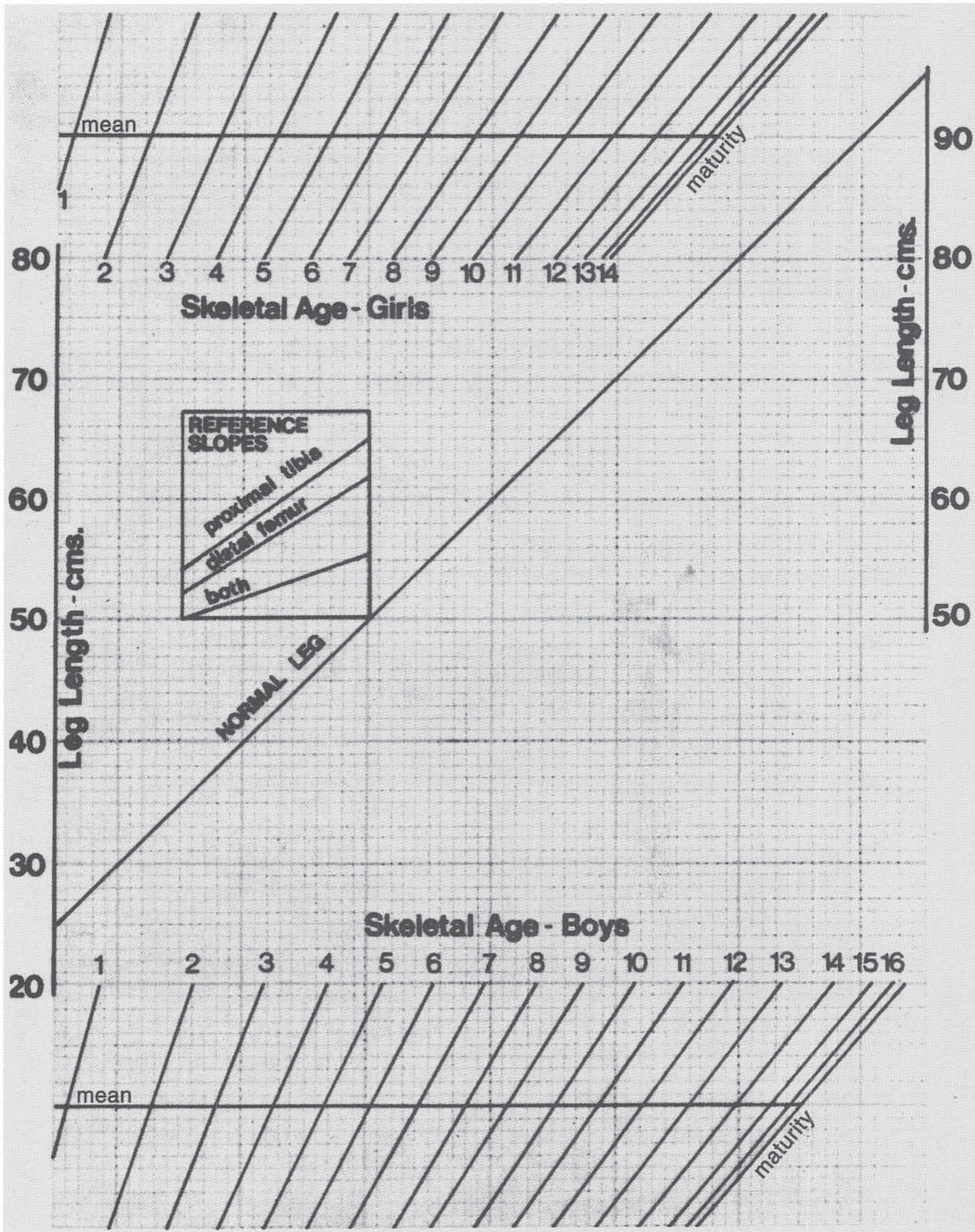


FIGURE 23-18 Moseley straight-line graph. (From Moseley CF: A straight-line graph for leg-length discrepancy. J Bone Joint Surg 1977;59-A:176.)

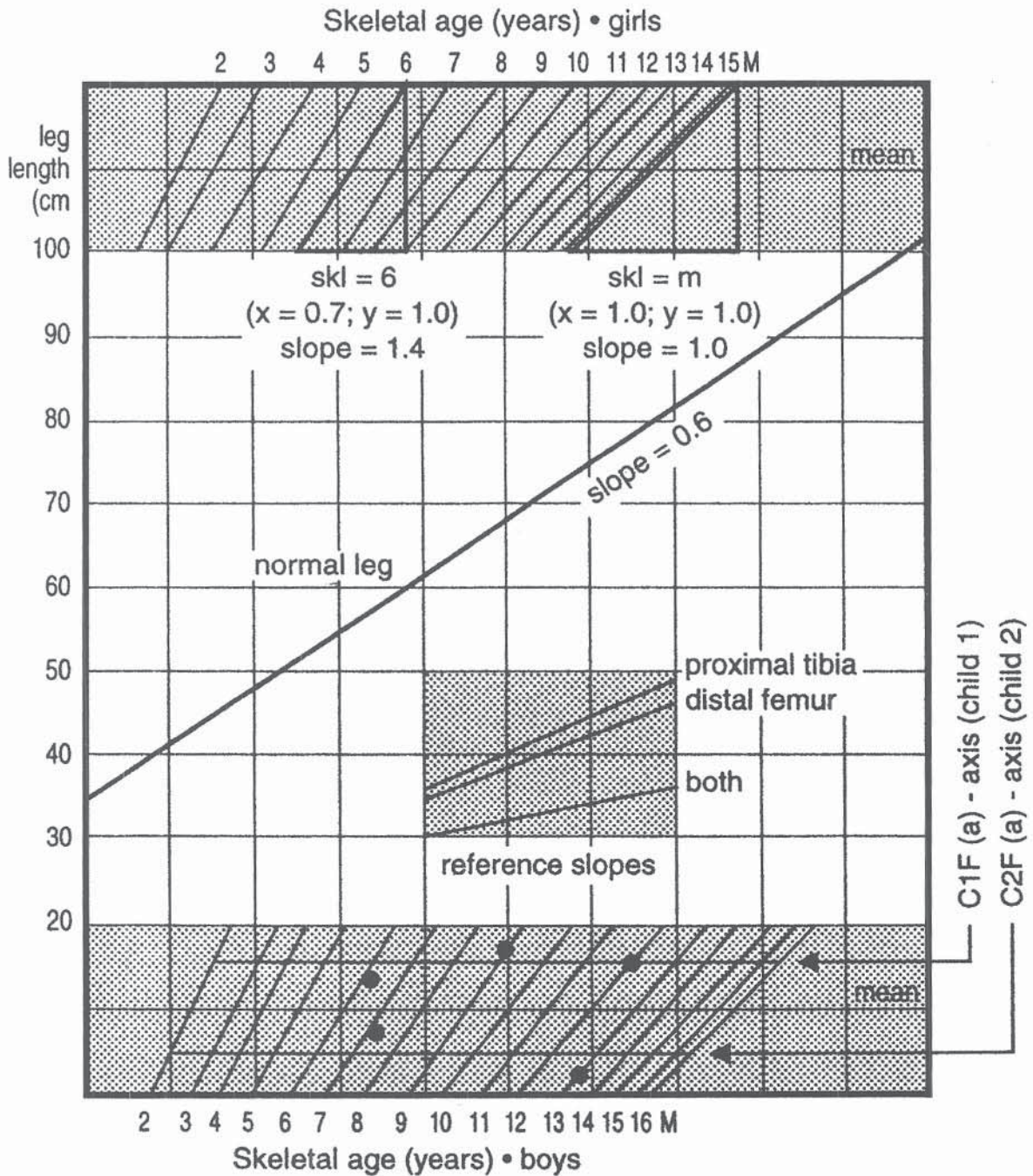


FIGURE 23-19 Rotterdam straight-line graph. This modified straight-line graph was developed using more modern growth data and was found by its originators to be more accurate in the prediction of leg length inequality and correction by epiphysiodesis than the Moseley straight-line graph. Method of use is as for the Moseley graph. See text, Figure 23-18, and Plate 23-1 (Straight-Line Graph for Leg-Length Discrepancy) for details.⁴¹

TABLE 23-5 Options and Indications for Treatment of Leg Length Inequality

Option	Indication	Contraindication
No treatment	Discrepancies < 2 cm	Shortening > 5% of contralateral limb (4 cm)
Shoe lift	Consider for discrepancies > 2 cm Recommend for toe-walkers	None
Extension orthosis or prosthesis	Child who walks with extreme long-leg knee flexion, or who hops	None
Epiphysiodesis	Predicted discrepancies > 2 cm	As sole means of correcting discrepancies > 8 cm Inadequate growth remaining
Epiphyseal stapling	Same as epiphysiodesis	Same as epiphysiodesis
Acute surgical shortening	Skeletally mature patient Femoral discrepancy 2–6 cm Tibial discrepancy 2–5 cm	Discrepancies requiring more than 6 cm of femoral or 5 cm of tibial shortening
Acute surgical lengthening	Femoral discrepancy 2–4 cm Tibial discrepancy 2–3 cm	Patients at risk for neurovascular injury or with poor bone quality
Gradual limb lengthening	Femoral discrepancy > 4 cm Leg length inequality associated with angular deformity requiring correction	Unstable joints associated with bone segment to be lengthened Noncompliant patient

“completely [did] away with” the residual discrepancy, although he measured the discrepancy at 2.5 cm. He reported on 20 further patients treated by epiphysiodesis for leg length inequality, describing the surgical technique and diagramming the procedure (Fig. 23-22). A piece of cortex 3 × 1–1.5 cm and 1 cm deep was removed, and the underlying epiphysis was excised to a depth of 1 cm. The piece of cortex was replaced with its ends reversed. White and Stubbins modified the technique, using a ½-inch osteotome to fashion a ½- to 1-inch square straddling the physis in a diamond position, curetting the physis exposed by this plug, and reinserting it rotated 90 degrees from its original position (Fig. 23-23).⁴⁵⁴ They reported no deformities resulting from over

200 procedures, which were “relatively free of complications.”

Green and Anderson also provided an early report of the results of epiphysiodesis.^{169,170} In their 1947 publication,¹⁶⁹ they reported the results of 77 procedures in 50 patients performed with a variety of techniques by different surgeons in more than one center. The technique used was to create

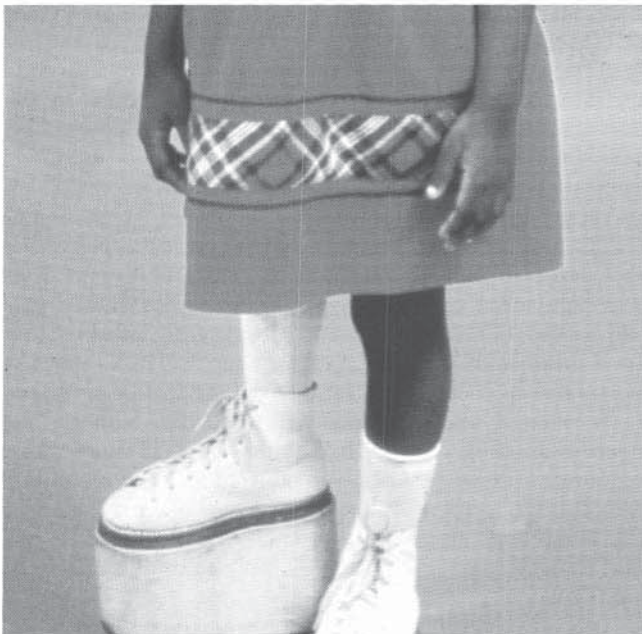


FIGURE 23-20 Large lift attached to the shoe to manage significant leg length inequality. In general, lifts of more than 8 cm are not well tolerated.

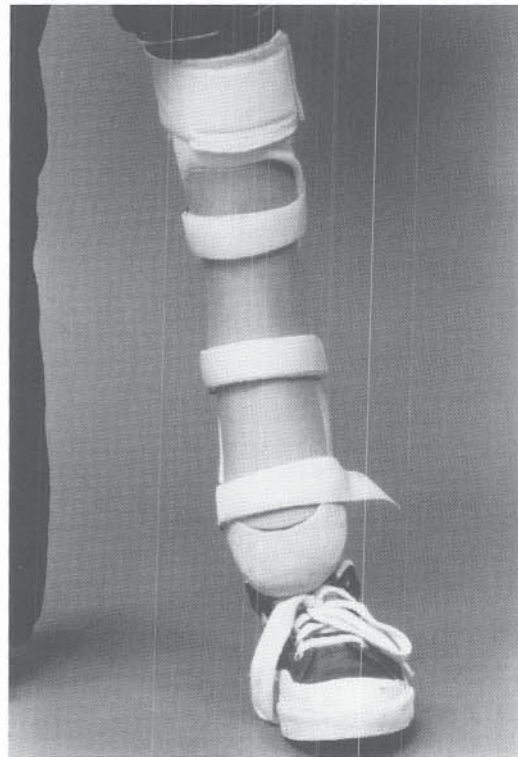


FIGURE 23-21 Once a child begins to walk with grossly exaggerated contralateral knee flexion, or hop, an extension orthosis should be considered. An AFO (usually with an anterior shell) or a KAFO is connected by a shank to a prosthetic foot (such as a SACH foot).

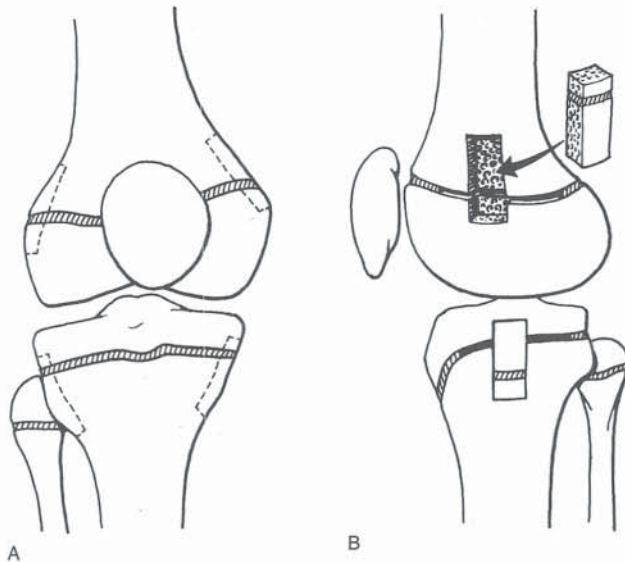


FIGURE 23-22 Phemister technique of epiphysiodesis of the distal femur and proximal tibia. A, A large rectangular bone block is removed from the lateral and medial aspect of the distal femur and/or proximal tibia. B, After the underlying physis is curetted, the bone blocks are reinserted after being rotated 180 degrees.

a “wide, thick graft extending at least one inch into the diaphysis, and at least 2 cm deep.” A hand drill was used to drill out remaining physis, and the graft was reinserted after being rotated 180 degrees. In 77 epiphysiodeses there were five cases of angular deformity developing (four requiring corrective osteotomy), one deep infection, one transient peroneal palsy, and three cases of overcorrection. In their 1957 publication, they evaluated the results of 237 epiphysi-

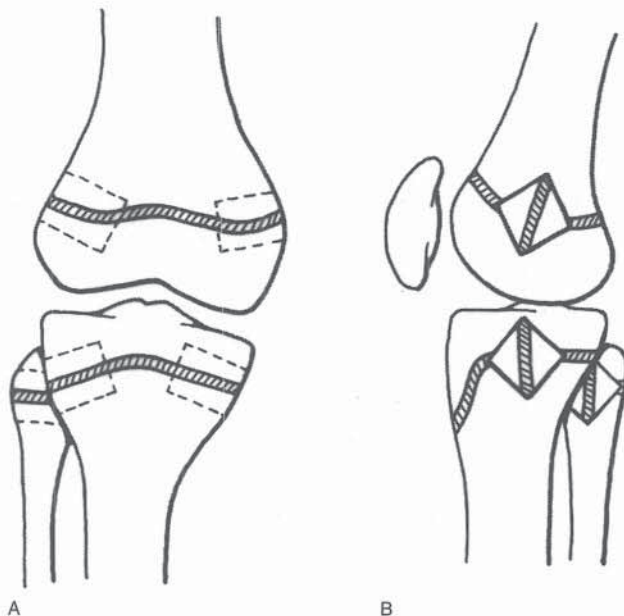


FIGURE 23-23 White and Stubbins technique of epiphysiodesis of the distal femur and proximal tibia. A, A square-sided cube of bone bridging the physis is removed. B, After the underlying physis is curetted, the cubes are rotated 90 degrees and replaced in their original beds.

odeses in 173 patients, and 83 staplings. The results of epiphysiodesis were good or excellent in the 173 epiphysiodesis patients, with few exceptions. Two had overcorrection greater than $\frac{1}{2}$ -inch, but five underwent a contralateral epiphysiodesis to prevent this from happening. Five developed angular deformity, which required a corrective osteotomy in four and a repeat epiphysiodesis in one. In one patient osteomyelitis developed. Their overall rate of complications (including slow fusion) was 9.3 percent. The Green modifications of distal femoral and proximal tibial epiphysiodesis are described in Plates 23-2 and 23-3.

Stephens and colleagues reported results in 56 patients treated by epiphysiodesis for leg length inequality during the years 1940-1976,⁴¹⁵ using the technique of White and Stubbins.⁴⁵⁴ There were no infections. Two patients had decreased sensation in the region of the infrapatellar branch of the saphenous nerve, and four patients had symptoms of chondromalacia patellae. Ten patients underwent a proximal tibial epiphysiodesis only, without concomitant epiphysiodesis of the proximal fibula; in five of these patients there was asymptomatic overgrowth of the fibula of 5 mm, with a normal appearance in the other five. Four patients (7 percent) needed further surgery, one for asymmetric fusion, two requiring the addition of a proximal tibial epiphysiodesis to improve equalization, and one requiring contralateral distal femoral epiphysiodesis to prevent overcorrection. Because they noted no problem with fibular overgrowth in their cases, Stephens and colleagues recommended that the proximal fibular physis not be epiphysiodesed if the patient had less than 3 to 4 years of skeletal growth remaining. However, I have treated two patients with symptomatic fibular head prominence and/or instability after isolated proximal tibial epiphysiodesis who met these criteria, and it is my standard to perform proximal fibular epiphysiodesis in all patients undergoing proximal tibial epiphysiodesis.

Little and colleagues noted one case each of infection, knee stiffness, and painful medial scar after a Phemister epiphysiodesis in a group of 71 patients.²⁶⁹ In addition, 14 required further surgery because of inadequate prediction of ultimate discrepancy.

Concern with the cosmetic appearance of two to four incisions around the knee has prompted interest in the percutaneous modification of epiphysiodesis.* Bowen and Johnson described a percutaneous technique of epiphysiodesis in which a portion of the physis is excised using stab incisions, curets, and fluoroscopic guidance.⁵⁸ Ogilvie and Canale and colleagues demonstrated in animal experiments that percutaneous techniques using a combination of drills and high-speed burs effectively produced the desired epiphysiodesis effect.^{71,334} This was subsequently substantiated by a number of authors in clinical series.† In all cases, a percutaneous stab incision was made directly over the physis to be ablated, and the physis was destroyed with various instruments (Fig. 23-24). It is important that an adequate amount of physis be destroyed (Bowen seeks to leave only the central one-third of the physis, others remove less), that the surgeon be attentive to the undulations of the physis, and that the physis be removed both anteroposteriorly as

* See references 22, 23, 59, 70, 71, 214, 232, 267, 269, 273, 334, 335, 355, 380, 432.

† See references 23, 70, 214, 267, 273, 335, 380, 432.

well as peripherally-centrally. Several technical variations have been described, including the use of a cannulated tube saw, cannulated reamers, reamers and curettes, and osteotomes and curettes. The proximal fibular physis can be curetted in an open fashion, percutaneously in an anterior-to-posterior direction (with care not to injure the peroneal nerve), or, according to the recommendations of Stephens and colleagues,⁴¹⁵ left intact if the patient has less than 3 to 4 years of skeletal growth remaining. Series comparing the Phemister and percutaneous techniques have noted shorter hospital stays, more cosmetic incisions, and a less frequent need for postoperative physical therapy.^{214,267,355,380} Horton and Olney noted continued growth after either percutaneous or Phemister epiphysiodesis in 13 percent and 15 percent of cases, respectively,²¹⁴ but all other authors have reported 100 percent closure rates after percutaneous epiphysiodesis, with few or no complications.*

EPIPHYSEAL STAPLING. Interest in mechanical disruption of normal physeal growth is as old as the concept of surgical epiphysiodesis as described by Phemister. Haas described the retardation of bone growth by using a wire loop around the physis in a series of animal experiments.¹⁸⁶ Successful retardation of growth in these experiments encouraged him to attempt this in five patients, two of whom, both with polio, had adequate follow-up to allow him to describe the results. In both patients stainless steel wire loops were passed around the distal femoral physis. In both patients the wire loop broke and was replaced, but retardation of growth was noted, as was resumption of growth after fracture of the wire. This suggested the reversibility of the technique, with obvious advantages. Haas subsequently conducted animal experiments using staples instead of wires, since the latter tended to break.¹⁸⁷ He noted deceleration of growth with staples if they were inserted medially and laterally. After removal of the staples, growth of the operated segment increased, but not to normal and not in all cases, suggesting a surgical injury to the physis. When the staples were inserted unilaterally, there was a global decrease in growth of the operated physis, but more on the side of staple insertion, producing an angular deformity. No clinical cases were reported by him in this publication. It was left to Blount to report the use of staples clinically.⁵² He noted that one staple inserted on either side of the physis would invariably break, two tended to bend and occasionally break, but if three were inserted, “growth will be stopped immediately and almost completely” (Figs. 23–25 and 23–26). He recommended open epiphysiodesis of the proximal fibula when tibial stapling was performed (done while the radiographs were developing!). He emphasized that the three staples should span the physis and that their position should be verified on both AP and lateral radiographs. He reported the results in 13 cases, seven treated for leg length inequality and six for angular deformity. It is difficult to determine the precise rate of complications in his patients, but he felt that this technique stopped elongation at the operate site almost immediately; that this surgery was less extensive, with a lower risk of complication than other methods; that “occasional complicating irregularities of growth following stapling” could be corrected by vigilance and rearrangement of the

staples; and that after removal of the staples, growth at the epiphysis was about the same as on the other side (sometimes faster, sometimes slower). Initially, stainless steel staples were used, but in his subsequent report, he found that vitallium staples with reinforced shoulders were superior.⁵¹ Green and Anderson, in the same publication describing the results of epiphysiodesis, evaluated 83 stapling procedures, with 61 patients having reached skeletal maturity.¹⁷⁰ Stapling was found to be effective in inhibiting growth, although the distal femur was found to grow an average of 6 mm after stapling. The incidence of complications was greater than after epiphysiodesis, but not significantly so; complications included slow arrest, asymmetric growth, and staple extrusion. There was, however, a high incidence of secondary operations after stapling, particularly in the proximal tibia. They too noted the “vagaries of growth which may occur after the removal of staples” and illustrated this with two patients, one of whom grew at the distal femoral physis 2 mm more than on the opposite side after staple removal, and another patient who did not grow at all after distal femoral stapling, resulting in 1.8 cm of overcorrection. Twenty-nine percent of the tibial staples and 14 percent of the femoral staples were removed; others were repositioned.

Bylander and colleagues, in a series of stereoscopic growth studies, found a gradual cessation of growth across the stapled physis over 6 months, accommodated by bending of the staples, which contributed to their loosening.^{66,67} Further experience with epiphyseal stapling has been described by Blount⁵¹ and others.^{135,382} Blount recommended epiphysiodesis when there was an anticipated undercorrection, preferring stapling for angular deformity of the *longer* leg, or when surgery is performed in younger children (ages 8 to 10).⁵¹ The staples should be inserted parallel to the physis, and the reinforced, smooth-tined vitallium staples used (Fig. 23–27). Blount reported that 426 operations were necessary in 185 patients, but only two patients required osteotomy for final correction. Frantz reported staple extrusion in 12 of 189 patients treated for either leg length inequality or angular deformity.¹³⁵ Sengupta and Gupta believed that this stapling is valuable in developing countries because of the relative simplicity of the procedure.³⁸² They found that 71 percent of 503 patients treated with stapling had less than 1 cm of discrepancy at skeletal maturity. Other studies have been less complimentary of the technique. May and Clements, in a review of 70 patients, noted that they had removed staples in 50, had 24 extrusions, and had knee deformity in 10.²⁸⁶ Trias and colleagues noted that six of 17 patients required osteotomy after staple removal.⁴³⁷

My experience with stapling has significantly narrowed my indications to nearly never. The procedure requires close attention to detail. Specifically, the proper staples must be used and the staples must be evenly spaced around and parallel to the physis (Fig. 23–28). The perichondrium and periosteum must not be stripped or otherwise damaged during either insertion or removal, or growth arrest may result. Careful postoperative monitoring of the patient is required. Removal of the staples after correction in a skeletally immature patient theoretically should be followed by symmetric, normal growth, without further treatment required. In practice, the surgeon is placed in the unpleasant position of watching with bated breath for evidence of either rebound overgrowth requiring further intervention or the

Text continued on page 1073

* See references 23, 147, 267, 273, 335, 355, 380, 432.

Epiphysiodesis of the Distal Femur (Green's Modification of Phemister's Technique)

OPERATIVE TECHNIQUE

A, The knee is supported in 20 to 30 degrees of flexion and the joint line is identified. First, the medial aspect of the distal femur is exposed. Beginning 1 cm superior to the joint line, a longitudinal incision about 3 cm long is made midway between the anterior and posterior margins of the femoral condyles. The subcutaneous tissue and deep fascia are divided in line with the skin incision.

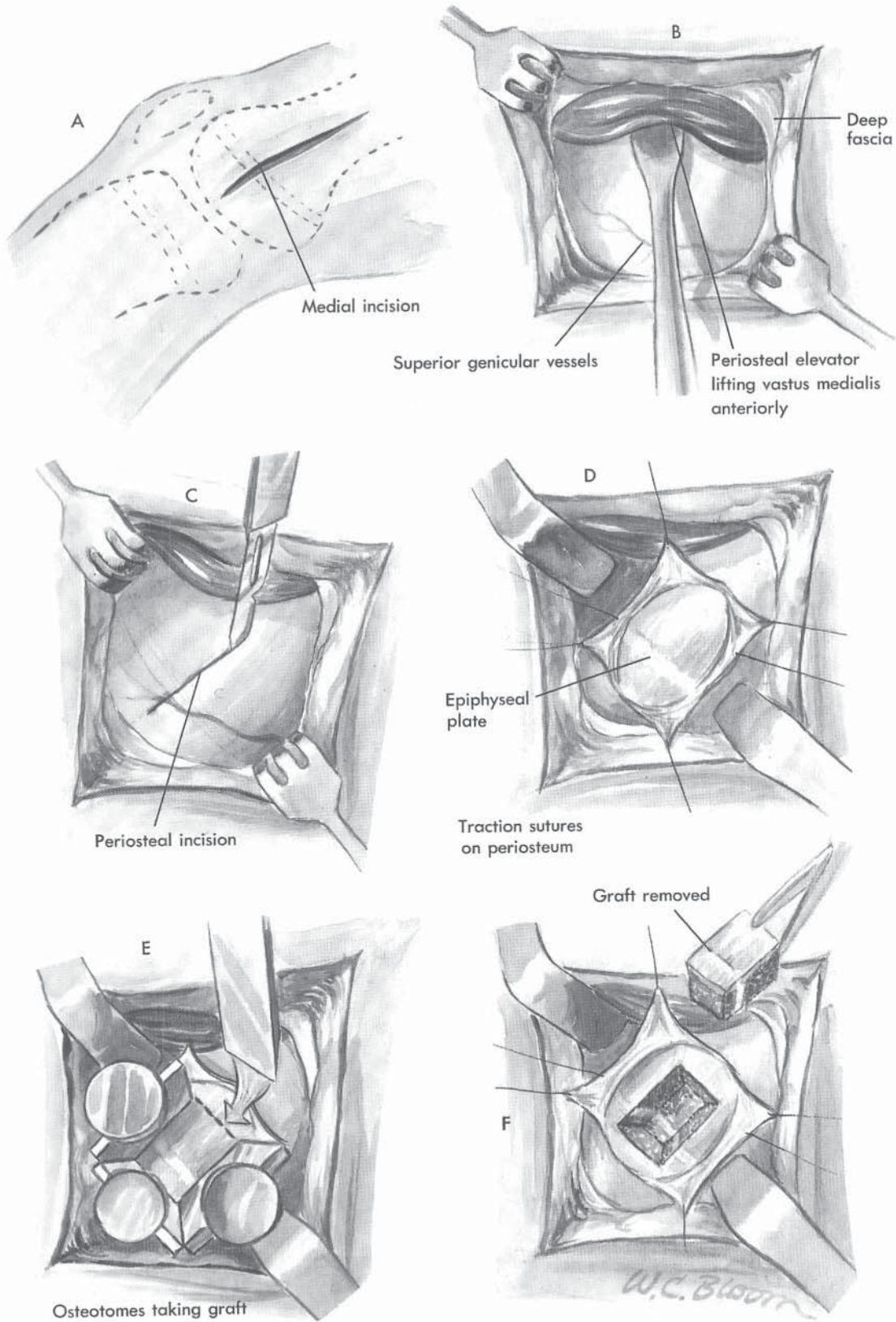
B, Following the anterior surface of the medial intermuscular septum, the vastus medialis muscle is lifted anteriorly with a blunt periosteal elevator. The suprapatellar pouch should not be entered. In the inferior margin of the wound, the capsule and reflected synovial membrane of the knee joint are gently elevated and retracted with blunt instruments distally. The superior medial genicular vessels traverse the wound; it is best to coagulate them to prevent troublesome bleeding later.

C, A midline longitudinal incision is made in the periosteum, starting proximally and extending throughout the extent of the wound.

D, The medial distal femoral physis is exposed by raising anterior and posterior flaps of periosteum by subperiosteal dissection; it appears as a white, glistening transverse line that is softer than adjacent cancellous bone. Some surgeons prefer to make a longitudinal I-shaped incision in the periosteum to expose the growth plate. The periosteum is gently retracted. Rough traction and shredding of the periosteum should be avoided. If necessary, elevators are placed subperiosteally on the anterior and posterior aspects of the distal femur for adequate exposure. Dull right-angled retractors are used for proximal and distal retraction.

E and F, With matched pairs of osteotomes, a rectangular piece of bone $1\frac{1}{8}$ to $1\frac{1}{2}$ inches long and $\frac{1}{2}$ to $\frac{3}{8}$ inch wide is excised. The epiphyseal plate should be at the junction of the distal one-third and proximal two-thirds of the length of bone graft resected, at a point equidistant between the anterior and posterior surfaces of the femur. The posterior cortex of the femur should not be broken. The depth of the bone graft is $\frac{1}{2}$ to $\frac{3}{4}$ inch. Because of the flare of the femoral condyles, the anterior and posterior osteotomes should be tilted somewhat distally so that they are perpendicular to the medial surface of the femur. Following removal of the osteotomes, the completeness of osteotomy is checked with a thin ($\frac{3}{8}$ or $\frac{1}{4}$ inch) osteotome. Then the graft is removed with curved osteotomes. Breakage of the graft at the physis is prevented by straddling the growth plate with the osteotomes.

PLATE 23-2. Epiphysiodesis of the Distal Femur (Green's Modification of Phemister's Technique)



Epiphysiodesis of the Distal Femur (Green's Modification of Phemister's Technique) *Continued*

G, The growth plate is curetted in anterior, posterior, and distal directions. It should be remembered that the distal femoral physis is pointed inferiorly. The softness of the cartilaginous plate serves as a guide to its direction. Cancellous bone graft is taken from the proximal bed and packed into the defect created by removal of the growth plate.

H, The bone graft is then reinserted into its original bed, with its ends reversed by 180-degree rotation.

I, With an impactor and mallet, the bone graft is securely seated in the bony defect. It should be tapped in a distal direction, as the growth plate is inferior in location.

J, The periosteum is tightly closed with interrupted sutures. It is important not to include the patellar retinaculum with the periosteum, as this will bind it down, restricting knee motion. Suture the periosteum with the knee in complete extension.

K, The same procedure is repeated on the lateral side.

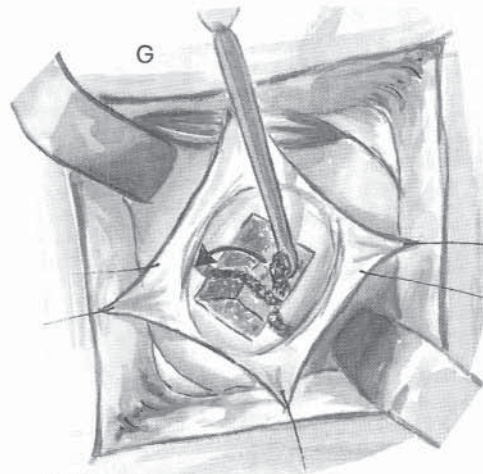
POSTOPERATIVE CARE

A compressive dressing is applied to the wounds. The limb is immobilized in a knee immobilizer in full extension. In the early postoperative period, the patient should be carefully observed for evidence of excessive swelling leading to a constrictive dressing. This is particularly likely if the patient has undergone a pangenicular epiphysiodesis or develops an acute hemarthrosis, and will necessitate splitting or loosening of the dressing.

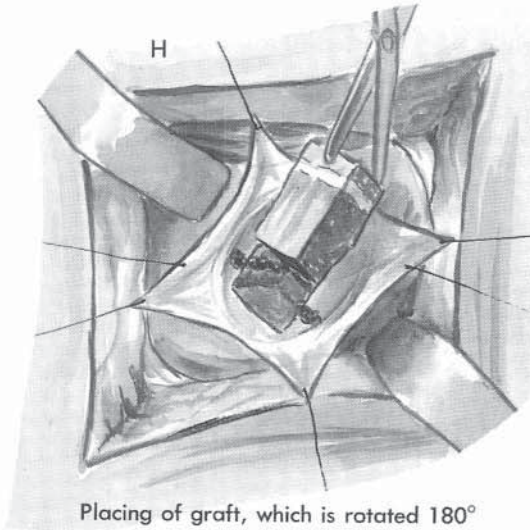
The patient is started on straight-leg-raising exercises and weightbearing as tolerated with crutches as soon as postsurgical discomfort allows. A patient with significant leg length inequality who does not normally use a shoe lift may need one if walking with the longer leg held straight in the knee immobilizer is too difficult. One week postoperatively the dressings are removed and active range-of-motion and strengthening exercises for the knee are instituted. If the patient has a large, uncomfortable hemarthrosis, it should be aspirated; smaller effusions can be ignored. The patient is evaluated between 4 and 6 weeks postoperatively to ensure that full range of motion has been recovered. Patients slow to recover knee range of motion may require supervised physical therapy. The patient is allowed to resume normal activities after recovery of knee strength and range of motion, typically 6 to 8 weeks after surgery.

The patient should be followed radiographically at appropriate intervals until skeletal maturity to document symmetric, complete surgical physeal closure and to monitor the effect of epiphysiodesis on leg length inequality.

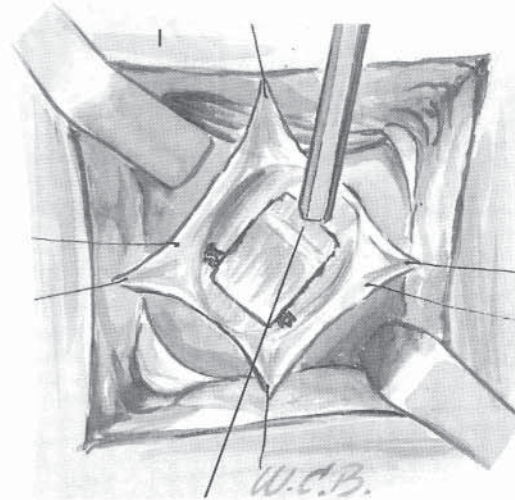
PLATE 23-2. Epiphysiodesis of the Distal Femur (Green's Modification of Phemister's Technique)



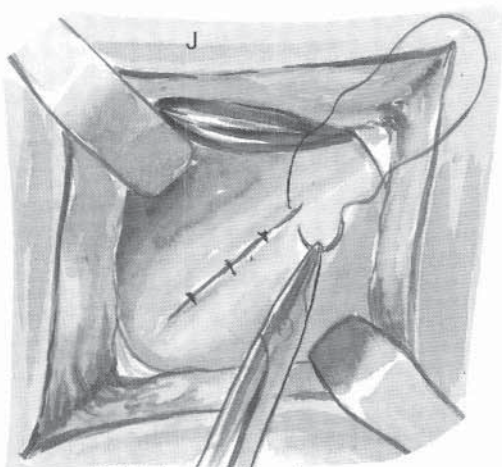
Taking cancellous bone with curet to fill area of growth plate



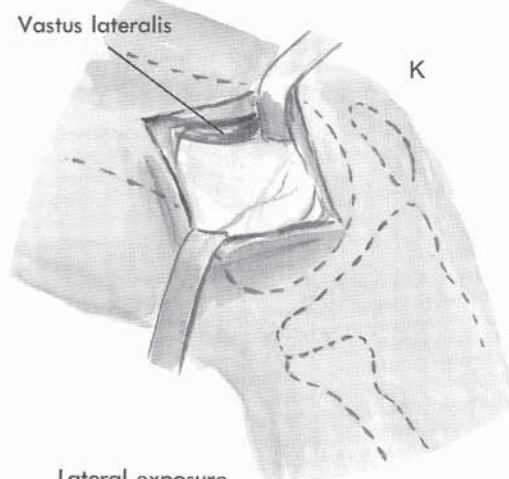
Placing of graft, which is rotated 180°



Impacting graft



Tight closure of periosteum



Lateral exposure

Epiphysiodesis of the Proximal Tibia and Fibula (Green's Modification of Phemister's Technique)

OPERATIVE TECHNIQUE

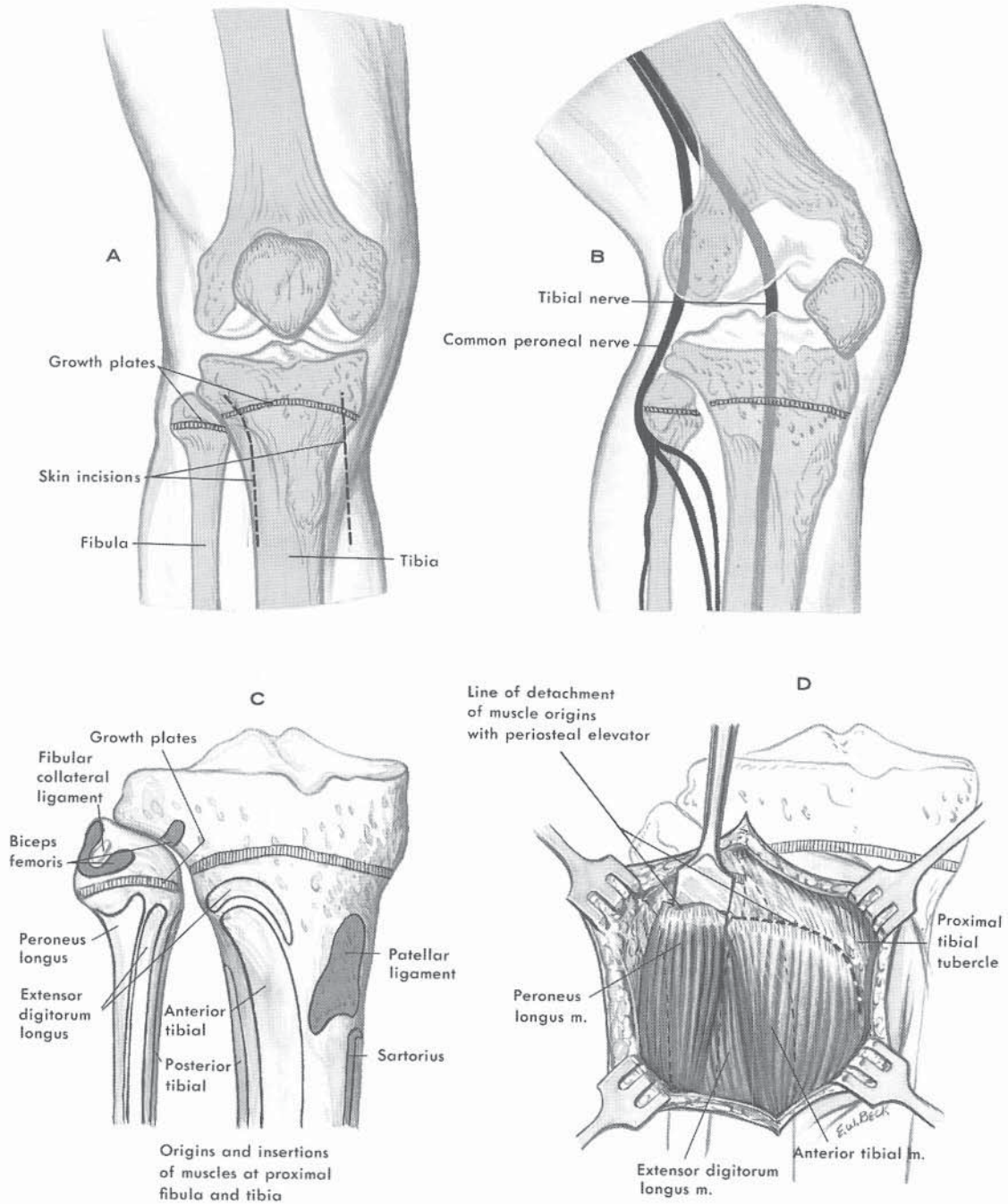
A, The patient is placed supine or in a semilateral position. A sterile folded sheet is placed under the knee for support. The knee joint line, the head of the fibula, and the proximal tibial tubercle are identified. A 30-degree slanted oblique incision is made midway between the proximal tibial tubercle and the fibular head; it begins proximally 1 cm inferior to the joint line and 1 cm anterior to the fibular head and extends distally and forward for a distance of 5 cm. The subcutaneous tissue is divided, and the wound flaps are widely undermined and retracted.

B and C, The head of the fibula is in line with the proximal growth plate of the tibia. The capsule of the knee joint, the insertion of the biceps tendon, and the fibular collateral ligament of the knee are identified.

The common peroneal nerve lies close to the medial border of the biceps femoris muscle in the popliteal fossa; then it passes distally and laterally between the lateral head of the gastrocnemius and the biceps tendon. Behind the fibular head it is subcutaneous. At the site of origin of the peroneus longus muscle at the head and neck of the fibula, the common peroneal nerve winds anteriorly around the fibular neck and then passes deep to the peroneus longus muscle and branches into the superficial and deep peroneal nerves.

D, The origins of the toe extensors, extensor hallucis longus, and anterior tibial muscles, along with a cuff of periosteal flap, are elevated from the arcuate line. With a periosteal elevator, the origin of the peroneus longus muscle is detached from the head of the fibula. Keeping the dissection anterior to the fibular head will prevent injury to the nerve.

PLATE 23-3. Epiphysiodesis of the Proximal Tibia and Fibula (Green's Modification of Phemister's Technique)



Epiphysiodesis of the Proximal Tibia and Fibula (Green's Modification of Phemister's Technique) *Continued*

E and F, The site of the growth plate of the proximal fibula is identified. Next, a longitudinal incision is made on the anterior aspect of the fibular head and extended distally to include the growth plate. Alternatively, a rectangular piece of bone ($\frac{1}{4}$ inch wide and $\frac{1}{2}$ inch long) is removed from the proximal fibula, straddling the physis. Three-fourths of the length of the bone graft includes the fibular head, so that only one-fourth of the graft length includes the metaphysis. The growth plate is thoroughly curetted, the ends of the bone graft are reversed (180 degrees), and the piece of bone is placed securely back in the graft bed. This author simply cures the growth plate from anteriorly to posteriorly.

The lateral aspect of the proximal tibial physis is already exposed for the fibular epiphysiodesis. A longitudinal incision is made midway between the anterior and posterior borders of the lateral tibia. The periosteum is elevated, and a rectangular piece of bone is resected in a manner similar to that described for the bone graft technique with the distal femur. The steps of the epiphysiodesis are the same as those outlined in Plate 23–2, G to K, for epiphysiodesis of the distal femur.

G and H, The medial side of the proximal tibial physis is exposed by a longitudinal incision about 3 cm long, beginning 1 cm distal to the joint line and continuing distally midway between the proximal tibial tubercle and posteromedial margin of the tibia. The subcutaneous tissue and deep fascia are divided in line with the skin incision. The anterior margins of the sartorius tendon and tibial collateral ligament are partially elevated and retracted posteriorly.

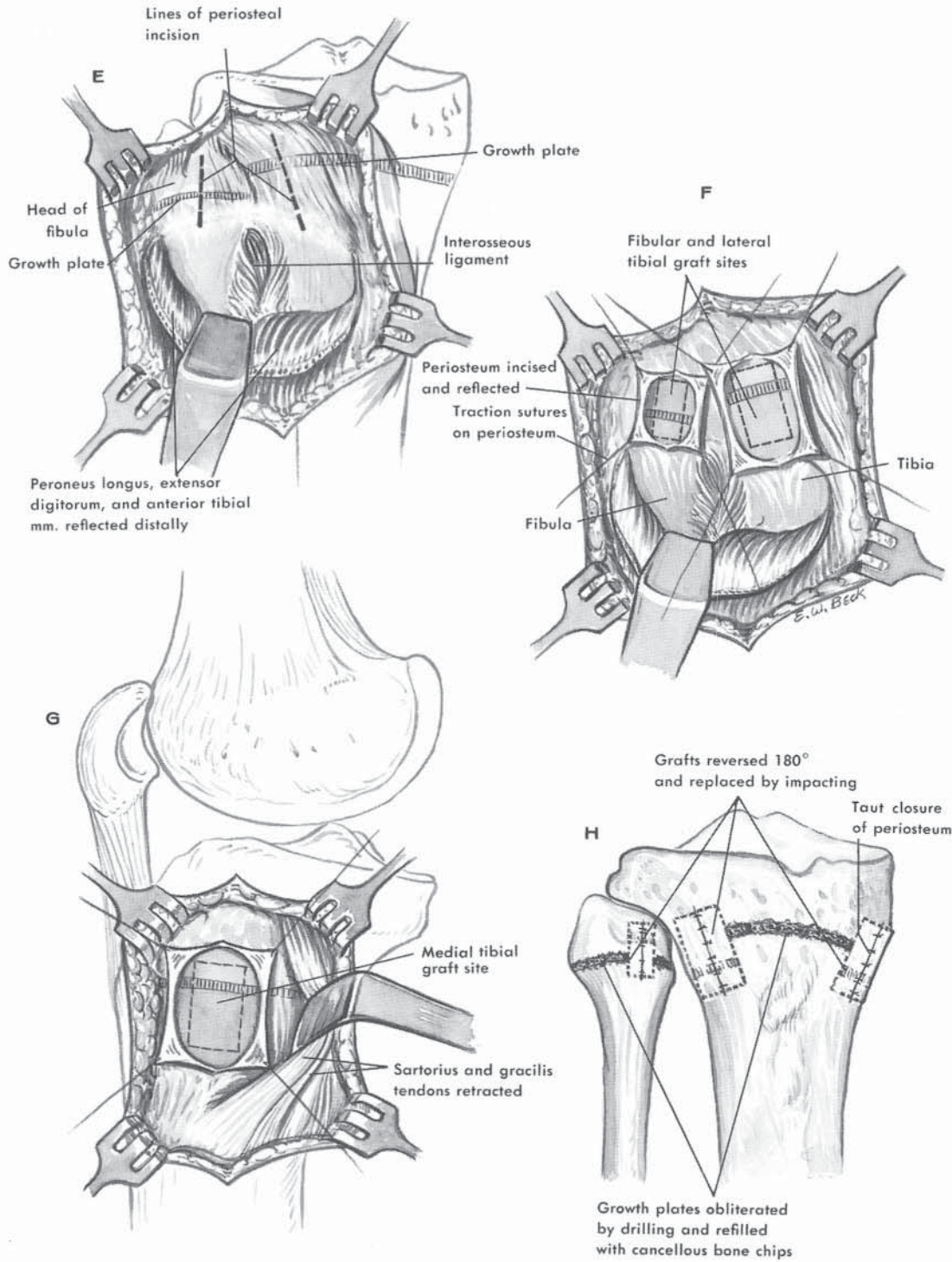
The steps for growth arrest of the proximal tibial physis follow the steps described for a distal femoral epiphysiodesis. The rectangular piece of bone graft removed from the tibia, usually $\frac{1}{2}$ inch wide and $\frac{3}{4}$ inch long, is smaller than that removed from the femur. Prior to closure of the wound, the tourniquet is released and hemostasis is secured.

POSTOPERATIVE CARE

After closure of the wound, compressive dressing and knee immobilizer are applied. Postoperative management is the same as for a distal femoral epiphysiodesis. In general, hemarthrosis is much less likely, and recovery of range of motion much more rapid and certain, after proximal tibial and fibular epiphysiodesis than after distal femoral epiphysiodesis.

PLATE 23-3. Epiphysiodesis of the Proximal Tibia and Fibula (Green's Modification of Phemister's Technique)

EPIPHYSIODESIS OF PROXIMAL TIBIA AND FIBULA (continued)



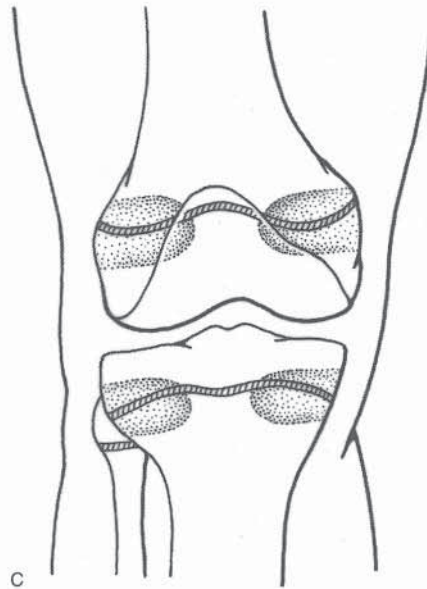
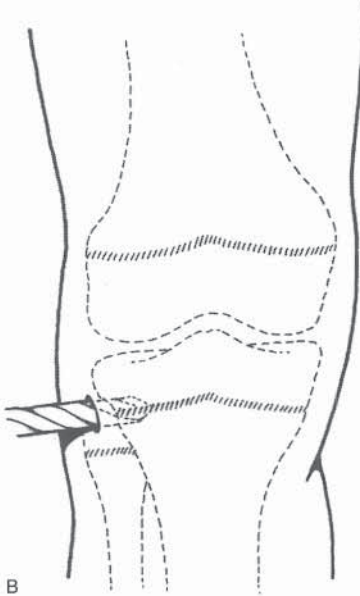
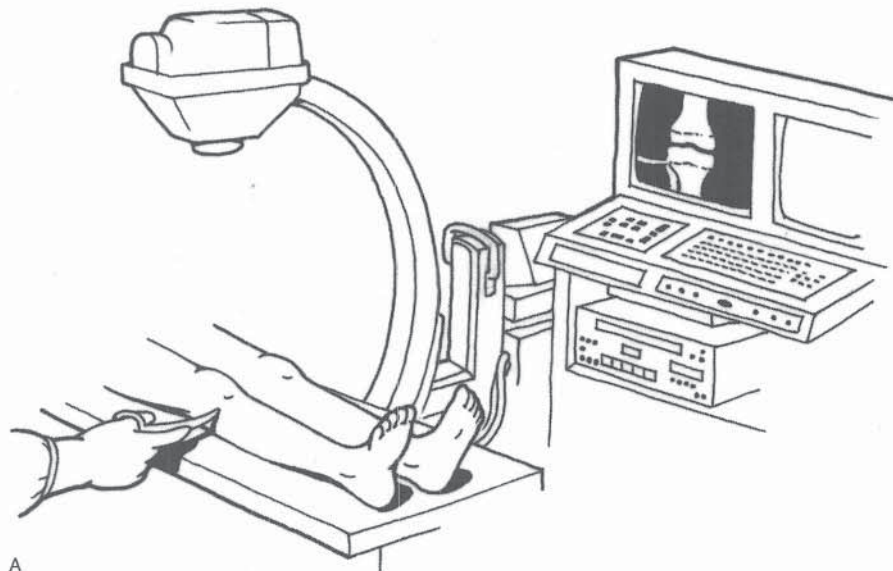


FIGURE 23-24 Technique of percutaneous epiphysiodesis. A, The physis is localized by fluoroscopy. B, The physis is removed with curets, a tube saw, or a drill under fluoroscopic control with sweeping motion superoinferiorly and anteroposteriorly across the radiographic line of the physis. C, An adequate amount of physis needs to be removed, usually leaving only a central bridge of physis.

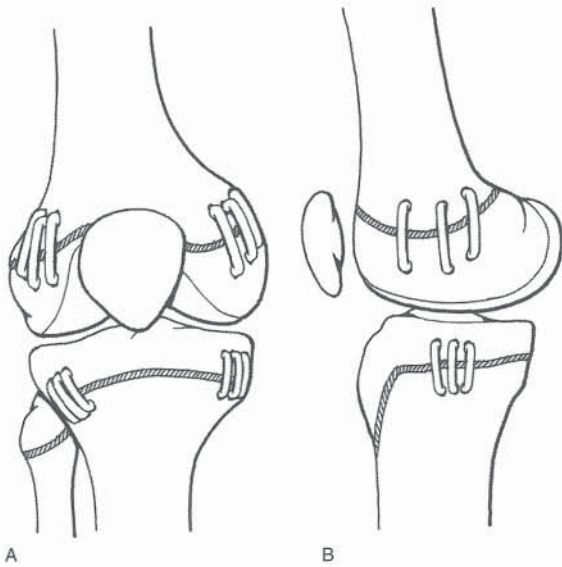


FIGURE 23-25 Ideal spacing of staples as recommended by Blount. Three evenly spaced staples should be placed extraperiosteally with their tines parallel to the physis. A, Anterior view. B, Medial view.

absence of growth, resulting in overcorrection of leg length inequality; new angular deformity; or reverse angular deformity. Even when the patient reaches skeletal maturity without requiring staple removal or readjustment in the management of the original indication, staples frequently need to be removed because of soft tissue irritation from staple prominence or extrusion.

Métaizeau and colleagues have described a modification of epiphysiodesis using percutaneously inserted transphyseal screws.²⁹⁵ They insert fully or partially threaded cancellous screws using either a crossed-screw or nonintersecting screw technique for the femur and tibia (Fig. 23-29). They insert a screw across the proximal fibula with an open technique to prevent injury to the peroneal nerve, and only if tibial epiphysiodesis is expected to exceed 2 cm. In their series of postfracture overgrowth and leg length inequality patients, they calculated an average reduction in distal femoral physeal growth of 68 percent after 6 months and 89 percent thereafter; for the tibia, physeal growth was reduced by 56 percent of normal in the first 6 months and by 95 percent thereafter. They also used this technique for angular deformity correction at the knee, as has Stevens and Belle at the ankle with a percutaneously inserted screw in the medial malleolus.⁴²⁰ In two of 41 patients a hemarthrosis developed postoperatively, without long-term sequelae. Serious complications included overcorrection of 1.3 cm because of failure to adequately monitor the patient's growth postoperatively, and the devel-

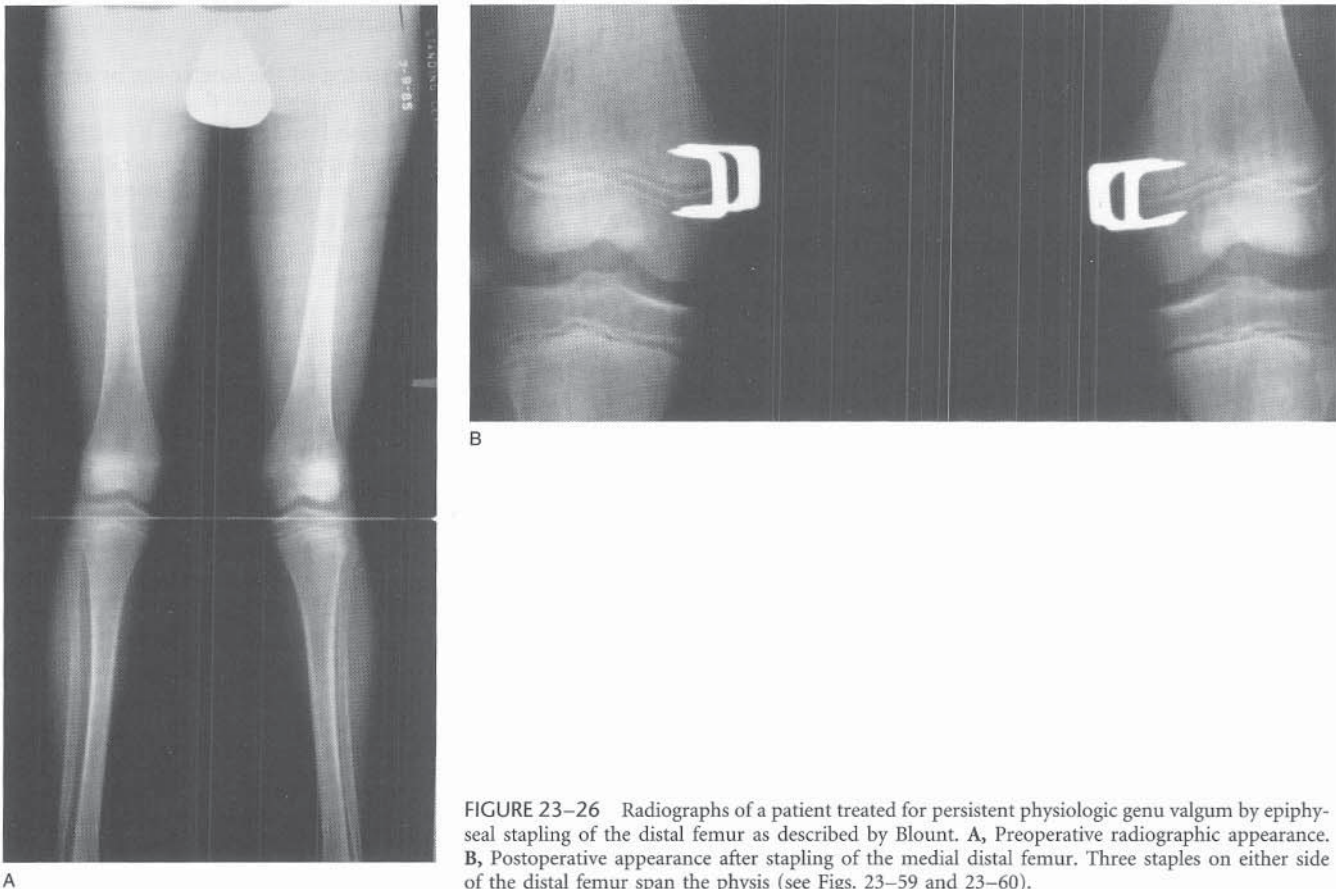
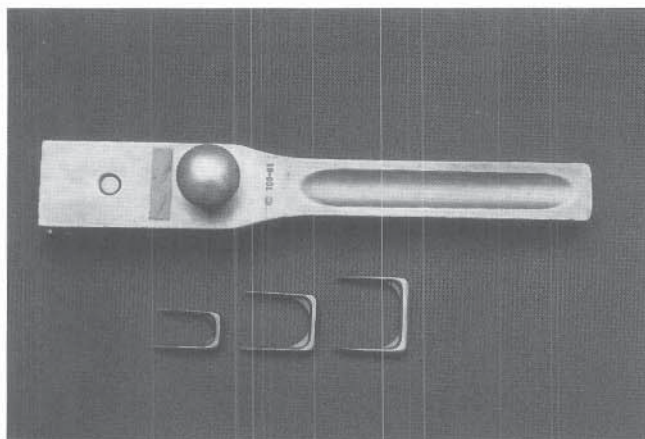



FIGURE 23-26 Radiographs of a patient treated for persistent physiologic genu valgum by epiphysiodesis of the distal femur as described by Blount. A, Preoperative radiographic appearance. B, Postoperative appearance after stapling of the medial distal femur. Three staples on either side of the distal femur span the physis (see Figs. 23-59 and 23-60).



A



B

FIGURE 23–27 Vitallium staples suitable for epiphysiodesis. Shoulders are reinforced to prevent bending of tines with growth. There should be no barbs on tines to facilitate their removal. A, Staples come in assorted sizes, with an inserter. B, A staple loaded in inserter.

opment of varus angulation of the proximal tibia in three patients. The latter complication was attributed to overgrowth of the fibula in cases in which the tibial growth retardation exceeded 2 cm and epiphysiodesis of the proximal fibular physis had not been performed. A theoretically attractive advantage of the technique is the prevention of overcorrection of angular deformity or leg length inequality by removal of the screws after correction if the patient is

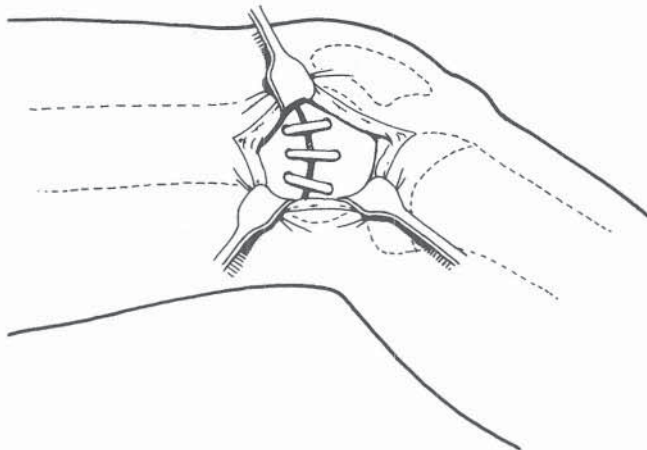


FIGURE 23–28 Proper technique of staple insertion. The physis is localized clinically, or preferably fluoroscopically, and driven across extraperiosteally. Typically three staples should be inserted, evenly spaced across the physis.

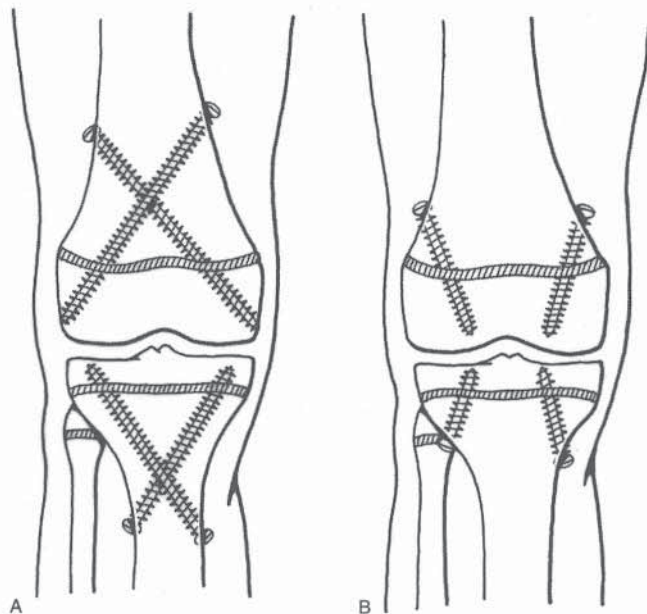


FIGURE 23–29 Scheme of insertion of cannulated percutaneous screws for epiphysiodesis (after Métaizeau). A, Crossed screw insertion. B, Uncrossed, convergent screw placement.

not skeletally mature. In all likelihood, however, further experience will reveal that removal of the screws, similar to removal of staples, will have an uncertain result with respect to resumption of growth or rebound effect. We have no experience with this technique.

ACUTE SHORTENING. Shortening of the longer leg by removal of the desired amount of bone and fixation has several appealing attributes. Surgical shortening is a single-stage procedure with a lower complication rate than either acute or gradual lengthening.* In contradistinction to epiphysiodesis, the surgeon need not rely on the vagaries of skeletal age and maturation. The only calculation required is the extent of bone to be resected, and consideration of whether a tibial or femoral segment should be removed to gain symmetric knee height. On the other hand, the likelihood and severity of complications are higher for surgical shortening than for epiphysiodesis,^{116,243,296,375} significant muscle adaption and rehabilitation are required,^{210,331,426} and the technique is often met with the same initial resistance as epiphysiodesis, in that patients and their families are usually not keen, at least until they appreciate the risks and intensity of treatment, to sacrifice length for safety or expediency. Femoral† or tibial^{162,92,133,242,243} shortening techniques can be performed. Combined one-stage femoral shortening and contralateral femoral lengthening using the segment of bone from the shortened side can also be done^{133,293,474} and is probably best indicated when the patient has a discrepancy greater than ideal for shortening alone and is not a candidate for gradual lengthening of the shorter limb.

* See references 43, 47, 62, 78, 92, 122, 133, 230, 242, 349, 368, 375, 425, 460, 462.

† See references 43, 47, 68, 78, 92, 122, 230, 242, 243, 349, 375, 425, 460, 462.

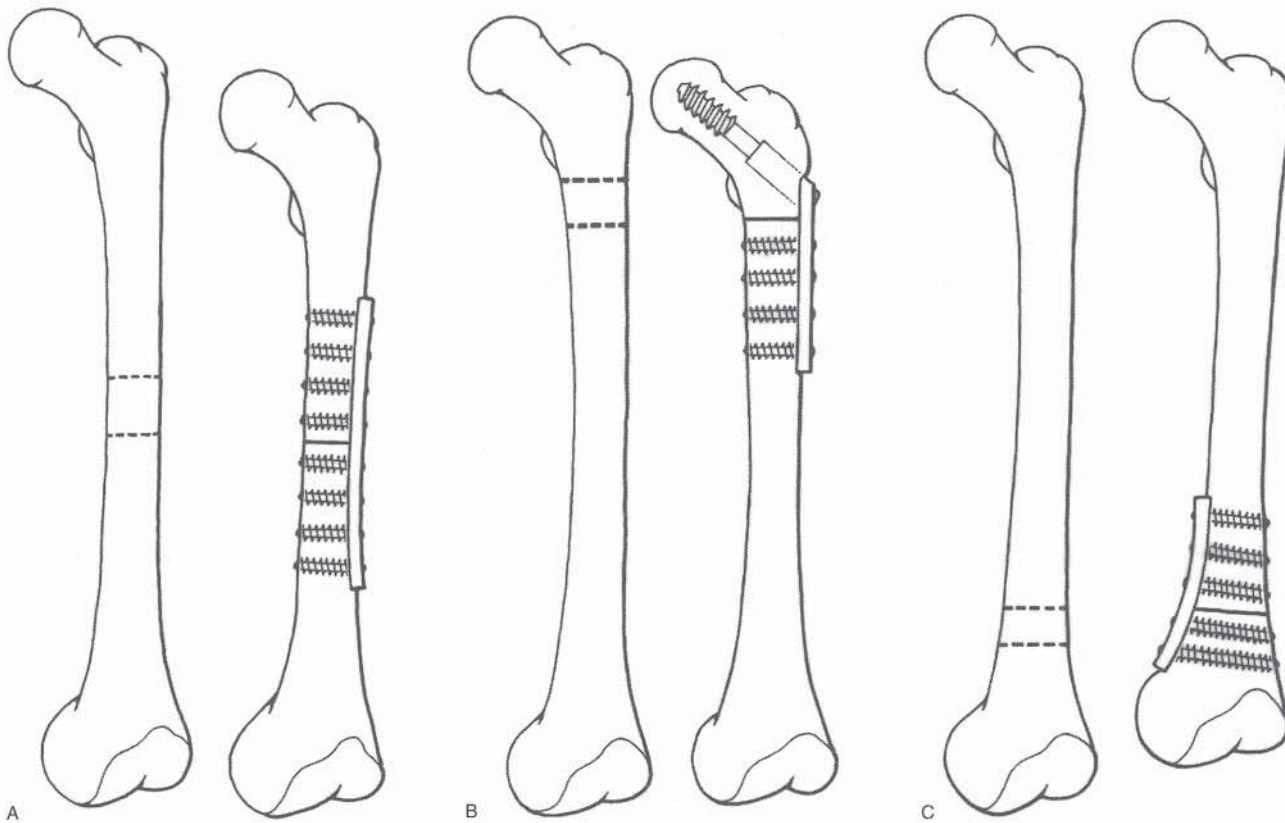


FIGURE 23-30 Options for open acute femoral shortening. A, Shortening in the midshaft of the femur with plating. B, Proximal femoral shortening with a compression screw plate or similar device fixation. C, Distal femoral shortening with compression plate fixation.

Femoral. Acute femoral shortening for the purpose of equalization of leg length has been described by many authors (Fig. 23-30).^{*} Acute shortening of the femur is a relatively major procedure and as such is generally indicated only in skeletally mature individuals with leg length inequality of more than 2 cm. Discrepancy localized to the femur and average stature are preferable features to maintain adequate overall stature and symmetric knee height after the procedure. Shortening can be undertaken in the proximal, middle, or distal portions of the femur. If there is associated angular deformity, then in general, osteotomy for angular correction and shortening should be at the level of deformity. In the absence of deformity, shortening can be at the subtrochanteric or mid-diaphyseal levels; distal metaphyseal shortening is less desirable because of the incongruity of the bone segments after shortening due to the funnel shape of the distal femur. Internal fixation may be achieved with a proximal femoral blade plate, plate and screws, or intramedullary rod. Merle d'Aubigné and Dubousset reported one case of deep infection with no other complications in four patients treated by an average 4.9 cm of femoral shortening over a Küntscher rod.²⁹³ Szepesi and colleagues described the results of subtrochanteric shortening of the femur in 14 patients, 11 of whom had developed leg length inequality as a sequela of developmental dysplasia of the hip.⁴²⁵ Shortening of 2.5

to 3.5 cm was carried out with internal fixation using an angled blade plate and screws. These authors reported no complications in their series of patients, although some muscle weakness was present for 6 months.

Thompson and colleagues reported the results of open femoral shortening with intramedullary fixation in 11 patients; since four of them had significant complications, they recommended against the procedure.⁴³¹ Küntscher developed the intramedullary saw that made "closed" femoral shortening possible.²⁵⁴ Winquist reported the advantages of "closed" femoral shortening, which has been made technically feasible by two advances: refinement of the intramedullary saw, and the development of the interlocking intramedullary nail.^{460,462} In 1986 Winquist described the technique and reported results in 154 patients treated with 2 to 7 cm of femoral shortening for a variety of reasons.⁴⁶⁰

Significant technical intraoperative problems can be encountered during closed femoral shortening with intramedullary rod fixation. These include difficulty completing the osteotomy, particularly posteriorly at the linea aspera; fragmenting and displacing the intercalary bone segment; and preventing rotational malalignment and distraction at the osteotomy site. Experience with intramedullary rodding techniques, a full complement of instrumentation and implants, fluoroscopic monitoring of the surgical procedure, and capable assistance are essential prerequisites to closed femoral shortening. Winquist described the role of the "unscrubbed surgeon" as the most important in the procedure,

* See references 47, 52, 68, 78, 92, 122, 133, 216, 230, 242, 292-294, 308, 317, 337, 349, 368, 375, 425, 431, 460, 461.

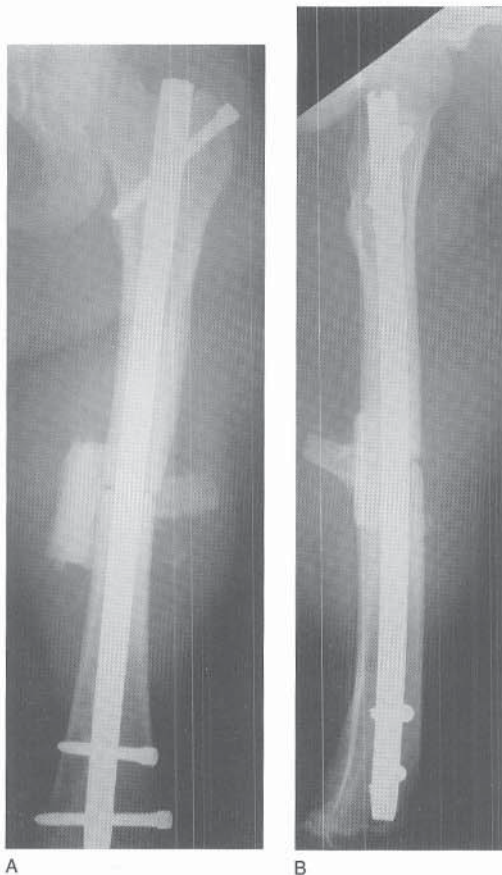


FIGURE 23-31 Radiographs obtained after closed femoral shortening with intramedullary fixation and proximal and distal locking of the rod in the femur to prevent rotational deformity. **A**, AP radiograph. Remnants of the removed intercalary segment of the femur are located around the shortening osteotomy site. **B**, Lateral radiograph.

since that assistant is responsible for completing closed osteoclasis after the initial saw cut and for maintaining rotational alignment. The linea aspera portion of the circumferential osteotomy may need to be cut percutaneously with an osteotome; some surgeons prefer this as an added “vent” for reaming (see below). Postoperatively the patient will need to walk with crutches for 6 to 12 weeks to protect the osteotomy site and to support the knee, which will be weakened by the effect of shortening on the thigh musculature.

Generally good results with closed femoral shortening and intramedullary rod fixation have been reported.* In Winquist’s series of 154 patients, there was one case each of superficial infection, delayed union, and nonunion. Three patients had rotational deformities greater than 20 degrees, two requiring surgical correction. Distraction of the osteotomy site occurred in five patients, all of whom had undergone attempted shortening of more than 4 cm. As reported by Sasso and colleagues, the problems of the development of postoperative external rotation deformity or distraction of the osteotomy site can be largely overcome by the use and manipulation of proximally and distally locked intramedullary rods (Fig. 23-31).³⁷⁵ Blair and colleagues reported

successful results in 20 skeletally mature patients treated by closed femoral shortening of 2 to 5 cm.⁴⁷ At an average 35 months’ follow-up, the patients’ ipsilateral hip and knee motion and strength were clinically normal. Uneven knee heights were exacerbated by the femoral shortening in four patients with leg length inequality secondary to tibial shortening, but this was deemed acceptable by both patient and surgeon. No other complications were encountered. Chapman and colleagues reported the results of femoral shortening of 2 to 6.6 cm in 31 patients.⁷⁸ There were no nonunions or infections. All patients regained full range of motion. Two patients had postoperative bleeding requiring a return to surgery to evacuate buttock hematomas; no other complications were encountered.

Significant biological complications can occur with closed femoral shortening. These include postoperative respiratory distress, presumably secondary to fat embolism; AVN of the femoral head from disruption of the blood supply in the piriformis fossa; and knee muscle weakness secondary to shortening. Sasso and colleagues reported acute respiratory distress requiring intubation and mechanical ventilation for 2 days in one patient out of a group of 18 treated by closed femoral shortening,³⁷⁵ and Edwards and Cummings reported two other cases.¹¹⁶ Closed rodding techniques are thought to be more likely to result in fat embolism because of the closed compartment in which reaming is done, in contrast to either reaming of femoral fracture or open shortening. Venting of the intramedullary canal distally may not, however, prevent this complication. Sasso and colleagues noted that venting of the intramedullary canal was not effective in preventing fat embolism during total knee replacement, and they recommended instead that an enlarged portal with slow, 0.5-mm incremental reaming be performed.³⁷⁵ AVN of the femoral head after intramedullary rod insertion (or extraction) in the piriformis fossa for the management of femoral shaft fractures has been reported in skeletally immature patients and after closed femoral shortening.²⁹⁶ These are very serious complications of which both patient and surgeon must be acutely aware in determining whether closed femoral shortening is indicated. Femoral shortening with intramedullary fixation devices inserted through the piriformis fossa should not be done in patients prior to skeletal maturity because of the risk of AVN of the femoral head.

The most common direct negative consequence of femoral shortening is weakness of the hamstrings and quadriceps. Lack of control of the knee will typically require the patient to walk with the assistance of crutches and possibly a knee immobilizer for 6 to 12 weeks postoperatively. The long-term clinical significance of this weakness is a matter of some debate, but it is clear that this weakness will occur at least temporarily postoperatively, and limits the extent of shortening that should be undertaken. Recommendations for the upper limit of femoral shortening because of this development varies from 4.5 cm²⁴² to as much as 7 cm.⁴⁶⁰ Kenwright and Albinana, in a review of 46 patients, reported successful shortening of up to 7.5 cm in the femur and 5 cm in the tibia without loss of function.²⁴³ Chapman and colleagues found normal quadriceps and hamstring strength by Cybex testing 1 year or more after closed femoral shortening in 13 patients out of a group of 31.⁷⁸ However, Holm and

* See references 47, 78, 92, 122, 242, 243, 349, 368, 375, 460, 462.

colleagues, evaluating 12 limbs prospectively in ten patients, found that 2 years postoperatively, neither hamstring nor quadriceps strength had returned to normal in any patient by Cybex 340 dynamometer testing (Cybex-Lumex Inc., Ronkonkoma, N.Y.).²¹⁰ There was an average 26 percent reduction of total work at 60°/sec for the quadriceps compared to preoperative values, and 12 percent for the hamstrings. The amount of reduction in strength correlated linearly with the amount of femoral shortening and was statistically significant in patients whose shortening was more than 10 percent of original femoral length. They concluded that shortening should be limited to 10 percent of original femoral length. In a separate study, these authors also compared muscle strength in 20 patients treated by diaphyseal intramedullary shortening with a group of 14 patients treated by subtrochanteric shortening and blade-plate fixation.³³¹ The group treated by subtrochanteric Z-cut shortening osteotomy did not sustain the same significant loss of muscle strength noted in the mid-diaphyseal group, despite the average shortening being 12 percent, and as much as 15 percent, of original length. However, patients in the subtrochanteric group were tested significantly longer postoperatively (average of 136 months) than patients in the mid-diaphyseal group (average of 34 months).

In conclusion, closed femoral shortening with intramedullary fixation with a locked rod can be indicated in skeletally mature patients with more than 2 cm, and probably less than 5 cm, of shortening, preferably in the femoral segment. Only surgeons experienced with the technique of intramedullary femoral rodding should undertake this procedure, and both patient and surgeon should be aware of the risk of respiratory distress, presumably from the development of fat embolism. Shortening should be limited to 10 percent or less of the original length to minimize the risk of long-term knee weakness. Open subtrochanteric shortening with blade-plate fixation is an acceptable alternative, without the risk of fat embolism and with potentially less risk of long-term muscle weakening. Skeletally immature patients should not undergo closed shortening with intramedullary rodding, to avoid the potential complication of AVN of the femoral head.

Tibial. Shortening of the tibia is performed less frequently than shortening of the femur for several technical reasons: the procedure must be performed in an open fashion, since the intercalary bone fragment must be extracted from the leg; the fibula must be osteotomized to allow shortening of the limb segment; and complications may be more frequent and significant (compartment syndrome, circulatory impediment, foot weakness) than noted with femoral shortening. Broughton and colleagues reported the results of 12 patients treated over a 25-year period by tibial shortening of 2.5 to 5.1 cm.⁶² The technique used was a step-cut mid-diaphyseal shortening osteotomy with fixation with two screws (Fig. 23–32). The only postoperative complication was a temporary delay in return of circulation to the foot after release of the tourniquet, which recovered spontaneously. The patients were satisfied on follow-up, and had normal function by clinical assessment.

Tibial shortening may also be accomplished with intramedullary fixation, similar to femoral shortening (Fig. 23–33).^{133,242,243} The patient must be counseled to expect

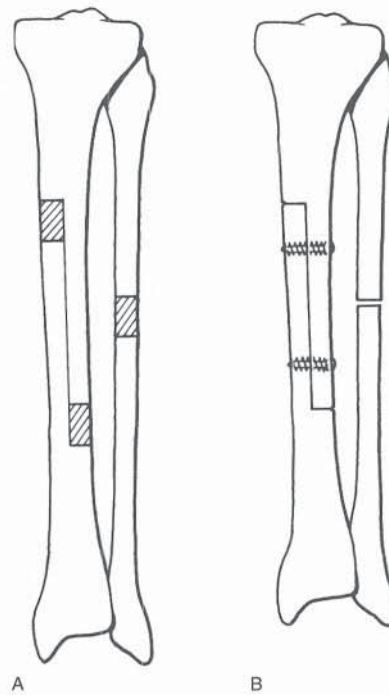


FIGURE 23–32 Scheme of tibial shortening using step-cut and screw fixation. A, Longitudinal osteotomy with step cuts in shaft of tibia. B, After shortening of the shaft of the tibia and transverse screw fixation.

weakness in the foot and ankle for a period postoperatively. Kenwright and Albinana reported successful shortening of the tibia of up to 5 cm without clinically evident loss of function,²⁴³ but Kempf and colleagues recommended that tibial shortening be limited to 3 cm.²⁴²

Lengthening of the Short Leg. Except in cases of clear hemihypertrophy, such as associated with neurofibromatosis and Klippel-Trénaunay syndrome, parental and patient interest usually focuses initially on methods of restoring the shorter limb to a length comparable to the longer side. It is important in our opinion to counsel the family of a child with a limb length inequality that the purpose of treatment is to maximize function and mobility, and, as far as possible, address cosmetic concerns. As discussed earlier, the motivation for treating minor discrepancies should *not* be the intuitive logic of preventing long-term injury to the lower extremity joints or spine. Unfortunately, the surgical options for normalizing leg length inequality by lengthening the short limb are more extensive than those that equalize leg lengths by shortening the longer extremity. The options for lengthening the shorter limb include stimulation of natural growth of the shorter limb, acute lengthening, and gradual lengthening.

STIMULATION OF GROWTH IN THE SHORT LEG. Stimulation of growth in the shorter leg has long been of interest to orthopaedic surgeons. Most interest in stimulation of the growth of the shorter leg is largely historical at present, since unfortunately, no effective method for doing so (except for femoral fracture in the 5- to 10-year-old age group, which is not recommended!) has evolved.* Bohlman in 1929 described

* See references 53, 112, 203, 427, 440, 458.

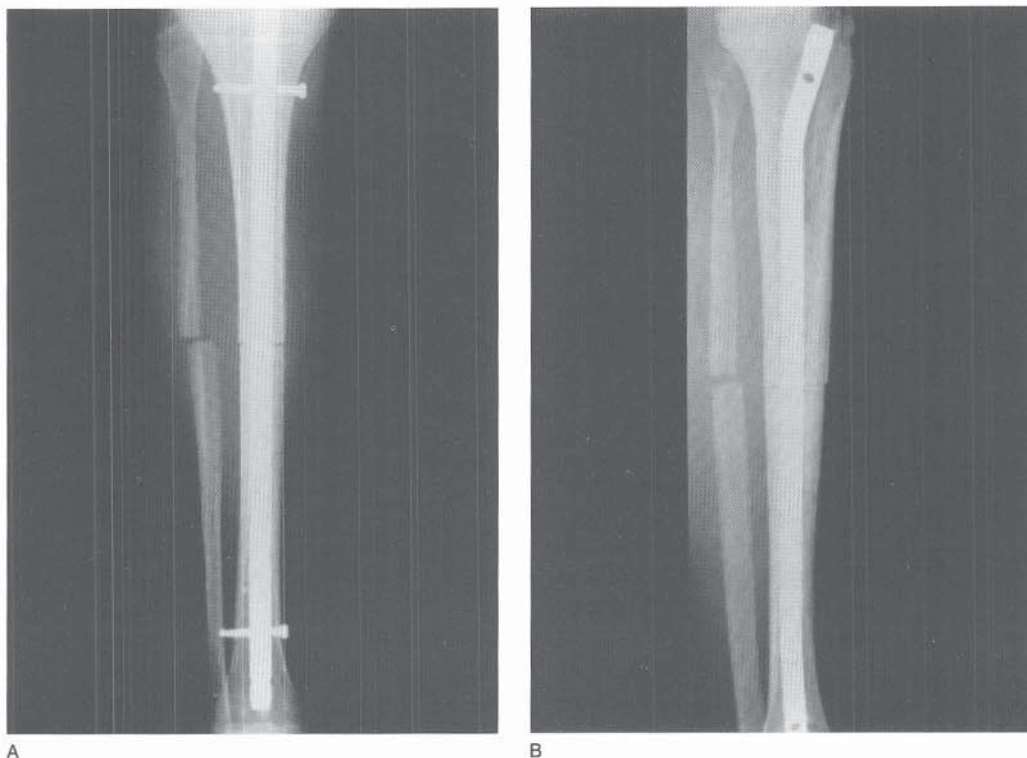


FIGURE 23-33 Open tibial shortening with intramedullary rod fixation in the tibia. A, Postoperative AP radiograph. B, Postoperative lateral radiograph.

a monumental effort to stimulate growth experimentally.⁵³ In a series of experiments, he inserted 22 different materials into drill holes in the distal femora of guinea pigs. Materials inserted into the drill hole included iron, copper, lead, ivory, resinous (“greasy”) pinewood, asphalt, and dry beef bone pegs; red iron oxide, black copper oxide, and menthol crystals; and *Staphylococcus aureus* “vaccine.” Dissection and measurement of all these specimens led him to conclude that none of these materials produced increased growth in the operated femora, and that shortening was the more common result. He concluded that insertion of foreign materials to promote growth was not warranted. Despite this experimental study, Tupman in 1960 reported the results of insertion of a beef bone peg into the metaphysis just below the physis in 28 children, the majority of whom had polio.⁴⁴⁰ The procedure was surprisingly well tolerated; the author reported temporary knee stiffness as the only complication he encountered. However, no actual reduction in leg length inequality was noted in any patient, although Tupman felt that progressive inequality was slowed in 12 patients. Solá and colleagues performed single- and two-stage (2 months apart) periosteal strippings of the entire length of the femur in dogs and monkeys.⁴⁰² Although an increase in length was noted in most specimens, the increase was only 1 to 2 mm on average. They did anecdotally report performing periosteal stripping in poliomyelitis patients, stating that 80 percent demonstrated a decrease in leg length inequality, but not to what extent. Wilde and Baker reported a reduction in leg length inequality in 38 children from an average 7.2 percent (3.8 cm) to 5.4 percent (3.2 cm) by circumferential periosteal stripping of the femur or tibia.⁴⁵⁸ In contradistinction to most other clinical studies, the ma-

jority of patients (15) had congenital fibular deficiency. Although the authors reviewed these results favorably, we cannot recommend a surgical intervention in children for such a modest positive result.

An intriguing concept is the transplantation of physal cartilage into areas where the original physis is deficient or damaged. Experimental attempts to perform physal transplant have been reported.^{325,336} Nettelblad and colleagues evaluated the feasibility of “vascularized” total physal transplant in dogs.³²⁵ When they performed a “switch” of the proximal fibula, with one side transplanted as a vascularized graft, the vascularized fibula continued to grow at a rate comparable to that of control fibulae, whereas the nonvascularized transplants did not. Histologically, the vascularized transplanted physes remained viable. In a less taxing procedure, Olin and colleagues found that a free plug of iliac crest apophyseal cartilage inserted into a surgically induced defect in the distal femur of rabbits prevented growth arrest and valgus deformity in 60 percent.³³⁶ It should be emphasized that the plug was maintained in its desired position by a press-fit into the defect, a situation that is difficult to replicate clinically. Although promising, neither technique has broad clinical applicability at the present time.

SURGICAL LENGTHENING. Lengthening of an extremity can be performed acutely or gradually and with internal fixation, external fixation, or combinations thereof. What follows is a discussion of the history, effects, techniques, complications, and indications for leg lengthening.

History. Codivilla⁸⁶ is credited with the earliest description of limb lengthening.^{241,345} Codivilla stated that the “best results are obtained from forced lengthening, practiced under nar-

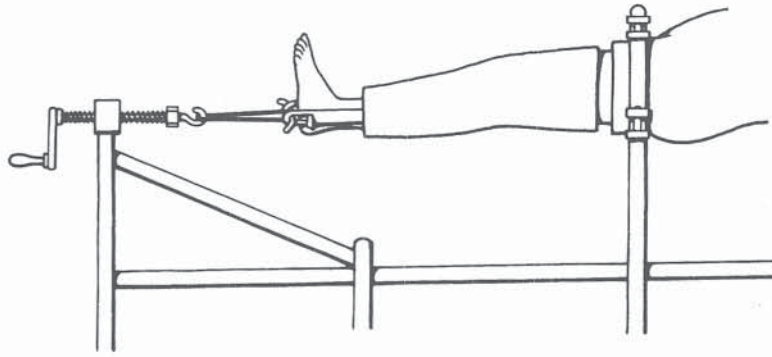


FIGURE 23-34 Codivilla apparatus for limb lengthening. Skeletal fixation of the calcaneus was performed distally, with acute, heavy traction applied to a midshaft femoral osteotomy through the traction pin, followed by incorporation of the limb and trunk in a spica cast.

cotics; by using a sudden and intense force; and by then applying the plaster apparatus to the limb while it is still maintained in complete extension.” Initially he described a technique of traction of up to 75 kg on the osteotomized femur, with the lower limb incorporated in plaster (Fig. 23-34). Ulceration and skin sloughing led him to place a “large nail” through the heel and fixed to the plaster apparatus. He reported lengthening of 3 to 8 cm using this technique. Putti, a student of Codivilla, in 1934 published a technique he originally described in 1921, in which “piano wires” were placed in an AP direction in the greater trochanter and transversely in the femoral condyles to apply traction and countertraction for a period of 2 to 3 weeks, followed by incorporation of the wires in a plaster cast worn for 8 to 10 months.³⁶¹ Abbott presented a method for lengthening the tibia, after due consideration of the contributions of Codivilla and Putti (as well as Ombrédanne and Magnuson).⁴ The technique included placement of Steinmann pins transversely above and below a complex tongue-and-groove step-cut in the tibia, with the Steinmann pins connected by spring-loaded rods. Lengthening did not commence until 7 to 10 days postoperatively, when all swelling had subsided. Daily turning of the thumb screws was continued until the desired lengthening (up to 2 inches) was completed over a 3- to 4-week period. He also described placing a metallic marker with incremental markings on the leg when taking radiographs to aid in the calculation of magnification. Bosworth described a technique using two transverse pins (or wires in children) above and below a step-cut tibial osteotomy and an additional pin in the os calcis.⁵⁷ Lengthening was carried out by a ratchet device attached to the pins, with the limb supported in a Balkan frame. Bosworth noted that this apparatus had been first described by O. Lambret of Lille, France, but only for the management of fractures.

Compere⁹⁰ and Sofield⁴⁰⁰ severely dampened enthusiasm for lengthening by noting the high frequency of serious (sometimes fatal) complications and significant loss of muscle function of the lengthened limb on long-term follow-up. Sofield and colleagues subsequently reported the results of leg lengthening in 40 patients more than 20 years after the treatment; this is still by far the longest follow-up investigation of the effect of leg lengthening.⁴⁰¹ These authors noted that although the majority of patients had maintained length and were pleased with the results of lengthening, many had lost some muscle strength in the lengthened limb (most had polio), and they concluded that “leg-lengthening was seldom justified.”

In 1952, Anderson introduced his technique of tibial lengthening using a distraction device.¹⁵ Initially he recommended a two-stage procedure to initiate lengthening, the first to divide the fibula and place the fragments under the periosteum of the tibia, and then to osteotomize the tibia. This approach was subsequently modified by Coleman and Noonan to a single stage of tibial and fibular osteotomy with internal fixation of the fibula to the tibia.⁸⁹

Wagner provided important contributions to limb lengthening and reconstruction, including introduction of his lengthening device in 1972.⁴⁴⁹ The technique included fixation of the long bone with heavy Schantz pins (or screws); osteotomy with resection of fascial tissue and acute lengthening of approximately a centimeter; gradual continued lengthening at a rate of 1 to 2 mm per day until the desired lengthening had been achieved; and a second surgical procedure during which a special plate was secured to the bone fragments, bridging the gap between bone ends, and filling the gap with bone graft (Fig. 23-35). This plate was usually subsequently removed in one or two stages (loosening the screws, followed by complete removal of the plate and screws). Wagner’s technique was the standard for lengthening of the tibia or femur in the Western Hemisphere until the introduction of current devices and techniques, and was the subject of many reports.*

Significant drawbacks to the Wagner technique included the need for at least three surgeries (device application and osteotomy; plate application and bone graft; plate removal), the extensive scarring these surgical interventions caused, and the relatively poor quality of the lengthened bone, which was prone to fracture and infection, and often precluded further lengthening.† The incidence and severity of complications associated with leg lengthening were significant enough for Chandler and colleagues to conclude as recently as 1988 that “Wagner leg lengthening is generally recommended when amputation is the only other surgical alternative and a full, complete informed consent is given to the parents and patient.”⁷⁷

Significant advances in the technique of limb lengthening (*method*) and the external fixation (*apparatus*) used to effect lengthening have been provided by Ilizarov²²⁴⁻²²⁶ and De Bastiani and colleagues.¹⁰⁵⁻¹⁰⁷ English-language publications by Ilizarov first appeared in 1989,^{224,225} but reports in the

* See references 3, 45, 60, 75, 77, 83, 87, 88, 100, 150, 181, 211, 234, 259, 272, 282, 284, 321, 339, 346, 371, 414, 449.

† See references 3, 45, 77, 181, 211, 271, 272, 414.

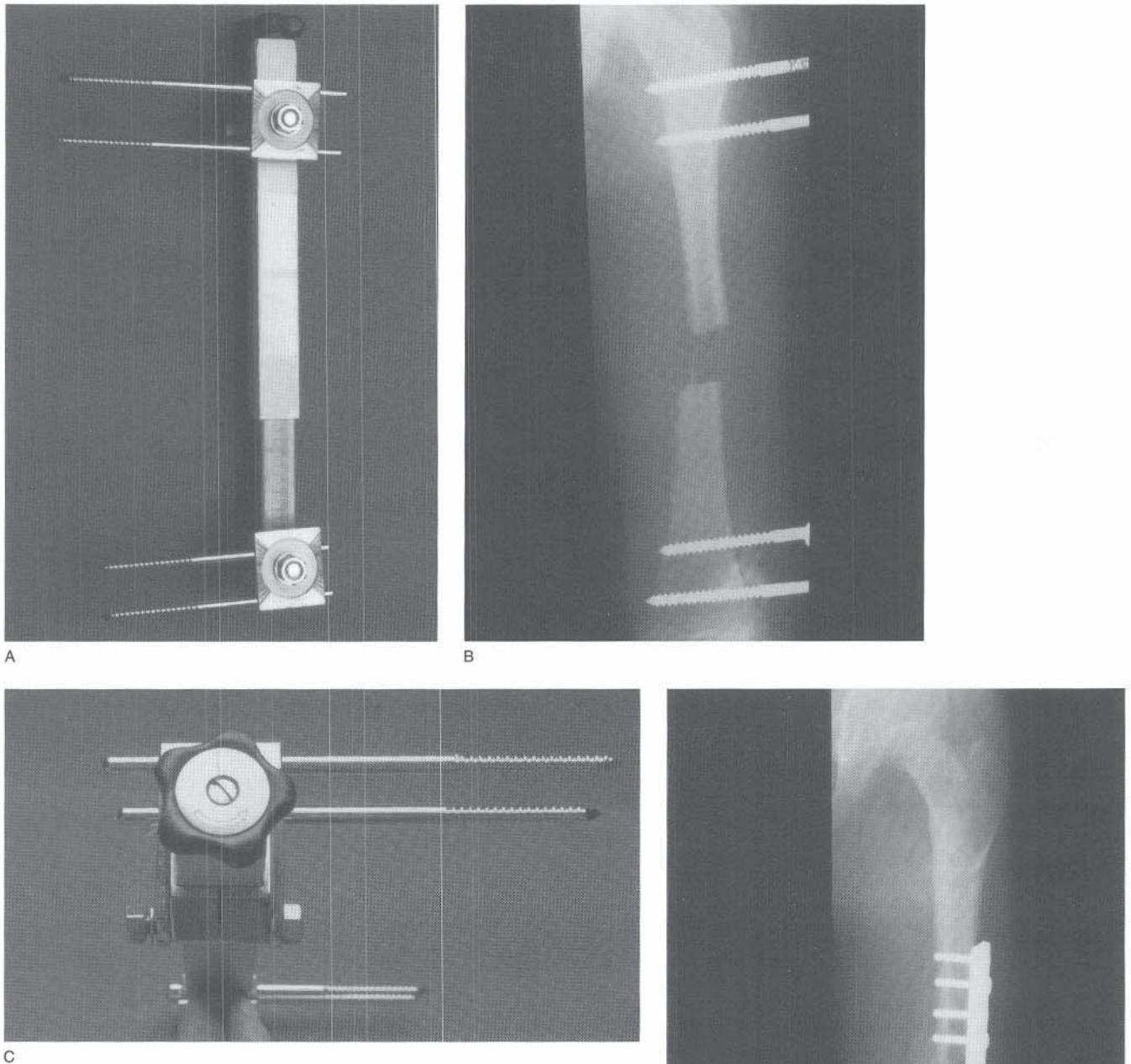


FIGURE 23-35 Wagner apparatus and technique. **A**, The apparatus consists of a telescoping rectangular tube with fixation clamps at either end to accept Schantz screws. The angle of screw insertion could be varied, but not the plane of insertion relative to the distractor. Usually two large Schantz screws were inserted in each fragment. **B**, At the initial surgery for femoral lengthening, the intermuscular septum and iliotibial band were divided transversely after application of the fixator, and the bone was acutely distracted approximately 1 cm. **C**, Lengthening was effected by turning a knob at one end of the device. Distraction was typically 1 to 2 mm per day in $\frac{1}{2}$ -mm increments (a complete revolution lengthened the device 1 mm). **D**, After completion of lengthening, a special lengthening plate was inserted, usually with an iliac crest bone graft inserted into the gap created by the lengthening, and the external fixator was removed.

D

Italian literature had begun appearing in 1981, and Ilizarov had been developing his techniques in the former Soviet Union since the late 1940s. Both Ilizarov and De Bastiani recommended gradual distraction either across the physis (*chondrodiatasis*) or after low-energy, soft tissue- and medullary canal-preserving osteotomy, or “corticotomy” (*callo-tasis*), with no immediate displacement of the bone fragments and gradual distraction of the developing fracture callus after a “latency” period (see discussions under Chondrodiatasis and Callotasis, below).

Excellent reviews of the history of both the methods of and the devices used to accomplish leg lengthening are provided by Wiedemann⁴⁵⁷ and Paterson³⁴⁵ and are recommended to any reader interested in further insight into this topic.

Acute Lengthening. Pelvic: Lengthening of a short limb by acute transiliac lengthening has been described by several authors.^{29,300,448} Millis and Hall³⁰⁰ attributed the introduction of the technique to Salter, as a modification of his pelvic osteotomy for acetabular dysplasia (Fig. 23–36).³⁷³ With this modification, the traditional triangular graft harvested from the ipsilateral iliac crest is replaced by a quadrangular graft, with angulation as needed to redirect the dysplastic acetabulum, if present. Millis and Hall used this modification in patients with femoral shortening associated with acetabular dysplasia, leg length inequality, intrapelvic asymmetry, and decompensated scoliosis. In a review of 20 patients 2 to 6 years after surgery, performed between the ages of 5 to 20 years, they found that the average amount of lengthening was 2.3 cm. They did not try to achieve more than 3 cm of lengthening. An iliopsoas tenotomy is mandatory with this technique. In their original description, the osteotomy and graft were held in place by two heavy threaded Steinmann pins; postoperatively, patients were maintained in traction for 5 days, followed by toe-touch weightbearing for 3 months. With more secure internal fixation (described in Chapter 15, Developmental Dysplasia of the Hip), a more

rapid return to ambulation may currently be possible. Only two of the 20 patients had leg length inequality as the sole indication for surgery; eight had acetabular dysplasia associated with leg length inequality. Complications in the entire group included three wound infections, a measurable loss of length in one (6 mm), and a femoral neck fracture in an adult with poliomyelitis and osteopenia. No cases of disruption of the sacroiliac joint, cartilage space loss, AVN of the femoral head, or neurovascular complications were noted in this group. The authors did, however, recount a separate case of attempted 3.5 cm lengthening in which partial sciatic nerve palsy was evident in the immediate postoperative period, which resolved when the graft was reduced to 2.5 cm. Barry and colleagues had similar good results in 23 patients, gaining an average of 2.8 cm (range, 2.0 to 3.5 cm).²⁹ However, two patients developed femoral nerve palsy postoperatively, which resolved in one but was permanent in the other.

In summary, transiliac lengthening should be kept in the surgeon’s armamentarium when assessing patients with acetabular dysplasia or fixed pelvic obliquity and leg length inequality. The ideal indication seems to be a patient requiring Salter innominate osteotomy for acetabular dysplasia with an associated ipsilateral shortening of 3 cm or less. Limiting lengthening to 2.5 cm appears prudent, and any postoperative neuropraxia should be treated by prompt return to the operating room to reduce the amount of acute distraction by trimming the quadrangular graft.

Femoral and tibial: In 1965 Merle d’Aubigné and Vaillant described in the French literature a technique of transverse osteotomy with acute lengthening over an intramedullary rod, with locking of the fragments by a cortical bone block.²⁹⁴ An English literature report was provided by Merle d’Aubigné and Dubousset in 1971.²⁹³ In that publication, the authors presented the results of three methods of acute leg length inequality correction: femoral shortening, femoral lengthening, and combined femoral lengthening and contralateral shortening. They provided a detailed description of acute femoral lengthening using a Küntscher rod, soft tissue release, and allograft bone (Fig. 23–37). Two of their patients who underwent the lengthening had transient ischemia requiring lysis of scar tissue around the femoral artery, three had transient sciatic nerve palsy, three had delayed unions, and two developed flexion contractures (one each of the hip and knee) requiring secondary release. Other modern descriptions of acute long bone lengthening are provided by several authors.* Cauchoix described a method of acute lengthening of the femur with internal fixation using a plate and screws.⁷⁶ Through a long lateral incision in the thigh, the iliotibial band is cut transversely, the vastus lateralis is released from the linea aspera after ligation of the perforating vessels as they enter the vastus lateralis, the linea aspera, including its tendinous attachments, is elevated with a chisel, the femoral shaft is exposed subperiosteally along its entire length, and the posterior intermuscular septum is transected (including the raised linea aspera). Steinmann pins are driven into the proximal and distal fragments at the base of the greater trochanter (anteroposteriorly) and the femoral condyles (transversely), and an 8-cm step osteotomy is made in the shaft of the femur. A cable is attached to each

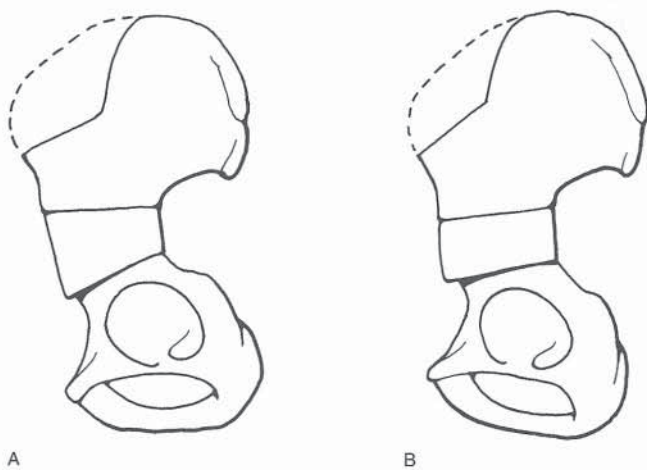


FIGURE 23–36 Scheme of acute transiliac lengthening combined with Salter innominate osteotomy for hip dysplasia associated with shortening. **A**, A quadrilateral graft can be used for combined lengthening and rotation of the distal pelvic fragment to correct associated acetabular dysplasia. Lengthening by this method should be limited to 2.5 to 3.0 cm. **B**, A rectangular graft may be used for acute transiliac lengthening without associated acetabular dysplasia.

* See references 76, 120, 133, 204, 231, 318, 434, 464, 474.

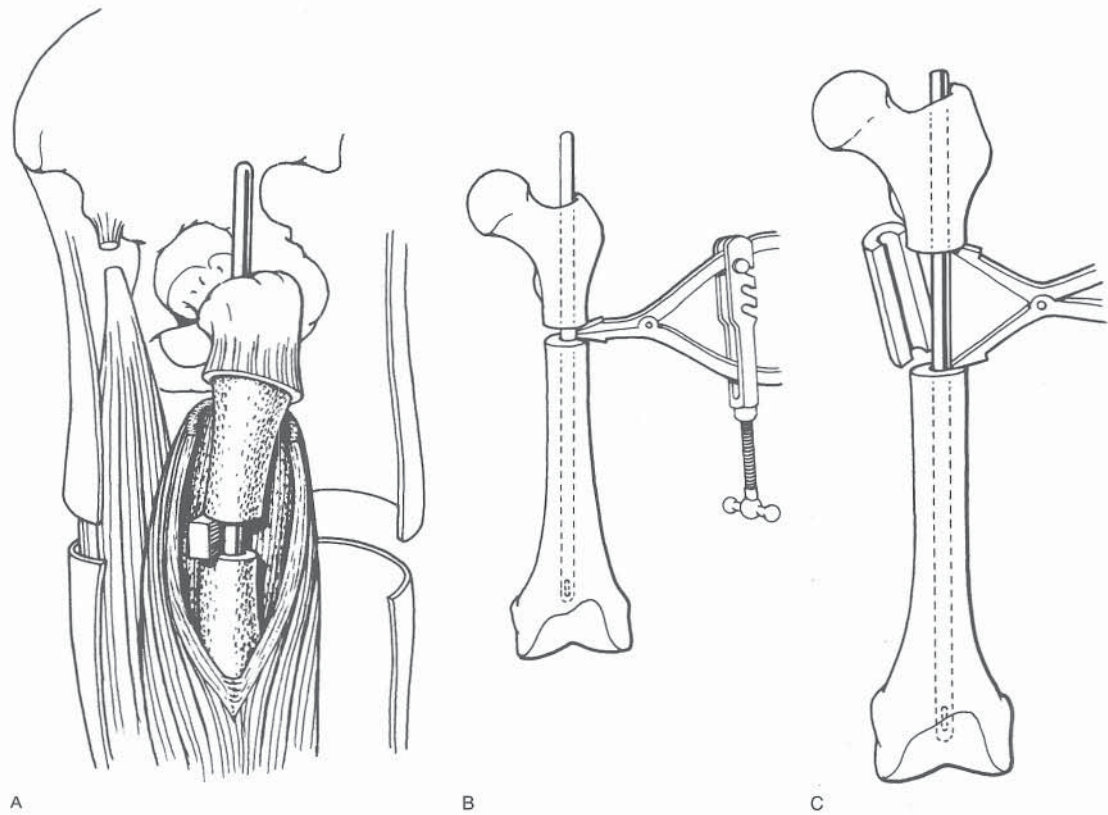


FIGURE 23-37 Acute femoral lengthening as described by Merle d'Aubigne and Dubousset.²⁹³ **A**, After insertion of a femoral (Küntscher) rod, femoral osteotomy, and initial distraction at the osteotomy site (held open by a blocking device), a soft tissue release of the iliotibial band, rectus femoris, and vastus lateralis is performed. **B**, Distraction is continued across the osteotomy with a distracting device. **C**, After distraction is complete, longitudinally halved segments of femur (cadaveric, or harvested from the contralateral femur when combined acute lengthening and contralateral one-stage shortening are performed) are placed in the distraction gap.

Steinmann pin through a traction bow, and the bone fragments are distracted. The knee is kept flexed to protect the sciatic nerve. The fragments are fixed with a long plate and screws; the author found it convenient to affix the plate to the proximal fragment before the lengthening. The gap is filled with autologous bone graft from the iliac crest.

Major complications are associated with acute lengthening of either the femur or tibia. These complications include acute femoral and/or sciatic nerve injury, femoral artery occlusion, reflex sympathetic dystrophy, intraoperative fracture at a site remote from the osteotomy for lengthening, implant failure, delayed union or nonunion requiring repeat bone graft, and infection. Long-term joint stiffness and subluxation, however, do not appear to be frequent problems with this technique. Cauchoix, in reporting the results in 180 cases, thought that up to 4.5 cm was a reasonable gain in length.⁷⁶ Two intraoperative fractures of the femur occurred, requiring extension of the internal fixation. He reported no distal vascular complications. One patient had a sciatic nerve injury with permanent foot drop, and two patients had quadriceps palsy that improved postoperatively but did not normalize. Fifteen patients had postoperative wound infections, in three the implants failed prior to union, in 12 nonunion developed, and eight had late fractures of the lengthened femur. Herron and colleagues reported results in nine patients treated by the method described by Cau-

choix with an average lengthening of 4 cm.²⁰⁴ They reported a rather intimidating implant failure rate (three patients), delayed union requiring repeat bone grafting in two, and a femoral refracture in one. Even more notable was femoral and/or sciatic nerve injury in four patients (with permanent sensory and/or motor weakness in all), and one case of femoral artery occlusion that did resolve with intraoperative shortening and lysis of adhesions around the artery. Courageously, these authors concluded that the technique was demanding, intraoperative monitoring of the neurovascular status of the limb was mandatory, but that when the technique was properly executed, the results were gratifying. More recently, in 1993, Murray and colleagues reported no neurovascular complications in 17 patients treated for angular or rotational deformities in conjunction with acute lengthening of 2 to 7 cm, using a variety of techniques and implants. In contradistinction to Cauchoix and Herron, they attempted to limit soft tissue dissection and subperiosteal bone exposure to that necessary to correct deformity, and used locked intramedullary rods whenever the deformity was mid-diaphyseal. They had no neurovascular complications.³¹⁸

Gradual Lengthening. Chondrodystasia: Since most causes of limb length inequality are in some way related to disturbance of normal physal function, effort to restore that function

is a logical progression of thought. As we have seen, however, efforts to stimulate normal growth have not succeeded, and transplantation of normal physes is currently largely not feasible. Interest has naturally turned to efforts to distract a physis mechanically, a process variably referred to as “chondrodiatasis,” “epiphysiolysis,” “epiphyseal distraction,” “distraction epiphysiolysis,” or “epiphyseal traction.”* The earliest report of attempted lengthening of bone by mechanical traction across a physis appears to be that of Gelbke,¹⁵³ and, as Letts and Meadows have noted, other early work was reported by Harsha, Marsh, and colleagues; Smith and Cunningham; and Ring.^{264,365}

Part of the reason for the different descriptive terms for distraction of the physis is that different methods of distraction have been used both experimentally and clinically. Letts and Meadows deliberately produced a physal fracture in an animal model, followed by distraction.²⁶⁴ Ring distracted across the physis in an animal model, but was uncertain whether this produced a physal fracture or not.³⁶⁵ The great majority of both clinical and experimental studies† indicate that distraction across the physis produces an epiphyseal separation after a period of a few days to a few weeks, which can be followed by further lengthening; hence the term “distraction epiphysiolysis.” The occurrence of this acute separation depends on the rate and extent of distraction force applied to the physis. First Sledge and Noble,³⁹⁸ then De Bastiani and colleagues,¹⁰⁶ noted experimentally that lower forces or slower distraction (for example, 0.5 mm per day) could result in hypertrophy of the cellular layers of the physis without actual acute physal separation. De Bastiani termed this form of physal distraction “chondrodiatasis” to specifically refer to physal distraction without separation; common usage (and the uncertainty clinically as to whether or not acute physal separation will occur) has resulted in use of the term “chondrodiatasis” without consideration as to whether the intent or event of physal separation occurs or not.

Theoretically, chondrodiatasis is appealing in skeletally immature patients. First, many angular deformities arise from the region of the physis and epiphysis in children, so that the apex of deformity correction more nearly corresponds to the apex of deformity with this technique (see subsequent discussion under Principles of Angular Deformity Correction in Children). Second, in some regions of the body the distracted bone segment is distal to deforming muscle forces. The specific example of this is the distal femur, where chondrodiatasis occurs distal to the adductor insertion, theoretically minimizing the risk of adduction deformity which can occur with femoral lengthening. However, several practical considerations keep this technique from being the most common method of limb lengthening in skeletally immature patients. The first practical problem is that the moment of physal separation is often extremely painful to the patient. Separation usually occurs with an audible pop, accompanied by acute distraction of the soft tissues as the result of the distraction force that has been building with distraction across the physis without corresponding movement of the bone. Although in theory, acute

physal separation may not occur with gradual distraction of 0.5 mm per day or less, in practice, owing to variability in physes and patients, this is not a controllable event, and may occur despite efforts to avoid it. Second, segmental fixation of the distal femoral epiphysis, proximal tibial epiphysis, or distal tibial epiphysis is in general more tenuous than segmental fixation of the metaphysis. Furthermore, in the distal femur and proximal tibia, fixation may be intra-articular, introducing a risk that pin-tract infection may lead to septic arthritis. Although this has not been a frequent complication in practice, there can be significant consequences for the patient. Finally, physal closure frequently occurs after distraction, as has been noted repeatedly, both experimentally* and clinically.^{44,91,192,306} To be fair, not all authors have noted this occurrence,^{91,105,398} or have noted a slowing of expected physal growth without an actual cessation of growth.^{11,106} This consequence has led to the recommendation that physal distraction be carried out only in patients approaching skeletal maturity. Several studies comparing chondrodiatasis with metaphyseal corticotomy and callotasis (see below) have noted comparable or worse results with chondrodiatasis with respect to the development and nature of complications.^{44,123,134,357,364}

In summary, we believe that chondrodiatasis has at best a limited role in the management of leg length inequality in children. The risks and problems associated with the increased challenge of the integrity of external fixation to the epiphysis only with the attendant increased risk for septic arthritis, the unpleasant acute physal disruption, and the unlikely continued growth of the physis subsequently make metaphyseal osteotomy and callotasis a more appealing and controllable alternative in our view.

Callotasis: Currently, a more accepted method of leg lengthening is by gradual distraction (callotasis) of a fracture callus after low-energy “corticotomy” of the long bone with careful preservation of the soft tissue envelope surrounding the bone, described by both Ilizarov^{224–227} and De Bastiani and associates.^{8–10,107} In contradistinction to the Wagner method, with the “corticotomy” technique, a limited exposure of the bone (usually the metaphysis) is made, with careful preservation of the surrounding soft tissue and periosteum without any initial distraction after external fixation of the bone segment to be lengthened (Fig. 23–38). After a 3- to 21-day “latent period,” during which fracture callus develops at the site of corticotomy, gradual distraction begins (Fig. 23–39). The distraction period continues until the desired amount of lengthening (or the maximal amount attainable secondary to soft tissue constraints) has been achieved (Fig. 23–40). The rate of lengthening is that which appears to be tolerable to the fracture callus and soft tissues without interference with their blood supply, typically a millimeter a day. The limb is maintained in the lengthened state in the external fixator until adequate consolidation of the new bone has occurred, to minimize the risk of fracture after removal of the apparatus (“consolidation period”) (Fig. 23–41). Typically, the consolidation period is approximately twice as long as the distraction period, but its duration is influenced by many factors (see below). The “healing index” is the total amount of time in external fixation per centimeter

* See references 7, 11, 44, 69, 91, 105, 106, 123, 130, 131, 134, 192, 233, 244, 306, 307, 322, 327, 364, 365, 398, 413, 441.

† See references 106, 129, 130, 233, 244, 305, 322, 413.

* See references 129, 130, 264, 305, 306, 413.

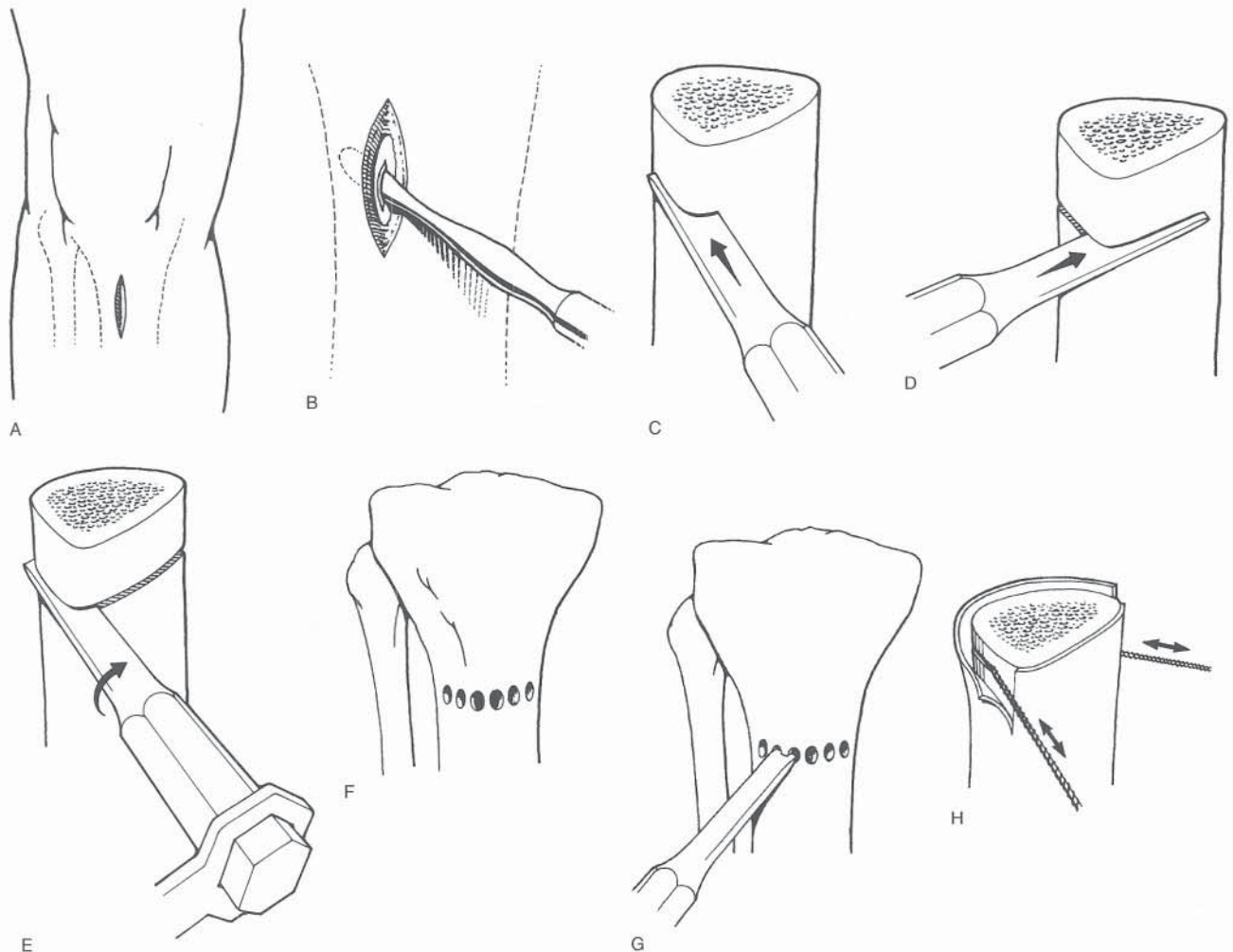


FIGURE 23-38 Corticotomy techniques. **A**, With either the drill and osteotome technique described by De Bastiani or the “corticotomy” technique described by Ilizarov, a small incision is made over the bone (in this example, over the proximal anterior tibial crest). **B**, The bone is exposed with minimal periosteal elevation. **C**, With Ilizarov’s corticotomy technique, the anterior aspect of the cortical bone is divided with a small osteotome. This bone cut is continued posteriorly along one surface of the cortex. **D**, The opposite anterior surface of the cortex is divided. **E**, The corticotomy is completed by torquing the osteotome within the cortex with the aid of a wrench applied to the handle of the osteotome. **F**, Alternatively, the level of bone osteotomy can be outlined with a series of small drill holes, as described by De Bastiani. **G**, The osteotomy is completed with an osteotome, similar to Ilizarov’s technique. **H**, A Gigli saw may be used to perform the osteotomy, thus ensuring complete osteotomy. Usually more than one skin incision will be required to pass the saw around the tibia. This technique will obviously damage the intramedullary circulation. See text for further discussion.

of lengthening, and is thus typically approximately 30 days per centimeter.

After removal of the external fixator, there is an extended period of regenerate new bone remodeling, which usually results in radiographically and histologically appearing normal bone. This regenerate new bone is much more amenable to repeated lengthening than bone formed after the Wagner technique of diaphyseal lengthening.

Ilizarov preferred dividing the bone with a small osteotome, often completing the osteotomy by a closed osteoclasia maneuver, such as rotation of the fragments.^{227,379} De Bastiani described making a series of drill holes in the bone at the desired level and connecting the holes with an osteotome.¹⁰⁷ Ilizarov’s premise was that preservation of the intramedullary blood supply was important to the quality of subsequent new bone (regenerate) formation. However, subsequent in-

vestigations have shown that minimization of injury to the soft tissues is the critical factor, not the actual preservation of the intramedullary blood supply.^{127,271,466} Similarly, the external device used is not critical to the development and quality of new bone formation; rather, it is the gradual manipulation of the fracture callus after an appropriate latent period which is important.

The importance of this technique of lengthening is easily appreciated by assessing the results of lengthening using the Wagner apparatus with the callotasis method. Several authors report significantly fewer soft tissue complications, better new bone formation, and the lack of need for secondary bone grafting and internal fixation when the Wagner method of soft tissue release and immediate initial distraction is replaced by the callotasis method using the same external fixation device.^{3,100,181,271,284,346}

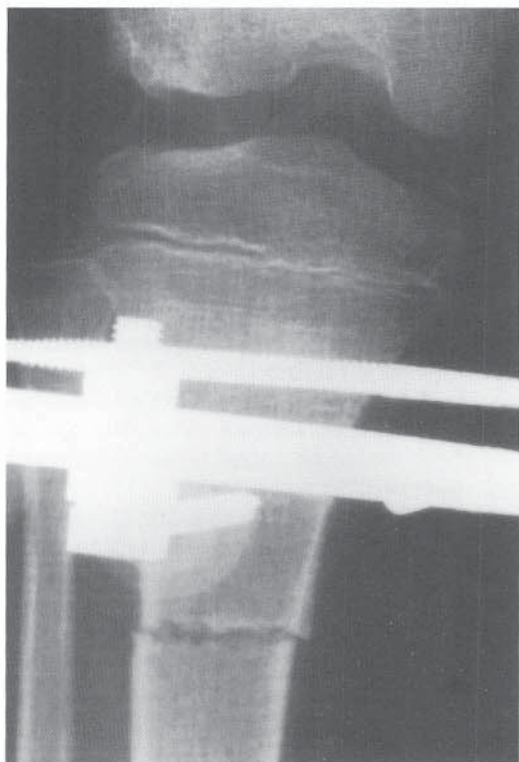


FIGURE 23-39 After corticotomy, the bone fragments are kept in apposition, allowing reconstitution of the local blood supply and the development of a fracture callus. This is the “latent” period of the callotasis technique.

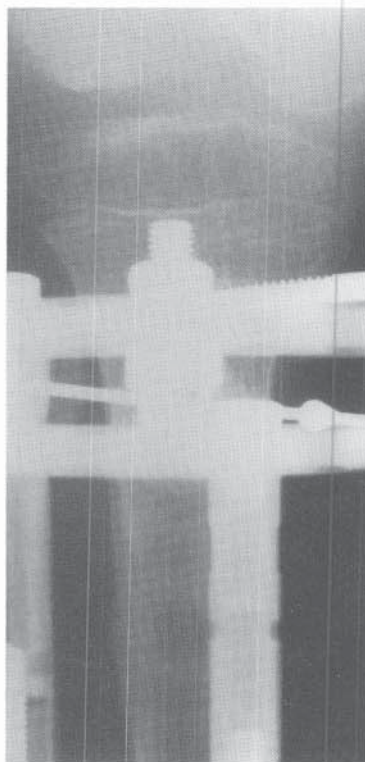


FIGURE 23-41 After completion of the distraction phase, the bone fragments are held to length by the external fixator (the consolidation phase) until regenerate bone healing is adequate to allow removal of the device.

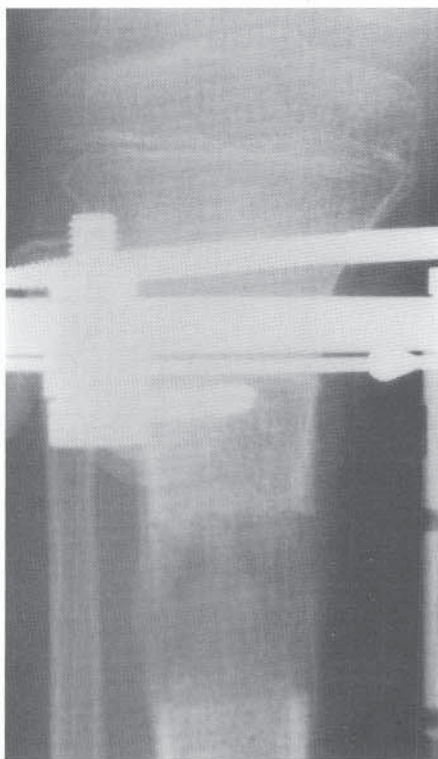


FIGURE 23-40 During the distraction phase, the bone fragments are gradually distracted, typically at a rate of 1 mm per day in four $\frac{1}{4}$ -mm increments. During this distraction phase, new bone (regenerate bone) can and should be seen between the ends of the distracted bone fragments.

Much credit must be given to Ilizarov for his studies on the effect of gradual distraction on bone and soft tissues,^{224,225} although the effect of lengthening was studied by many both before and after him. Ilizarov termed the process of tissue response to gradual lengthening using his method as the “tension-stress effect on the genesis and growth of tissues” and found that in general, with preservation of the soft tissue envelope and callotasis techniques, the tension created by gradual distraction stimulated neogenesis not only of bone, but also of all the soft tissues, including skin, blood vessels, peripheral nerves, and muscle.^{224,225,227} Further experience by other, perhaps lesser, surgeons is that while true neogenesis of these tissues may occur, injury of muscle, nerve, or blood vessels, overdistracted of muscle and/or nerve, poor bone formation, joint compression, and the psychological stress of lengthening by external fixation may lead to a much less functional result than simple “genesis” of tissues in clinical applications of Ilizarov’s methods.* The reader is encouraged to study closely the *effects* of lengthening on bone and soft tissues, and the closely related *complications* associated with this reconstructive procedure. These issues are more important to understanding the impact of leg lengthening on the child than the choice of external or

* See references 17, 31, 60, 79, 101, 103, 117, 123, 127, 128, 148, 149, 154, 177, 193, 212, 217, 219, 237, 238, 257, 271, 276, 297, 298, 301, 304, 320, 340, 358, 363, 388, 397, 406, 408, 411, 412, 418, 419, 423, 435, 442, 443, 451, 459, 469, 470.

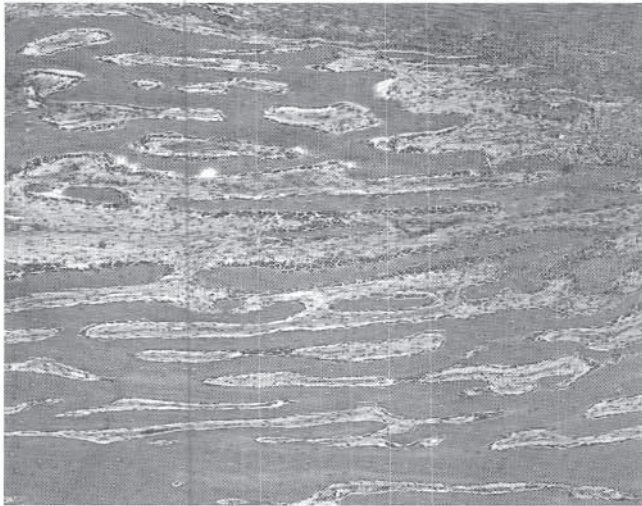


FIGURE 23-42 The major portion of new bone formation in the distraction gap occurs by intramembranous bone formation, with direct ossification of the fibrous tissue. Note the new bony spicules forming within dense collagenous tissue in the central and upper left portions of this specimen.

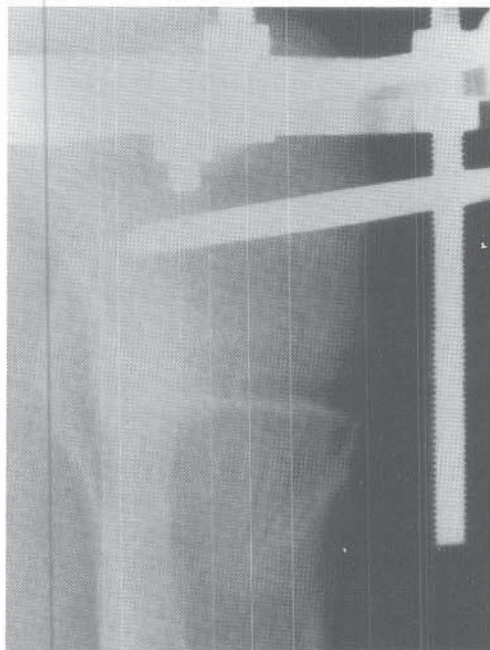
internal fixation method or the precise surgical technique used to accomplish the task.

Effect on bone: Ilizarov concluded, after extensive studies in dogs as well as an assessment of his clinical experience, that the quality and quantity of newly formed bone (“regenerate bone”) stimulated by the generation of “tension-stress” during limb elongation depended on the rigidity of external

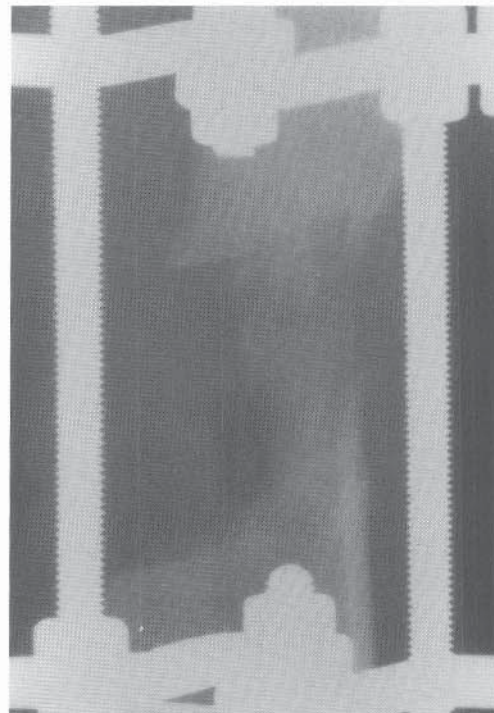
fixation, the extent of damage to the soft tissue and medullary canal at the time of osteotomy, the rate (speed) of distraction, and the frequency of the increments (rhythm) of distraction.^{224,225} Ilizarov found experimentally that new bone formation in the distraction gap was most exuberant when the medullary artery was preserved and soft tissue injury at the time of osteotomy was minimized. Other clinical investigations have concluded that the important features of an osteotomy resulting in acceptable new bone formation are minimal soft tissue injury during exposure of the bone and avoidance of bone necrosis by excessive heat generation as may be produced by an oscillating saw, rather than the preservation of the medullary artery.^{82,194,316,466} An important principle of callotasis is the “latency period,” during which the soft tissues stabilize, fracture callus develops, and the blood supply to the osteotomized region, including the intramedullary vessels, reconstitutes.⁴⁵⁵

Ilizarov found experimentally that continuous distraction at a rate of 1 mm per day was the ideal rate and rhythm of distraction in the formation of new bone in the distraction gap; for practical purposes, dividing the daily rate into four $\frac{1}{4}$ -mm increments provided adequate new bone formation. This “rate” of 1 mm per day with a “rhythm” of $\frac{1}{4}$ -mm increments is firmly established in current clinical practice, but it must be modified by the quality of new bone formation in each individual patient.

The gap tissue between the bone ends is characterized by dense, longitudinally arranged collagen bundles. Ilizarov reported a “growth zone” in the middle of this distraction gap simulating a growth plate (physis). Other investigations



A



B

FIGURE 23-43 An uneven column of new bone formation may be seen during the distraction phase. A, Slower radiographic evidence of ossification is typical around bone with poorer soft tissue coverage, such as the anteromedial tibia. B, New bone formation may also be poorer on the side from which the surgical approach to the bone was made for the osteotomy. In this example, the distal femur was approached from the medial side. The presumed etiology of this phenomenon is damage to the periosteal and endosteal blood supply by the surgical approach.

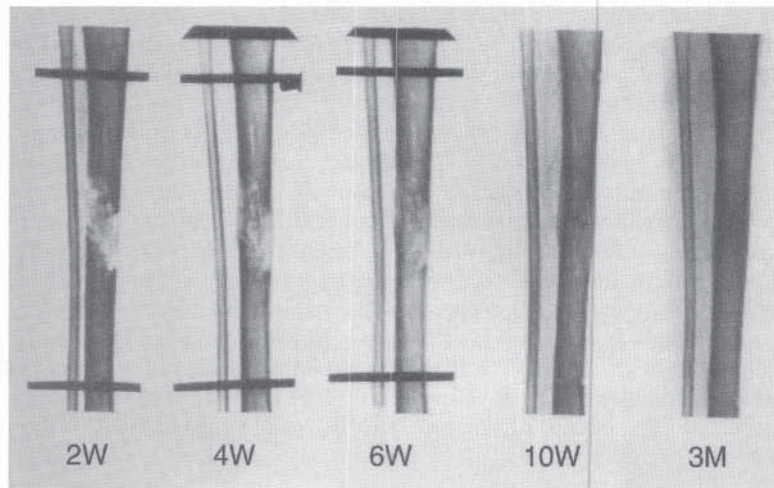


FIGURE 23-44 Kawamura's experimental distraction using an external fixator, published in 1968.²⁴¹

have demonstrated primarily intramembranous ossification of this collagenous tissue, with or without an intermediate cartilaginous precursor phase (or enchondral bone formation) (Fig. 23-42).^{194,467}

Other important factors affecting the extent and quality of new bone formation include the age of the patient, the location of the osteotomy, the amount of soft tissue surrounding the distraction gap, and the direction of the surgical approach.^{82,127,128} Specifically, metaphyseal osteotomies tend to heal more quickly than diaphyseal osteotomies, the proximal tibia tends to heal more quickly than the distal, the anterior tibia tends to heal more slowly than the posterior, and the side of surgical approach tends to heal more slowly than the unexposed surfaces (Fig. 23-43).

Effect on muscle: The effect of lengthening on the function of muscle, and correspondingly the resistance to lengthening by muscle tissue, was noted by the earliest descriptors of limb lengthening, including Codivilla⁸⁶ and his student, Putti.³⁶¹ It is fascinating to read Codivilla,⁸⁶ who in 1905 wrote, "We are in fact, without the requisite knowledge as to how the normal muscles and other tissues act, when subjected to forced distension; as to how great an extent they are capable of being lengthened, without their physiologic action being altered . . .," or Putti, who in 1934 wrote, "My experience with bone lengthening since the Great War has emphasized in my own mind that one must give much study to the muscular and ligamentous structures attached to the femur, as the handling of these structures in my opinion presents the greatest difficulty encountered in obtaining a successful result."³⁶¹ The harshest critic would argue that little progress has been made in the intervening period with respect to the impact of lengthening on muscle, and how that can be favorably altered by limb lengthening techniques.*

Kawamura and colleagues studied the effect of lengthening on bone and soft tissue extensively.²⁴¹ Their studies led them to conclude that limb lengthening causes temporary damage to muscle (worse in denervated muscle) and moderate to marked decreases in mono- and polysynaptic reflexes after 15 percent lengthening, and that blood flow to the

affected limb usually *decreased* with lengthening. The latter effect was reversed by medicating patients with diazepam. The published clinical and radiographic figures of one of their cases are remarkably reminiscent of radiographs of current callotasis techniques (see below) (Fig. 23-44).

The precise nature of response of muscle to distraction is poorly understood. Sun and colleagues found in an experimental study that myofibrillogenesis occurred, primarily near the myotendinous junction.⁴²¹ Matano and colleagues, in another experimental investigation, found that sarcomere length initially increased in response to stretch, then subsequently decreased.²⁸⁵ This suggested to the authors that muscle adapted to stretch by the addition of sarcomeres. However, increased fibrosis of the epimysium and perimysium has been noted by other investigators,^{157,459} suggesting decreased compliance of the muscle, with the potential result of loss of muscle function. On a macroscopic level, loss of muscle strength at the knee corresponding to the extent of lengthening has been noted.^{237,275} Overall, soft tissue (primarily muscle) tolerance of gradual lengthening seems to be limited to 15 to 20 percent of the original length of the lower limb segment, and lengthenings greater than this amount are associated with substantially higher incidence of complications.

Effect on peripheral nerves: Ilizarov described histologic evidence of development and growth of nerves, including axon elongation and Schwann cell lengthening and envelopment around the lengthened axon.²²⁴ Other studies, however, indicate a more deleterious effect of lengthening on peripheral nerve function in both experimental animals and clinical studies, particularly as assessed by nerve conduction and electromyographic investigations.* Wall and colleagues noted that acute stretching of the tibial nerve 12 percent beyond its original length in an experimental model resulted in complete loss of nerve conduction.⁴⁵¹ Ippolito and colleagues noted loss of myelin fibers after as little as 8 percent lengthening in an animal model.²²⁸ Electrophysiologic examinations of patients after tibial lengthenings have revealed high rates of abnormalities.^{148,353,470}

Effect on joints/articular cartilage: The one tissue that appears to incur only deleterious effects from lengthening

* See references 108, 157, 237, 258, 275, 285, 303, 309, 378, 396, 421, 422, 459, 465, 471.

* See references 31, 148, 219, 228, 260, 278, 353, 418, 451, 470.

is articular cartilage.^{320,389,406,411} Shevtsov and Asonova noted that the severity of degenerative changes in the knee of experimental animals was directly related to the duration of immobilization in an Ilizarov apparatus, and that subsequent unrestrained activity actually increased the amount of cartilage degeneration.³⁸⁹ Nakamura and colleagues noted that the severity of fibrillation of articular cartilage could be ameliorated by increasing the rhythm of distraction (120 increments, compared to two).^{319,320} Stanitski noted gross cartilage fibrillation and loss of proteoglycan staining in the knees of dogs undergoing 30 percent femoral lengthening.⁴⁰⁶ In a second study in which the apparatus was extended across the knee, articular cartilage demonstrated decreased proteoglycan staining but no gross fibrillation.⁴¹¹ Stanitski concluded that extending the apparatus across the knee had a protective effect on cartilage by preventing joint compression during lengthening.

Clinical investigations suggest that joint motion may be relatively preserved after lengthenings unencumbered by complications compromising joint function.^{60,206} Herzenberg and colleagues found that knee flexion averaged 127 degrees preoperatively compared to 122 degrees postoperatively in a series of 25 femoral lengthenings; two patients lost more than 15 percent of flexion compared to preoperative values.²⁰⁶ Bowen and colleagues found in a series of 23 patients that those undergoing femoral lengthening with ring-and-wire fixation and distal osteotomy had significantly reduced knee range of motion than patients undergoing lengthening after mid-diaphyseal osteotomy and monolateral fixation with Shanz half-pins.⁶⁰ Based on these experimental and clinical studies, it is unlikely that long-term follow-up will be kind to the assessment of the impact of lengthening on joint function and the development of early degenerative arthritis.

Complications of Lengthening. The incidence of complications associated with gradual leg lengthening has been reported to be as low as 14 percent¹⁰⁷ and as high as 134 percent (i.e., more than one complication for each segment lengthened).³²⁸ These widely divergent reports, and all in between, are more a reflection of the different definitions of “complication” in relation to limb lengthening and the diligence with which these events are sought. Wagner suggested that untoward events occurring during lengthening should be thought of as *problems* (intrinsic, cannot be avoided, and must be dealt with) and *complications* (extrinsic, must be avoided).⁴⁴⁹ Paley classified these untoward events as *problems* (difficulties not requiring operative intervention to resolve), *obstacles* (difficulties requiring operative intervention but without permanent sequelae), and *complications* (intraoperative injury or any difficulty resulting in permanent sequelae).³⁴⁰ However, I share the opinion of Stanitski and colleagues⁴¹² that any untoward event that transpires during lengthening or after apparatus removal is a complication *to the patient*, even though we as surgeons can acknowledge that the impact and long-term significance of different complications will vary in their nature and severity. Although the more modern methods of callotasis and improved fixation represent significant advances in our ability to perform lengthening with substantially reduced risks of complications, lengthening procedures still carry a very high to nearly certain risk of complications that we as surgeons would not tolerate in other reconstructive procedures. The reader and

any surgeon undertaking lengthening on behalf of a patient must be thoroughly versed in the myriad complications that can arise from attempted leg lengthening.* What follows is a *partial* list of complications associated with limb lengthening using current methods.

Nerve/vessel injury during application of device: Acute nerve or vascular injury during application of an external fixator is an uncommon but significant problem.^{24,279,281,340,442} The likelihood of acute nerve injury would seem to be higher with the use of transfixing wires, such as with the Ilizarov device, and in patients with distorted anatomy. Intimate familiarity with cross-sectional and surface anatomy, supplemented by a good textbook on this subject,^{20,125} is mandatory for any surgeon performing external fixation for any reason. Unfortunately, such knowledge will not necessarily prevent injury, since anatomic variations or severe deformities make the extrapolation of normal anatomy to the deformed limb ineffective. Peripheral nerve monitoring similar to spinal cord monitoring using sensory-evoked potentials has been described as an aid in the prevention of peripheral nerve injury during surgery.^{278–281} Alternatively, the surgeon may replace any half-pin or wire that causes stimulation of the distal extremity during insertion; this technique requires that muscle-paralyzing agents not be used during anesthesia.

Incomplete corticotomy: When a low-energy “corticotomy” is performed through a small incision with surgical efforts to minimize soft tissue injury, incomplete osteotomy may occur. When the patient commences gradual distraction, tension will develop within the distracting apparatus without bone separation (Fig. 23–45A). This complication can be avoided by using a Gigli saw to perform the osteotomy, or by distracting the osteotomy site intraoperatively to confirm complete division of the bone. A radiograph of the distraction site should be taken within a few days of initiation of distraction to confirm uneventful early distraction.

Premature consolidation: This complication is unique to gradual distraction techniques of callotasis (see previous discussion under Callotasis). On occasion, the rate of distraction will be inadequate for the maintenance of continued fragment separation, and premature consolidation will occur. The clinical setting will be similar to that of incomplete corticotomy, but after an initially successful distraction period (Figs. 23–45B and C). Factors in the development of premature consolidation include individual exuberant new bone formation, lack of patient compliance with the distraction protocol, an inadequate prescribed rate of distraction, and mechanical failure of the distraction mechanism. Treatment consists of mobilization of the premature consolidation by either closed manipulation or osteotomy of the regenerate bone with rapid resumption of distraction.

Poor regenerate bone formation: The opposite of premature consolidation is poor regenerate bone formation. This may be a global phenomenon (see Fig. 23–43), or there may be a focal defect (Fig. 23–45D). Poor new bone formation can lead to excessive consolidation time, fracture of regenerate bone, loss of length, or regenerate bone bending. Factors leading to poor new bone formation include too short a

* See references 17, 60, 79, 101, 103, 117, 123, 148, 149, 154, 177, 185, 193, 212, 217, 219, 257, 272, 297, 301, 304, 320, 333, 340, 358, 388, 397, 408, 418, 419, 423, 435, 442, 443, 469, 470.

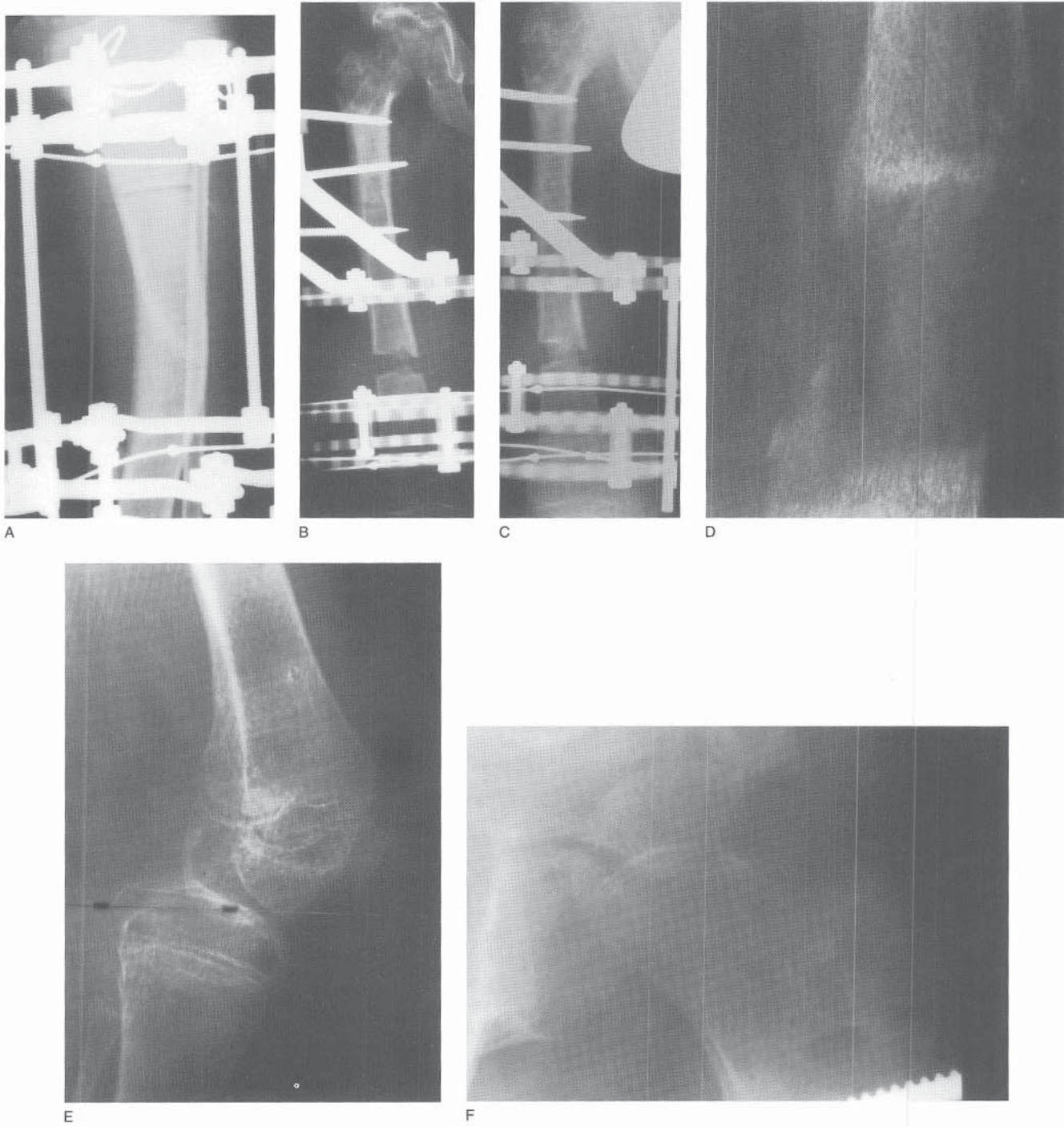


FIGURE 23-45 Complications associated with limb lengthening, particularly in association with the callotasis technique. **A**, Incomplete corticotomy. Despite 5 days of distraction, there is no separation of the bone fragments of the upper tibia. Note bending of the wires from the distraction of the apparatus without concomitant distraction of the bone. Surgical completion of the corticotomy was necessary. **B** and **C**, Premature consolidation. Distraction was stopped because of the development of knee flexion contracture (**B**). During the pause, the regenerate bone consolidated. The clinical and radiographic features are similar to incomplete corticotomy (note bending of the wires and half-pins in **C**). Repeat corticotomy was necessary. **D**, Poor new bone formation may be global, due to too rapid distraction, poor local blood supply, or other poorly understood host factors. **E**, Knee subluxation after femoral lengthening. Note the lack of full extension at the knee, and the posterior subluxation of the tibia on the femoral condyles. **F**, Proximal and posterior subluxation of the hip during femoral lengthening. This event occurred despite a preliminary Steel triple innominate osteotomy performed for acetabular dysplasia associated with congenital femoral deficiency.

Illustration continued on following page

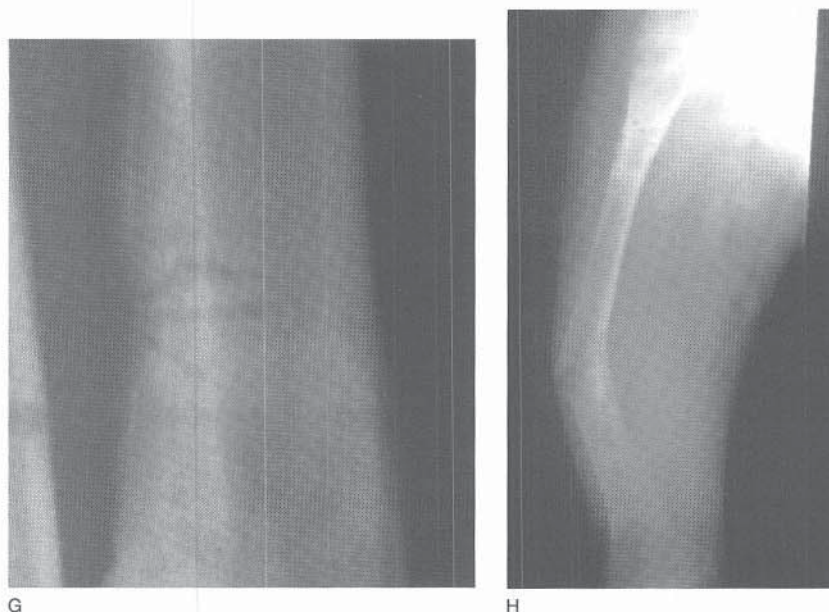


FIGURE 23–45 *Continued.* **G**, Ring sequestrum of the tibia at the site of a previous wire. Local debridement of necrotic bone was required. **H**, Regenerate bone fracture after apparatus removal. Axial deformity and loss of length invariably result from this event.

latency period, too rapid distraction, the location of the osteotomy site (metaphyseal level better than diaphyseal), excessive soft tissue injury during osteotomy, soft tissue injury by the surgical approach, preexisting poor vascular supply or soft tissue coverage, and local soft tissue anatomy (such as the anterior tibia).^{*} Reducing the rate of distraction, ceasing distraction altogether, compression of the distraction gap, and manipulation of the distraction gap may improve new bone formation in the distraction gap.

Joint subluxation: One of the most serious complications of leg lengthening is joint subluxation or frank dislocation. Typically, the hip and knee are at risk for subluxation or dislocation during femoral lengthening.[†] Anterior or posterior subluxation of the knee has been rarely reported during tibial lengthening. Risk factors for joint subluxation or dislocation include excessive lengthening, continued lengthening despite the development of contracture (especially hip flexion or adduction, and knee flexion), preexisting joint instability, or preexisting joint dysplasia. The development of joint subluxation is potentially catastrophic to the preservation of limb function. The best treatment is prevention by regular detailed clinical and radiographic examination assessing the development of contractures that predispose to subluxation. Significant acetabular dysplasia should be corrected by reconstruction prior to lengthening. If the risk of subluxation is considered significant and lengthening is still considered essential, prophylactic stabilization of the at-risk joint should be undertaken by extending the external fixation beyond that joint. If subluxation occurs, lengthening must stop, or be reversed. Vigorous physical therapy aimed at restoring motion must be instituted. If the subluxation does not respond promptly to this treatment (and it usually will not), extension of the lengthening device to incorporate the subluxed joint with gradual distraction and relocation of

the joint can be undertaken. This is most easily accomplished with circular fixation (see discussion under Ilizarov Apparatus, below). Soft tissue releases may be needed to help relocate the joint. Even when the joint is reduced with these measures, stiffness usually persists, and the long-term prognosis for the development of degenerative arthritis is high (Figs. 23–45E and F).

Neuropraxia and lengthening: In addition to acute nerve injury at the time of external fixation, neuropraxia can occur with lengthening.^{*} This may be due to a pure overstretching phenomenon, or it may be due to the development of nerve encroachment by an external fixation element due to alteration in the soft tissue–fixation element relationship. The peroneal nerve is more susceptible to this development. We believe that developmental neuropraxia should be treated by discontinuation of lengthening and careful clinical assessment of potentially offending wires or half-pins. If nerve function does not recover promptly, we believe that exploration of the nerve should be carried out prior to resumption of lengthening. Permanent nerve injury from leg lengthening is rare but does occur.

Pin site infection: Pin site infection is nearly universal in external fixation for leg lengthening owing to a combination of the duration of fixation and the need for fixation elements to move through the soft tissue, with attendant necrosis. Pin tract infections are so common that authors will report a frequency of 100 percent or will not even address this as a complication.

Sequestrum: Much less frequent than the development of pin site infection is the development of a true ring sequestrum. The presumed mechanism for the development of a ring sequestrum is bone necrosis secondary to excessive heat generation during insertion of the fixation element, followed by contamination by pin site infection (Fig. 23–45G). Re-

^{*} See references 127, 128, 193, 194, 265, 271, 274, 316, 379, 391, 455, 466, 468.

[†] See references 149, 234, 328, 339, 340, 371, 408, 423.

^{*} See references 24, 77, 148, 219, 260, 278, 333, 339, 340, 353, 418, 442, 451, 470.

removal of the offending half-pin or wire and curetting of the bone locally will be required.

Regenerate bone fracture: A significant complication of lengthening is fracture or bending of regenerate bone after apparatus removal. This can occur acutely, with the patient experiencing sudden pain and deformity, or gradually, with little pain but an awareness of the development of deformity (usually reported as “swelling”) (Fig. 23–45H). Rapid consolidation of the regenerate bone usually ensues, but almost always with a loss of length or the development of angular deformity. Treatment options include re-application of external fixation with osteotomy of the regenerate bone, closed osteoclasis with immobilization in a cast, or osteotomy and internal fixation. Current methods for determining the development of sufficient regenerate bone strength to prevent this complication are inadequate, and the incidence of fracture is as high as 10 to 15 percent. Prolonged external fixation, gradual disassembly of the external fixation device, temporary immobilization in a cast or brace after device removal, and internal fixation are treatment options to help prevent this complication.

Subsequent growth disturbance of the lengthened limb: There are many reports of significant deceleration of expected growth after leg lengthening in skeletally immature patients.* The presumed pathophysiology of this observation is as a direct response to increased pressure across physes after lengthening or hyperemia as an indirect consequence of increased blood flow to the limb during lengthening. This can result in the development of unexpected angular deformity or effective loss of length. Avoiding excessive lengthening and deferring lengthening until skeletal maturity whenever feasible are ways to avoid this complication.

Psychological stress: The prolonged treatment protocol, intensity of treatment of the extremity, and chronic pain, even if mild or moderate, may all result in significant psychological stress for both the child and parents.^{154,217,362,408,469} Younger children typically have trouble sleeping and lose weight during extended treatment regimens. Careful preoperative assessment of family stressors with the aid of clinical psychologists, extensive education of the child and family as to the nature of the entire procedure, and thoughtful selection of appropriate candidates for these extensive, extended treatment programs by the surgeon are all important prerequisites to proceeding with leg lengthening.

Other complications: In addition to these well-recognized complications, joint loss of motion, joint contracture, and muscle weakness may result from the effect of significant muscle tensioning by bone elongation. All of these untoward events are undoubtedly thought of as complications by the patient, and therefore should be carefully explained to prospective patients, guarded against, recognized and treated appropriately when they occur, and be given due consideration when the surgeon considers whether a child should undergo leg lengthening at all.

Indications for Leg Lengthening. In 1958, after evaluating 40 patients who had undergone leg lengthening 20 or more years previously, Sofield and colleagues stated that “we cannot escape the fundamental concept that improved function, not just increased length, is the objective, and that these

terms are not synonymous.”⁴⁰¹ The reader and all surgeons with the technical expertise to carry out leg lengthening would do well to remember these words, as they are as true today as when they were written. Each surgeon must carefully weigh the risks and benefits of leg lengthening in all patients with due consideration for the direct predictable consequences of bone lengthening with resultant soft tissue tensioning, and the possibility of the development of the innumerable complications discussed above.

Based on the work of Song and colleagues,⁴⁰³ we believe that compensatory mechanisms begin to break down with the development of the strategy of toe-walking, which as a generality occurs when limb shortening reaches 5 percent of the contralateral limb (approximately 4 cm in a patient with 50th percentile length to the tibia and femur). Thus, we believe that an expected limb length inequality of 4 cm can be considered a relative indication for leg lengthening. Although no absolute indications for lengthening can be set because of all the potential complications associated with this extensive reconstructive procedure, serious consideration should be given to leg lengthening when the expected shortening approaches 10 percent (8 cm), since attempts to correct discrepancies of this magnitude by shortening procedures may be excessive. Angular deformities requiring correction when associated with ipsilateral shortening can also be considered a relative indication for limb lengthening.

Whenever leg length inequality is 10 percent or less of the contralateral limb, we prefer to delay lengthening until skeletal maturity, provided that function of the limb is not compromised. This avoids the subsequent growth disturbance that potentially results from leg lengthening during growth and allows a more precise estimation of the amount of lengthening required. If greater discrepancy is anticipated, we combine lengthening with an appropriately timed contralateral epiphysiodesis, or we perform staged lengthenings of 15 to 20 percent of the original length of the bone segment under treatment.

Wagner Device. Heinz Wagner introduced his apparatus into the English literature in 1978,⁴⁴⁹ although his device had been in use since 1972.^{88,211} For some time, his method and device were the treatment of choice for limb lengthening.* His technique for femoral lengthening consisted of soft tissue release of the fascia lata and lateral intermuscular septum and application of his lengthening device. Two heavy Shantz screws were inserted into the bone above and below the osteotomy site and secured to his special telescopic device. Intraoperatively, acute distraction of approximately 1 cm was performed after diaphyseal osteotomy. A few days postoperatively, daily distraction of 1 to 2 mm in one or two increments was begun, performed by the patient or caretaker turning a knob at the end of the device. After completion of lengthening, if adequate consolidation was not to be expected within a “reasonable” period, internal fixation with a special lengthening plate and iliac crest bone graft was performed (see Fig. 23–35, Wagner technique).

Wagner emphasized a number of important principles, which are still true. The joints above and below the segment to be lengthened should be stable and without significant radiographic abnormality, or able to be made so. Patients

* See references 79, 212, 304, 358, 387, 388, 443.

* See references 3, 45, 60, 75, 77, 87, 88, 100, 176, 181, 211, 217, 238, 249, 271, 272, 284, 321, 339, 346.

should be cooperative and highly motivated, since the procedure is prolonged, complicated, and dependent on the patient's compliance with an exercise program. Children less than 8 years old should rarely undergo lengthening procedures since they are too young to be expected to cooperate or understand the procedure being carried out on their limbs. Lengthening for discrepancies less than 7 cm should be delayed until skeletal maturity if clinically appropriate to avoid the uncertain effect of lengthening on subsequent growth.

Results of lengthening: Wagner reported the results of femoral lengthening in 58 patients under the age of 17.⁴⁴⁹ Forty-four of them had undergone 89 preliminary "corrective" procedures. The average amount of lengthening was 6.8 cm; seven had undergone repeated lengthenings for an average total lengthening of 18.7 cm. He reported a 100 percent rate of pin "contamination" but only one pin site infection; four cases of deep infection, which resolved on removal of the plate; and three cases of joint subluxation/dislocation. Although he commented that the complication of fatigue fracture had been resolved by using a more flexible plate, he did not report the incidence of this fracture or the incidence of bone graft procedures in this patient population. Other authors reported good results,* although with complication rates as high as 92 percent²¹¹ and generally cautionary comments as to the complexity of this reconstructive procedure.

However, Jones and Moseley noted posterior subluxation of the knee in seven of 21 patients treated by femoral lengthening,²³⁴ and Salai and colleagues reported three cases of hip subluxation in 24 cases of femoral lengthening.³⁷¹ Luke and colleagues noted 10 fractures in eight patients (out of a group of 27 undergoing Wagner-type lengthening), seven of which required open reduction and fixation, and questioned the quality of bone healing after this form of lengthening.²⁷² Several authors noted that modifying the surgical technique to "corticotomy and callotasis" principles (preservation of the periosteum and soft tissues, no immediate distraction, and delayed distraction) combined with the Wagner external fixation device improved results.^{284,339,346} Finally, direct comparison between the Wagner apparatus and technique and the Ilizarov apparatus and technique demonstrated a generally lower rate of complication and improved bone healing with the latter.^{3,100,238,249} As a consequence, the Wagner method has been supplanted by corticotomy and callotasis techniques (described above), and by other forms of external fixation.

Dynamic Axial Fixator. De Bastiani and colleagues^{8-10,105-107} popularized the application of Ilizarov's concepts of low-energy "corticotomy" with a latency period prior to distraction and gradual distraction of the callus tissue (callotasis), and many publications regarding the techniques and results of this method and apparatus have been published subsequently.† De Bastiani and colleagues actually originally described the use of the monolateral fixator either for chondrodiastasis^{105,106} or for callotasis.¹⁰⁷ In their original description,¹⁰⁷ these authors recommended a 10- to 15-day latency period, followed

by ¼-mm incremental lengthening every 6 hours for the callotasis technique.

The apparatus itself consists of one of two types of external connecting bodies, a simple linear distractor (lengthener) with a telescopic body (available in several lengths), and a similar device with articulating, adjustable ends (fixator). The authors recommend use of the lengthener for lengthening, since the articulating joint of the fixator is prone to deformation with lengthening as soft tissue tension develops. The latter device is more suitable for fracture management. Either device is secured to the bone using conical, tapered half-pins, which are available in a variety of sizes.

The major advantage of this and related types of monolateral fixation is that they are easier for the surgeon to apply properly and for the patient to accommodate compared to circular external fixators. The device is relatively well tolerated by patients compared to circular external fixation, and a general anesthetic is typically not required for removal. However, the ability to correct axis malalignment or joint subluxation is much more restricted than with circular fixators, should these complications arise during lengthening.

Results of De Bastiani technique of leg lengthening: De Bastiani and colleagues described only 14 complications (14 percent) during the lengthening of 100 bone segments: premature consolidation of the lengthening bone, premature consolidation of the fibula, loosening of the half-pins requiring revision, and fracture after fixator removal (five patients).¹⁰⁷ Although other authors noted acceptable or improved results with this method compared to Wagner's technique, complication rates have been much higher.* Price and Cole, in a series of 11 segment lengthenings in 10 patients, reported 13 minor complications not requiring anesthesia or hospital admission, and three cases of angular deformity developing during lengthening that required manipulation under anesthesia.³⁵⁹ Schlenzka and colleagues reported good results in 10 patients.³⁷⁶ However, all four patients undergoing femoral lengthening developed varus deformity secondary to loosening of proximal femoral half-pins, which required revision. They solved the problem of the ball-joint connectors deforming with lengthening by locking them with methylmethacrylate. Noonan and colleagues reported the results of lengthening of 261 femora and tibiae using monolateral fixation and callotasis techniques.³²⁸ These authors recorded 114 complications in 114 femora, which led to 87 additional surgical procedures, and 196 complications, leading to 219 additional procedures in 147 tibial lengthenings. The monolateral devices used included Wagner, Orthofix (Orthofix, Verona, Italy), and Monotube (Howmedica, Rutherford, N.J.).

Ilizarov Apparatus. Ilizarov began his work with external fixation for the management of fractures, deformity correction and lengthening using a circular fixator, and fine, crossed, tensioned wires in the Kurgan region of Siberia in the early 1950s.^{20,166,224-227,405} Although initially not recognized for his contributions to the field of limb lengthening and deformity correction either in the former Soviet Union or the rest of the world, appreciation of the value of his method and apparatus is now universal. Ilizarov published extensively, primarily in Russian, on the principles and application of

* See references 18, 45, 77, 181, 211, 339, 414.

† See references 100, 163, 185, 276, 328-330, 356, 357, 359, 360, 376.

* See references 100, 185, 276, 328, 359, 360, 376.

his method of lengthening and use of his apparatus. Only in 1989 did he publish a portion of his extensive studies of the biology of lengthening in English.^{224,225} His apparatus and methods have been the focus of many investigations and reports since their introduction to the rest of the world.*

The most important contribution to limb lengthening provided by Ilizarov was undoubtedly his investigations into the effect of gradual distraction on both bone and soft tissues (see the previous discussion in the section Lengthening of the Short Leg, under the subsection Gradual Lengthening). Ilizarov's circular external fixator is inherently more complex than other devices used for either lengthening or deformity correction. This feature provides flexibility to the surgeon in the application of the apparatus to virtually any clinical deformity, but it also demands a thorough understanding of bony and soft tissue anatomy, the biological principles of lengthening and deformity correction, and the mechanical features of the apparatus itself. In essence, in current practice, for the purposes of leg lengthening, the circular external fixator is fixed to the femur or tibia using fine crossed wires tensioned to the rings, or a combination of wires and half-pins. The apparatus is fixed to the bone segment so that its axis parallels that of the bone. The bone is divided with a low-energy, soft tissue-preserving osteotomy ("corticotomy"), and subsequently lengthened using the callotasis technique described above.

Major advantages of the Ilizarov apparatus for leg lengthening include the ability to correct residual angular or rotational deformities without removing the apparatus, or without anesthetic; and the ability to extend the apparatus beyond the bone segment undergoing lengthening (such as the knee during femoral lengthening, or the ankle-foot during tibial lengthening) to stabilize the adjacent joint or improve fixation, as required in specific individual circumstances. The reader is cautioned that the complexity of the application of Ilizarov's apparatus for deformity correction and limb lengthening requires intimate familiarity with the device, the surgical technique of its application to the limb, and aftercare. Use of this device in a clinical setting requires specific training and guided experience beyond the scope of this or any textbook.

Results of use of apparatus for leg lengthening: In addition to the publications of Ilizarov²²⁴⁻²²⁷ and the ASAMI group,²⁰ a number of studies on the use of the Ilizarov apparatus in children have been published.† Bonnard and colleagues performed 26 femoral or tibial lengthenings in 24 children, for an average lengthening of 5 cm.⁵⁵ The healing index averaged 35 days. Only 13 of the 26 lengthenings were without complication. Complications included incomplete corticotomy, knee and/or ankle stiffness, and one case of hip subluxation. The desired length was achieved in 88 percent. The authors noted that the complication rate, particularly infection, was lower than that experienced with the Wagner method. Stanitski and colleagues reported results in a group of 30 children undergoing 36 femoral lengthenings, with an average lengthening of 8.3 cm in an average 6.4

months.⁴⁰⁸ This group encountered four cases of premature consolidation, two cases of malunion, and two cases of knee subluxation. Lengthening had to be discontinued in two patients because of psychological problems. The authors felt the Ilizarov technique showed significant improvement in results and reduction of complications compared to other lengthening techniques. Stanitski and colleagues also reported the results of 62 tibial lengthenings in 52 children using the Ilizarov technique.⁴¹² The average amount of lengthening was 7.5 cm (32 percent increase in length). There were 28 unplanned operative procedures.

Combined Internal and External Fixation for Lengthening (Lengthening over Intramedullary Rods). A significant problem associated with gradual lengthening of fracture callus is the prolonged consolidation phase spent in external fixation awaiting the moment when the surgeon has deemed that enough strength has developed in the lengthened segment to allow removal of the apparatus. To circumvent this period, lengthening of the femur or tibia over intramedullary rods with locking of the fragments to the rod at the completion of distraction and removal of the external fixation device has been proposed.* Interestingly, Bost and Larsen in 1956 were the first to publish experience with lengthening of the femur over an intramedullary rod.⁵⁶ At a single stage, through a Kocher approach, with the patient in a lateral decubitus position, the femur was divided either in a step-cut fashion, obliquely, or, their preference, transversely. An intramedullary rod (the authors did not specify a particular type) was inserted into the femur after osteotomy. Steinmann pins were introduced into the proximal and distal femur for traction and countertraction (usually one pin proximally in an AP direction) and two or three transversely distally in the distal femur, sometimes including the proximal tibia. The patient was then placed either in a Thomas splint for traction-countertraction or in an external frame designed by Bost. Gradual traction was continued until the desired length was achieved (in their series, averaging 11 weeks), and the patient was then placed in a spica cast after adequate consolidation had occurred, until union (an average of 32 weeks in patients not requiring bone graft and 72 weeks in those who required supplemental grafting). The purpose of the rod was to maintain fragment alignment. Bost and Larsen reported the results of 23 femoral lengthenings of $\frac{3}{8}$ to $4\frac{1}{4}$ inches in children. Ten femora required bone grafting to complete consolidation. The authors felt that the need for bone grafting and the length of time to union were directly related to the amount of lengthening, but that neither the reason for shortening nor the osteotomy type influenced the rate of consolidation. Emphasizing the seriousness of limb lengthening procedures in this era, they happily reported no deaths or loss of limb. The rate of other complications was, however, sobering. Seven patients developed late peroneal nerve palsy, and in two it was permanent. Knee deformity developed in seven patients, including five with posterior subluxation; four other patients lost knee range of motion. The intramedullary rod migrated proximally in four patients, bent in two, and broke in one. There were four late femoral fractures. This was all in addition to 11 patients with delayed union, 10 of whom had secondary bone grafting. There were no

* See references 3, 19-21, 24, 25, 30, 39, 55, 72, 97, 98, 101, 103, 104, 110, 151, 152, 154, 155, 176, 207, 218, 219, 221, 238, 248, 271, 289, 298, 323, 338, 341, 363, 389, 390, 393, 408, 410, 412, 442.

† See references 3, 19, 21, 24, 30, 39, 49, 55, 72, 79, 80, 98, 151, 154, 155, 189, 205, 207, 238, 271, 298, 323, 324, 363, 408, 409, 412, 442.

* See references 242, 251, 261, 266, 342, 395.

infections from the primary procedure, but there were three infections after supplemental bone grafting.

Wasserstein described a technique of femoral or tibial lengthening over a ribbon-like nail using external fixation and callotasis protocol.⁴⁵² However, the rate of lengthening was 1 to 2 mm per day, determined by patient tolerance, without regard for the quality of regenerate bone formation. At the end of distraction, a slotted allograft of axially oriented femur or tibia was inserted over the rod within the osteoperiosteal sleeve of new bone in the distraction gap. The external fixator was then compressed to promote union and could usually be removed within 6 to 8 weeks, according to Wasserstein. He recommended the procedure only for lengthenings greater than 6 cm, since an adequate rate of consolidation could be expected from the regenerate bone alone, without resort to a second operative procedure or use of the allograft, after lesser amounts of lengthening.

Kempf and colleagues used a step-cut osteotomy and locked intramedullary rod for acute femoral lengthening in 17 patients.²⁴² They reported 13 complications, including significant loss of length in five, femoral nerve palsy in four, three deep infections, and one nonunion. These authors concluded that acute femoral lengthening over a locked intramedullary rod should not exceed 4 cm.

More recently, Paley and colleagues described gradual lengthening by external fixation performed over a lockable intramedullary rod.³⁴² Other authors have reported the use of this technique both in the femur and in the tibia.^{251,261,266,395} The technique consists of simultaneous insertion of the intramedullary rod, external fixation, and osteotomy. After the desired lengthening is achieved, the patient undergoes a second stage of surgery when the external apparatus is removed and the rod is "locked" with screws (Fig. 23-46). The authors compared 32 lengthenings in 29 patients undergoing this procedure for an average lengthening of the femur of 5.8 cm with 32 standard Ilizarov femoral lengthenings in

31 patients. The "lengthening over nails" technique reduced the time in external fixation by one-half, resulted in earlier consolidation of the distraction gap and a more rapid return of knee motion. One nail and one proximal locking screw failed. There were no infections; however, the cost of treatment and average blood loss were higher in the "lengthened over nails" group. Simpson and colleagues reported good results in 20 cases of lengthening over a nail (18 femoral and two tibial), but did have three cases of deep infection, which responded to debridement and removal of the intramedullary nail after consolidation of the distraction gap.³⁹⁵ Marshall and colleagues found the risk of infection with intramedullary rodding after the use of external fixation for either fracture or lengthening to be low, and not a contraindication to this technique.²⁸³ Lin and colleagues also reported only one deep infection in 15 cases of femoral or tibial lengthening over an intramedullary rod.²⁶⁶ Kristiansen and Steen, however, sounded a cautionary note.²⁵¹ In a series of nine tibial lengthenings over intramedullary rods for short stature, they found that consolidation was very slow, averaging 4 months per centimeter of lengthening. This resulted in three fatigue fractures of the implants, requiring revision, and supplemental bone grafting in one. Furthermore, one patient developed a deep wound infection. As a result, these authors returned to the traditional Ilizarov method using external fixation alone.

Totally Implantable Lengthening Devices. An intriguing concept is that of a totally implantable lengthening device. Such a device would have the obvious benefit of requiring no period of external fixation, and would at least theoretically reduce concerns of infection associated with the combination of external and internal fixation. Guichet notes that Bliskunov is credited with the design of the first such device, for the femur. Two other femoral rods designed for this purpose have been described, one working on a purely mechanical

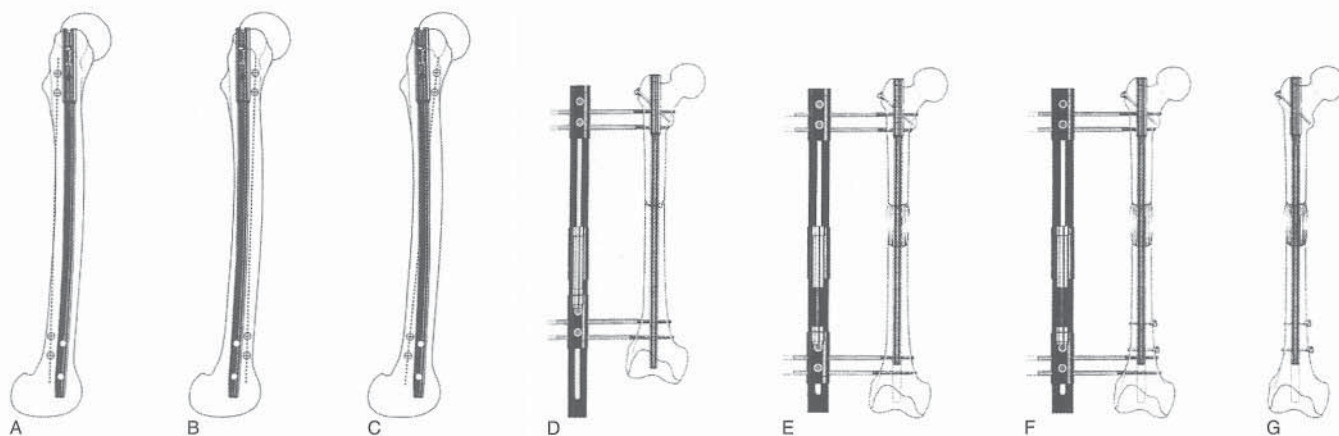


FIGURE 23-46 Scheme of femoral lengthening over a locked intramedullary nail, as described by Paley and colleagues.³⁴² A, A femoral lockable intramedullary nail is inserted after diaphyseal osteotomy, and locked proximally. An external fixator is applied to avoid contact between the external and internal fixation devices. In this example, half-pin fixation (denoted by ⊕) is located posterior to the rod both proximally and distally. B, Half-pin fixation anteriorly proximally and distally. C, Half-pin fixation anteriorly proximally, and posteriorly distally. D, Intramedullary fixation with proximal locking screw inserted. An external fixator (Orthofix) is applied parallel to rod. E, Lengthening over intramedullary nail performed with an external fixator. F, After lengthening is completed, distal locking screws are inserted into the intramedullary nail. G, The external fixator is removed after the distal locking screws have been inserted.

racheting mechanism¹⁸² and the other a transcutaneously controlled hydraulic system.³² However, at the present time, neither device is available for routine clinical use in North America.

SUMMARY OF LOWER EXTREMITY LENGTHENING. Leg lengthening represents one of the most significant and complicated reconstructive procedures that an orthopaedic surgeon can undertake on behalf of the patient. The surgeon should be very familiar with the principles of lengthening and the myriad complications that can develop as a consequence of the procedure. A broad array of devices for leg lengthening is available to the surgeon. The device selected should be one with which the surgeon is comfortable and familiar, one that will be tolerated by the patient, and one that has the ability to address both the deformity being corrected and the complications that may develop during leg lengthening.

REFERENCES

Leg Length Inequality

- Amputation or limb-lengthening for partial or total absence of the fibula [letter; comment]. *J Bone Joint Surg* 1991;73-A:1272.
- Aaron A, Weinstein D, Thickman D, et al: Comparison of orthoroentgenography and computed tomography in the measurement of limb-length discrepancy. *J Bone Joint Surg* 1992;74-A:897.
- Aaron AD, Eilert RE: Results of the Wagner and Ilizarov methods of limb-lengthening. *J Bone Joint Surg* 1996;78-A:20.
- Abbott LC: The operative lengthening of the tibia and fibula. *J Bone Joint Surg* 1927;9:128.
- Ackman JD, Rouse L, Johnston CE II: Radiation induced physal injury. *Orthopedics* 1988;11:343.
- Aitken AG, Flodmark O, Newman DE, et al: Leg length determination by CT digital radiography. *AJR Am J Roentgenol* 1985;144:613.
- Alberts LR, Pao YC, Lippiello L: A large-deformation, finite-element study of chondrodiastasis in the canine distal femoral epiphyseal plate. *J Biomech* 1993;26:1291.
- Aldegheri R: Femoral callotasis. *J Pediatr Orthop B* 1997;6:42.
- Aldegheri R: Distraction osteogenesis for lengthening of the tibia in patients who have limb-length discrepancy or short stature. *J Bone Joint Surg* 1999;81-A:624.
- Aldegheri R, Renzi-Brivio L, Agostini S: The callotasis method of limb lengthening. *Clin Orthop* 1989;241:137.
- Aldegheri R, Trivella G, Lavini F: Epiphyseal distraction: chondrodiastasis. *Clin Orthop* 1989;241:117.
- Altongy JF, Harcke HT, Bowen JR: Measurement of leg length inequalities by micro-dose digital radiographs. *J Pediatr Orthop* 1987;7:311.
- Anderson M, Green W, Messner M: Growth and predictions of growth in the lower extremities. *J Bone Joint Surg* 1963;45-A:1.
- Anderson M, Messner M, Green W: Distribution of lengths of the normal femur and tibia in children from one to eighteen years of age. *J Bone Joint Surg* 1964;46-A:1197.
- Anderson WV: Leg lengthening. *J Bone Joint Surg* 1952;34-B:150.
- Andrews MW, Amparo EG: Wilms' tumor in a patient with Beckwith-Wiedemann syndrome: onset detected with 3-month serial sonography [corrected and republished article; originally printed in *AJR Am J Roentgenol* 1992;159:835]. *AJR Am J Roentgenol* 1993;160:139.
- Aquerreta JD, Forriol F, Canadell J: Complications of bone lengthening. *Int Orthop* 1994;18:299.
- Armour PC, Scott JH: Equalisation of leg length. *J Bone Joint Surg* 1981;63-B:587.
- Aronson J: Limb-lengthening, skeletal reconstruction, and bone transport with the Ilizarov method. *J Bone Joint Surg* 1997;79-A:1243.
- ASAMI: Operative Principles of Ilizarov: Fracture Treatment—Nonunion Osteomyelitis—Lengthening/Deformity Correction, ed. Bianchi Maiocchi A, Aronson J (eds): Baltimore, Williams & Wilkins, 1991.
- Aston JW Jr, Henley MB: Physal growth arrest of the distal radius treated by the Ilizarov technique: report of a case. *Orthop Rev* 1989;18:813.
- Atar D, Lehman WB, Grant AD, et al: Pediatric update #12. A simplified method for percutaneous epiphysodesis. *Orthop Rev* 1990;19:358.
- Atar D, Lehman WB, Grant AD, et al: Percutaneous epiphysodesis. *J Bone Joint Surg* 1991;73-B:173.
- Atar D, Lehman WB, Grant AD, et al: Treatment of complex limb deformities in children with the Ilizarov technique. *Orthopedics* 1991;14:961.
- Atar D, Lehman WB, Grant AD, et al: The Ilizarov apparatus for treatment of melorheostosis: case report and review of the literature. *Clin Orthop* 1992;281:163.
- Azouz EM, Larson EJ, Patel J, et al: Beckwith-Wiedemann syndrome: development of nephroblastoma during the surveillance period. *Pediatr Radiol* 1990;20:550.
- Ballock RT, Wiesner GL, Myers MT, et al: Hemihypertrophy: concepts and controversies. *J Bone Joint Surg* 1997;79-A:1731.
- Barre PS, Thompson GH, Morrison SC: Late skeletal deformities following meningococcal sepsis and disseminated intravascular coagulation. *J Pediatr Orthop* 1985;5:584.
- Barry K, McManus F, O'Brien T: Leg lengthening by the transiliac method. *J Bone Joint Surg* 1992;74-B:275.
- Bassett GS, Morris JR: The use of the Ilizarov technique in the correction of lower extremity deformities in children. *Orthopedics* 1997;20:623.
- Battiston B, Buffoli P, Vigasio A, et al: The effects of lengthening on nerves. *Ital J Orthop Traumatol* 1992;18:79.
- Baumgart R, Betz A, Schweiberer L: A fully implantable motorized intramedullary nail for limb lengthening and bone transport. *Clin Orthop* 1997;343:135.
- Beals RK: Hemihypertrophy and hemihypotrophy. *Clin Orthop* 1982;166:199.
- Beals RK: Premature closure of the physis following diaphyseal fractures. *J Pediatr Orthop* 1990;10:717.
- Beattie P, Isaacson K, Riddle DL, et al: Validity of derived measurements of leg-length differences obtained by use of a tape measure. *Phys Ther* 1990;70:150.
- Beaudoin L, Zabjek KF, Leroux MA, et al: Acute systematic and variable postural adaptations induced by an orthopaedic shoe lift in control subjects. *Eur Spine J* 1999;8:40.
- Beckwith JB: Macroglossia, omphalocele, adrenal cytomegaly, gigantism, and hyperplastic visceromegaly. *Birth Defects* 1969;5:188.
- Belchier S: An account of the bones of animals being changed to a red color by aliment only. *Phil Trans R Soc* 1736;32:287.
- Bell DF, Boyer MI, Armstrong PF: The use of the Ilizarov technique in the correction of limb deformities associated with skeletal dysplasia. *J Pediatr Orthop* 1992;12:283.
- Belov S: Correction of lower limbs length discrepancy in congenital vascular-bone diseases by vascular surgery performed during childhood. *Semin Vasc Surg* 1993;6:245.
- Beumer A, Lampe HI, Swierstra BA, et al: The straight line graph in limb length inequality: a new design based on 182 Dutch children. *Acta Orthop Scand* 1997;68:355.
- Bhave A, Paley D, Herzenberg JE: Improvement in gait parameters after lengthening for the treatment of limb-length discrepancy. *J Bone Joint Surg* 1999;81-A:529.
- Bianco AJ Jr: Femoral shortening. *Clin Orthop* 1978;136:49.
- Bjerkreim I: Limb lengthening by physal distraction. *Acta Orthop Scand* 1989;60:140.
- Bjerkreim I, Hellum C: Femur lengthening using the Wagner technique. *Acta Orthop Scand* 1983;54:263.
- Blackstone BG, Coleman SS: Treatment of lower limb length inequality. *Surg Annu* 1984;16:259.
- Blair VP III, Schoenecker PL, Sheridan JJ, et al: Closed shortening of the femur. *J Bone Joint Surg* 1989;71-A:1440.
- Blair VP III, Walker SJ, Sheridan JJ, et al: Epiphysodesis: a problem of timing. *J Pediatr Orthop* 1982;2:281.
- Blane CE, Herzenberg JE, Di Pietro MA: Radiographic imaging for Ilizarov limb lengthening in children. *Pediatr Radiol* 1991;21:117.
- Bloedel PK, Hauger B: The effects of limb length discrepancy on subtalar joint kinematics during running. *J Orthop Sports Phys Ther* 1995;22:60.

51. Blount WP: A mature look at epiphyseal stapling. *Clin Orthop* 1971; 77:158.
52. Blount WP, Clark GR: Control of bone growth by epiphyseal stapling: preliminary report. *J Bone Joint Surg* 1949;31-A:464.
53. Bohlman HR: Experiments with foreign materials in the region of the epiphyseal cartilage plate of growing bones to increase their longitudinal growth. *J Bone Joint Surg* 1929;11:365.
54. Bohne WH, Root L: Hypoplasia of the fibula. *Clin Orthop* 1977; 112:107.
55. Bonnard C, Favard L, Sollogoub I, et al: Limb lengthening in children using the Ilizarov method. *Clin Orthop* 1993;293:83.
56. Bost FC, Larsen LJ: Experiences with lengthening of the femur over an intramedullary rod. *J Bone Joint Surg* 1956;38-A:567.
57. Bosworth DM: Skeletal distraction of the tibia. *Surg Gynecol Obstet* 1938;66:912.
58. Bowen JR, Johnson WJ: Percutaneous epiphysiodesis. *Clin Orthop* 1984;190:170.
59. Bowen JR, Leahey JL, Zhang ZH, et al: Partial epiphysiodesis at the knee to correct angular deformity. *Clin Orthop* 1985;198:184.
60. Bowen JR, Levy EJ, Donohue M: Comparison of knee motion and callus formation in femoral lengthening with the Wagner or monolateral-ring device. *J Pediatr Orthop* 1993;13:467.
61. Brand RA, Yack HJ: Effects of leg length discrepancies on the forces at the hip joint. *Clin Orthop* 1996;333:172.
62. Broughton NS, Olney BW, Menelaus MB: Tibial shortening for leg length discrepancy. *J Bone Joint Surg* 1989;71-B:242.
63. Butler MS, Robertson WW Jr, Rate W, et al: Skeletal sequelae of radiation therapy for malignant childhood tumors. *Clin Orthop* 1990;251:235.
64. Bylander B, Aronson S, Egund N, et al: Growth disturbance after physal injury of distal femur and proximal tibia studied by roentgen stereophotogrammetry. *Arch Orthop Trauma Surg* 1981;98:225.
65. Bylander B, Hagglund G, Selvik G: Dynamics of growth retardation after epiphysiodesis: a roentgen stereophotogrammetric analysis. *Orthopedics* 1993;16:710.
66. Bylander B, Hansson LI, Selvik G: Pattern of growth retardation after Blount stapling: a roentgen stereophotogrammetric analysis. *J Pediatr Orthop* 1983;3:63.
67. Bylander B, Selvik G, Hansson LI, et al: A roentgen stereophotogrammetric analysis of growth arrest by stapling. *J Pediatr Orthop* 1981;1:81.
68. Cameron HU: Managing length: the "too long" leg. *Orthopedics* 1997; 20:791.
69. Canadell J: Comparison of distraction epiphysiolysis and partial metaphyseal corticotomy in leg lengthening [letter; comment]. *Int Orthop* 1991;15:273.
70. Canale ST, Christian CA: Techniques for epiphysiodesis about the knee. *Clin Orthop* 1990;255:81.
71. Canale ST, Russell TA, Holcomb RL: Percutaneous epiphysiodesis: experimental study and preliminary clinical results. *J Pediatr Orthop* 1986;6:150.
72. Canuti M, Giorgi B, Valenti C: The Ilizarov apparatus in the treatment of congenital dysmetria of the leg. *Ital J Orthop Traumatol* 1988; 14:483.
73. Carey RP, de Campo JF, Menelaus MB: Measurement of leg length by computerised tomographic scanography: brief report. *J Bone Joint Surg* 1987;69-B:846.
74. Carpenter CT, Lester EL: Skeletal age determination in young children: analysis of three regions of the hand/wrist film. *J Pediatr Orthop* 1993;13:76.
75. Carroll NC, Grant CG, Hudson R, et al: Experimental observations on the effects of leg lengthening by the Wagner method. *Clin Orthop* 1981;160:250.
76. Cauchoix J: One stage femoral lengthening. *Clin Orthop* 1978;136:66.
77. Chandler D, King JD, Bernstein SM, et al: Results of 21 Wagner limb lengthenings in 20 patients. *Clin Orthop* 1988;230:214.
78. Chapman ME, Duwelius PJ, Bray TJ, et al: Closed intramedullary femoral osteotomy: shortening and derotation procedures. *Clin Orthop* 1993;287:245.
79. Cheng JC, Cheung KW, Ng BK: Severe progressive deformities after limb lengthening in type-II fibular hemimelia. *J Bone Joint Surg* 1998;80-B:772.
80. Cheng JC, Lam TP: Femoral lengthening after type IVB septic arthritis of the hip in children. *J Pediatr Orthop* 1996;16:533.
81. Chew DK, Menelaus MB, Richardson MD: Ollier's disease: varus angulation at the lower femur and its management. *J Pediatr Orthop* 1998;18:202.
82. Choi I, Sohn C, Chung C, et al: Optimum ratio of distraction in double level tibial lengthening. *Clin Orthop* 1999;368:240.
83. Choi IH, Kumar SJ, Bowen JR: Amputation or limb-lengthening for partial or total absence of the fibula [see comments]. *J Bone Joint Surg* 1990;72-A:1391.
84. Clericuzio CL, Johnson C: Screening for Wilms tumor in high-risk individuals. *Hematol Oncol Clin North Am* 1995;9:1253.
85. Cleveland RH, Kushner DC, Ogden MC, et al: Determination of leg length discrepancy: a comparison of weight-bearing and supine imaging. *Invest Radiol* 1988;23:301.
86. Codivilla A: On the means of lengthening in the lower limbs, the muscles and the tissues which are shortened through deformity. *Am J Orthop Surg* 1905;2:353.
87. Coleman SS: Simultaneous femoral and tibial lengthening for limb length discrepancies. *Arch Orthop Trauma Surg* 1985;103:359.
88. Coleman SS: Equalization of lower-limb inequality by lengthening. *Instr Course Lect* 1989;38:317.
89. Coleman SS, Noonan TD: Anderson's method of tibial-lengthening by percutaneous osteotomy and gradual distraction: experience with thirty-one cases. *J Bone Joint Surg* 1967;49-A:263.
90. Compere EL: Indications for and against the leg lengthening operation: use of the tibial bone graft as a factor in preventing delayed union, nonunion, or late fracture. *J Bone Joint Surg* 1936;18:692.
91. Connolly JF, Huurman WW, Lippiello L, et al: Epiphyseal traction to correct acquired growth deformities: an animal and clinical investigation. *Clin Orthop* 1986;202:258.
92. Coppola C, Maffulli N: Limb shortening for the management of leg length discrepancy. *J R Coll Surg Edinb* 1999;44:46.
93. Corry IS, Nicol RO: Limb length after fracture of the femoral shaft in children. *J Pediatr Orthop* 1995;15:217.
94. Craft AW, Parker L, Stiller C, et al: Screening for Wilms' tumour in patients with aniridia, Beckwith syndrome, or hemihypertrophy. *Med Pediatr Oncol* 1995;24:231.
95. Cummings G, Scholz JP, Barnes K: The effect of imposed leg length difference on pelvic bone symmetry. *Spine* 1993;18:368.
96. Cundy P, Paterson D, Morris L, et al: Skeletal age estimation in leg length discrepancy. *J Pediatr Orthop* 1988;8:513.
97. Curran AR, Kuo KN, Lubicky JP: Simultaneous ipsilateral femoral and tibial lengthening with the Ilizarov method. *J Pediatr Orthop* 1999;19:386.
98. D'Angelo G, Petas N, Donzelli O: Lengthening of the lower limbs in Ollier's disease: problems related to surgery. *Chir Organi Mov* 1996;81:279.
99. Daentl DL, Smith DW, Scott CI, et al: Femoral hypoplasia—unusual facies syndrome. *J Pediatr* 1975;86:107.
100. Dahl MT, Fischer DA: Lower extremity lengthening by Wagner's method and by callus distraction. *Orthop Clin North Am* 1991;22:643.
101. Dahl MT, Gulli B, Berg T: Complications of limb lengthening: a learning curve. *Clin Orthop* 1994;301:10.
102. Danielsson LG: Spontaneous premature closure of the tibial tubercle: report on 2 boys with a new disorder? *Acta Orthop Scand* 1997;68:177.
103. Danziger MB, Kumar A, De Weese J: Fractures after femoral lengthening using the Ilizarov method. *J Pediatr Orthop* 1995;15:220.
104. Day CS, Moreland M, Floyd SS Jr, et al: Limb lengthening promotes muscle growth. *J Orthop Res* 1997;15:227.
105. De Bastiani G, Aldegheri R, Renzi-Brivio L, et al: Chondrodystasia-controlled symmetrical distraction of the epiphyseal plate: limb lengthening in children. *J Bone Joint Surg* 1986;68-B:550.
106. De Bastiani G, Aldegheri R, Renzi-Brivio L, et al: Limb lengthening by distraction of the epiphyseal plate: a comparison of two techniques in the rabbit. *J Bone Joint Surg* 1986;68-B:545.
107. De Bastiani G, Aldegheri R, Renzi-Brivio L, et al: Limb lengthening by callus distraction (callotaxis). *J Pediatr Orthop* 1987;7:129.
108. De Deyne PG, Hayatsu K, Meyer R, et al: Muscle regeneration and fiber-type transformation during distraction osteogenesis. *J Orthop Res* 1999;17:560.
109. Dewaele J, Fabry G: The timing of epiphysiodesis: a comparative study between the use of the method of Anderson and Green and the Moseley chart. *Acta Orthop Belg* 1992;58:43.
110. Diachkova GH: Radiopaque muscle studies in patients treated with the Ilizarov method. *Bull Hosp Jt Dis* 1995;54:85.
111. Digby KH: The measurement of diaphyseal growth in proximal and distal direction. *J Anat Physiol* 1915;50:187.

112. D'Souza H, Shah NM: Circumferential periosteal sleeve resection: results in limb-length discrepancy secondary to poliomyelitis. *J Pediatr Orthop* 1999;19:215.
113. Duhamel HL: Sur le developpement et la crue des os des animaux. *Mem Acad R Sci* 1742:354.
114. Dutkowsky JP, Kasser JR, Kaplan LC: Leg length discrepancy associated with vivid cutis marmorata [see comments]. *J Pediatr Orthop* 1993;13:456.
115. Eastwood DM, Cole WG: A graphic method for timing the correction of leg-length discrepancy. *J Bone Joint Surg* 1995;77-B:743.
116. Edwards KJ, Cummings RJ: Fat embolism as a complication of closed femoral shortening. *J Pediatr Orthop* 1992;12:542.
117. Eldridge JC, Bell DF: Problems with substantial limb lengthening. *Orthop Clin North Am* 1991;22:625.
118. Elliott M, Bayly R, Cole T, et al: Clinical features and natural history of Beckwith-Wiedemann syndrome: presentation of 74 new cases [see comments]. *Clin Genet* 1994;46:168.
119. Elliott M, Maher ER: Beckwith-Wiedemann syndrome. *J Med Genet* 1994;31:560.
120. Ensley NJ, Green NE, Barnes WP: Femoral lengthening with the Barnes device. *J Pediatr Orthop* 1993;13:57.
121. Epps CH Jr, Schneider PL: Treatment of hemimelia of the lower extremity: long-term results. *J Bone Joint Surg* 1989;71-A:273.
122. Eyres KS, Douglas DL, Bell MJ: Closed intramedullary osteotomy for the correction of deformities of the femur. *J R Coll Surg Edinb* 1993;38:302.
123. Faber FW, Keessen W, van Roermund PM: Complications of leg lengthening: 46 procedures in 28 patients. *Acta Orthop Scand* 1991;62:327.
124. Farrar MJ, Bennet GC, Wilson NI, et al: The orthopaedic implications of peripheral limb ischaemia in infants and children. *J Bone Joint Surg* 1996;78-B:930.
125. Faure C, Merloz P: Transfixation (JE Robb, trans). Berlin, Springer-Verlag, 1987.
126. Ferron JL: Personal communication. Institute St. Pierre, Palavas Les Flots, France.
127. Fink B, Krieger M, Strauss JM, et al: Osteoneogenesis and its influencing factors during treatment with the Ilizarov method. *Clin Orthop* 1996;323:261.
128. Fischgrund J, Paley D, Suter C: Variables affecting time to bone healing during limb lengthening. *Clin Orthop* 1994;301:31.
129. Fishbane BM, Riley LH: Continuous transphyseal traction: experimental observations. *Clin Orthop* 1978;136:120.
130. Fjeld TO, Steen H: Limb lengthening by low rate epiphyseal distraction: an experimental study in the caprine tibia. *J Orthop Res* 1988;6:360.
131. Fjeld TO, Steen H: Limb lengthening by epiphyseal distraction in chondrodystrophic bone: an experimental study in the canine femur. *J Orthop Res* 1989;7:184.
132. Flourens P: Theorie experimentale de la formation des os. Paris, Balliere, 1847.
133. Fontanesi G, Giancetti F, Rotini R: Segmental shortening and equalization for leg length discrepancies in adults. *Ital J Orthop Traumatol* 1987;13:45.
134. Franke J, Hein G, Simon M, et al: Comparison of distraction epiphyseolysis and partial metaphyseal corticotomy in leg lengthening [see comments]. *Int Orthop* 1990;14:405.
135. Frantz CH: Epiphyseal stapling: a comprehensive review. *Clin Orthop* 1971;77:149.
136. Fraumeni JF Jr, Geiser CF, Manning MD: Wilms' tumor and congenital hemihypertrophy: report of five new cases and review of literature. *Pediatrics* 1967;40:886.
137. Friberg O: Leg length asymmetry in stress fractures: a clinical and radiological study. *J Sports Med Phys Fitness* 1982;22:485.
138. Friberg O: Clinical symptoms and biomechanics of lumbar spine and hip joint in leg length inequality. *Spine* 1983;8:643.
139. Friberg O: Leg length inequality and low back pain [letter]. *Lancet* 1984;2:1039.
140. Friberg O: Results of radiologic measurements of leg-length inequality (LLI) [letter; comment]. *Spine* 1992;17:458.
141. Friberg O, Koivisto E, Wegelius C: A radiographic method for measurement of leg length inequality. *Diagn Imaging Clin Med* 1985;54:78.
142. Friberg O, Kvist M: Factors determining the preference of takeoff leg in jumping. *Int J Sports Med* 1988;9:349.
143. Friberg O, Nurminen M, Korhonen K, et al: Accuracy and precision of clinical estimation of leg length inequality and lumbar scoliosis: comparison of clinical and radiological measurements. *Int Disabil Stud* 1988;10:49.
144. Froh R, Yong-Hing K, Cassidy JD, et al: The relationship between leg length discrepancy and lumbar facet orientation. *Spine* 1988;13:325.
145. Fullilove S, Fixsen J: Major limb deformities as complications of vascular access in neonates. *Paediatr Anaesth* 1997;7:247.
146. Furukawa T, Shinohara T: Congenital hemihypertrophy: oncogenic potential of the hypertrophic side. *Ann Neurol* 1981;10:199.
147. Gabriel KR, Crawford AH, Roy DR, et al: Percutaneous epiphyseodesis. *J Pediatr Orthop* 1994;14:358.
148. Galardi G, Comi G, Lozza L, et al: Peripheral nerve damage during limb lengthening: neurophysiology in five cases of bilateral tibial lengthening. *J Bone Joint Surg* 1990;72-B:121.
149. Ganel A, Blankstein A: Subluxation and dislocation of hip joint in femoral elongation. *Orthop Rev* 1987;16:341.
150. Ganel A, Horoszowski H, Kamhin M, et al: Leg lengthening in achondroplastic children. *Clin Orthop* 1979;144:194.
151. Garcia-Cimbrelo E, Olsen B, Ruiz-Yague M, et al: Ilizarov technique: results and difficulties. *Clin Orthop* 1992;283:116.
152. Gasser B, Boman B, Wyder D, et al: Stiffness characteristics of the circular Ilizarov device as opposed to conventional external fixators. *J Biomech Eng* 1990;112:15.
153. Gelbke H: Influence of pressure and tension on growing bone in experiments with animals. *J Bone Joint Surg* 1951;33-A:947.
154. Ghoneem HF, Wright JG, Cole WG, et al: The Ilizarov method for correction of complex deformities: psychological and functional outcomes. *J Bone Joint Surg* 1996;78-A:1480.
155. Gibbons PJ, Bradish CF: Fibular hemimelia: a preliminary report on management of the severe abnormality. *J Pediatr Orthop B* 1996;5:20.
156. Gibson PH, Papaioannou T, Kenwright J: The influence on the spine of leg-length discrepancy after femoral fracture. *J Bone Joint Surg* 1983;65-B:584.
157. Gil-Albarova J, Melgosa M, Gil-Albarova O, et al: Soft tissue behavior during limb lengthening: an experimental study in lambs. *J Pediatr Orthop B* 1997;6:266.
158. Giles LG: Lumbosacral facet "joint angles" associated with leg length inequality. *Rheumatol Rehabil* 1981;20:233.
159. Giles LG, Taylor JR: Low-back pain associated with leg length inequality. *Spine* 1981;6:510.
160. Giles LG, Taylor JR: Lumbar spine structural changes associated with leg length inequality. *Spine* 1982;7:159.
161. Giles LG, Taylor JR: The effect of postural scoliosis on lumbar apophyseal joints. *Scand J Rheumatol* 1984;13:209.
162. Glass RB, Poznanski AK: Leg-length determination with biplanar CT scanograms. *Radiology* 1985;156:833.
163. Glorion C, Pouliquen JC, Langlais J, et al: Femoral lengthening using the callotasis method: study of the complications in a series of 70 cases in children and adolescents. *J Pediatr Orthop* 1996;16:161.
164. Goel A, Loudon J, Nazare A, et al: Joint moments in minor limb length discrepancy: a pilot study. *Am J Orthop* 1997;26:852.
165. Gofton JP: Persistent low back pain and leg length disparity. *J Rheumatol* 1985;12:747.
166. Golyakhovsky V: Gavriel A. Ilizarov: "The magician from Kurgan." 1988 Classical Article. *Bull Hosp Jt Dis* 1997;56:54.
167. Gonzalez-Herranz P, Burgos-Flores J, Ocete-Guzman JG, et al: The management of limb-length discrepancies in children after treatment of osteosarcoma and Ewing's sarcoma. *J Pediatr Orthop* 1995;15:561.
168. Green DM, Breslow NE, Beckwith JB, et al: Screening of children with hemihypertrophy, aniridia, and Beckwith-Wiedemann syndrome in patients with Wilms tumor: a report from the National Wilms Tumor Study. *Med Pediatr Oncol* 1993;21:188.
169. Green WT, Anderson M: Experiences with epiphyseal arrest in correcting discrepancies in length of the lower extremities in infantile paralysis. *J Bone Joint Surg* 1947;29:659.
170. Green WT, Anderson M: Epiphyseal arrest for correction of discrepancies in length of the lower extremities. *J Bone Joint Surg* 1957;39-A:853.
171. Green WT, Anderson M: Skeletal Age and the Control of Bone Growth vol 17, p 199. Rosemont, IL, American Academy of Orthopaedic Surgeons, 1960.
172. Green WT, Wyatt GM, Anderson M: Orthroentgenography as a method of measuring the bones of the lower extremity. *J Bone Joint Surg* 1946;28:60.
173. Greiff J, Bergmann F: Growth disturbance following fracture of the tibia in children. *Acta Orthop Scand* 1980;51:315.

174. Greulich WW, Pyle SI: Radiographic Atlas of Skeletal Development of the Hand and Wrist. Stanford, CA, Stanford University Press, 1959.
175. Griffet J, el Hayek T, Giboin P: Melorheostosis: complications of a tibial lengthening with the Ilizarov apparatus. *Eur J Pediatr Surg* 1998;8:186.
176. Grill F: Correction of complicated extremity deformities by external fixation. *Clin Orthop* 1989;241:166.
177. Grimes J, Carpenter C, Reinker K: Toxic shock syndrome as a complication of orthopaedic surgery. *J Pediatr Orthop* 1995;15:666.
178. Gross MT, Burns CB, Chapman SW, et al: Reliability and validity of rigid lift and pelvic leveling device method in assessing functional leg length inequality. *J Orthop Sports Phys Ther* 1998;27:285.
179. Gross RH: Leg length discrepancy in marathon runners. *Am J Sports Med* 1983;11:121.
180. Grundy PF, Roberts CJ: Does unequal leg length cause back pain? A case-control study. *Lancet* 1984;2:256.
181. Guarniero R, Barros Junior TE: Femoral lengthening by the Wagner method. *Clin Orthop* 1990;250:154.
182. Guichet JM, Casar RS: Mechanical characterization of a totally intramedullary gradual elongation nail. *Clin Orthop* 1997;337:281.
183. Guichet JM, Spivak JM, Trouilloud P, et al: Lower limb-length discrepancy: an epidemiologic study. *Clin Orthop* 1991;272:235.
184. Guidera KJ, Helal AA, Zuern KA: Management of pediatric limb length inequality. *Adv Pediatr* 1995;42:501.
185. Guidera KJ, Hess WF, Highhouse KP, et al: Extremity lengthening: results and complications with the Orthofix system. *J Pediatr Orthop* 1991;11:90.
186. Haas SL: Retardation of bone growth by a wire loop. *J Bone Joint Surg* 1945;27:25.
187. Haas SL: Mechanical retardation of bone growth. *J Bone Joint Surg* 1948;30-A:506.
188. Haas SL: Restriction of bone growth by pins through the epiphyseal cartilaginous plate. *J Bone Joint Surg* 1950;32-A:338.
189. Haddad FS, Hill RA: Leg lengthening in spinal dysraphism. *J Pediatr Orthop* 1999;19:391.
190. Haicken BN, Schulman NH, Schneider KM: Adrenocortical carcinoma and congenital hemihypertrophy. *J Pediatr* 1973;83:284.
191. Hales S: Statistical essays: containing vegetable statics or, an account of some statistical experiments on the sap in vegetables. Vol 1. London, Woodward & Peele, 1731.
192. Hamanishi C, Tanaka S, Tamura K: Early physeal closure after femoral chondrodiastasis: loss of length gain in 5 cases. *Acta Orthop Scand* 1992;63:146.
193. Hamanishi C, Yasuwaki Y, Kikuchi H, et al: Classification of the callus in limb lengthening: radiographic study of 35 limbs. *Acta Orthop Scand* 1992;63:430.
194. Hamanishi C, Yoshii T, Totani Y, et al: Lengthened callus activated by axial shortening: histological and cytomorphometrical analysis. *Clin Orthop* 1994;307:250.
195. Harris RE, Fuchs EF, Kaempf MJ: Medullary sponge kidney and congenital hemihypertrophy: case report and literature review. *J Urol* 1981;126:676.
196. Hatzis JA, Stratigos AJ, Dimopoulos JC, et al: Linear scleroderma with severe leg deformity. *Australas J Dermatol* 1992;33:155.
197. Hauspie R, Bielicki T, Koniarek J: Skeletal maturity at onset of the adolescent growth spurt and at peak velocity for growth in height: a threshold effect? *Ann Hum Biol* 1991;18:23.
198. Heim M, Horoszowski H, Martinowitz U: Leg-length inequality in hemophilia: an interesting case report. *Clin Pediatr (Phila)* 1985;24:600.
199. Helling AL: Leg length inequality: a prospective study of young men during their military service. *Ups J Med Sci* 1988;93:245.
200. Helms CA, McCarthy S: CT scanograms for measuring leg length discrepancy. *Radiology* 1984;151:802.
201. Hennessy WT, Cromie WJ, Duckett JW: Congenital hemihypertrophy and associated abdominal lesions. *Urology* 1981;18:576.
202. Hermanussen M, Geiger-Benoit K, Burmeister J: Analysis of differential growth of the right and the left leg. *Hum Biol* 1989;61:133.
203. Hernandez JA, Serrano S, Marinosa ML, et al: Bone growth and modeling changes induced by periosteal stripping in the rat. *Clin Orthop* 1995;320:211.
204. Herron LD, Amstutz HC, Sakai DN: One stage femoral lengthening in the adult. *Clin Orthop* 1978;136:74.
205. Herzenberg JE, Paley D: Leg lengthening in children. *Curr Opin Pediatr* 1998;10:95.
206. Herzenberg JE, Scheufele LL, Paley D, et al: Knee range of motion in isolated femoral lengthening. *Clin Orthop* 1994;301:49.
207. Hill RA, Tucker SK: Leg lengthening and bone transport in children. *Br J Hosp Med* 1997;57:399.
208. Hofmann A, Wenger DR: Posteromedial bowing of the tibia: progression of discrepancy in leg lengths. *J Bone Joint Surg* 1981;63-A:384.
209. Hoikka V, Ylikoski M, Tallroth K: Leg-length inequality has poor correlation with lumbar scoliosis: a radiological study of 100 patients with chronic low-back pain. *Arch Orthop Trauma Surg* 1989;108:173.
210. Holm I, Nordsletten L, Steen H, et al: Muscle function after mid-shaft femoral shortening: a prospective study with a two-year follow-up. *J Bone Joint Surg* 1994;76-B:143.
211. Hood RW, Riseborough EJ: Lengthening of the lower extremity by the Wagner method: a review of the Boston Children's Hospital Experience. *J Bone Joint Surg* 1981;63-A:1122.
212. Hope PG, Crawford EJ, Catterall A: Bone growth following lengthening for congenital shortening of the lower limb. *J Pediatr Orthop* 1994;14:339.
213. Horsfield D, Jones SN: Assessment of inequality in length of the lower limb. *Radiography* 1986;52:223.
214. Horton GA, Olney BW: Epiphysodesis of the lower extremity: results of the percutaneous technique. *J Pediatr Orthop* 1996;16:180.
215. Hougaard K: Femoral shaft fractures in children: a prospective study of the overgrowth phenomenon. *Injury* 1989;20:170.
216. Howorth MB: Slipping of the upper femoral epiphysis. *J Bone Joint Surg* 1949;31-A:734.
217. Hrutkay JM, Eilert RE: Operative lengthening of the lower extremity and associated psychological aspects: the Children's Hospital experience. *J Pediatr Orthop* 1990;10:373.
218. Huang SC: Leg lengthening by the Ilizarov technique for patients with sequelae of poliomyelitis. *J Formos Med Assoc* 1997;96:258.
219. Huang SC, Chang CW: Electrophysiologic evaluation of neuromuscular functions during limb lengthening by callus distraction. *J Formos Med Assoc* 1997;96:172.
220. Hueter C: Anatomische studien an den exträmitatengelenken neugeborener und erwachsener. *Virchows Arch* 1862;25:575.
221. Hulsbergen-Kruger S, Preisser P, Partecke BD: Ilizarov distraction-lengthening in congenital anomalies of the upper limb. *J Hand Surg* 1998;23-B:192.
222. Hunter J: Experiments and observations on the growth of bones, from papers of the late Mr. Hunter. In Palmer JF (ed): *The Works of John Hunter with Notes*, vol IV, p 315. London, Longman Rees, Orme, Brown, Green and Longman, 1835.
223. Huurman WW, Jacobsen FS, Anderson JC, et al: Limb-length discrepancy measured with computerized axial tomographic equipment. *J Bone Joint Surg* 1987;69-A:699.
224. Ilizarov GA: The tension-stress effect on the genesis and growth of tissues. Part I. The influence of stability of fixation and soft-tissue preservation. *Clin Orthop* 1989;238:249.
225. Ilizarov GA: The tension-stress effect on the genesis and growth of tissues. Part II. The influence of the rate and frequency of distraction. *Clin Orthop* 1989;239:263.
226. Ilizarov GA: Clinical application of the tension-stress effect for limb lengthening. *Clin Orthop* 1990;250:8.
227. Ilizarov GA: *Transosseous Osteosynthesis*. Berlin, Springer-Verlag, 1992.
228. Ippolito E, Peretti G, Bellocchi M, et al: Histology and ultrastructure of arteries, veins, and peripheral nerves during limb lengthening. *Clin Orthop* 1994;308:54.
229. Ireland J, Kessel L: Hip adduction/abduction deformity and apparent leg-length inequality. *Clin Orthop* 1980;153:156.
230. Johansson JE, Barrington TW: Femoral shortening by a step-cut osteotomy for leg-length discrepancy in adults. *Clin Orthop* 1983;181:132.
231. Johnson EE: Acute lengthening of shortened lower extremities after malunion or non-union of a fracture. *J Bone Joint Surg* 1994;76-A:379.
232. Johnston CE II, Bueche MJ, Williamson B, et al: Epiphysodesis for management of lower limb deformities. *Instr Course Lect* 1992;41:437.
233. Jones CB, Dewar ME, Aichroth PM, et al: Epiphysal distraction monitored by strain gauges: results in seven children. *J Bone Joint Surg* 1989;71-B:651.
234. Jones DC, Moseley CF: Subluxation of the knee as a complication of femoral lengthening by the Wagner technique. *J Bone Joint Surg* 1985;67-B:33.
235. Jones KL: The etiology and diagnosis of overgrowth syndromes. *Growth Genet Horm* 1994;10:6.

236. Junk S, Terjesen T, Rossvoll I, et al: Leg length inequality measured by ultrasound and clinical methods. *Eur J Radiol* 1992;14:185.
237. Kaljumae U, Martson A, Haviko T, et al: The effect of lengthening of the femur on the extensors of the knee: an electromyographic study. *J Bone Joint Surg* 1995;77-A:247.
238. Karger C, Guille JT, Bowen JR: Lengthening of congenital lower limb deficiencies. *Clin Orthop* 1993;291:236.
239. Kasser JR, Jenkins R: Accuracy of leg length prediction in children younger than 10 years of age. *Clin Orthop* 1997;338:9.
240. Kaufman KR, Miller LS, Sutherland DH: Gait asymmetry in patients with limb-length inequality. *J Pediatr Orthop* 1996;16:144.
241. Kawamura B, Hosono S, Takahashi T, et al: Limb lengthening by means of subcutaneous osteotomy: experimental and clinical studies. *J Bone Joint Surg* 1968;50-A:851.
242. Kempf I, Grosse A, Abalo C: Locked intramedullary nailing: its application to femoral and tibial axial, rotational, lengthening, and shortening osteotomies. *Clin Orthop* 1986;212:165.
243. Kenwright J, Albinana J: Problems encountered in leg shortening. *J Bone Joint Surg* 1991;73-B:671.
244. Kenwright J, Spriggins AJ, Cunningham JL: Response of the growth plate to distraction close to skeletal maturity: is fracture necessary? *Clin Orthop* 1990;250:61.
245. Klenerman L: Unequal legs [editorial]. *BMJ (Clin Res Ed)* 1983;286:1302.
246. Kogutt MS: Computed radiographic imaging: use in low-dose leg length radiography. *AJR Am J Roentgenol* 1987;148:1205.
247. Kohan L, Cumming WJ: Femoral shaft fractures in children: the effect of initial shortening on subsequent limb overgrowth. *Aust NZ J Surg* 1982;52:141.
248. Kojimoto H, Yasui N, Goto T, et al: Bone lengthening in rabbits by callus distraction: the role of periosteum and endosteum. *J Bone Joint Surg* 1988;70-B:543.
249. Korzinek K, Tepic S, Perren SM: Limb lengthening and three-dimensional deformity corrections: a retrospective clinical study. *Arch Orthop Trauma Surg* 1990;109:334.
250. Koufos A, Grundy P, Morgan K, et al: Familial Wiedemann-Beckwith syndrome and a second Wilms tumor locus both map to 11p15.5. *Am J Hum Genet* 1989;44:711.
251. Kristiansen LP, Steen H: Lengthening of the tibia over an intramedullary nail, using the Ilizarov external fixator: major complications and slow consolidation in 9 lengthenings. *Acta Orthop Scand* 1999;70:271.
252. Kujala UM, Friberg O, Aalto T, et al: Lower limb asymmetry and patellofemoral joint incongruence in the etiology of knee exertion injuries in athletes. *Int J Sports Med* 1987;8:214.
253. Kujala UM, Kvist M, Osterman K, et al: Factors predisposing army conscripts to knee exertion injuries incurred in a physical training program. *Clin Orthop* 1986;210:203.
254. Küntscher G: Practice of Intramedullary Nailing. Springfield, IL, Charles C Thomas, 1967.
255. Lampe HI, Swierstra BA, Diepstraten AF: Timing of epiphysodesis in limb length inequality: the straight line graph applied in 30 patients. *Acta Orthop Scand* 1992;63:672.
256. Lampe HI, Swierstra BA, Diepstraten AF: Measurement of limb length inequality: comparison of clinical methods with orthoradiography in 190 children. *Acta Orthop Scand* 1996;67:242.
257. Lavini F, Renzi-Brivio L, de Bastiani G: Psychologic, vascular, and physiologic aspects of lower limb lengthening in achondroplastics. *Clin Orthop* 1990;250:138.
258. Lee DY, Choi IH, Chung CY, et al: Effect of tibial lengthening on the gastrocnemius muscle: a histopathologic and morphometric study in rabbits. *Acta Orthop Scand* 1993;64:688.
259. Lee DY, Choi IH, Chung CY, et al: A modified Wagner technique for femoral lengthening in skeletally mature patients with poliomyelitis. *Int Orthop* 1993;17:154.
260. Lee DY, Han TR, Choi IH, et al: Changes in somatosensory-evoked potentials in limb lengthening: an experimental study on rabbits' tibiae. *Clin Orthop* 1992;285:273.
261. Lee WH, Huang SC: Femoral lengthening: callotaxis with Ilizarov external fixator alone and with intramedullary locking nail. *J Formos Med Assoc* 1997;96:98.
262. Leitch JM, Paterson DC, Foster BK: Growth disturbance in Legg-Calvé-Perthes disease and the consequences of surgical treatment. *Clin Orthop* 1991;262:178.
263. Leppilahti J, Korpelainen R, Karpakka J, et al: Ruptures of the Achilles tendon: relationship to inequality in length of legs and to patterns in the foot and ankle. *Foot Ankle Int* 1998;19:683.
264. Letts RM, Meadows L: Epiphysiolysis as a method of limb lengthening. *Clin Orthop* 1978;133:230.
265. Li G, Simpson AH, Kenwright J, et al: Assessment of cell proliferation in regenerating bone during distraction osteogenesis at different distraction rates. *J Orthop Res* 1997;15:765.
266. Lin CC, Huang SC, Liu TK, et al: Limb lengthening over an intramedullary nail: an animal study and clinical report. *Clin Orthop* 1996;330:208.
267. Liotta FJ, Ambrose TA II, Eilert RE: Fluoroscopic technique versus Phemister technique for epiphysodesis. *J Pediatr Orthop* 1992;12:248.
268. Little DG, Aiona MD: Limb length discrepancy in congenital talipes equinovarus. *Aust NZ J Surg* 1995;65:409.
269. Little DG, Nigo L, Aiona MD: Deficiencies of current methods for the timing of epiphysodesis. *J Pediatr Orthop* 1996;16:173.
270. Liu XC, Fabry G, Molenaers G, et al: Kinematic and kinetic asymmetry in patients with leg-length discrepancy. *J Pediatr Orthop* 1998;18:187.
271. Lokietek W, Legaye J, Lokietek JC: Contributing factors for osteogenesis in children's limb lengthening. *J Pediatr Orthop* 1991;11:452.
272. Luke DL, Schoenecker PL, Blair VP III, et al: Fractures after Wagner limb lengthening. *J Pediatr Orthop* 1992;12:20.
273. Macnicol MF, Gupta MS: Epiphysodesis using a cannulated tubesaw. *J Bone Joint Surg* 1997;79-B:307.
274. Maffulli N, Cheng JC, Sher A, et al: Bone mineralization at the callotaxis site after completion of lengthening. *Bone* 1999;25:333.
275. Maffulli N, Fixsen JA: Muscular strength after callotaxis limb lengthening. *J Pediatr Orthop* 1995;15:212.
276. Maffulli N, Lombardi C, Matarazzo L, et al: A review of 240 patients undergoing distraction osteogenesis for congenital post-traumatic or postinfective lower limb length discrepancy. *J Am Coll Surg* 1996;182:394.
277. Mahar RK, Kirby RL, MacLeod DA: Simulated leg-length discrepancy: its effect on mean center-of-pressure position and postural sway. *Arch Phys Med Rehabil* 1985;66:822.
278. Makarov MR, Birch JG, Delgado MR, et al: Effects of external fixation and limb lengthening on peripheral nerve function. *Clin Orthop* 1996;329:310.
279. Makarov MR, Delgado MR, Birch JG, et al: Intraoperative SSEP monitoring during external fixation procedures in the lower extremities. *J Pediatr Orthop* 1996;16:155.
280. Makarov MR, Delgado MR, Birch JG, et al: Monitoring peripheral nerve function during external fixation of upper extremities. *J Pediatr Orthop* 1997;17:663.
281. Makarov MR, Delgado MR, Samchukov ML, et al: Somatosensory evoked potential evaluation of acute nerve injury associated with external fixation procedures. *Clin Orthop* 1994;308:254.
282. Malhis TM, Bowen JR: Tibial and femoral lengthening: a report of 54 cases. *J Pediatr Orthop* 1982;2:487.
283. Marshall PD, Saleh M, Douglas DL: Risk of deep infection with intramedullary nailing following the use of external fixators [see comments]. *J R Coll Surg Edinb* 1991;36:268.
284. Mastragostino S, Bagliani GP, Boero S, et al: The modified Wagner method for surgical lengthening of the limbs. *Ital J Orthop Traumatol* 1989;15:133.
285. Matano T, Tamai K, Kurokawa T: Adaptation of skeletal muscle in limb lengthening: a light diffraction study on the sarcomere length in situ. *J Orthop Res* 1994;12:193.
286. May VR, Clements EL: Epiphysal stapling with special reference to complications. *Southern Med J* 1956;58:1203.
287. McCaw ST: Leg length inequality: implications for running injury prevention. *Sports Med* 1992;14:422.
288. McCaw ST, Bates BT: Biomechanical implications of mild leg length inequality [published erratum appears in *Br J Sports Med* 1991;25:190]. *Br J Sports Med* 1991;25:10.
289. McKee MD, Yoo D, Schemitsch EH: Health status after Ilizarov reconstruction of post-traumatic lower-limb deformity. *J Bone Joint Surg* 1998;80-B:360.
290. Menelaus M: The Anstey Giles lecture: opening and closing the growth plate. *Aust NZ J Surg* 1981;51:518.
291. Menelaus MB: Correction of leg length discrepancy by epiphysal arrest. *J Bone Joint Surg* 1966;48-B:336.
292. Merle D'Aubigné R, Dubouset J: [Correction of severe disparity of the lower extremities with or without simultaneous correction of

- lateral deviations]. *Rev Chir Orthop Reparatrice Appar Mot* 1968; 54:593.
293. Merle d'Aubigné R, Dubouset J: Surgical correction of large length discrepancies in the lower extremities of children and adults: an analysis of twenty consecutive cases. *J Bone Joint Surg* 1971;53-A:411.
 294. Merle d'Aubigné R, Vaillant JM: A propos du traitement des inégalités de longueur des membres inférieurs: technique d'égalisation du femur en un temps. *Rev Chir Orthop* 1965;51:189.
 295. Métaizeau JP, Wong-Chung J, Bertrand H, et al: Percutaneous epiphysiodesis using transphyseal screws (PETS). *J Pediatr Orthop* 1998; 18:363.
 296. Mileski RA, Garvin KL, Huurman WW: Avascular necrosis of the femoral head after closed intramedullary shortening in an adolescent. *J Pediatr Orthop* 1995;15:24.
 297. Miller A, Rosman MA: Hypertensive encephalopathy as a complication of femoral lengthening. *Can Med Assoc J* 1981;124:296.
 298. Miller LS, Bell DF: Management of congenital fibular deficiency by Ilizarov technique. *J Pediatr Orthop* 1992;12:651.
 299. Miller RW, Fraumeni JF, Manning MD: Association of Wilms's tumor with aniridia, hemihypertrophy and other congenital malformations. *N Engl J Med* 1964;270:922.
 300. Millis MB, Hall JE: Transiliac lengthening of the lower extremity: a modified innominate osteotomy for the treatment of postural imbalance. *J Bone Joint Surg* 1979;61-A:1182.
 301. Minty I, Maffulli N, Fixsen JA: Septicemia in a child undergoing callotasis limb lengthening. *Bull Hosp Jt Dis* 1993;53:7.
 302. Mirovsky Y, Axer A, Hendel D: Residual shortening after osteotomy for Perthes' disease: a comparative study. *J Bone Joint Surg* 1984; 66-B:184.
 303. Mizumoto Y, Mizuta H, Nakamura E, et al: Distraction frequency and the gastrocnemius muscle in tibial lengthening: studies in rabbits. *Acta Orthop Scand* 1996;67:562.
 304. Montgomery RJ: Severe progressive deformities after limb lengthening in type-II fibular hemimelia [letter]. *J Bone Joint Surg* 1999;81-B:178.
 305. Monticelli G, Spinelli R: Distraction epiphysiolysis as a method of limb lengthening. I. Experimental study. *Clin Orthop* 1981;154:254.
 306. Monticelli G, Spinelli R: Distraction epiphysiolysis as a method of limb lengthening. III. Clinical applications. *Clin Orthop* 1981;154:274.
 307. Monticelli G, Spinelli R: Limb lengthening by epiphyseal distraction. *Int Orthop* 1981;5:85.
 308. Moore R: Conservative management of adolescent slipped capital femoral epiphysis. *Surg Gynecol Obstet* 1945;80:324.
 309. Morgan DL: New insights into the behavior of muscle during active lengthening [see comments]. *Biophys J* 1990;57:209.
 310. Moseley C: Leg length discrepancy and angular deformity of the lower limbs. In Morrissey RT, Weinstein SL (eds): *Lovell and Winter's Pediatric Orthopaedics*, 4th edition, p 849. Philadelphia, Lippincott-Raven Publishers, 1996.
 311. Moseley CF: A straight-line graph for leg-length discrepancies. *J Bone Joint Surg* 1977;59-A:174.
 312. Moseley CF: A straight line graph for leg length discrepancies. *Clin Orthop* 1978;136:33.
 313. Moseley CF: Leg-length discrepancy. *Pediatr Clin North Am* 1986; 33:1385.
 314. Moseley CF: Leg length discrepancy. *Orthop Clin North Am* 1987; 18:529.
 315. Moseley CF: Assessment and prediction in leg-length discrepancy. *Instr Course Lect* 1989;38:325.
 316. Mosheiff R, Cordey J, Rahn BA, et al: The vascular supply to bone in distraction osteogenesis: an experimental study. *J Bone Joint Surg* 1996;78-B:497.
 317. Mueller KH: Intramedullary nailing of comminuted fractures with additional fixation. *Instruct Course Lect* 1973;22:207.
 318. Murray DW, Kambouroglou G, Kenwright J: One-stage lengthening for femoral shortening with associated deformity. *J Bone Joint Surg* 1993;75-B:566.
 319. Nakamura E, Mizuta H, Sei A, et al: Knee articular cartilage injury in leg lengthening: histological studies in rabbits. *Acta Orthop Scand* 1993;64:437.
 320. Nakamura E, Mizuta H, Takagi K: Knee cartilage injury after tibial lengthening: radiographic and histological studies in rabbits after 3-6 months. *Acta Orthop Scand* 1995;66:313.
 321. Nakamura K, Bell MJ, Saleh M, et al: Results of leg lengthening using Wagner's technique. *Nippon Seikeigeka Gakkai Zasshi* 1991;65:498.
 322. Nakamura K, Matsushita T, Okazaki H, et al: Attempted limb lengthening by physal distraction: continuous monitoring of an applied force in immature rabbits. *Clin Orthop* 1991;267:306.
 323. Naudie D, Hamdy RC, Fassier F, et al: Complications of limb-lengthening in children who have an underlying bone disorder. *J Bone Joint Surg* 1998;80-A:18.
 324. Naudie D, Hamdy RC, Fassier F, et al: Management of fibular hemimelia: amputation or limb lengthening. *J Bone Joint Surg* 1997;79-B:58.
 325. Nettelblad H, Randolph MA, Weiland AJ: Free microvascular epiphysal-plate transplantation: an experimental study in dogs. *J Bone Joint Surg* 1984;66-A:1421.
 326. Newsham I, Kindler-Rohrborn A, Daub D, et al: A constitutional BWS-related t(11; 16) chromosome translocation occurring in the same region of chromosome 16 implicated in Wilms' tumors. *Genes Chromosomes Cancer* 1995;12:1.
 327. Noble J, Diamond R, Stirrat CR, et al: Breaking force of the rabbit growth plate and its application to epiphysal distraction. *Acta Orthop Scand* 1982;53:13.
 328. Noonan KJ, Leyes M, Forriol F, et al: Distraction osteogenesis of the lower extremity with use of monolateral external fixation: a study of two hundred and sixty-one femora and tibiae. *J Bone Joint Surg* 1998;80-A:793.
 329. Noonan KJ, Price CT: Pearls and pitfalls of deformity correction and limb lengthening via monolateral external fixation. *Iowa Orthop J* 1996;16:58.
 330. Noonan KJ, Price CT, Sproul JT, et al: Acute correction and distraction osteogenesis for the malaligned and shortened lower extremity. *J Pediatr Orthop* 1998;18:178.
 331. Nordsletten L, Holm I, Steen H, et al: Muscle function after femoral shortening osteotomies at the subtrochanteric and mid-diaphyseal level: a follow-up study. *Arch Orthop Trauma Surg* 1994;114:37.
 332. Nork SE, Bellig GJ, Woll JP, et al: Overgrowth and outcome after femoral shaft fracture in children younger than 2 years. *Clin Orthop* 1998;357:186.
 333. Oey PL, Engelbert RH, van Roermond PM, et al: Temporary muscle weakness in the early phase of distraction during femoral lengthening: clinical and electromyographical observations. *Electromyogr Clin Neurophysiol* 1999;39:217.
 334. Ogilvie JW: Epiphysiodesis: evaluation of a new technique. *J Pediatr Orthop* 1986;6:147.
 335. Ogilvie JW, King K: Epiphysiodesis: two-year clinical results using a new technique. *J Pediatr Orthop* 1990;10:809.
 336. Olin A, Creasman C, Shapiro F: Free physal transplantation in the rabbit: an experimental approach to focal lesions. *J Bone Joint Surg* 1984;66-A:7.
 337. Oppenheim WL, Namba R: Closed femoral shortening modification using an internal splint. *J Pediatr Orthop* 1988;8:609.
 338. Orbay JL, Frankel VH, Finkle JE, et al: Canine leg lengthening by the Ilizarov technique: a biomechanical, radiologic, and morphologic study. *Clin Orthop* 1992;278:265.
 339. Osterman K, Merikanto J: Diaphyseal bone lengthening in children using Wagner device: long-term results. *J Pediatr Orthop* 1991;11:449.
 340. Paley D: Problems, obstacles, and complications of limb lengthening by the Ilizarov technique. *Clin Orthop* 1990;250:81.
 341. Paley D, Fleming B, Catagni M, et al: Mechanical evaluation of external fixators used in limb lengthening. *Clin Orthop* 1990;250:50.
 342. Paley D, Herzenberg JE, Paremian G, et al: Femoral lengthening over an intramedullary nail: a matched-case comparison with Ilizarov femoral lengthening. *J Bone Joint Surg* 1997;79-A:1464.
 343. Papaioannou T, Stokes I, Kenwright J: Scoliosis associated with limb-length inequality. *J Bone Joint Surg* 1982;64-A:59.
 344. Parker L, Kollin J, Vicario D, et al: Hemihypertrophy as possible sign of renal cell carcinoma. *Urology* 1992;40:286.
 345. Paterson D: Leg-lengthening procedures: a historical review. *Clin Orthop* 1990;250:27.
 346. Paterson JM, Waller CS, Catterall A: Lower limb lengthening by a modified Wagner technique. *J Pediatr Orthop* 1989;9:129.
 347. Patton MA: Russell-Silver syndrome. *J Med Genet* 1988;25:557.
 348. Peixinho M, Arakaki T, Toledo CS: Correction of leg inequality in the Klippel-Trénaunay-Weber syndrome. *Int Orthop* 1982;6:45.
 349. Peters JD, Friermood TG: Closed intramedullary femoral shortening. *Orthop Rev* 1990;19:709.
 350. Peterson HA: Leg length discrepancy associated with vivid cutis mar-marata [letter; comment]. *J Pediatr Orthop* 1994;14:823.

351. Phemister DB: Operative arrestment of longitudinal growth of bones in the treatment of deformities. *J Bone Joint Surg* 1933;15:1.
352. Platto JT: Unequal leg length and back pain [letter]. *Lancet* 1984;2:582.
353. Polo A, Aldegheri R, Zambito A, et al: Lower-limb lengthening in short stature: an electrophysiological and clinical assessment of peripheral nerve function. *J Bone Joint Surg* 1997;79-B:1014.
354. Pope MH, Bevins T, Wilder DG, et al: The relationship between anthropometric, postural, muscular, and mobility characteristics of males ages 18–55. *Spine* 1985;10:644.
355. Porat S, Peyser A, Robin GC: Equalization of lower limbs by epiphysiodesis: results of treatment. *J Pediatr Orthop* 1991;11:442.
356. Price CT: Limb lengthening for achondroplasia: early experience [published erratum appears in *J Pediatr Orthop* 1989;9:733]. *J Pediatr Orthop* 1989;9:512.
357. Price CT: Metaphyseal and physal lengthening. *Instr Course Lect* 1989;38:331.
358. Price CT, Carantzas AC: Severe growth retardation following limb lengthening: a case report. *Iowa Orthop J* 1996;16:139.
359. Price CT, Cole JD: Limb lengthening by callotaxis for children and adolescents: early experience. *Clin Orthop* 1990;250:105.
360. Price CT, Mann JW: Experience with the Orthofix device for limb lengthening. *Orthop Clin North Am* 1991;22:651.
361. Putti V: Operative lengthening of the femur. *Surg Gynecol Obstet* 1934;58:318.
362. Rab GT, Simon SR: An improved method for pinning of chronic slipped capital femoral epiphysis. *J Pediatr Orthop* 1985;5:212.
363. Rajacich N, Bell DF, Armstrong PF: Pediatric applications of the Ilizarov method. *Clin Orthop* 1992;280:72.
364. Reichel H, Haunschild M, Kruger T, et al: Tibial lengthening: epiphyseal and callus distraction compared in 39 patients with 3–14 years follow-up. *Acta Orthop Scand* 1996;67:355.
365. Ring PA: Experimental bone lengthening by epiphyseal distraction. *Br J Surg* 1958;46:169.
366. Robertson WW Jr, Butler MS, D'Angio GJ, et al: Leg length discrepancy following irradiation for childhood tumors. *J Pediatr Orthop* 1991;11:284.
367. Rogalski R, Hensinger R, Loder R: Vascular abnormalities of the extremities: clinical findings and management. *J Pediatr Orthop* 1993;13:9.
368. Rossvoll I, Junk S, Terjesen T: The effect on low back pain of shortening osteotomy for leg length inequality. *Int Orthop* 1992;16:388.
369. Rubinstein RA Jr, Taylor LM Jr, Porter JM, et al: Limb growth after late bypass graft for occlusion of the femoral artery: a case report. *J Bone Joint Surg* 1990;72-A:935.
370. Rush WA, Steiner HA: A study of lower extremity length inequality. *AJR Am J Roentgenol* 1946;56:616.
371. Salai M, Chechick A, Ganel A, et al: Subluxation of the hip joint during femoral lengthening. *J Pediatr Orthop* 1985;5:642.
372. Saleh M, Milne A: Weight-bearing parallel-beam scanography for the measurement of leg length and joint alignment. *J Bone Joint Surg* 1994;76-B:156.
373. Salter RB: Innominate osteotomy in the treatment of congenital dislocation and subluxation of the hip. *J Bone Joint Surg* 1961;43-B:518.
374. Sanpera I Jr, Fixsen JA, Hill RA: Injuries to the physis by extravasation: a rare cause of growth plate arrest. *J Bone Joint Surg* 1994;76-B:278.
375. Sasso RC, Urquhart BA, Cain TE: Closed femoral shortening. *J Pediatr Orthop* 1993;13:51.
376. Schlenzka D, Poussa M, Osterman K: Metaphyseal distraction for lower limb lengthening and correction of axial deformities. *J Pediatr Orthop* 1990;10:202.
377. Schuit D, Adrian M, Pidcoe P: Effect of heel lifts on ground reaction force patterns in subjects with structural leg-length discrepancies. *Phys Ther* 1989;69:663.
378. Schumacher B, Keller J, Hvid I: Distraction effects on muscle: leg lengthening studied in rabbits. *Acta Orthop Scand* 1994;65:647.
379. Schwartzman V, Schwartzman R: Corticotomy. *Clin Orthop* 1992;280:37.
380. Scott AC, Urquhart BA, Cain TE: Percutaneous vs modified Phemister epiphysiodesis of the lower extremity. *Orthopedics* 1996;19:857.
381. Seibert JJ, McCarthy RE, Alexander JE, et al: Acquired bone dysplasia secondary to catheter-related complications in the neonate. *Pediatr Radiol* 1986;16:43.
382. Sengupta A, Gupta P: Epiphyseal stapling for leg equalization in developing countries. *Int Orthop* 1993;17:37.
383. Shah KJ: Beckwith-Wiedemann syndrome: role of ultrasound in its management. *Clin Radiol* 1983;34:313.
384. Shapiro F: Developmental patterns in lower-extremity length discrepancies. *J Bone Joint Surg* 1982;64-A:639.
385. Shapiro F: Legg-Calvé-Perthes disease: a study of lower extremity length discrepancies and skeletal maturation. *Acta Orthop Scand* 1982;53:437.
386. Shapiro F: Ollier's disease: an assessment of angular deformity, shortening, and pathological fracture in twenty-one patients. *J Bone Joint Surg* 1982;64-A:95.
387. Shapiro F: Longitudinal growth of the femur and tibia after diaphyseal lengthening. *J Bone Joint Surg* 1987;69-A:684.
388. Sharma M, MacKenzie WG, Bowen JR: Severe tibial growth retardation in total fibular hemimelia after limb lengthening. *J Pediatr Orthop* 1996;16:438.
389. Shevtsov VI, Asonova SN: Ultrastructural changes of articular cartilage following joint immobilization with the Ilizarov apparatus. *Bull Hosp Jt Dis* 1995;54:69.
390. Shevtsov VI, Asonova SN, Yerofeyev SA: Morphological characteristics of angiogenesis in the myofascial tissues of a limb elongated by the Ilizarov method. *Bull Hosp Jt Dis* 1995;54:76.
391. Shirai H, Abe M, Nagaoka T, et al: Appropriate osteotomy site and number in limb lengthening. *Clin Orthop* 1997;336:308.
392. Siffert RS: Lower limb-length discrepancy. *J Bone Joint Surg* 1987;69-A:1100.
393. Simard S, Marchant M, Mencia G: The Ilizarov procedure: limb lengthening and its implications [see comments]. *Phys Ther* 1992;72:25.
394. Simon S, Whiffen J, Shapiro F: Leg-length discrepancies in monoarticular and pauciarticular juvenile rheumatoid arthritis. *J Bone Joint Surg* 1981;63-A:209.
395. Simpson A, Cole A, Kenwright J: Leg lengthening over an intramedullary nail. *J Bone Joint Surg* 1999;81-B:1041.
396. Simpson AH, Cunningham JL, Kenwright J: The forces which develop in the tissues during leg lengthening: a clinical study. *J Bone Joint Surg* 1996;78-B:979.
397. Simpson AH, Gardner TN, Evans M, et al: Prevention of deformity during limb lengthening. *Clin Orthop* 1997;341:218.
398. Sledge CB, Noble J: Experimental limb lengthening by epiphyseal distraction. *Clin Orthop* 1978;136:111.
399. Smith CF: Instantaneous leg length discrepancy determination by "thigh-leg" technique [see comments]. *Orthopedics* 1996;19:955.
400. Sofield HA: Leg lengthening. *Surg Clin North Am* 1939;19:69.
401. Sofield HA, Blair SJ, Milar EA: Leg lengthening: a personal follow-up of 40 patients some twenty years after the operation. *J Bone Joint Surg* 1958;40-A:311.
402. Solá CK, Silberman FS, Cabrini RL: Stimulation of the longitudinal growth of long bones by periosteal stripping. *J Bone Joint Surg* 1963;45-A:1679.
403. Song KM, Halliday SE, Little DG: The effect of limb-length discrepancy on gait. *J Bone Joint Surg* 1997;79-A:1690.
404. Soukka A, Alaranta H, Tallroth K, et al: Leg-length inequality in people of working age: the association between mild inequality and low-back pain is questionable [see comments]. *Spine* 1991;16:429.
405. Spinelli RR: How we discovered, verified, and disseminated the Ilizarov method. *Bull Hosp Jt Dis* 1997;56:19.
406. Stanitski DF: The effect of limb lengthening on articular cartilage: an experimental study. *Clin Orthop* 1994;301:68.
407. Stanitski DF: Limb-length inequality: assessment and treatment options. *J Am Acad Orthop Surg* 1999;7:143.
408. Stanitski DF, Bullard M, Armstrong P, et al: Results of femoral lengthening using the Ilizarov technique [published erratum appears in *J Pediatr Orthop* 1995;15:722]. *J Pediatr Orthop* 1995;15:224.
409. Stanitski DF, Dahl M, Louie K, et al: Management of late-onset tibia vara in the obese patient by using circular external fixation. *J Pediatr Orthop* 1997;17:691.
410. Stanitski DF, Kassab S: Rotational deformity in congenital hypoplasia of the femur. *J Pediatr Orthop* 1997;17:525.
411. Stanitski DF, Rossman K, Torosian M: The effect of femoral lengthening on knee articular cartilage: the role of apparatus extension across the joint. *J Pediatr Orthop* 1996;16:151.
412. Stanitski DF, Shahcheraghi H, Nicker DA, et al: Results of tibial lengthening with the Ilizarov technique. *J Pediatr Orthop* 1996;16:168.
413. Steen H, Field TO, Ronningen H, et al: Limb lengthening by epiphyseal

- distraction: an experimental study in the caprine femur. *J Orthop Res* 1987;5:592.
414. Stephens DC: Femoral and tibial lengthening. *J Pediatr Orthop* 1983; 3:424.
 415. Stephens DC, Herrick W, MacEwen D: Epiphysiodesis for limb length inequality. *Clin Orthop* 1978;136:41.
 416. Stephens DC, Herrick W, MacEwen GD: Epiphysiodesis for limb length inequality: results and indications. *Clin Orthop* 1978;136:41.
 417. Stephens MM, Hsu LC, Leong JC: Leg length discrepancy after femoral shaft fractures in children: review after skeletal maturity. *J Bone Joint Surg* 1989;71-B:615.
 418. Stephens RT, Dillingham TR: Electromyographic and nerve conduction changes after tibial lengthening by the Ilizarov method [letter; comment]. *J Pediatr Orthop* 1996;16:131.
 419. Stevens MA, De Coster TA, Garcia F, et al: Septic knee from Ilizarov transfixation tibial pin. *Iowa Orthop J* 1995;15:217.
 420. Stevens PM, Belle RM: Screw epiphysiodesis for ankle valgus. *J Pediatr Orthop* 1997;17:9.
 421. Sun JS, Hou SM, Hang YS, et al: Ultrastructural studies on myofibrillogenesis and neogenesis of skeletal muscles after prolonged traction in rabbits. *Histol Histopathol* 1996;11:285.
 422. Sun JS, Hou SM, Liu TK, et al: Analysis of neogenesis in rabbit skeletal muscles after chronic traction. *Histol Histopathol* 1994;9:699.
 423. Suzuki S, Kasahara Y, Seto Y, et al: Dislocation and subluxation during femoral lengthening. *J Pediatr Orthop* 1994;14:343.
 424. Synder M, Harcke HT, Bowen JR, et al: Evaluation of physal behavior in response to epiphysiodesis with the use of serial magnetic resonance imaging. *J Bone Joint Surg* 1994;76-A:224.
 425. Szepesi K, Rigo J, Poti L, et al: Treatment of leg length discrepancy by subtrochanteric shortening of the femur. *J Pediatr Orthop* 1990;10:183.
 426. Tardieu C, Blanchard O, Tabary JC, et al: Tendon adaptation to bone shortening. *Connect Tissue Res* 1983;11:35.
 427. Taylor JF, Warrell E, Evans RA: Response of the growth plates to tibial osteotomy in rats. *J Bone Joint Surg* 1987;69-B:664.
 428. Temme JB, Chu WK, Anderson JC: CT scanograms compared with conventional orthoroentgenograms in long bone measurement. *Radiol Technol* 1987;59:65.
 429. ten Brinke A, van der Aa HE, van der Palen J, et al: Is leg length discrepancy associated with the side of radiating pain in patients with a lumbar herniated disc? *Spine* 1999;24:684.
 430. Terjesen T, Benum P, Rossvoll I, et al: Leg-length discrepancy measured by ultrasonography. *Acta Orthop Scand* 1991;62:121.
 431. Thompson TC, Straub LR, Campbell RD: An evaluation of femoral shortening with intramedullary nailing. *J Bone Joint Surg* 1954;36-A:43.
 432. Timperlake RW, Bowen JR, Guille JT, et al: Prospective evaluation of fifty-three consecutive percutaneous epiphysiodeses of the distal femur and proximal tibia and fibula. *J Pediatr Orthop* 1991;11:350.
 433. Timperlake RW, Cook SD, Thomas KA, et al: Effects of anticonvulsant drug therapy on bone mineral density in a pediatric population. *J Pediatr Orthop* 1988;8:467.
 434. Tjernstrom B, Olerud S, Karlstrom G: Direct leg lengthening. *J Orthop Trauma* 1993;7:543.
 435. Tjernstrom B, Olerud S, Rehnberg L: Limb lengthening by callus distraction: complications in 53 cases operated 1980-1991. *Acta Orthop Scand* 1994;65:447.
 436. Tjernstrom B, Rehnberg L: Back pain and arthralgia before and after lengthening: 75 patients questioned after 6 (1-11) years. *Acta Orthop Scand* 1994;65:328.
 437. Trias A, Mueller K, Ray RD: Epiphysal stapling. *Surg Gynecol Obstet* 1961;113:315.
 438. Trippel SB: Growth plate formation, function, and regulation. In Buckwalter JA, Ehrlich MG, Sandell LJ, et al (eds): *Skeletal Growth and Development: Clinical Issues and Basic Science Advances*, p 183. Rosemont, IL, American Academy of Orthopaedic Surgeons, 1998.
 439. Tupman G: A study of bone growth in normal children and its relationship to skeletal maturation. *J Bone Joint Surg* 1962;44-B:42.
 440. Tupman GS: Treatment of inequality of the lower limbs: the results of operation for stimulation of growth. *J Bone Joint Surg* 1960;42-B:489.
 441. van Roermund PM, ter Haar Romeny BM, Hoekstra A, et al: Bone growth and remodeling after distraction epiphysiolysis of the proximal tibia of the rabbit: effect of electromagnetic stimulation. *Clin Orthop* 1991;266:304.
 442. Velazquez RJ, Bell DF, Armstrong PF, et al: Complications of use of the Ilizarov technique in the correction of limb deformities in children. *J Bone Joint Surg* 1993;75-A:1148.
 443. Viehweger E, Pouliquen JC, Kassis B, et al: Bone growth after lengthening of the lower limb in children. *J Pediatr Orthop B* 1998;7:154.
 444. Viljoen D, Pearn J, Beighton P: Manifestations and natural history of idiopathic hemihypertrophy: a review of eleven cases. *Clin Genet* 1984;26:81.
 445. Vink P, Huson A: Lumbar back muscle activity during walking with a leg inequality. *Acta Morphol Neerl Scand* 1987;25:261.
 446. Volkmann R: Chirurgische Erfahrungen über Knochenverbiegungen und Knochenwachstum. *Arch Pathol Anat* 1862;24:512.
 447. Vostrejs M, Hollister JR: Muscle atrophy and leg length discrepancies in pauciarticular juvenile rheumatoid arthritis. *Am J Dis Child* 1988;142:343.
 448. Wagner H: *Femoral Osteotomies for Congenital Hip Dislocation*, vol 2. New York, Springer, 1978.
 449. Wagner H: Operative lengthening of the femur. *Clin Orthop* 1978; 136:125.
 450. Walker AP, Dickson RA: School screening and pelvic tilt scoliosis. *Lancet* 1984;2:152.
 451. Wall EJ, Massie JB, Kwan MK, et al: Experimental stretch neuropathy: Changes in nerve conduction under tension. *J Bone Joint Surg* 1992;74-B:126.
 452. Wasserstein I: Twenty-five years' experience with lengthening of shortened lower extremities using cylindrical allografts. *Clin Orthop* 1990;250:150.
 453. Westh RN, Menelaus MB: A simple calculation for the timing of epiphysal arrest: a further report. *J Bone Joint Surg* 1981;63-B:117.
 454. White JW, Stubbins SG: Growth arrest for equalizing leg lengths. *JAMA* 1944;126:1146.
 455. White SH, Kenwright J: The timing of distraction of an osteotomy. *J Bone Joint Surg* 1990;72-B:356.
 456. Wiedemann HR: Complexe malformatif familial avec hernia ombilicale et macroglossie un "syndrome nouveau." *J Genet Hum* 1964; 13:223.
 457. Wiedemann M: Callus distraction: a new method? A historical review of limb lengthening. *Clin Orthop* 1996;327:291.
 458. Wilde GP, Baker GC: Circumferential periosteal release in the treatment of children with leg-length inequality. *J Bone Joint Surg* 1987; 69-B:817.
 459. Williams P, Kyberd P, Simpson H, et al: The morphological basis of increased stiffness of rabbit tibialis anterior muscles during surgical limb-lengthening. *J Anat* 1998;193:131.
 460. Winquist RA: Closed intramedullary osteotomies of the femur. *Clin Orthop* 1986;212:155.
 461. Winquist RA, Frankel VH: Complications of implant use. In Epps CHJ (ed): *Complications in Orthopaedic Surgery*. Philadelphia, JB Lippincott Co, in press.
 462. Winquist RA, Hansen ST Jr, Pearson RE: Closed intramedullary shortening of the femur. *Clin Orthop* 1978;136:54.
 463. Wolff J: *Das Gesetz der Transformation der Knochen*. Berlin, August Hirschwald, 1892.
 464. Yadav SS: Double oblique diaphyseal osteotomy: a new technique for lengthening deformed and short lower limbs. *J Bone Joint Surg* 1993;75-B:962.
 465. Yang H, Alnaqeeb M, Simpson H, et al: Changes in muscle fibre type, muscle mass and IGF-I gene expression in rabbit skeletal muscle subjected to stretch. *J Anat* 1997;190:613.
 466. Yasui N, Kojimoto H, Sasaki K, et al: Factors affecting callus distraction in limb lengthening. *Clin Orthop* 1993;293:55.
 467. Yasui N, Sato M, Ochi T, et al: Three modes of ossification during distraction osteogenesis in the rat. *J Bone Joint Surg* 1997;79-B:824.
 468. Young JW, Kovelman H, Resnik CS, et al: Radiologic assessment of bones after Ilizarov procedures. *Radiology* 1990;177:89.
 469. Young N, Bell DF, Anthony A: Pediatric pain patterns during Ilizarov treatment of limb length discrepancy and angular deformity. *J Pediatr Orthop* 1994;14:352.
 470. Young NL, Davis RJ, Bell DF, et al: Electromyographic and nerve conduction changes after tibial lengthening by the Ilizarov method [see comments]. *J Pediatr Orthop* 1993;13:473.
 471. Younger AS, Mackenzie WG, Morrison JB: Femoral forces during limb lengthening in children. *Clin Orthop* 1994;301:55.
 472. Yrjonen T: Long-term prognosis of Legg-Calvé-Perthes disease: a meta-analysis. *J Pediatr Orthop B* 1999;8:169.

473. Yrjonen T, Hoikka V, Poussa M, et al: Leg-length inequality and low-back pain after Perthes' disease: a 28–47-year follow-up of 96 patients. *J Spinal Disord* 1992;5:443.
474. Zanasi R: Surgical equalisation of leg length: shortening of the long femur and lengthening of the short in one operation. *Ital J Orthop Traumatol* 1982;8:265.

Principles of Angular Deformity Correction in Children

INTRODUCTION

Children are commonly seen by the orthopaedist because of parental concern regarding angular deformity of the legs. To assess angular deformity properly, the examiner must be familiar with the normal evolution of the femoral-tibial angle in children and normal lower extremity alignment, both clinically and radiographically (see Chapter 21, Disorders of the Leg). A complete assessment of this deformity requires the examiner to obtain a good history and perform careful general musculoskeletal and focused lower body examinations (see discussion in Chapter 4, The Orthopaedic Examination: Clinical Application). Radiographs should be obtained as needed to complete the assessment.

ETIOLOGY

There are many potential causes of lower extremity angular deformity. Most of these can be readily determined from the combination of history and physical examination findings, and most of the rest will be easily diagnosed based on radiographic abnormality (Fig. 23–47). A list of potential causes of angular deformity is summarized in Table 23–6.

ASSESSMENT OF DEFORMITY

The physician will need to know how long the perceived deformity has been present, the rate of its evolution, whether there was any antecedent injury or infection in the limb, whether the patient has any pain or functional impairment in the use of the limb, and whether there is any personal or family history of a generalized condition that may manifest as angular deformity. The physical examination should include a general assessment of the health and vigor of the child and a search for signs of connective tissue disorder (such as neurofibromatosis, enchondromatosis with vascular anomalies [Maffucci's syndrome], Marfan syndrome, osteochondromatosis, or Ehler-Danlos syndrome). The physical examination of the lower extremities includes an assessment of standing lower extremity alignment, joint range of motion and stability, limb length inequality, neurologic status, and limb function during walking or running.

If abnormalities are detected on examination, radiographic assessment is indicated. A long standing film of the lower extremities with the hips, knees, and ankles all visible on the film is best for the quantification of lower extremity malalignment (Fig. 23–48). Specific views of abnormal joints, physes, or bone segments should also be obtained if a deformity localized to these regions is identified. Scans, including hand and wrist films for determining bone

age, should be obtained if there is leg length inequality present in association with the angular deformity (Fig. 23–49).

NORMAL LOWER EXTREMITY ALIGNMENT

The examiner must be familiar with the evolution of the normal femoral-tibial angle in children (Fig. 23–50).²⁰ In essence, essentially symmetric physiologic varus can be expected between birth and 18 to 24 months of age, followed by a valgus “deformity” that is maximal between the ages of 3 to 3½ years and resolves by the age of 6 to 8 years of age. After “mature” lower extremity alignment has been achieved, the legs will normally look “straight,” that is, the pelvis will be level and the medial femoral condyles and the medial malleoli will touch. Variations from this “standard” or “normal” appearance are common, and, just as for leg length inequality, there are no specific guidelines to separate normal variations (assuming symmetric appearance of the legs) from pathologic angular deformity.^{8,16,17,19,25}

Normal lower extremity alignment is reasonably well documented radiographically within a few degrees of variation from “normal” (Fig. 23–51).^{10,16,19,25} The *mechanical* axis is typically 0 to 1 degrees from the center of the femoral head to the “middle” of the knee to the middle of the distal tibial articular surface. The normal *anatomic* axis (femoral-tibial angle) is 5 to 7 degrees valgus, slightly higher in skeletally mature females than males. Thus, the mechanical and anatomic axes in the femur differ by 5 to 7 degrees. The mechanical and anatomic axes in the tibia are essentially the same. In the neutral anatomic position, with equal limb lengths, the top of the greater trochanter is normally level with the center of the femoral head, and the femoral shaft–femoral neck angle is 135 degrees. The normal angle between the distal femur and the frontal plane horizontal knee axis is 87 degrees (lateral distal femoral-mechanical axis angle). The angle between the axis of the tibia and the tibial articular surfaces is usually 87 degrees (medial proximal tibia-mechanical axis angle) proximally and 90 degrees distally.

There is some debate in the literature over what constitutes the “center” of the knee and ankle joints radiographically, what the range of normal values is for the various angle measurements, and what magnitude of deviation constitutes an “abnormality.”¹⁶ Furthermore, there are no clinical longitudinal studies that establish with certainty a “threshold” for deformity, above which degenerative arthritis or other limb function impairment is to be expected. There is some evidence that angular deformity after fracture malunion or other causes will lead to degenerative arthritis,^{8,12} but other investigations have disputed even this.¹³ The wise physician will incorporate symmetry, lower extremity function, symptoms, the patient's perception of deformity, and the magnitude of surgical intervention required to correct a particular deformity in determining whether lower extremity alignment is abnormal and requires treatment in any given patient.

Careful analysis of the mechanical axis and joint relationships in a child with a long-standing, presumably isolated deformity of one lower limb segment will often reveal the presence of a subtle, usually compensatory, deformity in the adjacent bone segment. An example of this is shown in

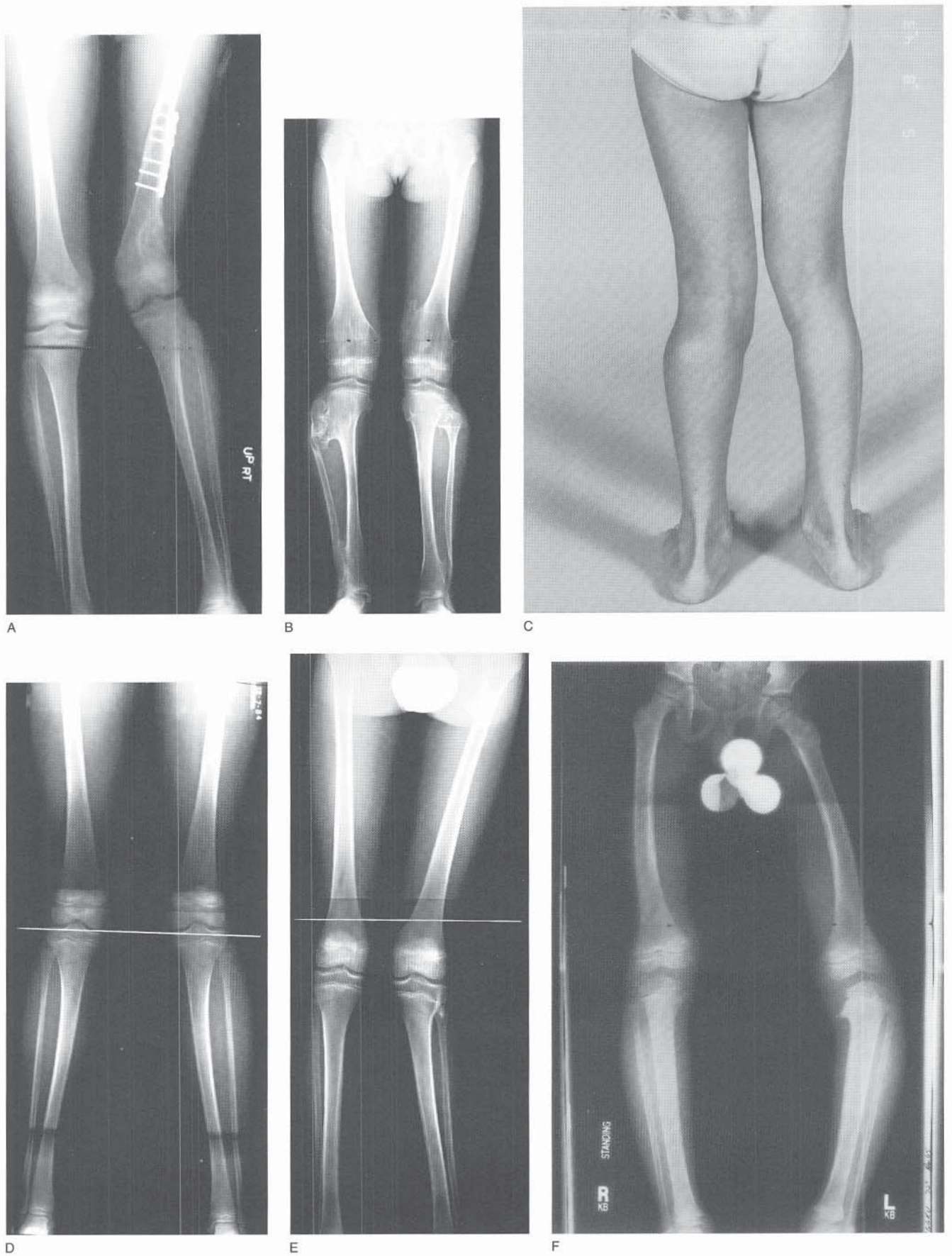


FIGURE 23-47 See legend on opposite page

TABLE 23-6 Causes of Lower Extremity Angular Deformity

Physiologic varus and valgus
Resolving
Persistent (physiologic) valgus
Systemic abnormalities
Metabolic bone disease of any cause:
Renal metabolic bone disease
Vitamin D-resistant rickets
Metaphyseal dysostosis (Schmidt, Jansen types)
Generalized bone disorders
Enchondromatosis (Ollier's disease, Maffucci's syndrome)
Osteochondromatosis (multiple hereditary exostoses)
Melorrrheostosis
Osteogenesis imperfecta
Physeal abnormalities
Partial physeal arrests secondary to:
Physeal fracture
Physeal infection
Irradiation
Direct (surgical) injury
Langenskiöld stage VI infantile Blount's disease
Asymmetric physeal growth deceleration:
After periphyseal fracture
In association with enchondroma or osteochondroma
Infantile Blount's disease and adolescent Blount's disease
Asymmetric physeal growth stimulation:
Proximal tibial metaphyseal fracture
Long bone malunion
Congenital long bone deformity
Posteromedial bowing of the tibia
Anterolateral bowing of the tibia
Variants of congenital pseudarthrosis of the tibia
Resolving anterolateral bowing of the tibia (rare)
Associated with congenital limb deficiency
Distal femoral valgus associated with congenital femoral deficiency
Anteromedial bow of tibia associated with congenital fibular deficiency

Figure 23-47A, where a growth disturbance of the lateral distal femoral physis by a solitary enchondroma has produced a distal femoral valgus deformity with mild limb shortening. Less obvious both clinically and radiographically is the presence of slight proximal tibial varus, partially compensating for the valgus deformity (Fig. 23-52). In a case such as this, if the distal femoral deformity is corrected completely, the varus deformity will be unmasked (Figs. 23-53A and B). If the deformity is corrected until the limb appears clinically straight, there will be residual deformities of the distal femur and proximal tibia, with knee joint obliq-

FIGURE 23-47 Different causes of angular deformity in children. **A**, Enchondroma of the lateral distal femur with growth disturbance, leading to a valgus deformity (see also Fig. 23-52). **B**, Radiographic appearance of a patient with osteochondromatosis, demonstrating osteochondromas of the left proximal tibial metaphysis with associated proximal tibial valgus deformity. **C**, Clinical appearance of the patient in **B**. **D**, Apparently healthy 13-year-old girl with persistent physiologic valgus deformity of the legs (see also Fig. 23-60). **E**, Valgus deformity of the proximal tibia after a penetrating injury to the proximal tibial epiphysis resulted in a partial lateral proximal tibial growth arrest (see also Figs. 23-49 and 23-65). **F**, Patient with Langenskiöld stage III infantile Blount's disease and proximal tibial varus deformity (see Fig. 23-58).

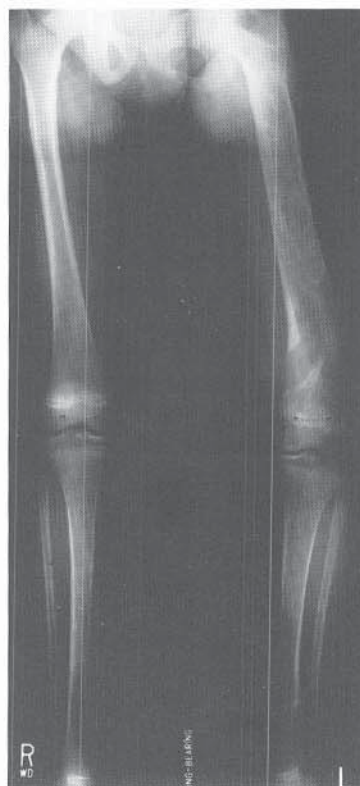

FIGURE 23-48 A long standing film with the hips, knees, and ankles visible on the radiographs is the best radiographic method to assess angular deformity in the lower extremities.

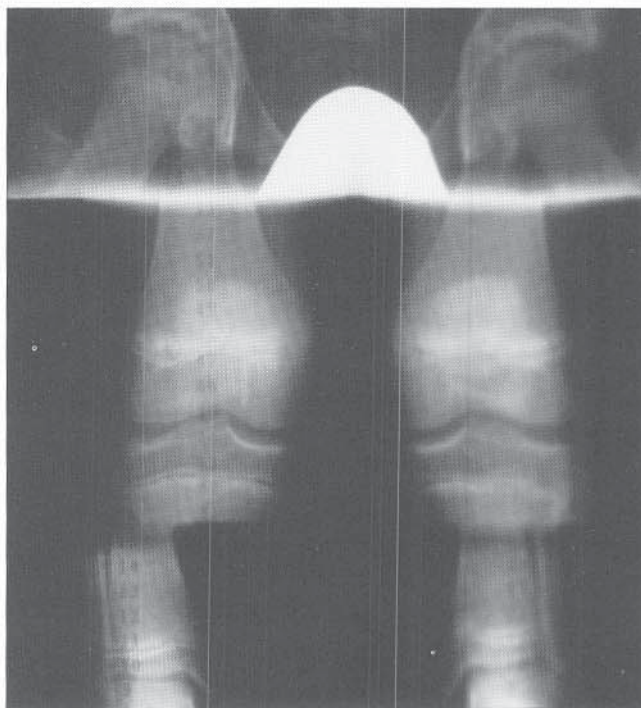


FIGURE 23-49 Patients with asymmetric angular deformity should undergo a clinical assessment and frequently scanography to document leg length inequality associated with the angular deformity. This patient, with a traumatic partial proximal tibial physeal arrest (same patient as in Fig. 23-47E), has, in addition, a leg length inequality of 2.5 cm by scanogram.

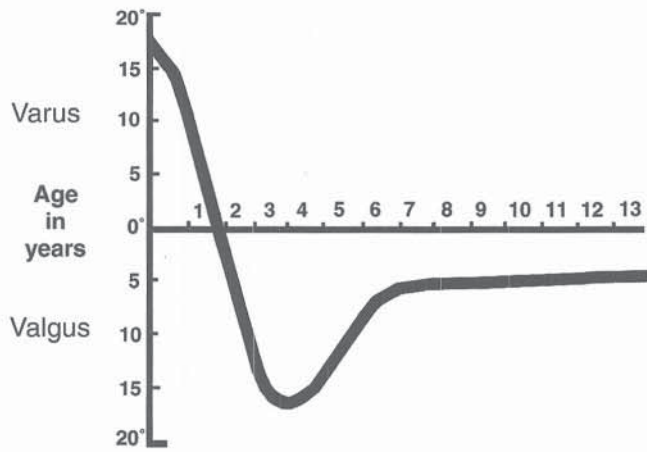


FIGURE 23-50 Evolution of the femoral-tibial angle in children. From birth to approximately 18 months of age, the femoral-tibial angle on radiographs is in varus, from 18 months to 6 years it is typically in valgus, and thereafter it is in 5 to 7 degrees of valgus. (Adapted from Salenius P, Vankka E: The development of the tibiofemoral angle in children. *J Bone Joint Surg* 1975;57-A:260.)

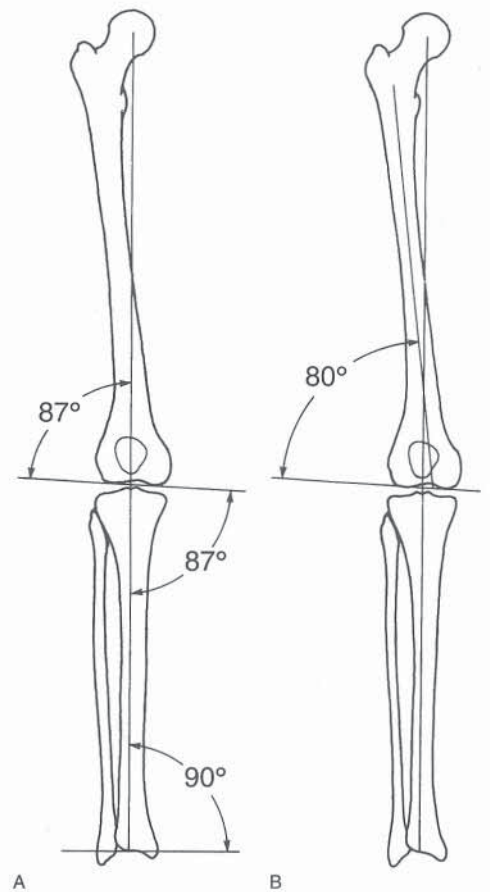


FIGURE 23-51 Scheme of the normal anatomic and mechanical axes. **A**, The *mechanical axis*, from the center of the hip to the center of the knee to the center of the ankle, is straight (0 degrees) to 1 degree of varus. The angle between the mechanical axis and the tangent to the knee joint is 87 degrees (lateral distal femoral angle), and the angle between the mechanical axis and the proximal tibia is 87 degrees (medial proximal tibial angle). **B**, The femoral-tibial angle (*anatomic axis*) is normally 5 to 7 degrees of valgus. The angle between the mechanical axis and a tangent to the ankle mortise is usually 90 degrees. See text for further explanation. Minor deviations from “normal” are common in the normal population.

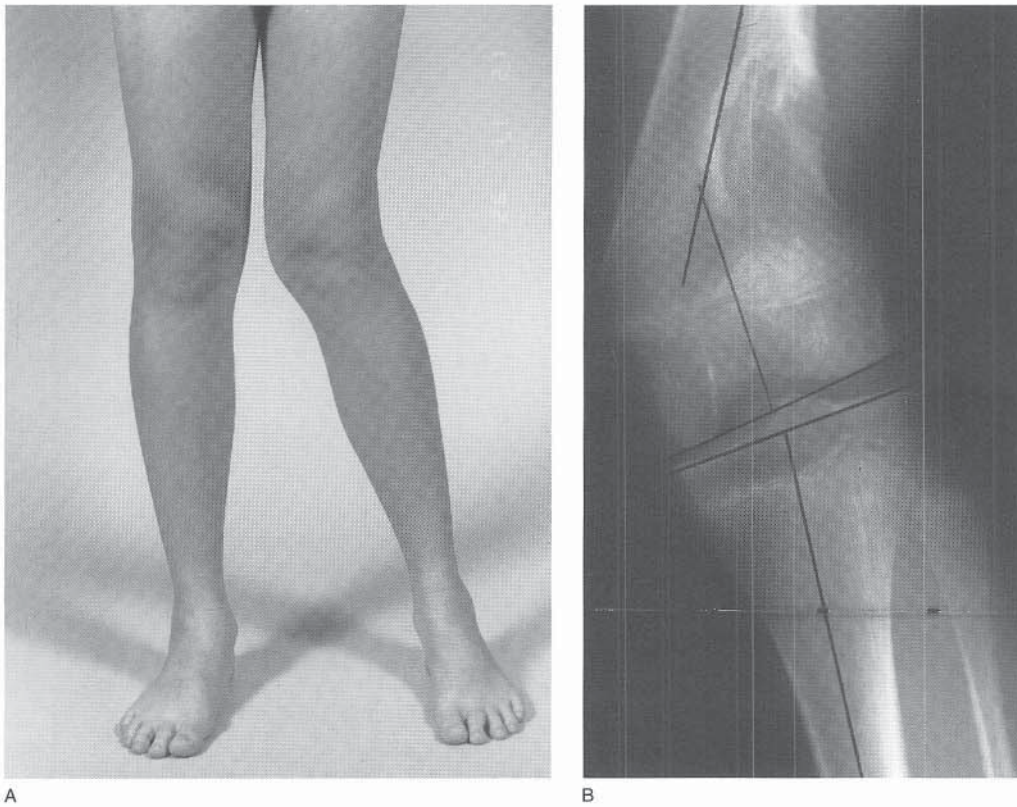


FIGURE 23-52 Patient with long-standing distal femoral valgus secondary to a solitary enchondroma affecting growth of the lateral distal femoral physis (same patient as in Fig. 23-47A). **A**, Clinical appearance of the valgus deformity. **B**, Radiographic appearance of the knee. A solitary enchondroma of the lateral distal femur has produced a lateral distal femoral physeal growth disturbance, and subsequent valgus deformity. Note that there is also a radiographic proximal tibial varus deformity. There is no enchondromatous lesion of the proximal tibia, and the proximal tibial deformity presumably developed to partially compensate for the distal femoral deformity.

uity to the mechanical axis (Fig. 23-53C). “Complete” correction to anatomic normalcy would require both distal femoral varus and proximal tibial valgus osteotomies (Fig. 23-53D), a significant surgical intervention. Myriad examples of this phenomenon can be identified in long-standing deformities in children (proximal tibial varus in association with posteromedial bowing of the tibia or proximal tibial metaphyseal fracture with valgus overgrowth (Fig. 23-54); distal tibial valgus and/or distal femoral valgus/varus in association with adolescent Blount’s disease (Fig. 23-55); and proximal tibial valgus associated with congenital club-foot deformity. What degree of deformity constitutes “enough” to warrant a two-bone, two-level osteotomy, or alternatively, how much angular deformity of the bone or joint obliquity can be left untreated without long-term detriment to the patient, is a matter of conjecture. I personally consider each deformity independently to the best of my ability. If I would normally consider correction of any secondary deformity if it was the only deformity present, I recommend correction of both. Any clinically or radiographically subtle deformity of no concern to the patient for which I would normally discourage correction I leave uncorrected (or, more often, undercorrect the primary deformity).

PRINCIPLES OF DEFORMITY CORRECTION

Ideally, angular deformity correction by osteotomy (when indicated) should be performed at the level of the apex of the deformity. When the apex of deformity is in the metaphysis or diaphysis of a long bone, such correction is not difficult. Either a closing or opening wedge osteotomy can be made at the level of deformity, with the desired angular deformity correction and internal or external fixation as preferred by the surgeon and depending on the specific clinical situation (Fig. 23-56).

In children, the apex of angular deformity is frequently at the level of the physis or epiphysis, where osteotomy is usually not feasible (Fig. 23-57). In such cases, osteotomy is usually performed at a level remote from the apex of angular deformity, typically in the adjacent metaphysis. If angular deformity correction alone is performed at this remote level, a translational deformity of the mechanical axis will result (Fig. 23-57B). To correct angular deformity at a level remote from the apex of the deformity without creating axis translation, the distal fragment must be translated an adequate amount to correct the translational deformity (Fig. 23-57C). Such correction is most easily accomplished with external fixation and gradual angular deformity correction, with the hinges placed in such a location as to effect

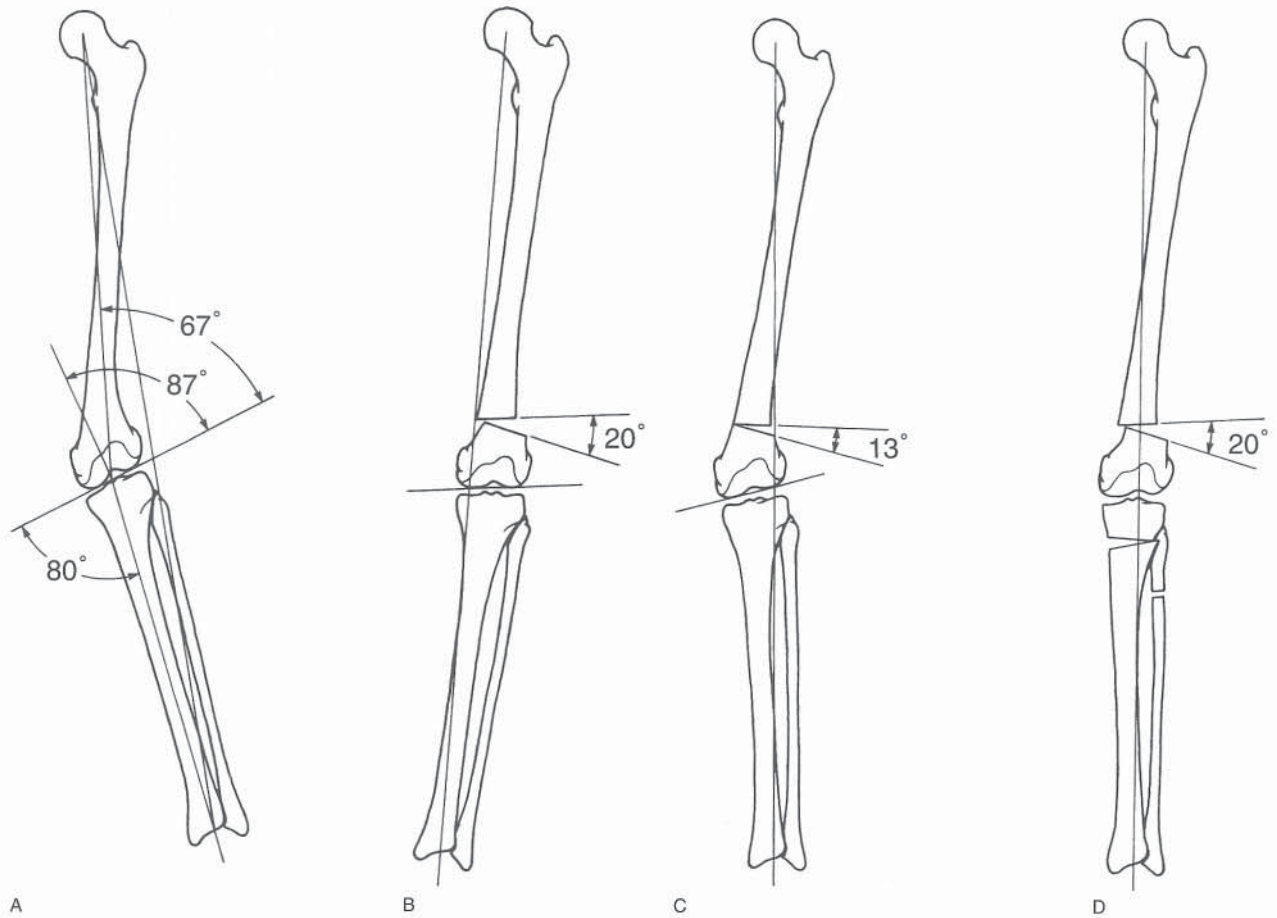


FIGURE 23-53 Approach to correcting the distal femoral deformity in the patient in Figure 23-52. **A**, Analysis of the deformity. There is 20 degrees of distal femoral valgus deformity secondary to the enchondroma-induced distal femoral growth disturbance. There is a partially compensating proximal tibial varus deformity of 7 degrees. **B**, Complete correction of the distal femoral valgus with proper knee orientation will unmask the slighter proximal tibial varus deformity. **C**, Incomplete correction will leave the patient with residual distal femoral valgus deformity, persistent proximal tibial varus deformity, and knee joint obliquity. **D**, Ideal correction requires correction of both the distal femoral and proximal tibial deformities with restoration of the mechanical axis and proper orientation of the knee joint to that axis.

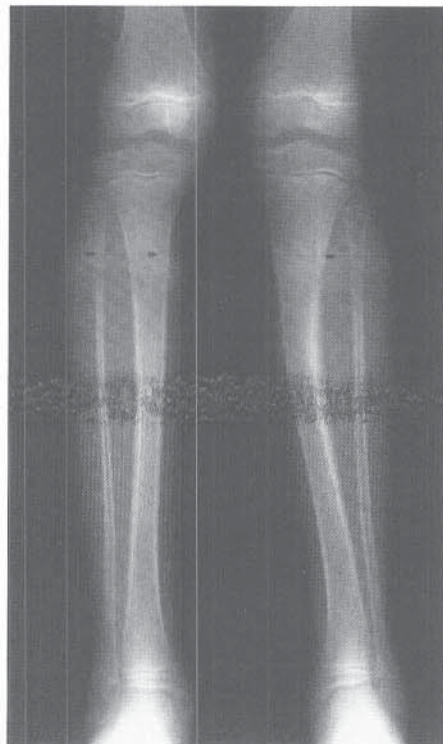
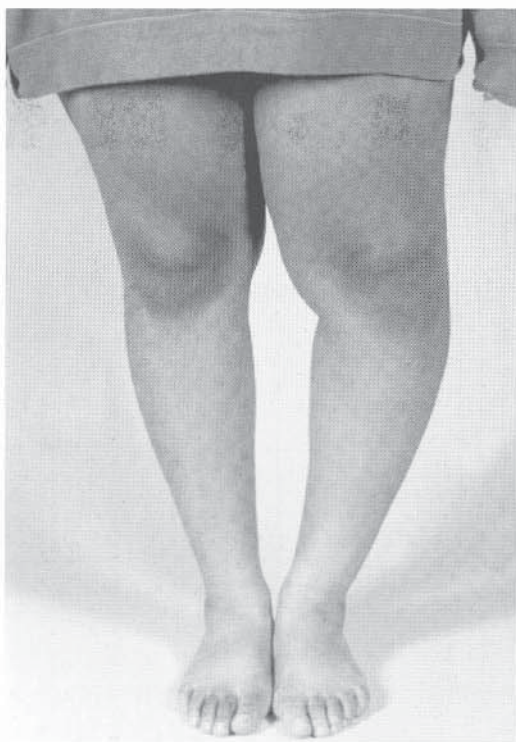
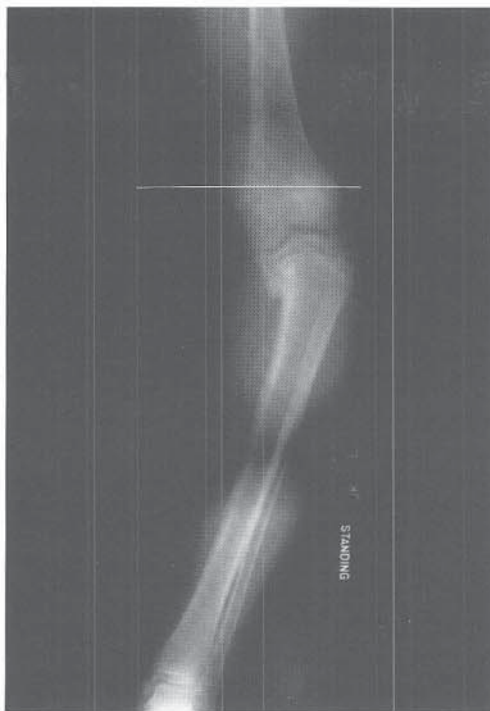FIGURE 23-54 Radiograph obtained several years after the development of a proximal tibial valgus deformity following a proximal tibial metaphyseal fracture. Some valgus deformity persists in the upper diaphysis, and there are slight compensatory varus deformities in the proximal and distal tibia.



A



B

FIGURE 23-55 Clinical and radiographic appearance of a patient with adolescent tibia vara (adolescent Blount's disease). A, Clinical appearance of the proximal tibial varus. B, Radiographic appearance. In addition to the obvious proximal tibial varus, a distal tibial valgus deformity at the ankle and a distal femoral valgus deformity are present.

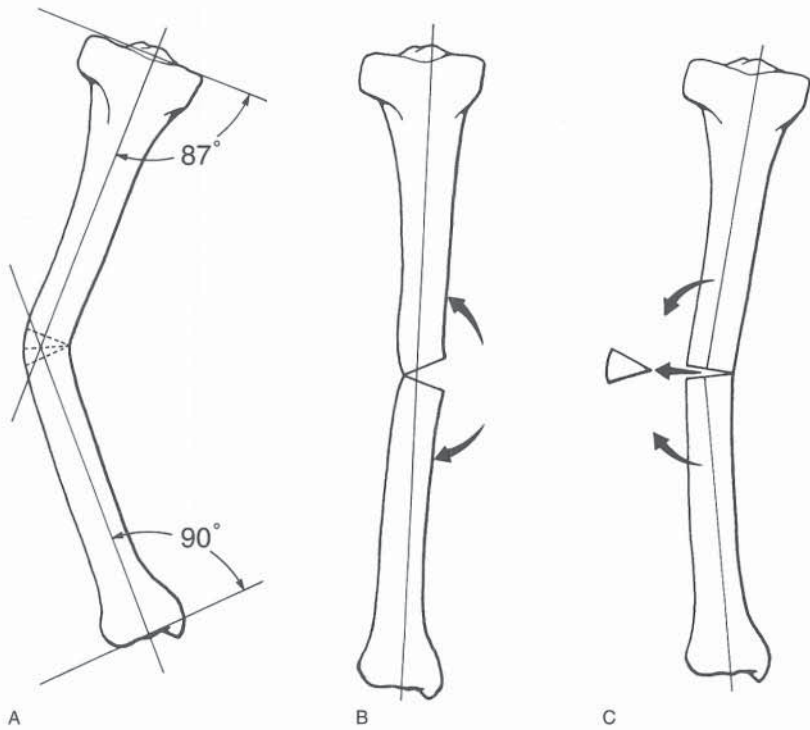


FIGURE 23-56 Angular deformity correction at the apex of the deformity. **A**, Analysis of an angular deformity of the diaphysis of the tibia. **B**, Deformity correction with an opening wedge at the apex of the deformity. **C**, Deformity correction with a closing wedge osteotomy at the apex of the deformity.

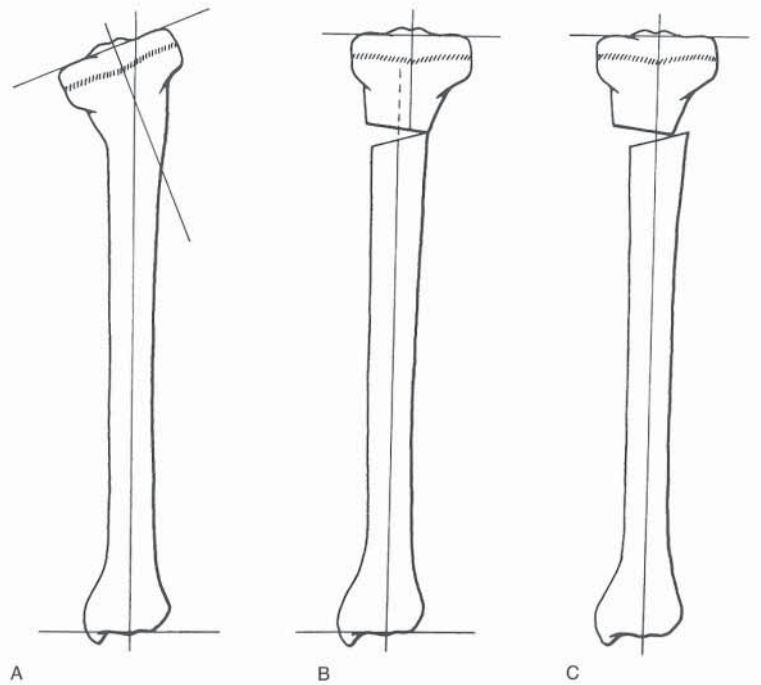


FIGURE 23-57 Correction of an angular deformity with its apex in the region of the epiphysis or physis. Such a location is typical of infantile or adolescent Blount's disease. **A**, Analysis of the deformity. There is proximal tibial varus, with an apex at the level of the physis. **B**, Angular deformity correction by valgus osteotomy in the metaphysis (below the tibial tubercle) will correct the angular relationships but leave the distal tibial mechanical axis medial to the proximal tibial mechanical axis. **C**, Ideal correction of the deformity requires both angular correction and translation of the distal fragment laterally to correct axis translation.

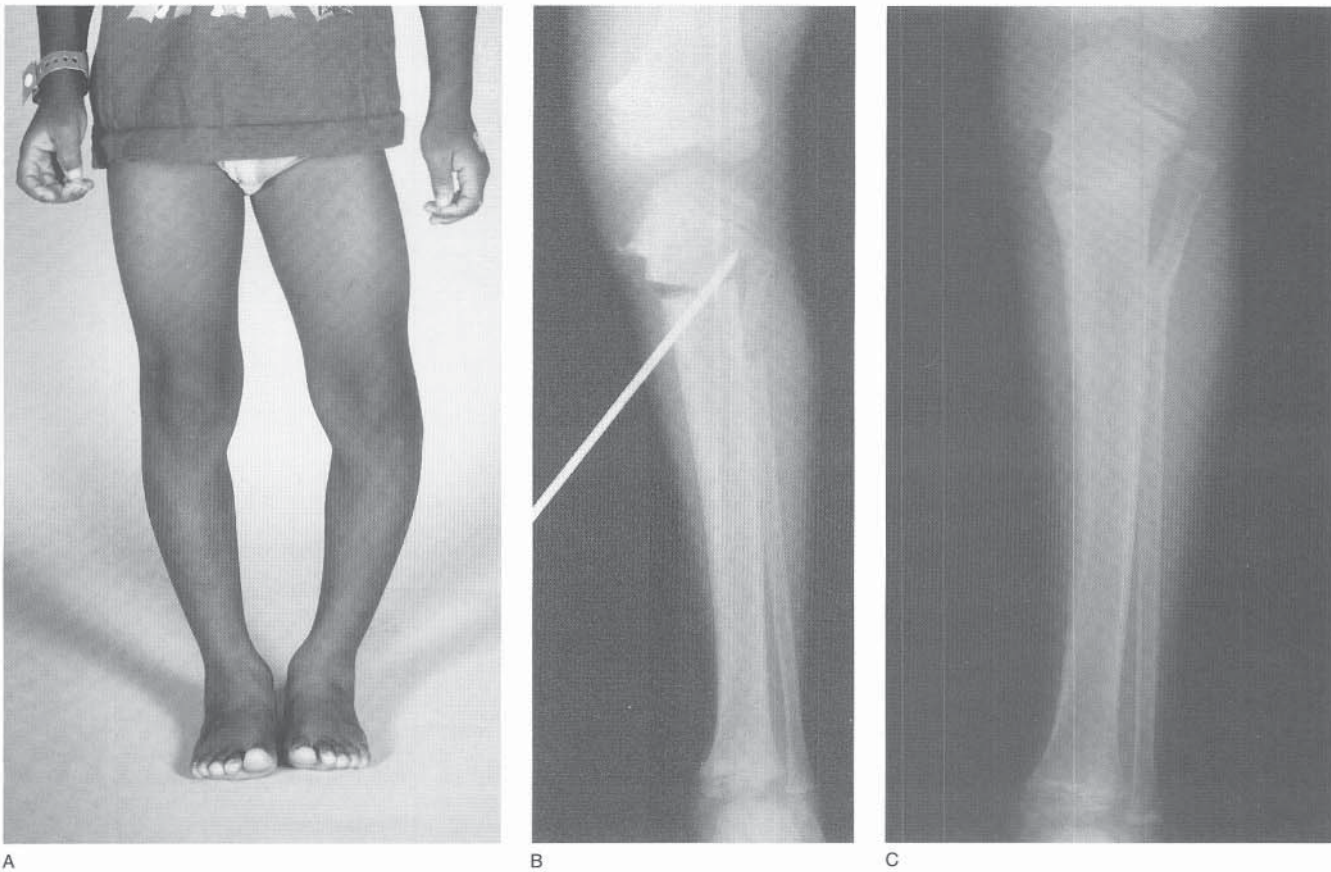


FIGURE 23-58 High tibial osteotomy for infantile Blount's disease with correction of the angular deformity and simultaneous lateral translation of the distal fragment. A, Preoperative clinical appearance (same patient as in Fig. 23-47F). B, Immediate postoperative appearance with Steinmann pin and cast fixation. C, Radiographic appearance after healing of the osteotomy.

this correction. This principle may be used, however, with acute correction techniques and simple fixation (such as a Steinmann pin) (Fig. 23-58). With more formal internal fixation, axis deviation usually results (Fig. 23-59).

SURGICAL OPTIONS FOR DEFORMITY CORRECTION

A number of surgical options are available to the surgeon to correct angular deformity in children. Surgical options include correction by influencing longitudinal growth by staple insertion or hemiepiphysiodesis, acute correction with internal or external fixation, and gradual correction with external fixation. Which technique is chosen depends on a number of factors, including how much growth remains in the affected bone segment, the likelihood of recurrence based on the etiology of the deformity, the quality of the bone to be treated, the presence and extent of associated leg length inequality, patient compliance, and individual surgeon preference.

Hemiepiphyseal Stapling. In a growing child with symmetric angular deformity, or angular deformity in the longer leg, asymmetric deceleration of growth may be attempted by inserting staples, as described by Blount (Fig. 23-60).^{4,5,7,15,24} The basic principles and techniques are the same as for using staples for leg length inequality. The best candidates

for this technique are patients with angular deformity of the longer leg or very young children who should not undergo epiphysiodesis because excessive growth retardation would result, and in whom correction by osteotomy is not desirable. The advantages of hemiepiphyseal stapling include a relatively low surgical morbidity, and in theory, reversibility of growth deceleration after staple removal. The main disadvantage of stapling for angular deformity is the uncertain nature of subsequent growth after the staples are removed: recurrence of deformity, continued angular growth, or maintenance of correction may follow (Fig. 23-61).

A variation of hemiepiphyseal stapling is to use percutaneously inserted screws across the physis, as described by Stevens and Belle²³ and Métaizeau and colleagues.¹⁴ The same disadvantages are present as with stapling for angular deformity correction (Fig. 23-62).

Hemiepiphyodesis. An alternative to hemiepiphyseal stapling is surgical hemiepiphysiodesis. This technique has been described primarily for the management of adolescent Blount's disease,⁹ but it may be used for any angular deformity originating in the region of the physis in which the physis on the convex side of deformity has adequate growth remaining to allow angular correction.⁶ The surgeon must determine the amount of growth remaining in the affected physis to ascertain that excessive limb shortening will not result. Bowen and associates⁶ have published a table to assist

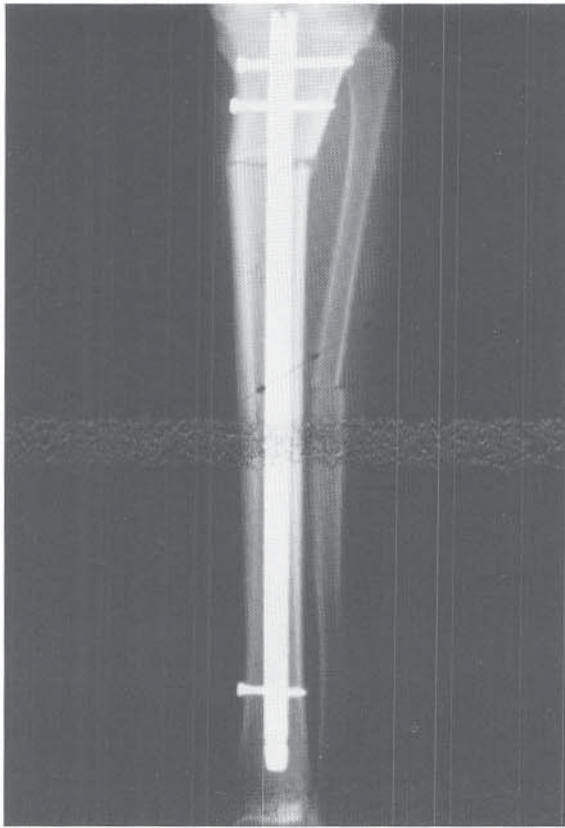


FIGURE 23-59 When a metaphyseal osteotomy combined with secure internal fixation is performed to correct epiphyseal or physeal apex deformities, realignment of the mechanical axis is often not achieved. In this example, a high tibial osteotomy for adolescent Blount's disease with intramedullary rod fixation results in medial translation of the mechanical axis of the distal fragment.

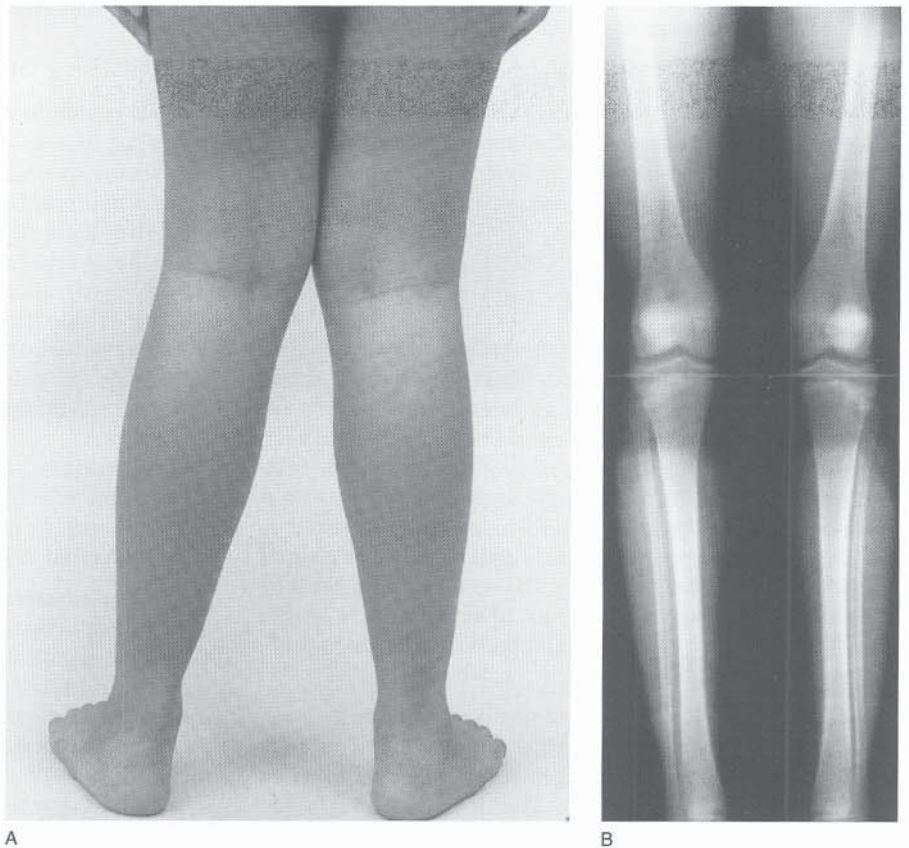

FIGURE 23-60 A patient treated for persistent physiologic genu valgum by epiphyseal stapling of the distal femur as described by Blount (same patient as in Fig. 23-47D). A, Preoperative clinical appearance. B, Radiographic appearance at skeletal maturity after removal of the staples.

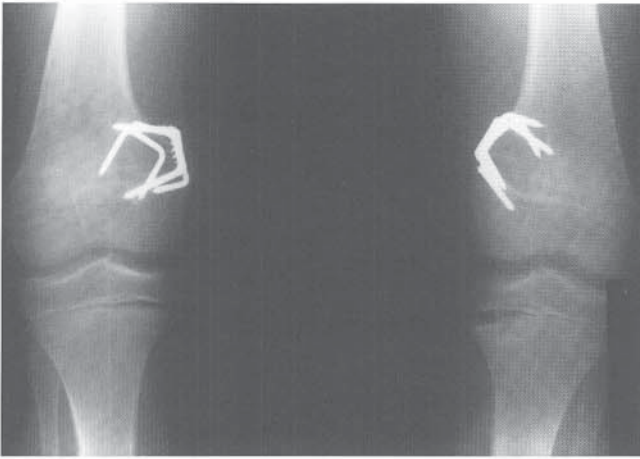


FIGURE 23-61 Example of complications that can arise from a poorly performed epiphyseal stapling. This patient was treated for dysplasia-related genu valgum by medial stapling of the distal femur. The staples have broken, extruded, and migrated. In addition, the patient was not adequately monitored, and genu varum has resulted. The barbed staples proved difficult to remove at surgery, and the patient required osteotomies to correct the genu varum.

in the timing of hemiepiphyseal, based on geometric manipulation of the Anderson-Green growth remaining charts.^{2,3} We have not found this method helpful in our practice, however, since often the physis in question (such as in adolescent Blount's disease) has an unpredictable amount of growth remaining. We prefer to determine that there is not an excessive amount of growth remaining, which could lead to an unacceptable amount of limb shortening, and we counsel families that completion of the hemiepiphyseal may be required after full correction has been achieved.

After hemiepiphyseal, the patient must be followed carefully postoperatively to guard against overcorrection; correction of deformity prior to skeletal maturity will require completion of epiphyseal and a determination of the need for contralateral limb epiphyseal to prevent symptomatic limb length inequality. This procedure is our preferred technique in patients with an adequate but not excessive amount of growth remaining in the physis to undergo epiphyseal in whom osteotomy is preferably avoided (Fig. 23-63).

Osteotomy. Osteotomies of the lower extremity carry a variable risk for delayed union, nonunion, infection, inadequate correction or overcorrection, compartment syndrome, and peripheral nerve injury, depending on the nature of the osteotomy, the degree of deformity and correction, the location of the osteotomy, the local bone condition, and other factors. Each of the following procedures has advantages and disadvantages, depending on the type of deformity being corrected; the surgeon must weigh these in each case to select the optimum treatment plan for specific deformities.

ACUTE CORRECTION. Acute correction of angular deformity by osteotomy provides a certain measure of immediate satisfaction to both patient and surgeon and limits the convalescent period to that required for osteotomy union. However, the risk of compartment syndrome after osteotomy of the tibia is higher with acute correction, and there is always some uncertainty involved in attempting to determine the exact amount of correction to be achieved when the patient is in the nonweightbearing position at surgery. Metaphyseal osteotomies with acute correction performed to correct deformities in which the apex is physeal or epiphyseal usually allow only limited translation of the fragments to restore axial alignment, and that translation usually prevents stable internal fixation. Usually the soft tissues are tensioned with

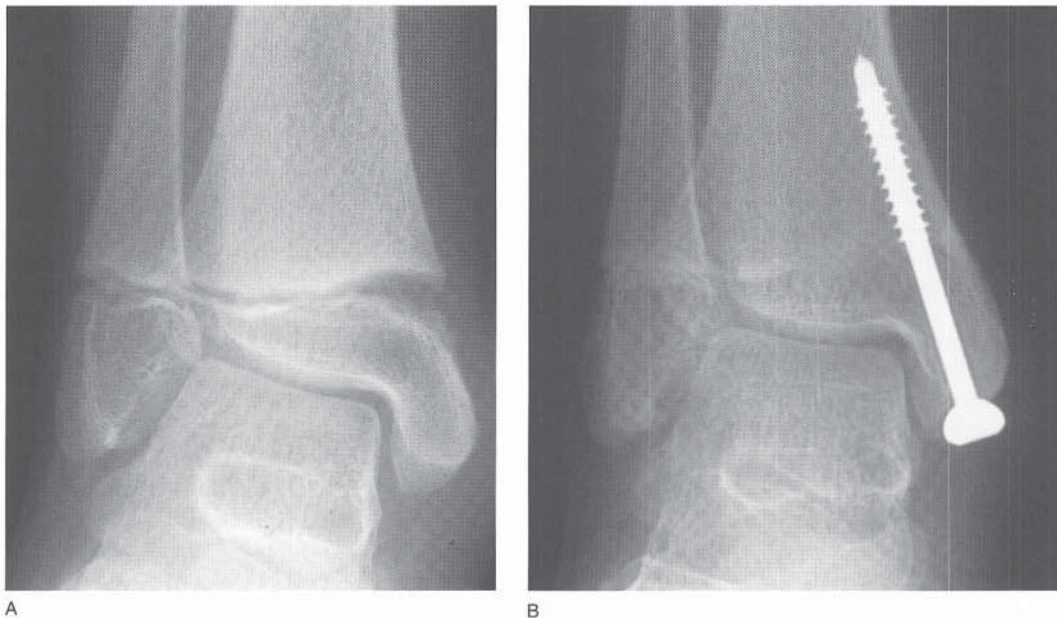

FIGURE 23-62 Correction of ankle valgus deformity by hemiepiphyseal effect of a percutaneously inserted medial malleolar screw. **A**, Preoperative appearance of distal tibial valgus associated with myelomeningocele. **B**, Postoperative appearance 2 years after insertion of medial malleolar screw with correction of distal tibial valgus deformity.

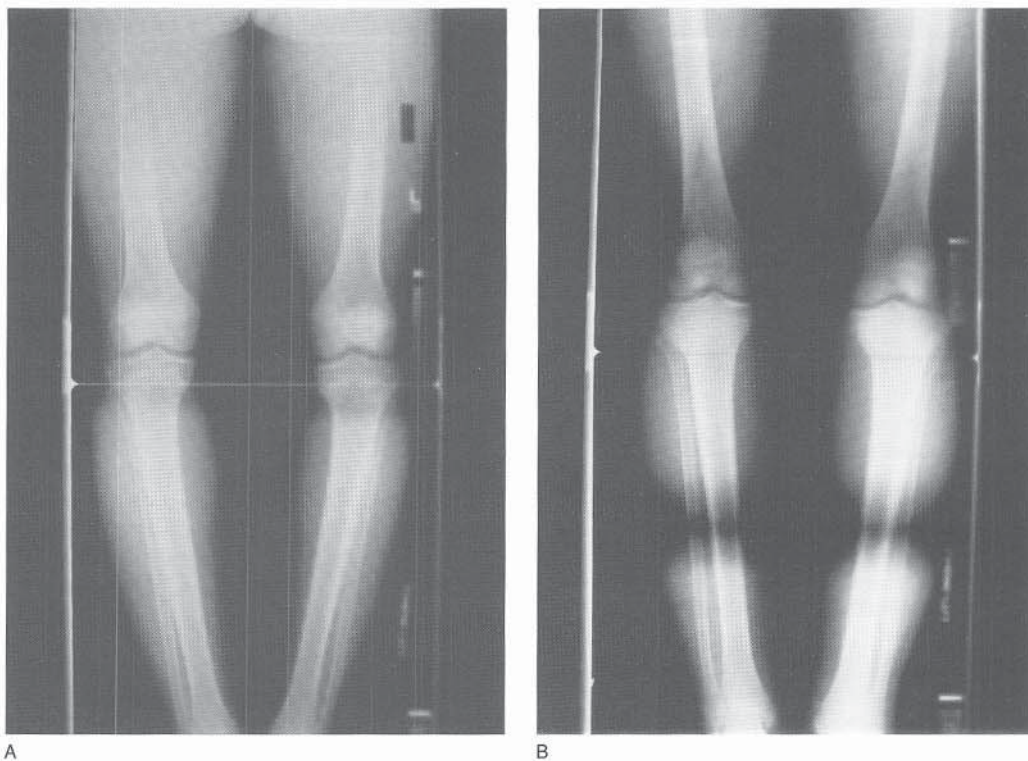


FIGURE 23-63 A patient with adolescent Blount's disease who was treated by open epiphysiodesis of the lateral proximal tibia and fibula. **A**, Preoperative radiographic appearance. **B**, Postoperative radiographic appearance, 12 months after hemiepiphysiodesis.

the acute correction, even if a closing wedge osteotomy is performed, so that the amount of lengthening achievable is limited. These osteotomies may be opening wedge, closing wedge, or a combination of opening and closing (see Figs. 23-56A to C). When the osteotomy is performed at a level in the bone remote from the apex of the deformity, translation of the fragments to restore mechanical axis alignment is preferable whenever possible (see Figs. 23-57A to C).

Internal fixation after acute corrective osteotomy may be definitive, with plate and screws or intramedullary device, or partial, such as with percutaneous pins supplemented with casts. Extensive definitive fixation is preferable in older children, in whom early mobilization and avoidance of extensive casting (such as with a spica cast) are desirable. Simple Steinmann pin fixation is appropriate for younger children, especially in tibial osteotomies, where less soft tissue dissection is desirable, casting is not obtrusive, and rapid union is typical.

Scheffer and Peterson have described a technique of opening wedge metaphyseal osteotomy with tricortical iliac crest graft interposition for angular deformity correction and minor acute lengthening.²¹ According to these authors, this technique is suitable for the management of angular deformities of 25 degrees or less and projected discrepancies of 2.5 cm or less, and if the local bone and soft tissue quality permit acute correction with a stable site for the interpositional bone graft. The graft can be held in place with Steinmann pins, crossed screws, or a bone plate (Fig. 23-64).

External fixation of corrective angular osteotomies has several theoretical advantages: the amount of soft tissue dissection is typically less, the risk of infection is less than

when internal fixation is used; postoperative adjustment to the extent of correction can usually be accomplished without difficulty, depending on the fixation device used; axis translation to restore the mechanical axis is more easily accomplished; and angular deformity correction can be combined with lengthening when desired. Disadvantages include longer healing time, slower mobilization, potentially more complex surgery with the application of the device, and the need for patient acceptance and compliance in the postoperative management.

External fixation may be used in conjunction with acute correction of angular deformity.^{11,18} The usual surgical technique is to orient the components of the device to parallel the axis of the bone segments, perform the osteotomy (as described earlier for leg lengthening), acutely correct the angular deformity ideally with translation as indicated, and secure the device. Subsequent lengthening of the limb through the osteotomy site by the callotasis technique is possible if desired. The advantages of this technique include immediate patient and surgeon satisfaction with immediate postoperative correction, and stable external fixation without the use of more complex hinge components in the external fixator. Disadvantages include a greater risk of neurovascular stretch than with other acute correction techniques, and, when the procedure is combined with lengthening, the healing index may be longer than with gradual correction.¹⁸ Noonan and colleagues reported generally good results in a group of 35 patients, with an average angular correction of 19 degrees;¹⁸ Kamegaya and colleagues recommended a dome-shaped osteotomy for correction of deformity greater than 20 degrees.¹¹ Noonan and colleagues found

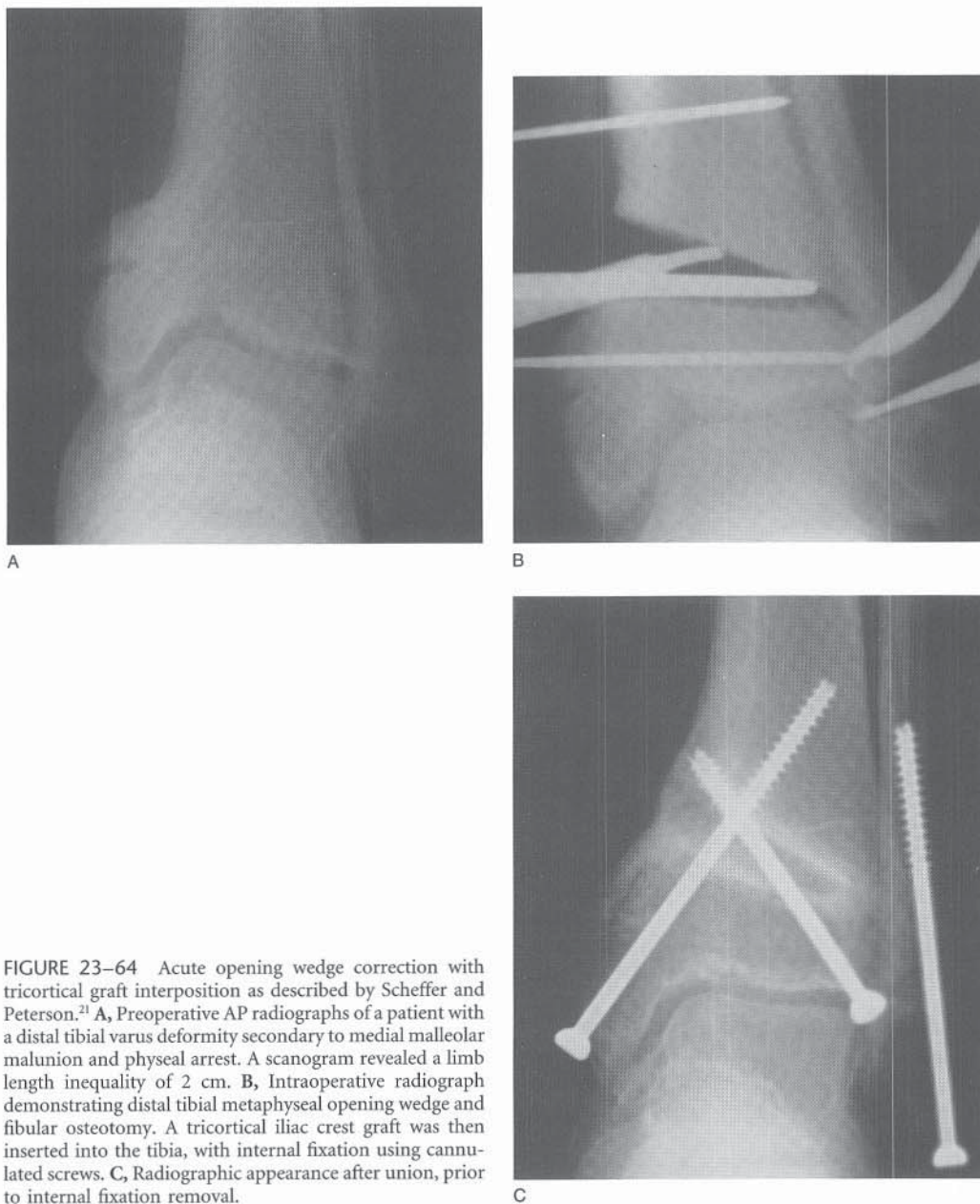
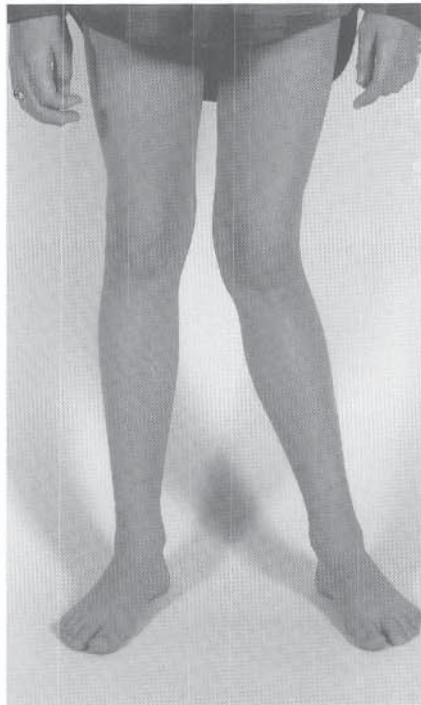
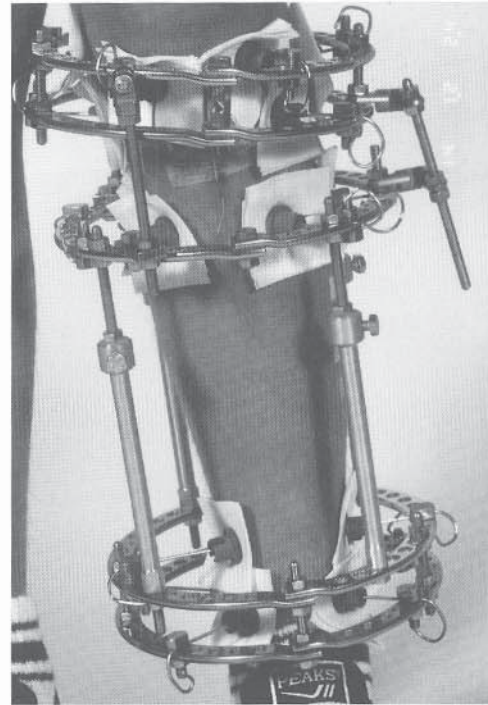


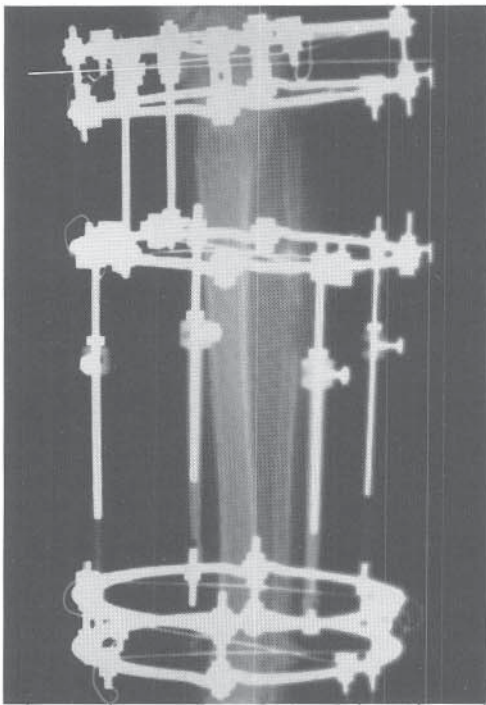
FIGURE 23-64 Acute opening wedge correction with tricortical graft interposition as described by Scheffer and Peterson.²¹ **A**, Preoperative AP radiographs of a patient with a distal tibial varus deformity secondary to medial malleolar malunion and physal arrest. A scanogram revealed a limb length inequality of 2 cm. **B**, Intraoperative radiograph demonstrating distal tibial metaphyseal opening wedge and fibular osteotomy. A tricortical iliac crest graft was then inserted into the tibia, with internal fixation using cannulated screws. **C**, Radiographic appearance after union, prior to internal fixation removal.



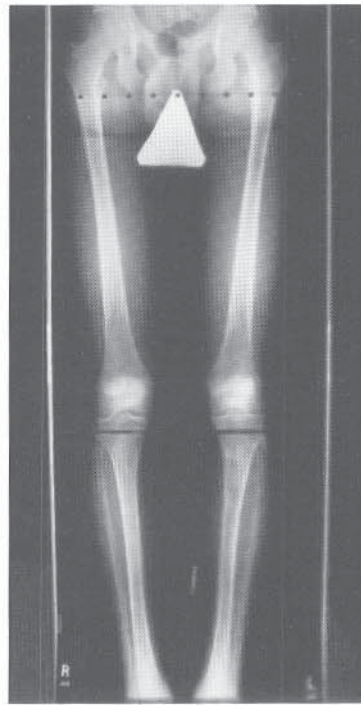A



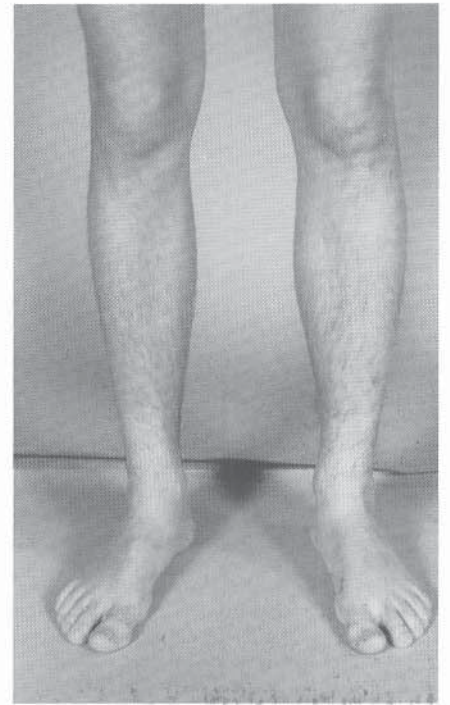
B



C



D



E

FIGURE 23-65 Gradual angular deformity correction using the Ilizarov circular ring fixator. **A**, Preoperative clinical appearance of a patient with a proximal tibial valgus deformity secondary to lateral proximal tibial physeal arrest (same patient as in Fig. 23-47E). **B**, Clinical appearance after application of Ilizarov apparatus with ring segments connected by hinges. **C**, Radiographic appearance after angular deformity correction and 2-cm lengthening. **D**, Final radiographic appearance. **E**, Final clinical appearance. The limb lengths are equal.

that adults and patients with metabolic bone disease such as rickets were more prone to bone complications, including poor bone healing, and did not recommend this technique in such patients.¹⁸

Angular deformities may also be corrected by osteotomy, external fixation, and gradual correction. The circular ring fixator is most suitable for this method, although satisfactory angular deformity correction using the Garches clamp (an Orthofix monolateral fixation device) and other similar devices have been reported (Fig. 23–65).^{1,22} The surgeon must be comfortable with the external fixation device used and with the proper location of hinges to correct the angular deformity and effect axis translation when necessary.

REFERENCES

Principles of Angular Deformity Correction in Children

- Aldegheri R: Distraction osteogenesis for lengthening of the tibia in patients who have limb-length discrepancy or short stature. *J Bone Joint Surg* 1999;81-A:624.
- Anderson M, Green W, Messner M: Growth and predictions of growth in the lower extremities. *J Bone Joint Surg* 1963;45-A:1.
- Anderson M, Messner M, Green W: Distribution of lengths of the normal femur and tibia in children from one to eighteen years of age. *J Bone Joint Surg* 1964;46-A:1197.
- Blount WP: A mature look at epiphyseal stapling. *Clin Orthop* 1971;77:158.
- Blount WP, Zeier F: Control of bone length. *JAMA* 1952;148:451.
- Bowen JR, Leahey JL, Zhang ZH, et al: Partial epiphysiodesis at the knee to correct angular deformity. *Clin Orthop* 1985;198:184.
- Frantz CH: Epiphyseal stapling: a comprehensive review. *Clin Orthop* 1971;77:149.
- Hemborg J, Nilsson B: The natural course of untreated osteoarthritis of the knee. *Clin Orthop* 1977;123:130.
- Henderson RC, Kemp GJ Jr, Greene WB: Adolescent tibia vara: alternatives for operative treatment. *J Bone Joint Surg* 1992;74-A:342.
- Hsu RW, Himeno S, Coventry MB, et al: Normal axial alignment of the lower extremity and load-bearing distribution at the knee. *Clin Orthop* 1990;255:215.
- Kamegaya M, Shinohara Y, Shinada Y: Limb lengthening and correction of angulation deformity: immediate correction by using a unilateral fixator. *J Pediatr Orthop* 1996;16:477.
- Kettlekamp D, Hillberry B, Murrish D, et al: Degenerative arthritis of the knee secondary to fracture malunion. *Clin Orthop* 1988;234:159.
- Merchant TC, Dietz FR: Long-term follow-up after fractures of the tibial and fibular shafts. *J Bone Joint Surg* 1989;71-A:599.
- Métaizeau JP, Wong-Chung J, Bertrand H, et al: Percutaneous epiphysiodesis using transphyseal screws (PETS). *J Pediatr Orthop* 1998;18:363.
- Mielke CH, Stevens PM: Hemiepiphyseal stapling for knee deformities in children younger than 10 years: a preliminary report. *J Pediatr Orthop* 1996;16:423.
- Moreland JR, Bassett LW, Hanker GJ: Radiographic analysis of the axial alignment of the lower extremity. *J Bone Joint Surg* 1987;69-A:745.
- Moseley C: Leg length discrepancy and angular deformity of the lower limbs. In Morrissy RT, Weinstein SL (eds): *Lovell and Winter's Pediatric Orthopaedics*, 4th ed, p 849. Philadelphia, Lippincott-Raven Publishers, 1996.
- Noonan KJ, Price CT, Sproul JT, et al: Acute correction and distraction osteogenesis for the malaligned and shortened lower extremity. *J Pediatr Orthop* 1998;18:178.
- Paley D, Tetsworth K: Mechanical axis deviation of the lower limbs: preoperative planning of multiapical frontal plane angular and bowing deformities of the femur and tibia. *Clin Orthop* 1992;280:65.
- Salenius P, Vankka E: The development of the tibiofemoral angle in children. *J Bone Joint Surg* 1975;57-A:259.
- Scheffer MM, Peterson HA: Opening-wedge osteotomy for angular deformities of long bones in children. *J Bone Joint Surg* 1994;76-A:325.
- Stanitski DF, Srivastava P, Stanitski CL: Correction of proximal tibial deformities in adolescents with the T-Garches external fixator. *J Pediatr Orthop* 1998;18:512.
- Stevens PM, Belle RM: Screw epiphysiodesis for ankle valgus. *J Pediatr Orthop* 1997;17:9.
- Stevens PM, Maguire M, Dales MD, et al: Physeal stapling for idiopathic genu valgum. *J Pediatr Orthop* 1999;19:645.
- Yoshioka Y, Siu D, Cooke TD: The anatomy and functional axes of the femur. *J Bone Joint Surg* 1987;69-A:873.