

Postural Development, 323

Postural Kyphosis, 323

Scheuermann's Kyphosis, 324

Progressive Noninfectious Anterior

Fusion, 336

Postlaminectomy/Postirradiation
Kyphosis, 337

Miscellaneous Causes of Kyphosis, 346

Postural Development

Posture is the relationship of the parts of the body to the vertical line passing through the center of gravity. In practice, the term posture is almost always used to describe spinal relationships, although certain nonpathologic conditions unrelated to the spine (e.g., flatfeet, tibial torsion) could be considered *postural variations*. Posture in the upright or erect position develops from the action of anti-gravity muscles, such as the erector spinae and gluteus maximus, on the axial skeleton of the infant and the toddler.

The spine is held in generalized flexion in the newborn, and the overall flexed position does not change significantly in the prewalking stage. In the sitting infant, the thoracolumbar spine assumes a flexed posture as the axial weight-bearing line of the head (the center of gravity) falls anterior to the axis of rotation of the spine in the sagittal plane. The pelvis and hips are flexed.

As the child begins standing upright, the anti-gravity muscles produce postural spinal curves and the normal sagittal contours of the spine begin to appear. Because the head is anterior to the axis of rotation, a cervical lordosis develops to move the center of gravity posteriorly. Because the hips and pelvis are in a flexed position, the erector spinae muscles must act against these flexed parts to put the lower extremities in a more vertically aligned weightbearing position. The result is an increase in lumbar lordosis. The thoracic portion of the spine remains in a kyphotic position, unchanged from the infantile flexed position.

Postural Kyphosis

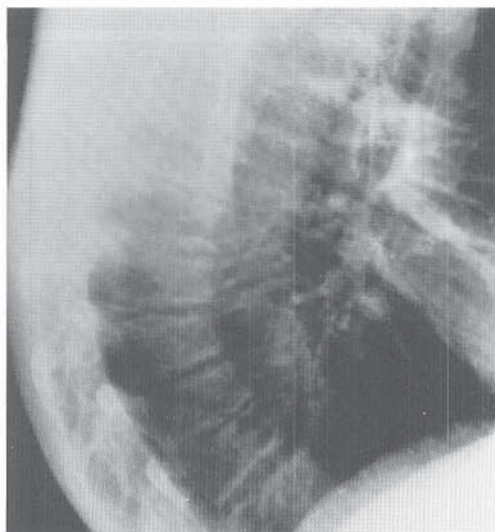
Increased kyphosis, or round-back deformity, in adolescence has been known in the medical literature since the nineteenth century. Before radiography became available, this deformity was believed to be secondary to muscular deficiencies or congenital anomalies. Postural round-back deformity of adolescence is a benign condition that must be distinguished from Scheuermann's deformity. In 1920, Scheuermann identified the radiographic characteristics of

a more specific type of fixed angular kyphosis with anterior wedging of the vertebral bodies and irregularities of the vertebral apophyses (Fig. 12-1A).⁶⁴ When seen with the typical clinical appearance of a sharper angular kyphosis, the condition bears his name, *Scheuermann's kyphosis*. Postural round-back of adolescence (Fig. 12-1B) is associated with none of the findings just described. It is a benign clinical deformity that is correctable by means of passive and active forces.

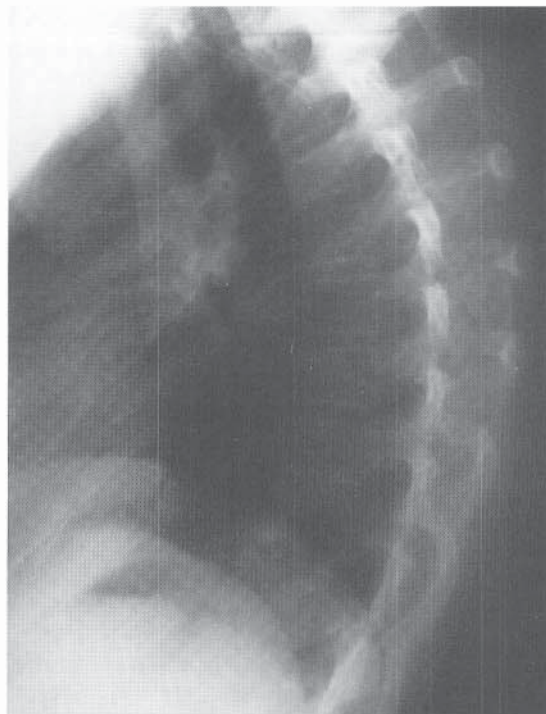
The normal range of thoracic kyphosis is considered to be 20 to 45 degrees (Cobb's angle).²⁶ This range is usually exceeded in both Scheuermann's kyphosis and postural round-back. Patients with postural kyphosis have a more flexible deformity than those with Scheuermann's kyphosis. They can frequently reduce their kyphosis by active contraction of the erector spinae muscles and flatten their lumbar lordosis with the abdominal muscles. In addition, the vertebrae do not exhibit the radiographic changes described for Scheuermann's disease.^{64,70}

In addition to postural round-back and Scheuermann's disease, other conditions that can cause hyperkyphosis include congenital kyphosis, which is diagnosed on the basis of radiographic demonstration of defects in vertebral body formation or segmentation, and the rarer variation, progressive, noninfectious anterior fusion. Other causes of hyperkyphosis that can be identified and distinguished on the basis of the history and physical examination findings include trauma, infection, postlaminectomy and postirradiation conditions, metabolic disease, and skeletal dysplasias (Table 12-1). Because most of these conditions represent serious threats to the patient's overall health and spinal cord function, correct and timely diagnosis is important.

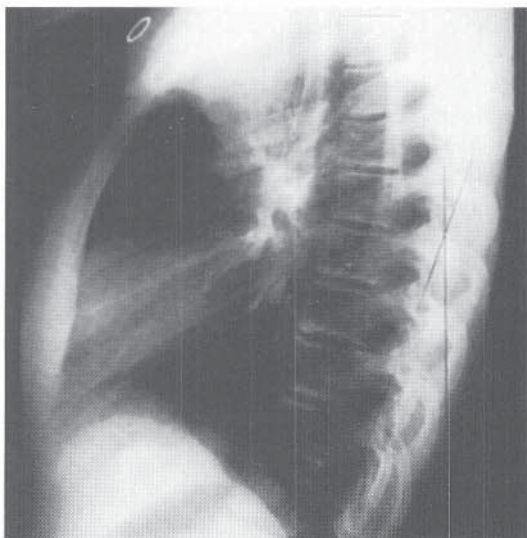
Postural hyperkyphosis usually responds to parent and patient education and nonoperative treatment. A series of muscle strengthening and stretching exercises for the trunk, abdomen, shoulder girdle, and lower extremities may be helpful.^{76,86} Orthotic management can also be used in cases of extreme cosmetic deformity (Fig. 12-1C). Because the natural history and long-term sequelae of postural hyperkyphosis are generally benign, more aggressive treatment (including surgery) is never indicated for this condition.



A



B



C

FIGURE 12-1 A, Thoracic vertebrae in Scheuermann's kyphosis. Note vertebral wedging at the apex, with irregular apophyseal edges. B, Postural kyphosis of adolescence. There is no vertebral wedging or apophyseal changes. C, Because of significant cosmetic concern, this adolescent girl requested treatment. After wearing a Milwaukee brace for 1 year, with an additional year of follow-up, her correction was maintained. This is an unusual method of managing postural kyphosis.

Scheuermann's Kyphosis

This deformity, initially described only for the thoracic spine, can also occur in the thoracolumbar and lumbar spine. Thoracic and thoracolumbar Scheuermann's kyphosis are defined by the location of the apex of the deformity: the apex of the thoracic type is between T7 and T9 and the apex of the thoracolumbar form is between T10 and T12 (Fig. 12-2). Lumbar Scheuermann's disease, characterized primarily by the typical radiographic changes associated with Scheuermann's kyphosis but lacking the clinical deformity because of its location, is discussed separately.

The reported incidence of Scheuermann's kyphosis has ranged from 0.4 percent to as high as 10 percent of adolescents between 10 and 14 years old.⁶¹ There is disagreement as to sex predilection, with some investigators reporting equal male-female prevalences⁷⁰ and others reporting either a male or a female predominance.^{4,12} The condition has its onset in the prepubertal growth spurt, becoming apparent

at around 10 to 12 years of age. Wedging of the apical vertebrae, the sine qua non of the diagnosis, has not been reported in children younger than 10 years.⁴

Originally it was thought that the wedging was due to lack of development of the vertebral ring apophysis in preadolescents and that after ossification, at about age 10 years, the deformity, a trapezoid-shaped wedging, could be seen radiographically (Fig. 12-3; see also Fig. 12-1A). However, the vertebral apophysis does not actually contribute to the longitudinal growth (height) of the vertebral body,⁶ and thus damage to it by vascular or mechanical mechanisms would not cause the characteristic wedging.^{4,61} Disorganized endochondral ossification in the vertebral end-plates, the true site of growth, is consistently found^{4,35} and has been likened to the histopathology of Blount's disease or slipped capital femoral epiphysis.⁶¹ The true cause of the wedging deformity and the reason it does not appear until after 10 years are unknown (see following discussion under Etiology).

The kyphotic apex usually is obvious during the Adams'

TABLE 12-1 Classification of the Causes of Kyphosis

Postural
Scheuermann's disease
Congenital
Failure of formation
Failure of segmentation
Mixed failure
Progressive noninfectious anterior fusion
Traumatic
Structural bone or ligament failure
Secondary to paralysis
Neuromuscular
Myelomeningocele
Developmental (secondary to paralysis)
Congenital
Post laminectomy
Post radiation therapy
Metabolic
Osteoporosis
Osteomalacia
Osteogenesis imperfecta
Skeletal dysplasia
Achondroplasia
Mucopolysaccharidosis
Neurofibromatosis
Collagen disease
Marfan's disease
Neoplastic
Benign
Malignant
Primary
Metastatic
Postinfectious
Bacterial
Fungal
Tuberculosis

forward-bending test and is even more apparent when the patient is viewed from the side during forward bending (Fig. 12-4). In the typical Scheuermann's deformity, which is fairly rigid, the increase in kyphosis is compensated for by an increase in lumbar and cervical lordosis. Only a limited amount of lordosis is possible in the cervical spine, and when the kyphosis exceeds this limit, the patient's head will protrude forward of the thorax (see Fig. 12-9). Anterior shoulder muscle and hamstring contracture and tightness may be present. The patient's inability to actively correct the deformity by "standing at attention" completes the clinical picture. A small scoliosis may accompany the more clinically apparent hyperkyphosis.

In the lumbar form of the condition, patients usually are male and backache typically is the presenting complaint.^{8,29} There usually is no deformity of the lumbar spine. However, the typical radiographic findings seen in the thoracic and thoracolumbar forms are present in the lumbar form as well. They include irregular vertebral end-plates, a reduction in disk height, and anterior vertebral defects (Schmorl's nodes), which can be dramatic (Fig. 12-5). These findings are diagnostic of the condition. The radiographic picture and the invariable complaint of back pain are consistent with a repetitive traumatic etiology. The patients typically are athletic or perform hard labor in a repetitive, overuse manner. Because Schmorl's nodes and the anterior defects are seen

over several segments of the lumbar spine, the association of the lumbar form with overuse syndromes is well accepted.²⁹

ETIOLOGY

Based on the radiographic findings, Scheuermann and other early investigators considered the kyphosis to be a form of osteochondritis. Mechanical, vascular, hormonal, nutritional, traumatic, and metabolic causes have all been proposed over the years; a summary is provided by Robin,⁶¹ to which the reader is referred. Despite significant investigation, however, the etiology of Scheuermann's disease remains unknown. There have been many discrepancies and nonconfirming, controversial findings in studies of histopathologic specimens obtained during operation. Of interest is that no signs of juvenile osteoporosis or other bony metabolic problems have been documented, and the typical disorganized endochondral ossification is probably a result rather than a cause of the condition. The histologic changes are varied and inconsistent and have not provided any insight into the etiology.^{4,61} Thus, the cause of typical thoracic or thoracolumbar Scheuermann's kyphosis remains idiopathic, while a traumatic origin is accepted for the lumbar form.

CLINICAL FEATURES

Patients with Scheuermann's kyphosis may complain of pain around the apex of the kyphosis as well as pain at the cervicothoracic border. Ascani and LaRosa have ascribed these clinical findings to degenerative dermatomal pain produced by loss of mobility of the disrupted facet joints at both the cervicothoracic and the thoracolumbar junctions.⁴ However, Stagnara believed that it was not the ankylosed segments at the junctional areas that were painful, but rather that the pain was generated in the mobile segments immediately adjacent to the ankylosed areas, owing to excessive load and hypermobility.⁷³ Because of the abnormal MRI patterns of signal intensity in the narrowed, irregular disk spaces, pain of discogenic origin has also been proposed.⁴

Although degenerative changes in the form of osteophytes have been noted on radiographs, the area of osteophytic degeneration frequently is mobile rather than ankylosed. Pain in apical areas does not seem to correlate with the magnitude of the kyphosis.⁵¹

Finally, progression of the kyphosis, which might be expected to have a high correlation with increasing symptoms, is poorly related to pain.⁸² Patients in one series had no increase in symptoms with progression. Those with greater deformities chose less strenuous jobs and activities and seemed to have more pain than those with lesser deformities, but the pain did not limit their daily work activities.⁵¹

Late painful sequelae are uncommon in patients with kyphosis of less than 75 degrees, although there may be an increase in the incidence of degenerative disk disease and spondylolysis in the lumbar spine caudal to the kyphotic deformity.⁴⁶ Hyperlordosis caudal to the kyphosis is likely the precursor to these conditions.

Because of the relatively benign natural history of the disease, treatment (nonsurgical or surgical) is not indicated in adolescents except in certain specific situations. The majority of patients have few symptoms and the deformity remains cosmetically acceptable, especially in light of the

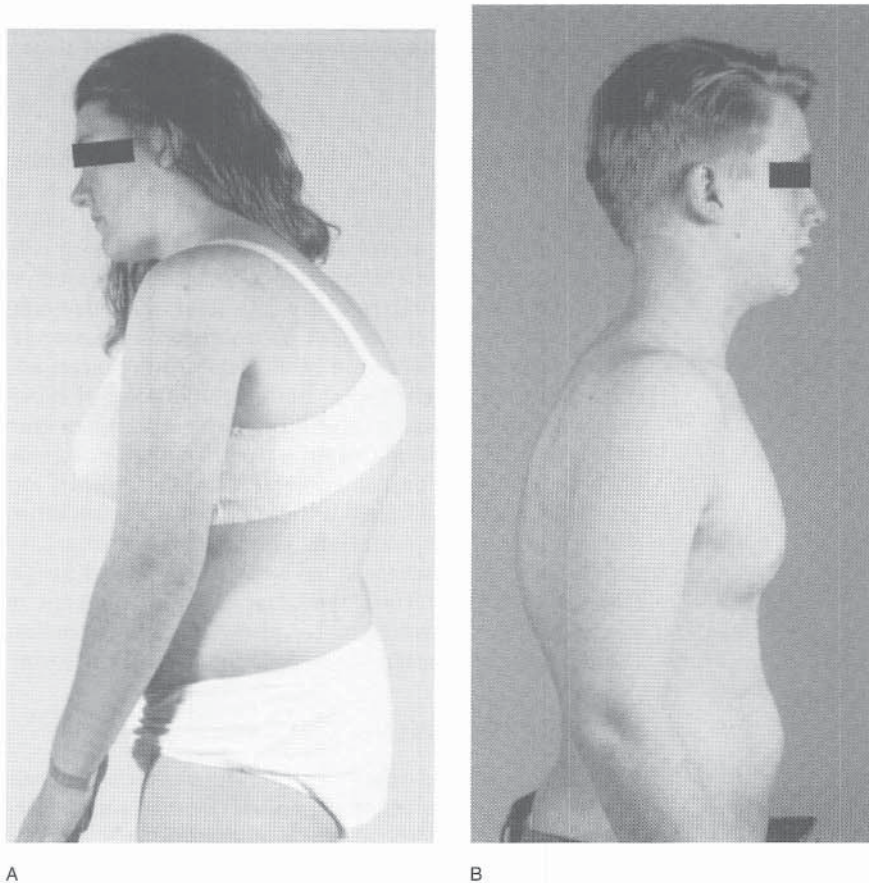


FIGURE 12-2 A, Clinical appearance of Scheuermann's kyphosis with thoracic apex. B, Scheuermann's kyphosis with thoracolumbar apex.

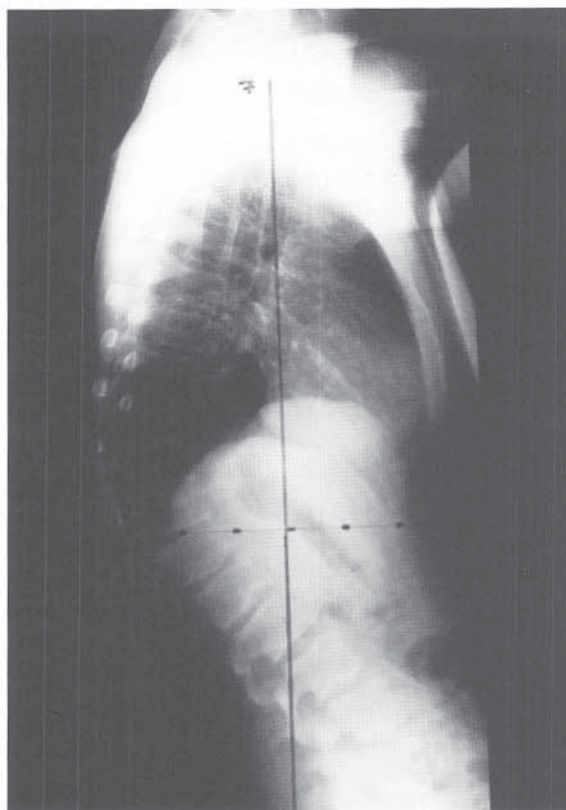
treatment options that exist. Although back pain and fatigue are frequent complaints, they are usually intermittent and mild, disappear with skeletal maturity, and do not affect activities of daily living.⁵¹ Other than an exercise program to counteract the decreased back extensor and abdominal muscle strength,⁵¹ we have generally recommended no active treatment for most patients with Scheuermann's kyphosis. More vigorous treatment is appropriate for those individuals with significant symptoms or progressive deformity, or when the deformity occurs in an immature adolescent. The few long-term follow-up studies examining the natural history of Scheuermann's disease that exist do not show that adult patients are disabled by their condition.^{12,46,51}

RADIOGRAPHIC FINDINGS

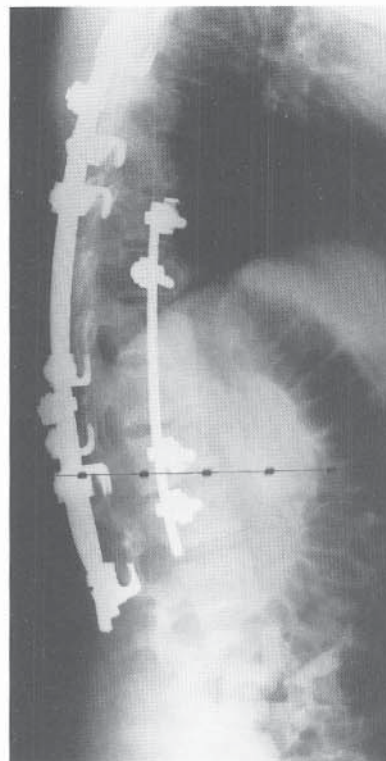
The diagnostic criteria of Sørensen⁷⁰ define the condition: (1) more than 5 degrees of anterior wedging of three consecutive adjacent vertebral bodies at the apex of the kyphosis; (2) irregular vertebral apophyseal lines, combined with flattening and wedging; (3) narrowing of the intervertebral disk spaces; and (4) a variable presence of Schmorl's nodes (Table 12-2; see also Figs. 12-1 and 12-3). In some patients these findings are seen only at the apex of the kyphosis, while in others the findings may be spread throughout the entire extent of the curve. Any evidence of actual bony ankylosis or fusion, especially in the more anterior portion of the disk spaces, changes the diagnosis to a form of congenital kyphosis or progressive noninfectious anterior fusion.

Additionally, patients with Scheuermann's kyphosis who are undergoing surgery (and thus presumably have a greater disruption of their sagittal balance) demonstrate a significant negative sagittal balance on standing radiographs—that is, the C7 plumb line falls more than 2 cm posterior to the sacral promontory (see Fig. 12-3A). Normally the combination of cervical lordosis, thoracic kyphosis, and lumbar lordosis produces a C7 plumb line falling within 2 cm anterior or posterior of the posterior edge of the sacral promontory.⁴⁶ A normal thoracic kyphosis, between 20 and 45 degrees, combines with a normal lumbar lordosis of 40 and 65 degrees (L1–S1) to produce sagittal balance. Patients with significant thoracic hyperkyphosis often have lumbar hyperlordosis. That as much as anything may be responsible for the negative sagittal balance.

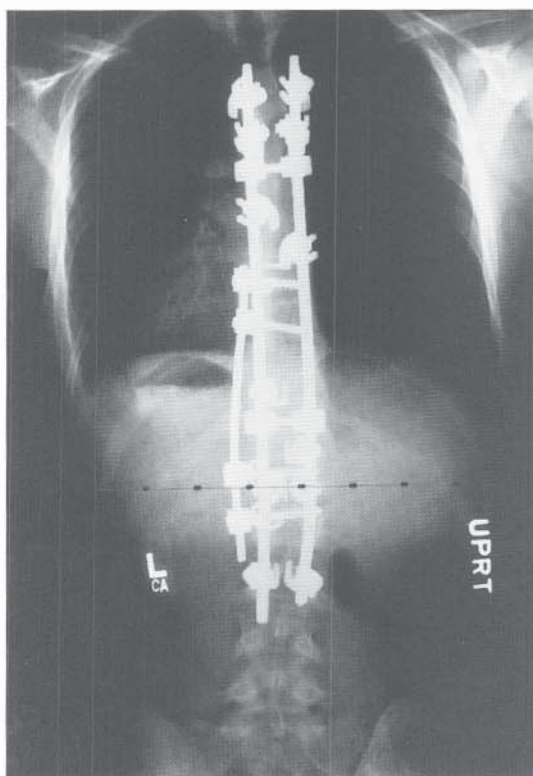
In lumbar Scheuermann's disease, wedging of the vertebral bodies usually is minimal, producing little disturbance in the sagittal plane. Late degenerative changes may result, especially when diskography has demonstrated tears in the annular ligaments of involved lumbar disks.⁴⁶ Spondylolysis at the lumbosacral junction (with or without mild degrees of spondylolisthesis) has been reported to be more prevalent in patients with Scheuermann's disease than in the normal population,¹⁹ although the Iowa long-term study disputes this commonly accepted finding.⁵¹ The possibility of spondylolysis must be considered when a patient with Scheuermann's kyphosis complains of low back pain. Although hyperlordosis itself is considered a cause of low back pain in Scheuermann's kyphosis, other causes, such as discogenic and spondylytic pain, must be ruled out.



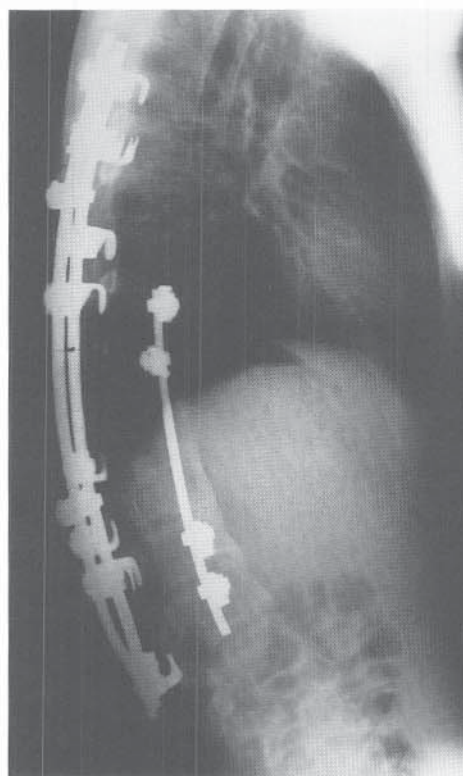
A



B



C



D

FIGURE 12-3 A, Trapezoid-shaped vertebral bodies at the thoracolumbar junction (apex at T10). This patient also had a posteriorly displaced sagittal balance. B, One year later the deformity had progressed to 70 degrees. The patient underwent anterior spinal fusion with distraction instrumentation, followed by posterior instrumentation with a compression construct. Immediate correction was to 30 degrees. C, Coronal radiograph of the spinal construct. D, At 2 years' follow-up the correction was maintained, with evidence of a solid anterior arthrodesis. No postoperative immobilization was necessary.

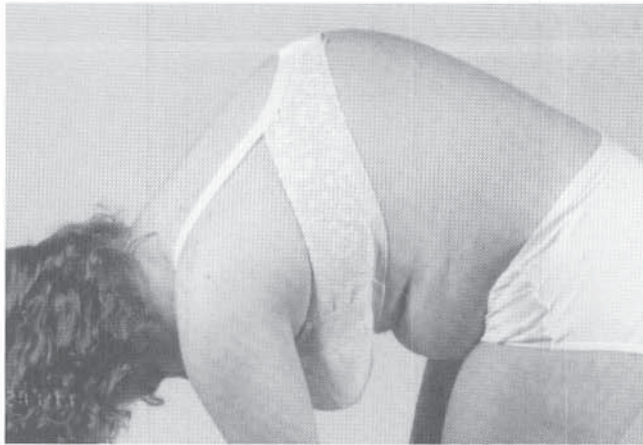


FIGURE 12-4 A sharply angled apical kyphosis is easily appreciated on forward bending.

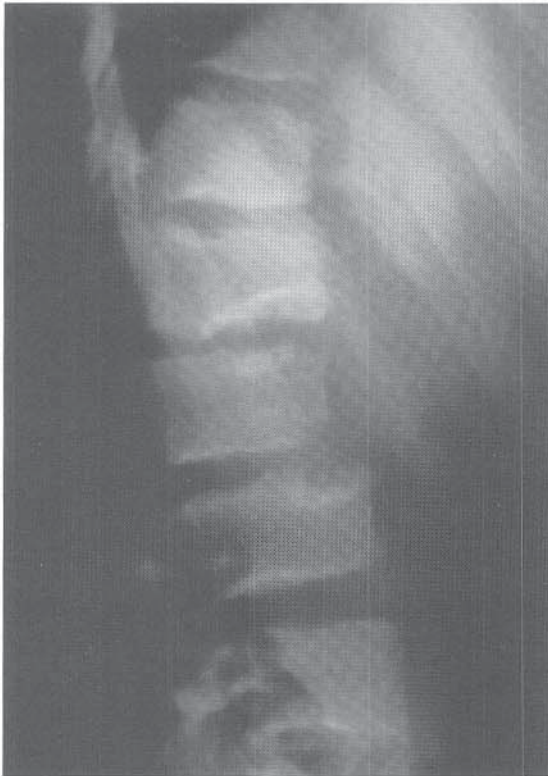

FIGURE 12-5 Lumbar Scheuermann's disease. Radiograph demonstrates prominent Schmorl's nodes and end-plate irregularities without deformity.

TABLE 12-2 Radiographic Features of Scheuermann's Kyphosis

- More than 5 degrees of anterior wedging of three consecutive adjacent vertebral bodies in the apex of the kyphosis
- Irregular vertebral apophyseal lines combined with flattening and wedging
- Narrowing of the intervertebral disk spaces
- Schmorl's nodes variably present

NONOPERATIVE TREATMENT

Indications for nonoperative treatment include relative skeletal immaturity (Risser 2 or less) and a deformity that is already cosmetically or functionally unacceptable (usually greater than 60 degrees) and is known to be progressive. Some authors believe that virtually any Scheuermann's deformity can be managed nonoperatively in the skeletally immature patient.⁷¹ The goal of nonoperative management is twofold: to control the deformity, and to attempt to reconstitute the anterior vertebral height by applying hyperextension forces (by means of a brace, for example). Without evidence of such reconstitution, loss of correction following discontinuance of brace therapy is almost assured.

Brace Therapy. For a thoracic apex, the Milwaukee brace is recommended,¹² as it is the only orthosis that can effectively apply three-point corrective forces to a midthoracic apical vertebra (Fig. 12-6). The brace should also decrease the lumbar lordosis and help correct the negative sagittal balance. For a thoracolumbar deformity, a thoracolumbar-sacral orthosis (TLSO) can be tried, usually supplemented with anterior sternal or infraclavicular outriggers to provide an extension moment cephalad to the apex.⁸⁶ With a decrease in lumbar lordosis, the patient is encouraged to actively hyperextend the spine to maintain the head in a more upright position. An advantageous feature of the Milwaukee brace that is not available with the TLSO is the ability to progressively bend more correction into the posterior kyphosis pads over time.

Initially, bracing should be prescribed on a full-time basis, with the patient allowed to remove the brace 1 to 2 hours per day in order to perform exercises. Radiographs should be obtained every 3 to 4 months, with progressive correction bent into the posterior kyphosis pads as tolerated. Brace treatment should continue until skeletal maturity is achieved, which for boys may require that they wear the orthosis until Risser 5. Although a weaning period from brace wear is usually recommended, there is no statistical evidence that a particular weaning schedule is more efficacious than another.

The results of orthotic management of Scheuermann's disease show that the deformity can be effectively improved during brace wear; however, when brace wear is terminated, a loss of correction occurs.^{50,63} In a series reported by Sachs and associates, larger deformities (more than 74 degrees) at the start of treatment showed the most significant loss of correction after brace discontinuance, with the result that there was little overall correction.⁶³ This finding suggests that orthotic management is perhaps not indicated for a deformity of large magnitude without some prior correction of the deformity—by casting, for example. Although smaller deformities can be maintained at a smaller magnitude with orthotic treatment, greater deformities need greater initial correction in order to be stabilized, thus requiring a more aggressive treatment approach.

At Texas Scottish Rite Hospital for Children, brace treatment is used relatively infrequently because of the generally benign nature of the deformity in adolescents. For immature patients, the Milwaukee brace is used most frequently, regardless of the curve pattern, as we have found the use of a TLSO less effective.

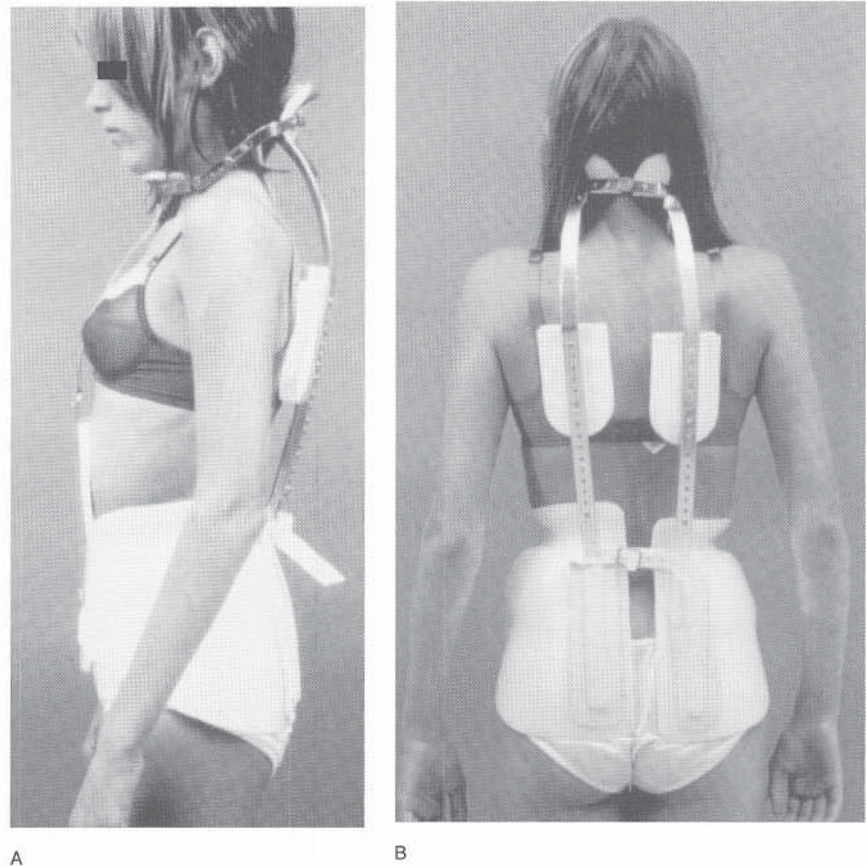


FIGURE 12-6 A and B, Milwaukee brace treatment for hyperkyphosis. The posterior pads can be progressively bent into more correction.

Cast Treatment. When passive correction is less than 40 percent, as determined from a hyperextension lateral radiograph, brace treatment is not likely to be effective. Following the methods of Stagnara⁷³ and Ponte et al.,⁵⁶ antigavity or localizer casts can be applied in serial fashion to produce more correction of the kyphosis (Fig. 12-7). This treatment regimen, used extensively in Europe, entails applying two or three casts (changed every 2 to 3 months) in an attempt to progressively correct the deformity. Following the 6- to 9-month period of casting, the patient is then treated with a Milwaukee brace or other type of retention brace to maintain the correction during the remainder of the growth. With such a regimen, not only is the deformity improved by as much as 40 percent, but there is less loss of correction. In a 2-year follow-up French study,⁴⁹ the loss of correction averaged just 7 degrees, while in a 3-year follow-up series reported by Ponte and associates, only 4 degrees of correction was lost.⁵⁶

The European experience with cast treatment has led to the following observations: (1) The long-term goal of controlling the deformity so that the curve ultimately ends up in a physiologic range (less than 50 degrees) is achievable. (2) The later treatment is begun, the lower is the probability of reconstituting the anterior vertebral height and maintaining any significant angular correction. (3) For patients presenting for treatment postpubertally, with little growth remaining, nonoperative treatment cannot correct vertebral wedging and so probably should not be attempted. In such cases it may be preferable to correct the deformity operatively, if indeed treatment is indicated.²⁴

The use of cast treatment in an adolescent rests largely on the patient's desire to achieve maximum correction without resorting to surgery. Because of the prolonged and relatively inconvenient treatment period (exceeding a year, with 6 to 9 months in casts and a minimum of 6 additional months in a brace), such therapy will never succeed without the total compliance and desire of the adolescent.

OPERATIVE TREATMENT

Indications. Surgical treatment of Scheuermann's kyphosis is reserved for patients with pain, a rigid deformity, a curve of more than 70 to 75 degrees, and an unacceptable cosmetic appearance. Although some have advocated surgical correction for a kyphotic deformity of as little as 50 degrees,^{13,24} the benign natural history and the lack of symptoms in patients with 60 degrees of kyphosis strongly argue against "prophylactic" surgery. If the deformity is painful, nonoperative pain management (e.g., general fitness, extension, shoulder, and hamstring stretching exercises) probably should be attempted for a minimum of 6 months before resorting to surgery. Patients with complaints about cosmesis but a nonprogressive deformity should be referred for psychological consultation before the physician acquiesces to surgical management. Although operative treatment may be appropriate for a patient with significant body image concerns, it is clearly inappropriate for a patient whose postural "problem" is exacerbated by depression, anxiety, and low self-esteem.

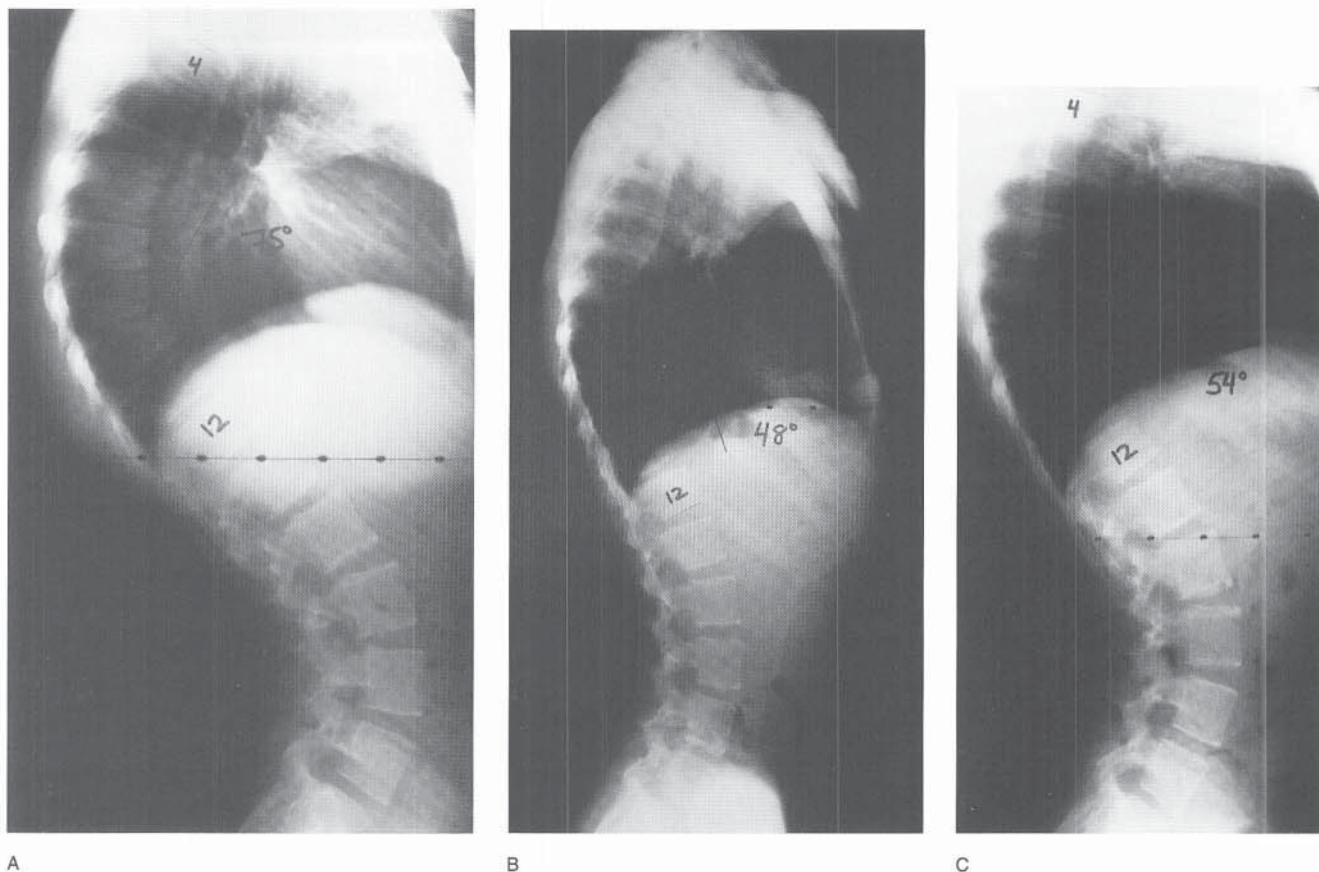


FIGURE 12-7 A, A 16-year-old boy with Scheuermann's kyphosis measuring 75 degrees and significant cosmetic concern. B, After 6 months of serial Risser casting, the deformity was reduced to 48 degrees. C, At age 18, the kyphosis measured 54 degrees. The patient wore a Milwaukee brace part-time for 1 year following cast correction.

Surgical Goal. The goal of surgical correction of kyphosis is to achieve a stable, balanced spine in the sagittal plane by obtaining solid arthrodesis without neurologic complications. The degree of curve reduction should be planned relative to the patient's overall sagittal balance. The deformity may require more or less reduction in the magnitude of the curve to achieve balance for the individual patient. According to Lowe, a kyphosis should never be reduced more than 50 percent of the preoperative deformity, both to prevent neurologic complications and to avoid junctional kyphoses at the ends of the fusion.⁴⁶ Historically, the biomechanical principles of kyphosis correction have included elongating the anterior column of the spine, providing some form of anterior column support, and shortening the posterior column of the spine (Fig. 12-8). Because of the first two principles, the use of an anterior release and fusion has been accepted as part of a standard two-stage corrective procedure. However, the need for the anterior procedure can be questioned when adequate correction and fusion are achievable by a posterior procedure alone.

Surgical Approach. Ferreira-Alves and associates studied patients treated with posterior fusion for Scheuermann's kyphosis. They found a gradual postoperative *improvement* in kyphosis in patients under 16 years of age that they attributed to remodeling of the anterior vertebral wedging.²⁴ If the patient is skeletally immature (less than Risser 3) and

has some anterior growth potential remaining, and if the kyphosis corrects to less than 50 degrees on a hyperextension lateral radiograph, then an instrumented posterior fusion alone may be sufficient.^{24,46,71} Patients who are mature and have no anterior growth potential will presumably suffer loss of correction following a posterior procedure alone, similar to that seen in a mature patient who has been treated nonoperatively with brace therapy after discontinuation of the brace. Bradford and associates observed an unacceptable loss of correction in patients who had been treated by posterior instrumentation and fusion alone,¹³ and in a second study published 5 years later, the same authors recommended anterior and posterior fusion, maintained by posterior instrumentation, to prevent such loss of correction postoperatively.¹⁰ On the basis of these two studies, the accepted standard of operative care for Scheuermann's kyphosis is an anterior release and fusion, followed by posterior instrumentation and fusion to achieve the previously elucidated biomechanical principles.

Interestingly, a close reading of the two reports by Bradford and associates shows little actual difference in the outcomes of the two sets of patients. The 1975 report of posterior fusion, concerned primarily with postoperative loss of correction, reported an average preoperative kyphosis of 72 degrees, with a final correction of 47 degrees.¹³ In the 1980 report the same surgeons used the two-stage approach to treat patients with an average preoperative kyphosis of 77

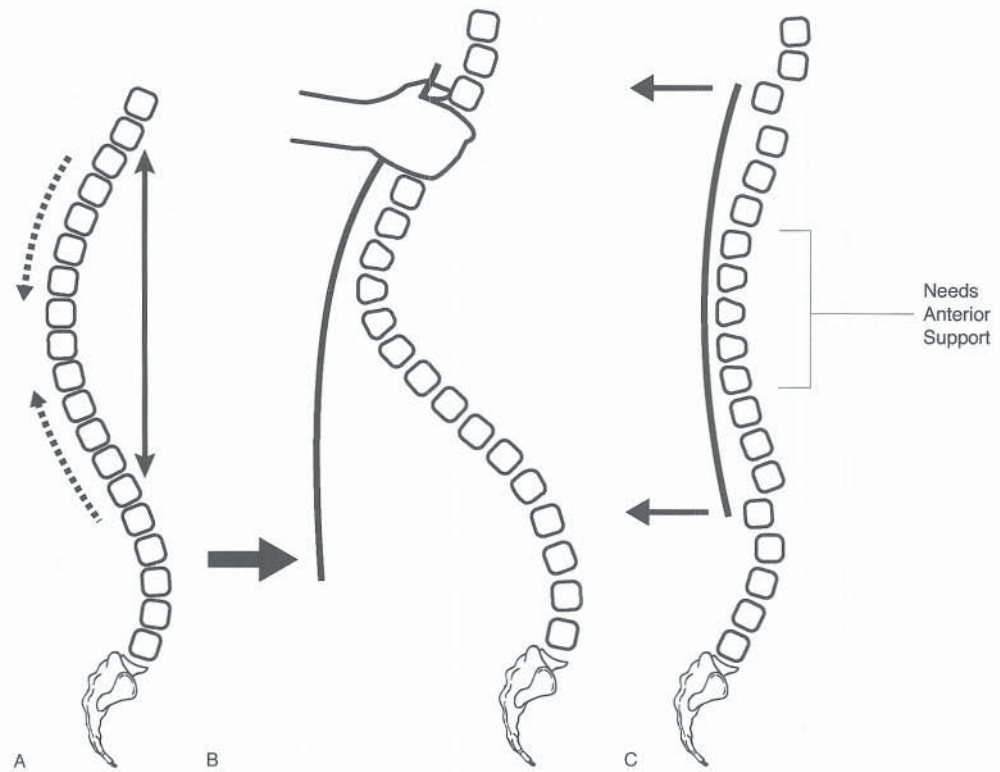


FIGURE 12-8 A, Anterior elongation and posterior shortening to correct kyphosis. B, Kyphosis correction by three-point cantilever technique. C, Anterior translation of the kyphotic apex produces opening of the disk spaces and a need for anterior column grafting or support with instrumentation. Junctional kyphosis at the ends of the construct can result from the posteriorly directed forces in concert with instrumentation that is shorter than the entire deformity.

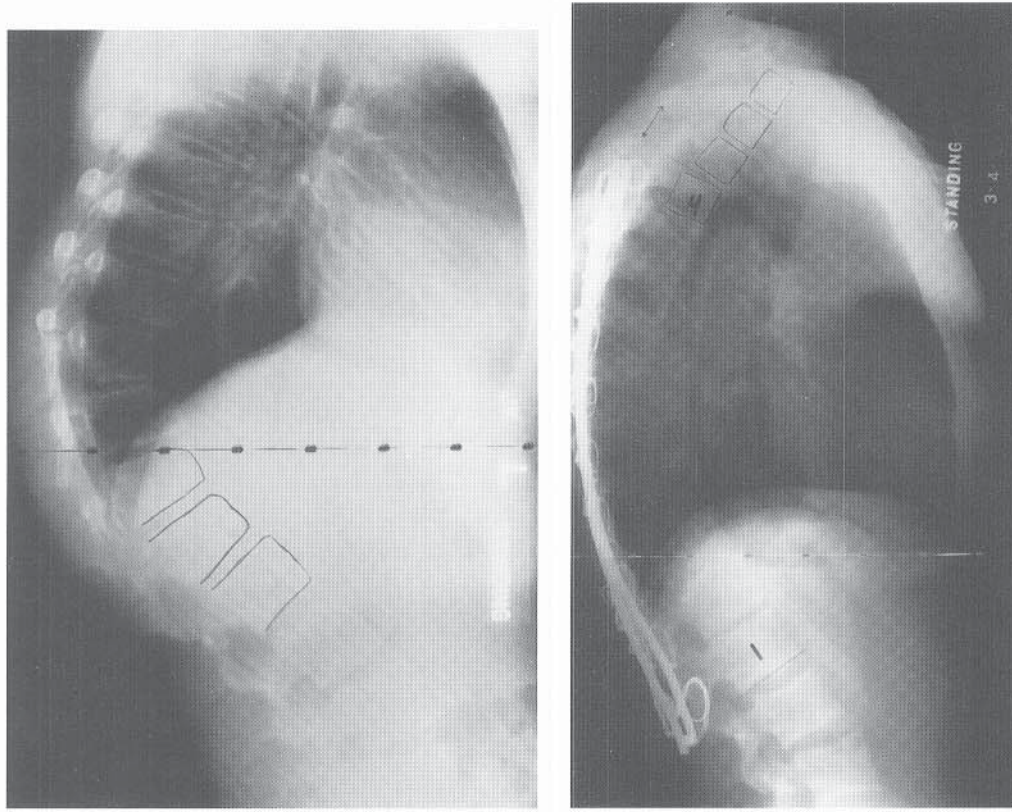
degrees, and the final average correction was also 47 degrees.¹⁰ In 1979, Taylor and associates reported an average correction from 72 degrees preoperatively to 46 degrees at follow-up using the same Harrington compression instrumentation posteriorly with no anterior release.⁸⁰ Other investigators,^{57,71,75} using the same Harrington compression instrumentation (two studies used a larger diameter $\frac{3}{16}$ -inch rod^{57,75}), achieved up to 59 percent correction with as little as 3 degrees' average loss of correction with the one-stage technique for placing posterior instrumentation only. Thus, there appears to be little justification for a routine anterior release, either to increase correction or to decrease postoperative loss of correction. The original concerns regarding a postoperative loss of correction exceeding 5 degrees were probably related more to the flexible internal fixation device (Harrington $\frac{1}{8}$ -inch compression rod) than to the lack of anterior release and column support. With the use of stiffer posterior instrumentation constructs, adequate correction can be obtained and maintained in many cases by posterior surgery alone, thus saving the patient the additional morbidity of an anterior procedure (whether performed on the same day or staged).

Preoperative Evaluation. The patient who has kyphosis should be evaluated for neurologic abnormalities, causes of pain (if present), and pulmonary function. Patients with Scheuermann's kyphosis may rarely present with signs of spastic paraparesis due to anterior cord compression, thoracic disk herniation, or syrinx. Thus, a careful neurologic evaluation is mandatory. Patients with significant pain should be evaluated by imaging studies in certain cases. Patients with atypical pain that is not mechanical in nature, such as night pain or dysesthetic pain, should undergo MRI to exclude intradural abnormalities (e.g., syrinx). Discogenic

sources of pain should be ruled out in patients who have significant radiculopathy, low back pain that is not easily controlled by standard nonsurgical measures, or a history of sciatica or extremely tight hamstrings. The presence or absence of spondylolytic defects should be confirmed, and the flexibility of the kyphotic curve and the presence of any scoliosis must also be determined. A precarious preoperative respiratory status is rare except in the most severe and neglected cases of kyphosis (more than 100 degrees).⁵¹ Only in such a patient would the choice of surgical approach (anterior and posterior versus posterior alone) be modified or dictated by the preoperative pulmonary status.

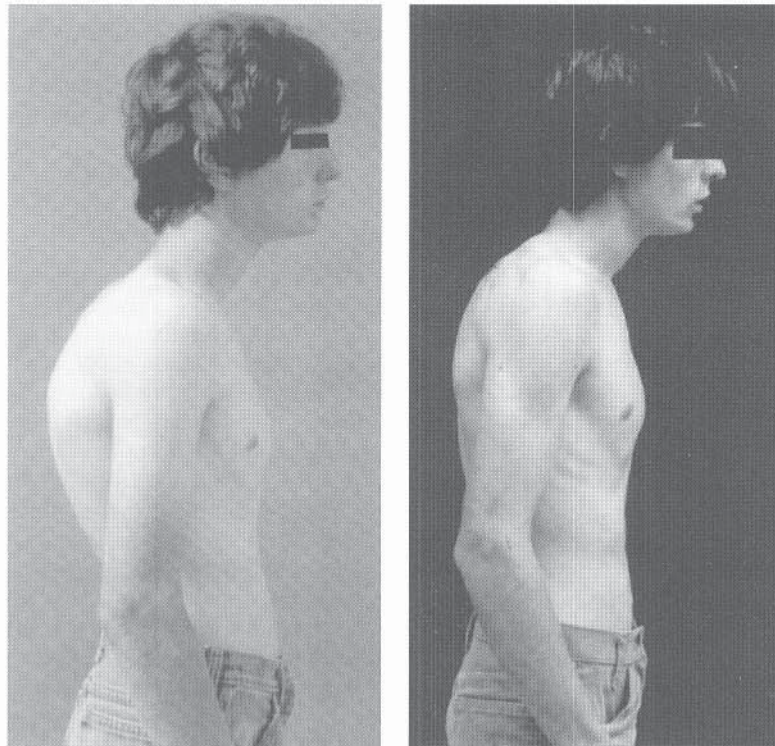
Determining Fusion Levels. Fusion levels are determined from the standing lateral radiograph. The upper limit of fusion must include the most proximal vertebra that is tilted into the kyphosis. This generally means fusion to T2, especially in patients less than 15 years old.²² If the fusion stops short of this level, there is a risk that a postoperative junctional kyphosis will develop at the upper end of the instrumentation (Fig. 12-9). Similarly, the caudal extent of the fusion should include the first lordotic disk space, which commonly includes one level distal to the measured end vertebra of the kyphosis. Failure to extend into the lumbar lordosis similarly risks a caudal junctional kyphosis.²² As the apex of the kyphosis is displaced ventrally by deformity correction, the C7-sagittal axis moves ventrally to produce a kyphotic moment at any lumbar level not already in lordosis. If the caudal extent of fusion does not include all nonlordotic segments, a junctional kyphosis can result.

In rigid kyphoses of large magnitude (especially in skeletally mature individuals), an anterior release and fusion of the apical portion of the deformity *may* be advisable to increase the correctability by the posterior instrumentation.



A

B



C

D

FIGURE 12-9 A, Preoperative lateral radiograph of a 16-year-old boy with a 70-degree kyphosis and midthoracic pain. B, Postoperative radiograph subsequent to anterior release and fusion and posterior instrumentation/fusion with Luque SSI instrumentation. Junctional kyphosis at T4 is noted from the widening of the spinous processes. C, Preoperative clinical appearance. Note anterior protrusion of the neck and chin. D, Postoperative appearance. The thoracic kyphosis is improved, but the chin and neck still protrude owing to the high junctional kyphosis.

This allows the surgeon to balance the spine more harmoniously and probably improve the rate of fusion.⁷¹ It could be argued that larger deformities not adequately corrected by posterior instrumentation alone went on to pseudarthrosis because the fusion mass was under tension rather than compression, a situation that is biomechanically detrimental to achieving solid fusion. Thus, anterior release and fusion *may* be indicated in such a rigid deformity, although experience with the $\frac{3}{16}$ -inch compression rod systems^{57,75} has not confirmed this indication.

ANTERIOR RELEASE AND FUSION TECHNIQUE

If an anterior release and fusion procedure is elected, it is usually performed as the first stage of a two-stage approach, with both stages usually performed on the same day, because the complication rate and morbidity are lower than if the staged procedures are performed 10 to 14 days apart. The release should include the rigid apical segments (as determined on a hyperextension lateral radiograph) and can encompass essentially the entire thoracic spine if necessary. The release is performed through a right-sided thoracotomy or thoracoscopically, unless the patient has a left convex scoliosis of sufficient magnitude that a left-sided release is indicated to approach the convexity of the scoliosis. The right side is generally more approachable because the cardiac structures and great vessels fall to the left of the spine.

THORACOTOMY APPROACH

The transthoracic approach should parallel the rib leading to the most cephalad segment to be released and fused. For example, a fifth rib thoracotomy would be used to reach the T5–6 disk space, if the latter was the most cephalad extent of the rigid segment requiring anterior release and fusion. If multiple segments are to be released caudally down to T12, the surgeon may wish to select a more distally located incision site so as to be able to reach both the most cephalad and the most caudal segments through one incision. The chest wall in patients with rigid Scheuermann's kyphosis can be inflexible, and in such a situation it may not be possible to perform a discectomy at T11–12 through a fifth rib thoracotomy. Although two parallel thoracotomies may be performed, the upper and lower levels can also be approached through the same incision by centering the incision more distally and then tunneling either proximally or distally in the subcutaneous plane to reach the appropriate rib at either end of the thoracic spine.

Once the chest has been entered, the pleura over the spine is opened longitudinally and a flap is created by posterior dissection to expose the costovertebral joints. Segmental vessels are preserved if only an anterior release and fusion procedure is being performed. If anterior instrumentation is to be used or if preserving the vessels does not allow adequate exposure of the upper and lower disks, it is recommended that vessels in the so-called watershed area of the midthoracic space (T4–9) be ligated and divided only after they have been temporarily occluded for 20 minutes, and somatosensory-evoked potential (SSEP) and motor-evoked potential (MEP) monitoring shows no signal degradation from ischemia. Ligation of these vessels can result in paraplegia due to cord ischemia, known as anterior spinal artery

syndrome.^{2,30} This clinical recommendation is based on experimental⁴¹ and clinical² evidence of a delay in degradation of SSEPs of up to 20 minutes following anterior spinal artery occlusion. The segmental vessels can be temporarily occluded with rubber vessel loops, which can also be used for retraction during the discectomy and fusion.

The costovertebral joints should be exposed and the rib heads resected to increase mobility of the spine and to increase visualization of the posterior disk space. The contents of the disk space should be evacuated, with ronguers used to remove the nucleus pulposus and curets or elevators used to dissect the vertebral apophysis off the end-plates. Resection should include division of the anterior longitudinal ligament and proceed posteriorly to the annulus guarding the posterior longitudinal ligament. By using spreaders and by manually extending the spine via pressure applied over the back, the surgeon can open up the disks sufficiently to allow rapid evacuation and release. The rib that has been resected for the thoracotomy approach is morcellized and used as the interbody bone graft. The pleura is then closed with running suture to achieve hemostasis and to maintain the rib graft in the interbody spaces.

Enhancement of the anterior fusion process by creating an osteoperiosteal flap has been described.⁴³¹ This can be accomplished following the discectomy but before the spinal pleura is closed. The flap should be created in a lateral to anterior direction, using an osteotome or other suitable elevator. This provides a bed for a solid anterior column of bone to develop in the apical portion of the kyphosis. Biomechanically, this column of bone is best able to resist compression forces and recurrent kyphosis, and thus is recommended whenever significant residual kyphosis may remain. In Scheuermann's disease, modern posterior instrumentation is quite capable of sufficiently correcting a kyphosis, but the need for anterior column grafting arises if the disk space opens and an anterior defect is created (see discussion under Posterior Instrumentation and Fusion, later in this chapter, and Fig. 12–8C). In severe cases of non-Scheuermann's kyphosis, such anterior grafting is a crucial part of obtaining a solid arthrodesis.

Anterior instrumentation to correct kyphosis primarily by distraction has been used in Scheuermann's disease as an adjunct to achieve correction as well as to provide support and prevent loss of correction resulting from anterior "settling" following discectomy. An example of solid anterior rod instrumentation for Scheuermann's kyphosis is shown in Figure 12–3. The routine use of anterior release and fusion may not be necessary. Should an anterior release and fusion technique be selected, anterior instrumentation can be used to maintain the correction and to supplement the interbody fusion. The details of anterior instrumentation for kyphosis are described in the section on non-Scheuermann's kyphoses.

THORACOSCOPIC ANTERIOR RELEASE AND FUSION

Following the success of video-assisted thoracic surgery (VATS) for intrathoracic procedures, Mack and associates in 1993 reported the application of this new endoscopic technique to spinal surgery.⁴⁷ With recent improvements in video technology and instrumentation and greater operator

skill, this technique can now be considered a feasible alternative to open thoracotomy procedures. There are both functional and cosmetic advantages to VATS techniques. Functionally, there is less incisional pain and less chest wall and shoulder girdle dysfunction, which hypothetically leads to a faster recovery, fewer postoperative respiratory complications in susceptible patients, and shorter hospitalization and rehabilitation times. Cosmetically, the VATS technique requires only stab wounds, whereas standard thoracotomy requires longer incisions. Few complications were reported in an early series that combined the experiences at three separate centers.⁴⁸

Anterior thoracoscopic discectomy and fusion has been reported as part of the two-stage treatment of Scheuermann's kyphosis.^{48,53} Using three to four portals, the operator removes the apical five to six disks, with or without segmental vessel ligation. Morcellized rib or other bone graft is inserted after curetting the vertebral end-plates. Clinical series⁵³ and animal studies^{34,52} have demonstrated that the anterior release technique (i.e., mobilizing the spine to improve correction by posterior instrumentation) results in a correction similar to that achieved by thoracotomy.

To date, no clinical studies are available to document the quality and incidence of thoracoscopic anterior arthrodesis. Animal studies suggest that meticulousness of end-plate removal and grafting technique are comparable between open and thoracoscopic techniques. In clinical practice, the actual rate of anterior fusion is confounded by the presence of posterior fusion, which always accompanies it. More important, in the only pediatric deformity series to date, the hypothetical advantages of the less invasive endoscopic procedure were not realized.⁵³ Recovery times (i.e., shorter hospitalization) were not reduced, and blood loss, volume of chest tube drainage, and operative time were actually greater in the thoracoscopic group than in a group of patients treated by open thoracotomy. Although overall recovery and other postoperative parameters clearly depend on the extent of the posterior procedure as well, at this time it is premature to state that a thoracoscopic release and fusion procedure for Scheuermann's kyphosis is a replacement for the traditional open thoracotomy. However, the thoracoscopic technique certainly warrants continued study as an alternative procedure.

POSTERIOR INSTRUMENTATION AND FUSION

Posterior instrumentation and fusion is normally performed immediately after the anterior procedure in a two-stage approach. The patient is placed on a standard four-poster spinal frame, with the abdomen free and the hips flexed to decrease lumbar lordosis. Because exposure of the upper thoracic segments will be necessary, the patient's head is slightly flexed to facilitate access to T1 if necessary. The spine is exposed through a standard midline incision in the subperiosteal plane out to the tips of the transverse process, at which point instrumentation is inserted for the particular procedure, based on the individual preference of the surgeon.

In the past, Luque instrumentation (segmental sublaminar wiring) was used to treat Scheuermann's kyphosis.⁴⁵ However, because of problems with junctional kyphosis and a perceived or actual increase in neurologic risk, the use of

Luque instrumentation is now relatively obsolete. When a three-point cantilever mechanism of correction has been used, an increase in the incidence of junctional kyphosis (particularly at the cephalad end of the instrumentation) has been noted. The increased incidence of junctional kyphosis is probably related to removal of the interspinous ligaments and ligamentum flavum at the uppermost segment, where a sublaminar wire must be passed. The ensuing posterior displacement of this most cephalad segment by the cantilever maneuver (Figs. 12-8 B and C), combined with destabilization for laminotomy and ligament removal, promotes development of a junctional kyphosis between the uppermost wired segment and the next, unwired one (Fig. 12-9). In relatively immature patients, upper junctional problems have been observed over time that may have been related to "adding on" postoperatively due to growth.²² The results are chin protrusion and pain at the cervicothoracic junction (Fig. 12-9).

When the cantilever maneuver is used, there is always the possibility that the operator will push a sublaminar wire anteriorly into the canal as a rod is pushed anteriorly against the spine. This risk, of course, is not limited to sublaminar wiring procedures. It is present whenever an implant is placed in the canal via laminotomy at a level where anteriorly directed force is applied. Neurologic injury has been reported in as many as 2 percent of procedures for inserting Luque rods for kyphosis.⁴⁶ For all of these reasons, Luque instrumentation has gradually been replaced by other instrumentation constructs.

Recently, multisegment hook-rod systems (Cotrel-Dubousset, TSRH, and Isola) have been used to correct posterior kyphosis. These systems, which allow segmental fixation with hooks or screws, can increase stability during a cantilever maneuver by taking advantage of the ability to "claw" adjacent laminae. Compression can be achieved between segments as well, and with the recent popularity of using pedicle screw fixation in the upper lumbar segments, the risk of laminar failure and instrumentation pullout is significantly reduced.

The typical construct includes two or three pairs of pedicle hook-transverse process claws cephalad to the apex of the kyphosis, and paired hooks or pedicle screws caudad to the apex of the kyphosis (Fig. 12-10).⁴⁶ As was implied in the discussion of Luque instrumentation, implants should *not* be placed in the canal via a laminotomy near the apex of the kyphosis because of the risk that these implants may protrude anteriorly during the corrective cantilever maneuver. The rod pushes against the lamina to correct the kyphosis. The caudal spine anchors (hooks or screws) capture the distal end of the rod in segmental fashion as the rod is pushed down (cantilevered) into them by corkscrews or other rod-moving instruments. An "open" implant instrumentation system makes these maneuvers simple, eliminating the awkward technique in a "closed"-hook system of seating a hook under the inferior edge of a caudal lamina while fixed to the rod.

Because the multisegmental hook-rod systems do not involve implants in the canal near the apex, the risk of neurologic complications is considered less than with sublaminar wiring. Nevertheless, because of the powerful correction that can be achieved by such systems, neurologic complications have been reported,¹⁴ most commonly follow-

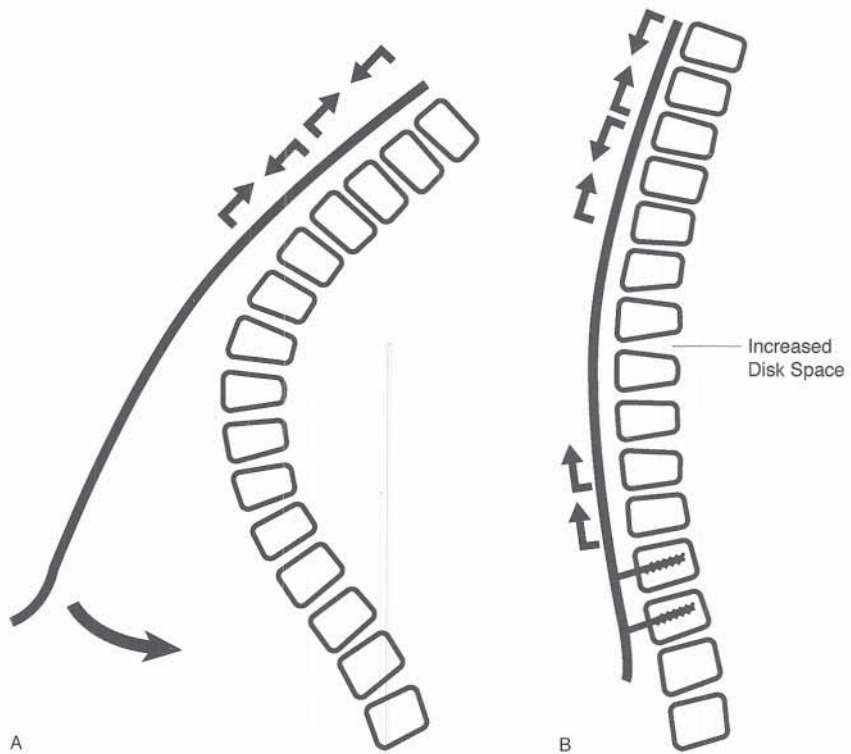


FIGURE 12-10 A and B, Correction of kyphosis by the cantilever technique using multiple sets of “claws” between pedicle and transverse process hooks. No implants are placed in the canal over the apex. Caudal fixation by paired sets of pedicle screws is most stable. Note the opening of disk spaces anteriorly resulting from preliminary anterior release.

ing an anterior release with segmental vessel ligation in a hyperkyphotic deformity. It has been proposed that a spinal cord made slightly ischemic by multiple anterior vessel ligations could then be further embarrassed by stretching (elongation) of the anterior cord during cantilever correction.¹⁴ For this reason, vessel ligation anteriorly should be avoided when possible, and neurologic monitoring with SSEPs or preferably MEPs should be carried out during the corrective maneuvers of the posterior procedure.

The original instrumentation used for kyphosis correction—the Harrington compression rod system^{13,32,71,80}—has regained popularity in a modified form for correcting kyphosis. The original Harrington compression instrumentation was effective in obtaining correction but, as emphasized in a 1975 report by Bradford et al.,¹³ there was an unacceptable loss of correction. Other complications of or drawbacks to the compression rod system included rod fracture, caudal hook pullout, and the need for postoperative immobilization due to the lack of stiffness and fatigue susceptibility of the small-diameter, $\frac{1}{8}$ -inch rod. Because it was a closed-hook system, it also was awkward to use, and intraoperative assembly was difficult. Tightening compression nuts along a threaded rod can be tedious, with a high “fiddle factor.” However, the fact remains: moving a nut along a threaded rod is mechanically superior to any extrinsically applied compression or distraction force, as a maximal mechanical advantage can be generated in a slow, measured application.

Reports by Sturm and associates⁷⁵ and Ponte and Siccardi⁵⁷ have described a more robust $\frac{3}{16}$ -inch compression rod system that achieves the best published correction of Scheuermann’s kyphosis. Such an approach is all the more attractive because it requires only a posterior procedure, saving the patient the morbidity of the anterior procedure. By utilizing a larger diameter compression rod ($\frac{3}{16}$ inch versus

$\frac{1}{8}$ inch), the two series reported improved maintenance of correction, with minimal mechanical failures or rod fractures.^{57,75} Based on these results, we have returned to a threaded $\frac{3}{16}$ -inch (4.8-mm) rod system using open hooks and screws.³⁷ Because the threads have been modified to make the pitch wider, the nuts can be moved more efficiently along the rod to achieve corrective compression more rapidly. A $\frac{3}{16}$ -inch rod is flexible enough that it can be implanted even in a severe kyphosis without contouring with a rod bender. Yet it is sufficiently stiff to provide adequate internal fixation following correction of the kyphosis and avoid postoperative immobilization for most patients.

The posterior procedure for correcting kyphosis involves creating space between adjacent laminae, which can then be closed during a cantilever or compression maneuver. We prefer to perform a wide laminar resection with complete facet resection, producing a closing-wedge “osteotomy” at each segment (Fig. 12-11). The closure of each segment, best done by the compression rod technique, produces the correction. Placement of implants (such as supralaminar hooks) in the spinal canal should be avoided because of potential neurologic complications and because the implant will block complete closure of the resection laminotomy, preventing full correction. The typical compression rod construct consists of paired hooks facing each other across the apical segment, which is uninstrumented. Above the apex, caudad-facing hooks are placed over the transverse processes, which in kyphotic deformities are often quite robust. Below the apex, cranially directed hooks are placed either as pedicle hooks or under the inferior laminar edges of the thoracic vertebrae above the ligamentum flavum. Paired pedicle screws are routinely used to anchor upper lumbar levels. The rods are seated sequentially in all anchors, and compression is then carried out simultaneously on each rod,

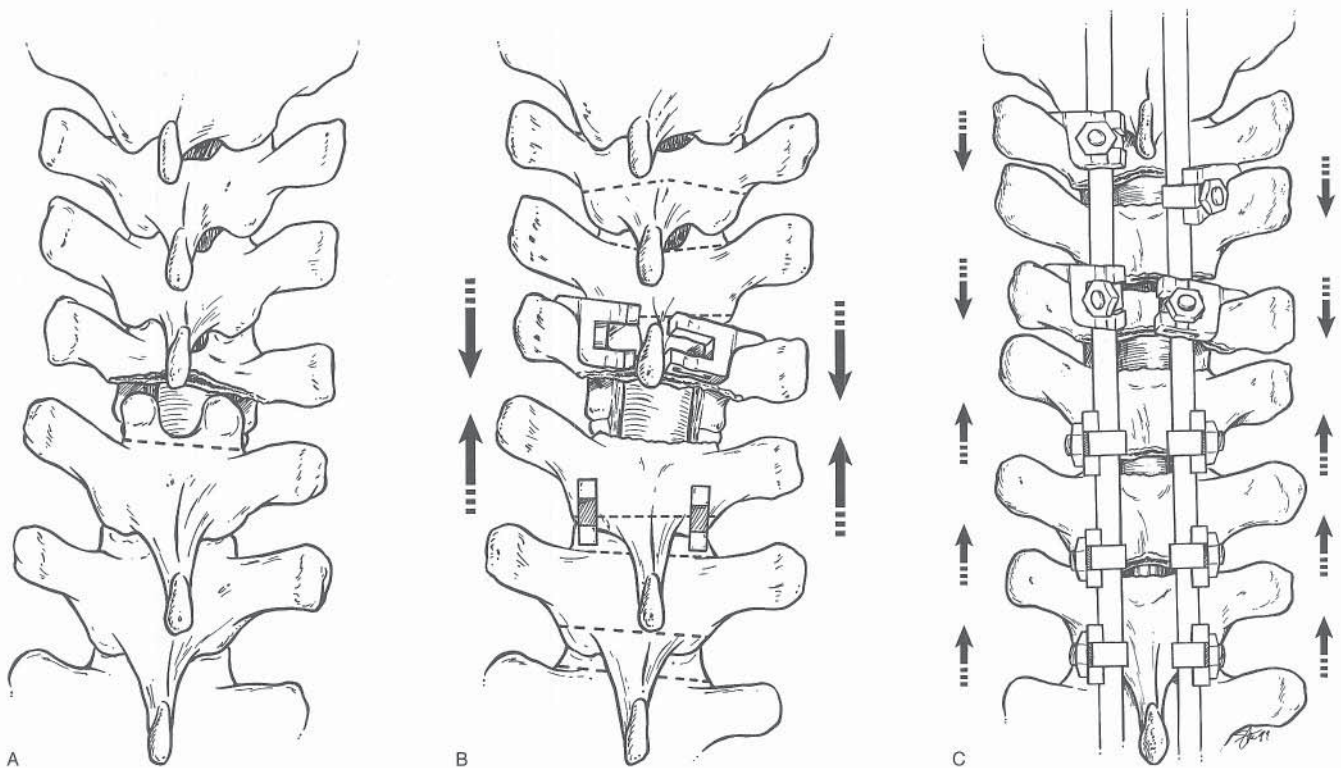


FIGURE 12-11 A, Laminar resection at apex of kyphosis to achieve posterior closing-wedge (shortening) correction. B, Facet resection at same interspace. Transverse process hooks are placed above, and pedicle (or sublaminar) hooks below the resection. C, Compression is applied sequentially, beginning at the apex, to close each laminotomy/resection.

beginning at the apex and moving peripherally. Each bony interspace is closed gradually. Radiographic control is recommended to avoid excessive or nonharmonious correction. Because of the powerful and incremental correction achievable with this technique, it can be difficult to recognize when adequate correction has been achieved and nut advancement can be stopped (Fig. 12-12).

Posterior fusion with iliac crest graft completes the posterior instrumentation procedure. Postoperative immobilization has not been necessary with the multisegment hook-rod systems.^{46,67} We have not found routine postoperative immobilization necessary following dual $\frac{3}{16}$ -inch compression rod instrumentation, although others have immobilized their patients in casts or braces for up to 9 months.^{10,13,24,57,75}

To date, compression rod techniques in treating kyphosis have achieved and maintained correction satisfactorily.³⁷ The typical loss of correction of 5 degrees or less confirms that if the kyphosis can be corrected to a normal range (40 to 45 degrees of residual kyphosis), anterior surgery appears unnecessary to maintain correction (Fig. 12-13). Earlier series had recommended anterior fusion to maintain correction, especially in skeletally mature patients, in whom apophyseal growth was unavailable to fill in the anterior disk space, which would collapse and cause loss of correction.^{10,71} However, by using the heavier compression rod construct, we have been able to maintain correction without the need for interbody fusion, and so we currently prefer posterior-only instrumentation over combined anterior-posterior procedures.

Progressive Noninfectious Anterior Fusion

Occasionally a patient with a typical clinical presentation of increasing kyphosis with growth will have partial or complete bony ankylosis or fusion of the disk spaces on radiographs. Known as progressive noninfectious anterior vertebral fusion,^{1,39,68} this condition is most likely a form of congenital kyphosis, differing primarily in that the fusion often is limited to the most anterior portion of the disk space (Fig. 12-14). Histologic study of the ankylosed areas has demonstrated dystrophic growth cartilage without disk material, suggesting that the ossification is programmed genetically, as would be observed in a physis that closes normally at maturity. The familial occurrence of this condition appears to corroborate this genetic cause.³⁹ The posterior disk space may remain unfused, and this, combined with lack of involvement of the posterior elements, produces a progressive kyphosis owing to anterior tethering. As of 1991, 80 cases had been reported in the literature.¹

The diagnosis may actually be made much earlier than in typical Scheuermann's disease if a radiograph (usually obtained for unrelated reasons) demonstrates narrowing of the anterior disk spaces and approximation of the anterior corners of the bodies. The diagnosis has been made as early as 1 year of age under these circumstances.¹ Usually the kyphosis is much more rigid than would be expected at this stage, consistent with the presence of anterior failure of

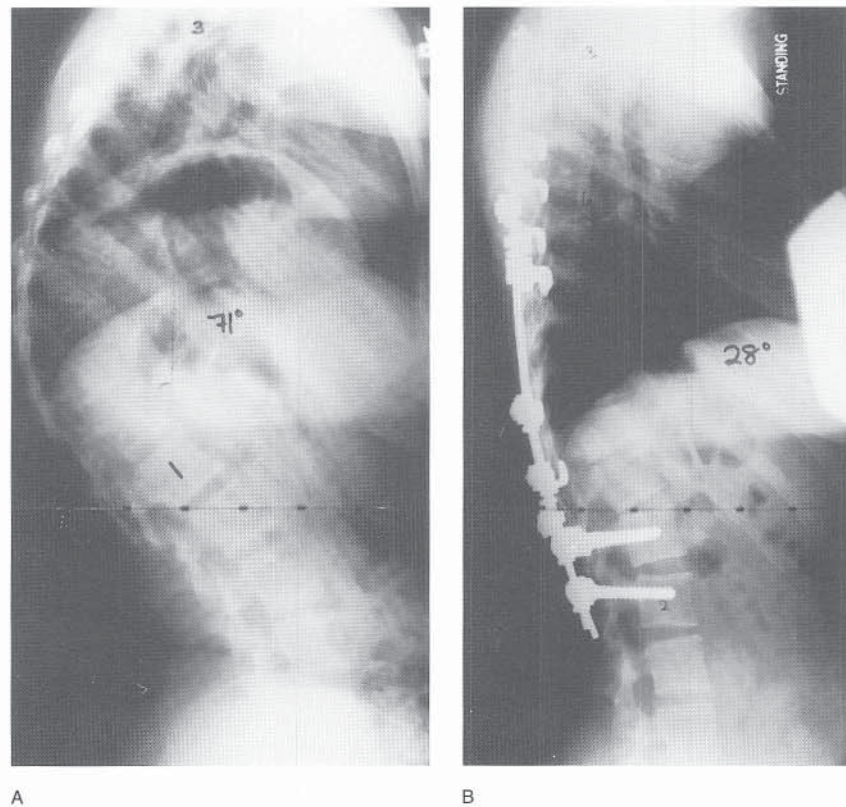


FIGURE 12-12 A, Preoperative radiograph of an adolescent girl with hyperkyphosis. B, Postoperative correction, showing excessive flattening of the midthoracic kyphosis (T6–10) due to overtightening of the compression system. There is also a caudal junctional kyphosis at L2–3 due to the overall excessive correction of the kyphosis.

segmentation, which is simply unossified at this time. Erosions may mimic the changes of Scheuermann's disease, but the posterior part of the disk space remains unaffected at this stage and may never completely fuse, although it will probably gradually narrow and then fuse with maturation. One segment or several adjacent segments can be affected, with the thoracic or thoracolumbar spine most commonly affected. Patients are usually asymptomatic, with the deformity the only clinical evidence of the disease.

Although the deformity is most likely congenital (and also genetic³⁹), the condition is treated the same as Scheuermann's deformity. Orthotic management has been reported to stop progression.¹ In established deformity after maturity, operative management is indicated for the same reasons as in Scheuermann's disease—that is, for pain associated with severe deformity and for cosmesis. Because of the anterior fusions of the anterior portion of the disk spaces, surgical correction requires anterior discectomy/osteotomy followed by posterior instrumentation.

Postlaminectomy/Postirradiation Kyphosis

The treatment of spinal cord tumors, benign or malignant, usually requires a laminectomy for either biopsy or excision. If the lesion is malignant, radiation therapy may be administered as either a primary or adjunctive treatment. The effect of either a laminectomy or radiation therapy on the growing spine can be a significant kyphotic deformity, requiring additional treatment for the deformity itself.⁷⁷

POSTLAMINECTOMY KYPHOSIS

The causes of postlaminectomy kyphosis are multifactorial. The excision of facet joints, laminae, and posterior ligamentous structures (interspinous ligament and ligamentum flavum) can result in the development of kyphosis as a result of destabilization of the posterior structural integrity of the spine. Normal flexion forces on the spine, including gravity, will produce a kyphosis following removal of interspinous ligaments, laminae, and spinous processes.⁵⁴ The increased flexion moment on a segment produces compression of anterior vertebral apophyses, resulting in a secondary growth disturbance due to growth inhibition.^{43,44} Once the posterior elements have been destabilized and the spine begins to flex, a vicious cycle of growth inhibition and further kyphosis develops.^{89,90} The cervical and thoracic spine seem to be most susceptible to this phenomenon, while the lumbar spine, being normally in lordosis, tends not to develop significant kyphosis unless a deformity exists prior to laminectomy (Fig. 12-15).

Neurologic involvement, especially muscle paralysis or weakness, obviously can exacerbate a kyphosis produced by destabilization. Patients with spinal cord injuries or tumors can develop spinal deformity secondary to paralysis alone,¹⁵ and those who have even mild muscle weakness or paralysis are extremely susceptible to progressive kyphosis following destabilizing laminectomy.

The facet joint seems to be the most critical structure influencing the development of postlaminectomy deformity.^{16,20,43} When facet joints are more horizontal in orientation, their disruption or removal allows significant flexion to occur in the cervical and thoracic spine. Scoliosis can also

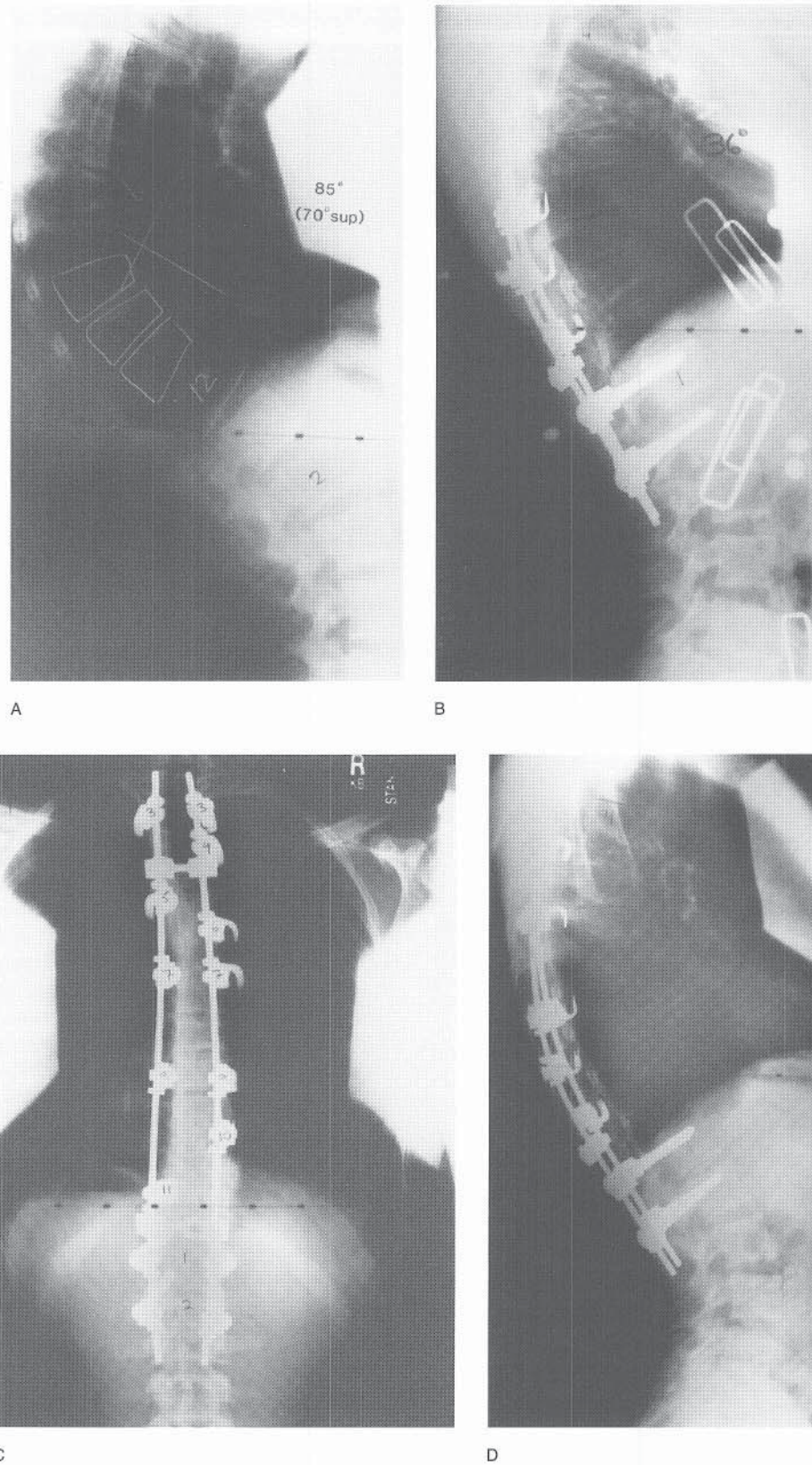


FIGURE 12-13 Imaging appearance in an 18-year-old man with a significant Scheuermann's kyphosis measuring 85 degrees (supine correction to 70 degrees). **A**, Close-up view of the thoracic apex demonstrating the severe changes of Scheuermann's disease. **B**, Immediate postoperative correction following posterior instrumentation/fusion with the threaded rod compression system. Anterior opening of the disk spaces in the apex is evident, but because no anterior discectomy was performed, this area did require formal support. (The patient was braced, perhaps unnecessarily, because of the disk opening). **C**, AP radiograph demonstrating the hook pattern for the threaded rod construct. **D**, At 15 months postoperatively, correction was maintained at 40 degrees.

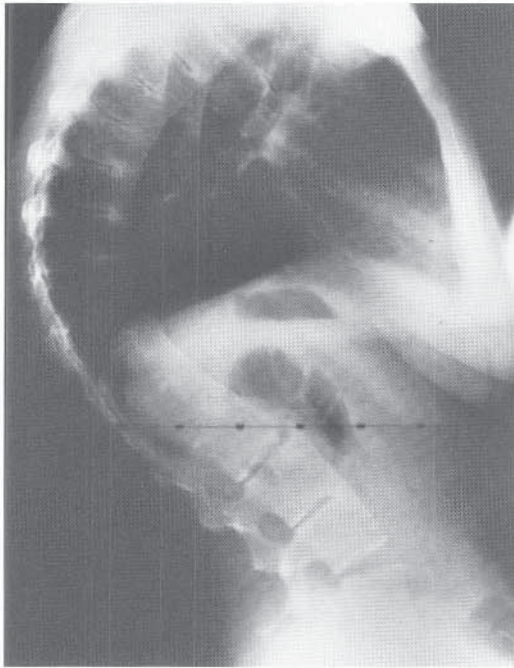


FIGURE 12-14 Fusion of the anterior portion of the disk spaces in progressive noninfectious anterior fusion.

occur, either separately or in conjunction with the kyphosis, depending on how symmetric was the removal of facet joints and posterior ligamentous structures.^{20,43}

The incidence of postlaminectomy kyphotic deformity correlates closely with the age of the patient at the time of the surgery and with the level and number of laminae removed.^{89,90} The younger the patient and the more cephalad the laminectomy, the more likely a postlaminectomy deformity will occur. For example, 46 percent of patients less than 15 years old develop postlaminectomy kyphosis, compared with only 6 percent of those ages 15 to 24 years. Eighty to 100 percent of cervical spine laminectomies, 36 to 50 percent of thoracic laminectomies, and 0 percent of lumbar laminectomies produce deformity.^{28,89,90} There are two patterns of postlaminectomy kyphosis: a sharp, angular kyphosis due to immediate posterior instability, usually exacerbated by anterior growth suppression producing wedged vertebral bodies (Fig. 12-16), and a more rounded kyphotic deformity, due to more chronic and lower-grade hypermobility (Fig. 12-17).

POSTIRRADIATION KYPHOSIS

If radiation therapy has been added to the treatment of the underlying process, the endochondral ossification at the apophysis can be significantly damaged, as this area is known to be radiosensitive. Kyphosis has been produced experimentally by simply irradiating immature animal apophyses.^{3,23} Thus, radiation therapy significantly increases the incidence and severity of kyphosis in a postlaminectomy patient less than 10 years old. A greater accumulated radiation dose increases the likelihood of postirradiation growth arrest, as does a larger radiation field. Physeal growth slows following as little as 60 cGy of radiation and can be completely inhibited at 1,200 cGy.^{33,59} Thus, doses up to 3,000

cGy (an amount used to treat neuroblastoma, Wilms' tumor, or medulloblastoma) can be expected to cause a significant decrease in the height of a vertebra, producing a flattened, beaked vertebra if any kyphosis is present (Fig. 12-18).^{21,60,69} In addition to inhibition of bone growth, significant soft tissue fibrosis and scarring can be observed in the radiation field, complicating any surgical procedures in the area because of delayed healing (Fig. 12-19). The importance of vascularized bone graft in such irradiated beds cannot be overemphasized (see discussion under Surgical Treatment, below).

The occurrence of clinically important postirradiation spinal deformity has been reported to range from 10 to 100 percent of cases treated.^{5,17,21,60,85} Although shielding and limiting the radiation field have resulted in less growth disturbance at the periphery of the treatment area, there is still a risk for any patient who has significant skeletal growth remaining. The increasing use and effectiveness of chemotherapy for malignant tumors has reduced the need for high-dose irradiation, but any child who has received radiation to the spine must be closely observed for the development of spinal deformity. The cumulative effect of destabilization by laminectomy, radiation therapy to the spine, and any muscle weakness caused by the underlying spinal cord tumor or injury itself is the development of a significant spinal deformity, with nearly 100 percent certainty. Both scoliotic and kyphotic deformities can increase during the adolescent growth spurt,^{40,43,60,85} suggesting that just because a young child does not develop acute deformity following the initial surgical and radiation treatment, the deformity cannot become significant later on.

TREATMENT

Prevention. Prevention is the best means of treating postlaminectomy/postirradiation kyphosis. The first preventive method is to remove as little bone as possible when accessing the spinal canal, with particular care to preserve the facets bilaterally. A second preventive method may be to perform an osteoplastic laminectomy,⁵⁸ in which the laminae and interspinous ligaments are removed en bloc and replaced at the end of the procedure by wiring and or internal fixation. Alternatively, the spinous processes are split in the midline, everting the hemilaminae or laminae in a block, and then are rewired or otherwise internally fixed, replacing the two laminar halves together. Using this latter technique, Shikata and associates prevented postlaminectomy deformity in eight patients with an average follow-up of 50 months, although some of the patients were adults.⁶⁶

Prophylactic Treatment. In patients with a high likelihood of developing deformity, prophylactic surgical treatment at the time of laminectomy should be seriously considered. Such prophylactic treatment could include fusion in situ at the time of laminectomy⁶⁶ with or without instrumentation, although instrumentation may be less attractive, owing to the need for continued MRI follow-up surveillance of the area for a malignant tumor. Titanium or absorbable instrumentation are MRI-compatible and would be indicated in any laminectomy patient with malignant disease. There may be some theoretical objections to immediate prophylactic fusion, including (1) lack of knowledge of the patient's

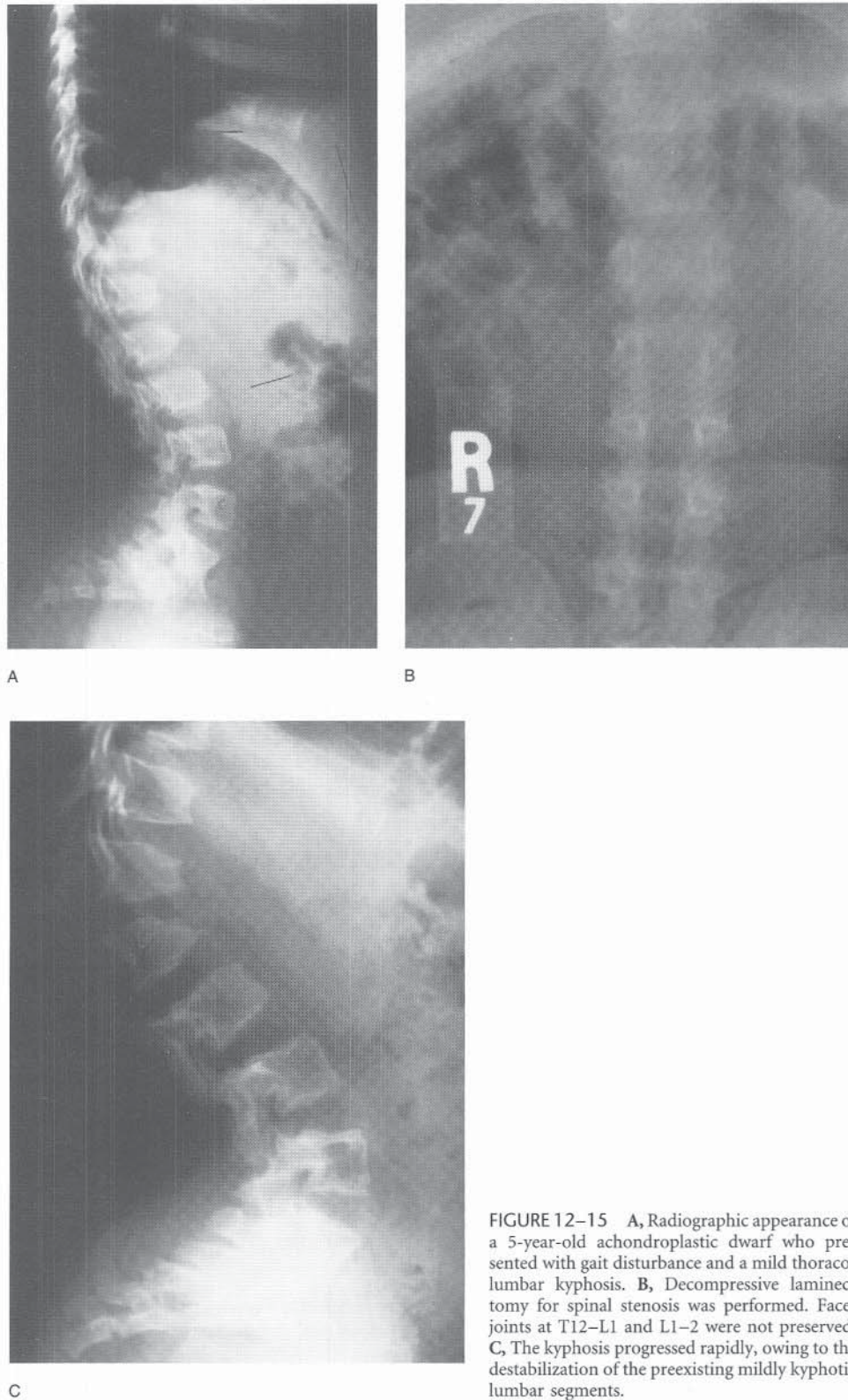
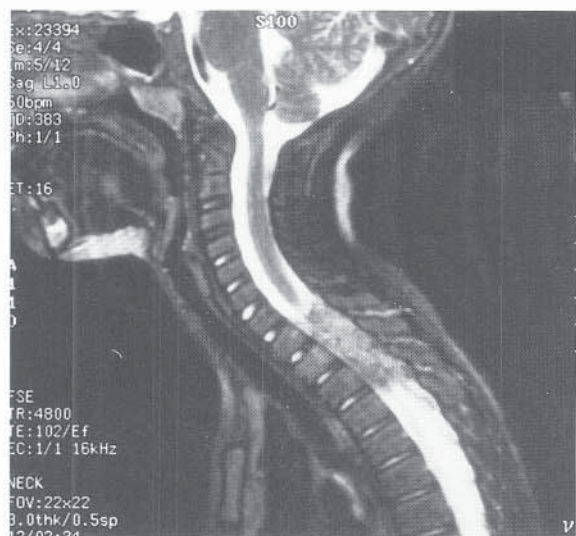


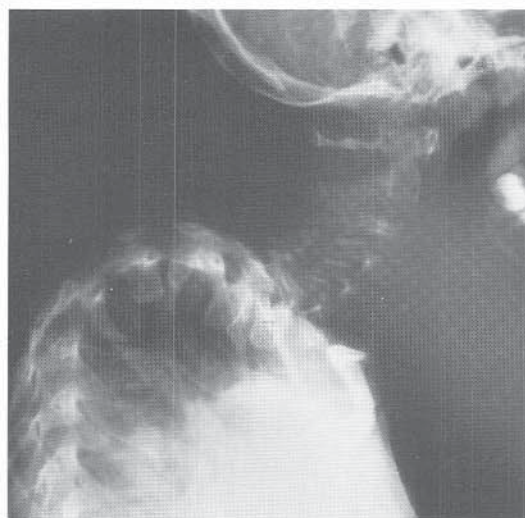
FIGURE 12-15 **A**, Radiographic appearance of a 5-year-old achondroplastic dwarf who presented with gait disturbance and a mild thoracolumbar kyphosis. **B**, Decompressive laminectomy for spinal stenosis was performed. Facet joints at T12–L1 and L1–2 were not preserved. **C**, The kyphosis progressed rapidly, owing to the destabilization of the preexisting mildly kyphotic lumbar segments.

survival expectation, (2) if the tumor resection prevents dural closure, instrumentation and bone graft may endanger the spinal cord through either impingement or hematoma, or (3) if the patient is to undergo chemotherapy or radiation therapy immediately following excisional biopsy, the fusion

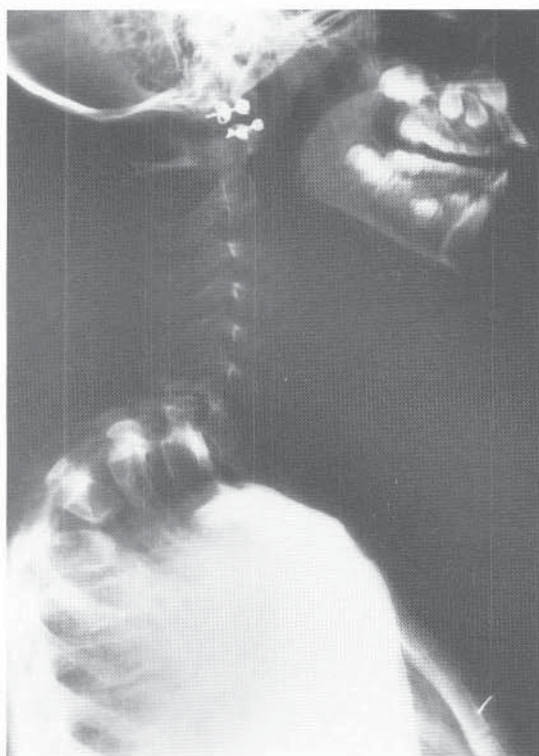may be inhibited by these antineoplastic agents. With modern therapy for malignancy, patients may have a long survival following diagnosis, and the orthopaedist must be prepared for a prolonged survival, regardless of the initial severity of the neurologic or physiologic deficit. Although



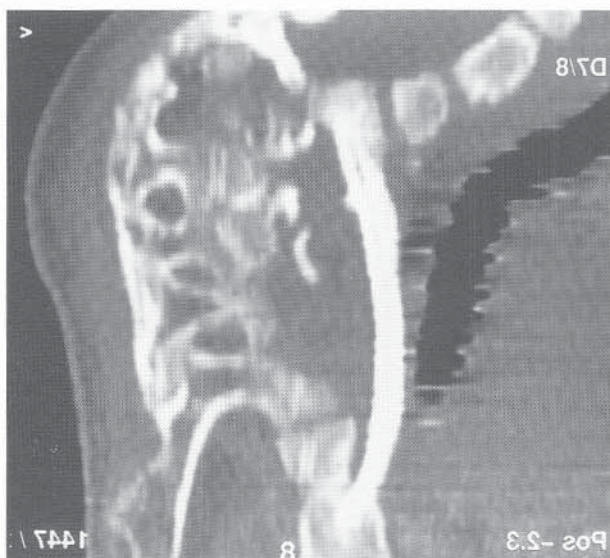
A



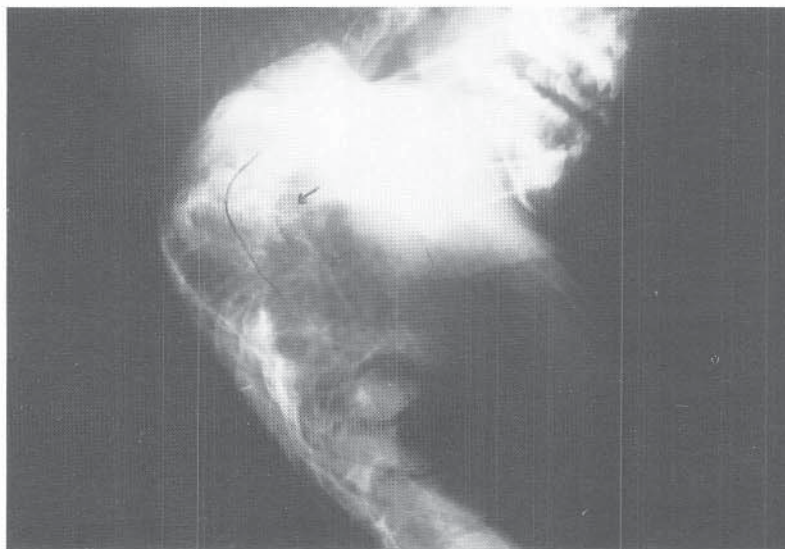B



C

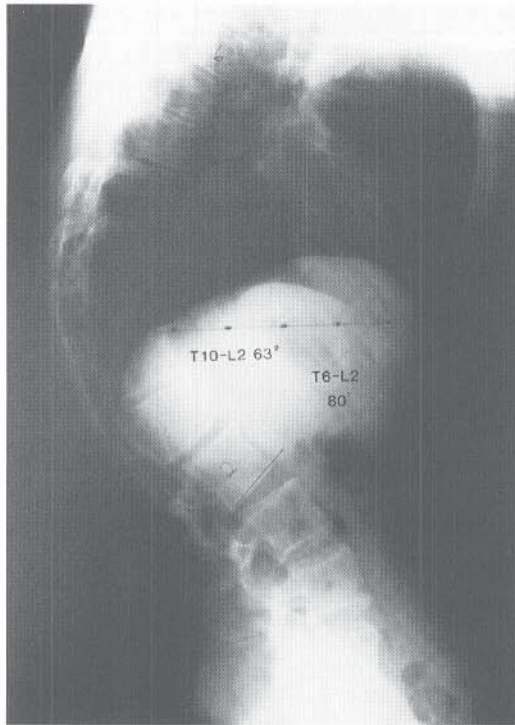


D

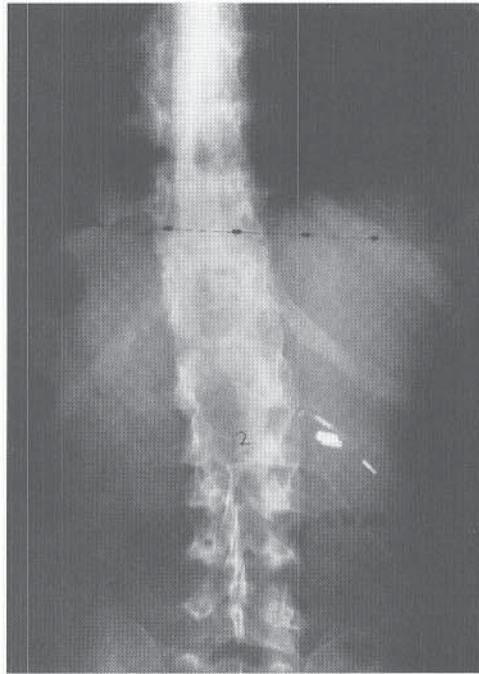

E

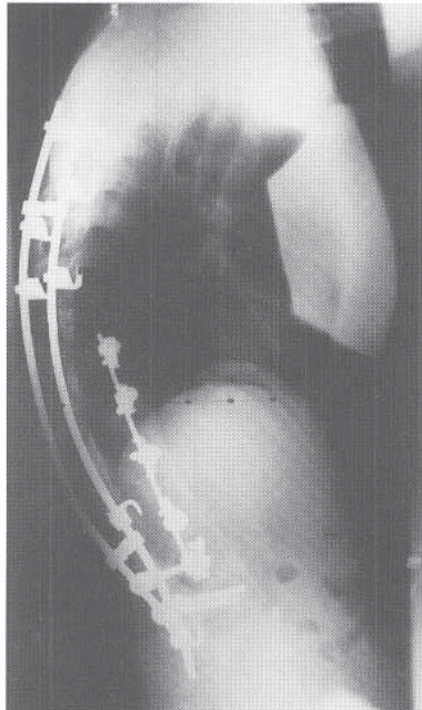
FIGURE 12-16 A, MRI demonstrating high-grade neuroectodermal tumor at the cervicothoracic junction in a 7-year-old girl. B, The patient underwent biopsy via a limited laminectomy at one level, followed by radiotherapy and chemotherapy. A sharply angled kyphosis developed at T2-4. C, The kyphosis was corrected by long-term halo traction. D, CT scan obtained after anterior and posterior fusion performed using a vascularized rib strut graft anteriorly. Note additional short grafts in the apex of the kyphosis. E, At 3 years postoperatively, the kyphosis was stable (arrows = rib strut).



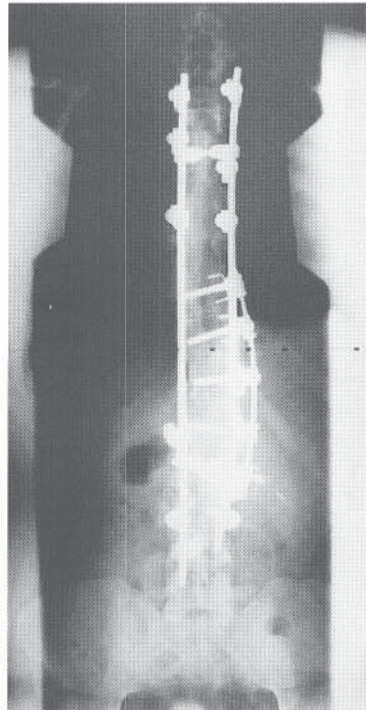
A



B



C



D

FIGURE 12-17 A and B, A 20-year-old man developed rounded but painful kyphosis in the thoracolumbar area 6 years after undergoing laminectomy and intradural resection of an astrocytoma. He had received no radiation therapy. C and D, Two years following anterior and posterior instrumentation and fusion. The anterior threaded distraction rod elongates the anterior column safely at the time of interbody fusion. This produces mild scoliosis, which is controlled by the posterior construct.

pseudarthrosis repair at a later date may be necessary, there is no easier time, for patient or surgeon, to perform prophylactic spinal fusion than at the time of laminectomy. Thus, the arguments against prophylactic fusion in a high-risk patient are less compelling than the advantages of performing the procedure.⁶⁶

The nonoperative, prophylactic treatment of post-laminectomy/postirradiation deformity by means of bracing has been recommended. However, there are no studies demonstrating the efficacy of this form of treatment, and its ineffectiveness in preventing progression is well known (see Fig. 12-19B).⁴³ Bracing may buy time while the child grows,

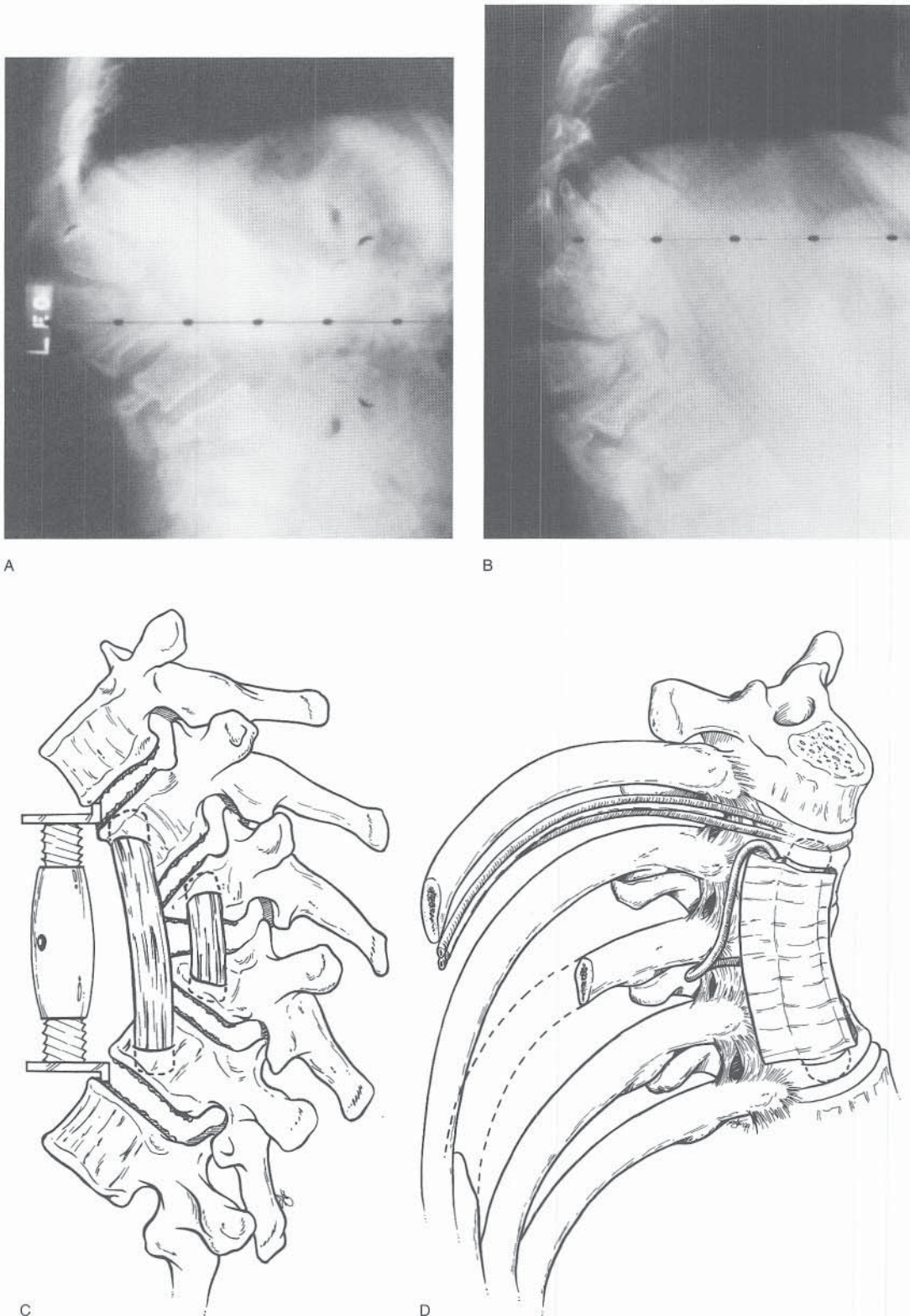


FIGURE 12-18 A, Beaked, flattened appearance of pathologically compressed vertebrae following irradiation for Wilms' tumor. B, Stabilization was achieved by means of an anterior vascularized strut graft using the 10th rib. The other disk spaces posterior to the strut graft appear pseudarthrotic, owing to the poor incorporation of nonvascularized graft caused by radiotherapy. C, Placement of strut grafts (nonvascularized) in the apex of a kyphosis, aided by a temporary distractor. D, Mobilization of a rib graft on its intercostal pedicle (figure redrawn after Bradford⁹). The pedicle should be of sufficient length to avoid kinking once the rib is rotated into place as the strut graft.

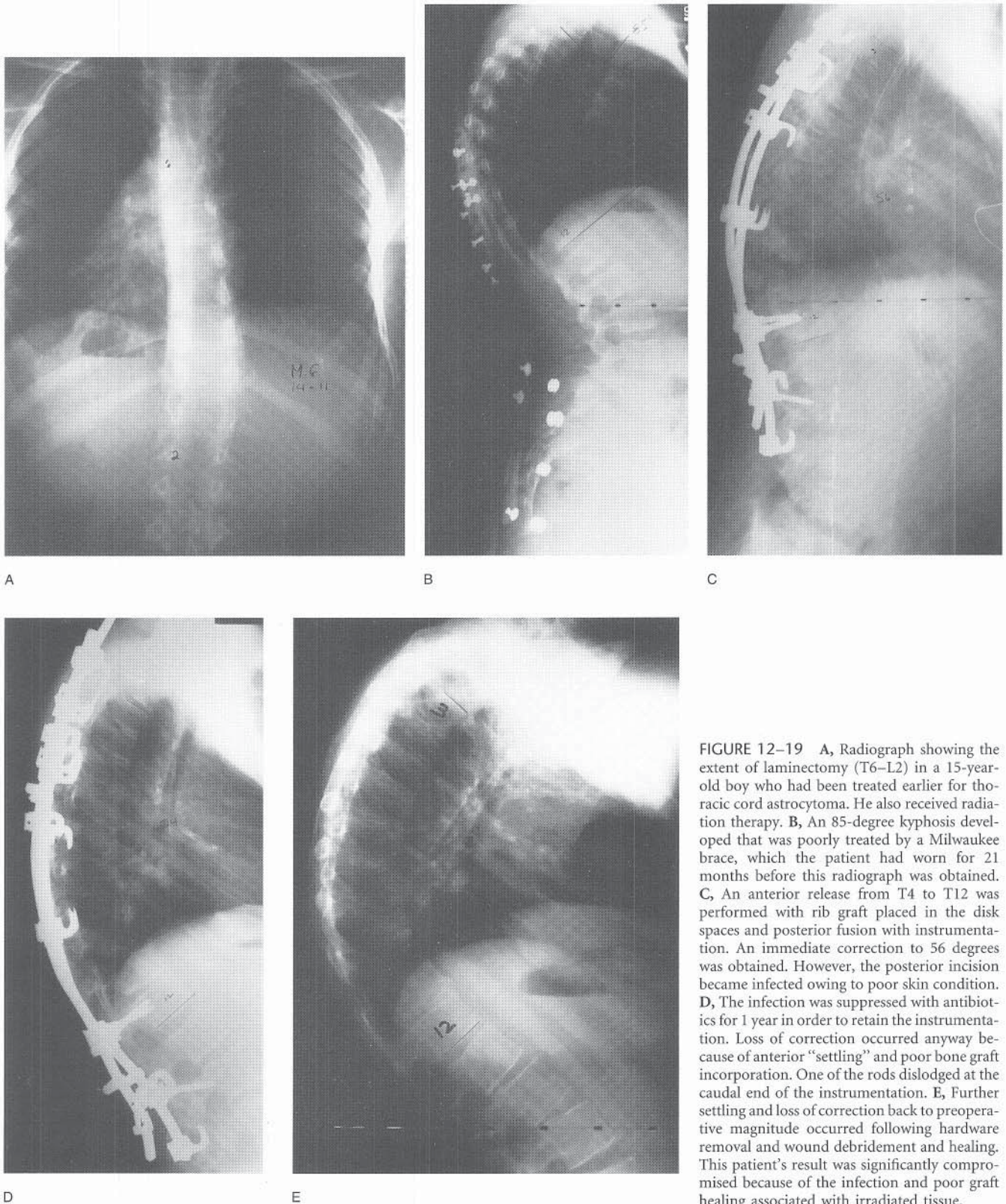


FIGURE 12-19 A, Radiograph showing the extent of laminectomy (T6–L2) in a 15-year-old boy who had been treated earlier for thoracic cord astrocytoma. He also received radiation therapy. B, An 85-degree kyphosis developed that was poorly treated by a Milwaukee brace, which the patient had worn for 21 months before this radiograph was obtained. C, An anterior release from T4 to T12 was performed with rib graft placed in the disk spaces and posterior fusion with instrumentation. An immediate correction to 56 degrees was obtained. However, the posterior incision became infected owing to poor skin condition. D, The infection was suppressed with antibiotics for 1 year in order to retain the instrumentation. Loss of correction occurred anyway because of anterior “settling” and poor bone graft incorporation. One of the rods dislodged at the caudal end of the instrumentation. E, Further settling and loss of correction back to preoperative magnitude occurred following hardware removal and wound debridement and healing. This patient’s result was significantly compromised because of the infection and poor graft healing associated with irradiated tissue.

controlling the deformity to some extent while the vertebral elements enlarge.³⁶ However, it is inappropriate to delay definitive surgical stabilization when patient growth produces an uncontrolled kyphosis.

Surgical Treatment. Anterior and posterior spinal fusion is usually recommended for progressive deformity. With the availability of effective treatment for malignancy, it would be rare for spinal stabilization not to be indicated for a progressive deformity. Combined circumferential fusion is necessary because of the higher pseudarthrosis rates (50 percent) reported with posterior fusion alone.⁴³ With postradiation deformities, anterior and posterior fusion is almost always necessary to obtain solid arthrodesis, owing to the fibrotic and dysvascular bony and soft tissues surrounding the spine. Anterior release and fusion to obtain correctability and anterior column support, followed by posterior instrumentation and fusion, is a traditional sequence for a rounded kyphosis (see Fig. 12–19).⁴³

In patients with bony elements robust enough for instrumentation, anterior constructs are attractive to maintain intraoperative correction, especially in the laminectomized segments. Distraction of the kyphotic apex combined with interbody, strut, or inlay graft fusion achieves and maintains correction made possible by the anterior release and discectomy. Increasing kyphosis (“settling”) in the postoperative period may be prevented or ameliorated by the anterior construct (see Fig. 12–17).

Anterior distraction instrumentation must be positioned on the lateral surface of the vertebral bodies to take into account the relative anterior-to-posterior translation between the apex and the end vertebrae to be instrumented. Screws in the end vertebra(e) should be placed posteriorly in the vertebral body, while screws near the apex should be more anterior (Fig. 12–20A). Rod contouring is minimized by such placement, which is important if gradual distraction using a threaded rod is contemplated. The rod can be placed posterior to end-vertebral screws and anterior to apical ones in a side-loading instrumentation system (e.g., TSRH instrumentation), further minimizing the need for rod contouring. Variable-angle screws are useful to accommodate different rod distances from the screws, thus avoiding the need for zig-zag bends in the rod (Fig. 12–20B).

Because of the distraction of the spine achieved with laterally placed screws, a frontal plane scoliosis will be produced (see Fig. 12–17). Anterior distraction instrumentation should therefore be placed in the *concavity* of any existing preoperative scoliosis to minimize this effect. Alternatively, a solid rod may be used, which can be contoured with an antiscoliotic bend to reduce this outcome. The disadvantage of a solid rod is that distraction correction is obtained by acute loading of each screw with a spreader or external distractor, thus risking screw loosening because of the acute, somewhat uncontrolled loading. A threaded rod allows gradual, controlled, repetitive loading—a safer technique in terms of screw-bone interface integrity and possibly for neurologic considerations. Should an instrumental scoliosis be produced by the distraction, it can easily be “treated” by a posterior construct combining compression on the convexity and distraction on the concavity to maintain coronal alignment (see Fig. 12–17).

In a sharply angled kyphosis with dysplastic vertebral

bodies (secondary to radiation therapy, for example), anterior placement of instrumentation may not be feasible owing to limited space and osteopenia. Strut-grafting becomes the best surgical option in this circumstance (see Fig. 12–18). One well-established technique includes use of a temporary distractor, such as the turn-buckle variety described by Pinto and associates,⁵⁵ to correct the kyphosis temporarily while a rib or fibular strut graft is keyed into the apex posterior to the distractor to maintain the correction (see Fig. 12–18C). Multiple strut grafts are useful in the sharpest-angled deformities.¹¹ However, if the grafts are nonvascularized and more than 5 to 6 cm long the likelihood of stress fracture due to incomplete revascularization, and hence possible loss of correction because of graft failure, increases.

For this reason, Bradford developed the transfer of a rib graft on its intercostal vascular pedicle for use in kyphosis.⁹ The rib graft is harvested by making the appropriate thoracotomy in the intercostal space *above* the rib to be transferred, then cutting the rib distally (anteriorly), disarticulating the costochondral junction. The inferior musculature is divided above the next caudal rib, leaving a cuff of muscle containing the intercostal vessels attached to the rib and undisturbed. Proximally the rib is cut subperiosteally, and then the intercostal pedicle is further dissected back to the segmental vessel origin near the intervertebral foramen (see Fig. 12–18D). The rib-composite graft may then be rotated into the apex of the kyphosis. A 1- to 2-cm cuff of muscle is removed from each end of the rib so that the ends can be keyed into slots in the end vertebra to receive the strut graft. The intercostal pedicle should be carefully checked for kinking before closure, and the periosteum over the rib can be incised to observe for bleeding, to ensure maintenance of vascularity.

With correct selection of a rib for transfer, almost any kyphosis from low cervical to about L3 can be strutted. For cervicothoracic applications, a rib two to three segments *below* the apex should be selected and rotated from below into the kyphosis (see Fig. 12–16). Below T6, the rib two segments cephalad to the apex can be rotated from above into the deformity, with the 10th or 11th rib (if long enough) used to reach lumbar segments (see Fig. 12–18). Because of the vascularity of the strut, healing is usually evident by 3 months postoperatively, consistent with experimental studies evaluating graft healing mechanically and histologically.⁶⁵

Neurologic surveillance is emphasized whenever correction of postlaminectomy or postirradiation kyphosis is attempted. Intraoperative spinal cord monitoring may not be technically feasible in some cases, such as when the patient has previously undergone intradural surgery for primary tumor treatment and subsequently developed radiation fibrosis. In such situations, functional wake-up tests⁸³ may be the only intraoperative, postcorrection surveillance method. Considering the fragile nature of the neural elements in the previously operated-on and irradiated area, acute correction of deformity may be inadvisable, and *in situ* fixation in the patient with normal or near-normal neurologic function may be the safest alternative. On the other hand, if increasing kyphosis is symptomatic and neurologic deficit from the deformity is documented or impending, then correction of the deformity or decompression by anterior vertebrectomy and strut grafting, followed by posterior fusion, may be the indicated appropriate sequence.⁴³ Finally, in a small patient

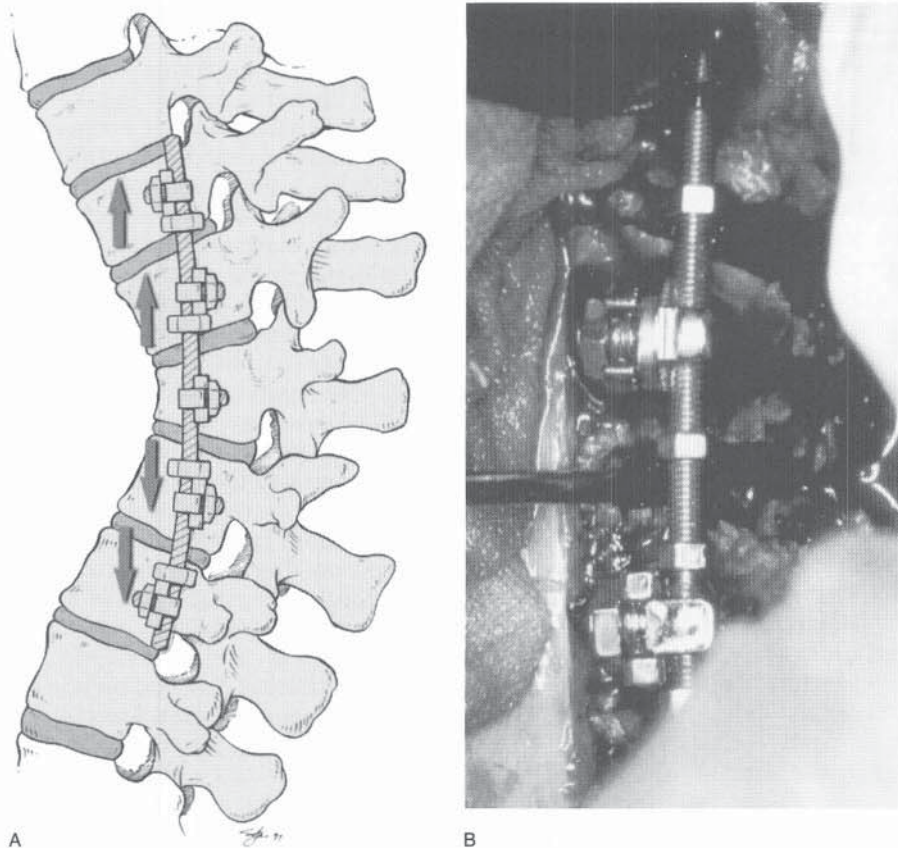


FIGURE 12-20 A, Posterior-to-anterior alignment of vertebral body screws for anterior distraction rod treatment of kyphosis. B, A variable angle eye bolt (top segment) accommodates a greater distance from rod to screw head at the apex of a kyphosis without rod contouring. A standard screw is at the next segment below.

with fragile vertebral elements and significant deformity, prolonged halo-gravity traction (via a wheelchair or a standing frame) may be the only option to achieve correction safely and slowly with careful neurologic monitoring over time. Once the deformity has achieved maximum correction, then in situ fixation followed by postoperative external immobilization or continued traction may be efficacious in maintaining correction while fusion occurs (see Fig. 12-16).

Miscellaneous Causes of Kyphosis

Certain syndromes and skeletal dysplasias characteristically result in kyphotic deformity in some portion of the spinal column. An awareness of these conditions facilitates early recognition and treatment and can help reduce neurologic morbidity from a neglected deformity. Kyphosis of the cervical spine is discussed in Chapter 10, Disorders of the Neck.

ACHONDROPLASIA

The most common spinal problems affecting patients with achondroplasia include occipitocervical stenosis with Arnold Chiari malformations in infancy, and spinal stenosis due to shortened pedicles and diminutive lumbar canal dimensions in late adolescence and adult life. However, about 30 percent of achondroplastic dwarfs have a thoracolumbar kyphosis in early childhood (see Fig. 12-15), with about one-third of these patients, or 10 percent of all achondroplasts, having

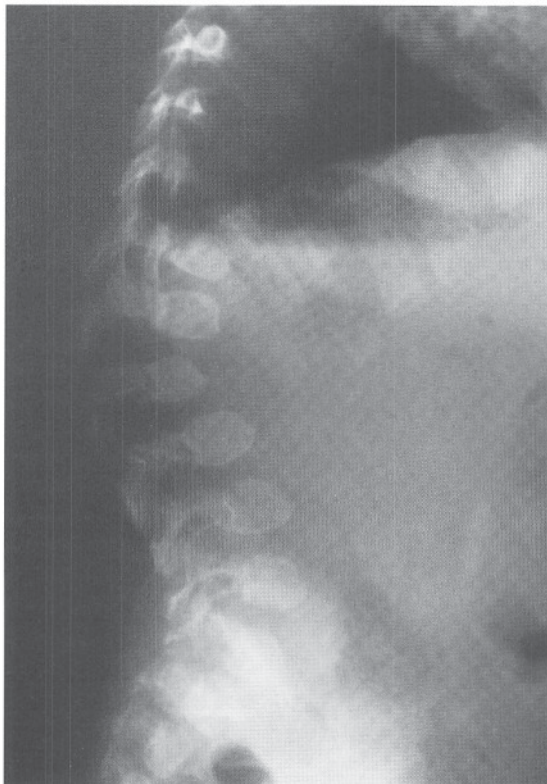
a progressive kyphotic deformity.^{43,81} The management of this deformity is discussed in Chapter 29, Skeletal Dysplasias.

PSEUDOACHONDROPLASIA

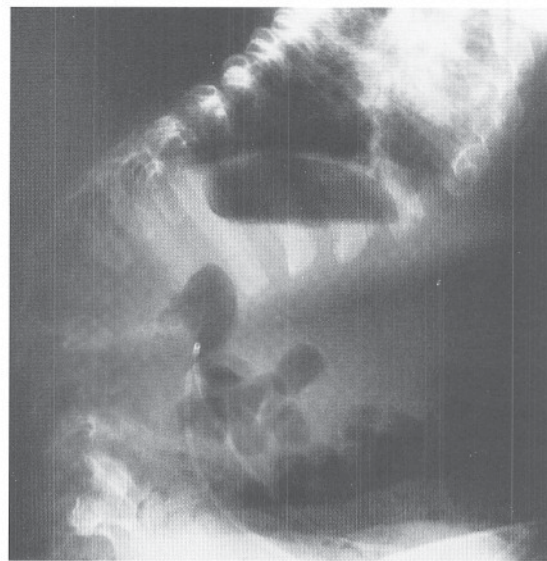
Kyphotic deformities are also seen in children with pseudoachondroplasia and are associated with multiple wedged vertebral bodies in the thoracic and thoracolumbar spine. The wedging may be related to incomplete ossification of the anterior tongue-like projections from the vertebrae, which are the characteristic radiographic findings in pseudoachondroplastic children.²⁷ On the other hand, kyphosis may occur as compensation for excessive lumbar lordosis, another characteristic finding in pseudoachondroplasia. Kyphosis in pseudoachondroplasia frequently responds to bracing. Surgery is indicated if progressive deformity is observed and if neurologic impairment is threatened. Because spinal stenosis is not associated with pseudoachondroplasia, late neurogenic claudication problems are not reported and instrumentation to correct thoracic or thoracolumbar kyphosis can be safely used.^{18,38,81}

SPONDYLOEPIPHYSEAL DYSPLASIA/ MUCOPOLYSACCHARIDOSIS

Thoracolumbar kyphotic deformities can be seen in patients with spondyloepiphyseal dysplasia (SED) or mucopolysaccharidosis (MPS). Patients with SED generally have a non-progressive, mild deformity that seldom requires treat-



A



B

FIGURE 12-21 A, A 2-year-old boy with mucopolysaccharidosis type VI (Maroteaux-Lamy syndrome) and thoracolumbar kyphosis. B, At age 8 the kyphosis had progressed, despite orthotic management with a TLSO. Surgical management was contemplated.

ment.^{38,81} Patients with MPS tend to have more severe deformities than SED patients, even though they have similar changes in the vertebral column. This is probably related to the progressive nature of the CNS developmental deficits produced by the storage disease. Previously, patients with type I MPS (Hurler's syndrome) and type II MPS (Hunter's syndrome) usually were not treated because of their poor survival into adolescence and adult life. However, this therapeutic position is currently changing with the advent of life-prolonging bone marrow transplantation.^{25,78,84} There has been marked improvement in patients' overall health and quality of life, with a significant increase in survival. Arrest or slowing of psychomotor retardation has been achieved.

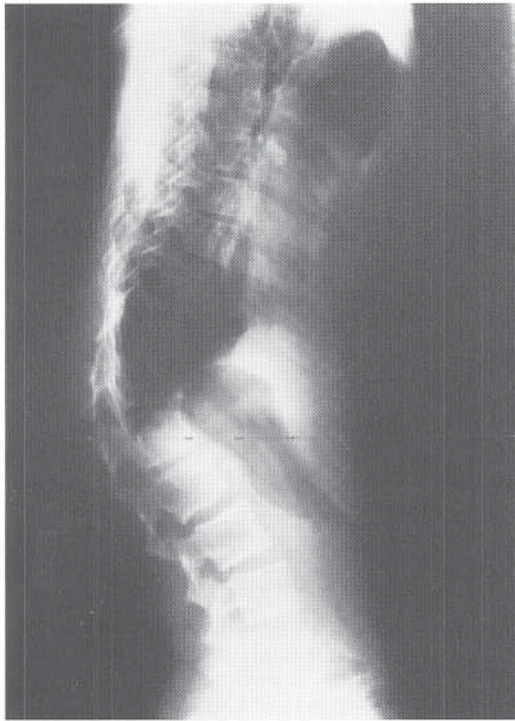
Thus, there is now a need to address various orthopaedic problems arising from the unrelenting dysostosis multiplex, which does not seem to regress, owing to poor penetration of musculoskeletal tissues by the enzyme replaced by the engrafted leukocytes.²⁵ As a result, thoracolumbar kyphosis has become the most commonly treated deformity, requiring posterior spinal fusion in 9 of 24 patients in two series of patients with Hunter's disease.^{25,78} Experience in treating the spines of patients with Hurler's disease is insufficient but would follow the guidelines for other MPS syndromes. Patients with mucopolysaccharidosis type IV (Morquio's disease) generally have mild, nonprogressive thoracolumbar kyphosis, although progressive deformity requiring surgery has been reported.⁷⁴ Patients with mucopolysaccharidosis type VI (Maroteaux-Lamy disease) can have significant thoracolumbar kyphosis, requiring either bracing or surgical stabilization (Fig. 12-21).

As with all SED and MPS conditions, evaluation of the more threatening upper cervical stenosis or instability is mandatory (see Chapter 29, Skeletal Dysplasias).

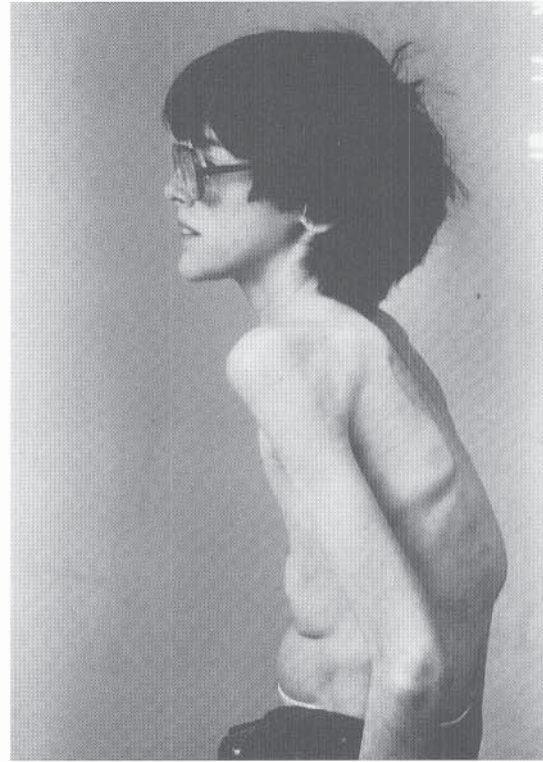
MARFAN'S SYNDROME

Marfan's syndrome, a connective tissue disorder, can result in kyphosis because of hyperlaxity of the spinal column and associated hypotonicity. Scoliosis is more common than pure kyphosis, occurring in up to 63 percent of patients.⁷² Frequently there is a reversal of the normal sagittal planes—that is, the patient has thoracic lordosis and lumbar kyphosis (Fig. 12-22). Spondylolisthesis has also been observed in patients with Marfan's syndrome including severe grade IV slips with cauda equina syndrome.^{79,87} Pure kyphosis, usually developing at the thoracolumbar junction, is estimated to occur in 10 percent of patients with Marfan's syndrome⁴² and is almost certainly a response to thoracic lordosis. The latter is probably structurally related to the vertical elongation of vertebral bodies seen on radiographs, which exaggerates the normally concave posterior surface of the vertebrae.

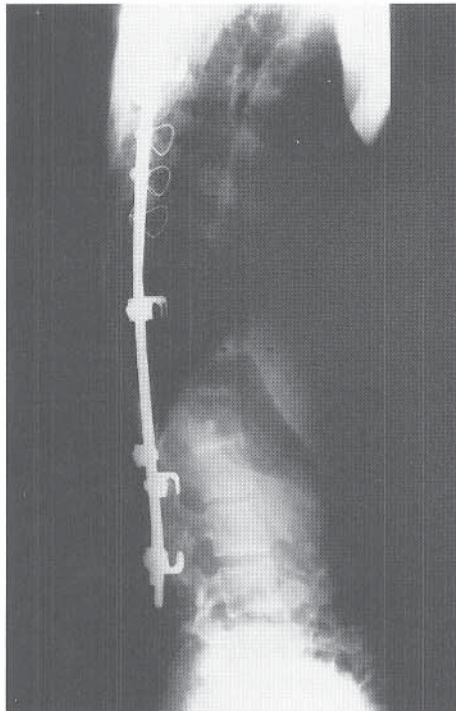
Nonoperative treatment for thoracolumbar spinal deformity has been tried but is generally unsuccessful.⁷ Surprisingly, most deformities in Marfan's syndrome are stiffer than an idiopathic deformity of similar magnitude. Persons with Marfan's syndrome also seem to report pain at the site of the spinal deformity more often than those with idiopathic deformities,^{62,72} thus making it more likely that patients with Marfan's syndrome will undergo surgical treatment. Because of the higher incidence of pseudarthrosis,^{7,62} anterior and



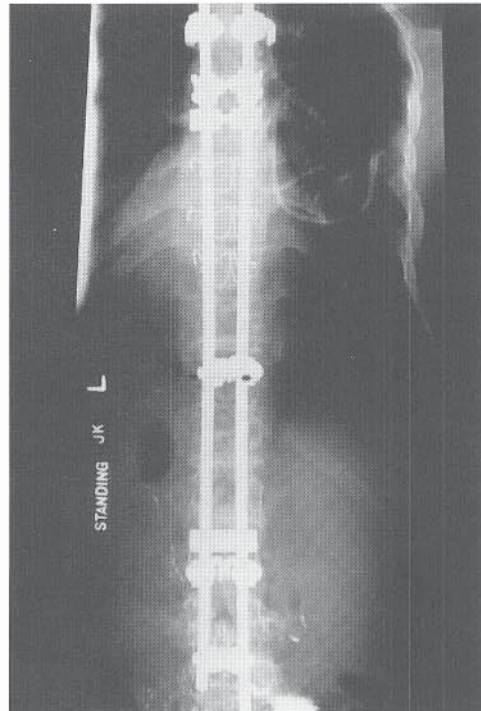
A



B



C



D

FIGURE 12-22 A, A 16-year-old boy with Marfan's syndrome and a 68-degree thoracolumbar kyphosis from T10–L2. Note the thoracic lordosis proximally. B, Clinical appearance. C and D, Radiographs obtained 3 years after anterior release and fusion of T10–L2, followed by PSF with placement of instrumentation at T4–L3. Sublamina wires in the thoracic spine were used to correct the thoracic lordosis.

posterior fusion are recommended. Anterior fusion of the apical kyphotic segments, after thorough disk excision and release, should be followed by a long posterior instrumentation and segmental fusion. Compression instrumentation is used to reduce the kyphotic segments and create upper lumbar lordosis, while thoracic lordosis is corrected with sublaminar wiring to pull the lordotic segments posteriorly to rods contoured into the kyphosis (Fig. 12–22).⁸⁸ The posterior instrumentation must extend well into the lumbar spine, usually to L4, to avoid the development of junctional kyphosis at the caudal end of the instrumentation. This secondary deformity is characteristic of treated Marfan's syndrome and may be a result of the hyperlaxity of posterior ligamentous structures.

REFERENCES

- Andersen J, Rostgaard-Christensen E: Progressive noninfectious anterior vertebral fusion. *J Bone Joint Surg* 1991;73-B:859.
- Apel DM, Marrero G, King J, et al: Avoiding paraplegia during anterior spinal surgery: the role of somatosensory evoked potential monitoring with temporary occlusion of segmental spinal arteries. *Spine* 1991;16:S365.
- Arkin AM, Simon N: Radiation scoliosis: an experimental study. *J Bone Joint Surg* 1950;32-A:396.
- Ascani E, LaRosa G: Scheuermann's kyphosis. In Weinstein SL (ed): *The Pediatric Spine*. New York, Raven Press, 1994.
- Barrera M, Roy LP, Stevens M: Long-term follow-up after unilateral nephrectomy and radiotherapy for Wilms' tumour. *Pediatr Nephrol* 1989;3:430.
- Bick EM, Copel JW: Ring apophysis of human vertebrae: contribution to human osteogony. *J Bone Joint Surg* 1951;33-A:783.
- Birch JG, Herring JA: Spinal deformity in Marfan syndrome. *J Pediatr Orthop* 1987;7:546.
- Blumenthal SL, Roach J, Herring JA: Lumbar Scheuermann's: a clinical series and classification. *Spine* 1987;12:929.
- Bradford DS: Anterior vascular pedicle bone grafting for the treatment of kyphosis. *Spine* 1980;5:318.
- Bradford DS, Ahmed KB, Moe JH, et al: The surgical management of patients with Scheuermann's disease: a review of twenty-four cases managed by combined anterior and posterior spine fusion. *J Bone Joint Surg* 1980;62-A:705.
- Bradford DS, Ganjavian S, Antonious D, et al: Anterior strut-grafting for the treatment of kyphosis: review of experience with forty-eight patients. *J Bone Joint Surg* 1982;64-A:680.
- Bradford DS, Moe JH, Montalvo FJ, et al: Scheuermann's kyphosis and roundback deformity: results of Milwaukee brace treatment. *J Bone Joint Surg* 1974;56-A:740.
- Bradford DS, Moe JH, Montalvo FJ, et al: Scheuermann's kyphosis: results of surgical treatment by posterior spine arthrodesis in twenty-two patients. *J Bone Joint Surg* 1975;57-A:439.
- Bridwell KH, Lenke LG, Baldus C, et al: Major intraoperative neurologic deficits in pediatric and adult spinal deformity patients: incidence and etiology at one institution. *Spine* 1998;23:324.
- Brown HP, Bonnett CC: Spinal deformity subsequent to spinal cord injury. *J Bone Joint Surg* 1973;55-A:441.
- Butler JC, Whitecloud TS III: Postlaminectomy kyphosis: causes and surgical management. *Orthop Clin North Am* 1992;23:505.
- Butler MS, Robertson WW Jr, Rate W, et al: Skeletal sequelae of radiation therapy for malignant childhood tumors. *Clin Orthop* 1990;251:235.
- Cooper RR, Ponseti IV, Maynard JA: Pseudoachondroplastic dwarfism: a rough-surfaced endoplasmic reticulum storage disorder. *J Bone Joint Surg* 1973;55-A:475.
- Dickson RA: Spine: spondylolisthesis. *Curr Orthop* 1998;12:273.
- Dietrich U, Schirmer M, Veltrup K, et al: Postlaminectomy kyphosis and scoliosis in children with spinal tumors. *Neurol Orthop* 1989;7:36.
- Donaldson WF, Wissinger HA: Axial skeletal changes following tumor dose radiation therapy. *J Bone Joint Surg* 1967;49:1469.
- Durrani AA, Choudhury SN: Complications of surgical management of Scheuermann's kyphosis. Presented at the 33rd annual meeting of the Scoliosis Research Society, New York, 1998.
- Engel D: Experiments on the production of spinal deformities by radiation. *AJR Am J Roentgenol* 1939;42:217.
- Ferreira-Alves A, Resina J, Palma-Rodrigues R: Scheuermann's kyphosis: the Portuguese technique of surgical treatment. *J Bone Joint Surg* 1995;77-B:943.
- Field RE, Buchanan JA, Copplemans MG, et al: Bone-marrow transplantation in Hurler's syndrome: effect on skeletal development. *J Bone Joint Surg* 1994;76-B:975.
- Fon GT, Pitt MJ, Thies AC Jr: Thoracic kyphosis: range in normal subjects. *AJR Am J Roentgenol* 1980;134:979.
- Ford M, Silverman FV, Kozlawski K: Spondyloepiphyseal dysplasia (pseudoachondroplastic type). *J Roentgenol Radiation Ther Nucl Med* 1961;86:462.
- Fraser RD, Paterson DC, Simpson DA: Orthopaedic aspects of spinal tumors in children. *J Bone Joint Surg* 1977;59-B:143.
- Greene TL, Hensinger RN, Hunter LY: Back pain and vertebral changes simulating Scheuermann's disease. *J Pediatr Orthop* 1985;5:1.
- Griep RB, Ergin MA, Galla JD, et al: Looking for the artery of Adamkiewicz: a quest to minimize paraplegia after operations for aneurysms of the descending thoracic and thoracoabdominal aorta. *J Thorac Cardiovasc Surg* 1996;112:1202.
- Hall JE: Dwyer Instrumentation in anterior fusion of the spine. *J Bone Joint Surg* 1981;63-A:1188.
- Herndon WA, Emans JB, Micheli LJ, et al: Combined anterior and posterior fusion for Scheuermann's kyphosis. *Spine* 1981;6:125.
- Hinkle CL: The effect of roentgen rays upon the growing long bones of albino rats: quantitative studies of the growth limitation following radiation. *AJR Am J Roentgenol* 1942;47:439.
- Huntington CF, Murrell WD, Betz RR, et al: Comparison of thoracoscopic and open thoracic discectomy in a live ovine model for anterior spinal fusion. *Spine* 1998;23:1699.
- Ippolito E, Ponseti IV: Juvenile kyphosis: histological and histochemical studies. *J Bone Joint Surg* 1981;63-A:175.
- Johnston CE II, Hakala MW, Rosenberger R: Paralytic spinal deformity: orthotic treatment in spinal discontinuity syndromes. *J Pediatr Orthop* 1982;2:233.
- Johnston CE II: The return of the threaded rod in spinal surgery. Scientific exhibit presented at the 33rd annual meeting of the Scoliosis Research Society, New York, 1998.
- Jones ET, Hensinger RN: Spinal deformity in individuals with short stature. *Orthop Clin North Am* 1979;10:877.
- Kharrat K, Dubouset J: [Progressive anterior vertebral fusion in children]. *Rev Chir Orthop Reparatrice Appar Mot* 1980;66:485.
- King J, Stowe S: Results of spinal fusion for radiation scoliosis. *Spine* 1982;7:574.
- Kobrine AI, Evans DE, Rizzoli HV: Relative vulnerability of the brain and spinal cord to ischemia. *J Neurol Sci* 1980;45:65.
- Kumar SJ, Guille JT: Marfan syndrome. In Weinstein SL (ed): *The Pediatric Spine*, p 665. New York, Raven Press, 1994.
- Lonstein JE: Postlaminectomy deformities: thoracic and lumbar spine. In Bridwell KH, DeWald RL (eds): *The Textbook of Spinal Surgery*, p 1055. Philadelphia, Lippincott-Raven, 1997.
- Lonstein JE: Post-laminectomy kyphosis. *Clin Orthop* 1977;128:93.
- Lowe TG: Double L-rod instrumentation in the treatment of severe kyphosis secondary to Scheuermann's disease. *Spine* 1987;12:336.
- Lowe TG: Scheuermann's disease. In Bridwell KH, DeWald RL (eds): *The Textbook of Spinal Surgery*. Philadelphia, Lippincott-Raven, 1997.
- Mack MJ, Regan JJ, Bobechko WP, et al: Application of thoracoscopy for diseases of the spine. *Ann Thorac Surg* 1993;56:736.
- McAfee PC, Regan JR, Zdeblick T, et al: The incidence of complications in endoscopic anterior thoracolumbar spinal reconstructive surgery: a prospective multicenter study comprising the first 100 consecutive cases. *Spine* 1995;20:1624.
- Michel CR, Caton J: Etude des resultats a long terme d'une serie de cyphoses regulieeres traitees pariorset de Livet a charniers. Presented at the reunion of the Groupe d'Etude de la Scoliose, Aix-en-Provence, 1978.
- Montgomery SP, Erwin WE: Scheuermann's kyphosis: long-term results of Milwaukee braces treatment. *Spine* 1981;6:5.
- Murray PM, Weinstein SL, Spratt KF: The natural history and long-term follow-up of Scheuermann kyphosis. *J Bone Joint Surg* 1993;75-A:236.
- Newton PO, Cardelia JM, Farnsworth CL, et al: A biomechanical comparison of open and thoracoscopic anterior spinal release in a goat model. *Spine* 1998;23:530.

53. Newton PO, Wenger DR, Mubarak SJ, et al: Anterior release and fusion in pediatric spinal deformity: a comparison of early outcome and cost of thoracoscopic and open thoracotomy approaches. *Spine* 1997;22:1398.
54. Panjabi MM, White AA III, Johnson RM: Cervical spine mechanics as a function of transection of components. *J Biomech* 1975;8:327.
55. Pinto WC, Avanzi O, Winter RB: An anterior distractor for the intraoperative correction of angular kyphosis. *Spine* 1978;3:309.
56. Ponte A, Gebbia F, Eliseo F: Nonoperative treatment of adolescent hyperkyphosis: a 30 years experience in over 3000 treated patients. *Orthop Trans* 1990;14:766.
57. Ponte A, Siccardi GL: Scheuermann's kyphosis: posterior shortening procedure by segmental closing wedge resections. *Orthop Trans* 1995;19:603.
58. Raimondi AJ, Gutierrez FA, Di Rocco C: Laminotomy and total reconstruction of the posterior spinal arch for spinal canal surgery in childhood. *J Neurosurg* 1976;45:555.
59. Reidy JA, Lingley JR, Gall EA, et al: The effect of roentgen radiation on epiphyseal growth. II. Experimental studies upon the dogs. *J Bone Joint Surg* 1947;29:853.
60. Riseborough EJ, Grabias SL, Burton RI, et al: Skeletal alterations following irradiation for Wilms' tumor: with particular reference to scoliosis and kyphosis. *J Bone Joint Surg* 1976;58-A:526.
61. Robin GC: The etiology of Scheuermann's disease. In Bridwell KH, DeWald RL (eds): *The Textbook of Spinal Surgery*, p 1169. Philadelphia, Lippincott-Raven, 1997.
62. Robins PR, Moe JH, Winter RB: Scoliosis in Marfan's syndrome: its characteristics and results of treatment in thirty-five patients. *J Bone Joint Surg* 1975;57-A:358.
63. Sachs B, Bradford D, Winter R, et al: Scheuermann kyphosis: follow-up of Milwaukee-brace treatment. *J Bone Joint Surg* 1987;69-A:50.
64. Scheuermann HW: Deforming osteochondritis of spine. *Ugeskr Laeger* 1920;82:385.
65. Shaffer JW, Davy DT, Field GA, et al: Temporal analysis of vascularized and nonvascularized rib grafts in canine spine surgery. *Spine* 1989;14:727.
66. Shikata J, Yamamuro T, Shimizu K, et al: Combined laminoplasty and posterolateral fusion for spinal canal surgery in children and adolescents. *Clin Orthop* 1990;259:92.
67. Shufflebarger HL: Cotrel-Dubouset instrumentation for Scheuermann's kyphosis. *Orthop Trans* 1989;13:90.
68. Smith JR, Martin IR, Shaw DG, et al: Progressive non-infectious anterior vertebral fusion. *Skeletal Radiol* 1986;15:599.
69. Smith R, Davidson JK, Flatman GE: Skeletal effects of orthovoltage and megavoltage therapy following treatment of nephroblastoma. *Clin Radiol* 1982;33:601.
70. Sørensen HK: *Scheuermann's Juvenile Kyphosis*. Copenhagen, Munksgaard, 1964.
71. Speck GR, Chopin DC: The surgical treatment of Scheuermann's kyphosis. *J Bone Joint Surg* 1986;68-B:189.
72. Sponseller PD, Hobbs W, Riley LH 3rd, et al: The thoracolumbar spine in Marfan syndrome. *J Bone Joint Surg* 1995;77-A:867.
73. Stagnara P: Cyphoses thoraciques regulieres pathologiques. In Gaggi A (ed): *Modern Trends in Orthopaedics*, p 268. Bologna, A. Gaggi, 1982.
74. Stevens JM, Kendall BE, Crockard HA, et al: The odontoid process in Morquio-Brailsford's disease: the effects of occipitocervical fusion. *J Bone Joint Surg* 1991;73-B:851.
75. Sturm PF, Dobson JC, Armstrong GW: The surgical management of Scheuermann's disease. *Spine* 1993;18:685.
76. Tachdjian MO: Posture and postural defects. In Tachdjian MO (ed): *Tachdjian's Pediatric Orthopaedics*, vol 3, p 2186. Philadelphia, WB Saunders Co, 1990.
77. Tachdjian MO, Matson DD: Orthopaedic aspects of intraspinal tumors in infants and children. *J Bone Joint Surg* 1965;47-A:223.
78. Tandon V, Williamson JB, Cowie RA, et al: Spinal problems in mucopolysaccharidosis I (Hurler syndrome). *J Bone Joint Surg* 1996;78-B:938.
79. Taylor LJ: Severe spondylolisthesis and scoliosis in association with Marfan's syndrome: case report and review of the literature. *Clin Orthop* 1987;221:207.
80. Taylor TC, Wenger DR, Stephen J, et al: Surgical management of thoracic kyphosis in adolescents. *J Bone Joint Surg* 1979;61-A:496.
81. Tolo VT: Spinal deformity in skeletal dysplasia conditions. In Bridwell KH, DeWald RL (eds): *The Textbook of Spinal Surgery*, p 307. Philadelphia, Lippincott-Raven, 1997.
82. Travaglini F, Conte M: Cifosi 25 anni dopo. In Gaggi A (ed): *Progressi in Patologia Vertebrale*. Bologna, Le Cifosi, 1982.
83. Vauzelle C, Stagnara P, Jouvinroux P: Functional monitoring of spinal cord activity during spinal surgery. *Clin Orthop* 1973;93:173.
84. Vellodi A, Young EP, Cooper A, et al: Bone marrow transplantation for mucopolysaccharidosis type I: experience of two British centres. *Arch Dis Child* 1997;76:92.
85. Wallace WH, Shalet SM, Morris-Jones PH, et al: Effect of abdominal irradiation on growth in boys treated for a Wilms' tumor. *Med Pediatr Oncol* 1990;18:441.
86. Wenger DR: Roundback. In Wenger DR, Rang M (eds): *The Art and Practice of Children's Orthopaedics*, p 422. New York, Raven Press, 1993.
87. Winter RB: Severe spondylolisthesis in Marfan's syndrome: report of two cases. *J Pediatr Orthop* 1982;2:51.
88. Winter RB: Thoracic lordoscoliosis in Marfan's syndrome: report of two patients with surgical correction using rods and sublaminar wires. *Spine* 1990;15:233.
89. Yasuoka S, Peterson HA, Laws ER Jr, et al: Pathogenesis and prophylaxis of postlaminectomy deformity of the spine after multiple level laminectomy: difference between children and adults. *Neurosurgery* 1981;9:145.
90. Yasuoka S, Peterson HA, MacCarty CS: Incidence of spinal column deformity after multilevel laminectomy in children and adults. *J Neurosurg* 1982;57:441.