

## Hemiplegia

Hemiplegic children have involvement of the arm and leg on one side of the body [A]. The upper extremity is more severely involved than the lower [B]. Spastic hemiplegia constitutes 20% of cases with spastic CP. These children generally have very few associated problems. Communication is unimpaired most of the time. They may have seizures, learning and behavioural problems. Functional prognosis is good compared to other types because one side of the body is normal. All hemiplegic children learn to walk by the age of three. They become independent in the activities of daily living. Seizures, mild mental retardation, learning difficulties and behavioural disturbances may complicate the management and integration into the society.

### Common musculoskeletal problems

The shoulder is adducted and internally rotated, the elbow is flexed and pronated, the wrist and fingers are flexed, the thumb is in the palm. The hip is flexed and internally rotated, the knee is flexed or extended, the ankle is in plantar flexion. The foot is generally in varus, although valgus deformity may also be seen. The hemiplegic side is short and atrophic depending on the severity of involvement [C].

Treatment consists of physiotherapy, occupational therapy, bracing, botulinum toxin injections and orthopaedic surgery [D]. Some children may need speech therapy and antiepileptic medication.

### Physiotherapy & occupational therapy

Motor problems of the hemiplegic child are usually mild. Physiotherapy is prescribed to prevent contractures of the involved side, to strengthen the weak muscles, to enable functional use of the upper extremity and to establish a better walking pattern.

The basic program for the lower extremity consists of hip, knee, ankle range of motion exercises; rectus femoris, hamstring and gastrocnemius muscle stretching and agonist muscle strengthening. Do not neglect the back extensors and pelvic girdle muscles. Prescribe occupational therapy to gain hand function. Activities that involve both hands may improve the use of the involved side. Inhibiting the sound extremity and forcing the involved one to work is a novel method called constraint induced therapy. This method has certain beneficial effects but it is frustrating for most children.

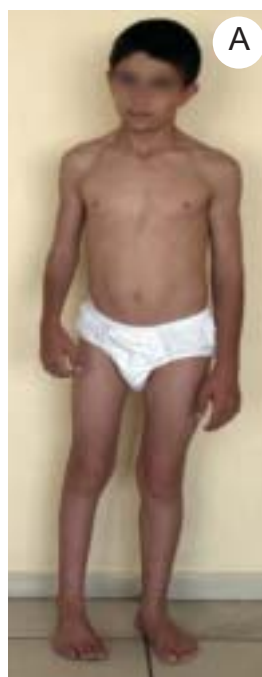Children with hemiplegia do not need physiotherapy for ambulation. Prognosis for independent walking is very good. Physiotherapy is beneficial to prevent contractures of the ankle. In most of the cases the physiotherapy and occupational therapy can be accomplished on an outpatient basis or home program.

### Botulinum toxin A

Botulinum toxin injections are used for upper and lower extremity spasticity in the young child [E]. The toxin reduces gastrocnemius-soleus and rectus femoris spasticity in the lower extremity. The child uses his braces more efficiently and may develop a better walking pattern. Early relief of spasticity may prevent shortening of the gastrocnemius muscle and delay or eliminate the need for surgical intervention.

In the upper extremity, inject botulinum toxin to relax wrist, finger and thumb flexors so that the child may gain forearm supination and wrist stabilization.

Relaxing the spastic muscles with botulinum toxin injections may aid the treatment team to visualize how the child will function when his spastic muscles are surgically lengthened. However, the toxin cannot show its real effect in some older children with already shortened muscles.



Typical problems of the hemiplegic child consist of difficulty using the hand, walking on tiptoes and falling frequently.

### Musculoskeletal problems in hemiplegia

Musculoskeletal problems in hemiplegia			
Upper extremity		Lower extremity	
Shoulder	Internal rotation Adduction	Hip	Flexion Internal rotation
Elbow	Pronation Flexion	Knee	Flexion Extension
Wrist	Flexion	Ankle	Plantar flexion
Hand	Flexion Thumb-in-palm	Foot	Varus

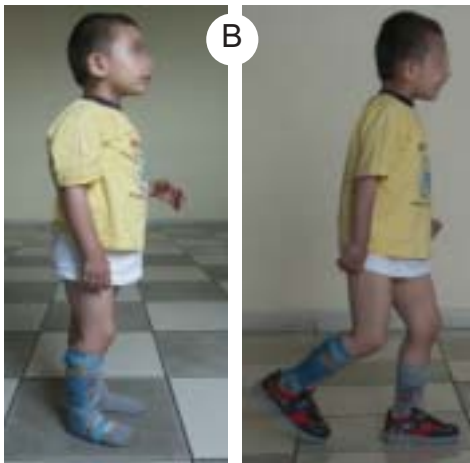### Treatment in hemiplegia

Treatment in hemiplegia	
<i>Physiotherapy</i>	Prevent contractures Strengthen weak muscles Establish a better walking pattern
<i>Occupational therapy</i>	Functional use of upper extremity Activities of daily living
<i>Bracing</i>	Lower extremity Solid or hinged AFOs  Upper extremity Functional or resting hand splints
<i>Botulinum toxin A</i>	Lower extremity Rectus femoris and gastroc spasticity  Upper extremity Pronator flexor spasticity
<i>Orthopaedic surgery</i>	Correction of Pes equinovarus Stiff knee Femoral anteversion

### Botulinum toxin A injections in hemiplegia

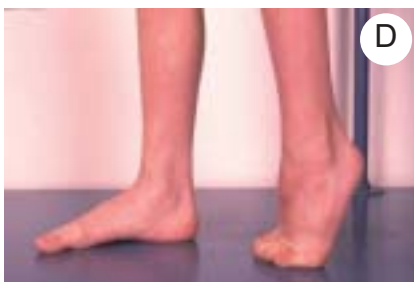Location	Problem	Muscle	Dose units/kg bw
Upper extremity	Elbow flexion	Biceps	2
	Forearm pronation	Pronator teres	1
		Flexor carpi radialis	2
	Wrist flexion	Flexor carpi ulnaris	2
		Flexor digitorum sup	2
	Finger flexion	Flexor digitorum prof.	2
Thumb in palm	Adductor pollicis	0,5	
Lower extremity	Rectus femoris	Stiff knee	3-6
	Gastrocnemius	Pes equinus	3-6
	Tibialis posterior	Pes varus	1-3

Type of brace	Indication
Solid AFO	Equinus and equinovarus
AFO in 5° dorsiflexion	Equinus & genu recurvatum
Hinged AFOs	Equinus and equinovarus if the child: can tolerate the hinge has varus-valgus control has 5° passive dorsiflexion
Supramalleolar orthoses (SMO)	Mild varus - valgus deformity without equinus



The AFO provides stability in stance and foot clearance in swing.

The foot in hemiplegia
Pes equinus, pes varus & combination
In isolation or with knee & hip problems
Watch the child walk
Examine passive range of motion
Test for flexibility
Examine active range of motion
Gait analysis & pedobarography



Neglected gastrocnemius spasticity results in fixed pes equinus deformity.

Causes of pes equinus
Gastrocnemius spasticity
Soleus spasticity

Pes equinus results in
Inadequate toe clearance during swing
Instability in stance
Short step length
Callosities
Difficulty with footwear

Botulinum toxin may be combined with surgery in the older child. Inject muscles which have mild spasticity and no shortening with Botulinum toxin and surgically lengthen the severely spastic short muscles. This combination approach adopted in the recent years enables a swifter return of function, less complications and less muscle weakness because of less extensive orthopaedic surgery.

**Bracing**

**Upper extremity bracing**

There are two indications for hand splints in hemiplegia. One is to prevent deformity and the other is to improve function. Night splints help stretch muscles and maintain range of motion. Tone usually decreases at night, therefore the use of resting splints at night to prevent deformity is questionable. The child's compliance with night splints is generally poor.

Use day splints to increase function by either supporting the wrist in 10° extension, the thumb in opposition or both. Keep in mind that day splints prevent sensory input in the already compromised hand.

**Lower extremity bracing [A]**

AFOs stabilize the ankle and foot and keep it in the plantigrade position for weight bearing [B]. They are set in 5° dorsiflexion to avoid genu recurvatum or at neutral to prevent knee flexion. If the foot remains fixed the child has to extend the knee. Correct all fixed contractures before giving braces. Use hinged AFOs for mono and hemiplegic patients especially when they have active dorsiflexion.

**Orthopaedic surgery**

The usual indications for surgery are pes equinus, pes varus and stiff knee. Thumb-in-palm and wrist flexion deformity also respond to surgery. Perform soft tissue procedures around 5-6 years of age. Wait until at least 8 years of age for bone procedures unless the deformity is causing a functional problem.

Delay upper extremity surgery for function (age 6 to 12) until the child is mature enough to cooperate with postoperative rehabilitation.

**The foot**

The common problems of the foot in hemiplegia are pes equinus and varus. They often occur in combination with each other and with knee problems [C]. Evaluate the hips, knees and feet as a whole when examining the lower extremity.

**Pes equinus**

Pes equinus is ankle plantar flexion during gait [D] that occurs because of gastrocnemius-soleus spasticity. It may be dynamic or static. Dynamic equinus occurs only during walking secondary to gastrocnemius spasticity. Passive ankle dorsiflexion is not limited. When the gastrocnemius-soleus muscle is short, passive ankle dorsiflexion is limited and static pes equinus occurs [E].

The child with pes equinus bears body weight on the metatarsals. Callosities occur in adolescents and adults. Step length is short, toe clearance in swing is inadequate and the ankle is unstable. Sometimes the discrepancy caused by pes equinus may result in pelvic obliquity [F].

**Stretching and corrective casting** Treat children younger than age 5 with stretching exercises and corrective casting. Apply corrective casts for 2 or more consecutive sessions for 3 weeks in dynamic and mild static contractures. Consider injecting botulinum toxin prior to casting to improve the results. Always prescribe stretching exercises and plastic AFOs after casting. Make sure that the corrective force is applied at the ankle joint during casting. If the cast does not fit properly, the force stresses the midfoot and causes rocker bottom deformity.

**Botulinum toxin** Botulinum toxin is the treatment of choice in very young children with gastrocnemius spasticity, recommended as a time-buying agent in children who are not suitable for surgery. Inject botulinum toxin into the spastic gastrocnemius muscle in a dose of 6 - 10 units per kilogram. Do not exceed 50 units per injection site. Apply a cast or use a full time solid AFO after the injection to improve and lengthen the effect. Relief of spasticity may result in a better gait pattern in young children.

**Surgical treatment** Consider surgical treatment in children who have walking difficulty because of a dynamic or static contracture [A]. Lengthen the gastrocnemius muscle by selectively incising its tendon through a full thickness transverse cut at the musculoskeletal junction as it combines with the soleus. Warren-White or Hoke are two different techniques advised to perform this operation. Lengthen the Achilles tendon if there is soleus contracture as well. Cut the Achilles tendon percutaneously by multiple partial tendon incisions and then dorsiflex the ankle with the knee in extension to allow the cut portions to slide in place. Try Z-lengthening in older and neglected cases where the tendon is markedly short.

Try and gain at least 15-20° dorsiflexion at the ankle. Put the child in a short leg cast with 5° dorsiflexion. Never cast in excessive dorsiflexion.

**Postoperative care** Keep the child in a short leg cast for 3 weeks. Use the cast up to 6 weeks for older children or after Z-lengthening. Begin ambulation as early as 2-3 days after surgery. Allow full weight bearing with crutches. Put the patient in AFOs right after cast removal and have him wear it night and day. Discard the brace during the day and use it as a night splint only after 3 months in children with good voluntary tibialis anterior function. Recurrence is high in patients with no voluntary tibialis anterior function. They must use their brace until they gain active dorsiflexion [B]. A pedobarography is useful to evaluate the outcome [C].

**Complications** of pes equinus surgery are rare [D]. There is a 25% risk of recurrence because of weakness of tibialis anterior muscle and also to skeletal growth. Recurrence risk increases in cases who have inadequate lengthenings or do not wear braces [E]. Patients younger than 5 years of age have a high risk of recurrence. Excessive lengthening of the triceps surae causes pes calcaneus deformity and the push-off is weakened.

### Pes varus

Pes varus is characterized by increased inversion and exaggerated weight bearing on the lateral margin of the foot [F]. The causes are tibialis anterior, tibialis posterior and triceps surae spasticity with peroneal muscle weakness [G]. The more common tibialis posterior spasticity causes hindfoot varus and tibialis anterior spasticity causes midfoot varus. Pes equinus usually accompanies pes varus, pure varus is relatively rare. The hemiplegic child with increased femoral anteversion or internal tibial torsion has intoeing gait that looks like varus.

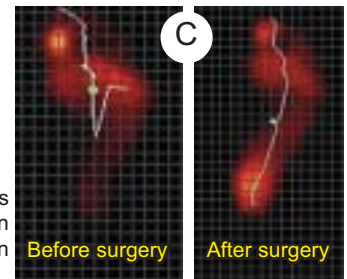
Varus over 10° causes problems with foot clearance during swing and stability in stance. Older children have difficulty wearing shoes. Callosities form under the fifth metatarsal [H].

**Stretching and corrective casting** Treat flexible pes varus with stretching exercises and braces. Inject botulinum toxin into the spastic tibialis posterior to decrease spasticity and achieve foot alignment with a brace. Perform the injection with EMG or electrical stimulation guide to localize the deep lying tibialis posterior muscle. Inject the gastrocnemius and soleus at the same session. Varus deformity tends to worsen after 5-6 years of age in many patients. Consider surgical treatment if the deformity becomes fixed.

A Surgical options for pes equinus	
Silfverskiöld test negative	Gastrocnemius lengthening
Silfverskiöld test positive	Achilles tendon lengthening
Severe neglected equinus	Posterior capsulotomy*

\* Combine with Achilles tendon lengthening

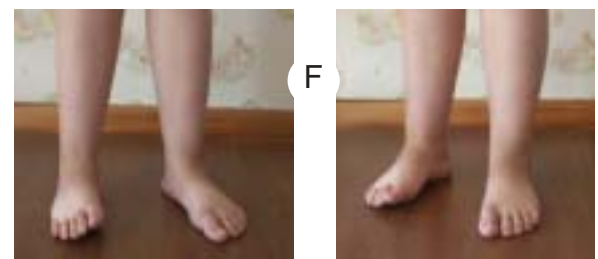B Postoperative care: Pes equinus surgery	
Cast	3 weeks in young child 6 weeks in older child
Ambulation	2 - 3 days
Weight bearing	Full
Brace	Until active dorsiflexion appears



Pedobarography shows the pressure distribution of the foot and is useful in evaluating pes equinus.

D Complications of pes equinus surgery	
Recurrence	
Excessive lengthening	
Pressure sores	

Causes of recurrence after pes equinus surgery	
E Weak tibialis anterior	
Musculoskeletal growth	
Inadequate lengthening	
Noncompliance with the brace	
Early surgery (age < 5 years)	
Z - lengthening	



The muscle responsible for pes varus may be difficult to determine on physical examination.

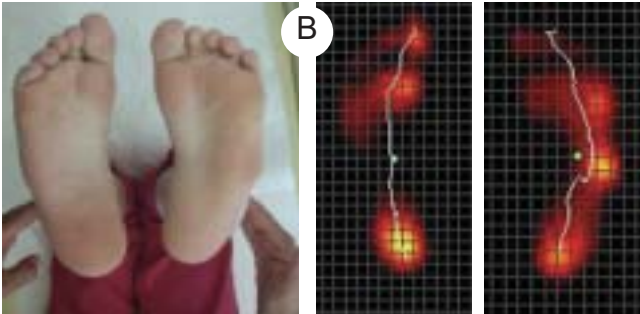
G Causes of the varus foot	
Tibialis posterior spasticity	Hindfoot varus
Tibialis anterior spasticity	Midfoot varus
Triceps surae spasticity	Ankle varus

H Pes varus results in	
Poor foot clearance during swing	
Instability in stance	
Difficulty with footwear	
Painful callosities	
Cosmetic problems	

**Surgical options for pes varus**

A

- \*Split tibialis anterior muscle transfer
- \*Tibialis posterior lengthening
- Split tibialis posterior muscle transfer
- Achilles tendon lengthening
- Calcaneal osteotomy
- Triple arthrodesis
- \* These two operations are usually combined.



Pure varus deformity results in excessive weight bearing on the lateral margin of the foot. The increased load on the lateral aspect of the foot can be detected by pedobarography.



Pes varus and pes equinus frequently occur together.

**The knee in hemiplegia**

D

Problem	Definition	Cause
Flexed knee	Flexion in stance	Hamstring spasticity
Genu recurvatum	Hyperextension in stance	Rectus femoris spasticity Pes equinus Hamstring weakness
Stiff knee	Decreased flexion during gait	Rectus femoris spasticity



Genu recurvatum is generally secondary to pes equinus. Rectus femoris spasticity contributes to the problem.

**Treatment of genu recurvatum**

F

Pes equinus	Gastrocnemius lengthening
Rectus femoris spasticity	Rectus femoris lengthening or transfer

**Surgical treatment** Correct muscle imbalance in young children before bony deformities develop. The choice of surgical method depends on the involved muscle [A].

The tiptoe test is a good method to evaluate the posterior tibialis muscle. Ask the child to walk on his toes. Because the tibialis anterior does not contract during tiptoe walking, persistence of varus shows spasticity of the tibialis posterior muscle.

Another method of evaluating these two muscles is dynamic EMG. It is not used a lot in the young child because the EMG needles inserted into the muscles disturb the child's gait.

Pedobarography may also help determine the true cause of equinovarus [B]. Overactivity of the tibialis posterior will cause more weight bearing on the fifth metatarsal whereas overactivity of the tibialis anterior will cause a cavus weight bearing pattern with increased pressure over the first and fifth metatarsals.

**Soft tissue surgery** Lengthen the tibialis posterior muscle at the musculotendinous junction and perform a split transfer of the tibialis anterior tendon (SPLATT).

Do a split transfer of the posterior tibialis tendon (SPLOTT) if the tibialis anterior muscle is weak, or when there is posterior tibialis contraction during swing. This operation preserves plantar flexion force and replaces weak peroneals. Results may not be optimal though recurrence is rare.

Combine triceps lengthening with other soft tissue surgeries if the triceps muscle is short [C].

**Bone surgery** There is a need for bone surgery in children with bony deformity. Wait until the child is 7 - 8 years old for a calcaneal osteotomy. Combine calcaneal osteotomy with tendon surgery to achieve satisfactory correction. Triple arthrodesis is an option for severe deformities in older children. Do not perform triple arthrodesis before 15 years of age. Postoperative care is similar to pes equinus.

**The knee**

Common knee problems in hemiplegia are flexed knee, genu recurvatum and stiff knee [D].

**Flexed knee**

The predominant pattern in hemiplegia is the flexed knee that is usually associated with triceps and hamstring spasticity. Use an AFO for mild cases, combine with botulinum toxin injections to the hamstrings if necessary. In older children and in severe cases lengthen the hamstrings surgically.

**Genu recurvatum**

Genu recurvatum is defined as knee hyperextension during stance. It occurs secondary to pes equinus, spasticity of rectus femoris, hamstring weakness or their combinations [D].

**Conservative treatment** Consider botulinum toxin injection to rectus femoris and gastrocnemius-soleus muscles. A plastic hinged or solid AFO with plantar flexion stop set at 5° - 7° dorsiflexion may prevent genu recurvatum [E].

**Surgical treatment** Depending on the etiology, lengthen the triceps surae and/or the rectus femoris. Rectus femoris transfer to medial hamstrings is another option [F].

**Stiff knee**

Stiff knee gait is defined as decreased knee flexion (less than 30°) during the gait cycle. The cause of stiff knee gait is rectus femoris spasticity. The spastic rectus femoris contracts during the swing phase and prevents the knee from going into flexion. Treatment is often difficult. Try botulinum toxin injections to the spastic rectus femoris. Lengthen or transfer the rectus femoris to the medial hamstring if necessary.

**The hip**

Hip problems are not common in hemiplegic children. Hip subluxation is extremely rare. Some children have a flexion-adduction and internal rotation deformity. Persistent femoral anteversion causes hip internal rotation and intoeing gait [A]. Internal rotation of the extremity disturbs foot clearance, the child may trip over his foot and fall. Children with intoeing develop a compensatory dynamic equinus that can be mistaken for gastrocnemius spasticity.

Consider lengthening the iliopsoas and adductor muscles and performing proximal or distal femoral rotation osteotomies according to the patients' needs. Correct a compensatory tibial external rotation with a distal tibial osteotomy during the same operation.

**Limb length discrepancy**

Almost all hemiplegic children have slight atrophy and shortening of the involved lower extremity [B,C]. The discrepancy is generally less than 15 mms. Shoe inserts or surgery are not necessary. On the contrary, having a slightly shorter leg on the involved side helps toe clearance during swing. Consider a shoe insert in a discrepancy of over 15 mm to prevent pelvic obliquity.

**Management of hemiplegic gait**

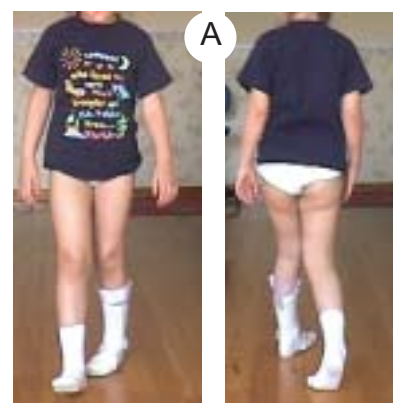There are four types of hemiplegic gait [D].

Type 1: There is weakness of the tibialis anterior and an adequate gastrocnemius-soleus length. The child shows foot drop in the swing phase. Use a hinged AFO allowing free dorsiflexion.

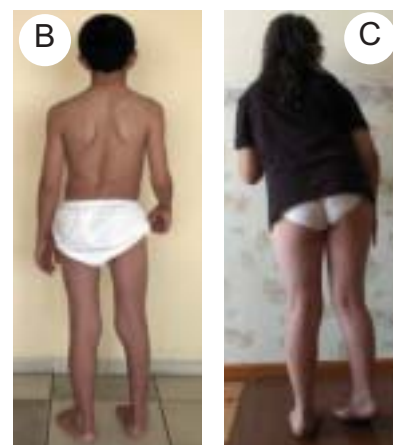Type 2: Gastrocnemius-soleus muscle is short in addition to tibialis anterior weakness. The child compensates with knee hyperextension in midstance [E]. Inject botulinum toxin to the gastrocnemius-soleus complex if the deformity is dynamic. If static, serial casting or surgery are options. Use hinged AFOs after surgery.

Type 3: There is persistent knee flexion in stance phase and decreased knee motion in swing phase in addition to the above findings. This is defined as stiff knee gait. The treatment should include hamstring lengthenings to treat knee flexion if they are active during swing as well as rectus femoris transfers to semitendinosus to treat decreased knee motion in swing.

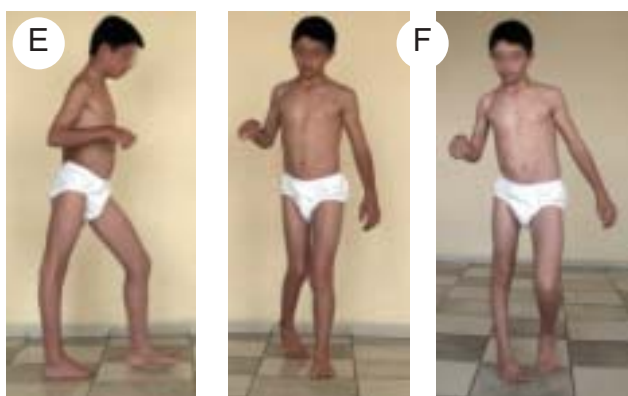
Type 4: There is adduction and flexion of the hip in addition to the findings above [F]. Lengthen the hip adductors and flexors if necessary. Bony deformities such as excessive internal femoral rotation and tibial torsion may also be seen. Treat bony deformities with appropriate rotational osteotomies [G].



Femoral anteversion causes hip internal rotation and intoeing gait.

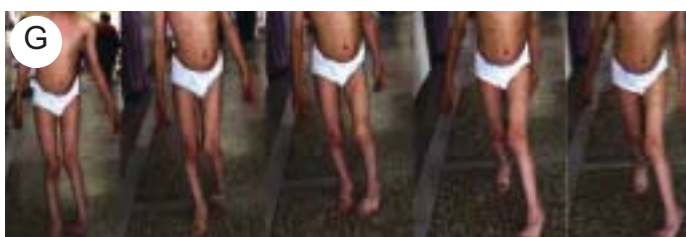

Limb length discrepancy is common, may cause pelvic obliquity and secondary scoliosis.



Hemiplegic gait is characterised by pes equinus, genu recurvatum, internal femoral rotation and hip adduction.

Hemiplegic gait (According to Winters & Gage)			
Type	Problem	Result	Treatment
I	Weak tibialis anterior Adequate gastroc-soleus	Foot drop in swing	Hinged AFO Allowing free dorsiflexion
II	Weak tibialis anterior Short gastroc-soleus	Foot drop in swing Genu recurvatum	Botulinum toxin to gastrocnemius Serial casting Surgery Hinged AFOs
III	In addition to above: Persistent knee flexion Decreased knee motion in swing	In addition to above: Stiff knee Knee flexion	In addition to above: Lengthen hamstrings Transfer rectus femoris to semitendinosus
IV	In addition to above: Hip adduction, flexion & internal femoral rotation	In addition to above: Intoeing	In addition to above: Release at the hip Derotation osteotomy



Rotational osteotomies maybe necessary to correct the excessive internal rotation in hemiplegia.

<b>A</b>	<b>Upper extremity problems</b>
	Lack of voluntary control
	Poor hand-eye coordination
	Sensory loss
	Astereognosis
	Spasticity
	Dystonia
	Weakness
	Contractures
	Joint instability

<b>B</b>	<b>Common deformities of the upper extremity</b>	
Shoulder		Internal rotation, adduction
Elbow		Flexion
Forearm		Pronation
Wrist		Flexion
Fingers		Flexion, ulnar deviation, swan neck
Thumb		Adduction, flexion



Spasticity and loss of selective motor control prevent positioning the upper extremity and manipulating objects with the hand.



Evaluate the hand using toys and simple every day tools. Determine the missing function and work towards mastering that.

<b>Resting splints to prevent deformity</b>		<b>F</b>
Resting hand splint	Wrist: 30° extension, Metacarpophalangeal joints: 60° flexion Interphalangeal joints: neutral position Thumb: opposition	
Ball abduction splint	Thumb abduction & opposition	

<b>Splints to improve function</b>		<b>G</b>
Wrist cock-up splint	Wrist: 30° extension Thumb: abduction Finger movement free	
Soft thumb loop splint	Thumb: out of the palm	
Opponens splint	Thumb: abduction & opposition Wrist: 30° extension	

**Upper extremity**

Lack of voluntary control, sensory impairment, muscular imbalances caused by spasticity and weakness, joint contractures, and articular instabilities all contribute to the upper extremity problem in CP [A]. The child has difficulty using the hand. The shoulder is in internal rotation and adduction, elbow in flexion, forearm in pronation, wrist in flexion and ulnar deviation, and thumb in adduction and flexion (thumb-in-palm) [B]. These deformities cause loss of function, but being unilateral they do not compromise the activities of daily living a lot. The child cannot position the hand in space, grasping an object and letting go are difficult [C,D]. Children with hemiplegia have a normal upper extremity that they use in daily life. They ignore the plegic side. This neglect reinforces the impairment, inhibits the development of hand-eye coordination and prevents function in the involved extremity. The child learns not to use his involved hand even if he has the potential.

The aim of treatment is to increase function, improve hygiene and cosmesis. The hand is a tool also for social communication. Even minor improvements in hand cosmesis increase the patient's self esteem and social status.

**Physical and occupational therapy**

Physical therapy and occupational therapy are useful to improve movement quality and range of motion. Range of motion and strengthening exercises as well as neurofacilitation methods are part of treatment. Activities involving the use of both hands improve function. Provide adequate sensory stimulation to develop better hand control [E].

Inhibiting the normal extremity by bracing or casting and forcing the plegic one to work may be useful in the young child during the period of the development of hand-eye coordination.

**Bracing**

The effects of bracing are unclear. Night splints in functional position may promote lengthening of muscle-tendon units and prevent deformity. However most children sleep with a completely relaxed arm and extended hand which make night splints seem useless [F]. Neoprene thumb splints to keep the thumb out of the palm or thermoplastic wrist extension splints are commonly used during the day [G].

**Local anesthetic and botulinum toxin blocks**

Local anesthetic blocks are used to determine the presence of a contracture and to assess power in the antagonist muscles. Block the median nerve at the elbow to relax the flexor muscles in the forearm. Spastic muscles will relax completely after the median nerve block. If the wrist or the fingers remain flexed after the local anesthetic injection, this indicates a fixed contracture and will benefit only from surgery.

Check for active muscle contraction in the antagonist muscles. The presence of voluntary wrist and finger extension after the block indicates better functional prognosis after botulinum toxin injections or surgery to relieve flexor spasticity.

Dynamic contracture caused by spasticity responds well to botulinum toxin injections. This method is particularly valuable in the young child from age 2 to 6 years because relief of spasticity allows him to use the hand better. This may permanently improve hand function, sensation and hand-eye coordination. The dose is 1-2 units per kilogram of body weight per muscle. EMG or electrical stimulation guide is beneficial to target the spastic muscles, but this is a painful technique and requires conscious sedation or general anesthesia in most children except the very bright and courageous. Because botulinum toxin effects are temporary, consider surgical intervention in the older child for definitive treatment.

## Surgery

Upper extremity surgery can improve hand function in a few selected cases [A]. The ideal surgical candidate must be a motivated, intelligent child who has good sensation in the hand and uses the extremity. Those children with satisfactory hand-eye coordination can benefit from surgery even when hand sensation is poor.

The surgeon must be careful in patient selection because some children develop adaptive mechanisms to compensate for lost hand movements as they grow. Functional loss occurs after surgery in such patients because surgery prevents the adaptive movements they developed over the years.

Consider surgery between 6- 12 years of age when the child will cooperate with postoperative rehabilitation. Set goals that fit with the expectations of the child and the parents.

**The shoulder** Adduction - internal rotation contracture is the most common problem. Provide a program of stretching exercises. Consider surgical lengthening of the muscles if the deformity is severe.

**The elbow** Flexion contractures of more than 45 are functionally disabling. Try botulinum toxin injection to elbow flexors and stretching exercises in dynamic deformities and even for cosmetic reasons. Consider surgery for elbow only if the hand is functional, if there is skin breakdown at the elbow or if hygiene in the antecubital fossa is poor. Deformities greater than 60° require surgical lengthening of the biceps tendon, be aware of the fact that this procedure worsens the forearm pronation deformity. Maximum range of motion is gained 3 months postoperatively.

**Forearm** The main problem is a pronation contracture because of spasticity in the pronator teres and pronator quadratus muscles [B]. Activities that require supination like grasping a walker or a cane, balancing objects in the palm, washing the face are impossible. Severe pronation causes radial head dislocation but it is generally painless and does not cause functional problems.

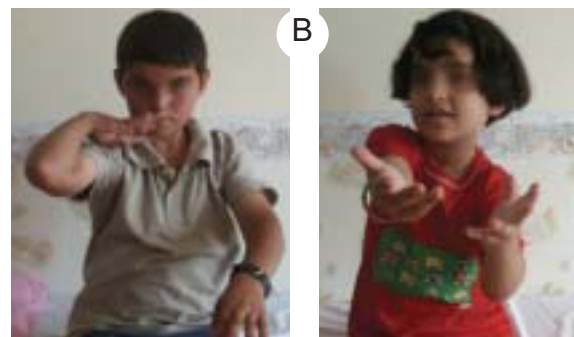Consider pronator teres transfer to the supinator if the child can voluntarily pronate the forearm. Pronator release gives satisfactory results if the child has active supination. Long-standing pronation contracture of the forearm leads to relative shortening of the biceps aponeurosis. Release this structure to allow the biceps to be a more effective supinator [C].

**Wrist** The wrist usually is held in a position of flexion and ulnar deviation because of flexor carpi radialis and flexor carpi ulnaris spasticity [D, E]. The digital flexors also contribute to wrist flexion. Finger flexors are inefficient and the grasp is weak when the wrist is flexed [F]. Grasping is essential for function. Correct flexion contractures of wrist and fingers and adduction of thumb if they interfere with grasp. Macerations and mycotic infections are common in severe flexion contractures of the hand. Surgery becomes necessary for hygienic purposes.

Options for surgery [G] include wrist flexor lengthening, flexor origin slide, tendon transfer to improve wrist extension, proximal row carpectomy, and wrist fusion with or without carpal shortening [H]. Avoid wrist arthrodesis because the patient loses the tenodesis effect of wrist extension that results in finger flexion and facilitates grasp and release. Consider wrist arthrodesis only to relieve the pain and improve the cosmesis of the hand when there is no or limited hand function.

Wrist and digital flexor muscles can be selectively lengthened distally. Do not release or transfer both flexor carpi ulnaris and radialis as this eliminates active wrist flexion.

A	Before surgery consider
	Voluntary hand use
	Sensation
	Intelligence
	Athetosis

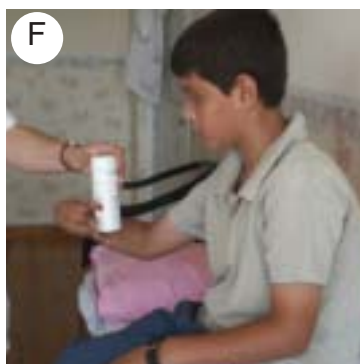

Limitation of forearm supination is a common problem of the hemiplegic upper extremity. It is also one of the most functionally disabling deformities.

C	Surgery for pronation contracture
	Release of lasertus fibrosis
	Release pronator teres insertion
	Pronator teres rerouting
	Flexor-pronator slide
	Pronator quadratus recession




Wrist flexion in hemiplegia may be a combination of spasticity and dystonia.



Wrist flexion impairs the ability to grasp objects and limits the use of the hand.

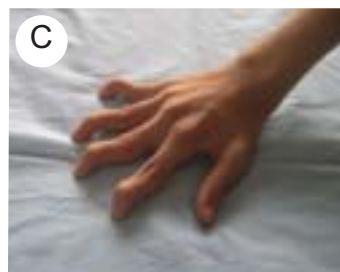G	Treatment of wrist flexion deformity
	Active finger extension at 20° wrist flexion: No need for surgery
	Active finger extension with the wrist over 20° flexion: Flexor releases, augmentation of wrist extensors or flexor carpi ulnaris release.
	No active finger flexion: Finger extensors must be augmented with flexor carpi ulnaris.

H	Indications for wrist arthrodesis
	No wrist control, strong finger flexion and extension
	Severe wrist flexion deformity and weak hand and wrist muscles
	Athetosis or dystonia, when finger function improves by wrist immobilization




**Procedures for finger flexion deformity**

- Flexor-pronator origin release
- Specific lengthening of musculotendinous units (Fractional lengthening or z-lengthening)
- Sublimis to profundus tendon transfer
- Finger flexor transfer for Wrist, finger, or thumb extension



Swan-neck deformity is generally not functionally disabling.



**Thumb-in-palm deformity in a teenager.**

<b>The thumb-in-palm deformity</b>
Simple metacarpal adduction
Metacarpal adduction & metacarpophalangeal joint flexion
Metacarpal adduction with hyperextension instability of the metacarpophalangeal joint
Metacarpal adduction, metacarpophalangeal & interphalangeal joint flexion

<b>Causes of thumb-in-palm deformity</b>
Contracture and spasticity of adductor pollicis, flexor pollicis brevis, flexor pollicis longus and first dorsal interosseous
Contractures of abductor pollicis longus, extensor pollicis brevis & extensor pollicis longus
Hypermobility of thumb metacarpophalangeal joint

<b>Surgical procedures for thumb in palm deformity</b>		
<i>Procedure</i>	<i>Location</i>	<i>Reason</i>
Tendinous insertion Muscular origin Fractional Release or lengthening	Adductor pollicis First dorsal interosseous Flexor pollicis brevis Flexor pollicis longus	Release contracture
Rerouting	Extensor pollicis longus	Augment active thumb abduction & extension
Arthrodesis Capsulodesis	Metacarpophalangeal joint	Stabilization
Four-flap Z-plasty deepening	Skin contracture	Between thumb & index fingers

Consider tendon transfers to augment wrist extension when it is weak or absent. Transfer the flexor carpi ulnaris to extensor digitorum communis when both finger and wrist extension is weak. This transfer improves wrist extension and does not impair finger extension and release.

**Fingers** Finger flexion deformity is a result of spasticity and contracture in the flexor digitorum superficialis and profundus muscles [A]. It becomes more obvious when the wrist and metacarpophalangeal joints are held in neutral position.

Consider surgical intervention when flexion deformity is severe [B]. The flexor-pronator origin release effectively lengthens the flexor digitorum superficialis, pronator teres and flexor carpi radialis. Correct finger flexion deformity by direct Z-lengthening of involved tendons. If there is spasticity of intrinsic hand muscles, releasing the finger flexors will increase the deformity. Excessive lengthening weakens flexor power, impairs grasp, and can produce swan neck deformities. In this case, transfer the flexor digitorum superficialis tendon to augment wrist, finger or thumb extension instead of lengthening.

Swan-neck deformity [C] is hyperextension deformity of the proximal interphalangeal joints. It is because of over-activity of the intrinsic muscles, and increases with the pull of the extensor digitorum communis when the wrist is in flexion. Consider surgical intervention if there is severe hyperextension, or when the proximal interphalangeal joints lock in extension.

**The thumb** The thumb-in-palm deformity [D] is characterized by metacarpal flexion and adduction, metacarpophalangeal joint flexion or hyperextension and usually interphalangeal joint flexion [E]. The causes are spasticity and contracture of the adductor pollicis, first dorsal interosseous, flexor pollicis brevis, and flexor pollicis longus [F]. The extensor pollicis longus, extensor pollicis brevis, and/or abductor pollicis longus are often weak or ineffective. The thumb-in-palm deformity impairs the ability of the hand to accept, grasp, and release objects. The goals of surgery [G] are to release the spastic muscles to position the thumb, to create a balance in the muscles around the thumb, and to provide articular stability for grasp and pinch.

**References**

2004 Koloyan G Adamyan A 'Surgical correction of foot deformities in children with cerebral palsy' Brain&Development 26 S4  
 2004 Taub E, Ramey SL, DeLuca S, Echols K 'Efficacy of constraint-induced movement therapy for children with cerebral palsy with asymmetric motor impairment' Pediatrics 113(2):305-12.  
 2002 Metaxiotis D, Siebel A, Doederlein L. 'Repeated botulinum toxin A injections in the treatment of spastic equinus foot' Clin Orthop 394:177-85  
 2002 Sienko Thomas S, Buckon CE, Jakobson-Huston S, et al 'Stair locomotion in children with spastic hemiplegia: the impact of three different ankle foot orthosis (AFOs) configurations' Gait Posture16(2):180-7.  
 2001 Boyd RN, Morris ME, Graham HK. 'Management of upper limb dysfunction in children with cerebral palsy: a systematic review' Eur J Neurol 8 Suppl 5:150-66  
 2001 Buckon CE, Thomas SS, Jakobson-Huston S, et al 'Comparison of three ankle-foot orthosis configurations for children with spastic hemiplegia' Dev Med Child Neurol.43(6):371-8.  
 2001 Rodda J, Graham HK 'Classification of gait patterns in spastic hemiplegia and spastic diplegia: a basis for a management algorithm Eur J Neurol 8(Suppl 5) 98-108  
 2000 Russman BS. 'Cerebral Palsy' Curr Treat Options Neurol 2(2):97-108.  
 1999 Matthews DJ, Wilson P 'Cerebral Palsy' in Pediatric Rehabilitation 3rd Edition pp: 193-217 Molnar GE, Alexander MA Hanley Belfus Philadelphia  
 1993 Wenger DR, Rang M The Art and Practice of Children's Orthopaedics Raven Press New York  
 1991 Law M, Cadman D, Rosenbaum P, et al 'Neuro-developmental therapy and upper extremity inhibitive casting for children with cerebral palsy' Dev Med Child Neurol, 33:379-387  
 1987 Bleck EE 'Orthopaedic management in cerebral palsy' JB Lippincott Philadelphia  
 1987 Winters TF, Gage JR, Hicks R 'Gait patterns in spastic hemiplegia in children and young adults' J Bone and Joint Surg Am 69:437-441



## Diplegia

Diplegia is defined as gross motor involvement of the lower and fine motor involvement of the upper extremities [A]. Diplegia constitutes 50% of the spastic CP population. Diplegic children have normal mental function and can communicate without difficulty. Their oromotor and gastrointestinal functions are normal. They often have visual perceptual deficits and strabismus. There is a tendency to fall backwards because of poorly developed balance reactions.

The main problem in spastic diplegia is walking difficulty [B]. Balance disturbance, muscle weakness, spasticity and deformities result in abnormal gait patterns typical for diplegic children. Abnormal gait increases energy consumption causing fatigue. Most diplegic children start cruising at two years of age and walk by age four. Neuromotor function improves until age seven. Children who cannot walk by then in spite of appropriate treatment usually become limited walkers.

Among all types of CP diplegic children benefit most from treatment procedures. Unlike hemiplegic children they cannot reach their potential if left untreated. With treatment they may become productive members of the society. Every effort is worth spending when treating a diplegic child [C].

### Physiotherapy and occupational therapy

Positioning, strengthening and stretching exercises preserve joint range of motion, increase strength and help improve gait [D]. Combine physiotherapy with bracing, walking aids and antispastic treatments to facilitate independent walking. The risk of contracture formation increases between ages 4-6 and during the prepubertal growth spurt period when the rapid increase in bone growth is not accompanied by a similar growth in muscle lengths. Relative muscle shortening causes contractures during this period. Biarticular muscles such as psoas, rectus femoris, hamstrings and gastrocnemius are more vulnerable. Intensive physiotherapy is then necessary to prevent contractures.

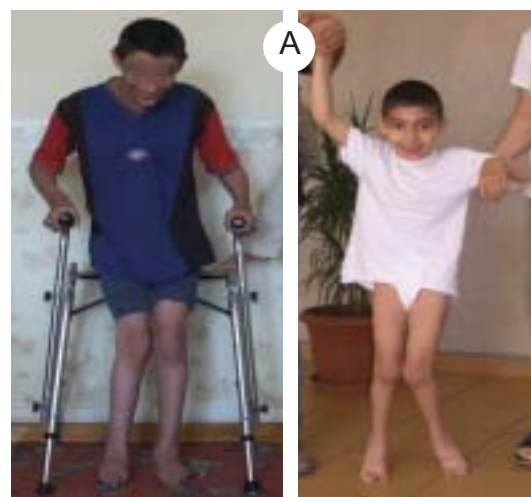Diplegic children should receive physiotherapy until they are preschoolers. Boring exercises should be combined with play activities particularly in toddlers and in noncompliant children. Provide antispastic medications above age 2 if spasticity interferes with mobility and sleep. Time all orthopaedic interventions in the preschooler so that they do not interfere with the child's education. Sports activities and play with peers are essential during school years. Swimming and horseback riding are beneficial for the poorly developed balance reactions of the diplegic. These activities restore a sense of well-being and self-confidence in the child.

Provide occupational therapy to improve hand function if there are obvious coordination problems.

### Botulinum toxin

Botulinum toxin is useful to relieve spasticity of the lower extremities of the young diplegic child. Consider injecting when spasticity becomes an obstacle to mobility and causes contractures. The dose is 4-6 units per kilogram of body weight per muscle [E]. Many muscles need injections, do not exceed a total dose of 400 units in a single injection session. When the necessary dose exceeds 400 units use phenol motor point block to the proximal muscles and botulinum toxin to the distal muscles. It is better to perform multiple muscle injections under general anesthesia or conscious sedation. Use simple local anesthetic creams beforehand for single muscle injections.

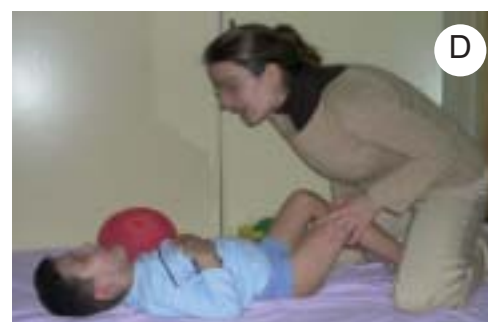Casting after botulinum toxin injections enhances and prolongs the effect. Continue with physiotherapy and bracing. The toxin has a temporary effect, yet it is an important tool to relieve spasticity in the young child when it is too early for orthopaedic surgery. Older



Deficient balance reactions and lower extremity spasticity are the main reasons of walking difficulty in diplegic children.

Musculoskeletal problems in diplegia	
Hip	Flexion, internal rotation and adduction
Knee	Flexion or occasionally extension
Ankle	Equinus, valgus (rarely varus)

Treatment in diplegia	
Physiotherapy	Increase strength Decrease spasticity Prevent contractures Improve gait
Occupational therapy	Improve hand function
Bracing	Solid or hinged AFOs or GRAFOs
Botulinum toxin	Decrease spasticity Hip: flexor/adductor Knee: flexor/extensor Ankle: plantar flexor/peroneal muscles
Orthopaedic surgery	Correct deformities



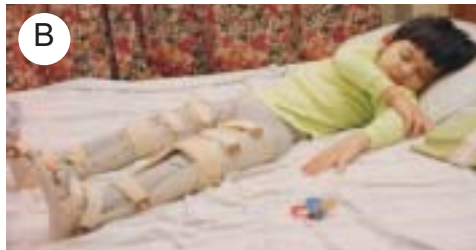Stretching and strengthening exercises are fundamental components of physiotherapy in diplegia.

E	Botulinum toxin A injections in diplegia			
	Jump	Crouch	Scissoring	Stiff knee
Psoas	1 - 2 u	1 - 2 u	1 - 2 u	
Adductors	3 - 6 u		3 - 6 u	
Rectus femoris	3 - 6 u			3 - 6 u *
Medial hamstrings	3 - 6 u	3 - 6 u	3 - 6 u	
Lateral hamstrings	3 - 6 u	3 - 6 u		
Gastrocnemius	3 - 6 u			

The given doses are per kg of body weight. Total dose should not exceed 12 u/kg of body weight or 400 U.  
\*Inject all heads of the quadriceps muscle in stiff knee gait.

Type of brace	Indication
Hinged AFOs	Jump gait & 10° passive ankle dorsiflexion
Solid AFOs	Jump gait & no passive ankle dorsiflexion Crouch gait Severe pes equinovalgus
GRAFOs	Crouch gait
SMOs	Mild valgus-varus deformity & good ankle control

A



Use resting splints only after you reduce spasticity and make sure that the child sleeps well without waking up.

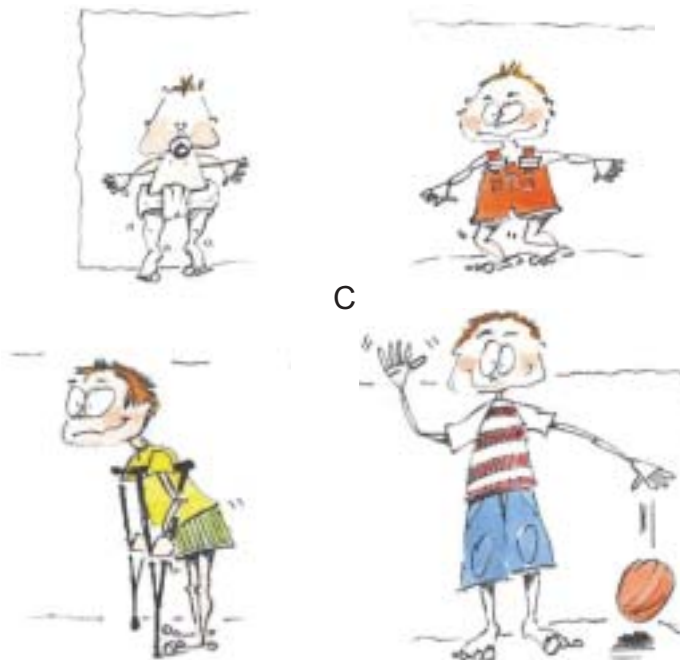
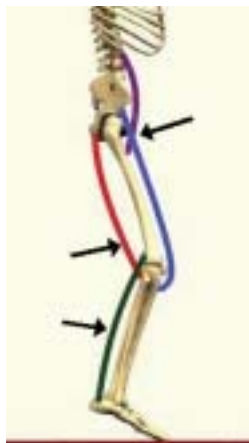
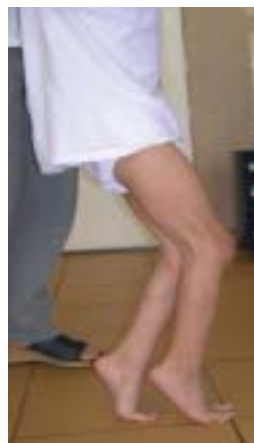

Illustration by Idil Çilingiroğlu

Correcting only equinus deformity in a child causes crouch gait with increased hip and knee flexion. A second operation to lengthen the knee flexors without addressing the hip flexors causes the child to bend at the hips because of the spastic iliopsoas. Erect posture is possible only after the third operation to lengthen the hip flexors. Lengthen all the flexors of the lower limb in a single surgical session to reduce hospitalizations.



D



Multilevel surgery is not the universal solution for every diplegic child. Some children need hamstring or gastrocnemius lengthening only. Plan surgery as the child's needs dictate.

children benefit from a combined use of botulinum toxin with surgery. Inject muscles without contractures and surgically lengthen those with contractures. This combined approach with surgery decreases the extent of surgery and enables a faster return of function in the postoperative period.

**Bracing**

Most diplegic children need variations of the AFO [A]. AFOs provide a stable base for standing and maintain good joint alignment during walking. Prescribe solid, hinged AFOs or GRAFOs depending on the gait pathology. Resting and night KAFOs are used to prevent knee and ankle contractures [B]. The child with severe spasticity cannot tolerate these, wakes up often and cries a lot. Do not use night splints if there is severe spasticity or contracture, relieve spasticity first.

**Other measures**

A small group of mildly involved diplegic children may benefit from selective dorsal rhizotomy. The ideal candidate for SDR is the independent ambulator between the ages of 3-10 with pure spasticity, good balance, no deformities, and a strong family support. The procedure is technically complex, and there is a need for long intensive physiotherapy afterwards. There may be increases in the hip and spinal pathology after the procedure. The long-term effects of SDR are still controversial though it has a place in treating spasticity in a very selective group of diplegic children.

Use of intrathecal baclofen pumps are becoming more common in ambulatory diplegic children. The complication rate and the expense limit their use.

**Orthopaedic surgery**

Most deformities of diplegics can be prevented or corrected with appropriate surgery. Therefore the most successful outcomes are seen in diplegic children. Delay surgery until the child is able to cruise holding onto furniture or walk holding hands. Provide intensive physiotherapy and botulinum toxin injections to lengthen the spastic muscles and prevent contractures during this period. The ideal age of operation is between 5-7 years. Early surgery is necessary in cases with hip instability, knee flexion contracture because of spastic hamstrings and contracture of gastrocnemius-soleus unresponsive to physiotherapy, botulinum toxin or serial casting.

Define clearly all of the musculoskeletal problems of the lower extremities prior to surgery and address them in a single setting in order to obtain a successful result. Multiple operations for each separate deformity add to the burden of the child and the family, lengthen the treatment period and cause multiple hospitalizations [C].

**Multilevel surgery**

Multilevel surgery is performing multiple surgical interventions at a single session. This concept evolved when physicians realized that doing one operation at a time did not address the complex gait pathologies of CP [D]. Perform all surgery directed at the hip, knee and ankle such as hip adductor releases, hamstring and gastrocnemius lengthenings or rectus transfers simultaneously during a single session to correct jump, crouch, stiffknee or scissoring gait. Add bony procedures for deformities such as hip subluxation, femoral anteversion, external and internal tibial torsion and severe pes valgus. Prescribe intensive physiotherapy to strengthen the muscles, prevent contractures and increase function after multilevel surgery.

All children do not need multilevel surgery. Some have mild problems and require lengthening of one or two muscles only. Tailorize treatment according to the child's needs.

### Musculoskeletal problems and their treatment

Muscle imbalance, spasticity and deformities at the hips, knees and ankles contribute to the specific posture and gait patterns typical for diplegic CP.

#### Scissoring

Scissoring is a frontal plane pathology also called crossing over. It occurs as a result of hip adductor and/or medial hamstring spasticity [A]. Persistent femoral anteversion is another important cause of scissoring. The child walks with legs crossing one another. [B] The hip is in flexion, adduction and internal rotation. The knees are turned inward. Scissoring gait may accompany sagittal plane pathologies such as jump or crouch knee gait.

Give stretching exercises to the hip adductors and medial hamstrings. Advise night splints for keeping the hips in abduction in the young child. W-sitting may increase adduction and internal rotation. It is presumed to reinforce femoral anteversion. However, if W-sitting is the only way the child can maintain sitting balance, do not prevent it. Encourage tailor-sitting or using an abduction wedge. Botulinum toxin injections in a dose of 50-75 units per muscle to the adductors and medial hamstrings temporarily increase range of motion. Adductor and psoas spasticity may result in hip subluxation. Lengthening tight hip adductors and medial hamstrings becomes necessary. Femoral derotation osteotomies are necessary if scissoring is caused by femoral anteversion.

#### Jump gait

Jump gait is the most common sagittal plane pathology in young diplegic children. Almost all diplegic children begin walking with a jump knee gait pattern. Jump gait is defined as excessive hip flexion, knee flexion and equinus in stance [C]. The cause is lower extremity flexor muscle spasticity. The child walks with hips and knees in flexion and ankles in plantar flexion looking like an athlete getting ready to jump.

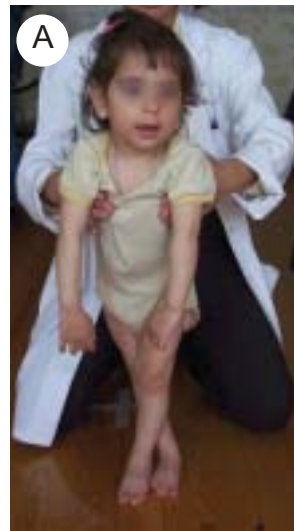Early treatment consists of multilevel botulinum toxin injections to the hip, knee and ankle flexors in addition to aggressive physiotherapy and AFOs. Strengthen the weak lower extremity muscles (gluteus maximus, quadriceps and tibialis anterior) and stretch the spastic muscles. Most children with jump gait require surgery around the age of 5-6 to release tight hip flexors and lengthen knee and ankle flexors. Perform all operations at a single session. Combine with adductor releases at the hip if necessary.

#### Crouch gait

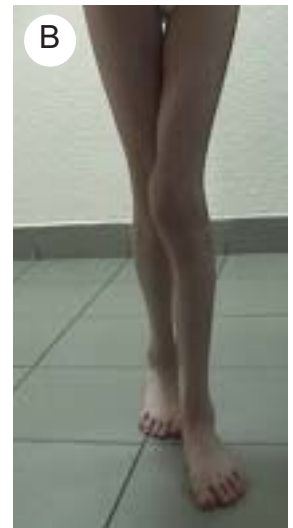Crouch gait is the second most common sagittal plane pathology and it occurs in the older diplegic [D]. It is defined as excessive knee flexion throughout the stance phase with dorsiflexion of the ankle joint. Common causes of crouch gait are short or spastic hamstrings, hip flexor tightness and excessive ankle dorsiflexion. Excessive ankle dorsiflexion may result from isolated triceps surae lengthening without addressing the spastic hamstrings. Hamstring tightness causes crouch and a short step length when walking. When sitting, tight hamstrings pull the ischial tuberosities and tilt pelvis posteriorly causing kyphosis and sacral sitting.

Treatment of crouch gait is difficult. Nonsurgical treatment methods are physical therapy to stretch the hamstrings and strengthen the quadriceps and triceps muscles. A GRAFO is useful to bring the ground reaction force in front of the knee and create an extensor moment.

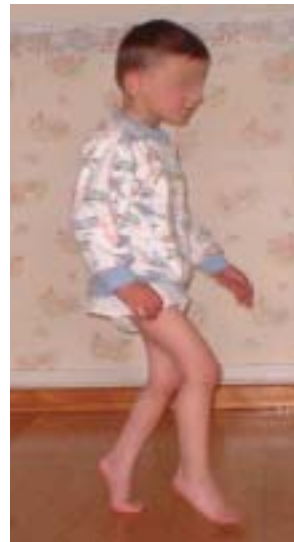Lengthen the hamstrings in children who have hamstring shortening and/or knee flexion contractures. After surgery,



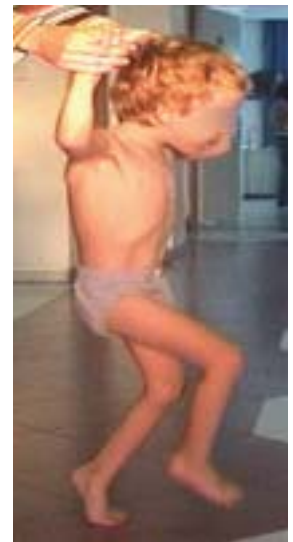
This type of scissoring is typical in the young diplegic child who is just beginning to walk.



Scissoring in the older child is because of persistent femoral anteversion, medial hamstring and adductor spasticity.



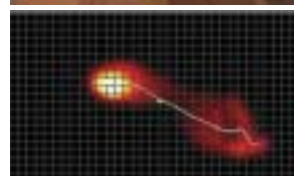C



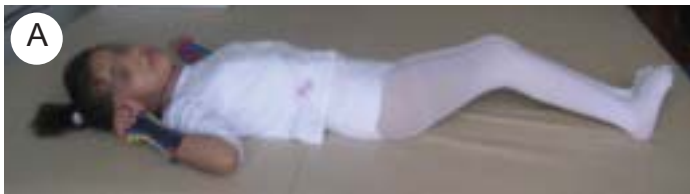Younger diplegic children show a jump gait pattern with hips, knees and ankles in flexion when they first start walking. They need to hold hands or use a walker, rarely they can balance themselves.



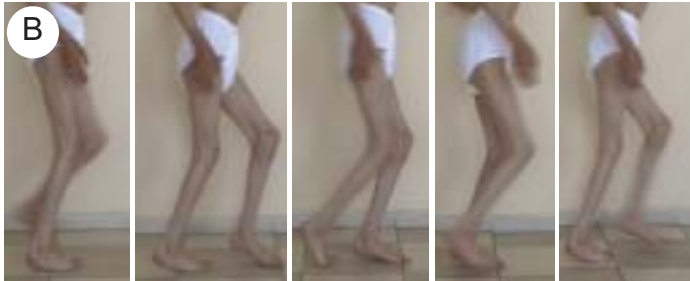D



Crouch gait, common in the older diplegic child is characterized by increased knee and hip flexion with ankle dorsiflexion. Pedobarography shows the disturbed load distribution: the heel carries most of the body weight.



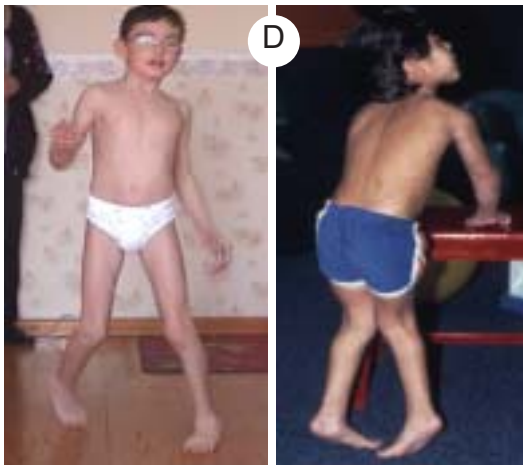Knee flexion is the most common knee deformity in the diplegic child. It occurs in combination with hip flexion and ankle equinus.



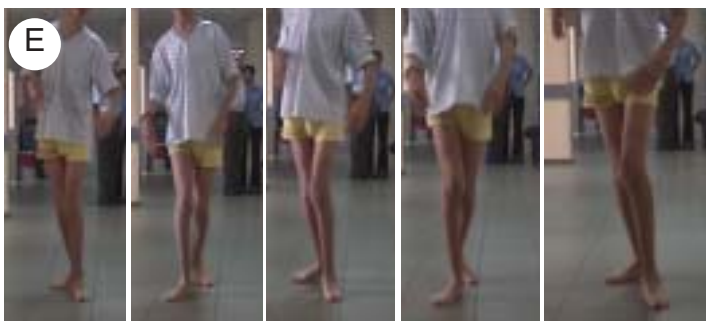Stiff knee gait is characterized by decreased knee range of motion during walking.



Genu recurvatum is usually seen as a secondary problem because of mild pes equinus.



Femoral anteversion leads to intoeing and pes equinus.



Miserable malalignment syndrome consists of femoral anteversion and external tibial torsion forcing the feet into valgus.

strengthen the gluteus maximus, quadriceps and triceps muscles by intensive physiotherapy. Use GRAFOs to prevent excessive knee flexion postoperatively.

Hamstring contractures cause knee flexion deformity [A]. Supracondylar extension osteotomy may be necessary in severe cases.

**Stiff knee**

This is a sagittal plane pathology characterized by limited range of motion in the knee joint, especially a lack of flexion in swing [B]. It occurs because of spasticity of rectus femoris muscle or unopposed rectus femoris function after hamstring lengthening. Compensatory movements of hip external rotation and circumduction are observed. The patient experiences difficulty going up steps. Step length is shortened, foot clearance is poor, shoes wear out rapidly.

Conservative treatment of stiff knee gait consists of stretching the rectus femoris. Botulinum toxin injections or motor point blocks with phenol to the rectus femoris can temporarily decrease spasticity and allow knee flexion. Transfer of the rectus femoris tendon posteriorly to the gracilis or semitendinosus can improve knee flexion.

**Genu recurvatum**

Genu recurvatum occurs in the stance phase of walking [C] and is generally associated with mild equinus caused by triceps surae spasticity, excessive spasticity in the quadriceps, and may be related to weakness of the hamstring muscles or contracture of the hip flexors.

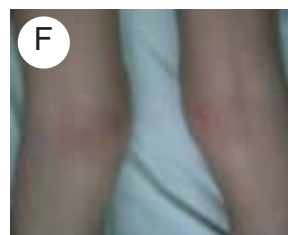Botulinum toxin injections to the spastic gastrocnemius and rectus femoris muscles are useful in young children. AFOs set in 5 degree dorsiflexion prevent genu recurvatum. Transferring the spastic rectus femoris to the medial hamstring and lengthening the gastrocnemius muscle are surgical options.

**Torsional deformities**

Femoral anteversion is naturally increased in all babies and regresses as the child grows. Persistent femoral anteversion causes scissoring and intoeing gait [D]. Adductor and flexor tightness also contribute to scissoring caused by increased femoral internal rotation. The knee and ankle joints do not function on the plane of movement and walking difficulty is increased.

There is no conservative treatment for torsional deformities. Perform proximal or distal femoral derotation osteotomies to correct this problem.

Compensatory tibial external torsion is often secondary to femoral anteversion and causes pes valgus in many children. This 'malignant malalignment syndrome' [E, F] requires external rotation osteotomy of the femur along with internal rotation osteotomy of the tibia.



Skin irritation at the medial side of the femoral condyles because legs rub against each other.

**Hip**

The risk of hip instability is less in diplegics than in the total body involved children. All diplegic children should still have baseline radiographs. Adductor stretching, positioning, and botulinum toxin injections decrease spasticity to a certain extent. Surgery is necessary in children with hips at risk.

**Pes valgus**

Pes valgus is characterized by abnormal eversion of the heel [A], convexity of the medial border of the foot [B] and prominence of the head of the talus [C]. It occurs because of spasticity of the peroneals, extensor digitorum communis and triceps surae. External tibial torsion creates a valgus stress at the ankle and contributes to pes valgus [D].

The natural history of certain mild developmental problems of the lower extremities such as pes planovalgus and genu recurvatum is benign. These disorders are seen in able bodied children as well and disappear spontaneously around 7-8 years of age as ligaments get tighter.

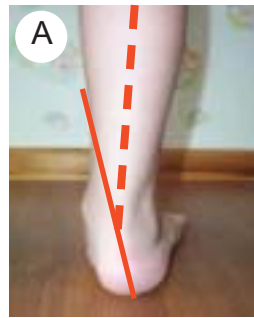
Severe pes valgus deformity causes callosities on the medial side of the foot, midfoot abduction and hallux valgus. Exercises and casting are not effective. Orthopaedic shoes or shoe inserts cannot correct the deformity. UCBL, SMO or rigid AFOs with UCBL soles (footplates) provide a stable base for standing. Surgical options are limited. Lengthen the gastrocnemius if the pes valgus is because of gastrocnemius tightness. Use AFOs postoperatively.

Tendon transfers do not correct the muscle imbalance in pes valgus. Combine lengthening the peroneus brevis muscle with bone surgery in young children. Dennyson-Fullford subtalar arthrodesis or calcaneal neck lengthening (Evans procedure) preserve hindfoot mobility without disturbing the growth potential. Delay bone surgery until preadolescence except for cases with severe deformity and rapid progression of hallux valgus. Triple arthrodesis in adults and adolescents is a last resort.

**Hallux valgus**

Hallux valgus occurs secondary to pes valgus or pes equinovalgus in ambulatory children [E]. Correct equinovalgus deformity first, hallux valgus deformity improves after this. Spasticity of the adductor hallucis muscle causes hallux valgus in plantigrade feet [F]. In this case, release the spastic muscle. Comfortable shoes with a wide toe box are useful for mild deformities. Perform metatarsal osteotomies or metatarsophalangeal arthrodesis in severe cases.

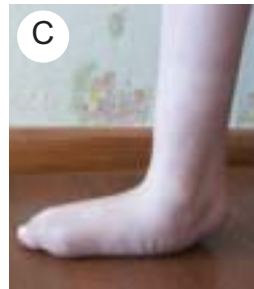The foot and ankle problems of the child with CP must be evaluated as a whole, not as separate deformities. A problem in one joint leads to problems in all the others [G,H]. Do not intervene unless you are certain of the effects of your intervention on all the other joints of the extremities.



Hindfoot valgus



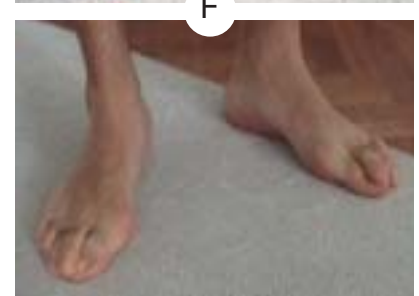
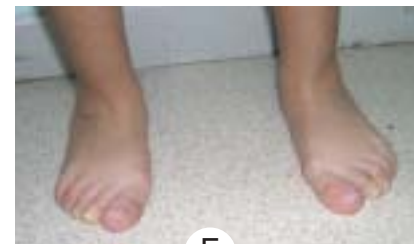Convexity of medial border in pes valgus



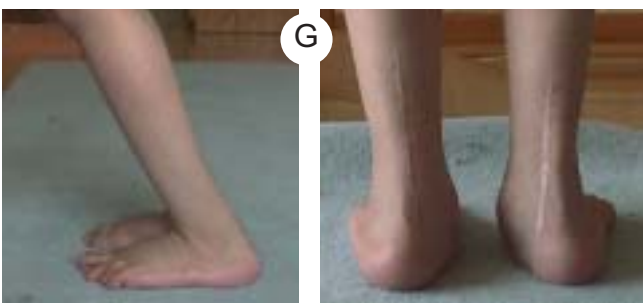Prominence of talar head



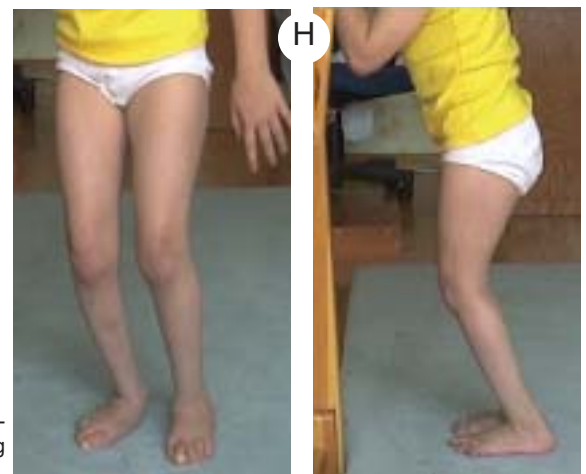Gastrocnemius spasticity contributes to pes valgus.



Hallux valgus in the younger and older child



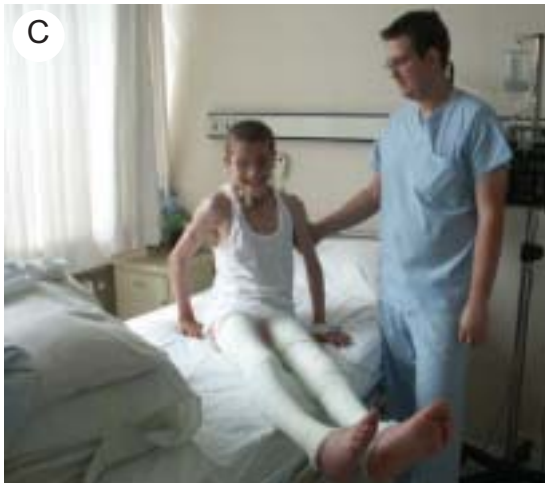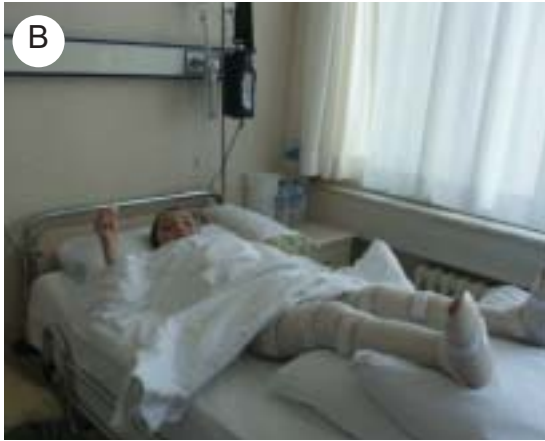This child has hallux valgus secondary to crouch gait. An Achilles tendon lengthening caused pes calcaneus that led to crouch when combined with untreated hamstring spasticity. Treatment plan should include hamstring lengthening and bilateral GRAFOs.



## Postoperative care of the diplegic child

A

	Muscle-tendon surgery	Bone surgery
Pain relief	Epidural or caudal analgesia, antispastic medication, NSAIDs, narcotics	
Immobilization	3 - 6 weeks in bivalved casts or splints, 6 weeks in cast for tendon transfers at the foot	3 weeks in cast, no need for cast in the older child after femoral derotation osteotomy
Physiotherapy	Intensive for 3 months, strengthening and range of motion exercises, switch gradually to swimming and sports	
Ambulation	2 - 4 days postoperatively	3-6 weeks



Elevation of the lower extremities, patient controlled epidural analgesia and early mobilization allow a faster return to function.

### Postoperative care

The postoperative care of the diplegic child consists of pain and anxiety relief, antispastic medication, early mobilization, bracing and intensive physiotherapy [A]. Epidural analgesia is helpful in the early period after surgery [B]. Oral baclofen or diazepam decrease muscle spasms and pain. Use plastic KAFOs or combine knee immobilizers with AFOs for immobilizing the lower extremity and allow ambulation on the second to third postoperative day after muscle tendon lengthenings [C]. The importance of strengthening the lower extremity muscles, especially those that have been lengthened cannot be overemphasized. Begin active exercises and sports after 6 weeks, as the child's general medical condition allows. Swimming, riding a bicycle or a tricycle, playing ball are excellent options. Progress from parallel bars to a reverse walker with wheels and to forearm crutches or gait poles depending on the child's balance. Do not neglect strengthening and range of motion exercises in the first 3-6 months after surgery.

The beneficial effects of the surgical intervention become obvious in the first 6 months after surgery, the child continues to progress for up to one to two years postoperatively. Neglected cases have a longer recovery period.

### Upper extremity

The upper extremity of the diplegic child is generally free from deformity. Severe cases have difficulty with fine motor control, they are slow and clumsy in activities of daily living, self-care and writing. These children benefit from occupational therapy to improve hand function.

### References

- 2004 Aiona MD, Sussman MD 'Treatment of spastic diplegia in patients with cerebral palsy: Part II' *J Pediatr Orthop B* 13(3):S13-38
- 2004 Buckon CE, Thomas SS, Piatt JH Jr, et al 'Selective dorsal rhizotomy versus orthopedic surgery: a multidimensional assessment of outcome efficacy' *Arch Phys Med Rehabil* 85(3):457-65
- 2004 Davids JR, Ounpuu S, DeLuca PA, et al 'Optimization of walking ability of children with cerebral palsy' *Instr Course Lect* 53:511-22
- 2004 Koloyan G, Adamyan A 'Surgical correction of foot deformities in children with cerebral palsy' *Brain&Development* 26 S4
- 2004 Marek J 'The natural history of the knee joint dysfunction in spastic cerebral palsy child' *Brain&Development* 26 S3-4
- 2004 Sussman MD, Aiona MD 'Treatment of spastic diplegia in patients with cerebral palsy.' *J Pediatr Orthop B* 13(2):S1-12
- 2003 Murray-Weir M, Root L, Peterson M, et al 'Proximal femoral varus rotation osteotomy in cerebral palsy: a prospective gait study' *J Pediatr Orthop* 23(3):321-9.
- 2002 Ounpuu S, DeLuca P, Davis R, et al 'Long-term effects of femoral derotation osteotomies: an evaluation using three-dimensional gait analysis' *J Pediatr Orthop* 22(2):139-45
- 2001 Chambers HG 'Treatment of functional limitations at the knee in ambulatory children with cerebral palsy' *Eur J Neurol* 8(Suppl 5) 59-74
- 2001 Rodda J, Graham HK 'Classification of gait patterns in spastic hemiplegia and spastic diplegia: a basis for a management algorithm' *Eur J Neurol* 8(Suppl 5) 98-108
- 1993 Wenger DR, Rang M *The Art and Practice of Children's Orthopaedics* Raven Press New York

### Quadriplegia

Quadriplegia is the involvement of neck, trunk and all four extremities. Quadriplegics have severe motor impairment and other signs and symptoms of CNS dysfunction such as cognitive impairments, seizures, speech and swallowing difficulties [A]. Some call this total body involvement because the trunk, neck and orofacial muscles are affected as well as the extremities.

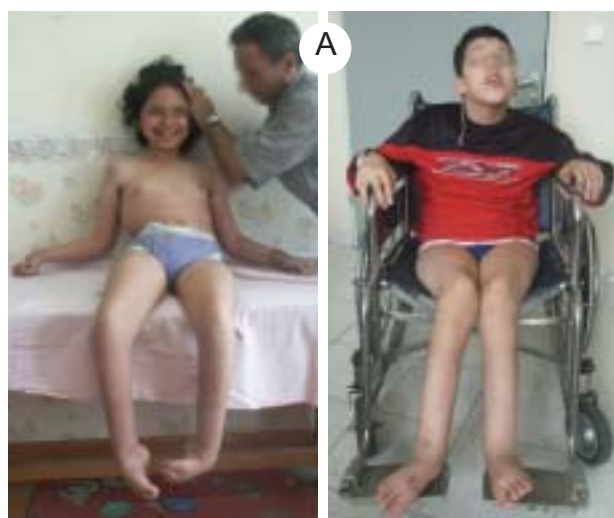Primitive reflexes persist, extrapyramidal signs such as dystonia and athetosis are common. Mental retardation, seizures, visual deficits, strabismus, bulbar dysfunction manifested by drooling, dysphagia, dysarthria and medical complications are frequent [B,C]. Gastroesophageal reflux causes feeding difficulty and can result in aspiration pneumonia [D]. Growth retardation is typical in severe cases. Many do not have bladder and bowel control. Cerebral dysfunction is more extensive and prognosis is worse. The spectrum of severity is variable, from having no sitting ability or head control to being able to walk independently. With proper treatment and education, children who have adequate mental function can use a wheelchair and communicate through a computer or other alternative aids. The majority of quadriplegics cannot be independent and need assistance in daily life. Only about 15% have the potential to walk and the rest are wheelchair bound. Most of them require lifelong all day care by the family. More than 50% of non-ambulatory quadriplegic children in North America do not survive beyond adolescence. The survivors face the late complications related to hip instability and spinal deformity.

Spine and hip deformities such as hip instability, pelvic obliquity and scoliosis are very common and interfere with sitting balance [E]. Knee and ankle deformities seen in hemiplegic and diplegic children may also exist in quadriplegia. The incidence of lower extremity contractures increase with severity of the motor impairment.

#### Goals of treatment

Management strategy changes over time. Between ages 0-2 years, emphasize physiotherapy, infant stimulation, positioning and parent education. During ages 2-5 muscle tone becomes a problem, dyskinesias manifest themselves. Look for ways to decrease muscle tone. From 5 years onwards consider orthopaedic interventions. During the teen years provide better hygiene and seating for the nonambulator; prevent pain secondary to spasticity.

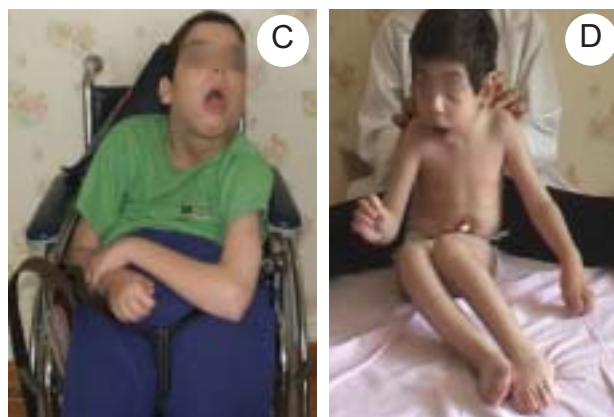The main goal is to obtain and maintain sitting balance [F]. Good sitting in the upright position facilitates care, enables independence with a motorized chair and frees the hands for any limited use. The child can become partially independent in activities of daily living. Stable hips and a straight spine are necessary to sit independently in the wheelchair. Prevent deformity in the spine and hip, correct the existing deformities, try to preserve standing ability for transfers.



Total body involved spastic children generally cannot walk, often need seating supports, have spinal and hip deformities and many other medical problems which complicate the management.

#### Associated problems in quadriplegia

Mental retardation
Seizures
Dysarthria-dysphasia
Incontinence
Hydrocephalus
Deafness
Visual impairment
Gastrointestinal disorder



Mental retardation, communication difficulty, drooling and dysphagia with difficulty swallowing and severe gastroesophageal reflux.

#### Musculoskeletal problems in quadriplegia

Spine	Scoliosis Hyperkyphosis
Hip	Subluxation Dislocation
Knee	Flexion
Ankle	Plantar flexion

#### Treatment in quadriplegia

<i>Physiotherapy</i>	Prevent hip subluxation Decrease deformity Preserve cardiovascular fitness
<i>Occupational therapy</i>	Provide assistive aids Adaptive equipment Increase independence in ADLs
<i>Bracing</i>	Spinal braces for better sitting Hip abduction brace for hip stability Resting splints for the knee & ankle
<i>Seating aids</i>	Proper positioning
<i>Spasticity management</i>	Oral medication Intrathecal baclofen pump Botulinum toxin
<i>Orthopaedic surgery</i>	Correct spine and hip problems



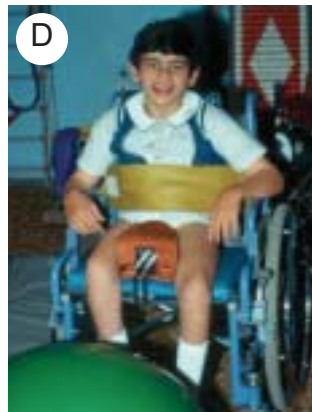**A**  
Some severely involved children do not have the motivation to sit by themselves and need external support in all positions.



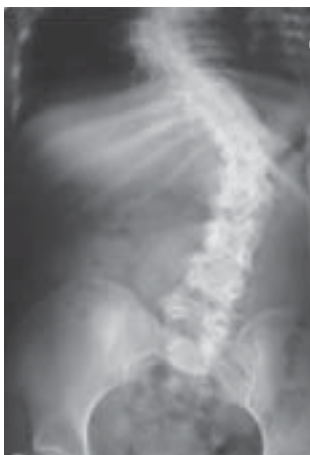**B**  
Child supported in the near-vertical position in a stander develops a sense of verticality as a preparation for ambulation.



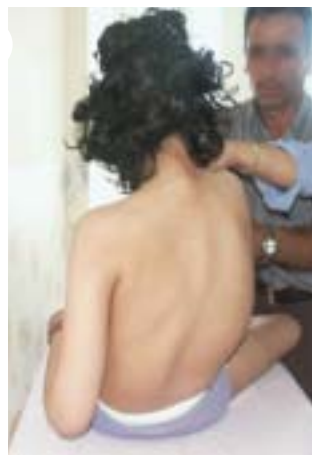**C**  
Associated problems such as visual impairments prevent mobility in the quadriplegic child.



**D**  
Child sitting supported in the wheelchair. Ideally the wheelchair should become part of the child.  
Courtesy of G. Koloyan



**E**  
Scoliosis interferes with sitting and also causes hip problems. It is the most common spinal pathology in quadriplegic children.



**Physiotherapy and occupational therapy**

Neurofacilitation techniques like Vojta or Bobath are used with the hope of stimulating the CNS towards normal development during infancy. Mobility issues arise as the baby becomes a child. Some children try to pull to stand whereas others move around hopping on their backs like a bunny or crawling backwards. There is a group of severely affected children who are not motivated to move or have no ability to move by themselves [A]. Encourage every child to stand in a suitable stander for short periods during the day regardless of the ambulation potential [B]. The child will be able to see the world vertically and have a feeling of what it's like to be standing on his feet. Standing may prevent contracture and improve cardiovascular, bowel and bladder function. It may increase bone mass and decrease fracture rate.

Less severely affected patients gradually learn to stand independently. The ability to stand independently for short periods and to take a few steps increases independence in daily living activities to a great extent. Some severely involved children who have motivation to move should use a wheeled mobility device [C]. They can learn transfers and wheelchair activities. Provide powered mobility devices to children from 2 years of age. Continue physiotherapy in the preschool and school period to prevent contractures, strengthen the upper extremity and improve cardiovascular capacity. Also provide occupational and speech therapy to improve hand function and communication to children who need support.

**Bracing**

The quadriplegic child spends almost his entire day in the wheelchair [D]. The wheelchair must be very comfortable. Do not use the wheelchair as a stretching device.

Night splints to prevent knee and ankle contractures are poorly tolerated by the child. Contoured seating aids increase sitting balance. Prefer powered wheelchairs because they conserve energy and are easier to use. Quadriplegic children with intact cognitive function can learn wheelchair skills.

Use plastic rigid KAFO's for therapeutic ambulation in parallel bars. Parapodiums and gait trainers are available to assist walking in mildly involved quadriplegic children.

**Orthopaedic treatment**

Hip instability and spinal deformity are the most important orthopaedic problems of the nonambulatory quadriplegic child. They do not respond to conservative measures and generally require orthopaedic surgery. Knee and ankle flexion deformities of the ambulatory quadriplegic child should be treated according to the same principles as in diplegia.

**Scoliosis**

Scoliosis is the most common spinal deformity [E]. The incidence and severity varies directly with the severity of motor involvement. Quadriplegics are 10 - 15 times more prone to develop scoliosis than diplegics. Scoliosis causes difficulty with sitting and impairs breathing. Pressure sores and pain cause a further decline in the life quality of the individual.

**Natural history** Keep in mind that scoliosis in CP is different from idiopathic scoliosis [A on opposite page]. Scoliosis develops by age 5 to 6 in CP and is progressive. The deformity continues to progress after skeletal maturity, especially if the curve exceeds 40°. It cannot be controlled by orthotics and requires surgical treatment. Risk factors for curve progression are younger age, poor sitting balance, pelvic obliquity, hip dislocation and the presence of multiple curves [B on opposite page].



**Conservative treatment** The goal of treatment is to preserve the ability to sit erect and comfortably [C]. Good sitting improves the patients respiratory function, feeding, gastrointestinal function, hand use, mobility and communication. Do not operate on small curves that do not disturb sitting ability or large curves in severely involved patients. Provide a thoracolumbosacral brace (TLSO) in curves of 30° to 60° to slow curve progression and allow the spine to grow before surgical stabilization. TLSOs may improve sitting balance, particularly for those patients in whom surgery is not indicated and for those who still have significant spinal imbalance after surgical treatment.

A TLSO is the most effective and economical means of providing improved trunk support. Place a custom molded seating device inside the wheelchair for patients who cannot tolerate the TLSO. Simple wheelchair modifications may lessen progression, delay surgery to allow for spinal growth prior to fusion and enable proper sitting.

**Surgical treatment** Progressing scoliosis needs surgical stabilization [D]. Surgical correction of a high grade scoliosis in a total body involved child or young adult is difficult and may require anterior and posterior procedures [E]. Perform posterior spinal fusion with segmental instrumentation to achieve a balanced spine over a reasonably level pelvis. Perform segmental instrumentation with arthrodesis (fusion) of the spine to the pelvis to correct for pelvic obliquity [F,G]. Aim to achieve spinal balance in both the coronal and sagittal planes to maximize sitting balance. Extend the fusion to the upper thoracic region to minimize the risk of developing cephalad junctional kyphosis. Include the pelvis in the fusion if pelvic obliquity exceeds 10o from the intercrestal iliac line to the top of L5 or L4 when measured on a sitting anteroposterior radiograph. Perform fusion from the upper thoracic region (T1-T3) to L5 or to the pelvis. If not fused, pelvic obliquity continues to progress. Rarely a lesser degree curve can be treated without pelvic fusion [H].

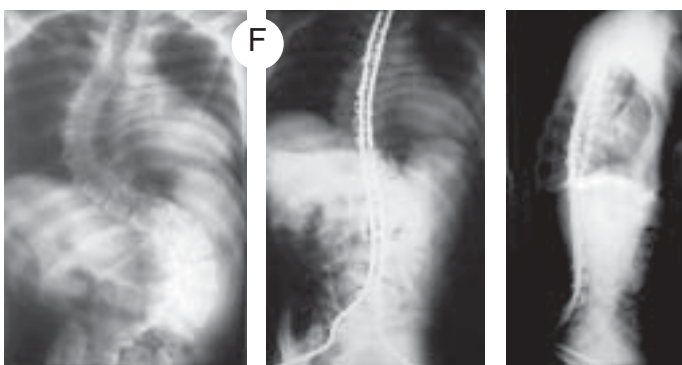
**Postoperative care** There is no need for postoperative bracing. Have the patients seated in the upright position a few days after surgery. Be aware of the physical and psychological problems of the patients. The children are malnourished, prone to infection, have difficulty communicating their needs and pain. Spasticity prevents appropriate positioning. Early postoperative mortality and morbidity is high. Preoperative nutritional status is important because malnourished patients have significantly higher infection rates and longer hospitalizations. Patients requiring both anterior and posterior fusions have fewer complications if both procedures are performed on the same day rather than at 1-to 2-week intervals. The surgeon's skill, speed, and stamina as well as patient blood loss and other factors determine the wisdom of same day anterior and posterior procedures in neuromuscular scoliosis.

Scoliosis in CP <b>A</b>		Risk factors for curve progression <b>B</b>	
Develops by age 5 - 6		Younger age	
Progresses after skeletal maturity		Poor sitting balance	
Cannot be prevented by braces		Pelvic obliquity	
Requires surgical treatment		Hip dislocation	
Worsens quality of life		Presence of multiple curves	
Shows poor prognosis			

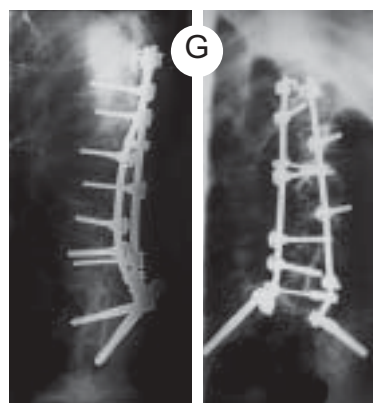
Requirements for comfortable balanced sitting & independent transfers <b>C</b>	
A straight spine and horizontal pelvis	
Hip range of motion: 30° to 90° of flexion	
Stable and painless hip	
Knee range of motion: 20° to 90° of flexion	
Plantigrade feet	

Surgical indications for scoliosis <b>D</b>	
Curves > 50°	
Fast curve progression	
Pain	
Deterioration of function	

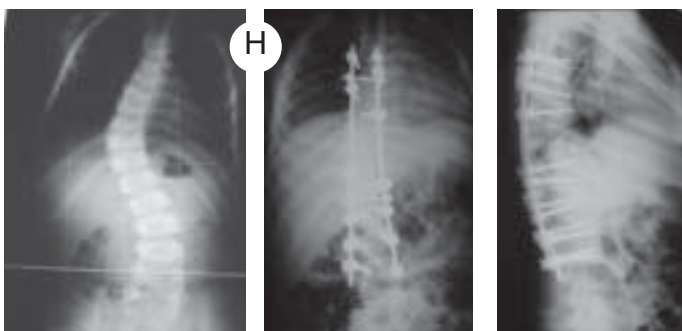
Treatment in different types of curves <b>E</b>		
	Group I	Group II
Curve type	Double thoracic or thoracolumbar	Large lumbar or thoracolumbar
Pelvic obliquity	Little	Marked
Surgical procedure	Posterior fusion alone	Combined anterior & posterior fusion
Include pelvis in fusion	Nonambulatory patients only	All patients



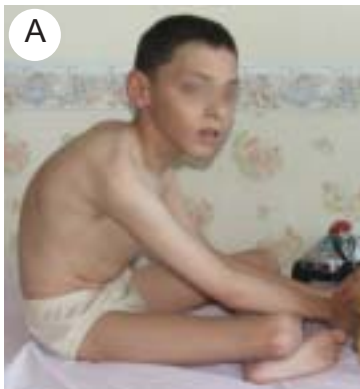Sublamina wires attached to the laminae provide secure fixation. The rods can be extended to include pelvis in the fusion. Implant costs are minimum.



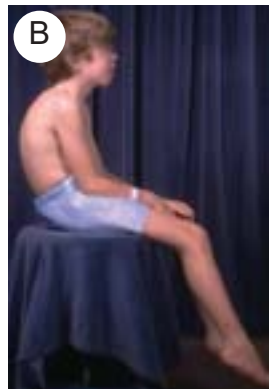Another method of obtaining lumbopelvic fusion is attaching iliac screws to spinal rods.



Use multiple pedicle screws for better correction and shorter fusion area if the dorsal skin coverage is adequate.



Long C-shaped hyperkyphosis in the child with weak spinal extensor muscles



Hamstring spasticity causes posterior pelvic tilt and sacral sitting resulting in lumbar kyphosis.

**Hyperlordosis**

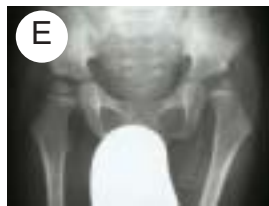Increased lordosis in the lumbar spine is usually secondary to hip flexion contractures and responds to correction of those contractures by appropriate means such as stretching or more often hip flexor release. Attempt spinal fusion and instrumentation to correct the deformity if it becomes rigid. Hyperlordosis can also be a compensatory deformity below a rigid thoracic hyperkyphosis, and it usually responds to correction of the primary problem.

**Hyperkyphosis**

Hyperkyphosis occurs in the young child with weak spinal extensor muscles [A]. There is a long, C-shaped forward posture of the entire spine. Correct this posture with proper seating, restraint straps on the wheelchair or a thoracolumbosacral orthosis providing support. A similar kyphosis occurs secondary to neglected hamstring contracture in the sitting patient. The hamstrings pull the pelvis and cause posterior pelvic tilt. The patient sits on his sacrum [B]. Lumbar lordosis decreases and thoracic kyphosis increases. Lengthen the hamstrings to correct this problem.

**C Hip dislocation results in**

Pain
Secondary scoliosis
Loss of sitting balance
Contralateral adduction deformity
Difficulty caring for the child dressing hygiene feeding



Hip subluxation is progressive unless treated.

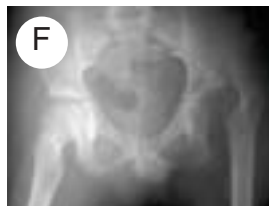**The hip**

Hip dislocation affects hygiene, sitting, and gait of the total body involved child. It causes pain by early adulthood [C]. Secondary scoliosis and contralateral adduction deformity causing ‘windswept hips’ further worsen the situation. Dislocated hips are difficult to treat, emphasize early treatment to prevent progression of hip instability.

**Classification** Hip instability is classified as “hip at risk”, hip subluxation and hip dislocation [D]. A “hip at risk” is defined as limitation of abduction to less than 45° bilaterally or markedly less abduction of one hip compared to the other. Hip subluxation is identified radiographically when the femoral head migrates partially out of the acetabulum [E]. Dislocation is present when all contact is lost between the femoral head and the acetabulum [F].

**D Hip instability**

Hip at risk	Abduction <45° bilaterally or less abduction on one side
Hip subluxation	Femoral head migrates partially out of the acetabulum
Dislocation	All contact lost between femoral head & acetabulum



Hip dislocation causes difficulty with sitting and pain. The affected leg is shorter on examination.

**Pathogenesis and natural history** The pathophysiology of hip instability is different from developmental hip dysplasia (DDH), the natural history is worse, outcome of salvage operations for the skeletally mature patients with a neglected hip are not always satisfactory. In contrast to DDH, the hips are normal at the first years of life. Progressive instability occurs later because of a combination of muscle imbalance, persistent primitive reflexes, faulty posture and absence of weight-bearing stimulation on bone to progressive instability [G].

The adductors and iliopsoas are spastic. Adduction and flexion contractures occur. Hamstring spasticity contributes to muscle imbalance. Excessive muscle tone exerts a constant force on the developing hip, deforming both the femur and the acetabulum. Deformities include femoral anteversion (normal decrease in anteversion does not occur during early childhood, fetal anteversion persists) and coxa valga (increased neck shaft angle of the proximal femur). The combination of these abnormalities leads to acetabular insufficiency and hip instability [H]. The majority of the hips subluxate in the posterior-superior direction, because the adductors and flexors are stronger than abductors and extensors.

Hip subluxation usually begins between the ages of 2-6 years though dislocation can occur as early as 18 months of age. Most hips dislocate by 6 years of age if they are going to do so. Children with the most severe neurologic involvement have the worst hips. The highest risk group is those who never achieve the ability to sit independently. The risk of hip instability is markedly less in diplegia and hemiplegia.

**G Differences between developmental hip dysplasia & hip instability in CP**

	Developmental hip dysplasia	Hip in CP
At birth	Pathological	Normal
Dislocation	First months	After age 2
Etiology	Idiopathic	Secondary to CP
Pathophysiology	Progressive acetabular deficiency leading to dislocation	Spasticity, muscle imbalance, primitive reflexes & no weight bearing leading to progressive instability
Natural history	Moderate to poor	Poor to very poor
Treatment outcome	Good	Limited

**H Causes of instability**

Muscle imbalance
Persistence of primitive reflexes
Absence of weight bearing

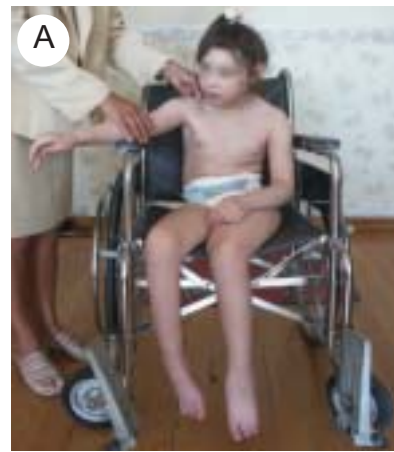**Clinical evaluation and follow up** Perform a clinical examination of the hips and obtain radiographs in every child. Asymmetric sitting and a shorter leg are clues to underlying hip subluxation/dislocation [A,B]. Evaluate the hip abduction range both in flexion and extension [C,D]. Use the Thomas test to measure hip flexion contracture. Evaluate rotation in the prone position. Excessive femoral anteversion worsens the progression of hip instability. Hip instability is always progressive [E]. Monitor progression carefully. Test and record hip abduction. Repeat clinical and radiographic evaluation twice a year between the ages of 2 - 8. Baseline AP hip radiographs are obligatory in all diplegic and quadriplegic children. Measure the migration index (MI) on hip radiographs [F]. The upper limit of normal for the migration index is 20 % at age four. Computerized tomography with three-dimensional reconstruction is not essential but it shows deformities of the femoral head and the area of greatest acetabular deficiency (posterosuperior in most-but not all-cases). One can also measure femoral anteversion on computerized tomography.

**Conservative treatment** Prescribe physical therapy to all children to preserve hip motion and promote weight bearing. Physical therapy alone does not prevent hip subluxation. Use abduction splints or a pillow to keep the knees apart. Botulinum toxin A can be injected in the adductors to temporarily decrease tone for 4 - 6 months.

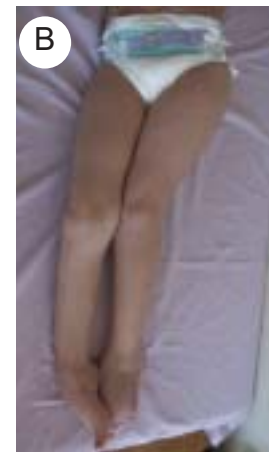**Adductor muscle lengthening** Intervene early and release the hip adductor muscles to prevent the need for complicated hip reconstruction later. Adductor release is necessary if the migration index (MI) is greater than 20 % in children with scissoring or in any child with MI between 20 - 50 %. Consider adductor lengthening in children under age 4 even if MI is up to 75 % [G]. Strive to gain at least 60° passive abduction on each side with the hip and knee flexed 90° or at least 45° abduction with the hip and knee extended. Dividing only the adductor longus is usually sufficient. Release the adductor brevis and gracilis muscles if necessary. Prefer open release to percutaneous techniques. Do the procedure bilaterally to balance the pelvis. Perform a fractional lengthening of the iliopsoas or a tenotomy if there is concomitant flexion contracture. Consider lengthening the rectus femoris muscle and the hamstring if popliteal angle is > 45° and hamstring tightness contributes to hip instability. Use traction or an abduction pillow after adductor lengthening.

Do not attempt obturator neurectomy. There are risks of overcorrection and hip abduction contracture.

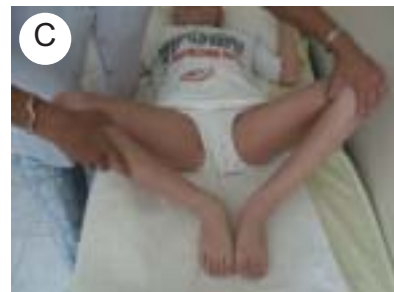**Bone Surgery** Perform a hip reconstruction when instability progresses after muscle lengthening, there is severe subluxation (MI > 75 %) or the hip is dislocated. Bony reconstruction is more reliable than adductor lengthening in children older than age four with an MI > 50% .



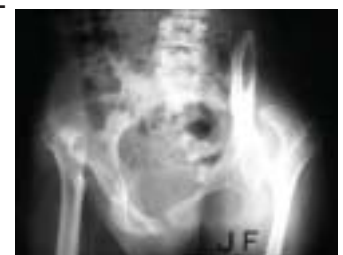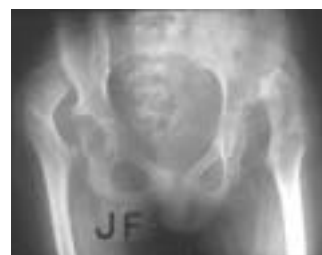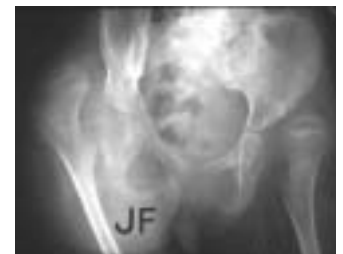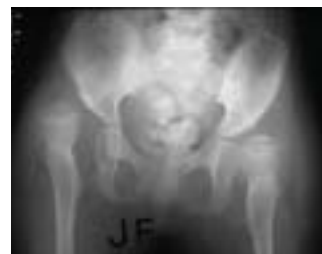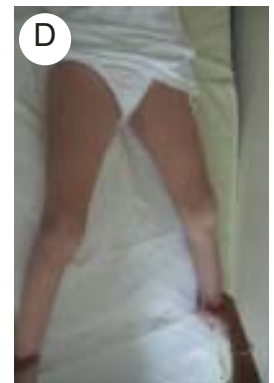Hip subluxation disturbs sitting balance and leads to discomfort.



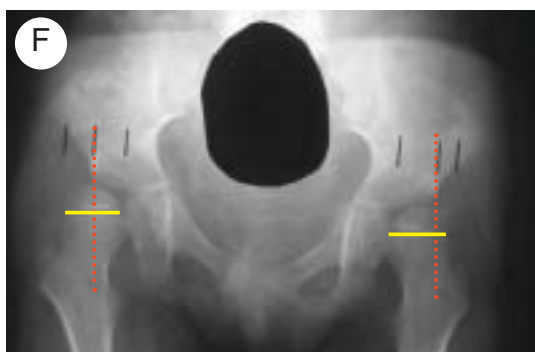
Leg length discrepancy is a sign of hip dislocation.



Examine hip abduction in flexion and extension. Obtain hip X-rays with 6 months intervals if there is persistent hip flexion or adduction tightness.

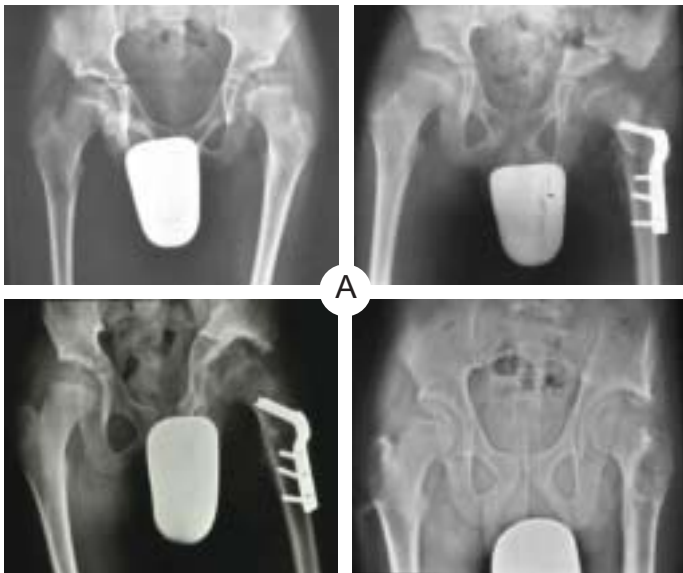


Neglected hip instability usually has a bad prognosis. The subluxed hips gradually dislocate, shortening gets worse, the high riding femoral heads disturb sitting and transfers. Intervene as early as is necessary to lengthen the spastic muscles. A minor operation saves the patient from extensive hip surgery later.

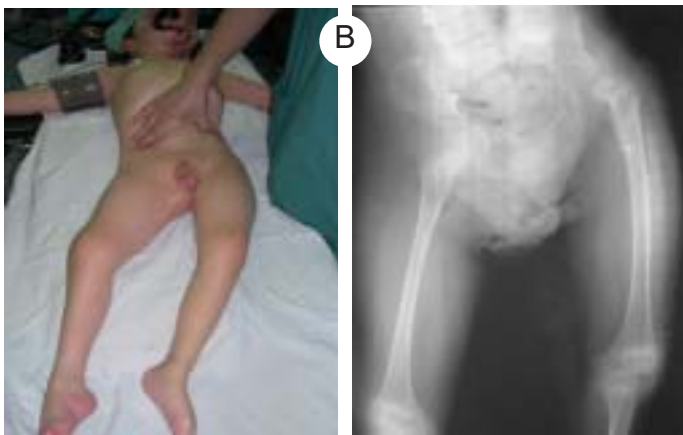


The Reimer's index: Draw a perpendicular line from the lateral acetabular margin. The percentage of the femoral head that lies lateral to this line is the migration index.

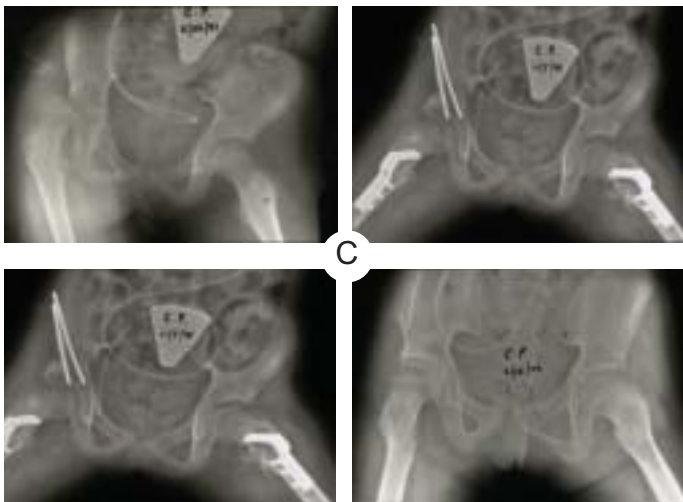Treatment of the hip at risk	
Migration index	Surgical procedure
> 20 %	Follow-up
> 20 % + scissoring	Adductor +/- iliopsoas lengthening
20 - 50 %	
50 - 75 %, age < 4	Bony reconstruction
50 - 75 %, age < 4	
> 75 %	



Long term follow up of surgical treatment of a patient with hip subluxation. The combined femoral - iliac osteotomy and soft tissue releases have produced a stable and pain free hip joint.



The 'windswept hip' is the combination of hip dislocation and adduction deformity on one side and secondary abduction deformity on the contralateral hip.



The 'windswept hip' can only be treated by a series of major operations performed in the same session. The outcome can be excellent but the operation is traumatic for the child. Try to prevent hip instability from progressing to this advanced stage with simpler measures like early adductor releases.

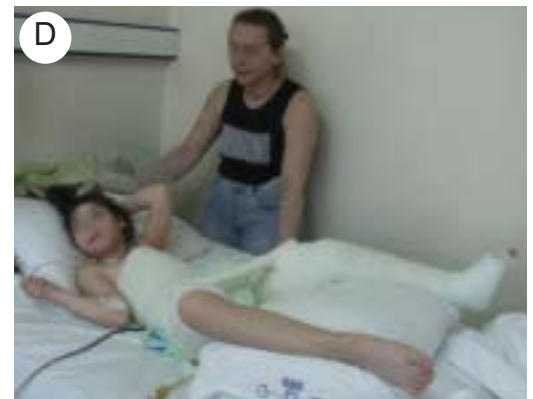The age for hip reconstruction is 4 years and onwards. Older children have better bone stock for plate fixation. The upper age limit depends on the degree of the loss of sphericity of the femoral head. Hip reconstruction is successful before permanent advanced deformity of the femoral head occurs. Once the femoral head begins to flatten medially and laterally, loss of articular cartilage is likely and pain relief after reconstruction is not satisfactory.

**Treatment of the subluxed hip** The usual surgical procedure is a combination of femoral varus - derotation osteotomy, iliac osteotomy, capsuloplasty, adductor and iliopsoas lengthening [A]. Some of these are not necessary in certain children. Plan the procedures according to the needs of the child. Preoperative three dimensional CT scans may help surgical planning.

**Treatment of the dislocated hip** There are a large number of different techniques to reconstruct the severely subluxated or dislocated hip. The surgeon has to decide on the extent of surgery depending on the patients' pathology. In spastic hip disease, the acetabulum has a very limited ability to remodel once advanced dysplasia has developed. Because acetabular deficiency is posteriorly located in most cases variations of the Dega acetabuloplasty in combination with soft tissue lengthenings, femoral shortening, varus derotation osteotomy of the femur (VDRO) and capsuloplasty is preferred.

**Windswept hip** Treatment of the windswept hip [B] is a major task. The combined procedure is a femoral varus derotation osteotomy with shortening, iliac osteotomy and flexor adductor release on the on the dislocated and adducted side. This must be accompanied by a femoral osteotomy and soft tissue releases on the contralateral abducted side [C].

**Salvage of the neglected dislocated or irreducible hip** Painful hip subluxation or dislocation in the older child is difficult to treat, attempting to reduce the hip may be impossible. The salvage procedures for these children are resection arthroplasty, valgus osteotomy, arthrodesis and arthroplasty. Proximal femoral resection arthroplasty involves interpositioning of the muscles and capsule, is easier to perform and the aftercare is more comfortable both for the family and the surgeon. Valgus osteotomy is not universally accepted. Arthrodesis of the hip can provide a stable and painless hip but is a major procedure and often not well tolerated because of the long immobilization in a hip spica cast. Total hip replacement has been done successfully even in young children but should be done by someone who has experience in hip replacement as well as understands the problems of the cerebral palsied person. In children who are able to stand for transfers and daily life activities or who are therapeutic ambulators, total hip arthroplasty provides a better outcome.



The hip spica cast is prone to complications such as pressure sores. Careful follow-up is necessary.

**Postoperative care** The patient is kept in a hip spica cast [D on previous page] for 4 - 8 weeks depending on the extent of surgery, bone quality, age and compliance.

### The knee, ankle and the foot

There are some mildly involved quadriplegic children who have the potential to stand independently and take a few steps. Correct the knee and ankle deformities [A,B] in such children to enable efficient transfers and limited ambulation. Even limited ambulation can ease the caregiver's burden enormously, if a quadriplegic patient can stand to transfer try to maintain this ability. Aim to obtain a comfortable posture in lying, sitting and in the standing frame. The knee should flex to 90° for sitting and extend to at least 20° for transfers. Severe knee flexion deformity causes skin sores behind the knee because of friction against the chair. Begin stretching and range of motion exercises early to prevent knee flexion deformity. Consider early hamstring lengthenings in children with deformity. Prescribe regular exercises, night splints and standing in the stander to protect the range of motion gained by surgical intervention. Distal femoral osteotomy is an option in children who have walking potential for knee flexion contractures.

A plantigrade foot is necessary for standing during transfers and in the stander, placing the foot comfortably on the footrests in the wheelchair and wearing shoes. Stretching, range of motion exercises and orthotics may prevent deformity in the young child. Perform soft tissue procedures, corrective osteotomies or arthrodeses in the older child.

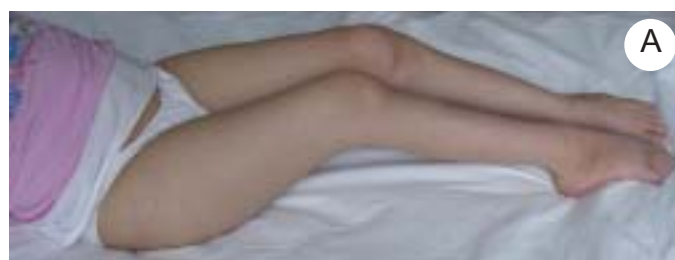### Upper extremity

Sensory deficits, spasticity, loss of selective motor control, movement disorders such as chorea, dystonia and rigidity and muscle weakness are the reasons for upper extremity dysfunction in total body involved children. Visual and cognitive disability increase the problem. The child does not use the upper extremities and in time, develops contractures and deformities.

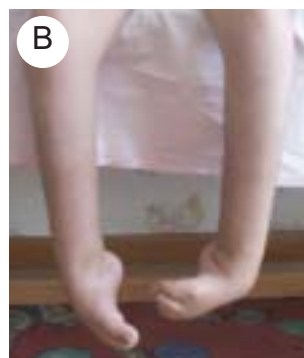
Many times there is no need for intervention beyond simple stretching and positioning. Functional splints may be useful. The shoulder internal rotation-adduction contracture does not interfere with function. The elbow flexion-pronation contracture creates problems when using forearm crutches [C]. Consider lengthening the spastic muscles and releasing the anterior capsule in a contracture of 100° and above to improve hygiene. Treat severe flexion contractures in the hand impairing hygiene and cosmesis with arthrodesis only after growth has stopped.

### References:


- 2004 Gilbert SR, Gilbert AC, Henderson RC. 'Skeletal maturation in children with quadriplegic cerebral palsy' *J Pediatr Orthop.* 24(3):292-7.  
 2004 Miller F 'Management of spastic spinal deformities' *Brain & Development* 26 S4-5  
 2004 Stott NS, Piedrahita L 'Effects of surgical adductor releases for hip subluxation in cerebral palsy: an AACPD evidence report' *Dev Med Child Neurol.* 46(9):628-45  
 2004 Yalçın S 'The spastic hip' *Brain&Development* 26 S3  
 2002 Flynn JM, Miller F. 'Management of hip disorders in patients with cerebral palsy' *J Am Acad Orthop Surg* 10(3):198-209  
 2002 Dobson F, Boyd RN, Parrott J, et al 'Hip surveillance in children with cerebral palsy. Impact on the surgical management of spastic hip disease' *J Bone Joint Surg Br* 84(5):720-6.  
 2001 Boyd RN, Dobson F, Parrott J, et al 'The effect of botulinum toxin type A and a variable hip abduction orthosis on gross motor function: a randomized controlled trial' *Eur J Neurol* 8 Suppl 5:109-119  
 2001 Gormley ME, Krach LE, Piccini L 'Spasticity management in the child with spastic quadriplegia' *Eur J Neurol* 8(Suppl 5) 127-135  
 1999 Widmann RF, Do TT, Doyle SM, Burke SW, Root L. Resection arthroplasty of the hip for patients with cerebral palsy: an outcome study. *J Pediatr Orthop.* 19(6):805-10



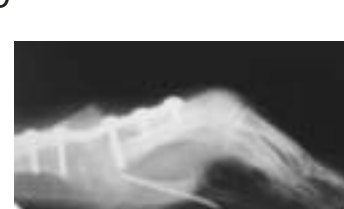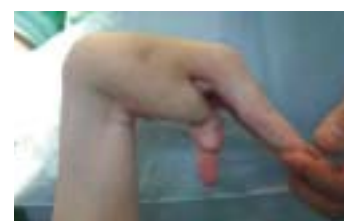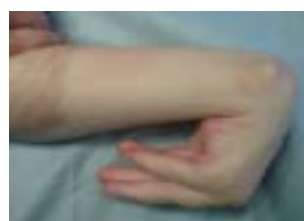Knee flexion deformity prevents therapeutic ambulation.



Improper positioning results in equinovarus deformity.



Elbow flexion-pronation contracture and wrist flexion in a quadriplegic child impairs the ability to use the upper extremities for transfers.



Patient with a severe wrist flexion contracture was treated effectively with arthrodesis.  
 Photos courtesy of G. Koloyan

- 1998 Dormans JP, Copley LA: *Orthopaedic Approaches to Treatment* 143-168 in *Caring for Children with Cerebral Palsy A Team Approach* Dormans JP, Pellegrino L Paul H Brookes Co Baltimore  
 1996 Sutherland DH, Chambers HG, Kaufman KR, et al 'Functional deficits and surgical treatment of the hip in cerebral palsy' AACPD instructional course Minneapolis  
 1995 Root L, Laplaza FJ, Brouman SN, et al 'The severely unstable hip in cerebral palsy' *J Bone and Joint Surg* 77A 703-712  
 1993 Buly RL, Huo M, Root L, et al 'Total hip arthroplasty in cerebral palsy. Long-term follow-up results' *Clin Orthop.* 296:148-53  
 1988 Root L. An orthopaedist's approach to cerebral palsy *Dev Med Child Neurol.* 30(5):569-70  
 1999 Widmann RF, Do TT, Doyle SM, et al 'Resection arthroplasty of the hip for patients with cerebral palsy: an outcome study' *J Pediatr Orthop* 19(6):805-10  
 1993 Buly RL, Huo M, Root L, et al 'Total hip arthroplasty in cerebral palsy. Long-term follow-up results' *Clin Orthop.* 296:148-53

A Movement problems in dyskinesia	
<i>Athetosis</i>	Involuntary, slow writhing movements of the hands feet face or tongue
<i>Chorea</i>	Multiple rapid jerky movements usually of the hands and feet.
<i>Dystonia</i>	Muscle tone is greatly increased. There are slow torsional contractions which increase with attempts at voluntary movement and result in abnormal posturing. Dystonia is localized more to the trunk and proximal extremities.

B Classification	
<i>Choreo-athetoid</i>	<i>Dystonic</i>
Hyperkinetic	Rigid
Purposeless involuntary movements	Co-contraction of agonist & antagonists

**Dyskinesia**

Athetosis, dystonia and chorea are the main movement disorders seen in dyskinetic children [A]. These children are initially hypotonic. As they get older, muscle tone begins to fluctuate. Involuntary movements occur when the child tries to move. Sometimes there is also movement at rest. When the child is totally relaxed in the supine position or asleep, there is full range of motion and decreased muscle tone. When the child wakes up or is excited, he becomes rigid. Lack of coordination is even more prominent during strenuous activities. The dyskinetic child spends excessive energy because of continuous uncontrolled movements. Abnormal contractions of many muscles occurring with the slightest voluntary motion increase the energy demand considerably.

**Classification**

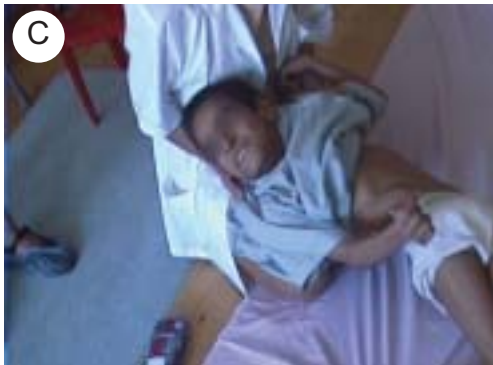Dyskinetic patients are subdivided into two groups [B]. The first and most common group are hyperkinetic or choreo-athetoid children. They show purposeless, often massive involuntary movements. The initiation of a movement of one extremity leads to movement of other muscle groups. Rapid, random and jerky movements are called chorea and slow writhing movements are called athetosis. They increase when the child is excited or frightened.

The second group are dystonic children [C]. They manifest abnormal shifts of general muscle tone induced by movement. When the child tries to move, there is a co-contraction of agonist and antagonist muscles leading to an abnormal posture of one or more parts of the body. These abnormal and distorted postures occur in a stereotyped pattern. The trunk and neck are rigid. As in all types of dyskinetic CP, the contractions in the flexor and extensor muscles of the extremities increase with voluntary movement and disappear during sleep.

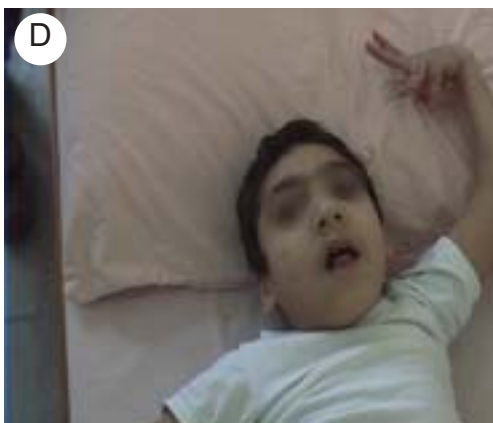Dyskinesia may accompany spasticity in a group of total body involved children [D]. Athetosis is common in combination with spastic diplegia.

**Associated features**

Mental status is generally not impaired [E]. There is communication difficulty because of oromotor dysfunction and most of these children are unable to talk. Spasticity of oropharyngeal muscles impair feeding. Growth retardation and a decreased capacity to gain weight are characteristic.



Severe dystonia interfering with sitting and positioning may respond to medical treatment only.



Involuntary contraction of hand muscles prevents effective use of the extremity.



Continuous repetitive muscle activity causes involuntary movements in all four extremities and the trunk in this 10 year old child. These movements increase when she wants to accomplish a certain task. Communication is difficult in spite of her normal mental function.

## Musculoskeletal issues

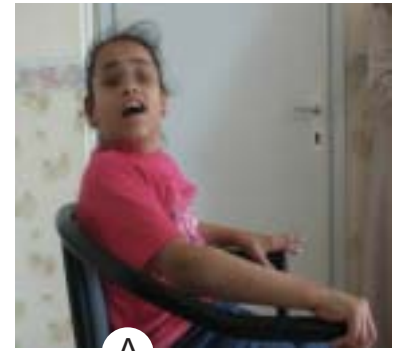The ambulation potential of dyskinetic children depends on the severity of involvement [A]. The majority of children with severe dystonia are unable to walk. Management is aimed at improving communication, independence in activities of daily living and wheelchair use. A percentage of children with athetosis can become ambulatory, however they have a clumsy and unstable gait. They lose their balance and fall easily when there is even the slightest disturbance from the world surrounding them. Contractures are almost never seen. Degenerative hip disease and acetabular dislocation are common complications during the adolescent growth spurt, particularly in children with athetoid cerebral palsy. Scoliosis is common. Complication rate of spine surgery is high. Cervical spine fusion is an option for treatment of advanced degenerative disease of the spine and C5-6 instability in the adult.

## Treatment

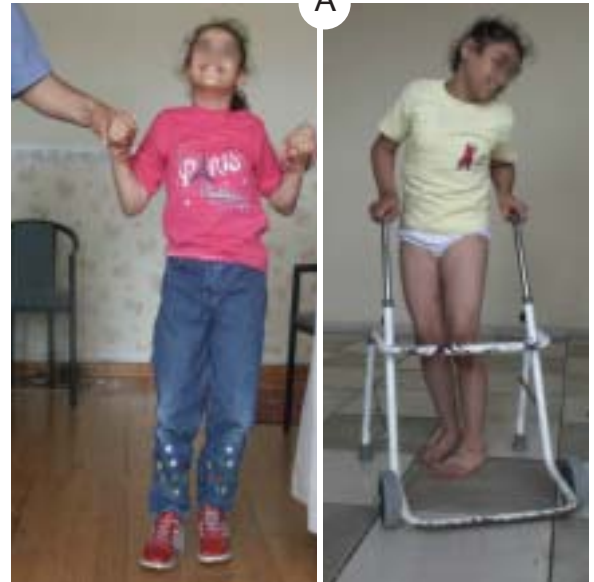Medical treatment, physiotherapy or orthopaedic surgery do not benefit children with dyskinetic CP. Medical treatment options are many in dyskinesia however their efficacy is questionable. The aim is to minimise muscle contractions and unwanted movements to ease the burden of care and to minimise the child's discomfort [B]. The use of intrathecal baclofen pumps are becoming increasingly popular in dystonic children to lessen involuntary contractions and ease the burden of care.

## References


- 2004 Panteliadis CP 'Classification' In Cerebral Palsy Principles and Management Panteliadis CP, Strassburg HM Thieme Stuttgart New York
- 2002 Einspieler C, Cioni G, Paolicelli PB, et al 'The early markers for later dyskinetic cerebral palsy are different from those for spastic cerebral palsy' *Neuropediatrics* 33(2):73-8
- 2002 Russman BS 'Cerebral Palsy: Definition, Manifestations And Etiology' *Turk J Phys Med Rehabil* 48 (2): 4-6
- 2000 Onari K 'Surgical treatment for cervical spondylotic myelopathy associated with athetoid cerebral palsy' *J Orthop Sci* 5(5):439-48.
- 1997 Mikawa Y, Watanabe R, Shikata J. 'Cervical myelo-radiculopathy in athetoid cerebral palsy' *Arch Orthop Trauma Surg* 116(1-2):116-8.
- 1993 Yokochi K, Shimabukuro S, Kodama M, et al 'Motor function of infants with athetoid cerebral palsy' *Dev Med Child Neurol* 35(10):909-16.
- 1982 Kyllerman M, Bager B, Bensch J, et al 'Dyskinetic cerebral palsy. I. Clinical categories, associated neurological abnormalities and incidences' *Acta Paediatr Scand.* 71(4):543-50.
- 1982 Kyllerman M 'Dyskinetic cerebral palsy. II. Pathogenetic risk factors and intra-uterine growth' *Acta Paediatr Scand* 71(4):551-8.



A

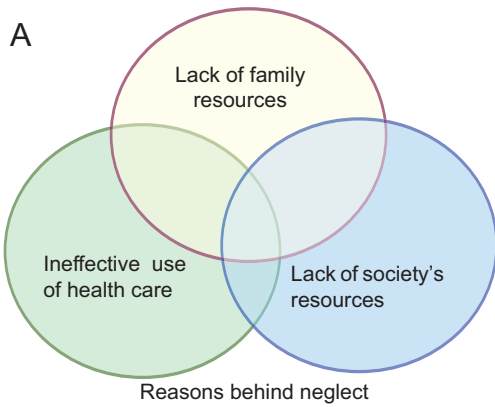


This child is able to walk with a walker but prefers crawling because dystonia disturbs her balance.



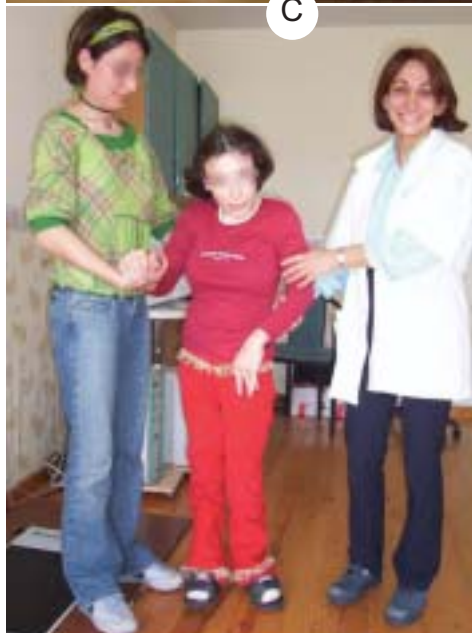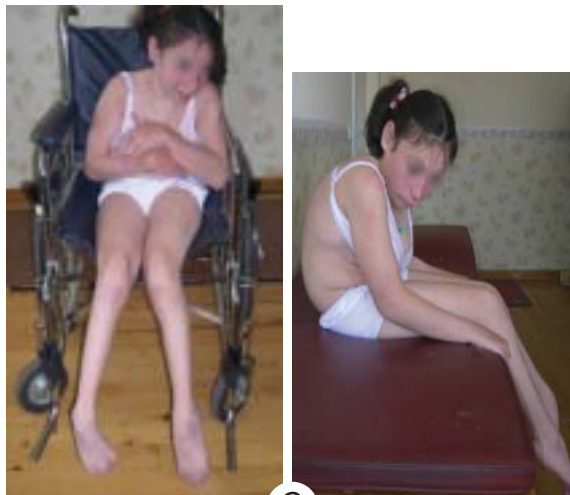B

23 year old mixed CP with severe dyskinesia and spasticity. His face, neck trunk and extremity muscles are all affected. He cannot sit in the wheelchair because of forceful muscle contractions. Intrathecal baclofen pump implantation may be a possible treatment alternative, however keeping the catheter in place would be a major challenge in such a severe case.



**B General consequences of neglect**

Secondary mental deprivation
Failure to thrive
Social isolation
Loss of mobility and ambulation
Increased burden on the family
Early mortality



Neglected 21 year old woman before and after treatment: Prior to surgery, she had severe knee flexion and ankle plantar flexion contractures, she had poor sitting balance. Simple hamstring muscle and Achilles tendon lengthenings were sufficient to improve sitting balance and enable therapeutic ambulation in solid plastic KAFOs.

**The Neglected Child**

Some children with CP cannot receive proper medical care because of reasons related to the family, the society and to the health care system they live in [A]. Lack of proper care by the family is one of the important reasons of neglect. The parents lack financial resources or are psychologically unable to provide adequate care for their disabled children. Families who are initially hopeful try to keep up with the demands of caring for a disabled child. They are frustrated or disappointed if their child does not achieve what they expect. Eventually they stop providing even the basic treatments such as home exercises because they think that their efforts are futile. Some families are ashamed of having a disabled child for cultural reasons.

In certain parts of the world the society is not well prepared or does not have the resources to accept and live with the disabled. The community is not organized to continue the care of the child with CP at school or at home. Opportunities for special education, recreation, vocational training and sheltered work are extremely limited. The child who cannot use a wheelchair outside the house because of environmental barriers remains confined to the house and loses skills. The adolescent or young adult with CP who cannot find a job has no reason to leave the house so he loses his ambulatory skills.

Resources for health care and medical education are limited in many countries around the world. These limited resources are often not used effectively because of a lack of information. The information on CP that is available is often incorrect, out-dated and sometimes even promotes harmful treatments. Physicians and other health care providers lack up-to-date education in the treatment of CP.

No matter what the reasons behind the neglect are, neglected children are unable to reach their full potential and become a burden for their caregivers in the long run. The child with diplegic CP is hurt most by neglect because he has a great potential that is wasted [B].

Physicians treating CP patients meet such patients from time to time when the families decide to provide medical care for their children at some point in their lives or when charity organizations decide to finance treatment efforts. Most neglected children need orthopaedic surgery for better function [C]. The decision to perform surgery is risky because these children have been neglected for a long time and prognosis may be poorer than expected. The child and the family may not comply with the necessary prolonged and intensive postoperative rehabilitation. The child's medical and psychosocial status may not allow major interventions. There are basic clues to making decisions about treatment of the neglected child that spring mainly from experience.

Consequences of neglect are different for diplegic and total body involved children [A on next page].

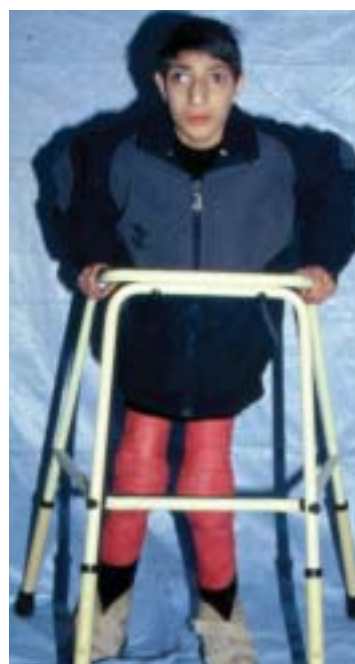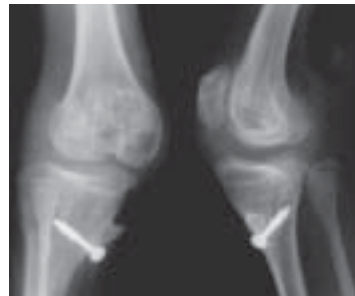
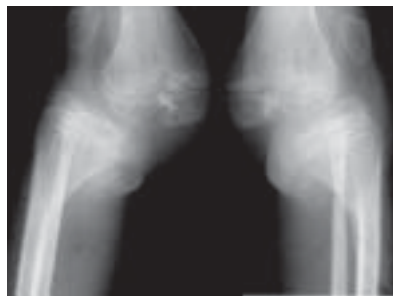
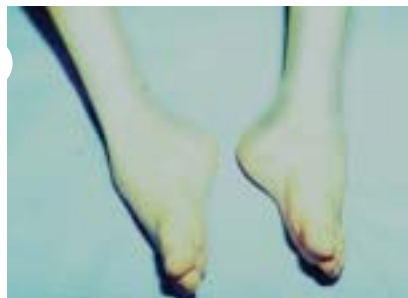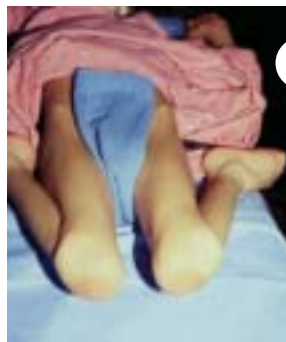**The total body involved child**

The main problems of the neglected total body involved adolescents and adults are spinal deformity and painful hips interfering with sitting as well as knee and ankle flexion contractures which prevent transfers. The patients also have severe hand flexion deformities. Growth disturbance, frequent infections and poor nutritional status almost always accompany the movement problem. Spasticity and dyskinesia are another major concern. Define the expectations clearly and get the parents' consent before advancing with treatment procedures.



Spine surgery is a difficult operation that places a great burden on the family and the child. Morbidity and mortality risks are high because of the poor general medical condition. Consider spine surgery only if there is a strong family support even if the patient's medical condition permits. Proper preoperative care does not decrease the risk of complications after spine surgery.

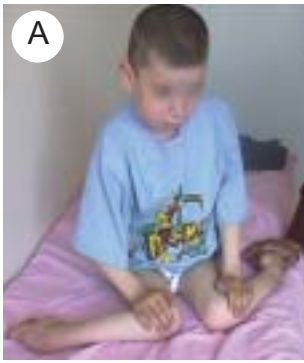Operations for the painful hip are relatively easy, but families prefer nonsurgical intervention most of the time. Advise analgesic medications and proper positioning. Perform hamstring and Achilles tendon lengthenings if there is a potential for standing and therapeutic ambulation. Do not attempt temporary measures such as phenol or botulinum toxin injections in this group of patients who seek more radical solutions to their problems [B].



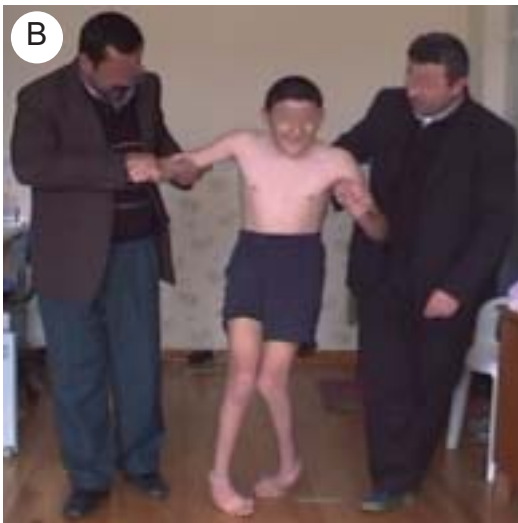Severe patella alta, knee flexion and equinus contractures in a neglected adolescent were treated with osteotomies and advancement of tuberositas tibia. The child was able to use a walker and stand in plastic KAFOs after surgery.

Courtesy of G. Koloyan

A Consequences of neglect	
Total body involved	Diplegic and hemiplegic
Failure to grow	Loss of motivation to move
Poor nutrition	Fear of falling
Frequent infections	Fragile bones
Painful hips	Painful knees
Severe spinal deformity	Severe knee flexion
Knee and ankle contracture	Ankle plantar flexion



Neglected 11 year old diplegic. He can crawl around the house but the equinus deformity is a major problem when he tries to stand.



Neglected 16 years old boy with spastic diplegia. He has severe flexion contractures of both lower extremities, femoral anteversion and pes equinovarus. He can walk a couple of steps with the assistance of two people. He has never used a walker and never received treatment of any kind.

### The diplegic child

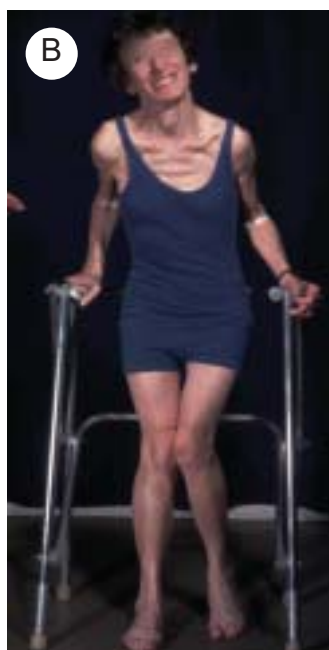The neglected diplegic child is probably the saddest situation that physicians treating children with CP will encounter. Most of these children have the potential to walk, but have been confined to immobility because of neglect [A]. Common problems include multiple severe deformities of the lower extremities. Hip problems are uncommon, instead, knee pain is present because of degenerative changes and overuse because of crawling on the knees. Children learn to walk between the ages of 4 to 7. It becomes difficult to teach them once they have missed that period in their lives. As the child grows older he loses the motivation to move, starts to feel afraid of falling and hurting himself. Bones are fragile and not used to carrying the body weight. The elderly immobile child has learnt to receive what he wants to have without spending any effort to move.

The neglected diplegic needs bone surgery as well as muscle tendon lengthenings to correct his deformities and to enable him to stand in an erect posture. Muscle weakness, bone pain and loss of selective motor control are much more pronounced compared to the young child who received adequate therapy. All deformities can be corrected, but correction of deformity does not always result in functional gain [B].

The postoperative rehabilitation period is tiring both for the child and the treatment team. Pain is an important obstacle to mobilisation. There is need for aggressive analgesic treatment. Fractures may be seen with intensive exercises. Intravenous bisphosphonate may prevent fractures. Bracing is difficult because of increased spasms and also decreased skin tolerance. It is difficult to gain ambulation in a child who has been in a wheelchair for a couple of years. In spite of all, children who have good intelligence and strong motivation should be given the chance of ambulation through orthopaedic surgery and aggressive rehabilitation.

### The hemiplegic child

The problems of the hemiplegic child are rather mild compared to total body involved or diplegic children. They become functional adults even if they do not receive physiotherapy, bracing or spasticity treatment in early childhood. The problems they will encounter are flexion contractures of the hand and equinus contracture of the foot. Hand surgery generally does not result in functional gains because of poor sensation and neglect. Equinus contracture will respond to Achilles tendon lengthenings. The patients do not like to use AFOs after surgery especially if they have been used to walking tiptoe for a long time.



The halo effect: As the baby with CP grows and becomes an adult he loses all the sweetness and cuteness of infancy and childhood. He gradually turns into a disabled adult and the people around him stop treating him with the affection and sympathy they had when he was a cute little child. This change in attitude is difficult to handle and the adult with CP is pushed towards social isolation.

Goals of management		Management modalities	
C	Maintain function	D	Physiotherapy
	Maintain walking		Analgesic medication
	Treat pain		Antispastic medication
	Orthopaedic surgery		

E	Effects of aging on outcome of therapy
	Prominent muscle weakness
	More time and effort for strengthening
	Less cardiovascular capacity
	Slower recovery

General problems of the adult		F
Musculoskeletal pain		
Neck 50% in spastic, 75% in dyskinetic CP		
Back		
Hip		
Knee		
Foot		
Contractures		
Overuse syndromes (in wheelchair or assistive device users)		
Fractures (more common in ambulators)		
Scoliosis (more common in nonambulatory patients)		
Gastrointestinal problems		
Constipation		
Reflux		
Dental problems		
Drooling		

## The Adult

Thanks to increased awareness of the community integration of disabled people, more children with CP [A] are becoming adult members of the society. Despite the fact that adult CP patients [B] continue to have similar problems they had as children, they often do not receive adequate medical care and physiotherapy. Diplegic and hemiplegic adults have near normal longevity. Both hearing and vision become worse with age. Total body involved adults continue to have the problems they had as children, namely; seizures, drooling, feeding and dental issues. 9% to 10.5% of adult patients with cerebral palsy have cardiovascular problems, including arterial hypertension and coronary artery disease. The goals of management and the modalities [C,D] remain the same though aging substantially affects the outcome of treatment [E].

There are certain aspects where the adult CP patient is different from the child. Some of the special problems of the adult are pain, increased rate of fractures, scoliosis and dietary issues.

### Special problems of the adult patient

#### Pain

Pain in the nonverbal patient is difficult to understand and evaluate. The patient is agitated, restless, does not eat or sleep well. Perform an extensive work-up to determine the cause of pain. Differential diagnosis includes musculoskeletal problems, gastroesophageal reflux leading to ulcers, urinary or gynaecological problems and menstruation. Common musculoskeletal system problems causing pain in the nonambulatory adult are cervical spine degeneration, scoliosis and hip pathology. Common musculoskeletal system problems causing pain in the ambulatory adult are hip, knee and foot deformities. Physiotherapy and simple analgesics may help. Consider surgery in severe cases.

#### Fractures

Adult quadriplegic CP patients have osteopenia. They have a lower dietary intake of calcium. Decreased exposure to sunlight, immobility, spasticity, and the metabolic conversion of the precursors of vitamin D to inactive metabolites by anticonvulsant medications predispose the patients to fractures. Osteoporosis becomes worse as the patient ages.

#### Scoliosis

Scoliosis occurs in 25% to 64% of institutionalized adults. Uncorrected scoliosis may result in decreased ambulation and decubiti.

#### Sexuality issues

Adolescents with cerebral palsy have delayed and prolonged puberty. The reason is poor nutritional state. They may develop precocious puberty as well. Try and recognize the timing of sexual maturation and provide age-appropriate sexual education. Also try and determine if the patient is sexually active. Pose questions regarding sexuality privately, using normalizing statements and open-ended questions.

#### Feeding and nutrition

Feeding problems in adolescents with low caloric intake may result in poor growth and decreased muscle mass at maturity. They result in an adult with low fat-free mass. Athetoid patients have higher caloric requirements. Reductions in appetite and weight are harmful to the adult who already has a low fat-free mass and resultant malnutrition. A diet with sufficient iron (particularly in female patients) is important, because iron deficiency anemia is common in women with cerebral palsy.

**General goals of management**

The goals of management in the adult with CP are to maintain function, maintain walking and to prevent or treat pain. Physiotherapy, analgesic and antispastic medication and orthopaedic surgery [A] have definite roles in this patient group. Oral tizanidin, diazepam or baclofen are options for spasticity treatment. The intrathecal use of baclofen is another alternative. Aging affects the outcome of all therapy procedures. Muscle weakness is more prominent in the adult compared to young children. Strengthening takes almost twice as much effort and energy. Cardiovascular capacity of disabled adults is markedly less than able bodied individuals. Recovery process after surgery is much slower.

**The ambulatory patient**

Deterioration of walking is the most important issue in ambulatory diplegics [B]. Adult diplegics have a greater energy expenditure when walking because of their bigger and heavier bodies. They exercise less, and receive almost no physiotherapy [C]. Depression is a problem in the adult patient. They lose the family support they had as a child and become socially isolated. Social isolation and depression contribute to the deterioration in walking ability.

Because of a lack of exercise there may be an increased rate of contractures. Treat flexion and/or adduction contracture of the hip with release and lengthening of the involved muscles together with intensive post-operative rehabilitation. Hamstring tightness causes crouched gait, short stride length and kyphosis when sitting. Lengthen the muscles to relieve this problem. Heel cord tightness and valgus/varus deformities of the feet respond to lengthening, muscle releases and split transfers.

Special problems encountered in the ambulatory adult CP patients are hip pain because of subluxated hips, malalignment syndrome causing painful knees and foot deformities. Hip subluxation is rare in the ambulatory CP child, but hip pain because of subluxated or dislocated hips may be seen in the adult. Treatment of choice is total hip arthroplasty. Apply hip spica casts for three weeks after total hip replacements to prevent early dislocations and relieve pain. Encourage the patients to stand in the cast fully weight bearing.

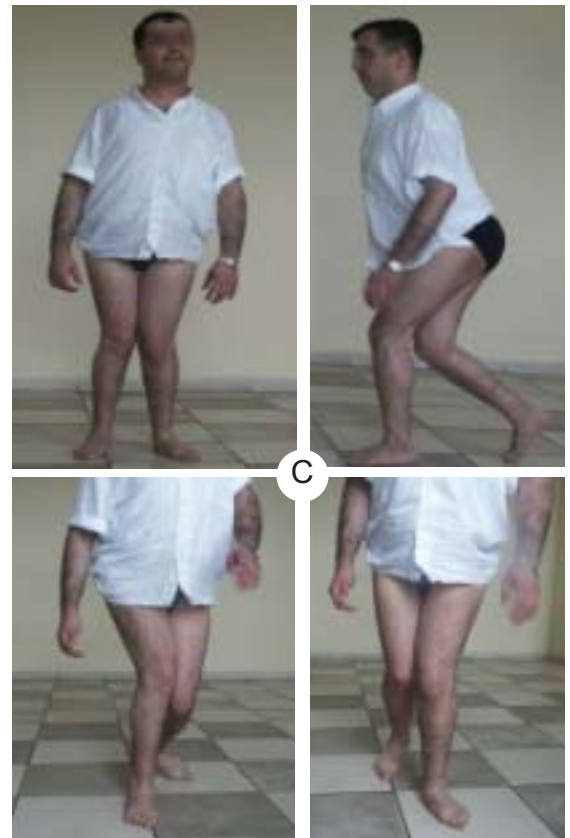Spastic rectus femoris working against tight hamstrings causes patella alta and leads to knee pain. Consider distal rectus femoris and intermedius tenotomy combined with distal hamstring lengthening. Osteoarthritis of the knee is rare.

Another important problem of gait in the ambulatory adult is the malalignment syndrome presenting as a combination of femoral anteversion and external tibial torsion [A on next page]. Malalignment syndrome results in patellofemoral osteoarthritis and painful knees. Treat with proximal femoral derotation and supramalleolar rotation osteotomy.

Common foot deformities are bunions (hallux valgus), claw toes and severe pes valgus. The standard procedure of metatarsophalangeal fusion is performed for hallux valgus. Consider resection arthroplasty, proximal interphalangeal fusion or the Ruiz procedure for claw toes. Severe pes valgus is usually associated with external tibial torsion. A treatment option is supramalleolar rotation osteotomy with triple arthrodesis [B on next page].

A Orthopaedic surgery in adult CP	
1. Muscle releases lengthenings and transfers for contractures	
	Hip flexor /adductor
	Hamstring
	Gastrocnemius-soleus
	Rectus femoris
2. Spine surgery for	
	Scoliosis
	Back pain
	Neck pain
3. Hip surgery	
	Total hip replacement
	Valgus osteotomy
	Resection arthroplasty
5. Bone surgery	
	Femoral or tibial derotation osteotomy
	Triple arthrodesis
	Hallux valgus surgery

B Problems of the ambulatory adult	
Deterioration of walking	
	Greater energy expenditure when walking
	Less exercise
	No physiotherapy
Psychosocial problems	
	Depression
	Social isolation
Musculoskeletal problems	
	Subluxated painful hips
	Malalignment syndrome
	Patella alta and knee pain
	Pes valgus-hallux valgus



This adult patient has multiple lower extremity deformities but there was no need to intervene because he has an efficient gait and functions well in the society.

**The nonambulatory patient**

Adults are physically bigger, therefore the care and transfer of the adult total body involved patient becomes a burden for the caregiver. Non-ambulatory adults often have severe osteoporosis with an increased rate of fractures. Wheelchair accommodations are sufficient for contractures that do not interfere with sitting or standing transfers in nonambulatory adults. Special problems of the nonambulatory adult are scoliosis, lack of hip abduction and knee pain [C].

Scoliosis can be progressive even in adults. Consider extensive spinal fusion if contoured wheelchairs or TLSO braces are not sufficient to provide adequate sitting balance.

Lack of hip abduction causes difficulty with hygiene and sitting. The cause of hip pain in the adult is hip subluxation and dislocation [D]. Simple analgesics and physiotherapy may be helpful. Total hip replacement is becoming increasingly popular because it offers the advantages of stability and standing for transfers [E]. Resection arthroplasty [F], arthrodesis [G] or valgus osteotomy [H] are other options.

CP is not just a pediatric problem. Exercise, stretching and other management modalities are lifelong commitments. Physicians and therapists alike need to be well prepared to deal with the problems of the adults with CP.

**References**

2004 Jahnsen R, Villien L, Aamodt G, et al 'Musculoskeletal pain in adults with cerebral palsy compared with the general population' J Rehabil Med. 36(2):78-84  
 2004 Jahnsen R, Villien L, Egeland T, et al 'Locomotion skills in adults with cerebral palsy' Clin Rehabil 18(3):309-16  
 2004 Jensen MP, Engel JM, Hoffman A et al 'Natural history of chronic pain and pain treatment in adults with cerebral palsy' Am J Phys Med Rehabil. 83(6):439-45  
 2004 Taylor N, Dodd K, Larkin H. 'Adults with cerebral palsy benefit from participating in a strength training programme at a community gymnasium' Disabil Rehabil. 26(19):1128-1134.  
 2003 Andersson C, Grooten W, Hellsten M, et al 'Adults with cerebral palsy: walking ability after progressive strength training' Dev Med Child Neurol 45(4):220-8.  
 2002 Engel JM, Kartin D, Jensen MP 'Pain treatment in persons with cerebral palsy frequency and helpfulness' Am J Phys Med Rehabil 81(4):291-6  
 2001 Hodgkinson I, Jindrich ML, Duhaut P, et al 'Hip pain in 234 non-ambulatory adolescents and young adults with cerebral palsy: a cross-sectional multicentre study' Dev Med Child Neurol 43(12):806-8  
 2000 Ando N, Ueda S. 'Functional deterioration in adults with cerebral palsy' Clin Rehabil. 14(3):300-6.



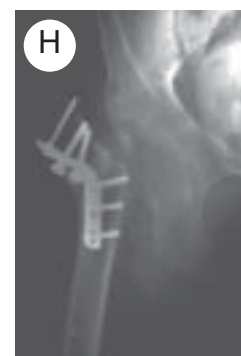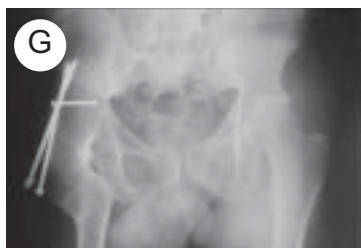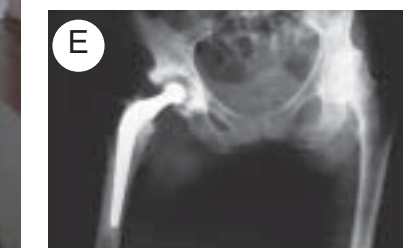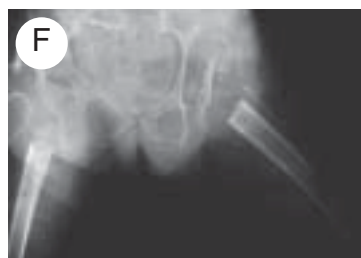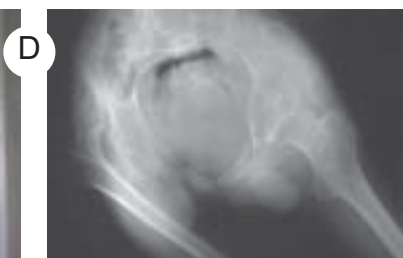
Miserable malalignment characterized by femoral anteversion, tibial external rotation and planovalgus.



This young man is a severely involved mixed diplegic. Dystonia and ataxia limit his walking capacity. He has pes valgus and spontaneous extension in both great toes.

**Problems of the nonambulatory adult**

C	Problems with care and transfer heavier severe contractures lack of hip abduction
	Fractures Osteoporosis
	Hip pain Subluxation Dislocation
	Scoliosis



Treatment options for the painful hip of ambulatory adults are total hip prosthesis, resection arthroplasty, arthrodesis and valgus osteotomy.

## Management With Limited Resources

CP is a worldwide problem. It spares no country or geographical location. The incidence of babies born with CP is the same around the world, however the prevalences at the time of school entry are different. This may mean that some children are lost by the time they approach school age or that some never have the chance to enter any sort of education.

There are many options for managing the child with CP to make him part of the society, to improve his quality of life as well as help his family. Even in well developed countries resources are rich but not infinite. In most other parts of the world disabled children are not lucky enough to benefit from most advanced technological improvements such as powered wheelchairs or newly developed drugs such as botulinum toxin. There is a limitation of specialized medical staff, equipment and finance. It remains to the physician to use his skill to help these children. The success of treatment depends upon an effective use of resources of the family, society and the health care system.

The principles of management with limited resources are to use the least expensive, time consuming and relatively more effective methods to deal with the problems of these children and to enable them to use the existing educational and vocational resources of the community they live in. In this context, the question of what is necessary and what is a luxury becomes a major concern.

### What happens when resources are limited?

#### Hemiplegia

Almost all children who have hemiplegic CP can become independent adults. They may have contractures and deformities but function efficiently despite these. Some with seizures, learning disabilities and behavioural problems experience difficulty attending school.

#### Diplegia

Most diplegic children have the potential to walk. They benefit a lot from all treatments to decrease spasticity and to improve walking capacity. When resources are limited they cannot fulfil their potential and remain nonambulatory or crawl for mobility. Mobility is directly related to integration into the society and independent living in most parts of the world. In countries where health care resources are limited education opportunities are also limited and children with impaired mobility have a greatly decreased chance of getting a proper education.

#### Quadriplegia

Quadriplegic children cannot be independent and need continuous care. They need proper health care and adequate nutrition to survive beyond adolescence. They also benefit from treatments to decrease spasticity so that the mother can take better care of them and from equipment for sitting, mobility, communication and education. When resources are limited, a higher percentage of children die early. The survivors and their families have poor life quality.

### What to do when resources are limited?

In most countries the medical treatment of children with CP is the responsibility of family rather than the government. Therefore it becomes very important that each penny spent for treatment gets good return. Keep this in mind and select the treatment that is worth the money spent.

Try to make the child as independent as possible for a better future. Special education can be very important in this regards. Tell the parents that physiotherapy improves only motor component of the child. Have them spend time for communication, cognition, self help and social development.

Provide a home bound program for children coming from far away places. Address the basic needs of the child and the family. Provide the opportunities for the child to get an education. Teach the family basic exercises to prevent contractures and deformities. Try and increase the level of communication. Find a way to establish a useful purpose for the child in the society so that he will be integrated. Aim to involve all the family members into caring for the child. Get support from the brothers and sisters of the disabled child.

#### The necessities

For all children the basic treatment should include positioning, stretching and strengthening exercises.

#### Children with walking potential

Simple solid AFOs are necessary to improve walking in the ambulatory children and to prevent contracture in the child who sits in the wheelchair.

#### Children without walking potential

Severely involved children need abductor pillows to prevent hip instability. They may need KAFOs for therapeutic ambulation. KAFOs at rest and at night may help prevent hamstring contractures. Severely involved total body involved children need proper seating arrangements in a wheelchair. A TLSO strapped to the wheelchair will provide the necessary trunk support. Oral antispastic agents such as baclofen and diazepam are readily available in many countries around the world, they are cheap and relatively safe. Gastrocnemius, hamstring and adductor lengthening surgery are safe, easy and reliable surgical interventions to relieve spasticity and improve walking in ambulatory children. Progressive hip instability is a major problem which impairs the life quality of the child, decreases survival and increases caregiver burden. In the presence of hip flexion and adduction contractures early adductor and psoas tendon releases may help prevent hip subluxation. If subluxation exists however, soft tissue releases alone will not be helpful.

The child who cannot communicate but has normal mental functions can easily use a communication board which contains a set of pictures or symbols. Simple methods to provide the basic educational needs exist and can be taught to mothers. Feeding and constipation problems may be solved using a daily routine and feeding the child at regular short intervals with food in liquid form.

Improving mobility is the most important issue worldwide. For the total body involved child, a manual wheelchair driven by caregivers may be the basic option. Powered children's wheelchairs may be unavailable or too expensive for certain parts of the world. Unfortunately in many regions environmental barriers limit the use of powered wheelchairs.